

REVIEW

Dental radiographic indicators, a key to age estimation

AS Panchbhai*

Department of Oral Medicine and Radiology, SPD College & Hospital, DMIMSU, Sawangi-M, Wardha, India

Objective: The present review article is aimed at describing the radiological methods utilized for human age identification.

Methods: The application and importance of radiological methods in human age assessment was discussed through the literature survey.

Results: Following a literature search, 46 articles were included in the study and the relevant information is depicted in the article. Dental tissue is often preserved indefinitely after death. Implementation of radiography is based on the assessment of the extent of calcification of teeth and in turn the degree of formation of crown and root structures, along with the sequence and the stages of eruption. Several radiological techniques can be used to assist in both individual and general identification, including determination of gender, ethnic group and age. The radiographic method is a simpler and cheaper method of age identification compared with histological and biochemical methods. Radiographic and tomographic images have become an essential aid for human identification in forensic dentistry, particularly with the refinement of techniques and the incorporation of information technology resources.

Conclusion: Based on an appropriate knowledge of the available methods, forensic dentists can choose the most appropriate since the validity of age estimation crucially depends on the method used and its proper application. The multifactorial approach will lead to optimum age assessment. The legal requirements also have to be considered.

Dentomaxillofacial Radiology (2011) **40**, 199–212. doi: 10.1259/dmfr/19478385

Keywords: age determination by teeth; forensic dentistry; radiology

Introduction

Radiology plays an indispensable role in human age determination. Radiological images are utilized in the process of age estimation, which is one of the essential tools in identification in forensic science.

Saunders,¹ a dentist, was the first to publish information regarding dental implications in age assessment by presenting a pamphlet entitled “Teeth A Test of Age” to the English parliament in 1837. While quoting the results from his study on 1000 children, he pointed out the value of dentition in age estimation.¹

The application of radiology in forensic sciences was introduced in 1896, just 1 year after the discovery of the X-ray by Roentgen, to demonstrate the presence of lead bullets inside the head of a victim.²

Since 1982, dental radiography, a non-destructive and simple technique used daily in dental practice, has been employed in methods of age estimation.³ Dental findings assessed by radiography are an important source of information in forensic odontological age determination.⁴

Developing teeth are used most reliably in age estimation; teeth are the most indestructible part of the body and exhibit the least turnover of natural structure. They therefore not only survive death but also remain relatively unchanged thereafter for many thousands of years.^{4–7} The anticipated developmental sequence that human dentition follows to reach complete dental development can be utilized in age determination.^{4,5,8,9} The methods based on the stages of tooth formation as appreciated on radiographs seems to be more appropriate in the assessment of age than those based on skeletal development as the dental development and calcification is controlled more by genes than by environmental factors.^{4,7,8} Teeth are less susceptible to

*Correspondence to: Dr Arati S Panchbhai, MDS, Senior Lecturer, Department of Oral Medicine and Radiology, SPD College & Hospital, DMIMSU, Sawangi-M, Wardha, India; E-mail: artipanch@gmail.com
Received 8 March 2010; revised 19 June 2010; accepted 26 June 2010

nutritional, hormonal and pathological changes, particularly in children. Age estimation in children can be based on radiographic analysis of developmental stages of the dental elements.^{4,7-10}

The age assessment methods are relatively simple and involve the identification of the stage of mineralization on radiographic images followed by their comparison with the standard stage to estimate the approximate age range.^{4,9} Various radiographic images that can be used in age identification are intraoral periapical radiographs, lateral oblique radiographs, cephalometric radiographs, panoramic radiographs, digital imaging and advanced imaging technologies.^{4,6-11} The radiographic images must be such that they include developing teeth of interest and that all the stages of dental development can be rated according to chosen development standards.⁴

The analysis of the digitized images of the available radiographs for the volume measurements has provided new perspectives in the field of age estimation. Innumerable variations of digital radiology techniques can be found in the literature, but essentially the method comprises the following steps: (1) radiographic image digitization with the aid of a scanner or video camera, or image acquisition directly from the X-ray system, coupled with a computer with monitor, printer and CD-ROM recorder; (2) image processing through the appropriate software, with resources for image rotation, translation and scaling, without the necessity of new exposures.^{6,11}

The current article presents a simplified and comprehensive picture with regard to the radiological methods used for human age estimation.

Materials and methods

A search of PubMed MEDLINE was undertaken with the search expression "dental, human age, radiology". The search included articles from 1932 to 2009 as most of the commonly used methods dealing with age assessment were published in the early years, and were modified subsequently to some extent, with the addition of recent advances and the novel methods of age determination. Out of 82 articles, 46 were relevant to the present work and were selected for the review.

For all the included studies, the information relating to the medicolegal importance of age estimation requirements for odontological age estimation significance and criteria for radiological age determination, phases of age estimation, various dental development surveys or methods used, rationale and advantages of radiological method was extracted.

Results

In humans, age determination is done for various reasons. Age determination of cadavers is carried out for reasons such as criminal cases and very mutilated

victims of mass disasters, such as fires, crashes, accidents, homicides, feticides and infanticides, etc. In living persons, the age estimation is done to assess whether the child has attained the age of criminal responsibility in cases such as rape, kidnapping, employment, marriage, premature births, adoption, illegal immigration, paediatric endocrinopathy, orthodontic malocclusion and when the birth certificate is not available and records are suspect.^{4,5,12-15}

In forensic radiology, there is a need to assess the chronological age, which is the actual age of the patient. The stages of tooth formation can be used to estimate the chronological age in young persons by applying the appropriate dental survey.⁸ The triad for odontological age estimation can be listed as:

- the subject for age estimation;^{4,16}
- appropriately chosen dental development survey;^{4,16} and
- legal consideration.^{4,16}

The present article deals with the dental implications in human age determination using radiological methods. The radiological application could be a part of a dental development survey or method applied for age assessment, or the direct radiological examination of the jaw bones for dentition. The radiological age determination is based on assessment of various features as follows:^{4-6,8,9,14,16-19}

- jaw bones pre-natally;^{4,5,14}
- appearance of tooth germs;^{4,5,14}
- earliest detectable trace of mineralization or beginning of mineralization;^{4,5,14}
- early mineralization in various deciduous teeth during intrauterine life;^{4,5,14}
- degree of crown completion;^{4,5,12}
- eruption of the crown into the oral cavity;^{4,5,12,14}
- degree of root completion of erupted or unerupted teeth;^{4,5,14,16}
- degree of resorption of deciduous teeth;^{5,14}
- measurement of open apices in teeth;^{19,20}
- volume of pulp chamber and root canals/formation of physiological secondary dentine;^{5,10,21-23}
- tooth-to-pulp ratio;^{11,12,15,21}
- third molar development and topography;^{4,5,8,13,14,21,24} and
- digitization of the available radiographs for analysis of images to obtain the dental information.^{6,11}

Analysis of these various radiographic features in the dentition of an individual corresponding to the phase of human development aids age determination.

Age estimation is grouped into three phases:

- A. pre-natal, neonatal and post-natal;^{4,5,11,13,16}
- B. children and adolescents;^{4,5,11,13,16} and
- C. adults.^{4,5,11,13,16}

For age determination, two methods are commonly used: the "Atlas method" in which radiographic dental development (mineralization) is compared with

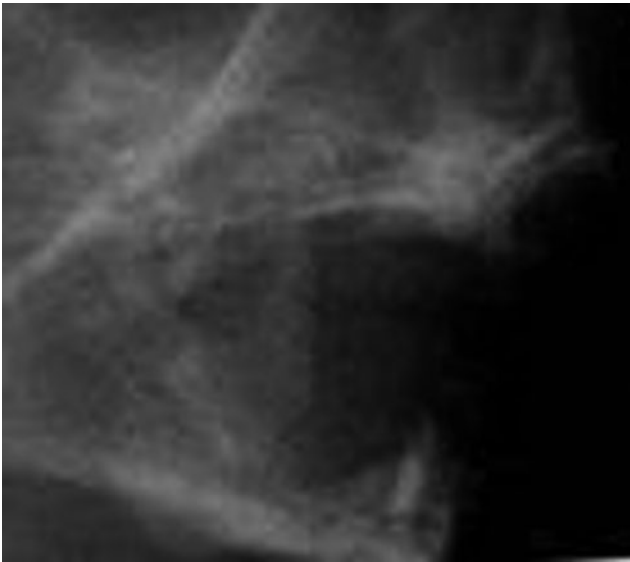


Figure 1 Radiograph of upper and lower jaws of a fetus at the sixteenth week of intrauterine life showing the initial mineralization of deciduous incisors

published standards, and the “Scoring method”, in which dental development is divided into various stages that are then assigned the scores that are evaluated through statistical analysis.^{4,25}

A. Pre-natal, neonatal and post-natal age estimation

Radiographically, the mineralization of deciduous incisors starts at the sixteenth week of intrauterine life.^{5,13} Before the mineralization of tooth germs starts, the tooth germs may be visible as radiolucent areas on the radiograph; the subsequent radiographs of the mandible will depict the deciduous teeth in various stages of mineralization as per the pre-natal age of the fetus (Figure 1).^{5,13,14} A radiograph of the mandible of the fetus taken at the twenty-sixth week of intrauterine life shows advanced mineralization in anterior teeth. The mineralized outline for the two cusps of the deciduous first molar, the one cusp outline for the deciduous second molar and the crypt of permanent first molar are seen (Figure 2).^{13,14}



Figure 2 Diagrammatic representation of a radiograph of a mandible of a fetus at the twenty-sixth week of intrauterine life showing advanced mineralization in anterior teeth, outline for two cusps of deciduous first molar, one cusp for deciduous second molar and the crypt of permanent first molar

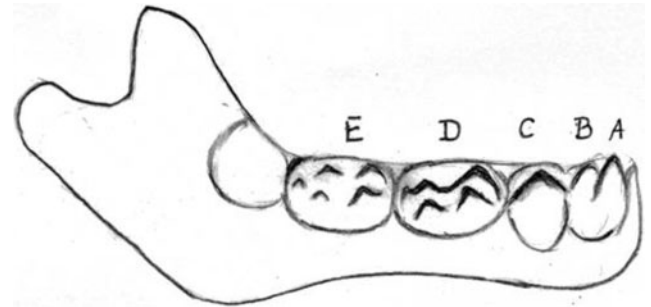


Figure 3 Diagrammatic representation of a radiograph of a mandible of a fetus at the thirtieth week of intrauterine life showing $\frac{3}{5}$ crown completion for anterior teeth, the fused cusps of deciduous first molar, five cusps of the deciduous second molar and the crypt of permanent first molar with no evidence of mineralization

A radiograph of the mandible of the fetus taken at the thirtieth week of intrauterine life shows $\frac{3}{5}$ crown completion for anterior teeth. The deciduous first molar cusps show fusion. The deciduous second molar with five cusps is seen, while there is no evidence of mineralization in the permanent first molar (Figure 3).^{13,14} While the radiograph of the newly born fetus shows completely fused cusps for the deciduous first and second molar, for the deciduous second molar there is no continuity across the occlusal surface. Within the crypt of the permanent first molar, there is evidence of a tip of one of the mesial cusps (Figure 4).^{13,14}

Stages by Kraus and Jordan: Kraus and Jordan²⁶ studied the early mineralization in various deciduous teeth as well as in the permanent first molar. The development is described in ten stages, denoted by Roman numerals from I to X; the IXth stage includes three stages and the Xth stage includes five stages. To the best of my knowledge, Kraus and Jordan completed the earliest studies on stages of mineralization of teeth in the intrauterine life (Figure 5).^{4,5,16,25}

B. Age estimation in children and adolescents

Dental age estimation in children and adolescents is based on the time of emergence of the tooth in the oral

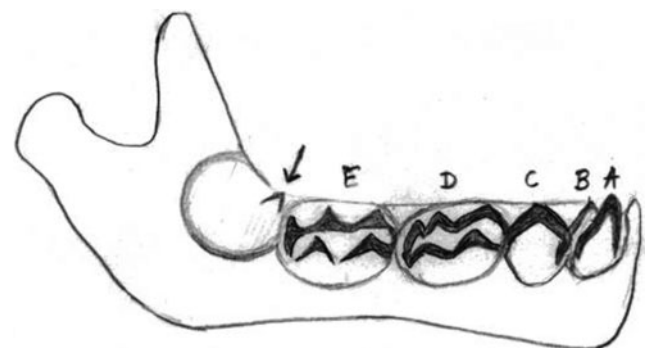


Figure 4 Diagrammatic representation of a radiograph of the mandible of a newborn fetus showing the completely fused cusps for deciduous first and second molar, and within the crypt of permanent first molar there is evidence of one mesial cusp tip

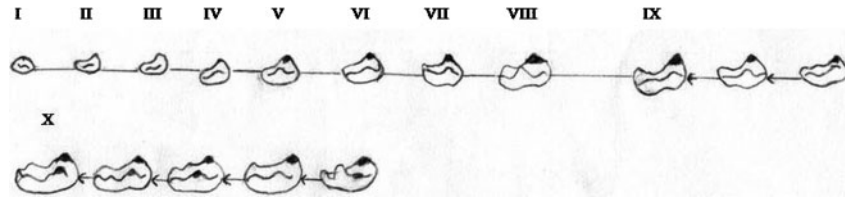


Figure 5 Developmental stages of lower deciduous first molar by Kraus and Jordan (available data). The development is described in ten stages denoted by Roman numerals from I to X; the IXth stage includes three stages and the Xth stage includes five stages

cavity and the tooth calcification.^{4,10} The radiographic analysis of developing dentition, especially when there is no clinical evidence available (2.5–6 years) as well as the clinical tooth emergence in various phases, will help in age determination (Figure 6a–c).^{4,5,10,16}

Methods applied for age determination in children and adolescents:

- Schour and Masseler method (Figure 7);^{4,11,16,27,28}
- Moorees, Fanning and Hunt method (Figure 9);^{4,5,16,29}
- Demirjian, Goldstein and Tanner method (Figure 10);^{4,11,16,30}
- Nolla's method (Figure 11);^{16,17,31} and
- age estimation using open apices (Figure 12).^{19,20}

1. Schour and Masseler method: In 1941, Schour and Masseler²⁷ studied the development of deciduous and permanent teeth, describing 21 chronological steps from 4 months to 21 years of age and published the numerical development charts for them. The American Dental Association (ADA) has periodically updated these charts and published them in 1982 (Figure 7),⁴ making it possible to directly compare the calcification stages of teeth on radiographs (Figure 8) with the standards. They have their origin in work by Logan and Kronfield³², which was carried out in 1933.^{4,10,16,27} These charts do not have separate surveys for males and females.^{10,28}

2. Moorees, Fanning and Hunt method: In this method, the dental development was studied in the 14 stages of mineralization for developing single and multirooted

permanent teeth and the mean age for the corresponding stage was determined (Table 1, Figure 9). Moorees et al²⁹ used panoramic radiographs or lateral oblique radiographs for their study. The earliest age in the survey was 6 months and the data also include the development of the third mandibular molar. Notably, female development was ahead of the male and the root formation stages showed variation compared with crown formation stages.^{4,5,16,29}

3. Demirjian, Goldstein and Tanner method: Demirjian, Goldstein and Tanner³⁰ rated seven mandibular permanent teeth in the order of second molar (M₂), first molar (M₁), second premolar (PM₂), first premolar (PM₁), canine (C), lateral incisors (I₂) and central incisor (I₁) and determined eight stages (A to H) of tooth mineralization together with stage zero for non-appearance (Figure 10) as follows:

If there is no sign of calcification, the rating 0 is given; the crypt formation is not taken into consideration.

Stage description:

(A) In both uniradicular and multiradicular teeth, a beginning of calcification is seen at the superior level of the crypt in the form of an inverted cone or cones. There is no fusion of these calcification points;

(B) Fusion of calcified points forms one or more cusps which unite to give a regularly outlined occlusal surface, or mineralized cusps are united so the mature coronal morphology is well defined;

(C) Crown half-formed, pulp chamber is evident, dentinal deposition is occurring;

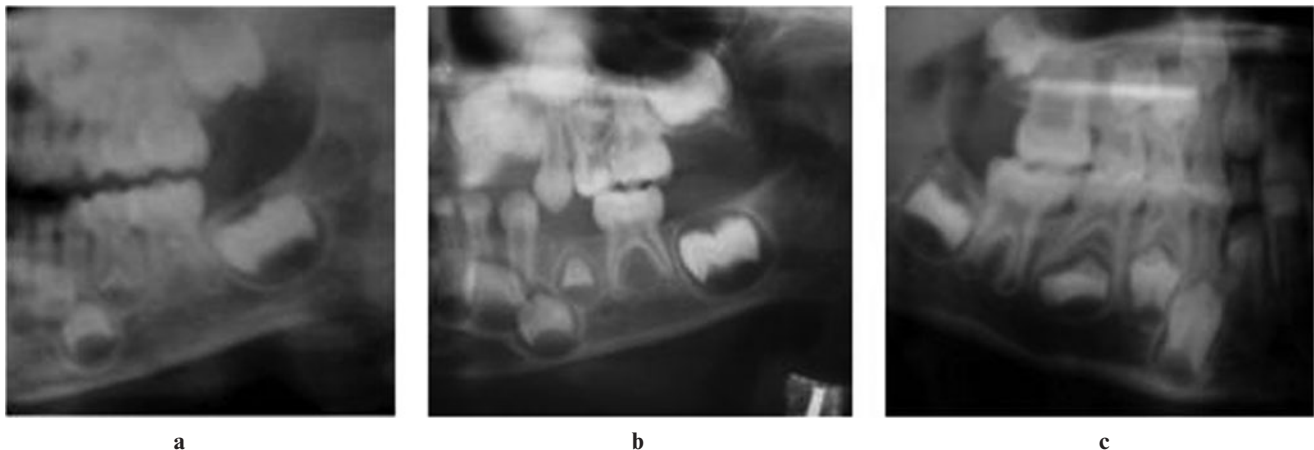

Figure 6 Radiographs showing upper and lower jaws with developing dentition of children aged (a) 2 years 6 months, (b) 3 years 9 months and (c) 6 years 8 months

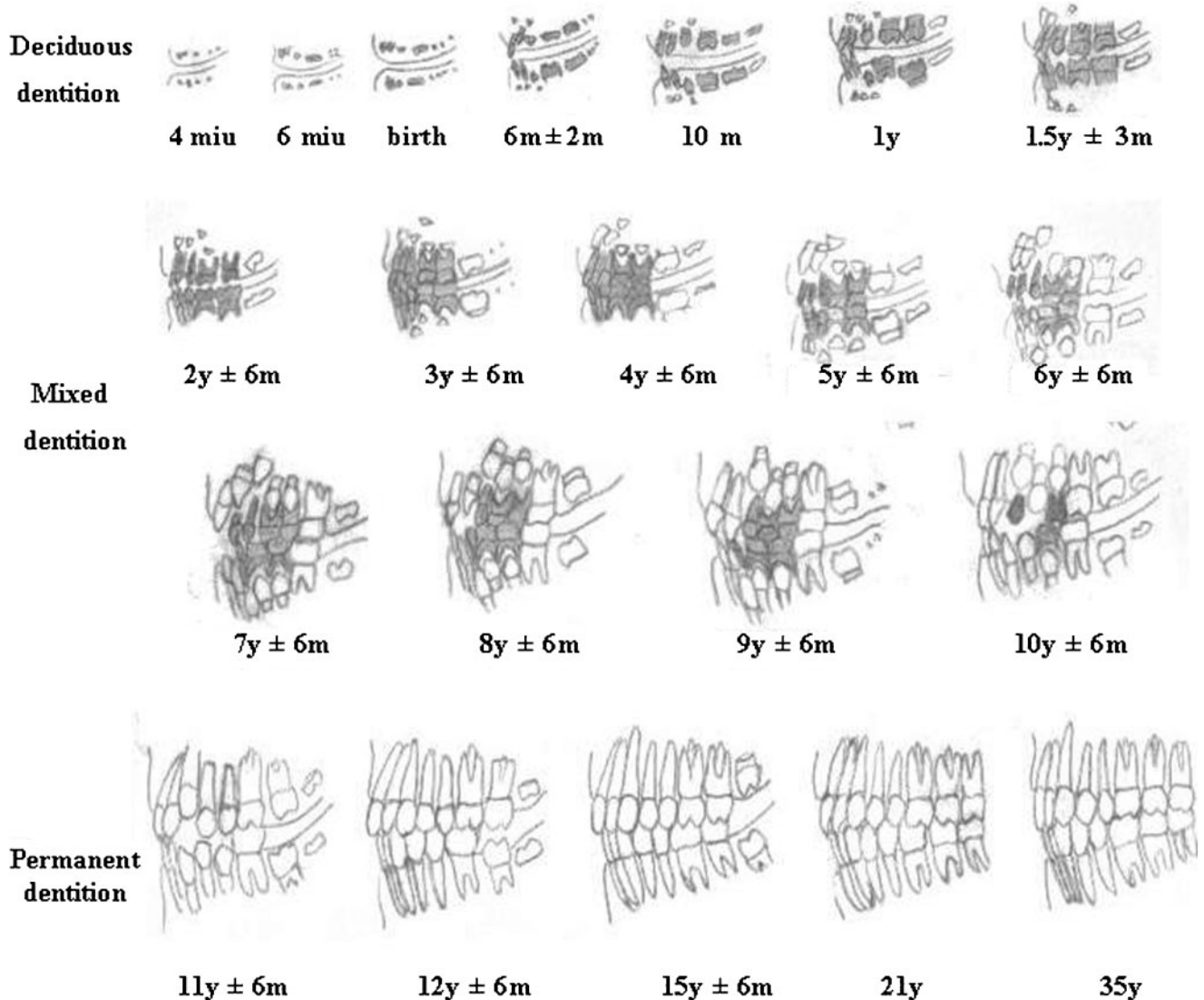


Figure 7 Dental development chart by Schour and Masseler (American Dental Association, 1982), (y = years; miu = months in intrauterine life; m = months)

(D) The crown formation is completed down to the cemento-enamel junction, pulp chamber has a trapezoidal form and beginning of root formation is seen;

(E) Initial formation of the radicular bifurcation is seen, the root length is still less than the crown height;

(F) The apex ends in a funnel shape; the root length is equal to or greater than the crown height;

(G) The walls of the root canal are now parallel and its apical end is still partially open; and

(H) The apical end of the root canal is completely closed; the periodontal membrane has a uniform width around the root and the apex.

The stages are the indicators of dental maturity of each tooth. The differences in the dental development between males and females are not usually apparent until the age of 5 years. Each stage of mineralization is given a score which provides an estimate of dental maturity on a scale of 0–100 on percentile charts. The

maturity scores (S) for all the teeth are added and the total maturity score may be converted directly into a dental age as per the standard table given or they are substituted in regression formula.^{4,5,16,30} Girls and boys have separate formulas. In females, the formula is:^{10,16}

$$\text{Age} = (0.0000615 \times S^3) - (0.0106 \times S^2) + (0.6997 \times S) - 9.3178$$

and in males, the formula is:

$$\text{Age} = (0.000055 \times S^3) - (0.0095 \times S^2) + (0.6479 \times S) - 8.4583$$

In this method, missing teeth from one side can be replaced by those from the other side. If the first molar is

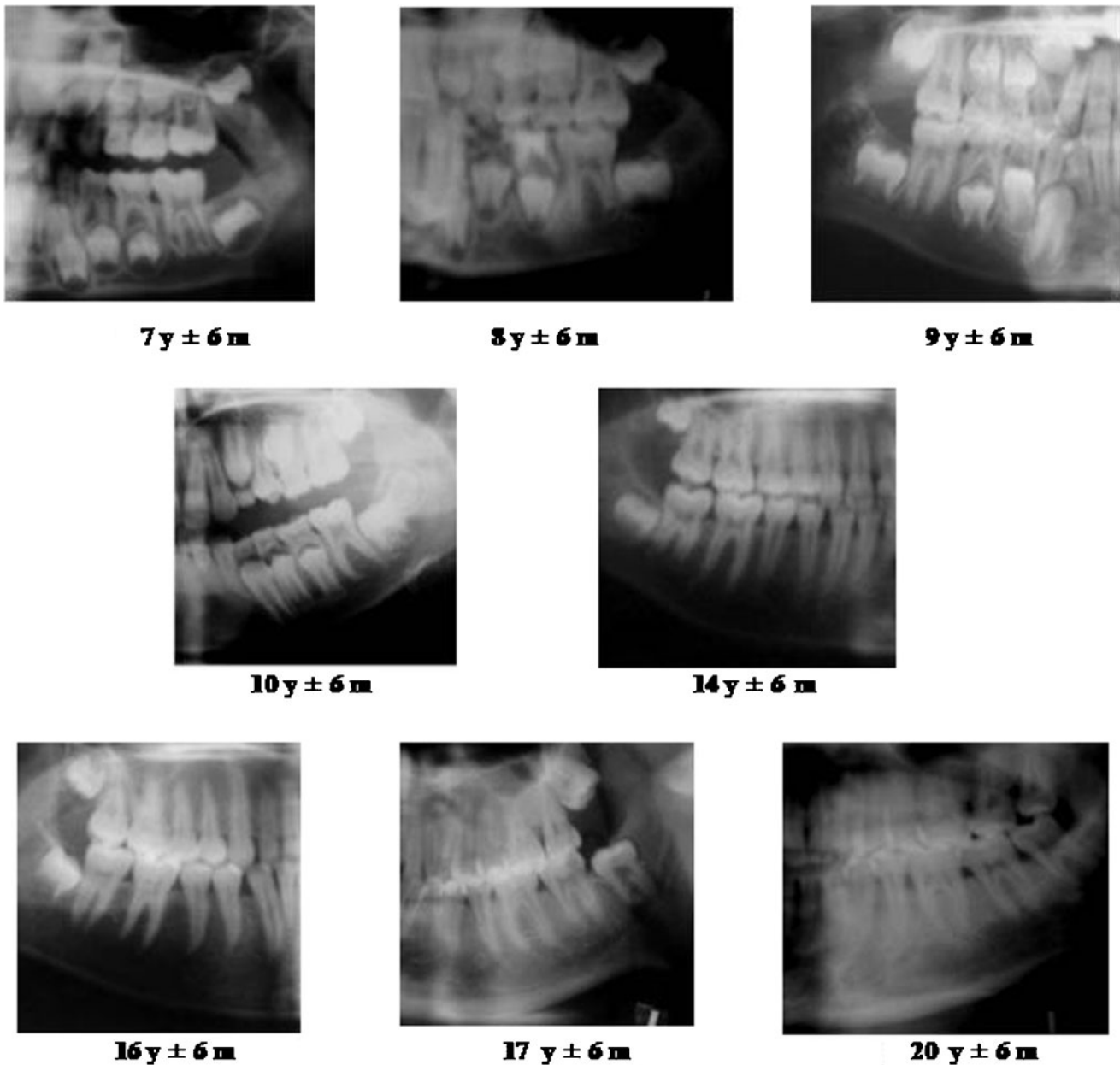


Figure 8 Cropped radiographic images showing dentition in various stages of development corresponding to given age of person (y = years, m = months)

absent, the central incisor can be substituted for it as their developmental age coincides.³⁰ This method is the most highly developed of all dental age surveys;³ the only drawbacks are that the survey does not include the developing third molar and the mandibular teeth need to be present for the survey to be applicable.^{4,10,16,30}

4. Nolla's method: Nolla³¹ evaluated the mineralization of permanent dentition in ten stages (Figure 11). The method can be used to assess the development of each tooth of the maxillary and mandibular arch. The radiograph of the patient is matched with the comparative figure. After every tooth is assigned a reading, a total is

made of the maxillary and mandibular teeth and then the total is compared with the table given by Nolla (Table 2).

The advantages of this method are that it can be applied to an individual with or without the third molar and that girls and boys are dealt with separately (Table 2).^{16,17,31}

5. Age estimation using open apices: Various studies assessed the relationship between the age and measurement of open apices in teeth.^{19,20} One of the studies determined this relationship in 455 Italian children aged between 5 and 15 years¹⁹ using panoramic radiographs of the patients, which were digitized for the analysis.

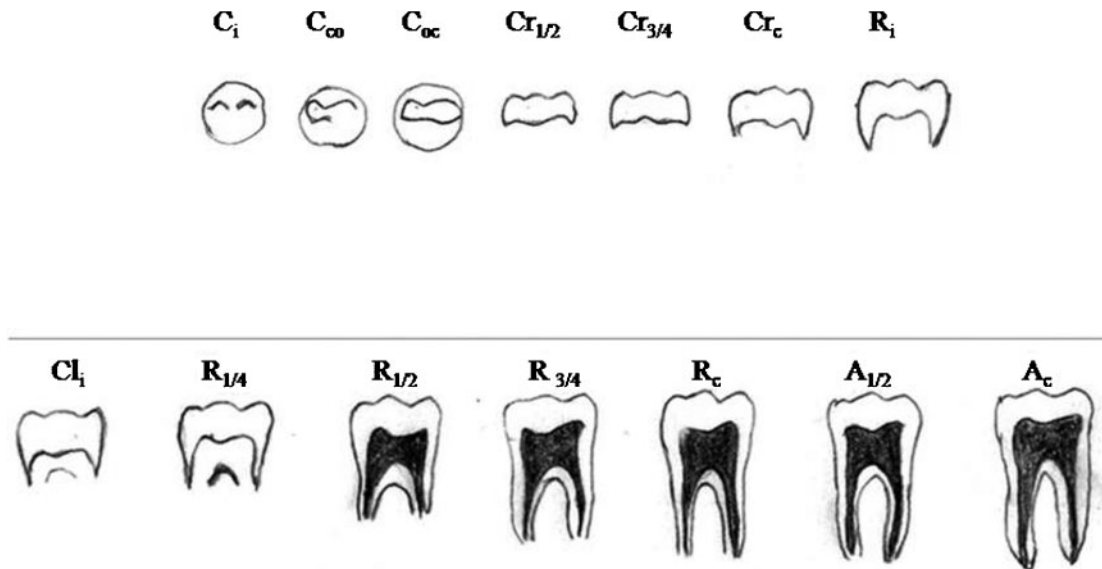


Figure 9 14 stages of tooth formation of multi-rooted tooth (Moorees et al). Initial cusp formation (C_i), coalescence of cusps (C_{co}), cusp outline complete (C_{oc}), crown half complete ($Cr_{1/2}$), crown three quarter complete ($Cr_{3/4}$), crown complete (Cr_c), initial root formation (R_i), initial cleft formation (Cl_i), root length quarter ($R_{1/4}$), root length half ($R_{1/2}$), root length three-quarters ($R_{3/4}$), root length complete (R_c), apex half closed ($A_{1/2}$), apical closure complete (A_c)

The seven left permanent mandibular teeth were valued. The number of teeth with root development completed with apical ends completely closed was calculated (N_0). For the teeth with incomplete root development, that is with open apices, the distance between inner sides of the open apex was measured (A) (Figure 12). For the teeth with two roots, the sum of the distances between inner sides of two open apices was evaluated.

To nullify the magnification, the measurement of open apex or apices (if multirooted) was divided by the tooth length (L) for each tooth (Figure 12) and these normalized measurements of seven teeth were used for age estimation.

The dental maturity was calculated as the sum of normalized open apices (s) and the numbers of teeth with root development complete (N_0). The values are substituted in the following regression formula for age estimation:¹⁹

$$\text{Age} = 8.971 + 0.375g + 1.631 \times 5 + 0.674 N_0 - 1.034 s - 0.176 s.N_0$$

where g is a variable equal to 1 for boys and 0 for girls.

C. Age estimation in adults

Clinically, the development of permanent dentition completes with the eruption of the third molar at the age of 17–21 years, after which the radiographic age estimation becomes difficult. The two methods commonly followed are the assessment of volume of teeth and the development of the third molar.

1. Volume assessment of teeth:

- pulp-to-tooth ratio method by Kvaal^{10,22}
- coronal pulp cavity index.²³

2. Development of third molar:

- Harris and Nortje method^{24,33}
- Van Heerden system.^{4,5,34}

1. *Volume assessment of teeth:* The age estimation in adults can be achieved by radiological determination of the reduction in size of the pulp cavity resulting from a secondary dentine deposition, which is proportional to the age of the individual.^{5,10,21–23}

- Method by Kvaal et al: In this method, pulp-to-tooth ratio were calculated for six mandibular and maxillary teeth, such as maxillary central and lateral incisors; maxillary second premolars; mandibular lateral incisor; mandibular canine; and the first premolar. The age is derived by using these pulp-to-tooth ratios in the formula for age determination given by Kvaal et al.^{10,22}

Using intraoral periapical radiographs, pulp-root length (R), pulp-tooth length (P), tooth-root length (T), pulp-root width at cemento-enamel junction (A), pulp-root width at mid-root level (C) and pulp-root width at midpoint between levels C and A (B) for all six teeth were measured (Figure 13). Finally, mean value of all ratios excluding T (M), mean value of width ratio B and C (W) and mean value of length ratio P and R (L) were substituted in the given formula:^{10,22}

$$\text{Age} = 129.8 - (316.4 \times M) (6.8 \times (W - L))$$

- The coronal pulp cavity index: The correlation between the reduction of the coronal pulp cavity and the chronological age was examined in a sample

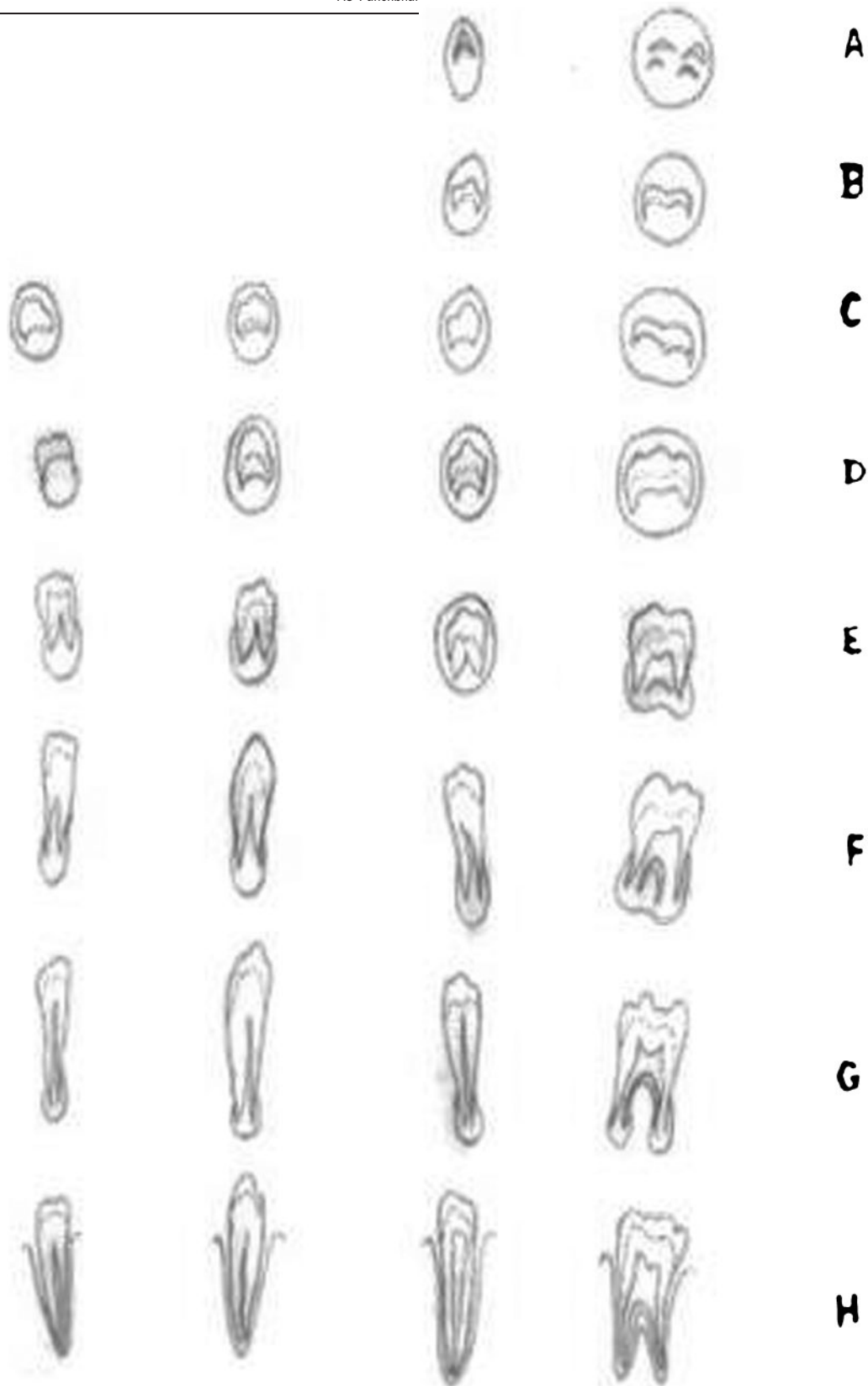


Figure 10 Eight stages (A to H) of mineralization of tooth (Demirjian system). A, beginning of calcification in the form of an inverted cone or cones; B, mineralized cusps are united to show coronal morphology; C, crown half formed, pulp chamber is evident; D, crown formation is completed up to cemento-enamel junction, with beginning of root formation; E, initial formation of the root bifurcation; F, the apex ends in a funnel shape; G, the walls of root canal are now parallel, its apical end partially open; H, the apical end of the root canal is completely closed; the periodontal membrane of uniform width around the root and the apex

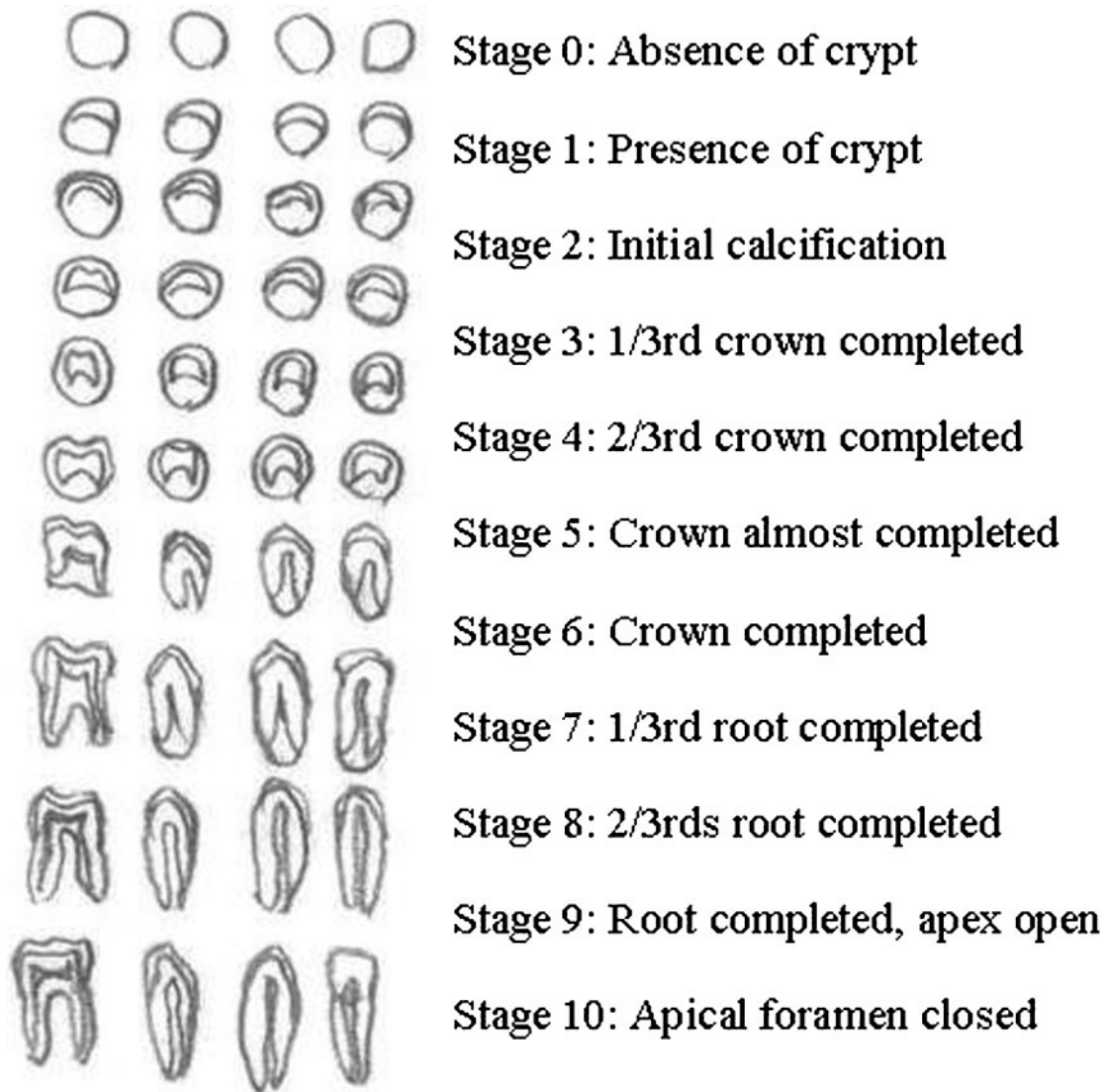


Figure 11 Ten stages of tooth formation with description (Nolla's method)

of 846 intact teeth from 433 individuals of known age and sex using panoramic X-ray photographs.²³ For each radiograph, only mandibular premolars and molars were considered, as the mandibular teeth are more visible than the maxillary ones. The side where the pulp chamber was more visible was chosen. Panoramic radiography was used to measure the length (mm) of the tooth crown (CL, coronal length) and the length (mm) of the coronal pulp cavity (CPC, coronal pulp cavity height or length) (Figure 14). The tooth-crown index (TCI) was computed for each tooth and regressed on the real age of the sample.²³

$$TCI = \frac{CPC \times 100}{CL}$$

Simple linear regression analysis was carried out by regressing the proportional coronal pulp cavity length

on the actual age for each group of teeth for males and females and for the combined sample.²³

2. Development of third molar: The radiographic age estimation becomes problematic after 17 years of age as eruption of permanent dentition completes by that age with the eruption of the third molar. Later, the development of the third molar may be taken as a guide to determine the age of the individual.^{4,5,8,14,24,35}

- Third molar development by Harris and Nortje method: Harris and Nortje³³ have given five stages (Figure 15) of third molar root development with corresponding mean ages and mean length: Stage 1 (cleft rapidly enlarging—one-third root formed, 15.8 ± 1.4 years, 5.3 ± 2.1 mm); Stage 2 (half root formed, 17.2 ± 1.2 years, 8.6 ± 1.5 mm); Stage 3 (two-third root formed, 17.8 ± 1.2 years, 12.9 ± 1.2 mm); Stage 4 (diverging root canal walls, $18.5 \pm$

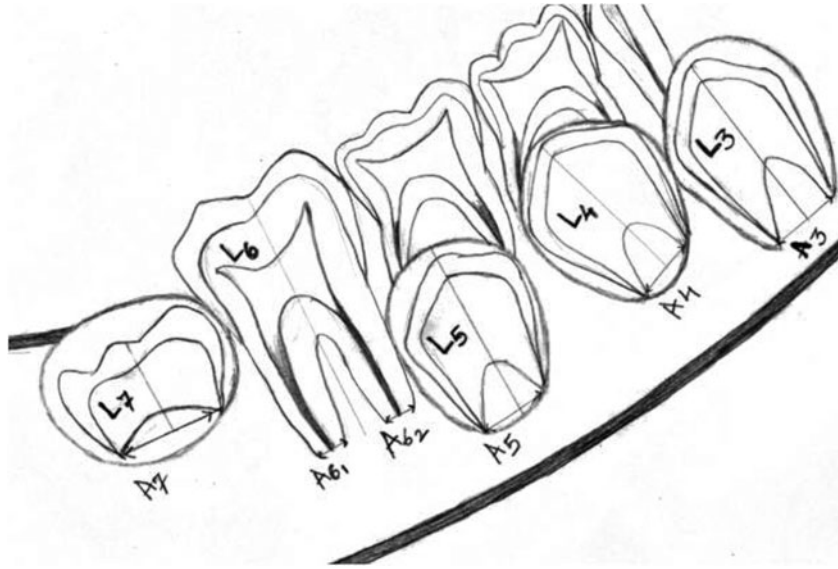


Figure 12 Showing the measurements of tooth, L = length of tooth (L₁, L₂), A = distance between inner sides of open apex (A₁, A₂)

1.1 years, 15.4 ± 1.9 mm); Stage 5 (converging root canal walls, 19.2 ± 1.2 years, 16.1 ± 2.1 mm).^{24,33,35}

- Third molar development by Van Heerden system: Van Heerden³⁴ assessed the development of the mesial root of the third molar to determine the

age. He described the development of the mesial root in five stages using panoramic radiographs (Table 3).^{4,34} The males and females were surveyed separately and no significant differences were found between them.^{4,5}

Table 1 14 stages of development of lower second molar (Moore et al)

Stages	Stage description (corresponding coded symbol)	Mean age (male)	Standard deviation	Mean age (female)	Standard deviation
1	Initial cusp formation (C _i)	3.6	0.5	3.4	0.3
2	Coalescence of cusps (C _{co})	3.9	0.4	3.5	0.5
3	Cusp outline complete (C _{oc})	4.7	0.7	4.2	0.4
4	Crown half complete (Cr _{1/2})	5.1	0.5	4.8	0.5
5	Crown three-quarter complete (Cr _{3/4})	5.6	0.6	5.3	0.6
6	Crown complete (Cr _c)	6.4	0.7	6.3	0.7
7	Initial root formation (R _i)	7.1	0.6	7.0	0.8
8	Initial cleft formation (Cl _i)	7.8	0.8	7.8	0.9
9	Root length quarter (R _{1/4})	9.1	1.0	9.0	1.0
10	Root length half (R _{1/2})	9.9	1.1	9.8	1.0
11	Root length three-quarters (R _{3/4})	10.6	1.3	10.4	1.2
12	Root length complete (R _c)	11.3	1.1	11.0	1.3
13	Apex half closed (A _{1/2})	12.1	1.3	12.2	1.1
14	Apical closure complete (A _c)	14.4	1.3	14.1	1.5

Table 2 Age norms for upper and lower teeth including third molars by Nolla's method

Age (years)	Boys		Girls	
	Sum of stages for eight mandibular teeth	Sum of stages for eight maxillary teeth	Sum of stages for eight mandibular teeth	Sum of stages for eight maxillary teeth
7	54.2	49.5	49.5	45.5
8	59.5	57.0	55.1	51.8
9	66.7	62.0	59.7	57.3
10	67.5	66.6	63.5	61.8
11	70.0	68.3	66.7	65.6
12	72.6	73.2	69.8	69.3
13	74.7	75.4	72.3	72.2
14	75.9	76.5	74.3	74.4
15	76.7	77.1	75.9	75.9
16	77.5	78.0	77.3	77.7
17	78.0	78.7	77.6	78.0

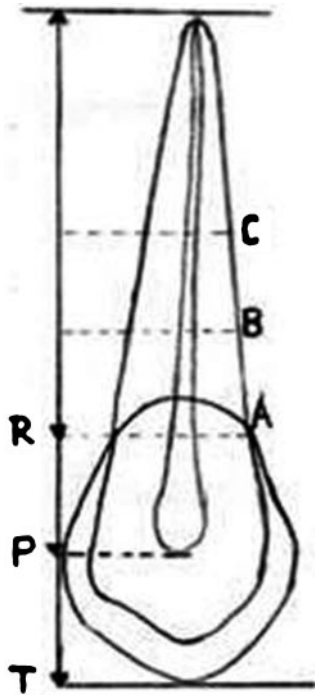


Figure 13 Diagram of premolar showing measurement sites: pulp-root length (R), pulp-tooth length (P), tooth-root length (T), pulp-root width at cemento-enamel junction (A), pulp-root width at mid-root level (C) and pulp-root width at midpoint between level C and A (B) (Kvaal et al)

Discussion

Amongst the various methods used for age determination in individuals, the radiological method has certain advantages over histological and biochemical methods. Other methods require either extraction or preparation of microscopic sections of at least one tooth from each individual;^{10,21} these methods therefore cannot be used in living individuals and in cases where it is not acceptable to extract teeth for religious or scientific reasons.^{10,21} Besides, they are quite expensive and require some sophisticated laboratory equipment.^{10,21} On the contrary, the radiographic method is a simple, quick, economic, non-mutilating and non-invasive method of age identification.^{7,10,21} Additionally, it can be applied for identifying the age in dead as well as living persons and in all communities.¹⁰

Age estimation is relatively difficult in pre-natal and neonatal phases compared with the post-natal phase. Though histological examination of tooth germs will be able to decide the age earlier in the pre-natal phase, it will be an invasive and time-consuming procedure.⁴ From the pre-natal dental development of the fetus until the eruption of the first tooth into the oral cavity post-natally, the radiological examination of the jaw bones for the developing tooth germs will be the mainstay for the age assessment (Figure 1–4).^{4,5,10,21} Similarly, in the post-natal phase, between the ages of 2.5 and 6 years *i.e.* up to eruption of the first permanent tooth, there is no clinical evidence available to determine the age, so radiography will play a major role in assessing the jaw bones for developing permanent dentition.^{4,5,14} The best precision and accuracy for radiographic age estimation is achieved when individual growth is rapid and many teeth are under development.^{36,37} After the age of 14 years, estimation becomes difficult since most of the dentition is completely developed.^{4,14,16}

Various age estimation methods or dental development surveys are available, although they are different from each other. They provide us with two types of information: the sequence of developmental events and the timing at which these events occur.⁴ Most surveys indicate that the least amount of variation in development occurs least in the younger age group but it increases with age.⁴

The Schour and Masseler²⁷ method has some drawbacks as these charts do not have separate surveys for males and females, and the mean age range of 2–5 years is put at 6 months and is thus too narrow.^{4,27,28} Later, Ublekar²⁸ modified these charts to widen these ranges. Regardless of these drawbacks, these charts are being used more commonly in age determination.^{10,28} Although the method by Moorees et al²⁹ has separate surveys for males and females, interobserver variation was found and confined to \pm one stage, which may suggest the difficulty in identifying where one stage begins and another one ends when using a rating system with so many intermediate stages.^{4,16} Therefore, it is advised to rate the stages carefully or, when applicable, use other methods, such as the Demirjian method.⁴

The method by Demirjian et al³⁰ is the most highly recommended and developed of all dental age surveys. However, interobserver variation was found and is

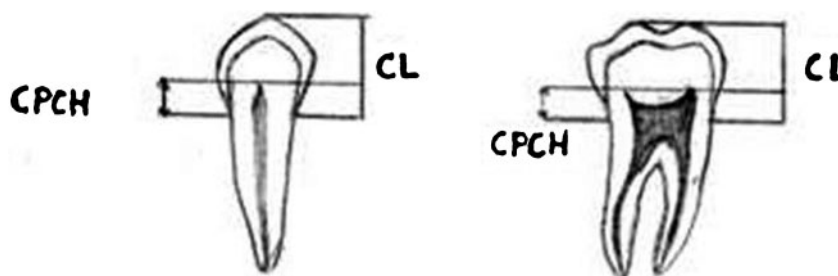


Figure 14 Coronal length (CL) and coronal pulp cavity height or length (CPCH) for premolar and molar teeth

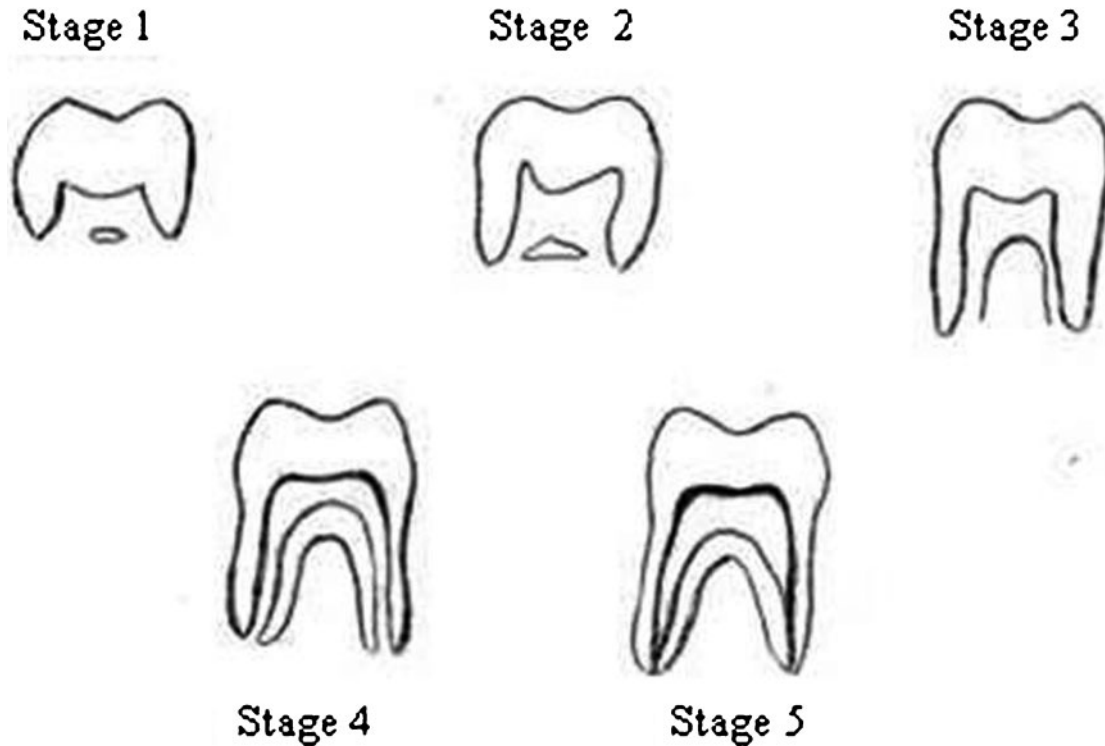


Figure 15 Five stages of lower third molar root development (Harris and Nortjè method)

confined to \pm one of the eight stages. Besides, the ratings in the survey are based on mandibular teeth only; hence the mandibular teeth need to be present for the survey to be applicable. Also, it does not include the third molar in the classification. Subsequently, this system was reviewed by Griffin and Malan³⁸ with emphasis on its possible forensic use, producing the self-explanatory pocket version of the system which can be used in the field. It was concluded that the eight-stage system was less prone to examiner error.³⁸

Later, Solari et al³⁷ used a modified Demirjian method to estimate the chronological age. In order to achieve the higher accuracy in defining the stages of development towards apexification, stages F₁ and G₁ were added, thus making ten stages of crown and root formation as follows:

(F₁) The root length is at least twice the crown length;

(G₁) Root walls are parallel, apices are not entirely closed. The periodontal ligament space at the apical ending is ≥ 1.0 mm.

The advantage of Nolla's method is that it can be applied to an individual with or without the third molar.³¹ Kurita et al¹⁸ evaluated the relationship between chronological age and estimated dental age in

360 healthy Brazilian people by the Nolla³¹ and Nicademmo methods³⁹ using panoramic radiographs. For boys, there was no significant difference in values when both the methods were compared; this was in contradiction to girls where a significant difference in values was found. Overall, the mean dental ages were underestimated in both the methods and a significant difference was found between the estimated dental age and the chronological age.¹⁸

Various methods or surveys have been devised for evaluation of tooth mineralization; the preferred ones are discussed here. Since the validity of age estimation crucially depends on the method used and its proper application, the most appropriate one should be used.^{4,10,24} There are variations in dental development between individuals and between different population groups as not all the individuals of the same chronological age achieve the same level of dental development.^{4,18} As the regional variations in the outcomes shows, the method applied needed to be adapted to local population.^{4,10,24} It must be emphasized that the age estimation in a forensic context may not be the same as that required in the clinical situation because that may be

Table 3 Stages of mesial root development of third molar Van Heerden method

Stages	Description	Length (mm)	Age (y)
Stage 1	Crown complete, radiographic evidence of root formation	3.5–5.3	16.8–16.9
Stage 2	Root length $>1/3 <1/2$	7–8.6	17.5
Stage 3	Root length $>2/3$ but not complete	10–12.9	17.8–17.9
Stage 4	Root fully formed with open apex	12–15.4	18.4–18.5
Stage 5	Apex closed		

questioned by the lawyer or may lead to miscarriage of justice.^{4,8,16} These variations make it important that:⁴

- the appropriate examination radiographs and specimens are obtained from the subject;⁴
- the material obtained and processed is ideally in a similar form to that used in the dental development survey chosen, so that direct and valid comparisons can be made;⁴
- the appropriate dental development surveys are chosen commensurate with one's understanding of these surveys and their suitability to the subject;⁴ and
- legal requirements are understood and complied with.⁴

Age estimation in adults would be challenging as the development of dentition completes by this age and there is no clue which could be reliable to assess the age. The two criteria that can be utilized for age determination in adults are assessment of volume of pulp cavity and of third molar development.

The reduction in the size of the pulp cavity resulting from a deposition of secondary dentine with aging as assessed by radiography can be taken as a guide to estimate the age of the individual.^{5,10,21–23} In 1925, Bodecker⁴⁰ identified the apposition of secondary dentine as being related to chronological age. Secondary dentine begins to form once the tooth crown is fully formed, the tooth is in occlusion and the root is complete. Since regular secondary dentine is laid down at the pulpal end of the primary dentine, the pulp cavity decreases in size with age. As regular secondary dentine is deposited in larger amounts on the floor of the pulp chamber than on the roof, some authors suggested that age has a greater influence than attrition or irritation on secondary dentine formation.²³

Recently, volume matching of teeth imaged by cone beam CT⁴¹ and the X-ray microfocus CT²¹ can be used to obtain pulp vs tooth volume ratio. Conventional X-rays provide two-dimensional information at low resolution while this technique allows the three-dimensional structure of the root canal of the extracted tooth. It works with the same scanning principle as in medical CT; however the spatial resolution is order of magnitude higher.²¹

The coronal pulp cavity index is a reliable biomarker for age assessment in the forensic context, especially in living individuals of unknown personal data.

The accuracy of dental age estimation in adults using evaluation of development of the third molar is questionable owing to great variability in its development. Solari et al³⁷ assessed the precision of third molar development

in Hispanics using the modified Demirjian method with two added stages—F₁ and G₁. The two additional stages may improve the accuracy in root development of third molars when it is used to calculate the probability of an individual being under the age of 18 years. The third molar development was greater in males than in females and the maxillary third molar development was ahead of the mandibular. In spite of these variations, its significance in age determination is justified.³⁷

Olze et al²⁴ assessed the validity of some of the methods by applying them to assess third molar development. The methods used to assess the stages of tooth mineralization were by Glesier and Hunt⁴², Demirjian et al³⁰, Gustafson and Koch⁴³, Harris and Nortje³³ and Kullman et al.⁴⁴ Of the methods tested, the Demirjian method was found to be the most accurate in terms of the evaluation of mineralization of the third molar for the purpose of forensic age determination.²⁴ Gunst et al⁴⁵ also underscored the importance of the third molar, while Mincer et al⁴⁶ did not support the use of the third molar as an age indicator.

Nonetheless, its implementation in forensic age determination is justified as no other reliable age indicator is available to determine the age in adults.³⁷ Besides, it will be a great help to determine whether the adolescents have reached their eighteenth birthday or not as jurisprudence will differ for juvenile detainees.^{5,16,24,37}

In all the methods used for age determination, the evaluation of radiographs for stages of tooth calcification is the most reliable as tooth calcification can be observed from radiographs for a period of several years^{4,8,10,19,37} and it is not altered by local factors such as lack of space or over retention of deciduous teeth. It also allows the assessment of the period when no clinical tooth emergence takes place.^{4,10} Additionally, age estimation would be relatively accurate since the number of teeth passing through various stages of calcification is available.^{4,10}

In conclusion, radiology has become an essential tool in the processes of human age identification. There could not be rigid guidelines regarding the age estimation, hence the degree of dental certainty or probability of the findings may be specified.^{4,16} Use of multiple age estimation methods, multiple teeth and experienced investigators aid towards the optimal age estimation.^{4,10,35}

Very few attempts have been made to find common standardization, calibration and evaluation procedures for methods of age estimation or to develop means of quality assurance for them. Efforts in this direction are necessary to assure the quality standards and adequate answers to the important legal and social issue of age estimation in forensic science.^{4,8,15}

References

1. Saunders E. *'The Teeth A Test of Age' considered with the reference to the factory children, addressed to the members of both Houses of Parliament*. London: Renshaw, 1837.
2. Eckert WG, Garland N. The history of the forensic applications in radiology. *Am J Forensic Med Pathol* 1984; 5: 53–56.
3. Matsikidis G, Schultz P. Alterbestimmung nach dem Gebbis mit Hilfe des Zahnfilms. *Zahnärztl Mitt* 1982; 72: 2524–2528.
4. Ciapparelli L. The chronology of dental development and age assessment. In: Clark DH, (ed). *Practical forensic odontology*. Oxford: Wright Butterworth-Heinemann Ltd, 1992, pp 22–42.

5. Masthan KMK. *Age and sex. Textbook of forensic odontology*. New Delhi: Jaypee Brothers Medical Publishers (P) Ltd, 2009, pp 59–65.
6. Carvalho SPM, Alves da Silva RH, Lopes-Júnior C, Peres AS. Use of images for human identification in forensic dentistry. *Radiol Bras* 2009; **42**: 1–12.
7. Babar MG, Iqbal S, Jan A. Essential guidelines for forensic dentistry. *Pakistan Oral Dent J* 2008; **27**: 79–84.
8. Ardakani F, Bashardoust N, Sheikha M. The accuracy of dental panoramic radiography as an indicator of chronological age in Iranian individuals. *J Forensic Odontostomatol* 2007; **25**: 30–35.
9. Ranganathan K, Rooban T, Lakshminarayan V. Forensic odontology: a review. *J Forensic Odontol* 2008; **1**: 4–12.
10. Achary AB, Sivapathasundharan B. Forensic odontology. In: Rajendran R, Sivapathasundharan B, (eds). *Shafer's textbook of oral pathology* (6th edn). India: Elsevier Private Ltd, 2009, pp 871–892.
11. Singaraju S, Sharda P. Age estimation using pulp-tooth area ratio: A digital image analysis. *J Forensic Dent Sci* 2009; **1**: 37–41.
12. Cameriere R, Ferrante L, Belcastro M, Bonfiglioli B, Rastelli E, Cingolani M. Age estimation by pulp/tooth ratio in canines by periapical X-rays. *J Forensic Sci* 2007; **52**: 166–170.
13. Masthan KMK. *Age estimation by teeth. Textbook of forensic odontology*. New Delhi, Jaypee Brothers Medical Publishers (P) Ltd, 2009, pp 92–97.
14. Whittakar DK, McDonald DG. *Age determination from teeth. A color atlas of forensic dentistry*. England: Wolfe Medical Publications Ltd, 1989, pp 58–66.
15. Cameriere R, Ferrante L, Cingolani M. Precision and reliability of pulp/tooth area ratio (RA) of second molar as indicator of adult age. *J Forensic Sci* 2004; **49**: 1319–1323.
16. Karjodkar FR. *Role of dental radiology in forensic odontology, Text book of dental and maxillofacial radiology*. (2nd edn). New Delhi: Jaypee Brothers Medical Publishers (P) Ltd, 2009, pp 929–963.
17. Cameriere R, Angelis D. Forensic radiology. In: Ghom AG, *Textbook of oral radiology*. India: Elsevier India Private Limited 2008, pp 620–634.
18. Kurita LM, Menezes AV, Casanova MS, Haiter-Neto F. Dental maturity as an indicator of chronological age: Radiographic assessment of dental age in a Brazilian population. *J Appl Oral Sci*; **15**: 95–104.
19. Cameriere R, Ferrante L, Cingolani M. Age estimation in children by measurement of open apices in teeth. *Int J Legal Med* 2006; **120**: 49–52.
20. Rai B, Anand SC. Age estimation in children from dental radiograph: A regression equation. *Int J Biol Anthropol* 2008; **1**: 1–5.
21. Vandevoort FM, Bergamans L, Cleyenbreugel JV, Bielen DJ, Lambrechts P, Wevers M. Age calculation using X-ray micro-focus computed tomographical scanning of teeth: A pilot study. *J Forensic Sci* 2004; **49**: 787–790.
22. Kvaal S, Kolltvit KM, Thompson IO, Solheim T. Age estimation of adults from dental radiographs. *Forensic Sci Inter* 1995; **74**: 175–185.
23. Drusini AG. The coronal pulp cavity index: A forensic tool for age determination in human adults. *Cuad Med Forensic* 2008; **53–54**: 235–249.
24. Olze A, Bilang D, Schmidt S, Wnecke KD, Geserick G, Schmeling A. Validation of common classification systems for assessing the mineralization of third molars. *Int J Legal Med* 2005; **119**: 1–8.
25. Sweet D. Why a dentist for identification. *Forensic odontology. Dent Clin North Am* 2001; **45**: 217–249.
26. Kraus BS, Jordan RE. *The human dentition before birth*. Philadelphia: Lea and Febiger, 1965, p 218.
27. Schour I, Massler M. Development of human dentition. *J Am Dent Assoc* 1941; **20**: 379–427.
28. Ublekar DH. *Human skeletal remains: Excavation, analysis and interpretation* (3rd ed). Taraxacum, Washington DC, 1999.
29. Moorees CFA, Fanning EA, Hunt EE. Age variation of formation stages for ten permanent teeth. *J Dent Res* 1963; **42**: 1490–1502.
30. Demirjian A, Goldstein H, Tanner JM. A new system of dental age assessment. *Hum Biol* 1973; **45**: 211–227.
31. Nolla CM. The development of permanent teeth. *J Dent Child* 1960; **27**: 254–266.
32. Logan W, Kronfield D. Development of the human jaws and surrounding structures from birth to the age fifteen years. *J Am Dent Assoc* 1933; **20**: 379–427.
33. Harris MPJ, Nortje CJ. The mesial root of the third mandibular molar. *J Forensic Odontostomatol* 1984; **2**: 39–43.
34. Van Heerden PJ. *The mesial root of the third mandibular molar as a possible indicator of age*. Dissertation for Diploma in Forensic Odontology, London Hospital Medical College, 1985.
35. Nuzzolese E, Di Vella G. Forensic dental investigations and age assessment of asylum seekers. *Int Dent J* 2008; **58**: 122–126.
36. Garn SM, Lewis AB, Polacheck DL. Variability of tooth formation. *J Dent Res* 1959; **38**: 135–148.
37. Solari AC, Abramovitch K. The accuracy of third molar development as an indicator of chronologic age in Hispanics. *J Forensic Sci* 2002; **47**: 531–535.
38. Griffin JT, Malan D. *Age determination of children from radiographic analysis of eight stages in the mineralization of the lower left permanent dentition, excluding third molar*. Dissertation for diploma in forensic odontology. London Hospital Medical College, 1987.
39. Nicodemo RA, Moraas IC, Medici FE. Tabela cronologica da mineralizacao dos dentes permanentes entre brasileiros. *Rev Fac Odontol* 1974; **3**: 55–56.
40. Bodecker CF. A consideration of some of the changes in the teeth from young to old age. *Dental Cosmos* 1925; **67**: 543–549.
41. Yang F, Jacobs R, Wilhems G. Dental estimation through volume matching of teeth imaged by cone-beam CT. *Forensic Sci Int* 2006; **159** (Suppl 1): S78–83.
42. Glesier I, Hunt EE. The permanent mandibular first molar; its calcification, eruption and decay. *Am J Anthropol* 1955; **13**: 253–283.
43. Gustafson G, Koch G. Age estimation up to 16 years of age based on dental development. *Odont Revy* 1974; **25**: 297–306.
44. Kullman L, Johanson G, Akesson L. Root development of the lower third molar and its relation to chronological age. *Swed Dent J* 1992; **16**: 161–167.
45. Gunst K, Mesotten K, Carbonez A, Willems G. Third molar root development in relation to chronological age: a large sample sized retrospective study. *Forensic Sci Int* 2003; **136**: 52–57.
46. Mincer H, Harris E, Berryman H. The ABFO study of third molar development and its use as estimator of chronological age. *J Forensic Sci* 1993; **38**: 379–390.