

Object naming is a more sensitive measure of speech localization than number counting: Converging evidence from direct cortical stimulation and fMRI

Nicole M. Petrovich Brennan, Stephen Whalen, Daniel de Moraes Branco, James P. O’Shea, Isaiah H. Norton, and Alexandra J. Golby*

Department of Neurological Surgery, Brigham and Women’s Hospital and Harvard Medical School, 75 Francis Street, CA 138-F, Boston, MA 02115, USA

Received 2 January 2007; revised 24 March 2007; accepted 16 April 2007
Available online 13 May 2007

Using direct cortical stimulation to map language function during awake craniotomy is a well-described and useful technique. However, the optimum neuropsychological tasks to use have not been detailed. We used both functional MRI (fMRI) and direct stimulation to compare the sensitivity of two behavioral paradigms, number counting and object naming, in the demonstration of eloquent cortical language areas. Fifteen patients with left hemisphere lesions and seven healthy control subjects participated. Patients had both preoperative fMRI at 3 T and direct cortical stimulation. Patients and controls performed object naming and number counting during fMRI at 3 T. Laterality indices were calculated from the fMRI maps for the Number-counting>Object-naming and Object-naming>Number-counting contrasts. The same number-counting and object-naming paradigms were tested during awake craniotomy and assessed for sensitivity to speech disruption. In all patients during intraoperative cortical stimulation, speech disruption occurred at more sites during object naming than during number counting. Subtle speech errors were only elicited with the object-naming paradigm, whereas only speech arrest and/or hypophonia were measured using the number counting paradigm. In both patients and controls, fMRI activation maps demonstrated greater left lateralization for object naming as compared to number counting in both frontal and temporal language areas. Number counting resulted in a more bihemispheric distribution of activations than object naming. Both cortical stimulation testing and fMRI suggest that automated speech tasks such as number counting may not fully engage putative language networks and therefore are not optimal for language localization for surgical planning.

© 2007 Published by Elsevier Inc.

Introduction

Awake craniotomy for the purpose of language mapping is a well-described and useful technique (Haglund et al., 1994; Berger and Rostomily, 1997; Berger et al., 1989; Meyer et al., 2001; Ojemann et al., 1989). Typically, as the surgeon performs direct bipolar electrical cortical stimulation with simultaneous electrocorticography, a neuropsychologist monitors the patient’s performance on a language task. Disruption of the task during cortical stimulation is taken to indicate that the underlying cortex is essential for the performance of that task. Surgical resection of the lesion is then performed respecting a margin, generally 1 cm, of the positive response sites.

Unfortunately, even when these margins are respected, patients may exhibit postoperative language deficits including difficulty with comprehension, speech production, naming, repetition, reading or writing. One possible reason such deficits occur may be because a variety of language tasks are not individually tested during cortical mapping. As a result, it is possible that the testing that is performed is not sensitive enough to detect the cortical localization of all possible language function in an area.

Hamberger et al. (2005), for example, demonstrated that the use of different language tasks during direct cortical stimulation can affect clinical language outcome. They found that patients who had resections that included sites at which auditory responsive naming was disrupted showed more postoperative aphasia than patients who did not have auditory responsive naming sites removed. This aphasia occurred despite the fact that those patients had their visual naming sites spared. Ideally then, patients would be mapped using several language tasks. However, intraoperative constraints of time, patient cooperation, sedation, and positioning preclude comprehensive language testing. Therefore, it is important to systematically examine the sensitivity of various language tasks so that we can maximize the efficiency of intraoperative language testing and better avoid postoperative deficits.

* Corresponding author. Fax: +1 617 713 3050.

E-mail address: agolby@bwh.harvard.edu (A.J. Golby).

Available online on ScienceDirect (www.sciencedirect.com).

There are many considerations when choosing a language task for use during awake craniotomy. Most importantly, one must choose a behavioral task that is dependent on the area being interrogated. Without neuropsychological consideration of the anatomical area being tested, there is a risk of false negative determination of language localization due to the sub-optimal choice of a language task. Thus, linguistic tasks should ideally be tailored to the lesion location in order to have the greatest sensitivity to the most probable deficits in a given patient. In addition, careful assessment of the patient's preoperative language function, by disclosing subtle impairments, can guide the choice of appropriate tasks. For example, a patient with a lesion in the temporo-parietal cortex might show signs of subtle reading deficits, prompting the neuropsychologist to test reading intraoperatively, whereas a lesion in inferior frontal cortex may call for verb generation or some other productive speech task.

Confrontation naming (object naming) and number counting are two tasks commonly used during intraoperative mapping (Ruge et al., 1999; Walker et al., 2004; Ojemann, 1993; Pouratian et al., 2003), and there is an extensive literature discussing the large-scale distribution of object naming within the putative language areas in the dominant hemisphere (Price et al., 2005; Deleon et al., 2007, Hirsch et al., 2001). However, it has been debated whether non-propositional speech is represented in a similar but separate neural network (Blank et al., 2002; Vanlancker-Sidtis et al., 2003). Bookheimer et al. (2000) suggested that some but not all automatic speech tasks engage dominant speech areas. Whereas, Blank et al. (2002), in a positron emission tomography (PET) study, suggested

that both propositional and non-propositional speech similarly activated posterior temporal areas, pars opercularis and the anterior insula.

We tested the hypothesis that confrontation naming, a well-established linguistic task, would be a more sensitive measure of language localization during electrocortical stimulation testing than number counting, an overlearned category of speech (Vanlancker-Sidtis et al., 2003). We also used fMRI to further characterize differences in the brain bases of the performance of these tasks in both patients and healthy control subjects. We hypothesized that object naming would lateralize more completely to the dominant hemisphere than number counting during fMRI, and that these differences would be reflected in the sensitivity of language localization during awake craniotomy with electrocortical stimulation testing.

Materials and methods

Patients

Fifteen patients with lesions in the left hemisphere participated (Table 1). Fourteen patients had primary brain tumors and one had a cavernous malformation. Fourteen patients underwent pre-surgical fMRI. Six patients underwent intraoperative cortical mapping under local anesthesia. Five of these patients had left temporal lobe lesions and one had a left frontal lesion. The nine remaining patients either did not have surgery (three), did not require awake cortical mapping clinically (five) or had a seizure

Table 1
Fifteen patients participated

| Patient | Age | Gender | Handedness | Lesion location | Pathology | Functional MRI paradigms | BDAE scores pre-op |
|---------|-----|--------|--------------|-----------------|------------------------------------|-----------------------------------|--------------------|
| 1 | 41 | M | R | Left frontal | Cavernous malformation | Object naming and number counting | 58/60 |
| 2 | 27 | M | L | Left temporal | Glioma | Object naming and number counting | 47/60 |
| 3 | 33 | F | R | Left frontal | Mixed glioma | Object naming and number counting | No |
| 4 | 33 | M | R | Left frontal | None available (no surgery) | Object naming and number counting | 55/60 |
| 5 | 38 | F | R | Left frontal | Mixed glioma | Object naming and number counting | 53/60 |
| 6 | 45 | M | R | Left frontal | Glioblastoma multiforme | Object naming and number counting | 48/60 |
| 7 | 40 | M | Ambidextrous | Left temporal | Glioblastoma multiforme | Object naming and number counting | 37/60 |
| 8 | 54 | M | L | Left temporal | Glioblastoma multiforme | Object naming and number counting | 52/60 |
| 9 | 51 | F | R | Left frontal | Anaplastic astrocytoma | Object naming and number counting | 57/60 |
| 10 | 48 | F | R | Left frontal | Oligodendroglioma | Object naming and number counting | N/A |
| 11 | 45 | F | R | Left temporal | Oligodendroglioma | Object naming and number counting | N/A |
| 12 | 61 | M | R | Left temporal | Glioblastoma multiforme | Object naming | 29/60 |
| 13 | 57 | M | R | Left temporal | Glioma | Object naming | 35/60 |
| 14 | 32 | M | R | Left temporal | Anaplastic mixed oligodendroglioma | Object naming | 57/60 |
| 15 | 52 | F | R | Left temporal | Glioblastoma multiforme | N/A | N/A |

Six patients underwent intraoperative electrocortical stimulation (grayed) and five of those six had pre-operative fMRI as well. All lesions were in the left hemisphere. BDAE=Boston Diagnostic Aphasia Examination.

before mapping began that precluded intraoperative testing (one). Twelve patients were right handed; two were left handed; and one was ambidextrous (Oldfield, 1971). Nine patients were male and 6 were female. Mean age was 43.8 years (SD 10.1 years). Eleven patients were tested with the Boston Diagnostic Aphasia Examination (BDAE) (Goodglass and Kaplan, 1972). All patients spoke English as a first language.

Healthy control subjects

Seven healthy control subjects participated. Two were males and five were females. All subjects were right handed and spoke English as a first language. Mean age was 29.1 years (SD 9.6 years).

All subjects were recruited and tested in compliance with the Partners Healthcare Institutional Review Board standards.

Intraoperative direct cortical stimulation (language mapping)

Intraoperative mapping was performed as previously described (Berger and Ojemann, 1992; Ojemann, 1993). Before the start of the case, patients were fitted with the same goggle-based stimulus display system that was used during the pre-surgical fMRI for stimulus presentation (Resonance Technology Inc., Northridge, CA). Patients' naming function was tested preoperatively using the BDAE picture pool and the Snodgrass and Vanderwart (1980) collection. Only objects that patients could reliably name preoperatively were selected for intraoperative testing so as not to misattribute baseline errors to stimulation testing. The same standardized black and white objects (BDAE and Snodgrass and Vanderwart) used during pre-surgical fMRI testing were presented on the goggle-based stimulus display running off of a PC laptop (Dell Computer Corporation, Round Rock, TX) running EPRIME (Psychology Software Tools, Pittsburgh, PA). Stimuli were self-paced, and presentation was coupled with cortical stimulation. Cortical sites were stimulated using the Ojemann bipolar stimulator from 2 to 10 mA, 75 Hz, square wave, 0.2-ms pulse duration (Radionics Inc., Burlington, MA). Stimulation testing was performed using both number-counting and object-naming paradigms. Paraphasic errors, speech arrest, hesitation, word finding difficulty, dysarthria, circumlocution, hypophonia, or no effect was noted for each stimulation current at each site. Electrocoitography was performed during stimulation to confirm stimulation and to monitor for after discharges or induced images. All points were tested using both tasks when an effect was noted for either object naming or number counting. At sites where speech disturbance was achieved during object naming, but not number counting, current threshold was escalated to 10 mA if no after discharges were seen, to ensure that the negative result was not threshold dependent. An effect was only recorded if it was repeatable on three separate occasions. Behavioral changes in the presence of after discharges were recorded but not counted as positive stimulation points.

fMRI

Functional MRI was performed using a GE 3-T Signa scanner and a standard quadrature birdcage headcoil at Brigham and Women's Hospital. Stimuli were presented using the same PC laptop used during intraoperative testing, and the same MR compatible goggle system. Whole-brain functional sequences were

acquired with a T2*-weighted echo-planar sequence sensitive to the blood oxygen-level-dependent signal (Ogawa et al., 1990). Patients and controls performed one of three fMRI paradigms detailed in Fig. 1. The first consisted of three conditions: object naming, non-semantic nonsense objects (for perceptual control) and fixation. The second paradigm (designed after preliminary intraoperative results suggested differences between number counting and object naming) contained five conditions: silent object naming, vocalized object naming, silent number counting, vocalized number counting and a baseline of nonsense objects for perceptual control (images at <http://www.cog.brown.edu/~tarr/stimuli.html>). The third was identical to the second paradigm except that all conditions were performed silently. Object-naming stimuli consisted of a different mixture of the Snodgrass and Vanderwart collection (Snodgrass and Vanderwart, 1980) and the BDAE (Goodglass and Kaplan, 1972) objects than those used during intraoperative testing.

The first fMRI paradigm (Fig. 1), the object-naming-only paradigm, had the following parameters: 192 images, TR 2000, TE30, matrix 64 × 64, FOV 24, axial slices, 5 mm, no skip. There were eighteen epochs (6 for each condition), each lasting 20 s, presented in a pseudo-random order. The second fMRI paradigm, the mixed number-counting and object-naming paradigm, contained 270 images of 40 pseudo-randomly alternating epochs of the five conditions described above. Each stimulation epoch lasted 12 s, and each baseline epoch was jittered (Price et al., 1999). All other MR acquisition parameters were the same as the first fMRI object-naming paradigm. For the purpose of the present report, only the non-vocalized tasks were used in the analyses. Anatomical T2-weighted and high-resolution T1-weighted gradient echo 3D images were then acquired for coregistration. The third fMRI paradigm had the identical acquisition parameters as the second fMRI paradigm.

All patients and subjects were pre-tested on a practice version (containing different stimulus exemplars) of the task before the scanning session to assure that they understood and could perform the task. Aphasic patients with naming difficulty (patients 7, 12 and 13) were presented only with pictures that represented the most high-frequency words.

fMRI data analysis

Images were motion corrected, smoothed with an 8-mm Gaussian kernel and normalized using the standard routines from SPM2 (Wellcome Department of Cognitive Neurology, London, UK). Data were analyzed using the general linear model. Analysis was first performed individually for each subject. A standard box-car response function with a time derivative was used as the hemodynamic basis function and only stimulus conditions were explicitly modeled. Language laterality indices (LIs) were calculated on random effects group subtraction analyses (Number counting > Object naming and Object naming > Number counting) within predefined regions of interest (ROIs) in the putative language areas in the frontal and temporal lobes (Broca's and Wernicke's areas), based on the electronic Pick Atlas (Department of Radiologic Sciences, Wake Forest University, Winston-Salem). The following anatomical areas were chosen for the ROI analysis for frontal language areas; inferior frontal and middle frontal gyri (hence forward termed Broca's area for simplicity). Posterior language areas included the classically defined superior temporal gyri as well as supramarginal and angular gyri (hence forward termed Wernicke's area). The contrasts Objects > Numbers and

Numbers>Objects were tested for the patient group and the control group separately. The LI was calculated using the formula $L-R/L+R$ for voxels meeting statistical significance $p<0.01$. This yielded the relative asymmetry of fMRI activation in both the number-counting and object-naming conditions. We defined an LI from +0.2 to +1.0 as left hemispheric dominance, an LI of -0.2 to -1.0 as right hemispheric dominance, and an LI of -0.2 to 0.2 as demonstrating bilateral activation based on previous studies (Gaillard et al., 2002; Springer et al., 1999). In order to eliminate thresholding as a possible source of differences in laterality, LIs for both object-naming and number-counting data were calculated at a range of p values ($p<0.09$, $p<0.05$, $p<0.01$ and $p<0.001$). No cases showed LIs that changed sides in a threshold dependent manner, but in some cases the most stringent p value eliminated all fMRI activity and therefore comparisons were not made in 5 patients and 3 controls. The following technical parameters were considered guidelines for exclusion from the study; head motion totaling more than 4 mm, obvious ‘edge effect’ after motion correction, or linear trend within the voxel profiles within the putative language areas. No subjects were excluded. No cluster thresholding or erosion processes were used.

Fusion of positive intraoperative stimulation points and pre-surgical fMRI

Positive electrocortical stimulation site locations were digitized and recorded intraoperatively using GE InstaTrak 3500 Plus guidance

system (Lawrence, MA). Electrocortical site location data and T2 surgical reference images were then transferred postoperatively to 3D Slicer (<http://www.slicer.org>). To bring the fMRI activations into the same frame of reference, the realigned mean fMRI image for each task was coregistered to the T2-weighted anatomical image using the Mutual Information Coregistration routine in SPM. The resulting transform was concurrently applied to the fMRI activation map for each task. Anatomical images and realigned activation images were then added to the 3D Slicer dataset. Measurements were then made in 3D Slicer from each positive stimulation site to the fMRI local maxima in the putative language areas.

Results

Intraoperative direct cortical stimulation

In all cases, object naming was interrupted more often during electrocortical stimulation than number counting (Table 2). In two patients, no speech disturbance at all was found during number counting. This was true even at sites at which electrical stimulation interrupted object naming and current was escalated. In the four cases where both object naming and number counting were interrupted, all of the areas that interrupted number counting also interrupted object naming. The converse was not true; those areas that resulted in the disruption of object naming did not all interrupt number counting (despite current escalation). The areas that did overlap in their interruption of both object naming and number

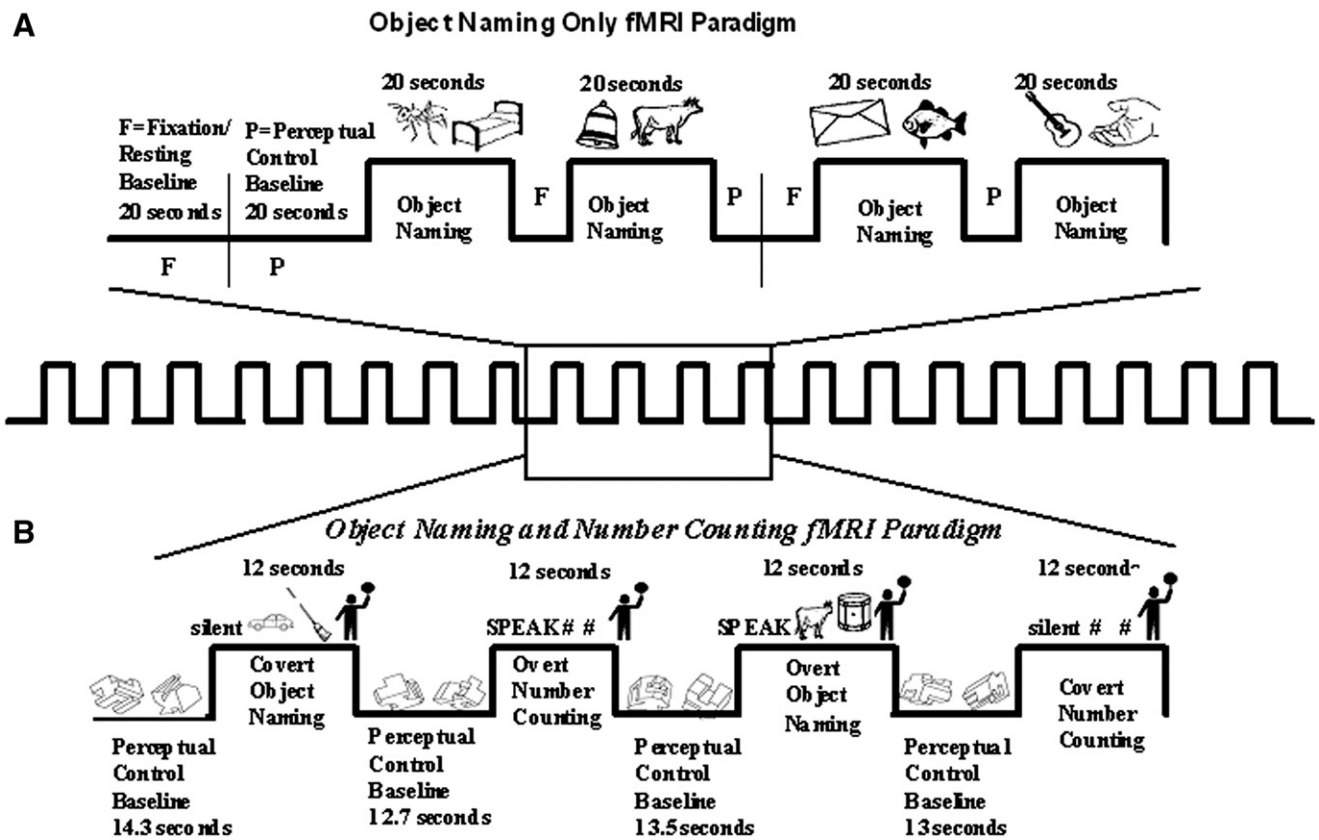


Fig. 1. Patients and subjects performed one of two fMRI paradigms. (A) 192 images of alternating covert object naming, and two baselines (one fixation and one nonsense images for perceptual control). (B) 270 Images of jittered alternating silent and vocalized object naming, silent and vocalized number counting and a baseline of nonsense images. (C) The same as panel B but performed exclusively silently.

Table 2
Behavioral results during cortical stimulation are listed

| Patient | 12 | 14 | 1 | 2 | 11 | 15 |
|--|----------------------------------|-----------------------|--|--|---|--|
| Location | Left temporal | Left temporal | Left frontal | Left temporal | Left temporal | Left temporal |
| Total number of sites stimulated | 7 | 7 | 9 | 6 | 5 | 7 |
| Number of sites interrupted during object naming | 4 | 2 | 4 | 2 | 4 | 4 |
| Number of sites interrupted during number counting | 1 | 0 | 1 | 0 | 3 | 2 |
| Number of sites interrupted during both tasks | 1 | 0 | 1 | 0 | 3 | 2 |
| Type of disruption | | | | | | |
| Object naming | Word finding (1,2,4) 4mA and 6mA | Word finding (2) 8mA | Hesitation (6,9,2) 8mA, 6mA and 6mA respectively | Word finding (19) 4mA | Phonemic paraphasia (1) 6mA | Dysarthria perseveration (1) 6mA for both |
| | Speech arrest (3) 2mA | Perseveration (2) 8mA | Phonemic paraphasia (3) 6mA | Phonemic paraphasia, circumlocuting (21) 2mA | Speech arrest (2) word finding (2) 4mA and 2mA respectively | Paraphasia and word finding (2) 6mA and 4mA respectively |
| | Phonemic paraphasia (4) 6mA | Hesitation (3) 8mA | Speech arrest (6) 4mA | | Hesitancy (3) 2mA | Speech arrest (4,6) 2 and 4 mA for both |
| Number counting | | | | | Phonemic paraphasia 6mA and hesitancy 2mA (5) | Paraphasia (7) 10mA |
| | Speech arrest (3) 2mA | | Speech arrest (6) 4mA | | Hypophonia (1) 10mA | Speech arrest (4) 4mA |
| | | | | | Speech arrest (2) 2mA | Speech arrest (6) 4mA |
| | | | | | Hypophonia (5) 8mA | |

In all cases object naming was interrupted more often than number counting. The overlap between sites that interrupted both object naming and number counting occurred only in the form of speech arrest and hypophonia. In two cases, stimulation did not cause any disruption of number counting but did interrupt object naming. () Indicates stimulation point number.

counting did so only in the form of speech arrest and hypophonia. In no case was a more subtle speech disturbance like paraphasia, word finding difficulty or perseveration elicited during number counting. In one case (patient 2), after discharges were seen at 10 mA. In the remaining 5 patients, current was not escalated past 10 mA and after discharges were not seen.

fMRI

Patients

In the patient group analysis, the Object-naming>Number-counting contrast revealed consistent greater left-lateralization in Wernicke's area (LI 0.46) as compared to Number counting>Object naming (LI -0.23). While Broca's area was considered bilateral during the Object-naming>Number-counting contrast (LI 0.08), it was negative (rightward) by similar magnitude during the

Number-counting>Object-naming contrast (LI -0.07). Fig. 2 shows the results of both contrasts. The fMRI maps shown are the group results of region-of-interest maps used to calculate the LIs.

Control subjects

The control group analysis showed a similar result. Wernicke's area was strongly left-lateralized (LI 0.76) during the Object-naming>Number-counting contrasts, whereas Wernicke's area was less left-lateralized during the Number-counting>Object-naming contrast (LI 0.35). This effect was more pronounced in Broca's area. During the Object-naming>Number-counting contrast the Broca's area LI was 0.35. However, during the Number-counting>Object-naming contrast, the LI in Broca's area was -0.23. Fig. 2 shows the results of both control group contrast with regions-of-interest shown.

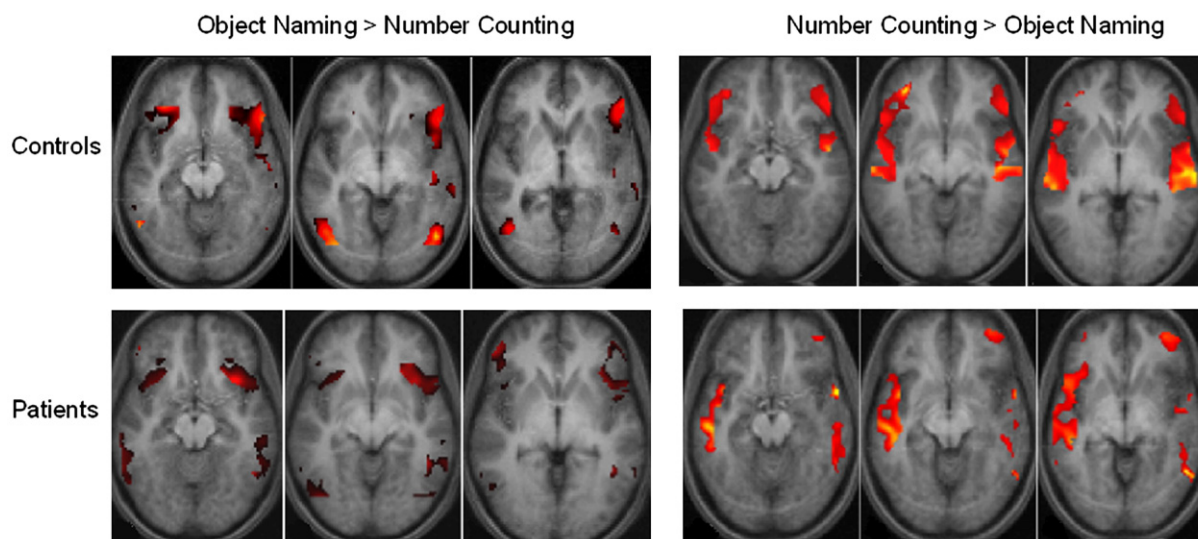


Fig. 2. fMRI results for patients and healthy control subjects. fMRI activity lateralizes more completely to the left-hemisphere in the Object-naming>Number-counting contrast than the Number-counting>Object-naming contrast in both Broca's and Wernicke's areas. Analyses are random effects group analyses at $p < 0.01$.

Comparison of positive intraoperative stimulation points and pre-surgical fMRI

The average distance between the anatomically defined Broca's area and the four positive stimulation points in patient 1 was 29 mm (SD 6 mm) during number counting and 25 mm (SD 7 mm) during object naming (Fig. 3). In patient 2, the average distance to the anatomically defined Wernicke's area was 51 mm (SD 13 mm) during number counting and 47 mm (SD 7 mm) during object naming.

Neuropsychological testing

Of the five patients that had neuropsychological testing both pre- and post-surgically, none showed a significant change in their confrontation naming performance. One patient experienced a mild transient form of pure alexia without agraphia postoperatively, which resolved within a week. Expressive and receptive language function in this patient remained in the same range as the pre-surgical assessment.

Discussion

The present results demonstrate that during intraoperative electrocortical language mapping in the dominant hemisphere, object naming yields more sites of speech interruption than number counting in all cases. Subtle speech errors were only elicited with the object naming paradigm, whereas only speech arrest and/or hypophonia were measured using the number counting paradigm. Further, in both patients and control subjects, fMRI activity was more left-lateralized during object naming as compared to number counting in both ROIs. Together, these findings imply that more complex language tasks like object naming rely on established dominant hemisphere networks and may be a more sensitive measure of language localization during direct cortical stimulation than language paradigms that test over-learned speech, such as counting.

Number counting is commonly used during awake craniotomies (Ruge et al., 1999; Duffau et al., 2003; Bello et al., 2006). As an overlearned speech pattern, sequential number counting is particularly convenient for language mapping as it can be preserved in aphasic patients. This affords the surgeon continuous speech output for electrocortical language mapping that might not have been possible otherwise in a profoundly dysphasic patient (Cappelletti et al., 2001; Trojano et al., 1988). In patients where more complex tasks are not feasible, or when used as a first step in more detailed language mapping this approach is reasonable. However, the results of this study imply that number counting is not as sensitive to the type of subtle disruption that may also indicate the location of essential language cortex. In our intraoperative mapping we never observed a linguistic error more subtle than arrest or hypophonia during number counting; only when object naming was used did we observe paraphasias, circumlocution, perseveration and word finding difficulty. This suggests that using number counting alone might lend itself to false negative determinations of language localization.

It is not surprising that object naming was interrupted more often than number counting during intraoperative mapping given the semantic, grammatical, and syntactic complexity of propositional (non-automated) speech. These complexities are reflected by the findings that propositional speech commonly activates a wide network of structures mostly in the dominant hemisphere (Naeser et al., 2004; Roux et al., 2003; Blank et al., 2002). By contrast, number counting (considered non-propositional) is largely devoid of many of these linguistic characteristics. These complexities may be problematic to the surgeon during electrocortical stimulation of the dominant temporal lobe, where often one must rely on subtle linguistic errors to map the receptive language areas. Using a task devoid of such complexities during electrocorticography may make it difficult to map the temporal lobe accurately. The fact that our fMRI and intraoperative results also suggest a differential representation for number counting as compared to object naming in the one

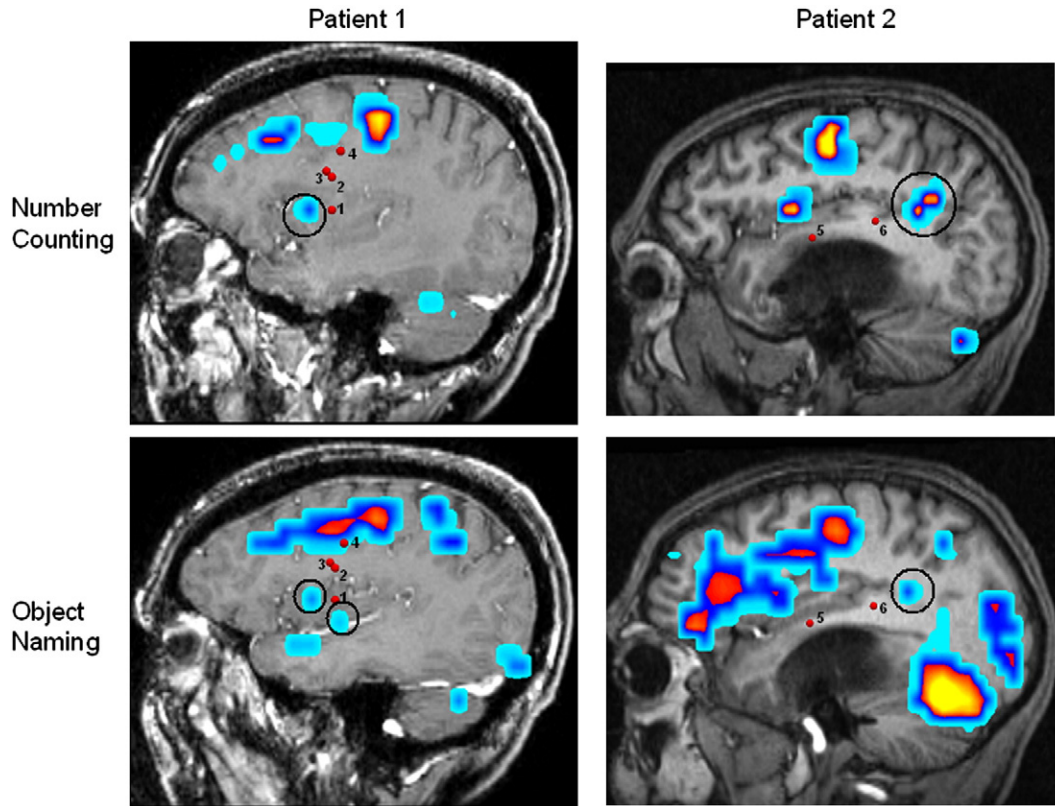


Fig. 3. Comparison of the locations of positive intraoperative stimulation points and pre-surgical fMRI maps for two patients. Stimulation points are represented in three-dimensional space. Distances were measured between the circled fMRI activations (the putative language areas) and the stimulation points labeled 1–6 for the two patients. The average distance between the anatomically defined Broca's area and the four positive stimulation points in patient 1 was 29 mm (SD 6 mm) during number counting and 25 mm (SD 7 mm) during object naming. In patient 2 the average distance to the anatomically defined Wernicke's area was 51 mm (SD 13 mm) during number counting and 47 mm (SD 7 mm) during object naming.

case where testing was focused on Broca's area implies a similar linguistic complexity in frontal speech areas, which is in keeping with current opinion (Grewe et al., 2005; Newman et al., 2003; Fiebach et al., 2005).

Several functional imaging studies have suggested that automatic speech tasks do not engage the language system to the extent that more complex language tasks do. Vanlancker-Sidtis et al. (2003) compared number counting and semantic fluency in a positron emission tomography (PET) study. They showed that counting activated a significantly more bilateral cortical and subcortical brain network. In another PET study investigating the adequacy of activating language cortex with automated speech tasks, Bookheimer et al. (2000) compared repeating a phoneme sequence, repeating the months of the year, and reciting the Pledge of Allegiance. Only the Pledge of Allegiance showed left-lateralized inferior frontal activity. This, the authors posited, may have been due to the fact that the Pledge of Allegiance was the only one of the tasks that had sufficient syntactic and semantic complexity to activate the posterior language areas. However, this automated task (the Pledge of Allegiance) also activated both left and right superior temporal gyri. This implies, as do our data from both intraoperative mapping and fMRI, that automated speech tasks may be less likely to activate essential temporal language areas, may be more bilaterally distributed categorically, and may be less amenable to

disruption with direct cortical stimulation, especially in the temporal lobe.

This study was not intended to assess outcome differences due to mapping technique or anatomical specificity of language task. It is possible that the greater sensitivity of object naming may decrease the likelihood of postoperative deficits. It may not, however, reduce the likelihood of deficits on other language tasks not specifically tested. For example, one of our patients had transient alexia postoperatively despite intact expressive and auditory receptive language. It may be advantageous to test several language functions intraoperatively. However, this must be balanced by the constraints of time, patient cooperation, and clinical benefit.

Only two of our patients' fMRI and intraoperative mapping data were amenable to quantitative comparison (Fig. 3). While our study was not designed to address anatomical topography in linguistic subcomponents, a comparison between two available datasets suggests that object naming elicited a more complex response in the frontal language areas in comparison to number counting. During object naming in patient 1, both the pars opercularis as well as the most inferior portion of the motor strip were activated. During number counting only the pars opercularis was activated. Additionally, intraoperative mapping showed interruption of speech in areas not activated by fMRI, suggesting a wide range in the distribution of secondary language areas.

This is particularly interesting in light of the fact that the patients performed exactly the same tasks in the operating room and the scanner. More data would be needed to characterize the more complex fMRI response to object naming, if any exists, as well as the disparity between the intraoperative mapping results and fMRI results. Practically, the use of confrontation naming or other neuropsychological language tasks is easily implemented in most operating rooms. When using a task-like picture naming, we pre-test patients and select stimuli that the patient can name reliably so as not to misattribute a linguistic error to electrocortical stimulation when the patient could not correctly name the object preoperatively. Additionally, the computerized delivery of stimuli using LCD goggles in both the fMRI and intraoperative settings enable precise replication of the fMRI testing environment, and serve to put the patient at ease during intraoperative mapping with distractor stimuli while not actively mapping.

The finding that automatic speech lateralized less well during fMRI measurements is only one measurement in a likely complex brain basis for non-propositional speech. It does however begin to characterize the mechanism for the preservation of automatic speech in aphasic patients. Additionally, the inclusion of confrontation naming for language mapping may reveal a more sensitive representation of language localization and may decrease the incidence of postoperative aphasia.

Acknowledgments

This research was supported by grants to A.J.G. from The National Institutes of Health (KO8 NS048063 and U41 RR019703) and The Brain Science Foundation.

References

- Bello, L., Acerbi, F., Giussani, C., Baratta, P., Taccone, P., Songa, V., et al., 2006. Intraoperative language localization in multilingual patients with gliomas. *Neurosurgery* 59 (1), 115–125.
- Berger, M.S., Ojemann, G.A., 1992. Intraoperative brain mapping techniques in neuro-oncology. *Stereotact. Funct. Neurosurg.* 58 (1–4), 153–161.
- Berger, M.S., Rostomily, R.C., 1997. Low grade gliomas: functional mapping resection strategies, extent of resection, and outcome. *J. Neurooncol.* 34 (1), 85–101.
- Berger, M.S., Kincaid, J., Ojemann, G.A., Lettich, E., 1989. Brain mapping techniques to maximize resection, safety, and seizure control in children with brain tumors. *Neurosurgery* 25 (5), 786–792.
- Blank, S.C., Scott, S.K., Murphy, K., Warburton, E., Wise, R.J., 2002. Speech production: Wernicke, Broca and beyond. *Brain* 125 (Pt 8), 1829–1838.
- Bookheimer, S.Y., Zeffiro, T.A., Blaxton, T.A., Gaillard, P.W., Theodore, W.H., 2000. Activation of language cortex with automatic speech tasks. *Neurology* 55 (8), 1151–1157 (Oct 24).
- Cappelletti, M., Butterworth, B., Kopelman, M., 2001. Spared numerical abilities in a case of semantic dementia. *Neuropsychologia* 39 (11), 1224–1239.
- Deleon, J., Gottesman, R.F., Kleinman, J.T., Newhart, M., Davis, C., Heidler-Gary, J., et al., 2007. Neural regions essential for distinct cognitive processes underlying picture naming. *Brain* [electronic publication ahead of print].
- Duffau, H., Capelle, L., Denvil, D., Gatignol, P., Sichez, N., Lopes, M., et al., 2003. The role of dominant premotor cortex in language: a study using intraoperative functional mapping in awake patients. *NeuroImage* 20 (4), 1903–1914.
- Fiebach, C.J., Schlesewsky, M., Lohmann, G., von Cramon, D.Y., Friederici, A.D., 2005. Revisiting the role of Broca's area in sentence processing: syntactic integration versus syntactic working memory. *Hum. Brain Mapp.* 24 (2), 79–91.
- Gaillard, W.D., Balsamo, L., Xu, B., Grandin, C.B., Braniecki, S.H., Papero, P.H., et al., 2002. Language dominance in partial epilepsy patients identified with an fMRI reading task. *Neurology* 59, 256–265.
- Goodglass, H., Kaplan, E., 1972. *The Assessment of Aphasia and Related Disorders*. Lea and Febiger, Philadelphia.
- Grewe, T., Bornkessel, I., Zysset, S., Wiese, R., von Cramon, D.Y., Schlesewsky, M., 2005. The emergence of the unmarked: a new perspective on the language-specific function of Broca's area. *Hum. Brain Mapp.* 26 (3), 178–190.
- Haglund, M.M., Berger, M.S., Shamseldin, M., Lettich, E., Ojemann, G.A., 1994. Cortical localization of temporal lobe language sites in patients with gliomas. *Neurosurgery* 34 (4), 567–576.
- Hamberger, J.M., Seidel, W.T., Mckhann, G.M., Perrine, K., Goodman, R.R., 2005. Brain stimulation reveals critical auditory naming cortex. *Brain* 128 (Pt 11), 2742–2749.
- Hirsch, J., Moreno, D.R., Kim, K.H., 2001. Interconnected large-scale systems for three fundamental cognitive tasks revealed by functional MRI. *J. Cogn. Neurosci.* 1 (13(3)), 389–405.
- Meyer, F.B., Bates, L.M., Goerss, S.J., Friedman, J.A., Windschitl, W.L., Duffy, J.R., et al., 2001. Awake craniotomy for aggressive resection of primary gliomas located in eloquent brain. *Mayo Clin. Proc.* 76 (7), 677–687.
- Naeser, M.A., Martin, P.I., Baker, E.H., Hodge, S.M., Sczerzenie, S.E., Nicholas, M., et al., 2004. Overt propositional speech in chronic nonfluent aphasia studied with the dynamic susceptibility contrast fMRI method. *NeuroImage* 22 (1), 29–41.
- Newman, S.D., Just, M.A., Keller, T.A., Roth, J., Carpenter, P.A., 2003. Differential effects of syntactic and semantic processing on the subregions of Broca's area. *Cogn. Brain Res.* 16 (2), 297–307.
- Ogawa, S., Lee, T.M., Kay, A.R., Tank, D.W., 1990. Brain magnetic resonance imaging with contrast dependent on blood oxygenation. *Proc. Natl. Acad. Sci. U. S. A.* 87 (24), 9868–9872.
- Ojemann, G.A., 1993. Functional mapping of cortical language areas in adults. Intraoperative approaches. *Adv. Neurol.* 63, 155–163.
- Ojemann, G., Ojemann, J., Lettich, E., Berger, M., 1989. Cortical language localization in left, dominant hemisphere. An electrical stimulation mapping investigation in 117 patients. *J. Neurosurg.* 71 (3), 316–326.
- Oldfield, R.C., 1971. The assessment and analysis of handedness: the Edinburgh inventory. *Neuropsychologia* 9 (1), 97–113.
- Pouratian, N., Bookheimer, S.Y., Rubino, G., Martin, N.A., Toga, A.W., 2003. Category-specific naming deficit identified by intraoperative stimulation mapping and postoperative neuropsychological testing. Case report. *J. Neurosurg.* 99 (1), 170–176.
- Price, C.J., Veltman, D.J., Ashburner, J., Josephs, O., Friston, K.J., 1999. The critical relationship between the timing of stimulus presentation and data acquisition in blocked designs with fMRI. *NeuroImage* 10 (1), 36–44.
- Price, C.J., Devlin, J.T., Moore, C.J., Morton, C., Laird, A.R., 2005. Meta-analyses of object naming: effect of baseline. *Hum. Brain Mapp.* 25, 70–82.
- Roux, F.E., Boulanouar, K., Lotterie, J.A., Mejdoubi, M., LeSage, J.P., Berry, I., 2003. Language functional magnetic resonance imaging in preoperative assessment of language areas: correlation with direct cortical stimulation. *Neurosurgery* 52 (6), 1335–1345.
- Ruge, M.I., Victor, J., Hosain, S., Correa, D.D., Relkin, N.R., Tabar, V., et al., 1999. Concordance between functional magnetic resonance imaging and intraoperative language mapping. *Stereotact. Funct. Neurosurg.* 72 (2–4), 95–102.
- Snodgrass, J.G., Vanderwart, M., 1980. A standardized set of 260 pictures: norms for name agreement, image agreement, familiarity, and visual complexity. *J. Exp. Psychol. Hum. Learn.* 6 (2), 174–215.

- Springer, J., Binder, J., Hammeke, T.A., Swanson, S.J., Frost, J.A., Bellgowan, P.S., et al., 1999. Language dominance in neurologically normal and epilepsy subjects: a functional MRI study. *Brain* 122, 2033–2045.
- Trojano, L., Fragass, N., Postiglione, A., Gross, D., 1988. Mixed transcortical aphasia. On relative sparing of phonological short-term store in a case. *Neuropsychologia* 26, 633–638.
- Vanlancker-Sidtis, D., McIntosh, A.R., Grafton, S., 2003. PET activation studies comparing two speech tasks widely used in surgical mapping. *Brain Lang.* 85 (2), 245–261.
- Walker, J.A., Quinones-Hinojosa, A., Berger, M.S., 2004. Intraoperative speech mapping in 17 bilingual patients undergoing resection of a mass lesion. *Neurosurgery* 54 (1), 113–117.