

3D-RADNet: Extracting labels from DICOM metadata for training general medical domain deep 3D convolution neural networks

Richard Du¹

DU94@HKU.HK

Varut Vardhanabhuti¹

VARV@HKU.HK

¹ *Department of Diagnostic Radiology, Li Ka Shing Faculty of Medicine, The University of Hong Kong, Hong Kong SAR*

Abstract

Training deep convolution neural network requires a large amount of data to obtain good performance and generalisable results. Transfer learning approaches from datasets such as ImageNet had become important in increasing accuracy and lowering training samples required. However, as of now, there has not been a popular dataset for training 3D volumetric medical images. This is mainly due to the time and expert knowledge required to accurately annotate medical images. In this study, we present a method in extracting labels from DICOM metadata that information on the appearance of the scans to train a medical domain 3D convolution neural network. The labels include imaging modalities and sequences, patient orientation and view, presence of contrast agent, scan target and coverage, and slice spacing. We applied our method and extracted labels from a large amount of cancer imaging dataset from TCIA to train a medical domain 3D deep convolution neural network. We evaluated the effectiveness of using our proposed network in transfer learning a liver segmentation task and found that our network achieved superior segmentation performance (DICE=90.0%) compared to training from scratch (DICE=41.8%). Our proposed network shows promising results to be used as a backbone network for transfer learning to another task. Our approach along with the utilising our network, can potentially be used to extract features from large-scale unlabelled DICOM datasets.

Keywords: Transfer learning, Large dataset, Data mining

1. Introduction

With the abundance of medical images routinely taken at hospitals, imaging-based machine learning approaches had become a centre of development in diagnostic radiology. Methods based on deep learning had promising results in many areas of diagnostic radiology such as tumour segmentation and classification (Gonzalez et al., 2018; Song et al., 2018; Nielsen et al., 2018). Despite successes, performances of neural networks in the medical domain are often limited by small development set. To alleviate the problem, transfer learning from pre-existing datasets were used to improve performance. Transfer learning is the process of taking existing pre-trained network architecture designed for an existing dataset (typically over a million) and then fine-tuned against on data for another task. The current most popular dataset used for transfer learning is ImageNet, which consists of over 14 million natural images with 20 thousand classes (Russakovsky et al., 2014). Popular ImageNet architectures such as ResNet, Inception and DenseNet had had success in medical imaging task, particular in radiographs and ophthalmological images such as a retina scan (Rajpurkar

et al., 2017; Gulshan et al., 2016). However, since most diagnostic imagery consists of 3D volumetric images, transfer learning from the natural domain are not feasible. Since 3D networks architecture generally is more prone to over-fitting due to having more parameters, this had often lead to some studies to treat each 2D slices of a 3D volume independently to leverage transfer learning, hence discarding the potential useful structural information.

Despite many radiological imaging datasets are available in the public domain from channels such as CodaLab (<https://competitions.codalab.org>) and The Cancer Imaging Archive (TCIA) (Clark et al., 2013), there has not been a large-scale 3D dataset that is available to use for training a network similar to ImageNet. One primary reason is that medical images are inherently more complex than natural images, and would require a significant amount of time and specialised medical knowledge to annotate. The recent effort by Chen et al. (2019) had developed a general multi-domain network (MED3D) based on publicly available volumetric segmentation datasets had shown superior performance in several organ segmentation tasks compared to training from scratch, further emphasises the need for a large-scale dataset. One limiting factor of MED3D is that it requires segmentation annotations which could be impractical on a large scale due to the time needed for annotating volumetric images. An alternative method is needed to build such network and dataset for transfer learning in the medical domain.

One potential avenue to explore is the use of digital imaging and communications in medicine metadata (DICOM). DICOM is the standardised format for storing and transferring medical images in clinics. Along with the imagery, DICOM metadata stores patient information and acquisition parameters of the scan. For example, information on the type of imaging modality, types of MRI sequences used, patient position during the scan, and the use of contrast agent could potentially provide enough distinct features to describe the appearance of the images for a neural network to learn. In this study, we explore whether we can automatically or semi-automatically extract labels from DICOM metadata of a large amount of DICOM images from publicly available datasets to train a general medical domain convolution neural network.

The main contributions of this study are as follows¹:

- We acquired and semi-automatically labelled a large public MRI and CT dataset available from TCIA by using the information provided in the DICOM headers.
- We trained a 3D convolution neural network on a large amount of volumetric radiological scans to classify modality, imaging sequence, view, presence of contrast agent, and the coverage of the body part.
- We demonstrated the effectiveness of using our proposed network for transfer learning of a liver segmentation task. We found a high performance gained compared to training a 3D convolution neural network from scratch.

1. To facilitate future development and application of our network and data. Source code, dataset and labels will be made publicly at <https://github.com/du1388/3d-radnet>

2. Methodology

This study aims to develop and train a general medical domain network from a large amount of 3D volumetric data that could be used for transfer learning to other medical imaging tasks. To achieve this, we acquired and analysed a large collection of cancer imaging data from the TCIA database to extract useful labels to train a convolution neural network called the 3D-RADNet. We then tested the effectiveness of the network in transfer learning by using the network as an encoder for segmentation of the liver.

2.1. Data Acquisition and Label Extraction

TCIA is an online database that hosts a large number of medical images of cancer. All images are in DICOM format and organised into different collections based on the type of diseases. For this study, we downloaded all collections that contain MRI and CT scans and can be redistributed under the creative commons attribution 3.0 unsupported license (<https://creativecommons.org/licenses/by/3.0/>). A list of all the TCIA collections acquired for this study are given in Appendix A Tables A1 and A2. Once all the scans were acquired, we extracted all the standardised DICOM metadata from all scan series in the collections for analysis.

2.1.1. MRI SEQUENCES

The appearance of an MRI image is dependent on the MRI sequences used for the acquisition. Commonly used diagnostic sequences can be classified into three types: spin-echo (SE), inversion recovery (IR) and gradient-echo (GR). This is specified in the DICOM attributes *Scanning Sequence* (0018,0020) under the same classification. Two main SE sequences, T1-weighted (T1 - SE) and T2-weighted (T2 - SE) are commonly used in diagnostic scans. The differences between weighing can be determined by the attributes *Repetition time* (0018,0080) and *Echo time* (0018,0081), where a T1-weighted scan have a short repetition time (TS) and short echo time (TE), and vice versa. For IR sequences, fluid-attenuated inversion recovery (FLAIR) and short tau inversion recovery (STIR) are most commonly used. The weighting of IR sequences can be determined by the TE time of the sequence. In addition to scanning sequence and TS/TE times, series (0008,103E) and study description (0008,1030) can also be used to identify types of sequences. However the descriptions are not standardised and can vary greatly depending on the convention used by the imaging centre and vendor. Due to a high amount of different variants and different name conventions of GR sequences, it is difficult to group the sequences accordingly. Therefore We decided not to use GR in our analysis. Other types of functional imaging sequences such as functional MRI, magnetic resonance angiography, diffusion and perfusion-weighted imaging was also excluded in our study due to vast differences in appearances. Time-series images such as dynamic-contrast were also excluded to avoid biases as there will be a high amount of the same scan present in training.

2.1.2. SCAN VIEW

The anatomically plane in which the scan was taken can be identified by the attributes *Patient Image Position* (0020,0032) and *Patient Image Orientation* (0020,0037). Patient

image position specifies the (x,y,z) coordinates of the upper left-hand corner of the image, whereas image orientation describes the direction cosine of the first row and the first column with respect to the patient. For most standard patient orientation of scans, a image orientation of [1,0,0,0,1,0], [1,0,0,0,0,-1], [0,1,0,0,0,-1] corresponds to axial, coronal and sagittal view respectively. For non-standard orientations, the view can be determined by *Patient position* (0018,5100) attributes. However, the occurrence of a non-standard view is rare. Hence we excluded all the cases from our analysis.

2.1.3. CONTRAST AGENT

The presence of a contrast agent in MRI and CT imaging can significantly affect the appearance of the image. The use of contrast agent are recorded in the attributes *Contrast/Bolus Agent* (0018,0010).

2.1.4. SCAN COVERAGE LABEL

The scan coverage of the body was explored to provide structural information of the image to the network. As scans protocols are often standardised in practice, extracting the target and coverage of the scan can systematically be obtained by comparing the study and series description, type of cancer given by TCIA and size of the scan. The label scheme for the coverage is shown in Figure 1. For each body parts/organs, the scan must cover the entirety of the target to be considered. For upper head and neck, it must include the sphenoid sinus, nasopharynx and oropharynx. Lower head and neck, it must cover from the larynx to apex of the lung.

2.1.5. IMAGE PROCESSING

All scans with less than 16 slices were excluded from the study to ensure there are sufficient slices for the network. To address heterogeneous voxels sizes and slice spacing across the scans, all scans were linearly resized to 48x192x192, which is the input size of the network. For scans with less than 48 slices, the scans were centred and filled with blank slices up to 48 slices. The effective slice spacing after resizing was recorded, and all resized scans with spacing higher than 1.5cm were excluded. All scans were then normalised by min-max normalisation and discretised to 256 grey levels.

2.2. 3D-RADNet Network

The proposed 3D-RADNet takes an input image of 48x192x192 and outputs five outputs classifying the image modality/sequences, view, contrast, scan coverage and slice spacing. For the network architecture, we adapted a ResNet50 structure to take 3D inputs (He et al., 2015). The network then connected to a fully connected layer of 1000 neurons and then branches into five separate layers corresponding to each of the outputs. For modality/sequence, view and contrast, softmax activation was used. Sigmoid activations were used of the scan coverage layer, and linear activation was used for slice spacing. The parameters of the network were optimised using cross-entropy loss and root-mean-squared with by ADAM optimiser.

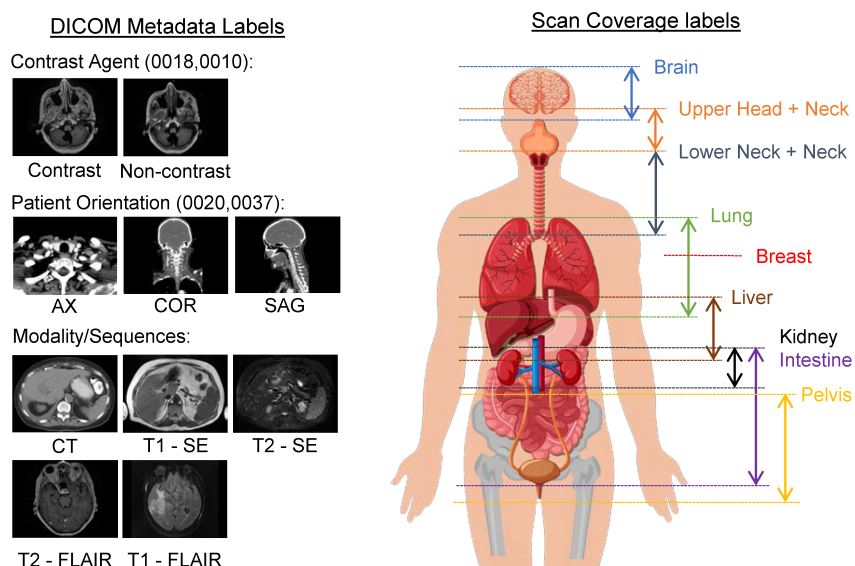


Figure 1: Scan coverage of labels used, and extracted labels from the DICOM metadata.

2.3. Liver segmentation

To evaluate the effectiveness of transfer learning in the proposed 3D-RADNet, we applied the network to segment the liver in the LiTS challenge dataset (<https://competitions.codalab.org/competitions/17094>). The LiTS challenge dataset consists of 131 abdominal CT scans with detailed delineation of the organ. Due to different slice spacing across the scans, all scans were linearly interpolated into 5mm spacing. The framework for transfer learning is described in Figure 2. The framework consists of two steps, the liver region proposal, and the training of the segmentation network. A sliding window of 48 slices with a stride of 8 slices was applied to extract patches of the potential region covering the liver. The extracted areas are evaluated with the 3D-RADNet to identify the regions containing the liver. As multiple patches from the sliding window can arise from one case, a threshold of 0.9 was used as cut off for selection. If no patches were greater than 0.9, the maximum score was used. The selected regions were then used for subsequent training. The decoder for the segmentation network was based on the VNet structure with up-sampling and skip-connection (Milletari et al., 2016). The parameters of the network were optimised using dice loss with by ADAM optimiser. To determine the impact of modification of the 3D-RADNet on the performance of segmentation, we trained different networks by freezing different residual blocks of the network. In addition, we also evaluate the impact of training sample in 3D-RADNet for transfer learning liver segmentation by training the network with random subsets of the training data.

3. Results

Of the 57 datasets acquired from TCIA, a total of 63276 (6544 unique subjects) individual MRI and CT image series were analysed. 45609 series were excluded from the study (in-

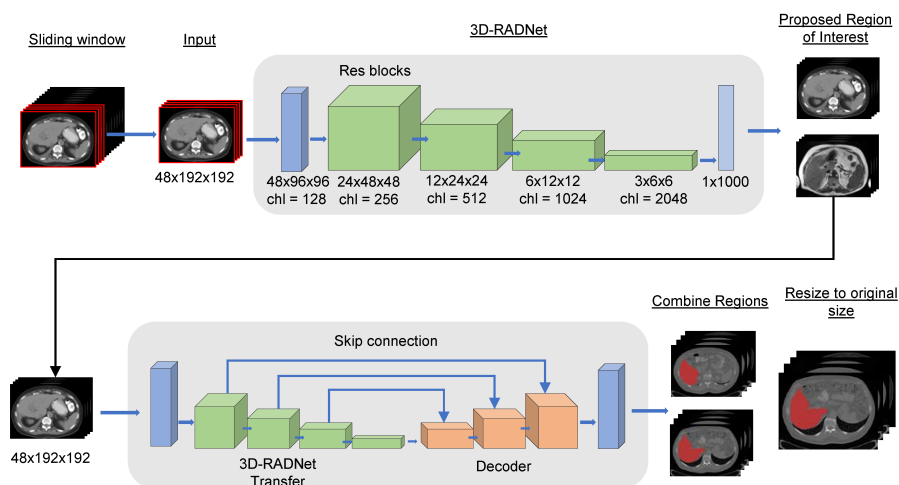


Figure 2: Transfer learning framework for liver segmentation task.

consistent/invalid slice position or spacing: 14575; the number of slices less than 16: 3768; missing series descriptions: 2041; excluded MRI sequences: 10887; Time-series: 14338). STIR sequence was also excluded from the study because of a low number of scans found. The remaining 17667 (4453 unique subjects) series were split into a training, validation and testing set for training the network. The summary of the data is shown in Table A3.

3.1. 3D-RADNet

The classification results of the 3D-RADNet are summarised in Table 1. Of all the classifications, the presence of contrast agent had the worse accuracy (84.8%) with all other classification achieving over 90% in the testing set. A mean absolute error of 3.1mm and root mean square error of 4.2mm was obtained in the testing set for slice spacing regression.

3.2. Transfer Learning and Liver Segmentation

For the training of the segmentation network, the dataset was split 70:15:15 into training ($n=92$), validation ($n=19$) and testing set ($n=20$). Table 2 shows the impact of performance by the degree of modification of the 3D-RADNet for liver segmentation. The best segmentation performance was obtained from the network trained with all encoding 3D-RADNet layers frozen (DICE = 90.0%). Retraining the encoding res-block 3 and 4 achieved the second-highest score (DICE = 84.3%). Lowest segmentation performance was seen from training the network from scratch and from initialised with 3D-RADNet weights without freezing any layers. This was further illustrated in Appendix A Figure A1 where it can be seen that the networks failed to generalised to the validation set. For the best performing network, the impact of reducing training samples on the segmentation performance was analysed. As expected, Table 3 shows that performance decrease with training samples

with a Dice score of 80% achieved with 20% training data (n=18). For all networks, the validation set was kept the same.

Table 1: Classification performance of 3D-RADNet on the testing set

	Samples	Accuracy	AUC	Recall	Precision
Modality/Sequence					
CT	117	100%	100%	100%	100%
T1 - SE	51	97.8%	98.1%	92.2%	94.0%
T2 - SE	101	96.8%	98.8%	99.0%	91.7%
T1 - FLAIR	27	99.7%	100%	100%	96.4%
T2 - FLAIR	20	97.5%	96.5%	60%	100%
<u>Total</u>	<u>316</u>	<u>95.9%</u>			
View					
Axial	267	99.4%	100.0%	99.3%	100%
Coronal	32	100%	100%	100%	100%
Sagittal	17	99.4%	100.0%	100%	89.5%
<u>Total</u>	<u>316</u>	<u>99.4%</u>			
Contrast					
Contrast	100	84.8%	91.7%	86.0%	71.7%
No Contrast	216	84.8%	91.7%	84.3%	92.9%
Scan Coverage					
Brain	200	98.4%	99.9%	97.5%	100%
Upper Head-Neck	42	98.7%	99.7%	90.5%	100%
Lower Head-Neck	38	98.7%	98.7%	89.5%	100%
Lung	64	98.4%	98.8%	93.8%	98.4%
Breast	82	98.7%	99.6%	96.3%	98.8%
Liver	52	99.1%	99.7%	98.1%	96.2%
Kidney	52	98.7%	99.8%	100%	92.9%
Intestine	46	98.1%	100.0%	89.1%	97.6%
Pelvis	55	98.1%	99.9%	96.4%	93.0%
<u>Total</u>	<u>316</u>	<u>91.5%</u>			

4. Discussion

In this study, we developed and trained a medical-domain 3D convolution neural network that can be used as a backbone network for transfer learning. We achieved this by acquiring a large amount of cancer imaging dataset from TCIA. We devised a scheme to extract labels from DICOM metadata to train the network. The labels extracted include imaging modalities and sequences, view, presence of contrast agent, slice spacing and scan coverage. Of all the labels, extracting the scan coverage was the most time-consuming part. As datasets from the TCIA came from a range of different centres and institutes, it was difficult to learn the structure of the cases. However, in practice, this would not be a problem when applied to a single centre as you would know the scanning protocols beforehand. To

Table 2: Impact of liver segmentation performance by freezing different layers of the network and comparison of performance to no transfer learning is also given.

Modification	Mean DICE	Mean IOU	Median DICE	Median IOU
Froze all layers	90.0%	80.7%	90.0%	81.8%
Froze to block 3	72.1%	59.7%	81.0%	68.1%
Froze to block 2	84.3%	76.8%	90.3%	82.3%
Froze to block 1	77.6%	65.1%	81.8%	69.3%
Weights only	44.8%	38.1%	43.0%	27.4%
No transfer learning	41.8%	38.0%	43.0%	27.3%

Table 3: Impact of liver segmentation performance by percentage of training samples

% Training Data	Mean DICE	Mean IOU	Median DICE	Median IOU
100% (n=92)	90.0%	81.6%	90.1%	82.0%
80% (n=74)	84.7%	75.0%	89.0%	80.0%
60% (n=55)	84.2%	73.9%	87.2%	77.3%
40% (n=37)	87.0%	77.9%	90.9%	83.4%
20% (n=18)	80.0%	69.30%	86.5%	76.1%

evaluate the effectiveness of our network for transfer learning, we applied the network to a liver segmentation task. The results show that transfer learning by using our network achieved significantly higher performance than training from scratch in 3D networks. This is expected as the higher number of variables in 3D compared to 2D networks means would be more prone to over-fitting. This was also reflected in that the network only generalised well when the layers of the network were fixed regardless of transfer learning.

In comparison to earlier work by [Chen et al. \(2019\)](#), our network achieved a lower but comparable performance (DICE=90.0%) compared to MED3D (DICE=94.6%) that was trained on segmentation datasets. One difference in our approach was that we did not refine the segmentation mask from the initial segmentation. As we wanted to evaluate the raw performance of segmentation from the whole image. We would expect the performance to increase by refining the mask from expanding the region by using the initial segmentation mask.

One major limitation of our work is that the network architecture used for the 3D-RADNet is a 3D adaptation of ResNet50 which developed for 2D natural images. ResNet may not be optimal for volumetric medical images. Alternative network architecture tailed for medical images may increase the performance of the network.

In conclusion, we presented an approach to extract labels from DICOM metadata that describes the appearance of the images to train a general medical domain network. The 3D-RADNet shows promising potential to be used as a backbone network for transfer learning to another task. Our approach, along with the network, can potentially be used to extract features from large-scale unlabelled DICOM datasets.

References

- H J Aerts, E R Velazquez, R T Leijenaar, C Parmar, P Grossmann, S Carvalho, J Bussink, R Monshouwer, B Haibe-Kains, D Rietveld, F Hoebers, M M Rietbergen, C R Leemans, A Dekker, J Quackenbush, R J Gillies, and P Lambin. Decoding tumour phenotype by noninvasive imaging using a quantitative radiomics approach. *Nature Communications*, 5:4006, 2014. ISSN 2041-1723. doi: 10.1038/ncomms5006.
- O. Akin, P. Elnajjar, M. Heller, R. Jarosz, B. J. Erickson, S. Kirk, and J. Filippini. The Cancer Genome Atlas Kidney Renal Clear Cell Carcinoma [TCGA-KIRC] collection. *The Cancer Imaging Archive*, 2016. doi: 10.7937/K9/TCIA.2016.V6PBVTDR.
- B. Albertina, M. Watson, C. Holback, R. Jarosz, S. Kirk, Y. Lee, and J. Lemmerman. Radiology Data from The Cancer Genome Atlas Lung Adenocarcinoma [TCGA-LUAD] collection. *The Cancer Imaging Archive*, 2016. doi: 10.7937/K9/TCIA.2016.JGNIHEP5.
- Samuel G Armato, Lubomir M Hadjiiski, Georgia D Tourassi, Karen Drukker, Maryellen L Giger, Feng Li, George Redmond, Keyvan Farahani, Justin S Kirby, and Laurence P Clarke. Special Section Guest Editorial: LUNGx Challenge for computerized lung nodule classification: reflections and lessons learned. *Journal of Medical Imaging*, 2(2):1–5, 2015. doi: 10.1117/1.JMI.2.2.020103. URL <https://doi.org/10.1117/1.JMI.2.2.020103>.
- B. Nicolas Bloch, Ashali Jain, and C. Carl Jaffe. Data From BREAST-DIAGNOSIS. *The Cancer Imaging Archive*, 2015a. doi: 10.7937/K9/TCIA.2015.SDNRQXXR.
- B. Nicolas Bloch, Ashali Jain, and C. Carl Jaffe. Data From PROSTATE-DIAGNOSIS. *The Cancer Imaging Archive*, 2015b. doi: 10.7937/K9/TCIA.2015.FOQUEUJVT.
- Walter R. Bosch, William L. Straube, John W. Matthews, and James A. Purdy. Data From Head-Neck_Cetuximab. 2015. doi: 10.7937/K9/TCIA.2015.7AKGJUPZ.
- Carlos E Cardenas, A Mohamed, G. Sharp, M. Gooding, H. Veeraraghavan, and J. Yang. Data from AAPM RT-MAC Grand Challenge 2019. *The Cancer Imaging Archive*, 2019. doi: 10.7937/tcia.2019.bcfjqfqb.
- Sihong Chen, Kai Ma, and Yefeng Zheng. Med3D: Transfer Learning for 3D Medical Image Analysis. *CoRR*, abs/1904.00625, 2019. URL <http://arxiv.org/abs/1904.00625>.
- P Choyke, B Turkbey, P Pinto, M Merino, and B Wood. Data From PROSTATE-MRI. *The Cancer Imaging Archive*, 2016. doi: 10.7937/K9/TCIA.2016.6046GUDv.
- Kenneth Clark, Bruce Vendt, Kirk Smith, John Freymann, Justin Kirby, Paul Koppel, Stephen Moore, Stanley Phillips, David Maffitt, Michael Pringle, Lawrence Tarbox, and Fred Prior. The Cancer Imaging Archive (TCIA): maintaining and operating a public information repository. *Journal of digital imaging*, 26(6):1045–1057, dec 2013. ISSN 1618-727X (Electronic). doi: 10.1007/s10278-013-9622-7.
- National Cancer Institute Clinical Proteomic Tumor Analysis Consortium CPTAC. Radiology Data from the Clinical Proteomic Tumor Analysis Consortium Clear Cell Renal Cell

- Carcinoma [CPTAC-CCRCC] collection [Data set]. *The Cancer Imaging Archive*, 2018a. doi: 10.7937/k9/tcia.2018.oblamn27.
- National Cancer Institute Clinical Proteomic Tumor Analysis Consortium CPTAC. Radiology Data from the Clinical Proteomic Tumor Analysis Consortium Cutaneous Melanoma [CPTAC-CM] collection [Data set]. *The Cancer Imaging Archive.*, 2018b. doi: 10.7937/k9/tcia.2018.odu24gze.
- National Cancer Institute Clinical Proteomic Tumor Analysis Consortium CPTAC. Radiology Data from the Clinical Proteomic Tumor Analysis Consortium Glioblastoma Multiforme [CPTAC-GBM] collection [Data set]. *The Cancer Imaging Archive. The Cancer Imaging Archive*, 2018c. doi: 10.7937/k9/tcia.2018.3rje41q1.
- National Cancer Institute Clinical Proteomic Tumor Analysis Consortium CPTAC. Radiology Data from the Clinical Proteomic Tumor Analysis Consortium Head and Neck Squamous Cell Carcinoma [CPTAC-HNSCC] Collection. *The Cancer Imaging Archive*, 2018d. doi: 10.7937/K9/TCIA.2018.UW45NH81.
- National Cancer Institute Clinical Proteomic Tumor Analysis Consortium CPTAC. Radiology Data from the Clinical Proteomic Tumor Analysis Consortium Lung Adenocarcinoma [CPTAC-LUAD] collection [Data set]. *The Cancer Imaging Archive*, 2018e. doi: 10.7937/k9/tcia.2018.pat12tbs.
- National Cancer Institute Clinical Proteomic Tumor Analysis Consortium CPTAC. Radiology Data from the Clinical Proteomic Tumor Analysis Consortium Pancreatic Ductal Adenocarcinoma [CPTAC-PDA] Collection [Data set]. *The Cancer Imaging Archive*, 2018f. doi: 10.7937/k9/tcia.2018.sc20fo18.
- National Cancer Institute Clinical Proteomic Tumor Analysis Consortium CPTAC. Radiology Data from the Clinical Proteomic Tumor Analysis Consortium Sarcomas [CPTAC-SAR] collection [Data set]. *The Cancer Imaging Archive*, 2018g. doi: 10.7937/TCIA.2019.9bt23r95.
- National Cancer Institute Clinical Proteomic Tumor Analysis Consortium CPTAC. Radiology Data from the Clinical Proteomic Tumor Analysis Consortium Uterine Corpus Endometrial Carcinoma [CPTAC-UCEC] Collection [Data set]. *The Cancer Imaging Archive*, 2018h. doi: 10.7937/k9/tcia.2018.3r3juisw.
- B. J. Erickson, S. Kirk, Y. Lee, O. Bathe, M. Kearns, C. Gerdes, and J. Lemmerman. Radiology Data from The Cancer Genome Atlas Liver Hepatocellular Carcinoma [TCGA-LIHC] collection. *The Cancer Imaging Archive*, 2016a. doi: 10.7937/K9/TCIA.2016.IMMQW8UQ.
- B. J. Erickson, D. Mutch, L. Lippmann, and R. Jarosz. Radiology Data from The Cancer Genome Atlas Uterine Corpus Endometrial Carcinoma (TCGA-UCEC) collection. *The Cancer Imaging Archive*, 2016b. doi: 10.7937/K9/TCIA.2016.GKJ0ZWAC.
- Bradley Erickson, Zeynettin Akkus, Jiri Sedlar, and Panagiotis Korfiatis. Data From LGG-1p19qDeletion. *The Cancer Imaging Archive*, 2017. doi: 10.7937/K9/TCIA.2017.dwehtz9v.

- German Gonzalez, Samuel Y Ash, Gonzalo Vegas-Sanchez-Ferrero, Jorge Onieva Onieva, Farbod N Rahaghi, James C Ross, Alejandro Diaz, Raul San Jose Estepar, and George R Washko. Disease Staging and Prognosis in Smokers Using Deep Learning in Chest Computed Tomography. *American journal of respiratory and critical care medicine*, 197(2): 193–203, jan 2018. ISSN 1535-4970 (Electronic). doi: 10.1164/rccm.201705-0860OC.
- Olya Grove, Anders E Berglund, Matthew B Schabath, Hugo J W L Aerts, Andre Dekker, Hua Wang, Emmanuel Rios Velazquez, Philippe Lambin, Yuhua Gu, Yoganand Balagurunathan, Edward Eikman, Robert A Gatenby, Steven Eschrich, and Robert J Gillies. Quantitative computed tomographic descriptors associate tumor shape complexity and intratumor heterogeneity with prognosis in lung adenocarcinoma. *PloS one*, 10(3):e0118261, 2015. ISSN 1932-6203 (Electronic). doi: 10.1371/journal.pone.0118261.
- Varun Gulshan, Lily Peng, Marc Coram, Martin C Stumpe, Derek Wu, Arunachalam Narayanaswamy, Subhashini Venugopalan, Kasumi Widner, Tom Madams, Jorge Cuadros, Ramasamy Kim, Rajiv Raman, Philip C Nelson, Jessica L Mega, and Dale R Webster. Development and Validation of a Deep Learning Algorithm for Detection of Diabetic Retinopathy in Retinal Fundus Photographs. *JAMA*, 316(22):2402–2410, dec 2016. ISSN 1538-3598 (Electronic). doi: 10.1001/jama.2016.17216.
- Kaiming He, Xiangyu Zhang, Shaoqing Ren, and Jian Sun. Deep residual learning for image recognition, 2015.
- N. Heller, N. Sathianathen, E. Kalapara, A., Walczak, K. Moore, H. Kaluzniak, J. Rosenberg, P. Blake, Z. Rengel, M. Oestreich, J. Dean, M. Tradewell, A. Shah, R. Tejpaal, Z. Edgerton, M. Peterson, S. Raza, S. Regmi, N. Papanikolopoulos, and C. Weight. Data from C4KC-KiTS [Data set]. *The Cancer Imaging Archive*, 2019. doi: 10.7937/TCIA.2019.IX49E8NX.
- C. Holback, R. Jarosz, F. Prior, D. G. Mutch, P. Bhosale, K. Garcia, and B. J. Erickson. Radiology Data from The Cancer Genome Atlas Ovarian Cancer [TCGA-OV] collection. *The Cancer Imaging Archive*, 2016. doi: 10.7937/K9/TCIA.2016.NDO1MDFQ.
- Wei Huang, Xin Li, Yiyi Chen, Xia Li, Ming-Ching Chang, Matthew J Oborski, Dariya I Malyarenko, Mark Muzi, Guido H Jajamovich, Andriy Fedorov, Alina Tudorica, Sandeep N Gupta, Charles M Laymon, Kenneth I Marro, Hadrien A Dyvorne, James V Miller, Daniel P Barbodiak, Thomas L Chenevert, Thomas E Yankeelov, James M Mountz, Paul E Kinahan, Ron Kikinis, Bachir Taouli, Fiona Fennessy, and Jayashree Kalpathy-Cramer. Variations of dynamic contrast-enhanced magnetic resonance imaging in evaluation of breast cancer therapy response: a multicenter data analysis challenge. *Translational oncology*, 7(1):153–166, feb 2014. ISSN 1936-5233. doi: 10.1593/tlo.13838. URL <https://www.ncbi.nlm.nih.gov/pubmed/24772219><https://www.ncbi.nlm.nih.gov/pmc/articles/PMC3998693/>.
- Jayashree Kalpathy-Cramer, Binsheng Zhao, Dmitry Goldgof, Yuhua Gu, Xingwei Wang, Hao Yang, Yongqiang Tan, Robert Gillies, and Sandy Napel. A Comparison of Lung Nodule Segmentation Algorithms: Methods and Results from a Multi-institutional Study.

- Journal of digital imaging*, 29(4):476–487, aug 2016. ISSN 1618-727X (Electronic). doi: 10.1007/s10278-016-9859-z.
- S. Kirk, Y. Lee, P. Kumar, J. Filippini, B. Albertina, M. Watson, and J. Lemmerman. Radiology Data from The Cancer Genome Atlas Lung Squamous Cell Carcinoma [TCGA-LUSC] collection. *The Cancer Imaging Archive*, 2016a. doi: 10.7937/K9/TCIA.2016.TYGKKFMQ.
- S. Kirk, Y. Lee, F. R. Lucchesi, N. D. Aredes, N. Gruszauskas, J. Catto, and J. Lemmerman. Radiology Data from The Cancer Genome Atlas Urothelial Bladder Carcinoma [TCGA-BLCA] collection. *The Cancer Imaging Archive*, 2016b. doi: 10.7937/K9/TCIA.2016.8LNG8XDR.
- S. Kirk, Y. Lee, C. Roche, E. Bonaccio, J. Filippini, and R. Jarosz. Radiology Data from The Cancer Genome Atlas Thyroid Cancer [TCGA-THCA] collection. *The Cancer Imaging Archive*, 2016c. doi: 10.7937/K9/TCIA.2016.9ZFRVF1B.
- S. Kirk, Y. Lee, C. A. Sadow, and S. Levine. Radiology Data from The Cancer Genome Atlas Rectum Adenocarcinoma [TCGA-READ] collection. *The Cancer Imaging Archive*, 2016d. doi: 10.7937/K9/TCIA.2016.F7PPNPNU.
- S. Kirk, Y. Lee, C. A. Sadow, S. Levine, C. Roche, E. Bonaccio, and J. Filippini. Radiology Data from The Cancer Genome Atlas Colon Adenocarcinoma. *The Cancer Imaging Archive*, 2016e. doi: 10.7937/K9/TCIA.2016.HJJHBOXZ.
- M. Linehan, R. Gautam, S. Kirk, Y. Lee, C. Roche, E. Bonaccio, and R. Jarosz. The Cancer Genome Atlas Cervical Kidney renal papillary cell carcinoma [KIRP] collection. *The Cancer Imaging Archive*, 2016a. doi: 10.7937/K9/TCIA.2016.ACWOGBEF.
- M. W. Linehan, R. Gautam, C. A. Sadow, and S. Levine. Radiology Data from The Cancer Genome Atlas Kidney Chromophobe [TCGA-KICH] collection. *The Cancer Imaging Archive*, 2016b. doi: 10.7937/K9/TCIA.2016.YU3RBCZN.
- W. Lingle, B. J. Erickson, M. L. Zuley, R. Jarosz, E. Bonaccio, J. Filippini, and N. Gruszauskas. Data from The Cancer Genome Atlas Breast Invasive Carcinoma [TCGA-BRCA] collection. 2016. doi: 10.7937/K9/TCIA.2016.AB2NAZRP.
- G. Litjens, O. Debats, J. Barentsz, N. Karssemeijer, and H. Huisman. Computer-aided detection of prostate cancer in mri. *IEEE Transactions on Medical Imaging*, 33(5):1083–1092, May 2014. ISSN 1558-254X. doi: 10.1109/TMI.2014.2303821.
- F. R. Lucchesi and N. D. Aredes. Radiology Data from The Cancer Genome Atlas Cervical Squamous Cell Carcinoma and Endocervical Adenocarcinoma [TCGA-CESC] collection. *The Cancer Imaging Archive*, 2016a. doi: 10.7937/K9/TCIA.2016.SQ4M8YP4.
- F. R. Lucchesi and N. D. Aredes. Radiology Data from The Cancer Genome Atlas Esophageal Carcinoma [TCGA-ESCA] collection. *The Cancer Imaging Archive*, 2016b. doi: 10.7937/K9/TCIA.2016.VPTNRGFY.

- F. R. Lucchesi and N. D. Aredes. Radiology Data from The Cancer Genome Atlas Stomach Adenocarcinoma [TCGA-STAD] collection. *The Cancer Imaging Archive*, 2016c. doi: 10.7937/K9/TCIA.2016.GDHL9KIM.
- A. Madabhushi and M. Feldman. Fused Radiology-Pathology Prostate Dataset. *The Cancer Imaging Archive*, 2016. doi: 10.7937/K9/TCIA.2016.TLPMR1AM.
- Fausto Milletari, Nassir Navab, and Seyed-Ahmad Ahmadi. V-net: Fully convolutional neural networks for volumetric medical image segmentation, 2016.
- Shah Nameeta, Xu Feng, Ralph B. Lankerovich, Michael Puchalski, and Bart Keogh. Data from Ivy GAP. *The Cancer Imaging Archive*, 2016. doi: 10.7937/K9/TCIA.2016.XLwaN6nL.
- David Newitt and Hylton Hylton. Single site breast DCE-MRI data and segmentations from patients undergoing neoadjuvant chemotherapy. *The Cancer Imaging Archive*, 2016. doi: 10.7937/K9/TCIA.2016.QHsyhJKy.
- David Newitt and Hylton Nola. Multi-center breast DCE-MRI data and segmentations from patients in the I-SPY 1/ACRIN 6657 trials. *The Cancer Imaging Archive*, 2016. doi: 10.7937/K9/TCIA.2016.HdHpgJLK.
- Anne Nielsen, Mikkel Bo Hansen, Anna Tietze, and Kim Mouridsen. Prediction of Tissue Outcome and Assessment of Treatment Effect in Acute Ischemic Stroke Using Deep Learning. *Stroke*, 49(6):1394–1401, jun 2018. ISSN 1524-4628 (Electronic). doi: 10.1161/STROKEAHA.117.019740.
- M. Patnana, S. Patel, and A. Tsao. Anti-PD-1 Immunotherapy Melanoma Dataset [Data set]. *The Cancer Imaging Archive*, 2019. doi: 10.7937/tcia.2019.1ae0qtcu.
- N. Pedano, A. E. Flanders, L. Scarpace, T. Mikkelsen, J. M. Eschbacher, B. Hermes, and Q. Ostrom. Radiology Data from The Cancer Genome Atlas Low Grade Glioma [TCGA-LGG] collection. *The Cancer Imaging Archive*, 2016. doi: 10.7937/K9/TCIA.2016.L4LTD3TK.
- Pranav Rajpurkar, Jeremy Irvin, Kaylie Zhu, Brandon Yang, Hershel Mehta, Tony Duan, Daisy Ding, Aarti Bagul, Curtis Langlotz, Katie Shpanskaya, Matthew P. Lungren, and Andrew Y. Ng. Chexnet: Radiologist-level pneumonia detection on chest x-rays with deep learning, 2017.
- C. Roche, E. Bonaccio, and J. Filippini. Radiology Data from The Cancer Genome Atlas Sarcoma [TCGA-SARC] collection. *The Cancer Imaging Archive*, 2016. doi: 10.7937/K9/TCIA.2016.CX6YLSUX.
- Holger R Roth, Le Lu, Amal Farag, Hoo-Chang Shin, Jiamin Liu, Evrim B Turkbey, and Ronald M Summers. DeepOrgan: Multi-level Deep Convolutional Networks for Automated Pancreas Segmentation. In Nassir Navab, Joachim Hornegger, William M Wells, and Alejandro Frangi, editors, *Medical Image Computing and Computer-Assisted Intervention – MICCAI 2015*, pages 556–564, Cham, 2015. Springer International Publishing. ISBN 978-3-319-24553-9.

- Olga Russakovsky, Jia Deng, Hao Su, Jonathan Krause, Sanjeev Satheesh, Sean Ma, Zhiheng Huang, Andrej Karpathy, Aditya Khosla, Michael Bernstein, Alexander C. Berg, and Li Fei-Fei. Imagenet large scale visual recognition challenge, 2014.
- Mirabela Rusu, Prabhakar Rajiah, Robert Gilkeson, Michael Yang, Christopher Donatelli, Rajat Thawani, Frank J Jacono, Philip Linden, and Anant Madabhushi. Co-registration of pre-operative CT with ex vivo surgically excised ground glass nodules to define spatial extent of invasive adenocarcinoma on in vivo imaging: a proof-of-concept study. *European radiology*, 27(10):4209–4217, oct 2017. ISSN 1432-1084 (Electronic). doi: 10.1007/s00330-017-4813-0.
- L. Scarpace, T. Mikkelsen, Soonmee Cha, S. Rao, S. Tekchandani, D. Gutman, and L. J. Pierce. Radiology Data from The Cancer Genome Atlas Glioblastoma Multiforme [TCGA-GBM] collection. *The Cancer Imaging Archive*, 2016. doi: 10.7937/K9/TCIA.2016.RNYFUYE9.
- Lisa Scarpace, Adam E. Flanders, Rajan Jain, Tom Mikkelsen, and David W. Andrews. Data From REMBRANDT. *The Cancer Imaging Archive*, 2015. doi: 10.7937/K9/TCIA.2015.588OZUZB.
- Kathleen M Schmainda, Melissa A Prah, Jennifer M Connelly, and Scott D Rand. Glioma DSC-MRI Perfusion Data with Standard Imaging and ROIs [Dataset]. *The Cancer Imaging Archive*, 2016. doi: 10.7937/K9/TCIA.2016.5DI84Js8.
- K.M. Schmainda and M Prah. Data from Brain-Tumor-Progression. *The Cancer Imaging Archive*, 2018. doi: 10.7937/K9/TCIA.2018.15quzvnb.
- K Smith, K Clark, W Bennett, T Nolan, J Kirby, M Wolfsberger, J Moulton, B Vendt, and J Freymann. Data From CT_COLONOGRAPHY. *The Cancer Imaging Archive*, 2015. doi: 10.7937/K9/TCIA.2015.NWTESAY1.
- Yang Song, Yu-Dong Zhang, Xu Yan, Hui Liu, Minxiong Zhou, Bingwen Hu, and Guang Yang. Computer-aided diagnosis of prostate cancer using a deep convolutional neural network from multiparametric MRI. *Journal of magnetic resonance imaging : JMRI*, 48(6):1570–1577, dec 2018. ISSN 1522-2586 (Electronic). doi: 10.1002/jmri.26047.
- M Vallières, C R Freeman, S R Skamene, and I El Naqa. A radiomics model from joint FDG-PET and MRI texture features for the prediction of lung metastases in soft-tissue sarcomas of the extremities. *Physics in Medicine and Biology*, 60(14):5471–5496, 2015. ISSN 0031-9155. doi: 10.1088/0031-9155/60/14/5471. URL <http://stacks.iop.org/0031-9155/60/i=14/a=5471?key=crossref.4ebd805d5c2e9543c94ce4172981418e>.
- Afua A. Yorke, Gary C. McDonald, David Solis Jr., and Thomas Guerrero. Pelvic Reference Data. *The Cancer Imaging Archive*, 2019. doi: 10.7937/K9/TCIA.2019.woskq5oo.
- Binsheng Zhao, Leonard P James, Chaya S Moskowitz, Pingzhen Guo, Michelle S Ginsberg, Robert A Lefkowitz, Yilin Qin, Gregory J Riely, Mark G Kris, and Lawrence H Schwartz. Evaluating Variability in Tumor Measurements from Same-day Repeat CT

Scans of Patients with Non-Small Cell Lung Cancer. *Radiology*, 252(1):263–272, 2009. doi: 10.1148/radiol.2522081593. URL <https://doi.org/10.1148/radiol.2522081593>.

M. L. Zuley, R. Jarosz, B. F. Drake, D. Rancilio, A. Klim, K. Rieger-Christ, and J. Lemmerman. Radiology Data from The Cancer Genome Atlas Prostate Adenocarcinoma [TCGA-PRAD] collection. *The Cancer Imaging Archive*, 2016. doi: 10.7937/K9/TCIA.2016.YXOGLM4Y.

Appendix A.

Table A1: List of TCIA dataset used for the training of the proposed 3D-RADNet network

TCIA Sets	Modality	Location	Patient
AAPM RT-MAC (Cardenas et al., 2019)	MRI	Head-Neck	55
Brain-Tumor-Progression (Schmainda and Prah, 2018)	MRI	Brain	20
C4KC-KiTS (Heller et al., 2019)	CT	Kidney	210
Breast-MRI-NACT-Pilot (Newitt and Hylton, 2016)	MRI	Breast	64
CPTAC-CCRCC (CPTAC, 2018a)	MRI, CT	Kidney	63
CPTAC-GBM (CPTAC, 2018c)	MRI, CT	Brain	63
CPTAC-HNSCC (CPTAC, 2018d)	MRI, CT	Head-Neck	55
CPTAC-LUAD (CPTAC, 2018e)	MRI, CT	Lung	32
CPTAC-PDA (CPTAC, 2018f)	MRI, CT	Pancreas	68
CPTAC-UCEC (CPTAC, 2018h)	MRI, CT	Uterus	60
CT COLONOGRAPHY (Smith et al., 2015)	CT	Colon	825
Head-Neck Cetuximab (Bosch et al., 2015)	CT	Head-Neck	111
ISPY1 (Newitt and Nola, 2016)	MRI	Breast	222
IvyGAP (Nameeta et al., 2016)	MRI, CT	Brain	39
LGG-1p19qDeletion (Erickson et al., 2017)	MRI	Brain	159
LungCT-Diagnosis (Grove et al., 2015)	CT	Lung	61
Lung-Fused-CT-Pathology (Rusu et al., 2017)	CT	Lung	6
NSCLC-Radiomics-Genomics (Aerts et al., 2014)	CT	Lung	89
Pancreas-CT (Roth et al., 2015)	CT	Pancreas	82
Pelvic-Reference-Data (Yorke et al., 2019)	CT	Pelvis	58
Prostate Fused-MRI-Pathology (Madabhushi and Feldman, 2016)	MRI	Prostate	28
PROSTATE-DIAGNOSIS (Bloch et al., 2015b)	MRI	Prostate	92
PROSTATE-MRI (Choyke et al., 2016)	MRI	Prostate	26
PROSTATEx (Litjens et al., 2014)	MRI	Prostate	346
QIN Breast DCE-MRI (Huang et al., 2014)	MRI	Breast	10
QIN LUNG CT (Kalpathy-Cramer et al., 2016)	CT	Lung	47
REMBRANDT (Scarpace et al., 2015)	MRI	Brain	130
RIDER Lung CT (Zhao et al., 2009)	CT	Lung	32
SPIE-AAPM Lung CT Challenge (Armato et al., 2015)	CT	Lung	70
TCGA-BLCA (Kirk et al., 2016b)	MRI, CT	Bladder	120
TCGA-BRCA (Lingle et al., 2016)	MR	Breast	139

Table A1 continues: List of TCIA dataset used for the training of the proposed 3D-RADNet network

TCIA Sets	Modality	Location	Patient
TCGA-CESC (Lucchesi and Aredes, 2016a)	MR	Cervix	54
TCGA-COAD (Kirk et al., 2016e)	CT	Colon	25
TCGA-ESCA (Lucchesi and Aredes, 2016b)	CT	Esophagus	16
TCGA-GBM (Scarpace et al., 2016)	MRI, CT	Brain	262
TCGA-HNSC (Zuley et al., 2016)	MRI, CT	Head-Neck	227
TCGA-KICH (Linehan et al., 2016a)	MRI, CT	Kidney	15
TCGA-KIRC (Akin et al., 2016)	MRI, CT	Kidney	267
TCGA-KIRP (Linehan et al., 2016b)	MRI, CT	Kidney	33
TCGA-LIHC (Erickson et al., 2016a)	MRI, CT	Liver	97
TCGA-LUAD (Albertina et al., 2016)	CT	Lung	69
TCGA-LUSC (Kirk et al., 2016a)	CT	Lung	37
TCGA-OV (Holback et al., 2016)	MRI, CT	Ovary	143
TCGA-STAD (Lucchesi and Aredes, 2016c)	CT	Stomach	46
TCGA-UCEC (Erickson et al., 2016b)	MRI, CT	Uterus	65

Table A2: List of TCIA dataset used for the testing of the proposed 3D-RADNet network

TCIA Sets	Modality	Location	Patient
Anti-PD-1 MELANOMA (Patnana et al., 2019)	MRI, CT	Skin	47
BREAST-DIAGNOSIS (Bloch et al., 2015a)	MRI, CT	Breast	88
CPTAC-CM (CPTAC, 2018b)	MRI, CT	Skin	92
CPTAC-SAR (CPTAC, 2018g)	MRI, CT	Extremities	22
HNSCC (CPTAC, 2018d)	MRI, CT	Head-Neck	55
QIN-BRAIN-DSC-MRI (Schmainda et al., 2016)	MRI	Brain	49
Soft-tissue-Sarcoma (Vallières et al., 2015)	MRI	Skin	51
TCGA-LGG (Pedano et al., 2016)	MRI, CT	Brain	199
TCGA-PRAD (Zuley et al., 2016)	MRI, CT	Prostate	14
TCGA-READ (Kirk et al., 2016d)	MRI, CT	Kidney	3
TCGA-SARC (Roche et al., 2016)	MRI, CT	Extremities	5
TCGA-THCA (Kirk et al., 2016c)	CT	Neck	6

Table A3: Breakdown of the training and testing set

	Training set	Validation set	Testing set
	n=12000	n=3305	n=316
Modality/Sequence			
CT	5149	1556	117
T1 - SE	2187	652	51
T2 - SE	3477	1017	101
T1 - FLAIR	463	207	27
T2 - FLAIR	724	273	20
View			
Axial	8424	2202	267
Coronal	1298	426	32
Sagittal	2278	677	17
Contrast			
Contrast	8619	2407	216
No Contrast	3381	898	100
Scan Coverage			
Brain	4966	1677	200
Upper Head-Neck	1070	266	42
Lower Head-Neck	953	191	38
Lung	1002	271	64
Breast	1011	303	82
Liver	2818	693	52
Kidney	3544	846	52
Intestine	2179	504	46
Pelvis	3901	845	55

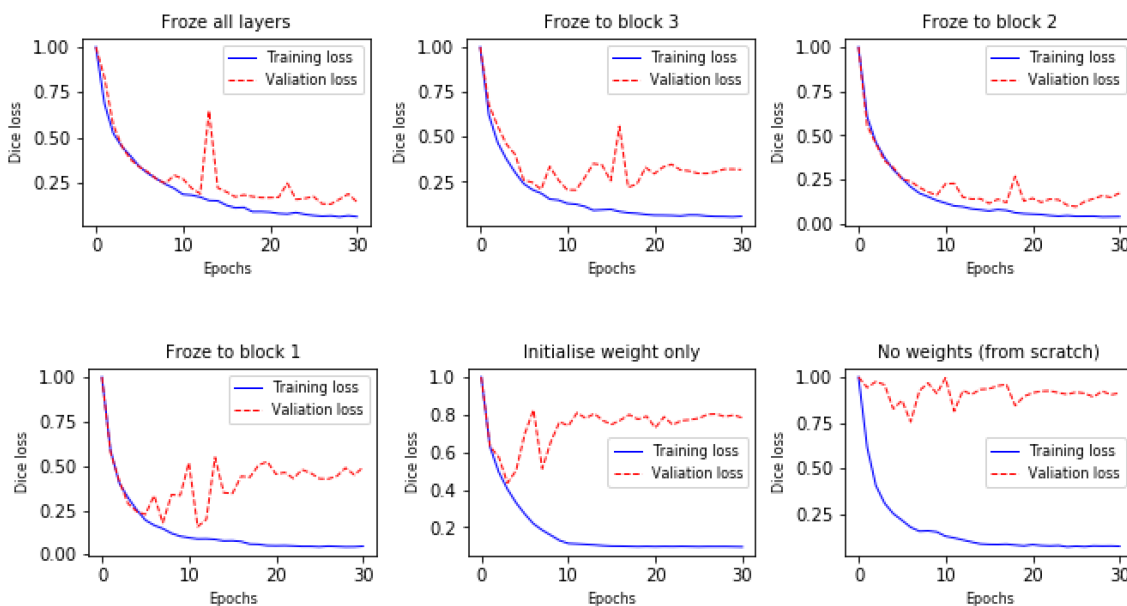


Figure A1: Training and validation losses during training