

A dataset of primary nasopharyngeal carcinoma MRI with multi-modalities segmentation

Yin Li^{1,†}, Qi Chen^{2,†}, Kai Wang^{1,†}, Meige Li^{1,†}, Liping Si³, Yingwei Guo¹, Yu Xiong¹, Qixing Wang¹, Yang Qin¹, Ling Xu², Patrick van der Smagt^{4,5}, Jun Tang^{1,*}, and Nutan Chen⁵

¹Department of Otorhinolaryngology, The First People's Hospital of Foshan, China

²Department of Radiology, The Second Affiliated Hospital of Anhui Medical University, China

³Department of Radiology, Zhongshan Hospital, Fudan University, Shanghai, China

⁴ELTE University, Budapest, Hungary

⁵Machine Learning Research Lab, Volkswagen Group, Munich, Germany

*corresponding author(s): Jun Tang (fsyytj@126.com)

†these authors contributed equally to this work

ABSTRACT

Multi-modality magnetic resonance imaging data with various sequences facilitate the early diagnosis, tumor segmentation, and disease staging in the management of nasopharyngeal carcinoma (NPC). The lack of publicly available, comprehensive datasets limits advancements in diagnosis, treatment planning, and the development of machine learning algorithms for NPC. Addressing this critical need, we introduce the first comprehensive NPC MRI dataset, encompassing MR axial imaging of 277 primary NPC patients. This dataset includes T1-weighted, T2-weighted, and contrast-enhanced T1-weighted sequences, totaling 831 scans. In addition to the corresponding clinical data, manually annotated and labeled segmentations by experienced radiologists offer high-quality data resources from untreated primary NPC.

Background & Summary

Nasopharyngeal carcinoma (NPC) is the sixth high-incidence cancer globally, with an estimated age-standardized incidence rate of 1.5 per 100,000 person-years as of 2020¹. However, it exhibits significant geographical variations, with much higher incidence rates in Southeast Asia, where it can reach up to 7.7 and 2.5 per 100,000 for males and females, respectively¹. Epstein-Barr virus (EBV) infection, genetic factors, family history and environmental factors are attributed to the risk of incidence². Men have three times higher morbidity than women in addition to a peak incidence typically between 40 and 60³. The five-year survival rate for NPC can range from around 60% to 90%, depending on the stage of the cancer at diagnosis, 14% of them suffered local recurrence, while 21% had concomitant distant metastases⁴. Radiotherapy is a primary treatment for NPC, especially for early-stage tumors. Induction chemotherapy (ICT) combined with concurrent chemoradiotherapy (CCRT) or CCRT alone is the treatment regimen of patients with advanced NPC⁵. Intensity-modulated radiation therapy (IMRT) is the preferred method due to its ability to target the tumor more precisely and reduce radiation-related toxicities to surrounding healthy tissues, thereby the contouring of primary gross tumor volume (GTVp) plays a crucial role regarding multimodal or multiparametric imaging data before radiotherapy⁶. Follow-up is recommended by the Chinese Society of Clinical Oncology and European Society for Medical Oncology guidelines consisting of a combination of periodic clinical, laboratory and radiological examinations including nasal endoscope, magnetic resonance imaging (MRI), and plasma EBV-DNA concentration^{7,8}. MRI is recommended to be performed every 6–12 months for surveillance of the local disease and the late complications⁷.

MRI is superior to CT in presenting soft-tissue contrast, multi-modalities imaging, and no ionizing radiation. Compared to CT imaging with advantages in bony visualization and peritumoral edema, MRI outperformed for displaying adjacent soft tissue invasion, skull base invasion, and the involvement of cranial nerves and retropharyngeal lymph node⁹. In terms of the advantage of metabolic imaging, positron emission tomography (PET)/CT has shown its superiority in the differential diagnosis of recurrence lesions in the nasopharynx¹⁰. MRI has better accuracy in detecting and re-staging the recurrence or residual primary lesions¹¹. MRI techniques include miscellaneous sequences due to their physical characteristics in imaging reconstruction, such as T1-weighted (T1W), T2-weighted (T2W), and contrast-enhanced T1-weighted (CE-T1), fluid-attenuated inversion-recovery, gadolinium-enhanced sequences, etc. The computer-assisted delineation of NPC GTVp based on the multi-modalities MRI and primary CT imaging data was widely employed in the process of pre-radiotherapy by oncologists^{2,18,19}. Annotation of NPC imaging by an experienced radiologist was a time-consuming procedure and individual-dependent precision impeded to some

extent the accuracy of IMRT.

As the application of machine learning (ML), especially convolutional neural networks (CNNs)^{12,13}, U-Net¹⁴, and vision Transformers (ViTs)¹⁵ in medical image analysis was introduced into the segmentation, prediction, and evaluation of disease, annotated MRI imaging data in multiple sequences in combination with clinical parameters provided multidimensional features to train and validate model¹⁶⁻²⁰. Recently, many curated automatic segmentation models have been proposed to offer the delineation of GTVp for NPC²¹⁻²⁴. The manually extracted features from the segmentation imaging in the field of deep learning offer highly accurate ground truth, more detailed annotation, and individual subtlety correction which rely on experienced oncologists. This need for public dataset publication is underscored by the inherent challenges in generating high-quality annotated data, which is both time-consuming and often unavailable alongside methodological publications. The labor-intensive specificity of accurately annotating medical images requires significant expertise and resources, making it a bottleneck in the development cycle of ML applications in medical imaging. By making these datasets publicly available, researchers and developers can leverage multidimensional features to improve model performance, innovate in automated segmentation, and enhance disease diagnosis and treatment strategies. Furthermore, published datasets enable the scientific community to collaborate more efficiently, replicate and validate findings, and accelerate the progress in medical imaging technologies of GTVp for NPC.

We presented a dataset of 277 patients with a clinical and pathological diagnosis of NPC with corresponding MR imaging axial slices including three contrasts: T1-weighted, T2-weighted, and contrast-enhanced T1-weighted which were through consistency test. The data included the laboratory examination regarding EBV status, biopsy results, and progression-free survival in the five-year follow-up period.

Methods

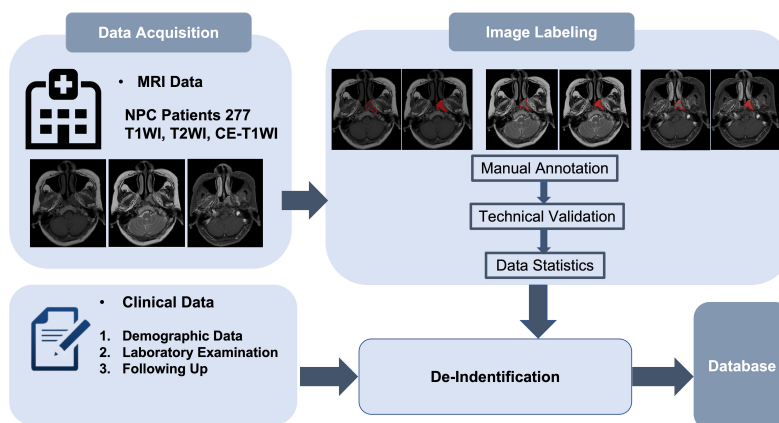


Figure 1. Graphic abstract and showcase. The MRI showcases a patient’s MRI imaging including T1WI, T2WI, and CE-T1WI sequences, which were processed by the manual annotation with labeled tumor boundaries and highlighted areas, respectively.

Image acquisition

	T1WI	T2WI	CE-T1WI
Echo time (ms)	12.74 ± 2.71	82.52 ± 12.29	12.24 ± 3.04
Repetition time (ms)	562.74 ± 140.15	3253.63 ± 601.4	633.62 ± 126.19
Pixel spacing (mm)	0.42 ± 0.03	0.58 ± 0.22	0.45 ± 0.02
Spacing between slices (mm)	3.98 ± 2.49	3.98 ± 2.49	3.98 ± 2.49
Slice thickness (mm)	5.08 ± 0.27	5.07 ± 0.27	5.07 ± 0.27

Table 1. MRI parameters of 277 patients. The results are represented as mean ± STD.

Our cohort included a total of 277 patients diagnosed with primary nasopharyngeal carcinoma in The First People’s Hospital of Foshan, China. All selected subjects were histopathologically confirmed as primary NPC without a prior history of radiation therapy, chemotherapy, or other malignancies that could potentially distort the tumor morphology. All patients were

restaged according to the eighth edition of the Union for International Cancer Control/American Joint Committee on Cancer (UICC/AJCC) staging system²⁵. The collected patients with age, gender, TNM stages, histopathological diagnosis, EBV status (VCA-IgA, EBV-DNA) and the 5 years progression-free survival further contributed to the clinical database. The process of data is depicted in Figure 1.

In our study, the image acquisition process was meticulously structured to ensure the highest quality of data for investigating nasopharyngeal carcinoma (NPC) segmentation. All cases underwent both plain and enhanced MRI scans, providing comprehensive imaging and clinical data. Exclusion criteria were as follows: (1) patients who had undergone radiotherapy or chemotherapy before the MRI examination, as the internal structure of the tumor and the boundary of the lesion may have changed after treatment, making it unable to fully reflect the original growth state of the tumor; (2) patients with a history of other malignant tumors; (3) images that did not meet standards, such as incomplete scan coverage due to excessively large lesion areas, insufficient image pixels, or the presence of artifacts. The dataset was captured using GE Discovery MR750w 3.0T and Philips Achieva 1.5T systems with Gadoteric Acid Meglumine Salt as the contrast agent. The setup and calibration of the two machines were similar, as can be seen from the STD of machine parameters in Table 1. Both datasets were rigorously curated, excluding patients with previous radiation or chemotherapy treatments, histories of other malignancies, or scans with subpar image quality. Table 1 displays the parameters of our MRI dataset.

To ensure the privacy and confidentiality of patient information, a strict anonymization protocol was applied. Personal identifiers such as names, ages, birth of data, sex, weight, content date were removed. Furthermore, unique patient IDs were replaced with the patients' index within the dataset. Indirect identifiers were also deleted to prevent any potential re-identification, e.g., study date and institute information.

Segmentation procedure

The segmentation procedure in our study was a critical step in preparing the MRI data for effective analysis. Since the manual segmentation is considered to provide highly accurate results and serves as the basis for subsequent analysis in our paper, all the MRI images were manually segmented. All MRI images were manually labeled by two radiologists with each more than 10 years of experience. The pixelwise tumor regions were segmented on the maximal slice of MRI images using ITK-SNAP version 3.6.1 (<http://www.itksnap.org>). They meticulously delineated the gross tumor volume (GTV) on transverse T1-weighted images (T1WI), T2-weighted images (T2WI), and contrast-enhanced T1-weighted images (CE-T1WI), while avoiding covering the adjacent tissue and air. The segmentation results were reviewed and modified by another senior radiologist with more than 15 years of experience. The segmented tumor regions were then converted into binary masks, representing the presence or absence of tumor tissue in each pixel. This rigorous segmentation procedure ensured the creation of a highly accurate and reliable dataset, forming a robust foundation for our subsequent analyses on NPC segmentation.

Morphological parameters

In the analysis of 3D tumor models, the Surface area, Volume, Max diameter and Surface regularity metrics are important to understand the tumor's spatial attributes, especially if the tumor has an irregular shape or extends in multiple directions. Surface Regularity = $v / (\frac{4}{3}\pi R^3)$ where v represents the volume of the segmented tumor and R denotes the equivalent radius of the tumor computed by the surface area. Surface Regularity is particularly important in understanding the complexity of a tumor's shape, as tumors with more irregular surfaces can indicate different biological behaviors compared to those with smoother surfaces. These metrics provide a comprehensive assessment of the tumor's characteristics, aiding in diagnosis and treatment planning.

Ethical statement

All methods of the present research were approved by the Board Committee on Ethics of the First People's Hospital of Foshan, Foshan, China (Number:2023-96) confirming that all data collection procedures adhered strictly to international guidelines on research ethics, ensuring the privacy and confidentiality of all participants involved.

Technical Validation

Data collection

Patient diagnosed with NPC were histopathologically confirmed and underwent both plain and enhanced MRI scans, providing comprehensive imaging and clinical data. Exclusion criteria included patients who had undergone previous radiotherapy or chemotherapy, those with a history of other malignant tumors, and images that did not meet quality standards. Ultimately, 277 patients met the criteria.

Segmentation method

Three modalities (T1WI, T2WI, and CE-T1WI) of MR images in the axial plane were exported from the Picture Archiving and Communication System (PACS) for analysis. Two experienced diagnostic radiologists individually performed manual

11. Thamboo, A. *et al.* Surveillance tools for detection of recurrent nasopharyngeal carcinoma: An evidence-based review and recommendations. *World J. Otorhinolaryngol. Neck Surg.* **8**, 187–204 (2022).
12. LeCun, Y., Bottou, L., Bengio, Y. & Haffner, P. Gradient-based learning applied to document recognition. *Proc. IEEE* **86**, 2278–2324 (1998).
13. Krizhevsky, A., Sutskever, I. & Hinton, G. E. Imagenet classification with deep convolutional neural networks. *Adv. neural information processing systems* **25** (2012).
14. Ronneberger, O., Fischer, P. & Brox, T. U-net: Convolutional networks for biomedical image segmentation. In *Medical image computing and computer-assisted intervention–MICCAI 2015: 18th international conference, Munich, Germany, October 5–9, 2015, proceedings, part III 18*, 234–241 (Springer, 2015).
15. Dosovitskiy, A. *et al.* An image is worth 16x16 words: Transformers for image recognition at scale. *arXiv preprint arXiv:2010.11929* (2020).
16. Li, Y. *et al.* Npcnet: jointly segment primary nasopharyngeal carcinoma tumors and metastatic lymph nodes in mr images. *IEEE Transactions on Med. Imaging* **41**, 1639–1650 (2022).
17. Huang, J.-b. *et al.* Achieving accurate segmentation of nasopharyngeal carcinoma in mr images through recurrent attention. In *Medical Image Computing and Computer Assisted Intervention–MICCAI 2019: 22nd International Conference, Shenzhen, China, October 13–17, 2019, Proceedings, Part V 22*, 494–502 (Springer, 2019).
18. Chen, H. *et al.* Mmfnet: A multi-modality mri fusion network for segmentation of nasopharyngeal carcinoma. *Neurocomputing* **394**, 27–40 (2020).
19. Lin, L. *et al.* Deep learning for automated contouring of primary tumor volumes by mri for nasopharyngeal carcinoma. *Radiology* **291**, 677–686 (2019).
20. Zhong, L. *et al.* A deep learning-based radiomic nomogram for prognosis and treatment decision in advanced nasopharyngeal carcinoma: a multicentre study. *ebiomedicine* **70**: 103522 (2021).
21. Tang, P. *et al.* Da-dsunet: dual attention-based dense su-net for automatic head-and-neck tumor segmentation in mri images. *Neurocomputing* **435**, 103–113 (2021).
22. Hao, Y. *et al.* Msu-net: multi-scale sensitive u-net based on pixel-edge-region level collaborative loss for nasopharyngeal mri segmentation. *Comput. Biol. Medicine* **159**, 106956 (2023).
23. Gu, R. *et al.* Cdds: Contrastive domain disentanglement and style augmentation for generalizable medical image segmentation. *Med. Image Analysis* **89**, 102904 (2023).
24. Luo, X. *et al.* Deep learning-based accurate delineation of primary gross tumor volume of nasopharyngeal carcinoma on heterogeneous magnetic resonance imaging: A large-scale and multi-center study. *Radiother. Oncol.* **180**, 109480 (2023).
25. Brierley, J. D., Gospodarowicz, M. K. & Wittekind, C. *TNM classification of malignant tumours* (John Wiley & Sons, 2017).
26. Li, Y. & Chen, N. A dataset of primary nasopharyngeal carcinoma mri with multi-modalities segmentation, [10.5281/zenodo.10900202](https://doi.org/10.5281/zenodo.10900202) (2024).

Author contributions statement

Conception and design: Y.L., J.T., N.C.; Data collection: Y.L., K.W., M.L., Y.G., Y.X.; Y.Q., Q.W., L.X.; Data labeling: Q.C., L.X., L.S.; Data processing: Y.L., Q.C., N.C., K.W., M.L.; Analysis and interpretation: Y.L., N.C., Q.C., L.S., P.v.d.S., J.T.; Writing: Y.L., Q.C., N.C., P.v.d.S.; All authors reviewed the manuscript.

Competing interests

The authors declare no competing interests.

Acknowledgment

This present study is supported by the Project of Foshan Science and Technology Bureau (2220001003814).