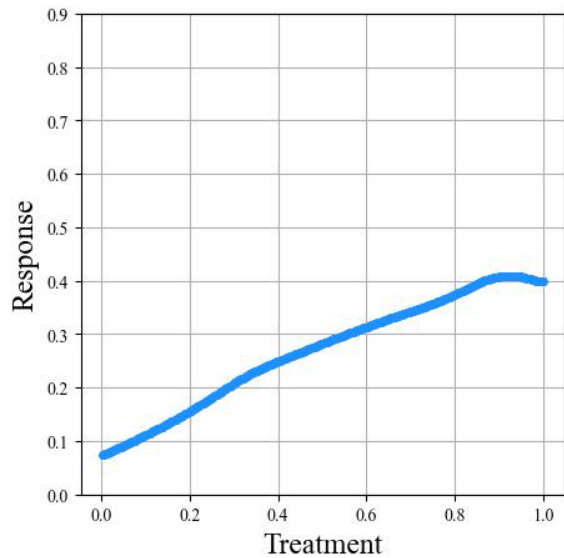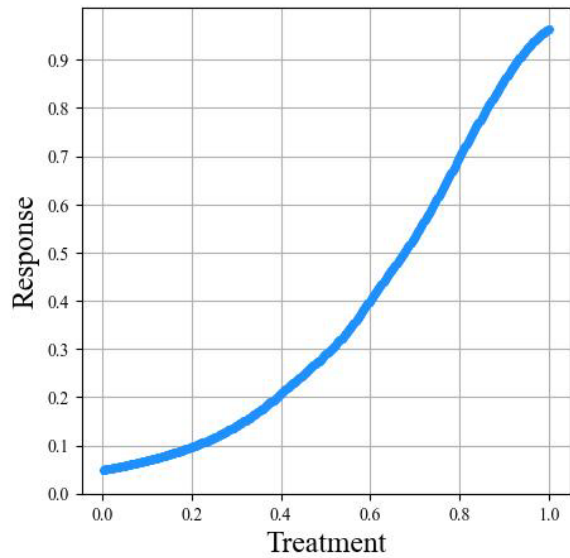
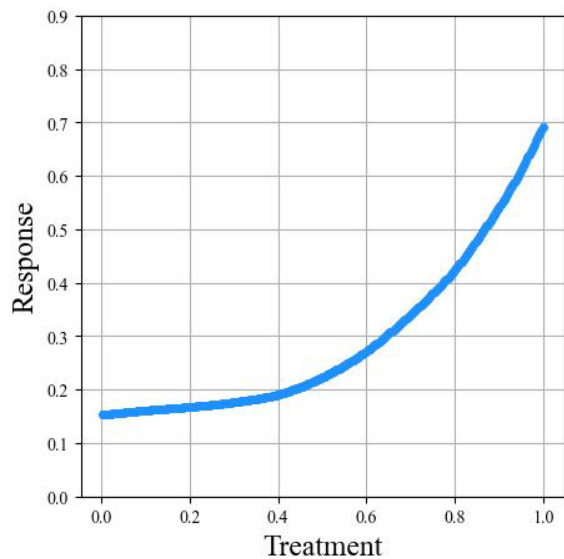


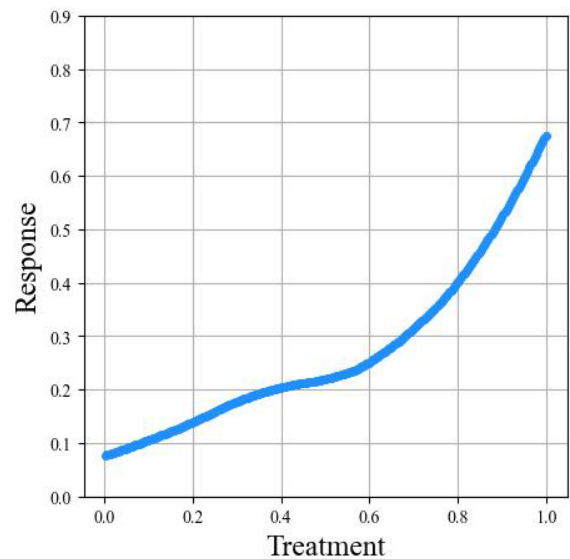
precentral gyrus



postcentral gyrus



left pallidum



right pallidum