

1.0T MR-based Treatment Planning for Spinal Stereotactic Radiosurgery – Initial Case Study

Ning Wen¹, Joshua Kim¹, Carri Glide-Hurst¹, Bo Zhao¹, Yimei Huang¹, David Hearshen², Milan Pantelic², M.Salim Siddiqui¹, Kenneth Levin¹, Benjamin Movsas¹, Indrin Chetty¹, and Samuel Ryu¹

¹Radiation Oncology, Henry Ford Health System, Detroit, Michigan, United States, ²Radiology, Henry Ford Health System, Detroit, Michigan, United States

Purpose: The role of magnetic resonance imaging (MRI) in routine clinical workflow in radiation oncology is a rapidly expanding technology. MRI is limited due to factors, such as reduced spatial resolution (relative to CT) due to geometric distortions, lack of electron density information, and imperfect positioning of MR-compatible immobilization for patient simulation; however, there are on-going investigations to address these concerns. The purpose of our study was to investigate the feasibility of developing a stereotactic radiosurgery (SRS) treatment protocol for spinal metastatic lesions based solely on images acquired from a dedicated 1.0 T Philips Panorama magnetic resonance simulation (MR-SIM) platform.

Materials and Methods: A patient diagnosed with soft tissue sarcoma was given SRS treatment with a single dose of 16 Gy at 90% to the C1-C2 paraspinal area. The patient was immobilized with a head, neck and shoulder thermoplastic mask (CIVCO Medical Solutions, Iowa, USA) for both CT and MRI simulation. The patient was simulated with 3 mm slices using a Philips Brilliance 16 slice CT scanner with IV contrast. The MR acquisitions employed T2-weighted Turbo Spin Echo (TSE) and pre and post gadolinium contrast 3D T1-weighted Fast Field Echo (FFE). Treatment planning was performed with two coplanar arcs using volumetric modulated arc therapy technique and 6MV flattening filter free beam. A voxel-based method was used to retrospectively generate a synthetic CT (SynCT) image set from a weighted combination of T1-weighted and T2-weighted images that were segmented according to regions using a tissue classification approach. The treatment plan was recalculated on the SynCT images with the same parameters.

Results: Fig.1 shows an axial slice of CT, T1-FFE, T2-TSE and SynCT images of the patient. The CT value range for the SynCT image was -1000 to 575 HU. The target volume was contoured in red and spinal cord in purple as shown in the images. The isodose lines shown in both CT and SynCT images are 90% (blue), 80% (cyan), 50%(magenta) and 30%(green) correspondingly. The dose differences between the two CT sets were within 3% for D95% (dose delivered to 95% of the volume), D10% and D5% of the target volume. The spinal cord dose difference of D10% was also within 3%.

Discussion: The open MR-SIM incorporates important modifications required for use in radiation therapy, including the use of rigid coils with integrated solenoid technology to accommodate MR compatible immobilization devices, the addition of a bridge laser system to correlate the patient position between the MRI scanner and the linear accelerator couch, as well as the use of a flat table top to facilitate the same body position between imaging and treatment. A novel approach for generating SynCT images from MRI images has been developed for dose calculation. Because of the difficulty in automatically distinguishing between bone and soft tissues/air in the MR images, the T2 TSE images were used to manually contour bony structures. We have been investigating the use of ultra-short TE (UTE) and water/fat separating multi-echo (mDIXON) sequences for improved bony segmentation. Artifacts caused by dental prosthetics (e.g. dental crowns) reduce image quality in MRI scans of the head and neck. This in turn impacts the ability to generate accurate SynCT images. Metal artifact reduction strategies could be employed to address this problem. Geometric distortions associated with MRI will degrade geometric accuracy in the synthetic CT images. Distortion corrections will need to be developed to ensure spatial resolution accurate enough for SRS-based treatment.

Conclusion: This pilot study shows that MRI has the potential to be a primary imaging modality for treatment planning. However, there are still many technical challenges to be addressed before MRI can be used as a stand-alone modality for SRS treatment.

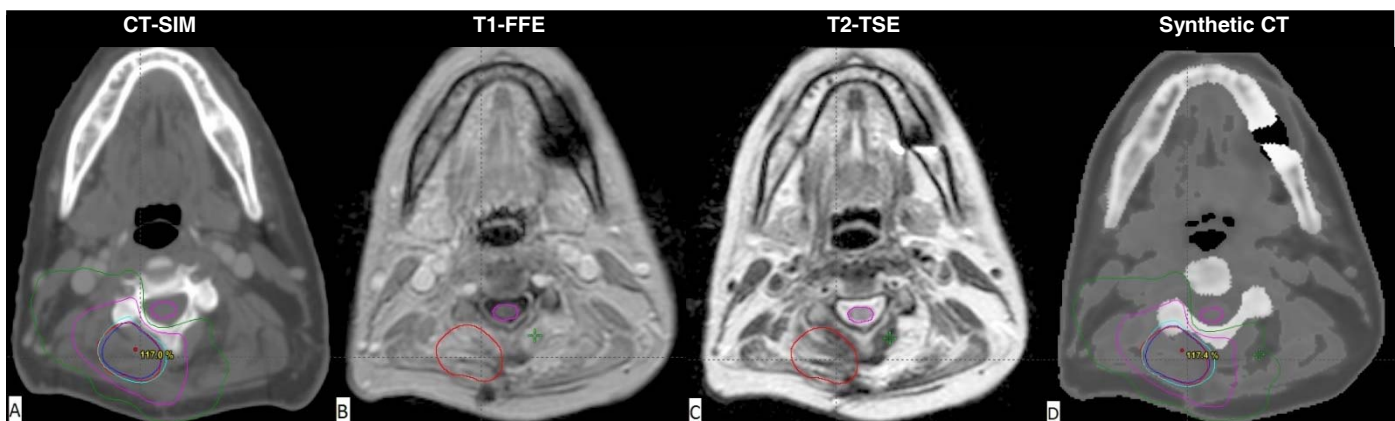


Figure 1. An axial slice with tumor and cord contoured on (a) CT-SIM, (b) T1-FFE, (c) T2-TSE and (d) SynCT. The isodose lines shown on both CT and SynCT images are 90% - prescription isodose line (blue), 80% (cyan), 50%(magenta) and 30%(green) correspondingly.