

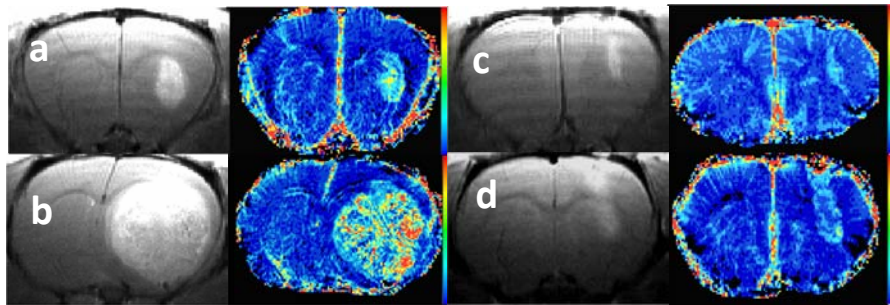
## Gallium maltolate inhibits angiogenesis in brain tumor xenograft model

Kimberly R Pechman<sup>1</sup>, Andrew Lozen<sup>1</sup>, Christopher R Chitambar<sup>2</sup>, and Kathleen M Schmainda<sup>3</sup>

<sup>1</sup>Neurosurgery, Medical College of Wisconsin, Milwaukee, WI, United States, <sup>2</sup>Medicine, Medical College of Wisconsin, Milwaukee, WI, United States, <sup>3</sup>Radiology & Biophysics, Medical College of Wisconsin, Milwaukee, WI, United States

**Target Audience:** neuro-oncologists, neuro-radiologists, neuro-surgeons, brain tumor imaging scientists

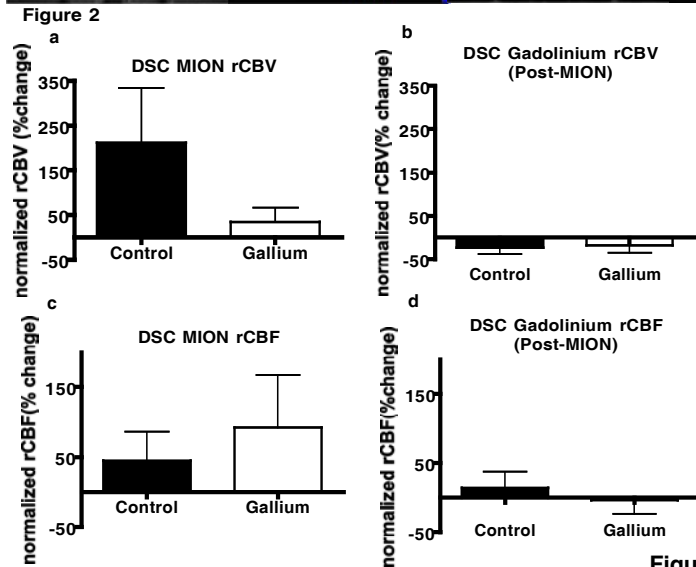
**Purpose:** Glioblastomas, the most common and most aggressive primary brain tumor, have a limited number of treatment options. We have found that gallium maltolate inhibits tumor growth *in vitro* and *in vivo*. Gallium is a group IIIa metal that is incorporated into the cell through the transferrin receptor, and expressed on brain vascular endothelial and glioblastoma cells. Consequently, the goal of this study was to evaluate gallium maltolate in the treatment of a U87 xenograft brain tumor model by evaluating changes in tumor blood volume.



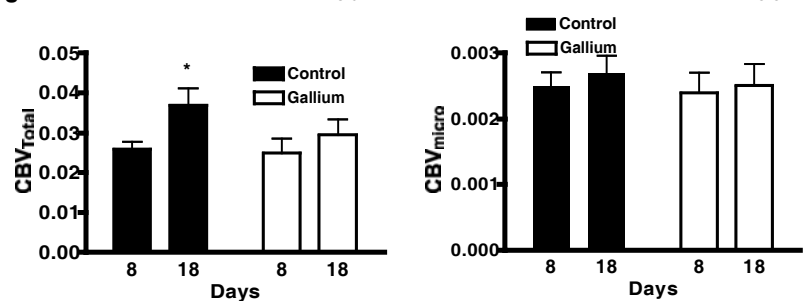
**Methods: Animal Model:** U87 human grade IV astrocytoma cells were cultured, harvested, and 200,000 cells were injected into athymic rats using intracranial, stereotaxic approach. Gallium maltolate (50 mg/kg/day, n=8) or saline (n=7) was given i.v. via an alzet mini pump in the jugular vein. Imaging was performed on days 8 and 18. **MRI:** Images were obtained on a Bruker 9.4 T scanner fitted with a linear transmit coil, and surface receive coil. Steady-state GRE (TR=1.5s, TE=4,10,16,22,28ms, matrix=256) and SE (TR=3s, TEs=15,30,45,60,75, matrix=96) images were collected before and after

injection of MION (5 mg/kg). DSC images were also acquired during the MION injection using a GRE EPI sequence (TE/TR=18ms/1s, FOV=3.5cm, matrix=96). Next, a loading dose of contrast agent (0.1 mmol/kg Omniscan, Nycomed Amersham) was administered to minimize leakage effects that confound rCBV measurements derived from DSC images, which were acquired using GRE-EPI during the gadolinium administration. Post contrast T1 weighted images were acquired using a spin-echo T1-weighted RARE sequence (TE/TR = 12.6ms/1500ms, FOV =3.5cm, matrix =256).

**Analysis:** The DSC was processed to create rCBF and rCBV maps, corrected for any leakage effects and normalized to normal appearing white matter using IB Neuro. The SE and GRE data were fit as a function of TE to a mono-exponential curve for determination of T2 and T2\*. The SE and GRE relaxation rate changes were then determined giving estimates of microvascular and total blood volume.  $((CBV_{micro} \approx \Delta R2 = R2_{MION} - R2_{pre-MION} \quad CBV_{Total} \approx \Delta R2^* = R2^*_{MION} - R2^*_{pre-MION})$ .



**Figure 3** Steady state MION rCBV<sub>Total</sub> Steady State MION rCBV<sub>micro</sub>



**Results:** Figure 1 shows the post Gd-DTPA and MION GRE rCBV maps for a control (a: day 8 and b: day 18) and a treated rat (c: day 8 and d: day 18) at each imaging time point. Treatment shows a trend of DSC rCBV with MION but not Gd-DTPA (Fig 2a, b) compared to saline controls. DSC rCBF with MION showed a trend of higher blood flow (Fig 2c, d) compared to controls. The DSC using MION was performed before the gadolinium in the same exam, and MION was still visible in the large vessels. We propose that this makes the gadolinium DSC more sensitive to the microvessels as the presence of MION may eliminate signal from the large vessels. These data are consistent with the steady state blood volumes shown in Fig 3, where the "total" or GRE CBV is different with treatment but not microvascular CBV.

**Discussion:** Gallium inhibited total blood volume. The trend is not significant for DSC rCBV the large variability in individual rats may be due to the mechanisms of the therapy (iron distribution). For the imaging studies included here tissue markers of transferrin receptors and vascular density (CD31) are being analyzed to provide additional information regarding mechanism of action. **Conclusion:** In general these results demonstrate that the novel gallium maltolate treatment may have antiangiogenic effects in malignant brain tumors. **Acknowledgements:** NIH/NCI RO1 CA082500, Advancing Healthier Wisconsin / MCW Translational Brain Tumor Program.