

# APPARENT DIFFUSION COEFFICIENT AS A POTENTIAL SURROGATE MARKER FOR KI-67 INDEX IN MUCINOUS BREAST CARCINOMA: COMPARISON WITH INVASIVE CARCINOMA OF NO SPECIAL TYPE

Natsuko Onishi<sup>1</sup>, Shotaro Kanao<sup>1</sup>, Masako Kataoka<sup>1</sup>, Mami Iima<sup>1</sup>, Rena Sakaguchi<sup>1</sup>, Makiko Kawai<sup>1</sup>, Tatsuki Kataoka<sup>2</sup>, Yoshiaki Mikami<sup>2</sup>, Masakazu Toi<sup>3</sup>, and Kaori Togashi<sup>1</sup>

<sup>1</sup>Department of Diagnostic Imaging and Nuclear Medicine, Kyoto University Graduate School of Medicine, Kyoto, Kyoto, Japan, <sup>2</sup>Department of Diagnostic Pathology, Kyoto University Graduate School of Medicine, Kyoto, Kyoto, Japan, <sup>3</sup>Department of Breast Surgery, Kyoto University Graduate School of Medicine, Kyoto, Kyoto, Japan

## Target audience

Clinical radiologist and oncologist interested in breast cancer diagnosis/treatment

## Purpose

Mucinous breast carcinoma (MBC), characterized for its high apparent diffusion coefficient (ADC) due to abundant mucin and low cellularity<sup>1</sup>, is dealt with differently from other types of breast carcinoma in breast MR imaging. In pathology, MBC can be classified into 3 subtypes: hypocellular type of pure MBC (major type showing high ADC), cellular type of pure MBC, and mixed MBC (containing non-mucinous “cellular” components consisting of infiltrating carcinoma without extracellular mucin). Better prognostic factors have been reported in pure MBC than in mixed MBC<sup>2,3</sup>, and in hypocellular type pure MBC than in cellular type<sup>4</sup>, which implied the association between cellularity and prognostic factors in MBC. Considering the known inverse correlation between ADC and cellularity<sup>5</sup>, we hypothesized that ADC has association with Ki-67 index (a marker of tumor proliferation used for risk stratification in breast carcinoma) in MBC.

The aims of this study were to prove our hypothesis and evaluate the potential of ADC to stratify MBC as a non-invasive surrogate marker for Ki-67 index.

## Methods

Pathologically confirmed 18 MBC lesions (mucinous group) were retrospectively analyzed. Control group consists of 18 luminal type invasive carcinoma of no special type (NST) lesions matched for histological grade, MR scan date/scanner type. Breast MRI was performed at a 3.0/1.5 T scanner (MAGNETOM Trio/Avant, A Tim System, Siemens AG) with 16/4ch breast coil. Axial bilateral breast diffusion weighted-MRI were obtained using the following parameters: single shot-EPI, TR/TE 7000/62 ms, FOV 330x160 mm, matrix 166x80, thickness 3 mm, NEX 3, 48 slices. ADC was calculated from signal intensity at b values of 0 and 1000 sec/mm<sup>2</sup>. Minimum ADC (ADCmin) and average ADC (ADCave) of the ROIs on the lesion were obtained. Ki-67 and cellularity were histopathologically evaluated. In the context of the St. Gallen consensus 2013, we classified mucinous group into “low Ki-67 mucinous group” (Ki-67 index <14%) and “high Ki-67 mucinous group” (≥14%). Correlation analyses between ADCmin/ave, tumor cellularity and Ki-67 index were evaluated using Pearson’s correlation coefficient. ADC values of high Ki-67 mucinous group and of low Ki-67 mucinous group were compared using Mann-Whitney test. P value < 0.05 was considered as statistically significant.

## Results

In mucinous group, ADCmin showed inverse correlation with cellularity (r=-0.802, p<0.0001) and with Ki-67 index (r=-0.825, p<0.0001) (Table1, Figure2). Correlation between cellularity and Ki-67 index was significant (r=0.633, p=0.005) (Table1). In control group, ADCmin showed inverse correlation with cellularity (r=-0.537, p=0.022), but no significant correlation with Ki-67 index (Table1). There was no significant correlation between cellularity and Ki-67 index (Table1). In both mucinous and control group, ADCave showed correlation pattern similar to ADCmin, but with larger p-value and weaker correlation than ADCmin.

ADCmin of high Ki-67 mucinous were significantly lower than that of low Ki-67 mucinous group (p=0.005, Figure3A). When the cut-off value of ADCmin=1.27 ×10<sup>-3</sup>mm<sup>2</sup>/sec is used, high Ki-67 mucinous group can be identified with a sensitivity of 100% and with a specificity of 93%. Mixed MBC and cellular type of pure MBC showed significantly lower ADCmin than hypocellular type of pure MBC (Figure3B).

## Discussion&Conclusion

Our analysis demonstrated 1) the inverse correlation between ADC and Ki-67 index in MBC and 2) the ability of ADC to classify highly proliferating MBC from low proliferating one. Considering that ADC evaluates whole the lesion non-invasively, while Ki-67 index only evaluates part of the lesion, ADC can be a promising non-invasive surrogate marker for Ki-67 index in the risk stratification of MBC.

## References

- 1.WOODHAMS R, KAKITA S, HATA H, et al. AJR Am J Roentgenol 2009;193:260-6.
- 2.ANAN K, MITSUYAMA S, TAMAE K, et al. Eur J Surg Oncol 2001;27:459-63.
- 3.FENTIMAN IS, MILLIS RR, SMITH P, et al. Br J Cancer 1997;75:1061-5.
- 4.CLAYTON F. Hum Pathol 1986;17:34-8.
- 5.GUO Y, CAI YQ, CAI ZL, et al. J Magn Reson Imaging 2002;16:172-8.

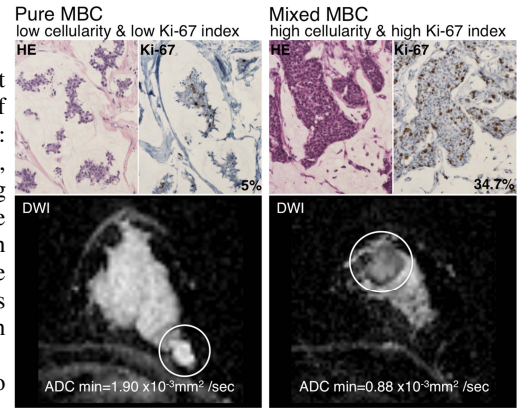


Figure1. Pure MBC & Mixed MBC

	r	P-value
Mucinous group		
ADCmin vs. Cellularity	-0.802	<0.0001
ADCmin vs. Ki-67 index	-0.825	<0.0001
Cellularity vs. Ki-67 index	0.633	0.005
Control group		
ADCmin vs. Cellularity	-0.537	0.022
ADCmin vs. Ki-67 index	0.035	0.892
Cellularity vs. Ki-67 index	0.032	0.899

Table1. Correlation analyses

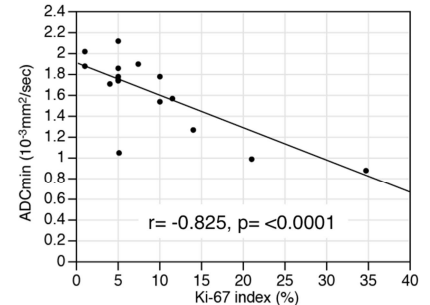


Figure2. mucinous group

Correlation between ADCmin and Ki-67 index

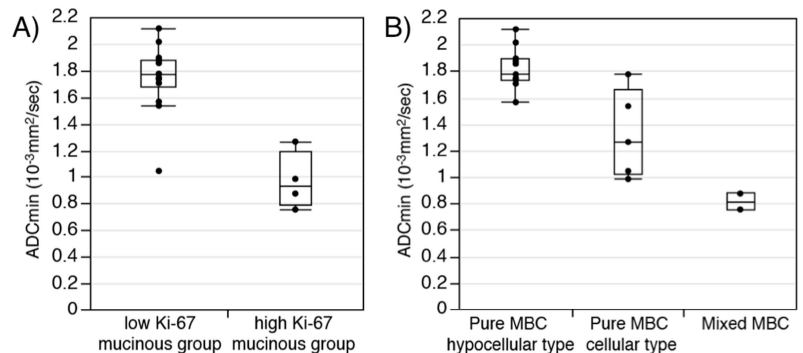


Figure3. mucinous group

Distribution of ADCmin compared between A) high and low Ki-67 mucinous group, B) 3 subtypes