

Virtual Prosthodontic Planning for Oral Rehabilitation: a Pilot Study

Jaafar Abduo¹

¹School of Dentistry, University of Western Australia, 35 Stirling Highway,
Crawley, WA 6009

{jaafar.abduo@uwa.edu.au}

Abstract. This report illustrates the application of digital work-up as a dental treatment planning tool for prosthodontic patients. A clinical case was selected according to the prosthodontic needs. The conventional work-up was performed in accordance with the traditional prosthodontic criteria. The digital work-up was comprised of scanning of the pre-treatment models followed by restoring the deficient teeth and replacement of the missing teeth. The two diagnostic work-up models were compared in relation to the modified teeth, soft tissue and occlusal contacts. It appears that the digital work-up is a feasible option and allows quantitative and qualitative evaluation of the dental treatment impact.

Keywords: diagnostics, work-up, dental rehabilitation, dental prosthesis, image registration

1 Introduction

Many patients suffer from dentally related problems such as missing or deficient teeth, disorganized dental arches, or unacceptable tooth contour. Consequently, dental clinicians commonly encounter situations where alteration in tooth contour is indicated. Prosthodontics is the dental specialty that deals with the diagnosis, treatment planning, rehabilitation and maintenance of the oral function, comfort, appearance and health of these patients [1]. In many instances, prosthodontic treatment necessitates irreversible alterations to the remaining hard tissues. In order to justify such alterations, significant benefits of the treatment should be apparent. Therefore, to reach a satisfactory outcome, comprehensive diagnostic planning and work-up should be conducted before embarking on the definitive prosthodontic rehabilitation. Further, the diagnostic work-up allows visualizing the outcome and helps in deciding on the most adequate treatment plan for a specific case.

For dental abnormalities, the conventional prosthodontic protocol involves obtaining diagnostic models that represent the patient's dental arches upon which the diag-

nostic work-up can be performed. The complexity of the treatment ranges from single or few teeth restorations, to the complete dentition. The planned treatment can involve altering the tooth morphology, altering the vertical dimension of occlusion, reorganizing the occlusion and restoring all the teeth of at least one dental arch [2, 3]. In the dental laboratory, the diagnostic work-up involves preparing dental models, reducing part of the teeth and building the contours with wax [2, 4]. The Ideal diagnostic work-up should be applicable, transferable, conservative and aesthetic. Three critical criteria must be fulfilled. (1) The dental modifications should preserve the emergence profile. Therefore, although the dental modifications can be significant at the incisal or occlusal surfaces, they should be less prominent closer to the soft tissues. Further, excessive reduction should be avoided as this can affect the health of dental pulp. (2) The soft tissues should not be altered as they will aid in transferring the diagnostic information. (3) The occlusal contacts should be accurately located against the opposing teeth.

The outcome of this “trial” treatment can be demonstrated to the patient for approval or suggestion of any further modifications. In this manner, the patient will be more informed of the final outcome. Subsequently, the diagnostic work-up will facilitate the “outcome based treatment” which implies that the magnitude of irreversible alteration to the teeth is dictated by the final outcome rather than the initial patient presentation [5, 6]. This is accomplished clinically by preparing the teeth according to the anticipated final prostheses design as determined by the diagnostic work-up. In addition, provisional prostheses can be fabricated following the diagnostic work-up and, should the provisional outcome satisfy the patient, the definitive prostheses will be fabricated to resemble the diagnostic work-up [5, 6].

More recently, with the advent of laser scanning, virtual planning, rapid prototyping and computer-aided design and manufacturing, it is hypothesized that diagnostic planning can be accomplished in time-efficient and well-controlled fashion. This pilot study introduces an additional application of computerized technologies that allows virtual alteration of dental morphology. It is envisioned that the digitally modified dentition can be used by the dental clinician and technician as a guide for the final prosthesis. In addition the study evaluates the potential of digital work-ups in producing acceptable outcome and compares the accuracy digital work-up to conventional work-up.

2 Materials and Methods

Human research ethics approval was obtained from the Human Research Ethics Committee of the University of Western Australia (RA/4/1/5097). A clinical case that requires diagnostic work-up prior to prosthetic treatment was selected. A total of 9 teeth in the maxillary arch required treatment. 6 teeth required restoration and 3 teeth required replacement. Maxillary and mandibular dental impressions were taken by irreversible hydrocolloid impression material (Alginate, GC America, IL, USA). The impressions were poured by dental stone (Buff Stone, Adelaide Moulding & Casting Supplies, South Australia, Australia). These models comprised the pre-treatment situation. Each model was duplicated twice by reversible hydrocolloid material (Mega-

feel, MKM System, Haanova, Slovakia). One set of models were treated by conventional work-up and the other by digital work-up.

2.1 Conventional Work-Up

The actual models were articulated on semi-adjustable articulator (Whip Mix, Louisville, KY, USA) and modified by trimming and contour alterations with inlay wax (VITA Zahnfabrik, Bad Sackingen, Germany). The required work-up modifications were even bilateral occlusal contacts, symmetry between the two sides, and natural teeth morphology (Fig. 1).

The conventional work-up models were scanned by Micro-CT scanner (SkyScan, Bruker, Kontich, Belgium). Virtual 3D Stereolithography (STL) images of the maxillary and mandibular models were constructed from the Digital Imaging and Communication Medicine (DICOM) images with the aid of DICOM viewing program (In-Vesalius, Renato, Archer Technology of Information Centre, Campinas, São Paulo, Brazil).

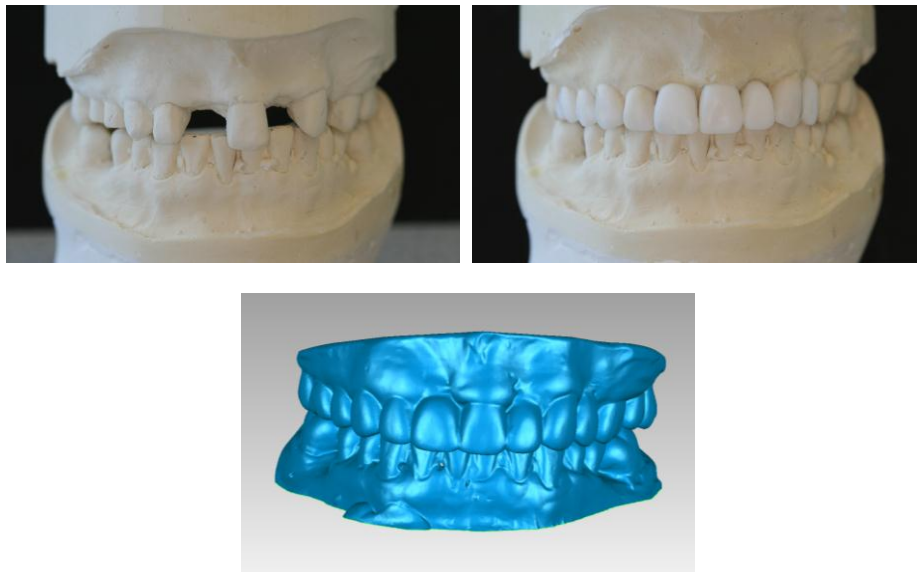


Fig. 1. Top left: Pre-treatment models. Top right: Conventional work-up models. Bottom: Scanned conventional work-up models.

2.2 Digital Work-Up

The maxillary and mandibular pre-treatment models were scanned by the Micro-CT scanner and STL images were constructed. A 3D rendering software package (Geomagic Studio, Raindrop Geomagic Inc., Research Triangle Park, NC, USA) was used to complete the digital work-up. The maxillary and mandibular models were

virtually articulated by using the point-to-point alignment feature of Geomagic Studio. To obtain aesthetic tooth morphology, physiological teeth moulds (Phonares Teeth, Ivoclar Vivadent AG, Schaan, Liechtenstein) were scanned by the Micro-CT scanner. Each virtual tooth was fitted manually on the model with the aim of obtaining ideal teeth arrangement, emergence profile, symmetry and aesthetics. This is followed by ensuring ideal occlusal contacts exist. The virtual tooth alignment involved size alteration, rotation and translation (Fig. 2).

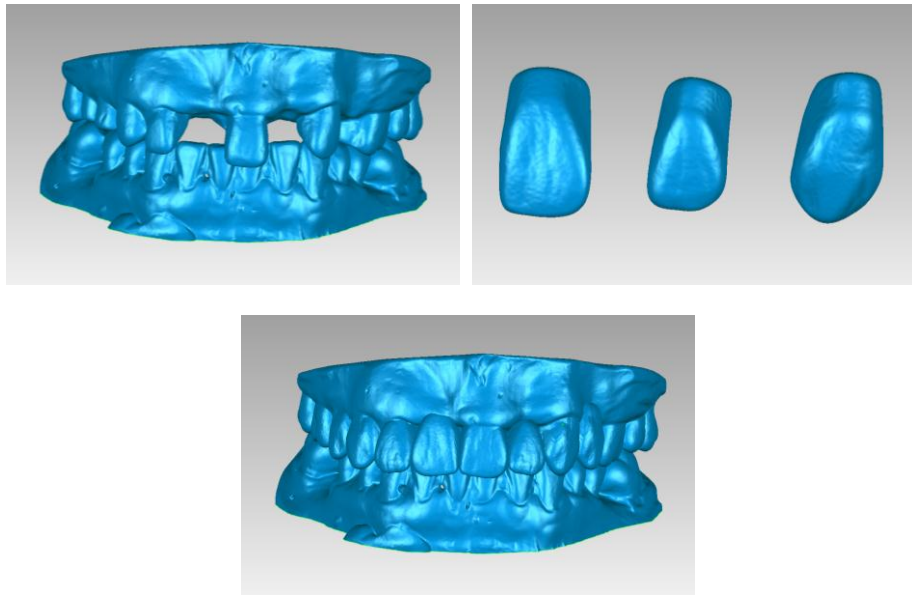


Fig. 2. Top left: Scanner pre-treatment models. Top right: Scanned physiological teeth. Bottom: Digital work-up models.

2.3 Analysis

The comparison between each treatment protocol was performed digitally at three levels; (1) tooth level, (2) soft tissue level, and (3) occlusion level. For the tooth level, alterations in the contour are expected as long as the emerging portion of the tooth is minimally affected and excessive reduction is avoided. Since the soft tissues are used as landmarks, they should not be altered. The occlusal contacts should be well-distributed and of comparable magnitude.

To compare the tooth morphology, each work-up models was superimposed on the pre-treatment model by the process of image registration. The image registration is comprised of point-to-point registration followed global registration. Eventually, the models were aligned through the best fit principles according to Iterative Closest Point (ICP) algorithm [7, 8]. This step aimed to evaluate the amount of tooth modifications that will be applied by each diagnostic work-up. The discrepancy distribution between the superimposed models was illustrated in colour-difference maps to locate

the dimensional positive and negative deviations. The threshold value was set at 2 mm. The warm colours represent positive deviations, while the cold colours represent negative deviations. The green colour indicates an optimal match.

The soft tissue band closer to the teeth was trimmed from each model and superimposed on the pre-treatment model. In addition to colour-difference maps generation, the average 3D Euclidean Distance (ED) of 2000 random points of the common surfaces of the two models was calculated. The absolute deviation values were used to solely quantify the deviation magnitude. Therefore, the less mean distance between the models, the better the accuracy of the diagnostic work-up.

The occlusal contacts were measured by Meshlab Software (Visual Computing Lab, University of Pisa, Italy). This was applied by measuring the distance between the occlusal surface of each maxillary model and mandibular model. The threshold value was set at 1 mm. According to the distance, the occlusal surface of each maxillary model was colour coded. The red colour indicates contact and the blue colour indicates lack of contact. Table 1 illustrates the comparison criteria of each level.

3 Results

3.1 Teeth Comparison

Following the image registration of each work-up model, the unrestored teeth were closely matched. This confirmed the accuracy of the registration process.

In relation to the conventional work-up (Fig. 3), the occlusal plane and teeth alignment were even. The symmetry between each side was observed. In general, the restored teeth were enlarged. Emergence profile was preserved and the teeth gradually enlarged toward the occlusal and incisal surfaces, where the enlargement was most excessive. The central incisor had more reduction (about 1 mm) on its facial aspect. This amount of reduction appears to be within the clinical acceptability.

The digital work-up (Fig. 4), had similar presentation in relation to occlusal plane, teeth alignment and symmetry. In general, the modified teeth exhibited greater definition than conventional work-up which can contribute to more aesthetic appearance. The emergence profile and enlargement features are similar to the conventional work-up. The amount of reduction on the facial aspect of the central incisor was less prominent than for the conventional work-up.

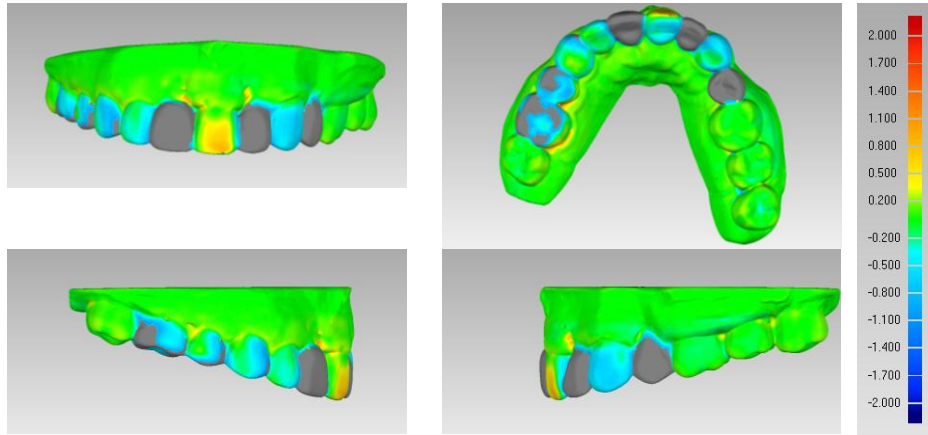


Fig. 3. Colour-difference maps of the conventional work-up model after superimposition on pre-treatment model.

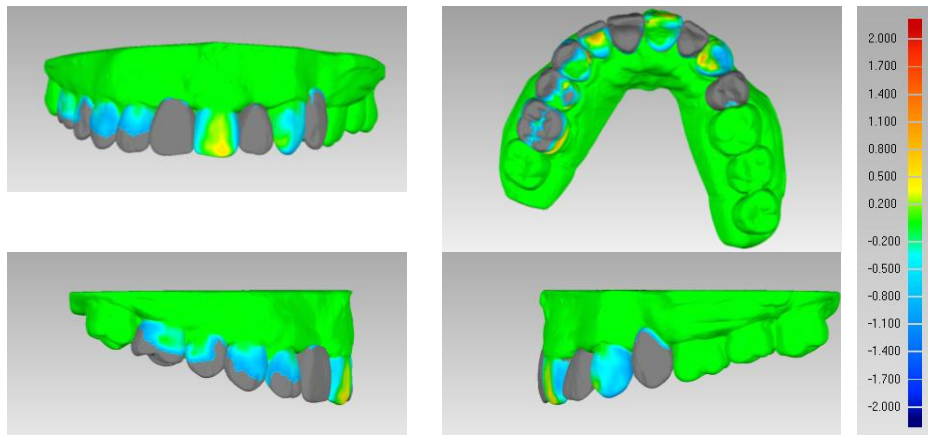


Fig. 4. Colour-difference maps of the digital work-up model after super-imposition on pre-treatment model.

3.2 Soft Tissue Comparison

The average ED between the pre-treatment and the conventional work-up models was 0.152 mm (SD = 0.06 mm). Greater average ED value was observed between the pre-treatment and the digital work-up models (0.779 mm, SD = 0.856 mm). This indicates that alteration of the soft tissue contour by the conventional work-up is less than the alteration by the digital work-up. The colour-difference maps illustrated that greater discrepancy magnitudes exist closer to the teeth for digital work-up model (Fig. 5).

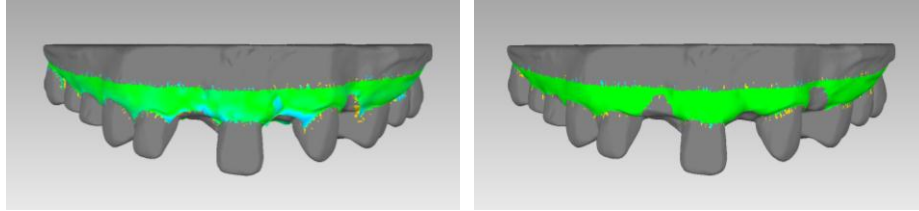


Fig. 5. Colour-difference maps of segmented soft tissue band following superimposition on pre-treatment model. Left: Conventional work-up model. Right: digital work-up model.

3.3 Occlusion Comparison

For the two work-up models, all the opposed teeth were in contact with the mandibular teeth (Fig. 6). It appears that the contact for the conventional work-up was more even in magnitude and distribution. Still, both of them improved the occlusal contacts in comparison with the pre-treatment model.

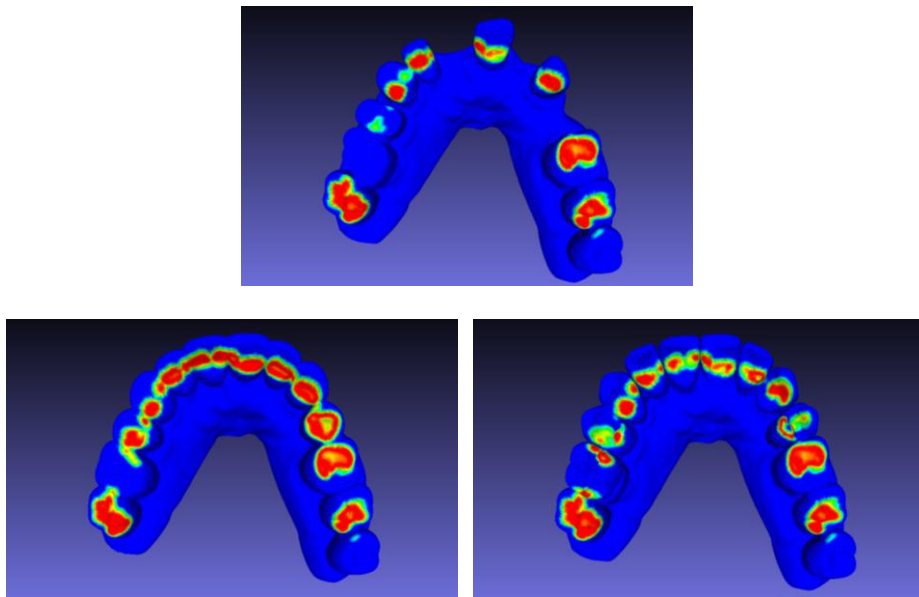


Fig. 6. Occlusal contacts on the maxillary teeth. Top: Pre-treatment model. Bottom left: Conventional work-up model. Bottom right: Digital work-up model.

4 Discussion

Today, with patients' high aesthetic expectations, the possible high standard of treatment and the risk of legal litigations, more emphasis has to be placed on the diagnostic work-up to allow the patient to visualize the final outcome. On the basis of accurate planning, the patient will be able to provide consent after being fully informed by observing the diagnostic work-up outcome. However, it is common for the clinician to omit the diagnostic work-up procedure, or to leave it to dental technicians to decide. The reason behind this is that the conventional diagnostic work-up is a time consuming process and requires special training and artistic abilities. The technicians might have the expertise in developing natural looking dental morphology; however, they commonly lack the visualization of the biological parameters. Therefore, the predictable application of the diagnostic work-up is limited to clinicians with a special level of training.

It is speculated that the introduced digital work-up approach will alleviate many of the difficulties associated with conventional work-up. In addition, digital work-up exhibits several advantages that justify its routine application. For example, the process is completed virtually and requires no physical material which has significant economical implication. The pre-treatment models are not altered and can be preserved in the patient record. The applicability and efficiency of this technique are further augmented by automation of the tooth modification process. The evaluation of the implications of the diagnostic work-up is a useful feature to analyze the feasibility of the proposed treatment [9]. It is expected that this feature will enhance patient's communication and reviewing dental modifications with relative ease.

In the era of digital dentistry, it is more likely in the future that digital dental impression will become popular [10]. Therefore, models manipulation will be purely virtual, which will omit the conventional impression taking, model pouring and subsequent scanning. To enhance the applicability of the digital work-up, actual models can be produced by rapid prototyping technology. The printed model is envisioned to provide direct guidance to the involved dental clinician and technician.

The digital protocol appears to be promising and very comparable to conventional protocol. In fact the high tooth definition implies that the computerized protocol can produce more aesthetic treatment planning. However, the tooth-soft tissue junction appears to be more affected with the digital work-up than conventional work-up. This was illustrated by the greater ED for the digital work-up. Certainly, greater soft tissue accuracy is always desirable, although the clinical significance of the reported discrepancies cannot be confirmed.

5 Conclusion

This pilot study confirms the applicability of digital treatment planning and tooth modifications for patients presenting with deficient or missing teeth. In addition, the proposed approach allows the quantitative and qualitative diagnostic evaluations of the impact of dental treatment on the existing dentition. In relation to accuracy, the conventional protocol is more accurate at soft tissue and occlusion levels; however this observation should be validated with greater sample number.

Acknowledgements. The author thanks Professor Mohammed Bannamoun for his guidance on the project. The author acknowledges the facilities, the scientific and technical assistance of the National Imaging Facility at the Centre for Microscopy, Characterization & Analysis, University of Western Australia, a facility funded by the University, State and Commonwealth Governments. This paper is part of a project supported the Research Development Award from the University of Western Australia and the Raine Priming Grant.

References

1. The Glossary of Prosthodontic Terms. *J. Prosthet. Dent.* 94, 10-92 (2005)
2. Keough, B.: Occlusion-Based Treatment Planning for Complex Dental Restorations: Part 1. *Int. J. Periodontics. Restorative. Dent.* 23, 237-247 (2003)
3. Besimo, C.E., Rohner H.P.: Three-Dimensional Treatment Planning for Prosthetic Rehabilitation. *Int. J. Periodontics. Restorative. Dent.* 25, 81-87 (2005)
4. Abduo, J.: An Innovative Prosthesis Design for Rehabilitation of Severely Mutilated Dentition: a Case Report. *J Adv. Prosthodont.* 3, 37-42 (2011)
5. Magne, P., Belser, U.C.: Novel Porcelain Laminate Preparation Approach Driven by a Diagnostic Mock-Up. *J. Esthet. Restor. Dent.* 16, 7-16 (2004)
6. Gurel, G.: Porcelain Laminate Veneers: Minimal Tooth Preparation by Design. *Dent. Clin. North. Am.* 51, 419-431 (2007)
7. Williams, J., Bennamoun, M.: Simultaneous Registration of Multiple Corresponding Point Sets. *Comput. Vis. Image. Und.* 81, 117-142 (2001)
8. Mian, A.S., Bennamoun, M., Owens, R.: Three-Dimensional Model-Based Object Recognition and Segmentation in Cluttered Scenes. *IEEE. T. Pattern. Anal.* 28, 1584-1601 (2006)
9. Davis, G.R., Tayeb, R.A., Seymour, K.G., Cherukara, G.P.: Quantification of Residual Dentine Thickness Following Crown Preparation. *J. Dent.* 40, 571-576 (2012)
10. van Noort, R.: The Future of Dental Devices is Digital. *Dent. Mater.* 28, 3-12 (2012)