

ORIGINAL
ARTICLE

The Accuracy of Ultrasonographic Examination of Injured Posterior Cruciate Ligament

Chung-Yuan Wang¹, Tiffany T.F. Shih², Hsing-Kuo Wang³, Ya-Ning Chiu⁴, Tyng-Guey Wang^{4*}

The purpose of this retrospective study was to define the accuracy of sonographic examination compared with magnetic resonance imaging (MRI) in detecting tears of the posterior cruciate ligament (PCL). Thirty-five patients with traumatic knee injuries fulfilling all the criteria were selected from 531 patients referred for sonographic examinations during 2003 to 2005 in the university hospital. The presence or absence of PCL injury was determined by MRI. Torn PCL was indicated when a PCL diameter (anterior-posterior dimension) greater than 10 mm, or a wavy or indistinct posterior PCL margin was found on sonographic examination. Among the 35 patients, 13 were found to have PCL tears on sonographic examination. Ten of these tears were also diagnosed by MRI. Two of 22 patients with normal PCL on sonographic examination were found to have PCL tears following MRI. There was significant agreement between MRI and sonography. We found that sonographic examination could accurately detect tears of the PCL and can be utilized as the first choice of imaging modality for patients with PCL injuries.

KEY WORDS — injury, internal derangement, posterior cruciate ligament, sonography

■ *J Med Ultrasound* 2009;17(4):187–192 ■

Introduction

High-resolution ultrasound has been routinely used to detect knee joint diseases for over 20 years [1–3]. This technique is widely considered to be efficacious for detecting damage to the superficial

tendons and ligaments such as the patellar tendon and the medial as well as the lateral collateral ligament [4–6]. It is also used to detect meniscus lesions, although its accuracy is still debated [7–9].

Suzuki et al [10] claimed that the anterior cruciate ligament could be visualized directly during



ELSEVIER

Received: December 17, 2008 Accepted: March 2, 2009

¹Department of Physical Medicine and Rehabilitation, Pingtung Christian Hospital, Ping Tung, ²Department of Medical Imaging, National Taiwan University Hospital, School of Medicine, National Taiwan University, ³Department of Physical Medicine and Rehabilitation, National Taiwan University Hospital, School of Physical Medicine, National Taiwan University, and ⁴Department of Physical Medicine and Rehabilitation, National Taiwan University Hospital, School of Medicine, National Taiwan University, Taipei, Taiwan.

*Address correspondence to: Tyng-Guey Wang, Department of Physical Medicine and Rehabilitation, National Taiwan University Hospital, 7 Chang-Shan South Road, Taipei, Taiwan. E-mail: tgw@ntu.edu.tw

sonographic examination. However, indirect or dynamic techniques are generally applied in conjunction with sonography to diagnose anterior cruciate ligament tears [11–13]. In contrast, sonography can clearly depict the posterior cruciate ligament (PCL) from the posterior aspect of the knee where it appears as a hypoechoic to anechoic band [14]. Although several studies have reported significant thickening and irregularities of the posterior margin associated with tears of the PCL [15–17], none have evaluated the diagnostic accuracy of sonography in detecting tears of the PCL. The aim of this study was to investigate the accuracy of high-resolution ultrasound in detecting tears of the PCL.

Materials and Methods

All data were obtained by a retrospective review of medical records. From January 2003 to December 2005, a total of 531 subjects undergoing sonographic examination for knee injuries resulting from sports, falls or traffic accidents were selected from the rehabilitation department of a university hospital. In addition to a history of knee trauma, patients included in the study must also have undergone a knee magnetic resonance imaging (MRI) examination following sonographic examination. All sonographic examinations were performed by a member of the author group, an expert in sonography (with 7 years of experience in musculoskeletal sonography). The ethic committee of our institution approved this study and we received permission from patients to publish their sonographic images. Forty patients were initially included, and the reports of the MRI images of these 40 patients were read. Five patients were excluded from this study since the MRI reports recorded “suspected” PCL tears. The images of these five patients were re-read by a board certified radiologist with 20 years of experience. The radiologist could not definitely diagnose the status of the PCL with the available images. These five cases were excluded and a total of 35 patients were included in the study.

Sonography was performed using the ATL-HDI 5000 (Advanced Technology Laboratories Inc., Bothell, WA, USA) or Xario SSA-660A (Toshiba Inc., Tokyo, Japan). Ultrasound, with a 7–14 MHz linear transducer. During examination, patients were in the prone position, with knees extended. The probe was positioned over the posterior knee for longitudinal scanning. One end of the probe was placed on the intercondylar tibial area and the other end was internally rotated around 15–30 degrees to the lateral margin of the femoral condyle. The clearest possible image of the PCL was obtained by adjusting the transducer [14].

The examiner determined whether the posterior margin of the PCL was loose or indistinct, and measured the thickest anterior-posterior diameter of the PCL (usually at the tibial spine). The criteria for a torn PCL under sonography were as described in the studies conducted by Hsu et al [15] and Cho et al [17]. These criteria were: (1) a maximum anterior-posterior PCL diameter greater than 10 mm (Fig. 1), or (2) local indentation of the posterior margin or a wavy or indistinct posterior PCL margin (Figs. 2 and 3).

MRI studies were performed using a 1.5-T magnet (Signa, GE Healthcare, Milwaukee, WI, USA or Sonata, Siemens Medical Solutions, Erlangen, Germany) and a commercially available circumferential extremity coil. Imaging was performed as follows: coronal multiplanar gradient recall T2-weighted images (TR range/TE range 500–550/18–20; flip angle, 20°), sagittal spin-echo T1-weighted images (TR range/TE range, 500–600/14–18), and sagittal fast spin-echo T2-weighted images (TR range/effective TE range, 4,000–5,000/80–120; echo-train length, 8). Slice thickness was 4 mm on sagittal images and 4 mm on coronal images. The interslice gap was 1 mm. The matrix size was 256 × 192, and the field of view was 14–16 cm.

MRI indicators of complete PCL tear included (1) failure to identify the PCL, (2) amorphous high signal intensity in the region of the PCL on T1- and T2-weighted images without definable ligamentous fibers, and (3) visualization of PCL fibers with

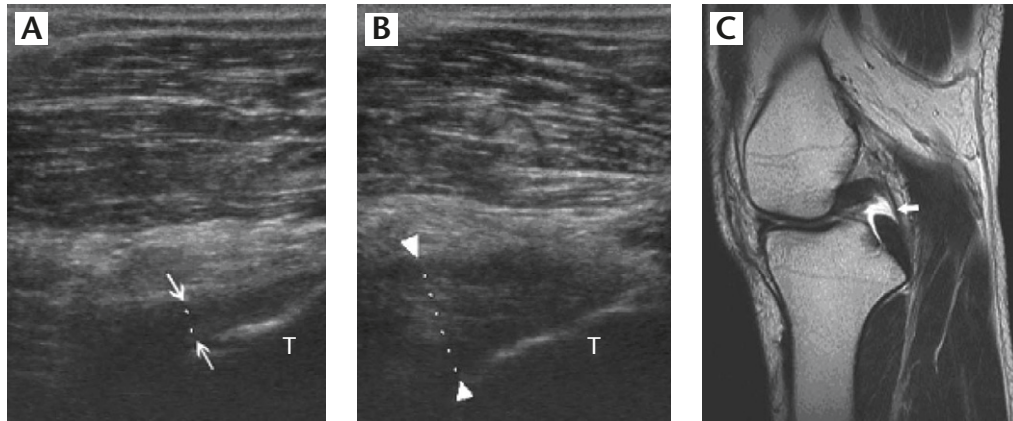


Fig. 1. Sonograms and magnetic resonance imaging (MRI) from a 21-year-old man who had a torn left posterior cruciate ligament (PCL) caused by a traffic accident. The examination date was 20 days after the accident. (A) The right PCL appeared as a hypochoic band (arrow), with the greatest anterior-posterior diameter equal to 7.4 mm. (B) Sonogram of the torn left PCL (arrowhead) revealed increased diameter (11.3 mm). (C) MRI of torn PCL (open arrow). T=tibia.

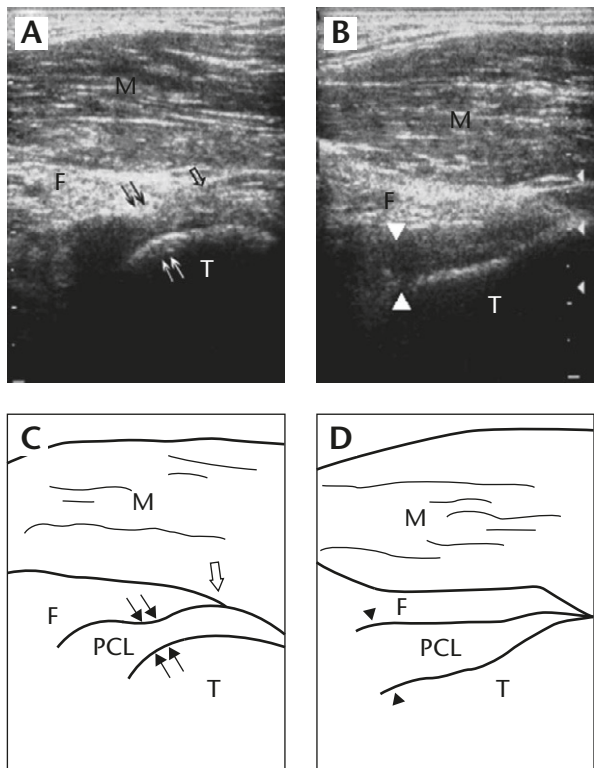


Fig. 2. Sonograms from a 34-year-old man who had a torn left posterior cruciate ligament (PCL) caused by a traffic accident. The examination date was 8 months after the accident. (A) Sonogram of the torn left PCL with an indentation (arrow) and blurring posterior margin at the tibial insertion (open arrow). (B) The normal right PCL (arrowhead) appeared as a hypochoic band, with the greatest anterior-posterior diameter equal to 7.1 mm. (C) Schematic diagram of (A). (D) Schematic diagram of (B). S=subcutaneous tissue; M=muscle; F=fat pad; T=tibia.

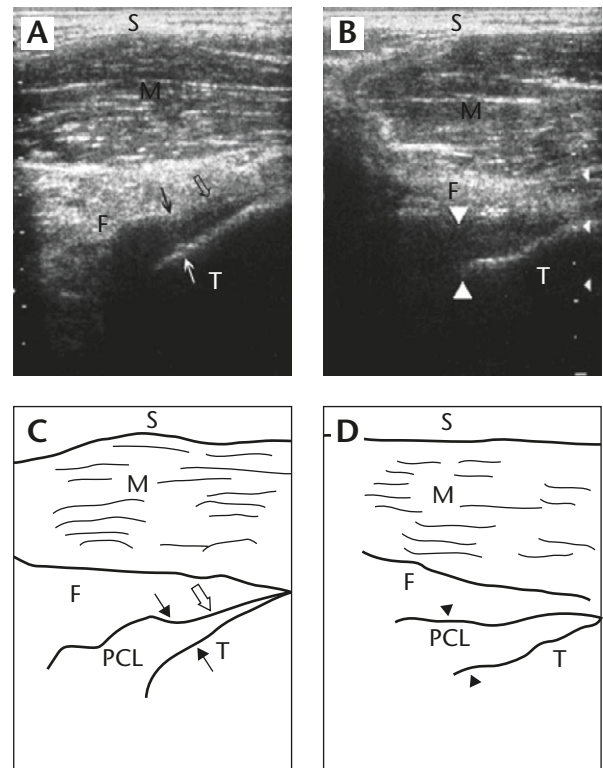


Fig. 3. Sonograms from a 25-year-old man who had a torn right PCL caused by a traffic accident. The examination date was 10 months after the accident. (A) An indentation of the posterior margin (arrow) with tibial site thinning in the right knee (open arrow). (B) The left PCL appeared as a hypochoic band (arrowhead), with the greatest anterior-posterior diameter equal to 7.2 mm. (C) Schematic diagram of (A). (D) Schematic diagram of (B). S=subcutaneous tissue; M=muscle; F=fat pad; T=tibia.

focal discrete disruption of all visible fibers. Partial PCL tears or intra-substance injuries did not meet these criteria but may have demonstrated significant abnormal signal intensity within the substance of the PCL, or caused some fibers to appear intact and discontinuous.

Results

Twenty-six of 35 participants were male and nine were female. The average age was 29.2 ± 9.6 years, ranging from 17 to 55 years. Knee injuries were caused by the following: falls (9 subjects), traffic accidents (14 subjects), and sporting injuries (12 subjects). The average time from the initial injury to sonographic examination was 154 days (range, 2–1,008 days), and the average time between sonographic examination and MRI was 29 days (range, 2–86 days).

Thirteen patients were diagnosed with PCL tears on sonographic examination. Of the patients diagnosed with PCL tears by sonographic examination, five met the criteria of having a PCL diameter greater than 10 mm, and eight met the criteria of exhibiting an irregular posterior PCL margin. An identical diagnosis was made after MRI in 10 of these 13 individuals. Two patients whose PCL appeared normal on sonogram were diagnosed with PCL tears following MRI (Table). By using kappa statistical analysis, there was significant agreement between MRI and sonographic examination ($p = 4.41 \times 10^{-5}$).

Among these 35 patients, five had inconsistent results on MRI and sonography. Three patients were

diagnosed with PCL tears by sonography but had normal PCL by MRI. In one of these patients, the posterior margin of the PCL was absent on sonography and subsequent arthroscopy confirmed PCL tear. The other two patients exhibited PCL diameters of greater than 10 mm, (11.4 mm and 12.0 mm) as detected by sonography. However, MRI revealed intra-substance degeneration of the PCL with fine continuity in both patients and neither underwent arthroscopy.

Two patients were diagnosed with normal PCL by sonography as opposed to a partial tear diagnosis by MRI. One patient had a PCL diameter of 8.7 mm in the injured knee and 6.3 mm in the non-injured knee. The other patient had PCL diameters of 6.0 mm and 5.6 mm in the injured and non-injured knees, respectively. In both patients the posterior margin of the PCL was normal on sonography.

Sixteen of the 35 patients ultimately had arthroscopy and another four patients had surgery. Only one patient was incorrectly diagnosed by MRI as determined following arthroscopy. This patient was diagnosed with a torn PCL during sonographic examination due to the irregular posterior margin. Although the MRI diagnosis was normal, the arthroscopy finding was consistent with the initial sonographic diagnosis.

Discussion

We found sonography to be reliable in detecting tears of the PCL. Sonograms of the PCL were first described in the 1980s [14,16]. The PCL appears as a hypoechoic band upon posterior scanning of the knee joint due to the presence of anisotropy, which is different from hyperechoic images of other ligaments. Cho et al [17] first described sonogram changes associated with tears of the PCL. They compared the sonograms of 15 patients with PCL injuries to those of 13 individuals with normal PCLs. They noted that torn PCLs exhibited heterogeneous echoes, indistinct posterior margins and increased thickness (>10 mm). Similar findings were noted in other studies [15,16]. In the present

Table. The accuracy of sonographic examination in detecting posterior cruciate ligament (PCL) tears (magnetic resonance imaging [MRI] as gold standard)*

	MRI(+)	MRI(-)
Sono(+)	10	3
Sono(-)	2	20

*Sensitivity $10/12 = 83.3\%$, specificity $20/23 = 87.0\%$, accuracy $30/35 = 85.7\%$. MRI(+) = PCL tears on MRI study; MRI(-) = PCL intact on MRI study; Sono(+) = PCL tears on sonogram; Sono(-) = PCL intact on sonogram.

study, we found that sonographic examination had a sensitivity of 83.3%, a specificity of 87.0% and an accuracy of 85.7% in detecting PCL tears when MRI was taken as the gold standard. Therefore, sonography would appear to be a reliable diagnostic tool for detecting PCL tears. However, since only those who also underwent MRI were included in the analysis, true sensitivity might be problematic. In addition, specificity may also be criticized if any of the cases which were positive on sonographic examination did not undergo MRI. Therefore, we used kappa statistical analysis to investigate the percentage of agreement between these two methods, and found that there was significant agreement between MRI and sonography.

The accuracy of MRI in diagnosing PCL injury is highly satisfactory in most of the published literature [18–20]. Compared with arthroscopy, MRI has the advantage of being non-invasive and practical in detecting PCL injury. Therefore, instead of arthroscopy, we chose MRI as the gold standard.

The diagnostic criteria for torn PCL in previous studies [15–17] included increased thickness and indistinct margin or indentation of the surface. In the study by Cho et al [17], the criteria for a torn PCL included a PCL diameter greater than 10 mm. All the subjects in their study with a torn PCL were found to have a PCL diameter greater than 10 mm. This increased diameter is a consequence of PCL swelling, bleeding and fluid collection around the ligament [17,21]. In another study, Hsu et al [15] found that PCL diameter was increased in injured compared with non-injured knees within a week of the initial injury. However, none of the subjects with torn PCLs had a PCL diameter greater than 10 mm, and the diagnoses were confirmed by arthroscopy. Miller [16] examined patients with both acute and chronic PCL injuries. Torn PCL diameters ranged from 5.4 mm to 12.1 mm. The authors, however, did not specify how many patients had PCL diameters greater than 10 mm. In the present study, we found that only five patients had a PCL diameter greater than 10 mm, while eight patients were diagnosed with posterior margin irregularities. Therefore, a PCL diameter greater than 10 mm should not be

the only criterion for the detection of torn PCLs. Besides, if not acutely injured, these patients may not exhibit swelling or bleeding, but may have more obvious signs of a partial collapse of the PCL.

Visualization of the PCL from the posterior aspect of the knee may be impeded by the posterior margin of the femur. As for the anatomic spatial relationship, the PCL is clearly observed from the adherent area of the tibial eminence but not from the femoral side. If the injury is to the femoral side, the diagnosis of PCL tear by sonography might be affected. However, this can be partially overcome by the use of a curved probe [16]. In previous studies, 9–27% of PCL tears were to the femoral side [22,23]. This percentage varied with injury cause. If the injury is a complete tear on the femoral side, complete contraction of the PCL may result in a greater PCL diameter or an irregular collapse of the posterior margin. However, with a partial PCL tear, such a diagnosis is difficult.

Selection bias in a retrospective study is inevitable. Patients who were highly suspicious of having an internal knee injury by clinical physicians were referred for sonographic examination or MRI analysis. Therefore, the distribution of normal patients and injured patients may not have been even. However, participants selected for this study had knee joint injuries rather than PCL injuries per se. Thus, the likelihood of selection bias may not be so severe. The finding that 13 patients had PCL tears and 22 patients had normal PCLs would appear to be an acceptable distribution.

There may have been some technical errors pertaining to both sonographic and MRI examinations in this retrospective study. However, the sonographic staff had 7 years' experience in PCL scanning, and each image was examined by the same person. In addition, five MRI cases were excluded because of diagnostic uncertainty with the available images. Hence, some difficult to diagnose cases may have been excluded, thereby increasing the overall accuracy of diagnosis.

As only 13 patients were found to have PCL tears, further analysis regarding tear position and type (i.e. complete or partial tear) was not possible. PCL

tears are not commonly associated with knee joint diseases. In a previous study, 47 of 1,950 patients were found to have complete or partial PCL tears following MRI [24]. The cases included in our study were selected from a cohort of around 500 patients who underwent knee joint examinations. Additional cases are needed to further analyze the different types of PCL tears in detail.

Sonographic examination has sufficient accuracy to detect tears of the PCL. Therefore, sonographic examination could be utilized as the first choice of imaging modality in patients with suspected PCL injuries.

References

1. Khan Z, Faruqui Z, Ogyunbiyi O, et al. Ultrasound assessment of internal derangement of the knee. *Acta Orthop Belg* 2006;72:72-6.
2. Court-Payen, M. Sonography of the knee: intra-articular pathology. *J Clin Ultrasound* 2004;32:481-90.
3. Friedman L, Finlay K, Popovich T, et al. Sonographic findings in patients with anterior knee pain. *J Clin Ultrasound* 2003;31:85-97.
4. Cook JL, Ptaznik R, Kiss ZS, et al. High reproducibility of patellar tendon vascularity assessed by colour Doppler ultrasonography: a reliable measurement tool for quantifying tendon pathology. *Br J Sports Med* 2005;39:700-3.
5. De Maeseneer M, Lenchik L, Starok M, et al. Normal and abnormal medial meniscocapsular structures: MR imaging and sonography in cadavers. *AJR Am J Roentgenol* 1998;171:969-76.
6. Lee JI, Song IS, Jung YB, et al. Medial collateral ligament injuries of the knee: ultrasonographic findings. *J Ultrasound Med* 1996;15:621-5.
7. Najafi J, Bagheri S, Lahiji FA. The value of sonography with micro convex probes in diagnosing meniscal tears compared with arthroscopy. *J Ultrasound Med* 2006;25:593-7.
8. Casser HR, Sohn C, Kiekenbeck A. Current evaluation of sonography of the meniscus. Results of a comparative study of sonographic and arthroscopic findings. *Arch Orthop Trauma Surg* 1990;109:150-4.
9. Azzoni R, Cabitza P. Is there a role for sonography in the diagnosis of tears of the knee menisci? *J Clin Ultrasound* 2002;30:472-6.
10. Suzuki S, Kasahara K, Futami T, et al. Ultrasound diagnosis of pathology of the anterior and posterior cruciate ligaments of the knee joint. *Arch Orthop Trauma Surg* 1991;110:200-3.
11. Skovgaard Larsen LP, Rasmussen OS. Diagnosis of acute rupture of the anterior cruciate ligament of the knee by sonography. *Eur J Ultrasound* 2000;12:163-7.
12. Ptaznik R, Feller J, Bartlett J, et al. The value of sonography in the diagnosis of traumatic rupture of the anterior cruciate ligament of the knee. *AJR Am J Roentgenol* 1995;164:1461-3.
13. Friedl W, Glaser F. Dynamic sonography in the diagnosis of ligament and meniscal injuries of the knee. *Arch Orthop Trauma Surg* 1991;110:132-8.
14. Wang TG, Wang CL, Hsu TC, et al. Sonographic evaluation of the posterior cruciate ligament in amputated specimens and normal subjects. *J Ultrasound Med* 1999;18:647-53.
15. Hsu CC, Tsai WC, Chen CP, et al. Ultrasonographic examination of the normal and injured posterior cruciate ligament. *J Clin Ultrasound* 2005;33:277-82.
16. Miller TT. Sonography of injury of the posterior cruciate ligament of the knee. *Skeletal Radiol* 2002;31:149-54.
17. Cho KH, Lee DC, Chhem RK et al. Normal and acutely torn posterior cruciate ligament of the knee at US evaluation: preliminary experience. *Radiology* 2001;219:375-80.
18. Polly DW Jr, Callaghan JJ, Sikes RA, et al. The accuracy of selective magnetic resonance imaging compared with the findings of arthroscopy of the knee. *J Bone Joint Surg Am* 1988;70:192-8.
19. Gross ML, Grover JS, Bassett LW, et al. Magnetic resonance imaging of the posterior cruciate ligament. Clinical use to improve diagnostic accuracy. *Am J Sports Med* 1992;20:732-7.
20. Fischer SP, Fox JM, Del Pizzo W, et al. Accuracy of diagnoses from magnetic resonance imaging of the knee. A multiple-center analysis of one thousand and fourteen patients. *J Bone Joint Surg Am* 1991;73:2-10.
21. Ptaznik R. Ultrasound in acute and chronic knee injury. *Radiol Clin North Am* 1999;37:797-830.
22. Sonin AH, Fitzgerald SW, Hoff FL, et al. MR imaging of the posterior cruciate ligament: normal, abnormal, and associated injury patterns. *Radiographics* 1995;15:551-61.
23. Patten RM, Richardson ML, Zink-Brody G, et al. Complete vs partial-thickness tears of the posterior cruciate ligament: MR findings. *J Comput Assist Tomogr* 1994;18:793-9.
24. Sonin AH, Fitzgerald SW, Friedman H, et al. Posterior cruciate ligament injury: MR imaging diagnosis and patterns of injury. *Radiology* 1994;190:455-8.