



Title	Measurement of transcallosal inhibition in traumatic brain injury by transcranial magnetic stimulation.
Author(s)	Takeuchi, Naoyuki; Ikoma, Katsunori; Chuma, Takayo; Matsuo, Yuichiro
Citation	Brain Injury, 20(9), 991-996 https://doi.org/10.1080/02699050600909771
Issue Date	2006-08
Doc URL	http://hdl.handle.net/2115/28229
Rights	This is an electronic version of an article published in Takeuchi, N; Ikoma, K; Chuma, T; Matsuo, Y, Measurement of transcallosal inhibition in traumatic brain injury by transcranial magnetic stimulation, BRAIN INJURY, 20(9), AUG-2006, 991-996. BRAIN INJURY is available online at: http://www.informaworld.com/
Type	article (author version)
File Information	BI20-9-991.pdf



[Instructions for use](#)

#2005-064

Title: Measurement of transcallosal inhibition in traumatic brain injury by transcranial magnetic stimulation.

Naoyuki Takeuchi M.D.¹ Katsunori Ikoma M.D. PhD.¹ Takayo Chuma M.D.¹ Yuichiro Matsuo M.D.¹

¹Department of Rehabilitation Medicine, Hokkaido University Graduate School of Medicine, Sapporo 060-0814, Japan

This work was supported by research project grant-in-aid for scientific research No. 16500330 from the Japan Society for the Promotion of Science.

Corresponding address Naoyuki Takeuchi M.D.

Department of Rehabilitation Medicine, Hokkaido University Graduate School of Medicine North14 West5 Sapporo 060-0814, Japan

telephone number: 81-11-706-6066 fax number: 81-11-706-6067

e-mail: naoyuki@med.hokudai.ac.jp

Abstract

Primary objective: To study whether transcallosal inhibition (TCI) can evaluate the severity of traumatic brain injury (TBI).

Research design: Case-control study.

Methods and procedures: We studied 20 patients with a chronic TBI and 20 control subjects. We checked following transcranial magnetic stimulation parameters; resting motor threshold, central motor latency times, onset latency of TCI, duration of TCI, transcallosal conduction times and amount of TCI. We evaluated the severity of TBI using Glasgow Coma Scale (GCS).

Main outcome and results: The amount of TCI was significantly lower in the patients than the control subjects ($p < 0.001$). The amount of TCI was highly correlated with the GCS ($r = 0.787, p < 0.001$).

Conclusion: An assessment of TCI was found to be a more sensitive and useful methods for an evaluation of the severity of TBI.

Introduction

The functional integrity of the corpus callosum (CC) that connects homologous motor cortices can be tested electrophysiologically in humans by transcranial magnetic stimulation (TMS) [1]. When TMS is performed during an ongoing tonic voluntary contraction, the activity of the muscles ipsilateral to the site of the cortical stimulation is temporarily suppressed. This transcallosal inhibition (TCI) is not detected in patients with CC lesions [2]; hence, a transcallosal route is presumed to account for it. In recent years, TCI has been found to be a useful diagnostic tool in patients with multiple sclerosis, corticobasal ganglionic degeneration, and progressive supranuclear palsy [3–5].

CC lesions are commonly detected in patients with traumatic brain injury (TBI) [6–12]. The diffuse axonal injury (DAI) due to acceleration-deceleration and rotational forces is considered to be an important factor in the formation of a CC lesion [6–8, 10, 11]. A majority of the TBI survivors recover from coma and show remarkable progress toward regaining their preinjury functional abilities. However, patients with TBI often have cognitive impairments, including attention, memory, and executive function deficits [8, 13]. When attempting to correctly evaluate the severity of TBI, a method that requires little cooperation from the patient is desirable so that any cognitive impairment is excluded.

Our hypothesis was that the TCI method could detect an abnormality of the CC in

patients with TBI. The TCI method is simple and objective and requires little cooperation from the patient; hence, this method has the advantage of excluding any cognitive impairment when the severity of the TBI was evaluated. To our knowledge, imaging was the only available technique that could evaluate the severity of DAI while the patient was alive [9, 12, 14]. Therefore, TCI may be a unique diagnostic tool for electrophysiologically evaluating the DAI by monitoring the CC lesions. In the present investigation, we examined whether TCI could evaluate the severity of TBI that was indicated by the Glasgow Coma Scale (GCS) [15].

Methods

Patients and controls

Twenty patients with TBI (14 men and 6 women; aged, 18–60 years; mean age, 38.5 ± 13.9 years) were studied (Table 1).

Insert table 1 about here

The mean period after their TBI was 25.3 ± 10.7 months. We used the GCS scores that were obtained at the time of their first admission after accident to evaluate the severity of TBI (scale mean, 8.7 ± 2.5; range, 6 to 14). All the patients who were enrolled for the study fulfilled the following criteria: (1) age from 18 to 60 years, (2) drugs that are known to influence the excitability of the central nervous system (for example, an

anti-epileptic or psychoactive drug) had not been administered in the past month, and (3) no concomitant cervical or upper limb injury that could affect conduction along the peripheral nerves and spinal cord. The exclusion criteria for patients in this study were as follows: (1) the subjects, their guardians, or legal representatives were unwilling to give consent for participating in the study and (2) the patient had a history of neurological disease.

Twenty normal subjects, who were matched for age and sex (15 men and 5 women, aged 20–56 years; mean age, 35.3 ± 11.2 years), participated as control subjects in the study. They did not have any history or clinical evidence of any neurological disease.

Informed consent for the study was obtained from all the patients and control subjects. The protocol was approved by the local ethical committee of the Hokkaido University Graduate School of Medicine.

Magnetic stimulation and recording

Focal TMS to the motor cortex of each hemisphere was performed using a 70-mm figure-of-eight coil connected to a Magstim 200 stimulator (2-T version; Magstim Company, Dyfed, UK). The stimulation point for eliciting the maximal hand motor responses for each subject was determined. The current in the axis of the stimulation coil was directed anteroposteriorly (the induced current had the opposite orientation) because this direction is the most effective for eliciting TCI [16]. The electromyographic (EMG) responses were recorded bilaterally from the first dorsal

interosseous muscle (FDI) using Ag-AgCl surface electrodes. The EMG signal was amplified, filtered, and stored in a personal computer for off-line analysis (Neuropack; Nihon Koden, Tokyo, Japan).

The resting motor threshold (rMT) was defined as the lowest stimulator output that could produce motor evoked potentials (MEPs) with a peak-to-peak amplitude that was greater than 50 μ V in at least 5 of 10 trials [17]. In a TCI session, each motor cortex was stimulated 20 times, with an intensity of 150% rMT, during unilateral maximal tonic contraction of the ipsilateral FDI. During each stimulation, the subjects maintained a sustained maximal tonic contraction of the FDI muscle, with visual and auditory feedback, for approximately 2 s. To avoid central or peripheral fatigue during maximal tonic muscle contraction, the subjects rested for 3 min after a series of 10 stimuli. The stimuli at a frequency of 0.1 Hz were applied over the cortex. The peripheral latencies were obtained by magnetic stimulation of the cervical nerve roots using a 90-mm circular coil.

Response indices

The peak-to-peak amplitude of 10 averaged MEPs of the contralateral EMG obtained with an intensity of 120% rMT was determined. The central motor latency times (CMLTs) were calculated by subtracting the longest peripheral conduction time following magnetic stimulation of the cervical nerve roots from the onset latency of the cortically elicited contralateral EMG response.

The TCI parameters were evaluated by rectifying and averaging 20 EMG signals of the active FDI ipsilateral to the site of the cortex stimulation. The TCI was quantified by the period of relative EMG suppression after the stimulus, i.e., when the EMG activity dropped below the background activity. The onset latency of TCI was measured from the stimulus to where the EMG activity clearly fell below the mean amplitude of the EMG activity in the 100 ms before the stimulus. The duration of TCI was measured from its onset to where the EMG activity again reached the mean amplitude of the EMG activity before the stimulus. The transcallosal conduction times (TCTs) were determined by subtracting the onset latency of the corticospinally mediated contralateral responses from the onset latency of TCI in the same FDI. The area of suppressed EMG activity below the mean amplitude of the EMG activity before the stimulus was also averaged. The amount of TCI was then defined as the percentage of this mean suppressed activity in the mean amplitude of the EMG activity before the stimulus [18]. That is to say, the more the EMG activity was suppressed the greater was the amount of TCI.

Statistical analysis

Any parameters of the MEPs (rMT, CMLTs, amplitude) and TCI (amount of TCI, duration of TCI, TCTs) of the patients that exceeded mean value ± 2.5 SD (the pooled data across the left and right sides) of the **control subjects** were considered to be abnormal. The observed data (MEPs and TCI parameters) from the patients and the **control subjects** were compared by using a Mann-Whitney U test. Any possible

correlation between the amount of TCI and GCS was determined by using the Spearman rank correlation test.

Results

The data for the MEPs and the TCI parameters that were obtained for the control subjects and the patients are listed in Table 2.

Insert table 2 about here

MEPs parameters

We did not observe any difference between the mean data of the control subjects and the patients for the rMT, CMLTs, or amplitude (Table 2). In addition, we did not observe a significant difference in laterality in the MEPs parameters (rMT, CMLTs, and amplitude) for the control subjects and patients. An increased rMT was found in 15% (3 of 20), a decreased amplitude in 15% (3 of 20), and prolonged CMLTs in 20% (4 of 20) of the patients with TBI on either or both sides.

TCI parameters

The amount of TCI was significantly lower in the patients than in the control subjects ($p < 0.001$). One patient (patient no. 13) did not display TCI on either side. Therefore, we excluded her from the TCI correlation study. In 70% of the patients (14 of 20), the amount of TCI was abnormal. However, when compared with the control subjects the

latency onset of TCI, the duration of TCI, and the TCTs of the patients with TBI were not significantly different. The typical TCI that were observed for the control subjects and patients are shown in Figure 1. The amount of TCI was significantly correlated with the GCS (Figure 2; $r = 0.787$, $p < 0.001$).

Insert figure 1 and 2 about here

Discussion

There was a significant difference between the control subjects and the patients with TBI for the amount of TCI, but not rMT, CMLTs, or amplitude. This result suggested that the TCI method of evaluating CC was more sensitive for detecting abnormal findings in patients with TBI than the method of evaluating the excitability of the cortex and corticospinal tract function by TMS.

The GCS score has been reported to be strongly correlated with the severity of the TBI [19–21]. Therefore, the severity of TBI is usually described by the amount of impaired consciousness as defined by the GCS. Moreover, the GCS has a significant correlation with a CC lesion [6, 10]. TCI methods by TMS can evaluate the function of integrity of the CC connecting homologous motor cortices [1–5]. In our study, the amount of TCI was significantly correlated with the GCS. Based on these reports, it may be considered that the TCI method by TMS is useful for evaluating the severity of

TBI by monitoring the CC function.

No significant difference in the MEPs parameters (rMT, CMLTs, and amplitude) of the control subjects and patients was observed. The normal rMT and CMLTs in our patients with TBI may have indicated that they had only minimal or no loss of motor cortex excitability and conduction in the pyramidal tract. These results indicated that the abnormal findings in patients with TBI could not be easily detected by the well established method of determining the corticospinal tract function by using TMS. In contrast to our results, Chistyakov et al. have reported that patients with TBI had a higher rMT than the control subjects [22, 23]. However, this report had compared the more damaged side in TBI patients with that in control subjects [23]. In our investigation, the patients with TBI exhibited normal rMT and did not show significant laterality. Chistyakov et al., in a follow-up study, have also reported some improvement in the observed high rMT [22]. In fact, in our study, the period after the TBI was longer than the postaccident period of the Chistyakov's study that reported the high rMT of patients with TBI. In addition, a severe brain injury that might preclude consciousness and voluntary movement did not invariably predicate an abnormal rMT and CMCT [24]. Based on these reports, the normal rMT observed in our study was not thought to be specific with regard to the studies that reported high rMT in patients with TBI. In addition, the TCI route is thought to be longer than rMT, CMLTs, and amplitude because in addition to the corticospinal tract, the TCI route included the commissural

fibers via the CC. Therefore, the TCI method might detect the abnormal findings in patients with TBI more than the well established method of evaluating corticospinal tract function by using TMS.

The patients with TBI often have cognitive impairments, including attention, memory, and executive function deficits [8, 13]. A recent study reported that the area of the CC in patients with TBI correlated with the memory function [11]. Therefore, the TCI that can monitor the CC function might also be correlated with cognitive impairment in patients with TBI. In addition, the TCI as well as imaging is useful for accurately evaluating the patients with TBI because TCI is a simple method that requires little cooperation from the patient. Moreover, the CC lesion is considered to reflect the DAI [6–8, 10, 11]; therefore, TCI may be a diagnostic tool for electrophysiologically evaluating the DAI in vivo by monitoring the CC lesions. It has been recently considered that the diffusion MR tensor imaging may be able to detect the DAI [9, 14]; hence, some in vivo studies used the diffusion MR tensor imaging to detect the DAI [9, 12, 14]. Therefore, we must study the correlation between diffusion MR tensor imaging and the TCI to suggest the utility of TCI for evaluating the DAI in patients with TBI.

In conclusion, we confirmed that the TCI was positively correlated with the severity of the TBI. Moreover, an assessment by TCI was found to be a more sensitive method for detecting abnormal findings in patients with TBI than the well established method of evaluating corticospinal tract function by using TMS. This study is the first to report the

evaluation of the severity of TBI by using a TCI method that tests the functional integrity of CC by using TMS.

Acknowledgment

We thank Professor Yukio Mano at the department of rehabilitation medicine, Hokkaido University graduate school of medicine for supervision and expertise. We also thank Mami Onodera for technical support. This work was supported by research project grant-in-aid for scientific research No. 16500330 from the Japan Society for the Promotion of Science.

References

1. Meyer, B. U., Rörich, S., Einsiedel, H. G., Kruggel, F. and Weindl, A.: Inhibitory and excitatory interhemispheric transfers between motor cortical areas in normal humans and patients with abnormalities of the corpus callosum. *Brain*. **118**: 429-440, 1995.
2. Meyer, B. U., Rörich, S. and Woiciechowsky, C.: Topography of fibers in the human corpus callosum mediating interhemispheric inhibition between the motor cortices. *Annals of Neurology*. **43**: 360-369, 1998.
3. Schmierer, K., Niehaus, L., Rörich, S. and Meyer, B. U.: Conduction deficits of callosal fibers in early multiple sclerosis. *Journal of Neurology, Neurosurgery and Psychiatry*. **68**: 633-638, 2000.
4. Schmierer, K., Irlbacher, K., Gross, P., Rörich, S. and Meyer, B. U.: Inhibitory and excitatory interhemispheric transfers between motor cortical areas in normal humans and patients with abnormalities of the corpus callosum. *Neurology*. **59**: 1218-1224, 2002.
5. Wolters, A., Classen, J., Kunesch, E., Grossmann, A. and Benecke, R.: Measurements of transcallosally mediated cortical inhibition for differentiating parkinsonian syndromes. *Movement Disorders*. **19**: 518-528, 2004.
6. Gentry, L. R., Thompson, B. and Godersky, J. C.: Trauma to the corpus Callosum: MR features. *AJNR American Journal of Neuroradiology*. **9**:

1129-1138, 1988.

7. Parizel, P. M., Gothem, O. O. and Hauwe, L.: Imaging findings in diffuse axonal injury after closed head trauma. *European Radiology*. **8**: 960-965, 1998.
8. Meythaler, J. M., Peduzzi, J. D., Eleftheriou, E. and Novack, T. A.: Current concepts: diffuse axonal injury-associated traumatic brain injury. *Archives of Physical Medicine and Rehabilitation*. **82**: 1461-1471, 2001.
9. Arfanakis, K., Haughton, V. M., Carew, J. D., Rogers, B. P., Dempsey, R. J. and Meyerand, M. E.: Diffusion Tensor MR Imaging in Diffuse Axonal Injury. *AJNR American Journal of Neuroradiology*. **23**: 794-802, 2002.
10. Scheid, R., Preul, C., Gruber, O., Wiggins, C. and Cramon, D. Y.: Diffuse axonal injury associated with chronic traumatic brain injury: Evidence from T2*-weighted gradient-echo imaging at 3 T. *AJNR American Journal of Neuroradiology*. **24**: 1049-1056, 2003.
11. Tomaiuolo, F., Carlesimo, G. A., Di Paola, M., Petrides, M., Fera, F., Bonanni, R., Formisano, R., Pasqualetti, P. and Caltagirone, C.: Gross morphology and morphometric sequelae in the hippocampus, fornix, and corpus callosum of patients with severe non-missile traumatic brain injury without macroscopically detectable lesions: a T1 weighted MRI study. *Journal of Neurology, Neurosurgery and Psychiatry*. **75**: 1314-1322, 2004.
12. Salmond, C. H., Menon, D. K., Chatfield, D. A., Williams, G. B., Pena, A.,

- Sahakian, B. J. and Pickard, J. D.: Diffusion tensor imaging in chronic head injury survivors: correlations with learning and memory indices. *Neuroimage*. **29**: 117-124, 2006.
13. Whyte, J., Hart, T., Laborde, A. and Rosenthal, M.: Rehabilitation of the patient with traumatic brain injury. In: Delisa JA (editor) *Rehabilitation medicine: principles and practice*, 3rd edn (New York: Lippincott-Raven), pp. 1191-1240, 1998.
14. Chan, J. H., Tsui, E. Y., Peh, W. C., Fong, D., Fok, K. F., Leung, K. M., Yuen, M. K. and Fung, K. K.: Diffuse axonal injury: detection of changes in anisotropy of water diffusion by diffusion-weighted imaging. *Neuroradiology*. **45**: 34-38, 2003.
15. Teasdale, G. and Jennett, B.: Assessment of coma and impaired consciousness: a practical scale. *Lancet*. **7872**: 81-84, 1974.
16. Meyer, B. U., Kühn, A. and Röricht, S.: Influence of the direction of induced currents on callosally and corticospinally mediated electromyographic responses following magnetic motor cortex stimulation in man. *Journal of Physiology*. **497**: 34-35, 1996.
17. Rossini, P. M., Barker, A. T., Berardelli, A., Caramia, M. D., Caruso, G., Cracco, R. Q., Dimitrijevic, M. R., Hallett, M., Katayama, Y., Lucking, C. H., Maertens de Noordhout, A. L., Marsden, C. D., Murray, N. M. F., Rothwell, J.

- C., Swash, M. and Tomberg, C.: Non-invasive electrical and magnetic stimulation of the brain, spinal cord and roots: basic principles and procedures for routine clinical application. Report of an IFCN committee. *Electroencephalography and Clinical Neurophysiology*. **91**: 79-92, 1994.
18. Arányi, Z. and Rösler, K. M.: Effort-induced mirror movements. A study of transcallosal inhibition in humans. *Experimental Brain Research*. **145**: 76-82, 2002.
 19. Jane, J. A. and Rimel, R. W.: Prognosis in head injury. *Clinical Neurosurgery*. **29**: 346-352, 1984.
 20. Levin, H. S., Gary, H. E. and Eisenberg, H. M.: Neurobehavioral outcome 1 year after severe head injury: experience of the Traumatic Coma Data Bank. *Journal of Neurosurgery*. **73**: 699-709, 1990.
 21. Stambrook, M., Moore, A. D., Peters, L. C., Deviaene, C. and Hawryluk, G. A.: Effects of mild, moderate, and severe closed head injury on long-term vocational status. *Brain Injury*. **4**: 183-190, 1990.
 22. Chistyakov, A. V., Soustiel, J. F., Hafner, H., Elron, M. and Feinsod, M.: Altered excitability of the motor cortex after minor head injury revealed by transcranial magnetic stimulation. *Acta Neurochirurgica*. **140**: 467-472, 1998.
 23. Chistyakov, A. V., Soustiel, J. F., Hafner, H., Trubnik, M., Levy, G. and Feinsod, M.: Excitatory and inhibitory corticospinal responses to transcranial

stimulation in patients with minor to moderate head injury. *Journal of Neurology, Neurosurgery and Psychiatry*. **70**: 580-587, 2001.

24. Moosavi, S. H., Ellaway, P. H., Catley, M., Stokes, M. J. and Haque, N.: Corticospinal function in severe brain injury assessed using magnetic stimulation of the motor cortex in man. *Journal of the Neurological Sciences*. **164**: 179-186, 1999.

Legends

Figure 1

Examples of the TCI raw data. Each recording represents the average of 20 rectified electromyogram activities.

- a) Typical TCI elicited from the first dorsal interosseous muscle (FDI) of control subject. An oblique line showed the area of TCI (The amount of TCI = 57.1%)
- b) TCI elicited from FDI of patient with severe TBI. Note the amount of TCI was small (The amount of TCI = 24.9%, GCS = 7 points).

TCI: transcallosal inhibition; TBI: traumatic brain injury; GCS: Glasgow coma scale

Figure 2

The amount of TCI had a significant correlation with GCS in 19 patients with TBI ($r = 0.787$ $p < 0.001$).

TBI: traumatic brain injury; TCI: transcallosal inhibition; GCS: Glasgow coma scale

Table 1

Clinical characteristics of patients with traumatic brain injury.

Patient no.	Age	Sex	GCS on admission	Duration since injury (months)	Type of lesions
1	29	M	9	29	Diffuse
2	60	F	10	38	Focal
3	31	M	9	23	Combined
4	40	M	8	25	Diffuse
5	26	M	7	9	Diffuse
6	31	M	8	45	Diffuse
7	56	M	13	24	Focal
8	52	F	9	31	Combined
9	18	M	6	21	Diffuse
10	23	M	6	27	Combined
11	33	M	6	51	Combined
12	60	M	12	10	Focal
13	28	F	6	32	Diffuse
14	52	M	6	28	Combined
15	25	F	8	15	Combined
16	43	M	7	18	Combined
17	33	F	14	23	Diffuse
18	52	M	9	19	Combined
19	23	M	8	24	Diffuse
20	55	F	13	14	Diffuse

GCS, Glasgow Coma Scale; Diffuse, MRI findings detected the small punctiform parenchymal hemorrhages in the mesencephalon, corpus callosum, basal ganglia or periventricular; Focal, MRI findings detected the hemorrhagic brain contusions in the frontal and/or temporoparietal lobes; Combined, Both of diffuse and focal lesions.

Table 2

MEPs and TCI parameters.

parameter	control subjects, 40hands		patients with TBI, 40hands	
	Mean \pm SD	Normal range ^a	Mean \pm SD	Abnormal hands/patients
Resting motor threshold (%)	44.1 \pm 5.1	31.3-56.9	46.4 \pm 8.2	4/3
Amplitude of MEPs (mV)	1.3 \pm 0.4	0.3-2.3	1.1 \pm 0.7	3/3
Central motor latency times (ms)	6.9 \pm 0.6	5.4-8.5	7.2 \pm 1.1	6/4
Onset latency of TCI (ms)	34.0 \pm 2.6	27.5-40.5	35.1 \pm 3.1 ^b	4/3
Duration of TCI (ms)	26.2 \pm 6.1	10.9-41.4	24.7 \pm 7.6 ^b	3/2
Transcallosal conduction times (ms)	12.5 \pm 1.9	7.7-17.4	12.6 \pm 2.2 ^b	2/2
Amount of TCI (%)	54.1 \pm 5.1	41.4-66.7	39.1 \pm 10.3 ^{b,*}	22/14

^anormal range = mean \pm 2.5 SD

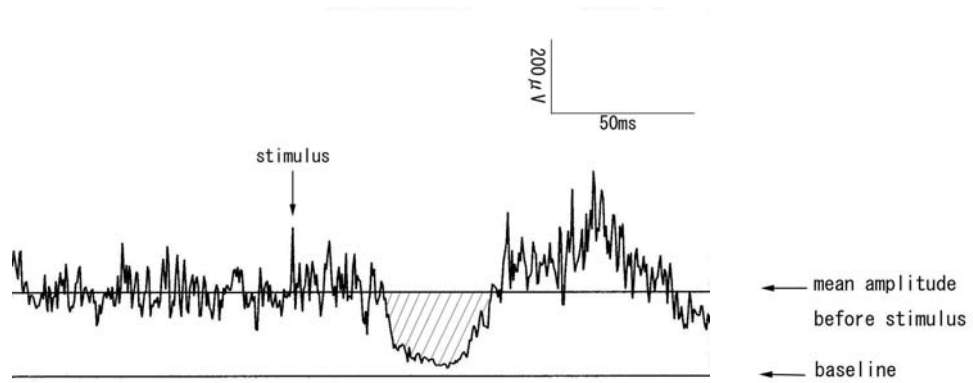
^b38 hands(one patient had no TCI on both sides)

* $p < 0.001$ (compared with control subjects)

MEPs = motor evoked potentials; TCI = transcallosal inhibition; TBI = traumatic brain injury.

Figure 1

a)



b)

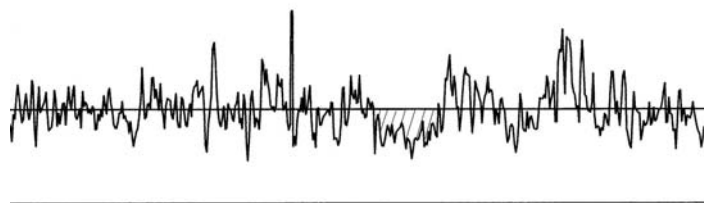


Figure 2

