

A Study of Replacement of Timolol-Pilocarpine with Latanoprost in Pseudoexfoliation Glaucoma

Lovro Bojić¹, Zdravko Mandić², Katija Novak-Lauš², Zlatko Sonicki³
and Deni Karelović⁴

¹ Eye Clinic, University Hospital »Split«, Split, Croatia

² Eye Clinic, University Hospital »Sestre Milosrdnice«, Zagreb, Croatia

³ School of Public Health »Andrija Štampar«, School of Medicine, University of Zagreb, Zagreb, Croatia

⁴ School of Medicine, University of Split, Croatia

ABSTRACT

The aim of the study was to evaluate the efficacy of replacing current dual local therapy (timolol and pilocarpine) with latanoprost 0.005% in 71 pseudoexfoliation glaucoma patients with controlled intraocular pressure (IOP). 39 patients switched to latanoprost 0.005% and 32 patients continued timolol-pilocarpine therapy. Mean diurnal (IOP) was measured at baseline, after 0.5, 1, 3 and 6 months of treatment. After 6 months 38 patients with latanoprost and 30 patients with timolol-pilocarpine had completed the study. At baseline the mean diurnal IOP was 20.4±2.0 mmHg for patients in latanoprost treatment group and 21.4±2.1 mmHg for patients in timolol-pilocarpine group. At the end of the study, after 6 months of treatment, the mean diurnal IOP values were 16.6±2.4 and 17.9±2.0 mmHg respectively. IOP was statistically significantly reduced from baseline ($p < 0.001$). The mean diurnal IOP change from baseline was -3.3 ± 0.5 mmHg (mean±SEM, ANCOVA) for the patients treated with latanoprost and -3.2 ± 0.4 mmHg for the patients treated with timolol+pilocarpine. This difference in IOP reduction between groups was not statistically significant ($z = 0.69$; $p = 0.49$). This study showed that combination therapy (timolol plus pilocarpine) in pseudoexfoliation glaucoma can effectively be replaced by latanoprost monotherapy.

Key words: latanoprost, timolol-pilocarpine, replacement, glaucoma

Introduction

Glaucoma is multifactorial syndrome of progressive optic neuropathy characterized by an unphysiological large cup/disc ratio with reduced retinal sensitivity, visual field defects and additional psychophysical alterations^{1,2}. In addition to intraocular pressure (IOP), which is an established risk factor, many other risk factors have been described^{3–5}. Evidence suggests that higher mean IOP and higher peak IOP increase the risk of visual field loss^{6,7}. Latanoprost is a prostaglandin F_{2α} analog and selective F-prostaglandin receptor agonists that effectively reduce intraocular pressure (IOP) in patients with glaucoma^{8–10}. In many patients topical β adrenergic antagonists alone do not sufficiently lower IOP and additional medications have to be prescribed. Pilocarpine is frequently used as »add on« therapy. The purpose of this study was to evaluate the efficacy of replacing current dual therapy (β-blocker and pilocarpine) with latanoprost 0.005% in pseudoexfoliation glaucoma.

Materials and Methods

This study included 71 pseudoexfoliation glaucoma patients in a 6-month's open-label comparison of latanoprost monotherapy to the current dual therapy: timolol and pilocarpine. After obtaining approval from the appropriate regulatory authorities and ethics committees, oral consent was obtained from all patients before entering the study. After a 4 week run-in period on timolol 0.5% twice daily and pilocarpine 2% three times a day, the patients were randomized to two parallel study groups: one group switched from timolol and pilocarpine to latanoprost, 0.005% once daily in the evening (39 patients), while the other group continued on timolol and pilocarpine (32 patients). The study protocol followed the guidelines of the Declaration of Helsinki.

All participants, aged 51–75 (mean 61.1±5.2 years), enrolled in study were diagnosed as suffering of pseudoexfoliation glaucoma, based on having controlled IOP on current local therapy (IOP<21 mmHg), open angle on gonioscopy with dandrufflike flakes of exfoliation material, exfoliation material on the pupillary margin and on the anterior lens surface. No evidence of underlying ocular or systemic cause of high IOP, glaucomatous visual field defect and papillary excavation (C/D vertical > 0.3). The patients were included in the study by the judgment of the investigator based of the disease status of each individual patient. Exclusion criteria included any treatment with more than two glaucoma medications and any previous treatment with latanoprost, current use of contact lenses, previous filtering surgery, argon laser trabeculoplasty, pregnant women and any ocular inflammation within three months were reasons for excluded from study. The patients were examined at a prestudy visit within 4 weeks of trial treatment initiation. Table 1 presents the schedule of examinations. Intraocular pressure was measured by Goldmann applanation tonometer. In each eye three measurements were performed and the mean of the three measurements was used in the statistical analyses. IOP were recorded at baseline and 15 days, 1 months, 3 months and 6 months after the initiation of latanoprost. Examinations were done at 9 a.m., 1 p.m. and 6 p.m. and the diurnal IOP was calculated.

Statistical analysis was performed using Statistica for Windows (Stat Soft Inc, USA, and Version 6.0). All data were analyzed by a descriptive analysis. Comparisons between the groups were made using the non-parametric Mann-Whitney U test. An analysis of covariance (ANCOVA) was performed with diurnal IOP changes at months 6 from baseline as response variable, baseline diurnal IOP as

TABLE 1
SCHEDULE OF EXAMINATION

Examinations	Four weeks before baseline	Baseline	Time after commencement of the therapy (months)			
			0.5	1	3	6
Gonioscopy	X					
Visual field	X					X
Ophthalmoscopy	X	X	X	X	X	X
Visual acuity	X	X	X	X	X	X
Adverse events	X	X	X	X	X	X
Slit-lamp examination	X	X	X	X	X	X
Intraocular pressure	X	X	X	X	X	X

covariate and group as factors. We also used Wilcoxon matched pairs test to compare baseline and post-treatment IOP at each point of measurement for each group. A 95% confidence interval was calculated for the difference in mean IOP reduction between the treatment groups. A Chi-square test and Student's t-test were used to compare patient data such as sex and age. Findings with an error probability value of < 0.05 were considered to be statistically significant.

Results

Of 71 pseudoexfoliation glaucoma patients included in study, 39 patients were consisted the latanoprost treatment group and 32 the timolol-pilocarpine group. The demographic characteristic is presented in Table 2. One of the patients from the latanoprost treatment group was withdrawn before the study termination be-

cause of the lost of follow up. Two patients from the timolol-pilocarpine treatment group were withdrawn because of headache.

At baseline the mean diurnal IOP was 20.4 ± 2.0 mmHg (mean \pm SD) for patients in latanoprost treatment group and 21.4 ± 2.1 mmHg for patients in the timolol-pilocarpine group. At the end of the study, after 6 months of treatment, the mean IOP values were 16.6 ± 2.4 and 17.9 ± 2.0 mmHg, in the two groups respectively.

The mean IOP at each measurement for the treatment groups is presented in Table 3. Compared with baseline measurements the mean IOP reduction at 6 months was statistically significant in both treatment groups ($p < 0.001$). The changes in mean diurnal IOP from baseline to the 6 months for the two groups determined with ANCOVA are shown in Figure 1. The mean diurnal IOP change from baseline

TABLE 2
DEMOGRAPHIC DATA OF ALL PATIENT

Group	Latanoprost	Timolol-pilocarpine	p
Number of patients	38	30	
Mean age (\pm SD)	60.3 ± 4.9	62.2 ± 5.4	0.1 ^a
Sex (male/female)	17/21	14/16	0.8 ^b

^aStudent's t-test; ^bChi-square test

TABLE 3
MEAN VALUES (\pm SD) OF IOP (mmHg) IN
LATANOPROST AND TIMOLOL-PILOCARPINE
GROUP AT 5 CONSECUTIVE MEASUREMENTS

Time	Latanoprost (N=38)	Timolol-pilocarpine (N=30)
Baseline	20.4 (2.0)	21.4 (2.1)
15 days	17.1 (1.6)	18.1 (1.7)
1 months	16.7 (1.6)	18.0 (1.8)
3 months	16.4 (1.8)	18.2 (1.9)
6 months	16.6 (2.4)	17.9 (2.0)

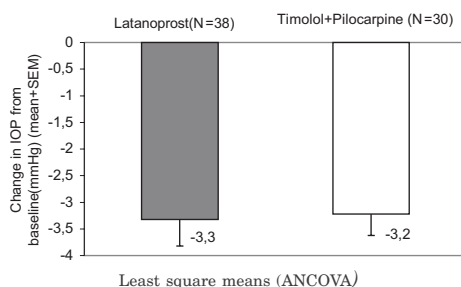


Fig. 1. Diurnal IOP reduction (mean \pm SEM) after 6 months compared with baseline values.

was -3.3 ± 0.5 mmHg, (mean \pm SEM, ANCOVA), 95% CI (-4.2 ± 2.4) mmHg, for the patients treated with latanoprost and -3.2 ± 0.4 mmHg, 95% CI (-4.0 ± 2.4) mmHg for the patients treated with timolol+pilocarpine. Switching from timolol-pilocarpine to latanoprost once daily caused statistically not significant reduction in mean diurnal IOP ($z=0.21$; $p=0.84$). The change in treatment in these groups caused a reduction corresponding to 16% for latanoprost and 15% for timolol-pilocarpine. This difference in IOP reduction between groups was not statistically significant ($z=0.69$; $p=0.49$).

No systemic adverse event was reported. Adverse ocular events in latanoprost group was reported by 9 patients (23.7%), conjunctival hyperemia in 4 (10.5%), itching in 4 (10.5%) and increase iris pigmen-

tation in 1 (2.6%) patients. In the timolol-pilocarpine group adverse ocular effects was reported in 8 (21%) patients: eye irritation in 5 (16.7%) and headache in 3 (10%) patients.

Discussion

Combination of two topical medications is common in the treatment of glaucoma. A topical medication that reduces inflow such as β -adrenergic antagonist preferably is combined with medication that increase outflow such as pilocarpine and latanoprost. It is a great importance to consider the option of switching a patient from multiple dosing regiments to monotherapy. In our study, patients with pseudoexfoliation glaucoma on current dual therapy with topical β -adrenergic antagonists in combination with pilocarpine, were switched to treatment with latanoprost once daily. Mean diurnal IOP was considered a relevant measure of clinical efficacy for comparing these two treatment groups after 6 months of therapy. The results of the study showed that latanoprost 0.005% applied topically once daily is at least as effective in reducing the IOP as timolol-pilocarpine. Similar results were found in other studies^{11–15} although IOP reducing effect was something less marked in our patients. Switching from the timolol-pilocarpine to latanoprost reduced mean diurnal IOP by 16%. IOP reducing effect in the timolol-pilocarpine group was 15%. This difference in IOP reduction between the two groups was not statistically significant ($p=0.49$). A multicenter randomized 6-week trial of 237 glaucoma patients conducted in France and Sweden showed that latanoprost monotherapy was at least as effective as therapy with the fixed combination of timolol and pilocarpine in reducing mean diurnal IOP¹⁵. Although our study compared two relatively small groups and the previous studies did not

detect differences as well, the power of the study was enough to detect significant differences.

This study showed that latanoprost 0.005% applied topically once daily is effective in reducing the IOP as combination timolol-pilocarpine and this dual therapy (timolol plus pilocarpine) in pseudo-

exfoliation glaucoma can effectively be replaced by latanoprost monotherapy in many patients. The convenience of daily administration of a single drop of latanoprost versus multiple drops of timolol and pilocarpine can improve patient compliance too.

REFERENCE

1. ORGÜL, S., J. FLAMMER, Primary open-angle glaucoma and the role of pharmacotherapy in the management of glaucoma patients. In: ORGÜL, S., J. FLAMMER (Eds.): Pharmacotherapy in glaucoma. (Verlag Hans Huber, Bern, 2000).
2. VOJNIKOVIĆ, B., S. NJIRIĆ, L. BOJIĆ, D. KOVAČEVIĆ, Coll. Antropol., 25 (2001) 127.
3. LANDERS, J., I. GOLDBERG, S. L. GRAHAM, Clin. Exp. Ophthalmol., 30 (2002) 242.
4. FLAMMER, J., I. O. HAEFLIGER, S. ORGUL, T. RESINK, J. Glaucoma, 8 (1999) 212.
5. BOJIĆ, L., Z. MANDIĆ, D. BUKOVIĆ, D. KARELOVIĆ, T. STRINIĆ, Coll. Antropol., 26 (2002) 589.
6. KASS, M. A., D. K. HEUER, E. J. HIGGINBOTHAM, C. A. JOHNSON, J. L. KELTNER, J. P. MILLER, R. K. PARRISH, M. R. WILSON, M. O. GORDON, Arch. Ophthalmol., 120 (2002) 701.
7. MARTINEZ-BELLO, C., B. C. CHAUHAN, M. T. NICOLELA, Am. J. Ophthalmol., 129 (2000) 302.
8. AUNG, T., P. T. K. CHEW, F. T. S. OEN, Y. H. CHAN, L. H. THEAN, L. YIP, B. A. LIM, S. K. L. SEAH, Br. J. Ophthalmol., 86 (2002) 75.
9. ELDER, M., J. MORA, Clin. Exp. Ophthalmol., 29 (2001) 368.
10. HIGGINBOTHAM, E. J., R. FELDMAN, M. STILES, H. DUBINER, Arch. Ophthalmol., 120 (2002) 915.
11. MISHIMA, H. K., K. MASUDA, Y. AZUMA, M. ARAIE, Arch. Ophthalmol., 114 (1996) 929.
12. HEDMAN, K., A. ALM, Eur. J. Ophthalmol., 10 (2000) 94.
13. MANDIĆ, Z., L. BOJIĆ, K. NOVAK-LAUŠ, D. ŠARIĆ, Coll. Antropol., 26 (2002) 595.
14. DIESTELHOURST, M., J. P. NORDMANN, C. B. TORIS, Surv. Ophthalmol., 47 (2002) S155.
15. NORDMANN J. P., M. SODERSTROM, J. F. ROULAND, F. MALECAZE, Br. J. Ophthalmol., 84 (2000) 181.

L. Bojić

Eye Clinic, University Hospital »Split«, Spinčićeva 1, 21000 Split, Croatia

ISPITIVANJE ZAMJENE TIMOLOLA I PILOKARPINA S LATANOPROSTOM KOD PSEUDOEKSFOLIJATIVNOG GLAUKOMA

SAŽETAK

Cilj ove studije bio je ispitati efikasnost zamjene dvojne lokalne terapije (timolol i pilokarpin) kod 71-og bolesnika s pseudoeksfolijativnim glaukomom s reguliranim intraokularnim tlakom (IOT). Kod 39 bolesnika uveden je u terapiji latanoprost 0.005%, a ostala 32 bolesnika su nastavila sa svojom početnom terapijom (timolol i pilokarpin). Srednji dnevni IOT mjereno je na početku, 0.5, 1, 3 i 6 mjeseci. Nakon 6 mjeseci, 38 bolesnika s latanoprostom i 30 sa timololom i pilokarpinom završila su ispitivanje. Početna srednja dnevna vrijednost IOT-a bila je 20.4 ± 2.0 mmHg kod bolesnika s latanoprostom u terapiji, a 21.4 ± 2.0 mmHg kod bolesnika s timololom i pilokarpinom. Na-

kon 6 mjeseci srednja vrijednost dnevnog IOT-a bila je 16.6 ± 2.4 mm Hg odnosno 17.9 ± 2.0 mmHg. Ovo sniženje IOT-a bilo je statistički značajno ($p < 0.001$). Srednja vrijednost promjene IOT-a bila je -3.3 ± 0.5 mmHg (srednja vrijednost \pm SEM, ANCOVA) kod bolesnika s latanoprostom u terapiji, a -3.2 ± 0.4 mmHg kod bolesnika s timololom i pilokarpinom. Ova razlika u sniženju IOT-a nije statistički značajna ($z = 0.69$; $p = 0.49$). Ovo ispitivanje ukazuje da dvojna terapija (timolol i pilokarpin) kod pseudoeksfolijativnog glaukoma može biti uspješno zamijenjena latanoprost monoterapijom.