

# Fine Needle Aspiration Cytology of Chondroid Syringoma

Marija Škoro<sup>1</sup>, Karmen Trutin Ostović<sup>1,6</sup>, Igor Čikara<sup>2</sup>, Danko Müller<sup>3</sup>, Nina Petra Novak<sup>1</sup> and Mišo Virag<sup>4,5</sup>

<sup>1</sup> Department of Clinical Cytology and Cytometry, Dubrava University Hospital, Zagreb, Croatia

<sup>2</sup> Department of Diagnostic and Interventional Radiology, Dubrava University Hospital, Zagreb, Croatia

<sup>3</sup> Department of Patology, Dubrava University Hospital, Zagreb, Croatia

<sup>4</sup> Department of Maxillofacial Surgery, Dubrava University Hospital, Zagreb Croatia

<sup>5</sup> Zagreb University, School of Medicine, Zagreb, Croatia

<sup>6</sup> University of Applied Health Studies, Zagreb, Croatia

## ABSTRACT

*Chondroid syringoma (CS) is a rare, benign, appendageal tumor with diagnostic feature of myxochondroid stroma supporting eccrine and apocrine epithelial structures. The usual presentation is a painless, slowly growing mass, typically located in the head and neck region. It usually affects middle-aged and older male patients. Because of its unremarkable clinical presentation it is often overlooked. It should be included in the differential diagnosis of cutaneous head and neck tumors, especially in middle-aged men. Optimal treatment of CS is total surgical excision. We present a 63 year-old man with a small nodule on the neck with 5 years of duration. The diagnosis was made initially on fine needle aspiration cytology that was performed by ultrasound guidance and confirmed subsequently by histology. FNA cytology may be very useful to determine diagnosis before excision.*

**Key words:** chondroid syringoma, skin tumor, fine needle aspiration cytology

## Introduction

Chondroid syringoma is a rare, benign, appendageal tumor with the diagnostic feature of a myxochondroid stroma supporting eccrine and apocrine epithelial structures. Its etiopathogenesis is unknown. This tumor is often overlooked because of rarity and unremarkable clinical presentation. These painless, firm, intradermal or subcutaneous nodules are most often on the head, face and neck, between 0.5 and 3 cm in diameter but can occur on the trunk and extremities<sup>1</sup>. It usually affects middle-aged and older male patients. It is usually benign lesion but some malignant cases have been reported<sup>2</sup>. Histologically, ultrastructurally and immunohistochemically these tumors are similar to pleomorphic adenomas of the salivary glands. In contrast to pleomorphic adenomas, chondroid syringomas are thought to arise from sweat glands.

The first-line treatment is total excision of the tumor. The vast majority of mixed tumors do not recur after surgical excision but seeding and regrowth of stromal and

epithelial elements may occur, especially as a consequence of incomplete curettage.

## Case Report

A 63 year-old man presented with a small, five years old nodule on the neck. Physical examination revealed a small, painless, subcutaneous nodule without involvement of the overlying skin. Ultrasonography showed a small subcutaneous, inhomogenous mass measuring 8 mm that showed hypervascularisation (Figure 1). Radiologist required an ultrasound-guided fine needle aspiration biopsy.

That procedure was performed and during it the lesion started to extremely bleed. The smears were cellular and showed numerous clusters and papillary formations of relatively small, monomorphic epithelial cells embedded in a myxoid stroma (PAS positive, Alcian negative)

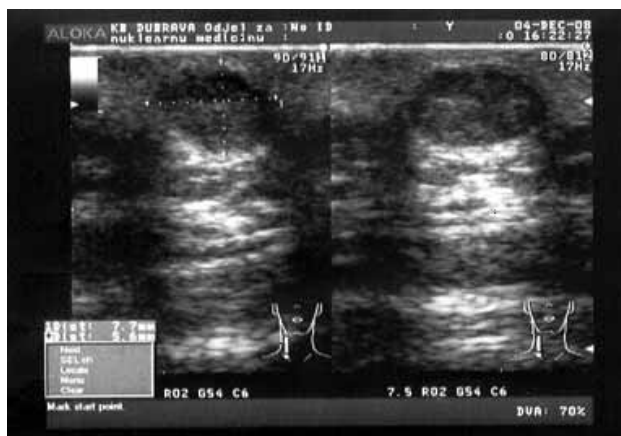


Fig. 1. Ultrasonography of small subcutaneous mass measuring 8 mm in diameter.

(Figure 2a). The cytoplasm was dense, moderate in amount, with well-defined cell borders. The nuclei were round to ovale, centrally located with fine, evenly distributed chromatin (Figure 2b). The cells embedded in chondromyxoid ground substance were elongated and either arranged individually or in a fusiform pattern (Figure 2c).

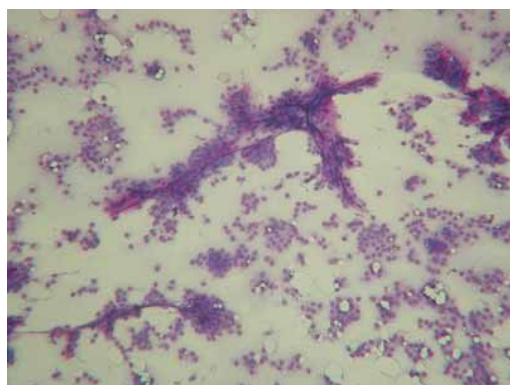


Fig. 2a) Numerous clusters of relatively small monomorphic epithelial cells embedded in a myxoid stroma (MGG, x100).

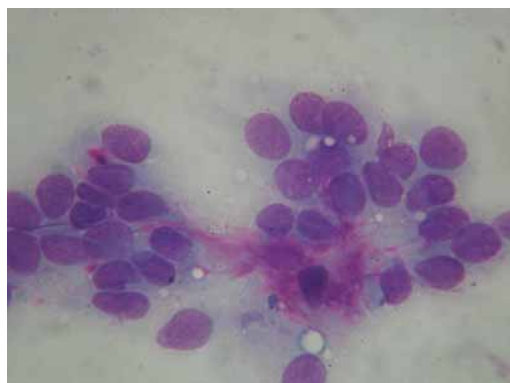


Fig. 2b) Dense cytoplasm, moderate in amount and round to ovale nuclei with fine, evenly distributed chromatin (MGG, x1000).

The combination of epithelial elements and myxoid stroma suggested a diagnosis of chondroid syringoma.

The lesion was excised and sent for histopathologic examination. Gross examination showed a relatively well-circumscribed small epidermal tumor 0.6 cm in diameter. Histological examination revealed two different components of tissue. The first component was the stroma with myxoid and chondroid regions; and the other component had structures showing tubules and branches in a solitary or grouped fashion that were lined by a double row of cuboidal epithelial cells (Figure 2d).

Histologic findings are consistent with benign appendageal tumor – tumor mixtus of the skin.

## Discussion and Conclusion

The term chondroid syringoma has widely replaced the older term mixed tumor of the skin. Hirsch and Helwig first described it in 1961 because of the presence of sweat gland elements set in cartilaginous stroma<sup>3-6</sup>. This tumor is rare among primary skin tumors. The incidence is low – 0.01–0.098%<sup>2-4</sup>. There are only few case reports describing the fine needle aspiration cytologic features of chondroid syringoma for diagnosis<sup>7,8</sup>.

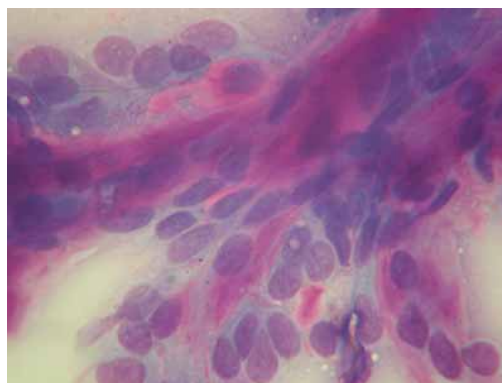


Fig. 2c) Elongated cells embedded in chondromyxoid ground substance (MGG, x1000).

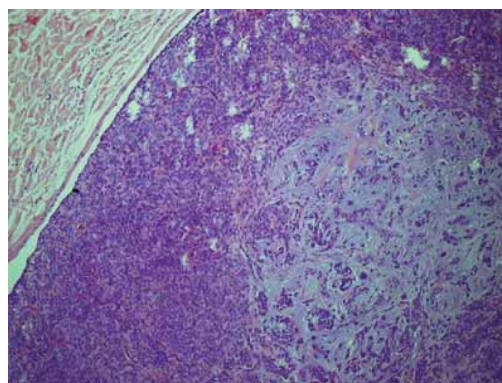


Fig. 2d) Stroma with myxoid and chondroid regions and tubules and branches lined by a double row of cuboidal epithelial cells (HE, x100).

Its clinical characteristic are not pathognomonic. CS presents as a slow growing, firm, painless, subcutaneous or intracutaneous nodule measuring 0.5–3 cm in diameter<sup>7,8</sup>. The overlying skin may be fixed to the nodule<sup>1</sup>. They are often mistaken for other types of skin lesions such as dermoid or sebaceous cyst, neurofibroma, dermatofibroma, lipoma, basal cell carcinoma, pilomatricoma, histiocytoma and seborrheic keratosis<sup>2,5</sup>. It usually affects middle-aged and older male patients. In our case, it occurred in a 63-year-old male.

The site of predilection for CS is the head and neck region, particularly cheek, nose or skin above the lip. Less commonly it can develop on the scalp, eyelid, orbit, hand, foot, forehead, axillary region, abdomen, penis, vulva and scrotum<sup>2,3</sup>. It is often single but only few cases of multiple CS are described<sup>9</sup>. Rare cases of malignant CS and their cytomorphologic features have been reported<sup>10</sup>. These forms occur more commonly in younger female patients. They are occurring on the trunk and extremities, often larger than 3 cm and locally invasive<sup>2,3-6</sup>. Of the malignant type, 48 percent are reported to have regional lymph node metastases and 45 percent result in distant metastases<sup>4</sup>. Symmetry and noninfiltrative pattern of growth are important features in differentiating benign mixed tumors from the rarely encountered malignant variant<sup>1</sup>. Malignant forms can display bland features, lacking mitoses and marked nuclear pleomorphism with prominent nucleoli<sup>10</sup>. In most cases of malignant chondroid syringoma, anaplastic changes are present from the beginning. Rarely, a many years old chondroid syringoma suddenly undergoes malignant changes with widespread metastasis<sup>11</sup>.

There are some reported cases of chondroid syringoma of the breast that may be confused with different benign and malignant tumors. It may encounter diagnostic difficulties when the clinical findings are suggestive for malignancy and cytologic appearance is identical to a salivary gland pleomorphic adenoma<sup>12</sup>.

Bates and Baithun described another type of these tumors called atypical mixed tumors. They have architectural features suggestive of malignancy but do not conclusively fall into malignant category<sup>4</sup>.

Histologically, CS is similar to pleomorphic adenomas of the salivary glands. It consists of mixed epithelial and

mesenchymal elements. The epithelium may consist of branching small to dilated ducts or small solid cords. The stroma may appear to represent loose reactive fibrous tissue, pale hyalinized fibrous tissue, myxoid tissue or solid hyaline cartilage<sup>1,13</sup>. Two histological variants of this tumor are described by Headington, the eccrine type with smaller lumens lined by a single row of cuboidal epithelial cells and the apocrine type with tubular and cystic branching lumina lined by two rows of epithelial cells<sup>4</sup>. Mixed tumors may exhibit clear cell change and follicular differentiation within the epithelial cells. In 40% cases these tumors contain hyaline cells. When these cells are the predominant cell type, the tumor is called hyaline-cell rich CS<sup>13</sup>. Immunohistochemical studies shown positivity for cytokeratin, vimentin, desmin and S-100 protein in the stroma. The cystic spaces are frequently filled with PAS-positive, diastase-resistant material<sup>1,4-12</sup>.

Fine needle aspiration cytology may be very useful to determine diagnosis of benign and malignant lesions before excision. Sometimes it is difficult because of the overlapping cytologic features. In our case the diagnosis was made initially on fine needle aspiration cytology and confirmed by histology.

Optimal treatment of CS is total surgical excision with wide disease free margins because of malignant potential and recurrency. The patient should be followed carefully for both local recurrence and metastases. The recurrent lesion alerts the clinician to the possibility of malignancy and can be treated by surgical re-excision<sup>11</sup>.

In conclusion, although CS lesions are rare lesions, it should be considered in differential diagnosis of small subcutaneous nodules in the head and neck region in middle-aged male patients. The diagnosis is made on microscopic examination. FNA cytology is a safe diagnostic procedure that may be used for diagnostic purposes and may prove useful to determine pathology before histological examination.

FNA cytology plays important role in the preoperative investigation of skin tumors as well as in the evaluation of possible recurrence of previously treated neoplasm. Reliable results are accessible in the hands of adequately experienced cytologists.

## REFERENCES

1. RAGSDALE BD, MURPHY GF, Tumors of the skin. In: SILVERBERG SG, DELELLIS RA, FRABLE WJ (Eds) Principles and practice of surgical pathology and cytopathology (Church Livingstone, New York, Edinburgh, 1997).
2. MEBAZAA A, TRABELSI S, DENGUELZI M, SRIHA B, BELAJOUZA C, NOUIRA R, Dermatol Online J, 12 (2006) 14.
3. AGRAWAL A, KUMAR A, SINHA AK, KUMAR B, SABIRA KC, Singapore Med J, 49 (2008) 33.
4. SIVAMANI R, WADHERA A, CRAIG E, Dermatol Online J, 12 (2006) 8.
5. TURHAN-HAKTANIR N, SAHIN O, BUKULMEZ A, DEMIR Y, Pediat Dermatol, 24 (2007) 55.
6. SRINIVASAN R, RAJWANSHI A, PADMANABHAN V, DEY P, Acta Cytol, 37 (1993) 535.
7. KUMAR S, GHOTEKAR LH, THAPPA DM, SMILE R, Acta Cytol, 47 (2003) 522.
8. KUMAR B, Chondroid syringoma diagnosed by fine needle aspiration cytology, Diagn Cytopathol, accessed 19.08.2009., Available from: URL: <http://www.ncbi.nlm.nih.gov/pubmed/19693940>.
9. LAKHSMI T, GNANESHWAR AR, Indian J Dermatol Venereol Leprol, 64 (1998) 83.
10. MISHRA K, AGARWAL S, Acta Cytol, 42 (1998) 1155.
11. SHASHIKALA P, CHANDRASHEKHAR HR, SHARMA S, SURESH KK, Indian J Dermatol Venereol Leprol, 70 (2004) 175.
12. PARWANI AV, ALI SZ, Arch Pathol Lab Med, 127 (2003) 233.
13. LEBOLT PE, Appendageal tumors. In: LEBOLT PE, BURG G, WEEDON D, SARASIN A (Eds) Pathology and Genetics of Skin Tumours (IARC, Lyon, 2006).

M. Škoro

*Department of Cytology and Cytometry, Dubrava University Hospital, Avenija Gojka Šuška 6, 10 000 Zagreb, Croatia  
e-mail: marija.skoro@kbbd.hr*

## **CITOLOGIJA HONDROIDNOG SIRINGOMA**

### **S A Ž E T A K**

Hondroidni siringom je rijedak, benigni tumor kožnih adneksa koji ima karakteristike miksohondroidne strome u koju su uklopljene ekrine i apokrine epitelne strukture. Najčešće se javlja u obliku bezbolnog, spororastućeg tumora, koji je tipično smješten na glavi i vratu. Obično pogađa muškarce srednje i starije dobi. Zbog svog nekarakterističnog izgleda često se previdi. Trebao bi se uzeti u obzir u diferencijalnoj dijagnozi kožnih tumora glave i vrata, naročito kod sredovječnih muškaraca. Terapija je totalna kirurška ekscizija. Prezentirali smo slučaj 63-godišnjeg muškarca sa malim tumorom na vratu koji je prisutan 5 godina. Dijagnoza je postavljena na osnovi citološke punkcije koja je rađena pod kontrolom ultrazvuka, a zatim potvrđena na histologiji. Citološka punkcija može biti vrlo korisna u postavljanju dijagnoze prije ekscizije.