

Bite Splints in General Dental Practice

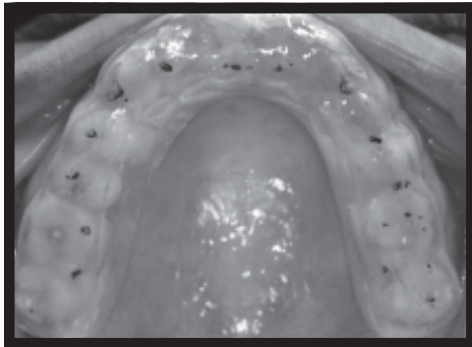
By Sven E Widmalm, DDS, PhD.

This handout is not supposed to be the only basis for working with bite splints. It has to be complemented with information from instructors assigned to help in clinics.

Introduction

A bite splint (synonyms: occlusal splint, bite plane, night guard) is a removable appliance, usually fabricated of resin, most often designed to cover all the occlusal and incisal surfaces of the teeth in the upper or lower jaw. It is being used frequently in treatment of patients with temporomandibular joint disorders (TMD) and related diseases such as tension headache

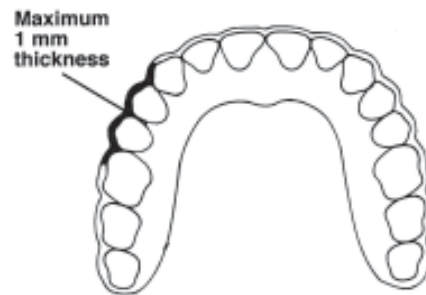
function, and jaw muscle function affects the way the TMJ functions. Therefore changes in the patient's occlusion will at least sometimes have some effect on the jaw muscles and the TMJ structures. The effect can be direct by changing the relations between the intracapsular TMJ elements or indirect by affecting the muscles' working conditions. In extreme conditions changes in occlusion may lead to displacement and destruction of the TMJ disks. Occlusal interferences may thus cause internal TMJ derangement. However,



Plane maxillary splint. The articulator paper markings are from contacts with mandibular cusps and incisal edges. It is desirable that all supporting cusps make contact with the splint at jaw closing.

and neck pain. One advantage with bite splints is that they provide a relatively easy, inexpensive and non-harmful way to make reversible changes in the occlusion. The goal for bite splint treatment is mainly to improve jaw muscle and TMJ function and to relieve pain related to dysfunction of those systems. The most common reason for bite splint prescription is, however, bruxism.

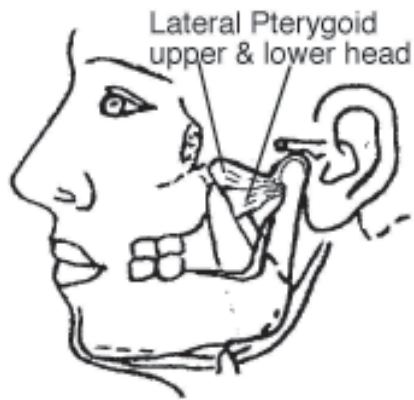
To evaluate the possible role of occlusion in the etiology of TMD and jaw muscle dysfunction in patient examination it is necessary to have a good understanding of functional jaw muscle and TMJ anatomy. Occlusion affects the way jaw muscles



Schematic drawing showing the outline of a maxillary bite splint of Michigan type.

internal derangements such as disk displacement may certainly be caused by a number of other factors, for instance trauma to the jaw. Such a displacement may change the occlusion and make it unstable with observable interferences. The role of interferences is complex and there is no general agreement about the role of interferences in TMD etiology.

There is no general agreement about if and why splint treatment may have a beneficial effect. Some researchers have found that about 80% of their patients received some benefit from splint therapy. Some claim, however, that the only effect is placebo. With such a divergence in opinions about the value of splint treatment, it is understandable that



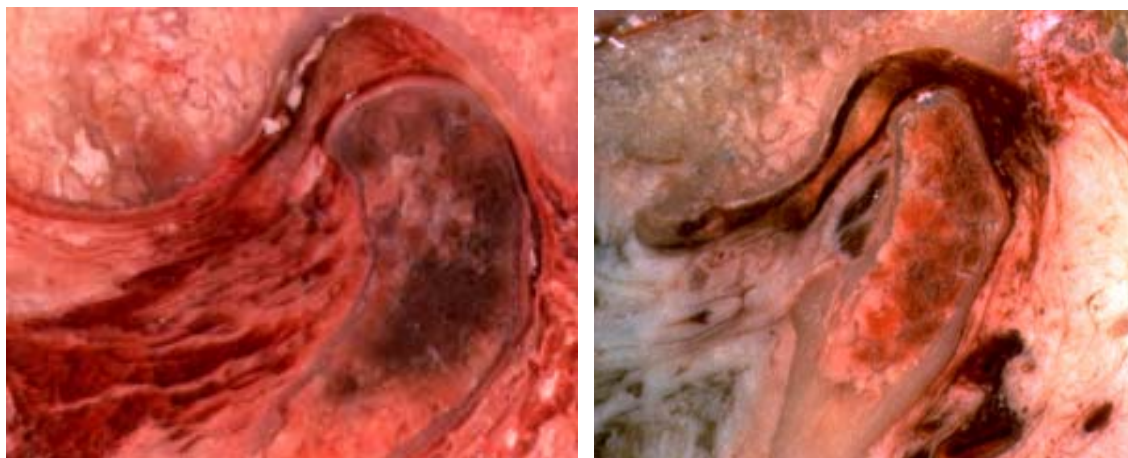
This figure illustrates the importance of looking at occlusion, jaw muscles, and the temporomandibular joint (TMJ) as units which are dependent upon each other in function. That is we need to have good knowledge about all units to treat any of them and preserve optimal function of the stomathognathic system.

- To protect the teeth in bruxing patients.
- To protect the cheek and/or tongue in patients with oral parafunctions.
- To stabilize unstable occlusion.
- To promote jaw muscle relaxation in patients with stress related pain symptoms like tension headache and neck pain of muscular origin.
- To test the effect of changes in occlusion on the TMJ and jaw muscle function before extensive restorative treatment.
- To eliminate the effect of occlusal interferences.

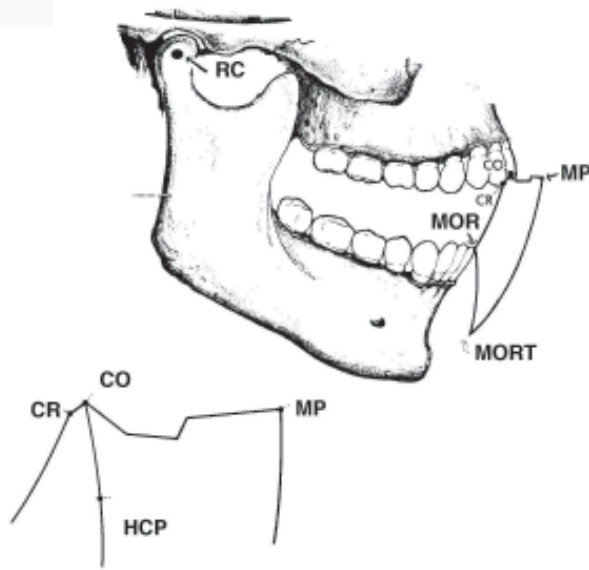
no consensus has been reached about pros and cons of different designs.

Numerous variations in design, and explanations for its possible effect, have been published since Karolyi 1901 described his splint. It is difficult to prove or disprove the advantages of one type or another. There are often large discrepancies between the signs observed by the therapist and the symptoms described by the patients. Most of what we know about splint design and use is based on “clinical experience”. Still, the clinician should not hesitate in suggesting conservative splint treatment when he/she sees a reason for it. Compared to most other treatment modalities, it is an inexpensive, non- invasive, reversible procedure which, according to most clinically experienced authors, has a high success rate.

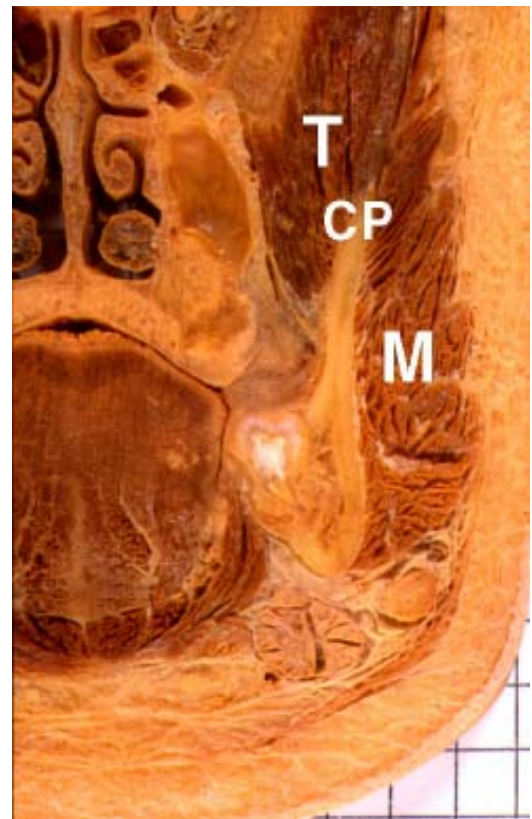
A reasonable assumption seems to be that rigid rules for the design of a splint are less justified and that a splint, following a few basic principles, is well justified for the following purposes:



Sagittal sections through one TM joint with the disk in normal position (left) and another joint with the disk displaced anteriorly (right). So called repositioning splints were for a while often used in attempts to help the disk go back and stay in a normal position.



The well known Posselt-diagram shows the so called border movements of the lower jaw (mandible). Impaired ability to perform such movements is an important sign of TMJ dysfunction. It is important to make notes about the patient's ability to perform jaw movements before and during bite splint treatment. RC=rotation center (center for the hinge axis movement when the first part of jaw opening occurs without translation of the condyle). CO=central occlusion or the position of maximal intercuspitation. CR=centric relation. MOR=maximal opening without translation. MORT=maximal opening with rotation and translation. HCP=habitual closing path. MP=maximal protrusion. (Modified after Ramfjord & Ash, 1983).

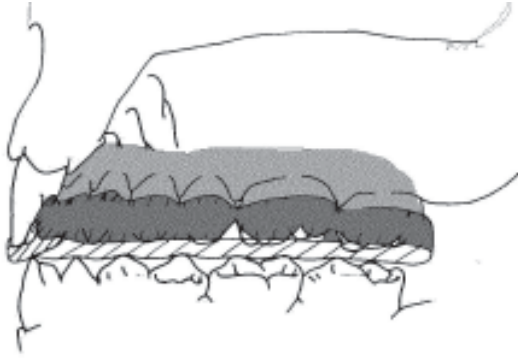


This coronal (frontal) section through the area of the third molar shows some of the most important jaw closing muscles, the masseter (M) and the temporalis (T) muscles. Pain in those muscles are important signs in TMJ muscle dysfunction and a common reason for bite splint treatment. Note especially the insertion of the temporalis muscle into the coronoid process (CP). Tenderness in this area is often found at intraoral palpation on TMD patients.

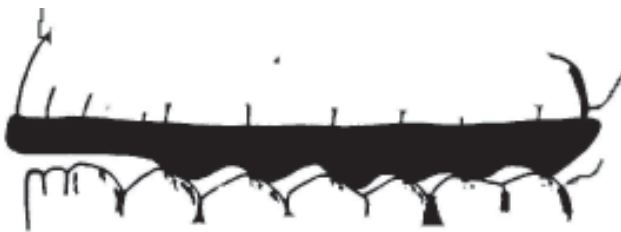- To unload the TMJ in patients with acute TMJ pain of intracapsular origin.

Bite splints can be classified according to:

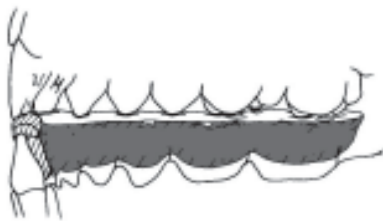
- Material used for fabrication.
- Location of placement.
- Design of area for contact with opposing teeth.
- Effects on condylar position at clenching.
- Specific purposes.



Sagittal section through a plane maxillary splint illustrating one of the important principles namely that all supporting cusps in the lower jaw should make contact with the splint.



Repositioning splints guide the mandible into a position that facilitates repositioning of a displaced disk.



Mandibular splint with the occlusal surface in soft cured acrylic.

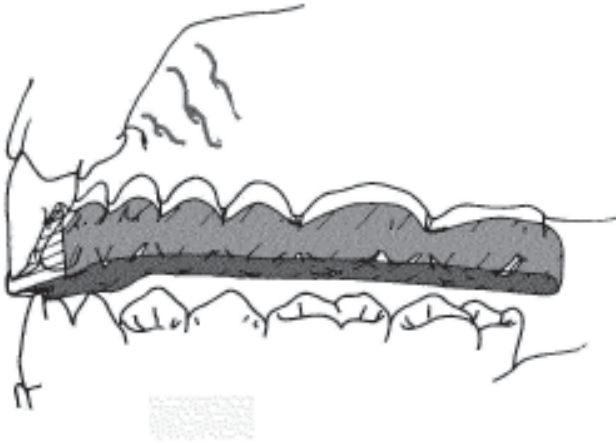- Splints may for instance be classified as follows:
- A) Splints which make balanced contacts with all opposing teeth at jaw closure
 - a) Causing a minimal increase of vertical allowing the patient to close with a “hinge axis movement”. That is the rotation centers of the condyles are not changed.
 - b) causing a more than minimal increase of the vertical but still without changing the condyles’ rotation centers.
 - c) Increase the vertical and causing a translatory movement of the condyles at the final part of closure (thus changing the rotation centers).
 - B) Splints that make contact only with parts of the opposing arch at jaw closure.
 - a) Contacts only with the anterior teeth in the opposing arch.
 - b) Contacts only with the molar and premolar teeth in the opposing arch.

Splints in groups A.a, b have a minimal risk of causing permanent changes in occlusion. Splints in groups A.c and B can cause such changes if used for longer than a few (4-6) weeks. Examples of Group A.c splints for instance, are the so-called repositioning splints. Those have been tried to keep a repositioned disk in a normal position during healing. However, the risk for permanent detrimental changes in the occlusion make the use of repositioning splints less advisable.

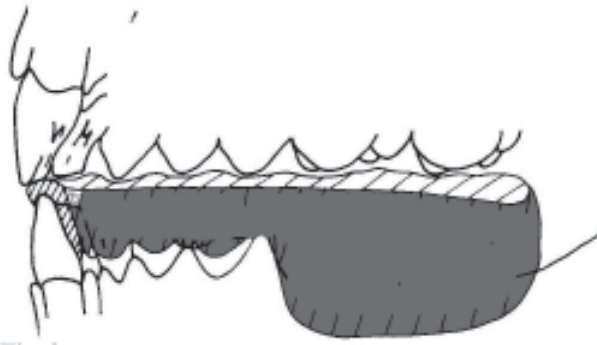
Long term use of splints that make contact only with some of the opposing teeth may cause serious irreversible changes in the occlusion. Splints where the only contacts are with the incisors may cause an anterior open bite. Splints with contacts only in the molar regions may cause intrusion of the teeth there. There are unfortunately quite a few TMD clinicians who advocate the long term use of such

splints without first trying other possible remedies.

Most patients use their splints only during sleep to protect them from the effects of involuntary parafunctional motor activities like bruxing, clenching, tongue pressure, etc. Those who can not control such habits when awake may need to use the splint during daytime hours. There are no fixed rules for the length of time that a conservative plane splint (a splint that does not change the jaw relations except for a minimal increase of vertical) should be used. Some patients can discard them after a few months; others may need to



Relaxation plate (Sved plate). Only the opposing anterior teeth make contact with the splint. It has been recommended for patients with muscle pain if the plane splint is without effect. It should not be used for more than a few weeks and never without supervision by dentist. Long term use may cause irreversible occlusal changes.



If teeth are missing in the lower jaw a mandibular splint may be preferred. It is important to create stable, balanced occlusion over full mandibular and maxillary arches. This means that splints sometimes may have to be made both for the upper and for the lower jaws. Missing teeth can be replaced by adding artificial teeth to the splint which then can act both as a splint and a temporary partial denture.

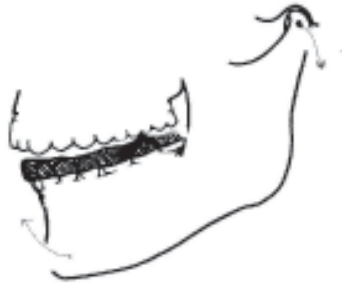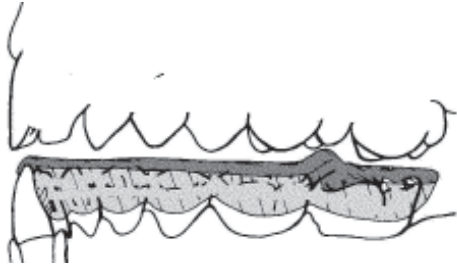
Hard splints can not be used in children for more than short periods because they may not fit after a relatively short time and therefore interfere with the normal growth pattern. A soft splint may also be indicated in adult patients who can not adjust to a conventional splint because they feel it is too tight, creating tension.

continue using them for decades. Splints that do not cover all teeth with balanced contacts with the opposing teeth, like Sved plates, repositioning splints, etc., should, however, not be used for longer periods than four to six weeks. During that time they may have to be used continuously and removed only when brushing the teeth. Irreversible changes may occur in the occlusion if a repositioning splint is used for longer periods than about six weeks.

As a general rule a non-specialist should never encourage a patient to use any type of splint for more than a few months except for cases where the teeth need to be protected because of bruxing, clenching habits. Side effects from long term use of splints can be severe and non-reversible especially those from unsupervised mandibular advancement splints and splints covering only the molar and premolar areas.

Splint Material

Many metal materials have been tried in the past such as gold, silver, - even lead! Most splints are now made using heat-cured acrylic. Splints can also be made in soft acrylic or using light cured composite. Soft acrylic splints are usually made for the lower jaw, can be made quickly by the dentist and are indicated for short time use in patients with acute pain and/or dysfunction symptoms caused by muscular hyperactivity or acute trauma. This type is also indicated in children with deciduous teeth if they have signs and symptoms of severe bruxism. Gnashing the teeth may serve the purpose to adjust the occlusion of the deciduous teeth while the jaws are growing. However, a splint may be indicated if the children develop pain symptoms, if the gnashing sounds are disturbing or if the permanent teeth are affected, showing signs of nonfunctional wear.



Bite splint with pivot was introduced by Krogh-Poulsen and supposed to be helpful in patients with disk displacement. The proposed effect on the condyles (pulling them down at clenching) has been questioned by several authors and this splint type is now seldom used. A slightly different type of distraction splint has, however, been found beneficial in patients with juvenile rheumatoid arthritis.

Soft acrylic splint for daytime use are indicated in patients when night time use of a hard splint is not sufficient to relieve the symptoms or break the habit during daytime. A soft splint can be used during daytime to help in breaking the parafunctional habit, either alone or used in one jaw with a conventional hard splint in the other.

Soft splints do not last as long as those made in hard acrylic and have to be replaced when they are worn down or have lost their fit. They are simple to fabricate and are more easily adjusted to adequate contact patterns due to the softness of the occlusal surface. Replacing the occlusal contact area of a hard cured splint with soft cured acrylic makes a variation of the splint. Some patients prefer the cushion effect created by the soft acrylic.

Maxillary or mandibular splint?

Most splints are maxillary. Many clinicians find it easier to make a stable splint with good retention and adequate cuspid guidance in the upper jaw. If the splint is to be used during daytime it may be preferred, for esthetic reasons, to make a mandibular splint which may be less visible.

Extension onto the facial surfaces of the incisors should be avoided. Besides not being esthetic it may prevent adequate lipseal. Breakage of lipseal may lead to mouth breathing during sleep with harmful side effects. Extension onto the incisal facial surfaces is not needed for retention which can as well be obtained by extension onto the buccal surfaces of molars and premolars. Such coverage is not visible and does not prevent lipseal. If not enough retention

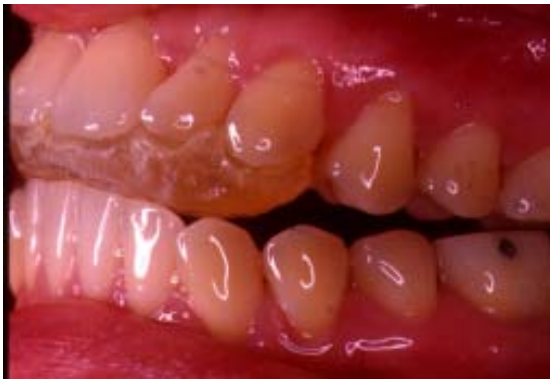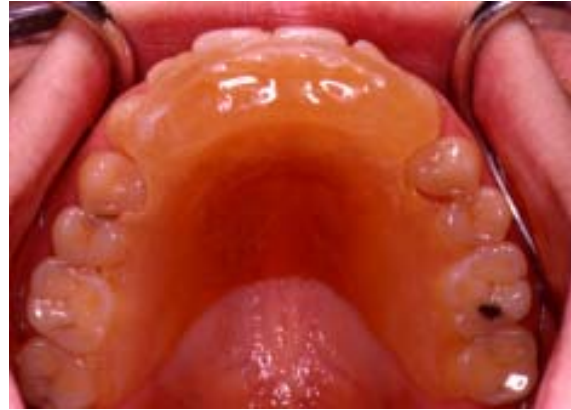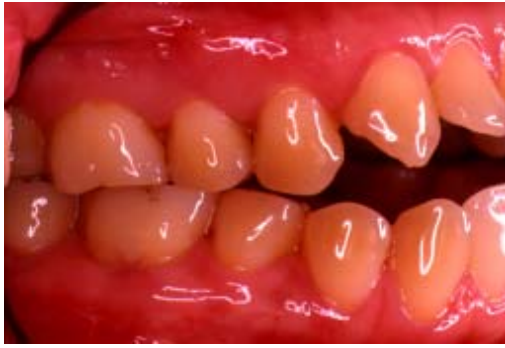can be obtained that way a couple of simple clasps may be added.

A maxillary splint can also be made “invisible” in most cases if extension onto the facial surfaces is avoided. If teeth are missing the splint should be made for the jaw with the fewest teeth. This is especially important if molar support is lost. Some patients have successfully used splints in both the upper and the lower jaws. If molars and premolars are missing in both jaws it may be advisable to make both an upper and a lower splint or to first restore occlusion in at least one jaw with prosthodontic reconstruction.

Without specific reasons for a mandibular placement, a splint should be made for the upper jaw. A mandibular splint encroaches more on the space normally occupied by the tongue. In patients with horizontal overjet, a mandibular splint has to be extended in the anterior direction to obtain anterior support. Such a “buttress” may interfere with normal lipseal and irritate the lower lip thereby triggering parafunctional activity in the orbicularis oris. Anterior contact may not be possible in all cases with large horizontal overjet.

Following here are descriptions of some of the most used types of splints.

A Michigan (MI) type splint (plane splint with cuspid guidance) is usually placed in the upper jaw covering all the maxillary teeth, giving the opposing mandibular teeth balanced, even contacts at habitual closure.



There are serious dangers with long term use of non-conservative splints, especially those making contacts with only some of the opposing teeth. In this case a splint which made contact only with the anterior mandibular teeth had been used for more than 10 years. Acute TMJ pain may be relieved but the risk for creating an anterior open bite should be explained to the patient before use.

In a MI splint all mandibular teeth, except the cuspids, are discluded at protrusive and lateral movements. This type is recommended in patients with signs and symptoms of jaw muscle hyperactivity (bruxism, clenching). If teeth are missing, the splint is usually made in the jaw where most teeth are lost. If molar support is lost in one jaw only, the splint should most often be made in that jaw with a saddle extended where teeth are missing. Some patients may feel that a mandibular splint is uncomfortable and a maxillary splint may then be tried in spite of lost mandibular occlusal support.

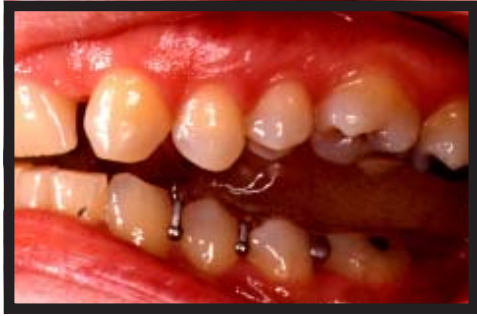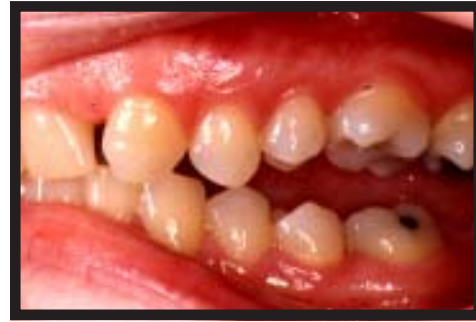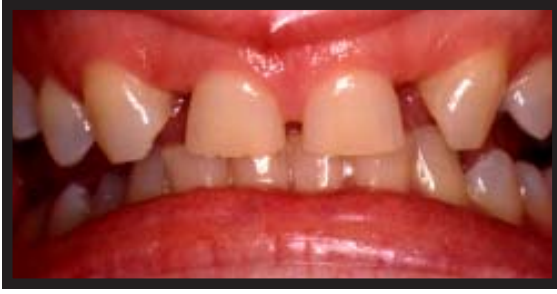Cuspid Guidance. A cuspid guidance is created to provide a rise in lateral and protrusive movements, so that the only contacts are between the mandibular cuspid apex and the cuspid guidance. The mandibular cuspid should slide on a flat area inclined only in the sagittal plane during protrusive and in the coronal (frontal) plane during lateral movements.

Ideally cuspid guidance should be on the apex of the mandibular cuspid. It may be on the mesial cuspid ridge of the mandibular cuspid during protrusive movement or on the distal cuspid ridge of the mandibular cuspid during lateral movement. No guidance should be on the axial surface of the mandibular cuspid! There should be no posterior contacts in protrusive and balancing and no incisal contacts in protrusive.

In the natural dentition a slide from CR to CO takes place mostly with a vertical and sometimes also with a lateral shift in the mandible's position. One important goal in the fabrication of a plane splint is to create an area around the contacts at habitual closing which makes it possible for the mandibular teeth to move from CR to a CO position without such vertical or lateral shifts. It is considered by many clinicians that part of the beneficial effect of the plane bite splint is because of the elimination of such shifts.

Plane splints without cuspid guidance. For esthetic reasons some patients may prefer to have splints without cuspid guidance. It is easier to make a plane splint "invisible" if that feature is excluded.

A common feature to the above two types is that balanced contacts with all opposing supporting



In this case the patient had been given a splint which made contact only with the opposing posterior teeth. Acute pain was relieved but returned and new layers of acrylic were added which may explain which seems to be intrusion of the posterior teeth and a posterior open bite. The patient had this type of splints for a period of about 10 years. She had chronic TMJ pain. Surgical and orth-

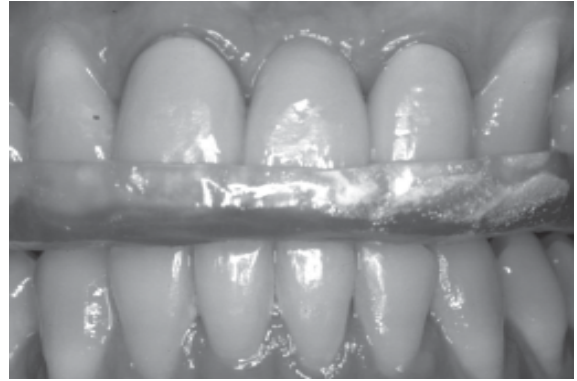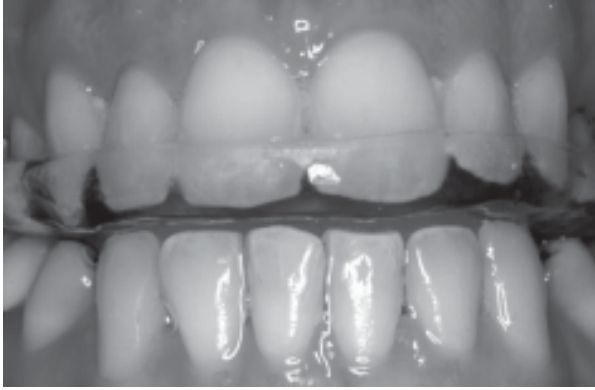
odontic consults deemed it not possible to recreate a stable occlusion. Study casts and/or photos showing the occlusion before start of bite splint treatment should be kept in the patient file but were in this, as in many similar others, not existing.

cusps and the incisal anterior teeth edges should be achieved. There are, however, some clinicians with long time experience from treating TMD patients who claim that better results are achieved if the anterior contacts (incisal areas) are very light or removed.

Bite splint according to Shore. This splint has a design similar to the plane splint but does not extend onto the facial or buccal surfaces of the teeth, and covers the entire palatal area. It may be preferred by some patients who need to use the splint also during daytime, for esthetic reasons, because it can be made less visible. In some patients with parafunctional tongue activities, such a palatal extension may be felt more comfortable. A Michigan splint can easily be changed into this type by removing facial and buccal extensions, adding palatal cover and, if needed, securing adequate retention with clasps.

Relaxation plate (Sved plate). Only the opposing anterior teeth make contact with this splint. It is not recommended if the patient has acute pain in the TMJ or feels pain or soreness at palpation of those areas. It is easy to change a plane splint into a relaxation plate or vice versa. It is recommended that the relaxation type is tried in patients with acute or chronic muscle pain if the plane splint is without effect. It is usually placed on the upper teeth with an incline in the anterior part giving contact only with opposing cuspids and incisors. It should be used only during nighttime and not more than 10-12 hours/day. There is a risk for intrusion of teeth, which has to be explained to the patient before splint delivery. Regular checkups are, as always, important.

Mandibular splint with lingual bar. Unlike the Sved plate, this type is supposed to be used during daytime. Its primary purpose is to help patients who can not control oral parafunctional activities when awake and do not feel comfortable with a splint of the Shore-type. The splint does not cover the cuspids or the incisors and should have balanced contacts in the premolar and molar areas both in CO and in CR. It is most often adjusted to achieve group contact on the working side at lateral movements. Precautions are the same as for the relaxation type splint.



The left splint was made in heat cured acrylic and the right one in light cured composite (LCC). LCC is an excellent alternative when treating patients with acute pain because the splint can be made “in house” and fabricated in about one hour after casts have been prepared. Some dentists fear the color makes the appearance less attractive. It is, however, not necessary to extend the splint onto the facial surfaces of the anterior teeth. Such coverage should instead be avoided in all splints because it may prevent lipseal and lead to mouth breathing during sleep. Retention can be secured by simple clasps if needed and there are no basis for believing that coverage is needed to keep the anterior teeth from “moving”.

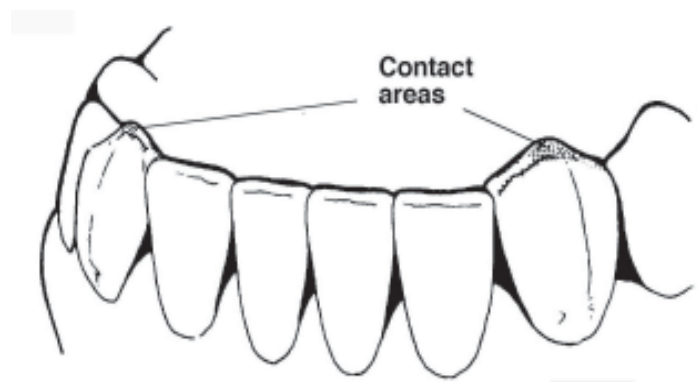
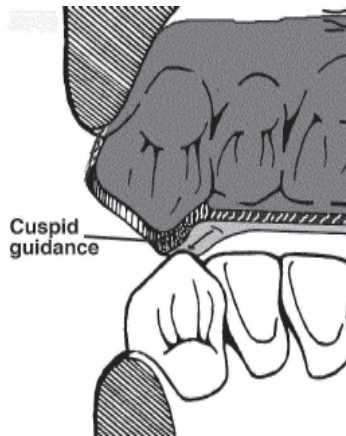
Repositioning splints. Plane bite splints increase the vertical but should not in any other way affect the position of the mandible when habitual clenching occurs on the splint. Repositioning splints guide the mandible into a different position at closing, which is supposed to facilitate repositioning of the disk and reduce the load on retrodiscal pain sensitive areas. These splints are sometimes indicated for short-term use to keep a recaptured disk in a normal superior position for instance when a displaced disk has been recaptured by manipulation.

Bite splint with a pivot. This type was introduced by Krogh-Poulsen about 40 years ago and was supposed to be helpful in patients with disk displacement. The proposed effect is that the condyles are pulled downwards upon clenching on the pivot, thereby relieving traumatic load and giving the disk freedom to reassume a normal position. Today it is seldom used because most patients find it uncomfortable.

Cap splints. A cap splint can be described as an intermediary between a splint and a bridge. It is useful for temporary reconstruction before final decision about design, vertical dimension, etc. It is often made in metal with the occlusal surface in hard acrylic.

Combination splint/partial denture and splint/orthodontic appliance. Missing teeth can easily be replaced by adding artificial teeth to the splint. A Shore splint may function as a temporary partial denture by adding artificial teeth. Another fringe area exists between occlusion and orthodontics. There are numerous combinations of splint and orthodontic appliances. An ‘invisible retainer’ may simultaneously function as a soft acrylic splint.

Others. Patients with oral parafunctions like cheek biting, tongue thrust, large diastemata, etc. may benefit from a splint with extensions or enlargements designed in a way that will keep the cheeks from being pinched or the tongue from pressing against the lingual surfaces of the teeth.



Cuspid guidance is a feature of the Michigan splint that has been found clinically useful when added to the plane splint. It functions by breaking all contacts, except for between the guidance and the apex of the mandibular cuspids, during lateral and protrusive movements. It is relatively difficult to create and should be avoided unless the dentist is willing to give enough time to careful adjustments. It is for instance important to establish contact only with the apex of the opposing cuspid and not with the axial surfaces during movement.

Fabrication of splint

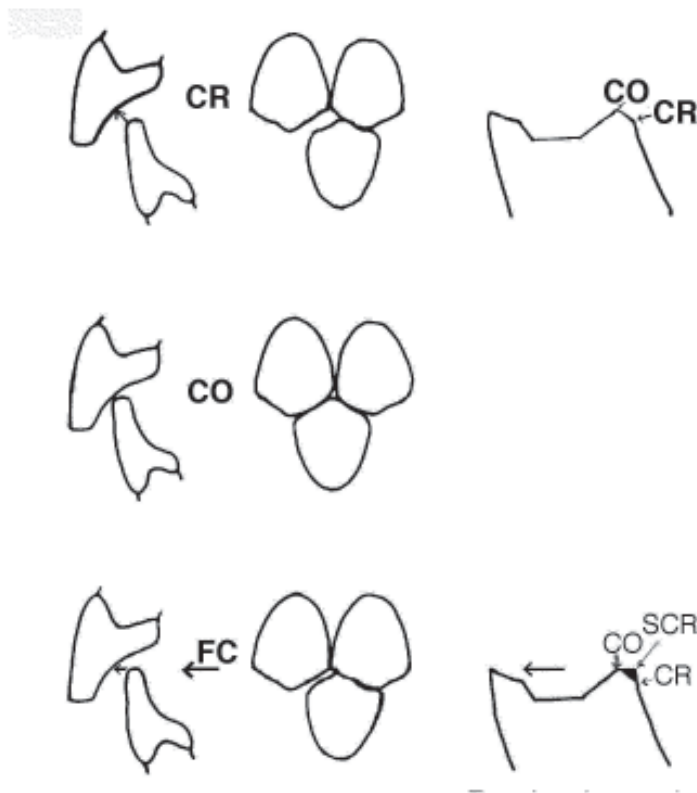
Many procedures can be left to a laboratory but any dentist more seriously involved in treating TMD patients should be able to make and deliver a splint shortly (1-2 hours) after taking impressions. This is especially important if patients have acute pain but also if they have to travel a long way for treatment. Using light cured composite for instance, a splint can be made “in house” and delivered about one hour after the casts have been mounted in articulator.

The main procedures are

- Taking and pouring impressions
- Face bow recording
- Bite registration
- Mounting of casts
- Blocking out of undercuts
- Waxing the splint or forming of composite
- Curing of acrylic or composite
- Delivery and maintenance of splint

Some of those procedures may be omitted without jeopardizing the end result. It is not always needed to make a face bow recording or bite registration. A few important points should be stressed. If impressions are taken using alginate they should be poured **immediately**, never waiting more than 1-2 minutes, to avoid dimensional changes. A high quality stone has to be used and mixed with the right proportions of powder and water. A most common mistake is mixing the plaster with too much water. A good choice is for instance Velmix which should be mixed with the proportions 100 g powder to 20 cc water. Other things to remember are that the tray should be large enough to go about 5 mm beyond the most posterior teeth. When placing the tray its essential to not have “break through”, and the thinnest alginate above the occlusal surfaces should be at least 2 mm.

An accurate bite registration is difficult to make and deserves special attention. The material used



“Freedom of centric” means that the lower jaw is able to move from centric relation (CR) to centric occlusion (CO) without restrictions in an area with a diameter of 1-2 mm. In the natural dentition this movement has naturally a vertical component but a lateral slide should, according to some clinicians, be avoided and corrected if larger than 1-2 mm. In the Michigan splint the vertical component too should be eliminated. The goal is to let the mandibular supporting cusps slide between contact in splint centric (SCR) and in habitual contact position (CO) without vertical or lateral shift.

(mostly wax) should not cover the facial surfaces of the incisors and should not make contact with the soft tissues. It is necessary to see the incisal edges of the anterior teeth to ensure that they are aligned the same way with and without checkbite. The wax should never touch the papillae. If it does those tissues are displaced and the wax will not fit on the cast.

Centric relation (CR) can not be properly registered in most patients with acute signs and symptoms of TM disorders. It may even be contraindicated to try to make such a registration. Any pushing of the mandible in a patient with TMJ inflammation and/or internal derangement can increase the tissue injury. It is acceptable and often preferable to register only the position into which the patient habitually closes. Be especially careful with patients with lateral deviations after the first tooth contact at clenching. If the patient has a lateral slide-in-centric, check that the closing movement stops before any lateral slide takes place. Make sure that the wax is thick enough to register a position before the lateral slide.

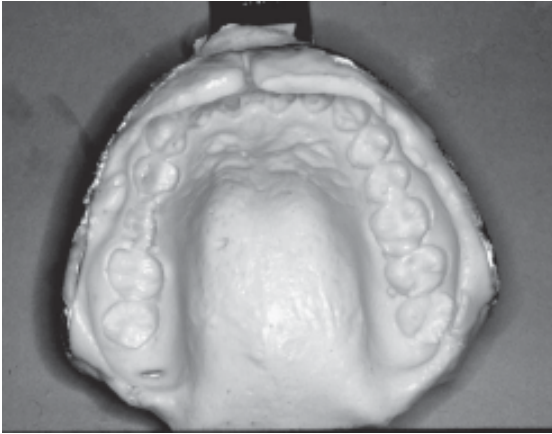
Always try to take a checkbite if:

- There is a large discrepancy between CR and CO.
- There is a significant lateral deviation of the mandible on opening and closing.
- There is a significant lateral slide in centric.

Checkpoints for Centric wax bite registration

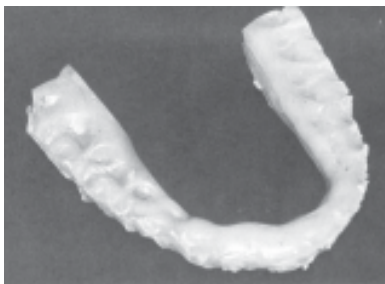
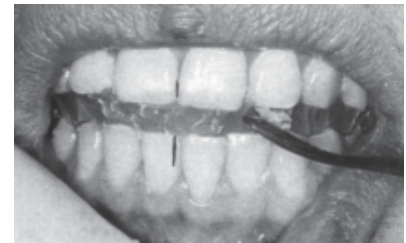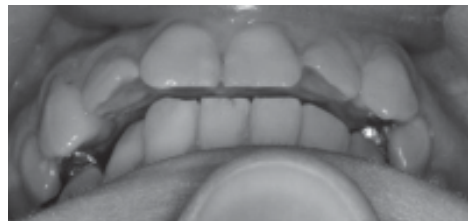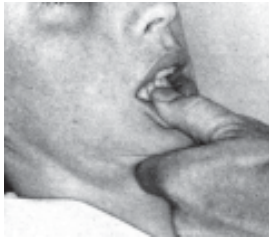- No perforations of wax.
- Stable position on maxillary teeth and on casts.

Face bow registrations are not mandatory but the casts need to be mounted on an articulator, which makes it possible to have normal values of the distance between the casts and the condylar elements.



Taking a good impression may be the most important step in the bite splint fabrication because if the impression is bad nothing can later be done to provide a splint of the best quality. A common fault is to use too small trays and/or let the tray make contact with the teeth (causing a “break-through”). The alginate should not be thinner than 1-2 mm in any area. Break through is acceptable if it occurs in a soft tissue area not to be covered by the splint. The flow of alginate beyond the lingual part of the tray as seen in this picture is not acceptable. It may

cause the patient to gag and is easily avoided by tilting the tray at the insertion bringing it up to first make soft tissue contact in the posterior soft tissue areas and the bringing the anterior part of the tray up into its final position. Another important rule is to always pour alginate impressions immediately in high quality stone mixed with correct proportions of water and powder. It is a common mistake to mix the plaster too thin.



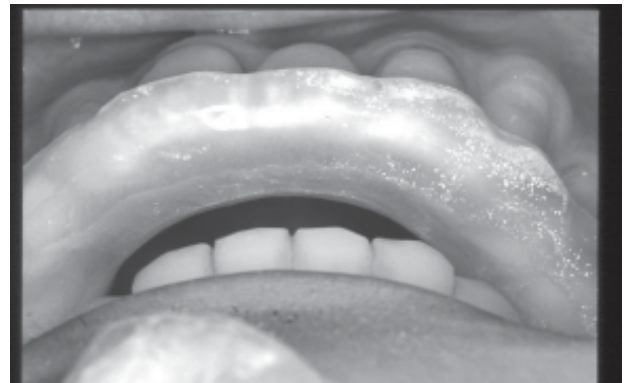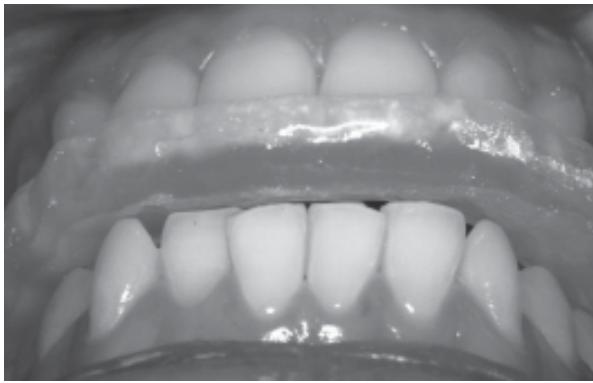Casts may be mounted in the position of maximal intercuspitation (CO). An accurate CR checkbite can hardly be made if the patient has acute pain and/or internal TMJ derangement. Many clinicians prefer to take a checkbite in “open vertical” especially if there is a large lateral slide from CR to CO or disk displacement with reduction. If a checkbite is made it is most important to not let the wax extend onto the facial surfaces of the anterior teeth or touch soft tissues. If the wax

makes contact with soft tissues it will not fit on the cast. There are some commercially available large prefabricated waxrims which, if used, make it almost impossible to get an accurate recording.

Splint delivery

Freedom of Centric. Flat, “horizontal” area, 0.5 - 1.0 mm in diameter, allowing smooth slide without vertical component, between CR and CO. Use different colors of articulating paper for CO and CR.

Borders of splint. Extension not more than 1 mm. in the horizontal plane beyond the occlusal surfaces of the maxillary teeth, minimal thickness adjacent to the second molars and minimal thickness labial to the



The checkbite for the above case was made using a prefabricated wax rim that covered large parts of the facial surfaces of the incisors and probably taken with the mandible in a protruded position. The left picture shows how the patient's mandible at closing onto the finished splint has been guided into an anterior position. The right picture shows the same splint with the CR position achieved with assistance from the examiner. It is obvious that this splint could not give balanced contact with all mandibular teeth when closing into CR and may cause the patient to habitually go into a protruded position.

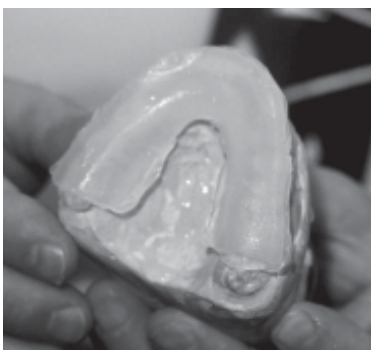incisors.

The finished splint should be smooth. Interproximal buccal areas are used for retention. If excessive they should be blocked out to avoid too much retention.

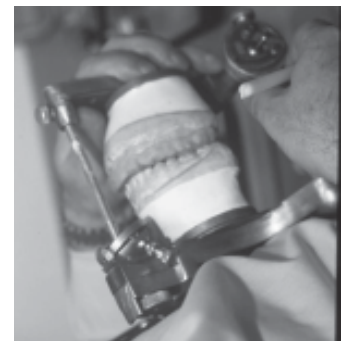Most important is to check the splint for not having too much retention. Especially undesirable are gross extensions onto the facial surfaces of the incisors. Such extensions are really not needed at all. Improved retention can, if needed, be achieved by adding simple ball clasps in the molar or premolar areas or by adding acrylic or composite in the molar interproximal areas on the lingual of the appliance.

Mark occlusal contacts with thin (12 microns or less) articulating paper. Thick articulating paper gives enlarged, smudged markings. Check lateral and protrusive movements for interferences with thin articulating paper and with shimstock. When checking for CR and CO use different colors!

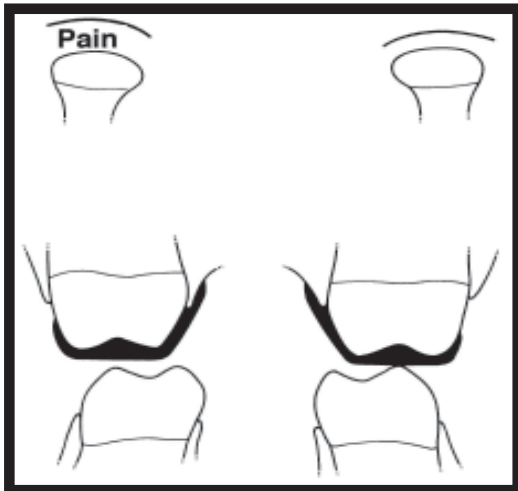
Reduce the appliance as much as possible in the labial areas and check for lipseal. Avoid excess of acrylic in the external areas by "scalloping" into the buccal embrasures leaving about 1-mm thickness of



Light cured composite can be used for fast splint fabrication. The method is especially valuable when treating patients with acute TMD problems. For instance if a patient comes with acute disk displacement it is very important to place the splint immediately. The risk for



irreversible changes can naturally be expected to increase more the longer the patient has to wait for the treatment splint. The composite is placed on the cast and adjusted on the articulator mounted casts. It can then be cured in a special unit which takes about 90 seconds.



After the delivery of a splint the dentist has to be ready to see the patient and make adjustments. The soft tissues in a TMJ with inflammation may swell or shrink causing loss of balanced contacts. Creating balanced contacts is supposed to protect the sensitive areas from mechanical pain producing pressure.

acrylic.

Polish all areas to a shiny, glossy finish except where the mandibular teeth cusps make contact. If those areas are polished after adjustment some contacts may be lost. Use a soft rag wheel with wet pumice and a low speed engine to avoid heating and warping of the acrylic. A final polish may be achieved with a rag wheel and Bendick®. Be sure the patient can place and remove the splint. Instruct the patient in the care and maintenance procedures. Reappoint the patient for splint adjustment within one to two weeks after insertion. Be ready to see the patient even earlier. Acute pain may be caused by inflammation in intracapsular TMJ tissues. They may swell or shrink during different stages of the disease period. As one beneficial effect of the splint is supposed to be its unloading effect it is important to maintain balanced occlusion. Therefore repeated adjustments may have to be made for quite long periods. Eliminating all posterior contacts and keeping the anterior may temporarily relieve pain symptoms. This is often only a short term effect and using such a splint for longer periods than 4-6 weeks may lead to extrusion of posterior teeth and/or intrusion

of the anterior teeth. It is desirable but not always possible to make and maintain contacts with all opposing balancing cusps. The main goal in splint adjustment is to eliminate any unstable relations.

Checkpoints

- Splint fully seated.
- No rocking.
- adequate retention.
- Even bilateral and posterior contacts.
- No balancing contacts.
- No incisal protrusive contacts.
- Splint comfortable relative to bulk.
- Lipseal.
- Feather edge on palatal side.
- Check for splint centric and CR contacts.
- Do not polish the splint centric contacts.

REFERENCES

Ash, M. M. Jr. & Ramfjord, S. P. 1982 An Introduction to Functional Occlusion. W. B. Saunders Company, Philadelphia.

Krogh-Poulsen, W. 1981 Treatment of oro-mandibular dysfunction by means of occlusal splints. Scan Odont no.1, pp 5-13.

Krogh-Poulsen & Olsson, A. 1968 Management of the occlusion of the teeth. Facial pain and mandibular dysfunction. Eds. Schwartz, L. & Chayes. W. B. Saunders Co., Philadelphia.

Lundh, H. 1987 Correction of Temporomandibular Joint Disk Displacement by Occlusal Therapy. Swedish Dental Journal, Supplement 51.

Ramfjord, S. P. & Ash, M. M. Jr. 1983 Occlusion. W. B. Saunders Company, Philadelphia.