

# UC Irvine

## Clinical Practice and Cases in Emergency Medicine

### Title

CPC-EM Full Text Issue

### Permalink

<https://escholarship.org/uc/item/8r84w12h>

### Journal

Clinical Practice and Cases in Emergency Medicine, 1(3)

### ISSN

2474-252X

### Author

Hernandez, Nancy G.

### Publication Date

2017

### License

<https://creativecommons.org/licenses/by/4.0/> 4.0

Peer reviewed

# CPC Emergency Medicine

Volume I, Number 3, August 2017

Open Access at [www.cpcem.org](http://www.cpcem.org)

ISSN: 2474-252X

## *Clinical Practice and Cases in Emergency Medicine*

*In Collaboration with the Western Journal of Emergency Medicine*

### Clinicopathological Cases from the University of Maryland

- 152 29-year-old Woman with Dyspnea**  
*E England, M Callahan, LJ, Bontempo, ZDW Dezman*

### Case Reports

- 159 Accidental Ingestion of Hearing Aid with Exposed Battery**  
*EB Kunststadt, MI Langdorf*
- 162 Management of Complex Facial Lacerations in the Emergency Department**  
*A Badeau, S Lahham, M Osborn*
- 166 Pediatric Death Due to Myocarditis After Exposure to Cannabis**  
*TM Nappe, CO Hoyte*
- 171 Posterior Reversible Encephalopathy Syndrome Presenting as Stroke Mimic**  
*D Frick, M Huecker, H Shoff*
- 175 Takotsubo Cardiomyopathy Presenting as Wellens' Syndrome**  
*RS Taylor, L Skjerli, J Ashurst*
- 179 Acute Myocardial Infarction with Simultaneous Gastric Perforation**  
*A Kaplan, D Schwarzfuchs, V Zeldetz, J Liu*
- 183 Occult Iliac Deep Vein Thrombosis in Second Trimester Pregnancy: Clues on Bedside Ultrasound**  
*R Avula, M Niemann, N Dorinzi, K Robinson, M Sharon, J Minardi*
- 187 "A Large Hiatal Hernia": Atypical Presentation of Gastric Volvulus**  
*A Kiyani, M Khosla, V Anufreichik, KY Chuang*
- 190 A Near Fatal Sneeze Spontaneous Splenic Rupture: A Case Report and Review of the Literature**  
*GW Reinhold, TK Melonakos, DT Lyman*
- 194 Repeat Point-of-Care Echocardiographic Evaluation of Traumatic Cardiac Arrest: A New Paradigm for the Emergency Physician**  
*B Thomas, E Durant, S Barbant, A Nagdev*

*Contents continued on page iii*



**UC Irvine Health**



**A Peer-Reviewed, International Professional Journal**

ACOEP's

# SCIENTIFIC ASSEMBLY

# SAVE THE DATE

NOVEMBER 4-8, 2017

HYATT REGENCY, DENVER, COLORADO

## Save the Date for ACOEP's Flagship Conference

Don't miss out on:

- Keynote speaker Zubin Damania, MD, aka ZDogg
- Kickoff Party in downtown Denver presented by Island Medical Management
- Expanded Tachy Track
- Customizable experience through breakout lecture series
- Pre-Conference Tracks including: Wilderness Medicine, Resuscitation, Advanced Ultrasound, Advanced Airway
- 7th Annual FOEM Legacy Gala: Dinner and Awards Ceremony presented by US Acute Care Solutions
- ...and much more!

Visit [www.acoep.org/scientific](http://www.acoep.org/scientific) for more information!



# Clinical Practice and Cases in Emergency Medicine

In Collaboration with the *Western Journal of Emergency Medicine*

Rick A. McPheeters, DO, Editor-in-Chief  
*Kern Medical*

Manish Amin, DO, Associate Editor  
*Kern Medical*

Mark I. Langdorf, MD, MHPE, Associate Editor  
*University of California, Irvine School of Medicine*

Shadi Lahham, MD, MS, Associate Editor  
*University of California, Irvine School of Medicine*

Shahram Lotfipour, MD, MPH, Managing Associate Editor  
*University of California, Irvine School of Medicine*

## Editorial Board

Erik D. Barton, MD, MBA  
*University of California, Irvine*

Peter A. Bell, DO, MBA  
*Ohio University, Heritage  
College of Osteopathic Medicine*

Barry E. Brenner, MD, MPH  
*Case Western Reserve University*

David F.M. Brown, MD  
*Massachusetts General Hospital/  
Harvard Medical School*

Francis Counselman, MD  
*Eastern Virginia Medical School*

Robert W. Derlet, MD  
*University of California, Davis*

Daniel J. Dire, MD  
*University of Texas Health  
Sciences Center San Antonio*

Steven Gabaeff, MD  
*Clinical Forensic Medicine*

Brent King, MD, MMM  
*University of Texas, Houston*

Edward Michelson, MD  
*Texas Tech University*

Linda S. Murphy, MLIS  
*University of California, Irvine  
School of Medicine Librarian*

Jonathan Olshaker, MD  
*Boston University*

Edward Panacek, MD, MPH  
*University of South Alabama*

Niels K. Rathlev, MD  
*University of Massachusetts  
Baystate School of Medicine*

Robert M. Rodriguez, MD  
*University of California, San  
Francisco*

Scott Rudkin, MD, MBA  
*University of California, Irvine*

Peter Sokolove, MD  
*University of California, San  
Francisco*

Samuel J. Stratton, MD, MPH  
*Orange County, CA, EMS Agency*

Robert Suter, DO, MHA  
*UT Southwestern Medical Center*

Scott Zeller, MD  
*University of California, Riverside*

Leslie Zun, MD, MBA  
*Chicago Medical School*

## Advisory Board

Peter A. Bell, DO, MBA  
*American College of Osteopathic  
Emergency Physicians  
Ohio University, Heritage  
College of Osteopathic Medicine*

John B. Christensen, MD  
*California Chapter Division of  
AAEM*

Amal Khalil, MBA  
*UC Irvine Health SOM*

Mark I. Langdorf, MD, MHPE  
*UC Irvine Health SOM*

Elena Lopez-Gusman  
*California ACEP  
American College of Emergency  
Physicians*

Shahram Lotfipour, MD, MPH  
*UC Irvine Health SOM*

Trevor Mills, MD, MPH  
*California Chapter Division of  
AAEM  
LSU Medical Center*

Aimee Moulin, MD  
*California ACEP  
American College of Emergency  
Physicians  
University of California, Davis*

Nicholas T. Sawyer, MD, MBA  
*California ACEP  
American College of Emergency  
Physicians  
University of California, Davis*

Robert Suter, DO, MHA  
*American College of Osteopathic  
Emergency Physicians  
UT Southwestern Medical Center*

Jan Wachtler  
*American College of Osteopathic  
Emergency Physicians*

## International Editorial Board

Pablo Aguilera, MD  
*Pontificia Universidad Catolica  
de Chile, Santiago, Chile*

Anwar Al-Awadhi, MD  
*Mubarak Al-Kabeer Hospital,  
Jabriya, Kuwait*

Arif A. Cevik, MD  
*Eskişehir Osmangazi University  
Medical Center, Eskişehir, Turkey*

Francesco Dellacorte, MD  
*Azienda Ospedaliera  
Universitaria "Maggiore della  
Carità," Novara, Italy*

Abhinandan A. Desai, MD  
*University of Bombay Grant  
Medical College, Bombay, India*

Gayle Galletta, MD  
*Sørlandet Sykehus HF, Akershus  
Universitetssykehus, Lorenskog,  
Norway*

Vijay Gautam, MBBS  
*University of London, London,  
England*

Wirachin Hoonpongsimanont,  
MD, MSBATS

*Siriraj Hospital, Mahidol  
University, Bangkok, Thailand*

Rosidah Ibrahim, MD  
*Hospital Serdang, Selangor,  
Malaysia*

Katsuhiko Kanemaru, MD  
*University of Miyazaki Hospital,  
Miyazaki, Japan*

Amin A. Kazzi, MAAEM, MD  
*The American University of  
Beirut, Beirut, Lebanon*

Steven H. Lim, MD  
*Changi General Hospital, Simei,  
Singapore*

Khrongwong Musikatavorn, MD  
*King Chulalongkorn Memorial  
Hospital, Chulalongkorn  
University, Bangkok, Thailand*

Bandr Mzahim, MD  
*King Fahad Medical City, Riyadh,  
Saudi Arabia*

Jacob (Kobi) Peleg, PhD, MPH  
*Tel-Aviv University, Tel-Aviv,  
Israel*

## Editorial Staff

Ahdilah Haswary, BS  
*Editorial Director*

Maryam Farooqui, BS  
*Associate Editorial Director*

Jimmy To, BS  
*Associate Editorial Director*

Usman Alam, BS  
*Marketing Director*

Tushank Chadha, BS  
*Associate Marketing Director*

Nancy Hernandez, BA  
*Publishing Director*

Tracy Nguyen, BS  
*Associate Publishing Director*

June Casey, BA  
*Copy Editor*

Alissa Fiorentino  
*WestJEM Staff Liaison*



# Clinical Practice and Cases in Emergency Medicine

In Collaboration with the *Western Journal of Emergency Medicine*

This open access publication would not be possible without the generous and continual financial support of our society sponsors, department subscribers, and chapter subscribers.

## Professional Society Sponsors

AMERICAN COLLEGE OF OSTEOPATHIC EMERGENCY PHYSICIANS

CALIFORNIA ACEP

CALIFORNIA CHAPTER DIVISION OF

AMERICAN ACADEMY OF EMERGENCY MEDICINE

## Academic Department of Emergency Medicine Subscriber

Allegheny Health Network Pittsburgh, PA	INTEGRIS Health Oklahoma City, OK	Oklahoma University Norman, OK	University of Illinois at Chicago Chicago, IL
American University of Beirut Beirut, Lebanon	Kaweah Delta Health Care District Visalia, CA	Oregon Health and Science University Portland, OR	University of Iowa Iowa City, IA
Arrowhead Regional Medical Center Colton, CA	Kennedy University Hospitals Turnersville, NJ	Penn State Milton S. Hershey Medical Center Hershey, PA	University of Louisville Louisville, KY
Baystate Medical Center/Tufts University Springfield, MA	Kern Medical Bakersfield, CA	Presence Resurrection Medical Center Chicago, IL	University of Maryland Baltimore, MD
Beaumont Hospital Royal Oak, MI	Lakeland HealthCare St. Joseph, MI	Regions Hospital/ Health Partners Institute for Education and Research St. Paul, MN	University of Massachusetts Medical School Worcester, MA
Beth Israel Deaconess Medical Center Boston, MA	Lehigh Valley Hospital and Health Network Allentown, PA	Robert Wood Johnson Hospital New Brunswick, NJ	University of Michigan Ann Arbor, MI
Boston Medical Center Boston, MA	Loma Linda University Medical Center Loma Linda, CA	Southern Illinois University Carbondale, IL	University of Missouri Columbia, MO
Brigham and Women's Hospital Boston, MA	Louisiana State University Health Sciences Center New Orleans, LA	Stanford University Palo Alto, CA	University of Nebraska Medical Center Omaha, NE
Brown University Providence, RI	Madigan Army Medical Center Tacoma, WA	SUNY Upstate Medical Center Syracuse, NY	University of Nevada Las Vegas, NV
California Chapter Division of AAEM Milwaukee, WI	Maimonides Medical Center Brooklyn, NY	Temple University Philadelphia, PA	University of Oklahoma Norman, OK
California State University Fresno Fresno, CA	Maricopa Medical Center Phoenix, AZ	University of Alabama, Birmingham Birmingham, AL	University of South Alabama Mobile, AL
Carl R. Darnall Army Medical Center Fort Hood, TX	Massachusetts General Hospital Boston, MA	University of Arizona Tucson, AZ	University of Southern California/ Keck School of Medicine Los Angeles, CA
Eastern Virginia Medical School Norfolk, VA	Mayo Clinic College of Medicine Rochester, MN	University of California, Davis Medical Center Sacramento, CA	University of Tennessee, Memphis Memphis, TN
Emory University Atlanta, GA	Medical College of Wisconsin Milwaukee, WI	University of California, San Francisco San Francisco, CA	University of Texas Houston, TX
Florida Hospital Medical Center Orlando, FL	Mt. Sinai Medical Center Miami Beach, FL	University of California Irvine Orange, CA	University of Warwick Library Coventry, United Kingdom
Good Samaritan Hospital Medical Center West Islip, NY	National University Hospital Singapore, Singapore	University of California, Los Angeles Los Angeles, CA	University of Washington Seattle, WA
Hennepin County Medical Center Minneapolis, MN	North Shore University Hospital Manhasset, NY	University of California San Diego La Jolla, CA	University of Wisconsin Hospitals and Clinics Madison, WI
Henry Ford Medical Center Detroit, MI	Northwestern Medical Group Chicago, IL	University of Chicago Chicago, IL	York Hospital York, ME
Highland Hospital Oakland, CA	Ohio State University Medical Center Columbus, OH	University of Colorado & Denver Health Denver, CO	Wake Forest University Winston-Salem, NC
		University of Florida Jacksonville, FL	Wright State University Dayton, OH

## State Chapter Subscriber

ARIZONA CHAPTER DIVISION OF THE  
AMERICAN ACADEMY OF EMERGENCY MEDICINE

CALIFORNIA CHAPTER DIVISION OF THE  
AMERICAN ACADEMY OF EMERGENCY MEDICINE

FLORIDA CHAPTER DIVISION OF THE  
AMERICAN ACADEMY OF EMERGENCY MEDICINE

GREAT LAKES CHAPTER DIVISION OF THE  
AMERICAN ACADEMY OF EMERGENCY MEDICINE

TENNESSEE CHAPTER DIVISION OF THE  
AMERICAN ACADEMY OF EMERGENCY MEDICINE

UNIFORMED SERVICES CHAPTER DIVISION OF THE  
AMERICAN ACADEMY OF EMERGENCY MEDICINE

VIRGINIA CHAPTER DIVISION OF THE  
AMERICAN ACADEMY OF EMERGENCY MEDICINE

## International Society Partners

SOCIEDAD ARGENTINA DE EMERGENCIAS  
SOCIEDAD CHILENO MEDICINA URGENCIA  
MEDITERRANEAN SOCIETY OF EMERGENCY MEDICINE

THAI ASSOCIATION FOR EMERGENCY MEDICINE  
EMERGENCY MEDICINE ASSOCIATION OF TURKEY

NORWEGIAN SOCIETY FOR EMERGENCY MEDICINE  
LEBANESE ACADEMY OF EMERGENCY MEDICINE

Alissa Fiorentino  
CPC Emergency Medicine Staff Liaison  
Phone: 1-800-884-2236

# *Clinical Practice and Cases in Emergency Medicine*

In Collaboration with the *Western Journal of Emergency Medicine*

## JOURNAL FOCUS

*Clinical Practice and Cases in Emergency Medicine* (CPC-EM) is an internationally recognized journal affiliated with the MEDLINE-indexed *Western Journal of Emergency Medicine* (WestJEM). It will offer the latest in patient care case reports, images in the field of emergency medicine and state of the art clinicopathological cases. CPC-EM is fully open-access, peer reviewed, well indexed and available anywhere with an internet connection. CPC-EM encourages submissions from junior authors, established faculty, and residents of established and developing emergency medicine programs throughout the world.

## Table of Contents *continued*

- 197 **Unsuspected Clenbuterol Toxicity in a Patient Using Intramuscular Testosterone**  
*MK Griswold, E Blohm, R Cross, EW Boyer, JL Carey*
- 201 **Compartment and Crush Syndromes After Sleep Deprivation and a Therapeutic Dose of Zolpidem**  
*MR Huecker, E Yazel*
- 205 **When Too Much Is Enough: Pediatric Cyproheptadine Overdose with Confirmatory Level**  
*T McGovern, J McNamee, S Marcus, J Kashani*
- 208 **An Unusual Case of Posterior Reversible Encephalopathy Syndrome**  
*RP Zemple, T Pelleg, MR Cossio*
- 212 **Life-threatening Vesicular Bronchial Injury Requiring Veno-venous Extracorporeal Membrane Oxygenation Rescue in an Electronic Nicotine Delivery System User**  
*T Carter, D Tucker, A Kilic, TJ Papadimos, A Barlow, E Berry*
- 218 **Hematometocolpos in a Pubescent Girl with Abdominal Pain**  
*HC Kotter, D Weingrow, CP Candors*
- 221 **Testicular Rupture: A Tough Nut to Crack**  
*TL Holliday, KS Robinson, N Dorinzi, AW Vucelik, EL Setzer, DL Williams, MJ Sharon, JJ Minardi*
- 225 **Cervical Artery Dissection and Choosing Appropriate Therapy**  
*JT Lau, JS Hunt, DI Bruner, AL Austin*
- 229 **Abiotrophia defectiva Endocarditis: An Easy Miss**  
*E Escarcega, C Trovado, O Idahosa, J Gillard, H Stankewicz*
- 232 **Sub-acute Tamponade and the Value of Point-of-Care Ultrasound for Rapid Diagnosis: A Case Report**  
*DC Kolinsky, AJ Kim, EA Ablordepey*
- 238 **Cranial Neuropathies and Neuromuscular Weakness: A Case of Mistaken Identity**  
*DZ Adams, A King, C Kaide*
- 242 **Remote Management of Atrial Fibrillation: A Case Report**  
*A Chiu, M Kasper, J Rimmer, M Donnelly, Y Chen, C Chau, L Sidow, A Ash*

Policies for peer review, author instructions, conflicts of interest and human and animal subjects protections can be found online at [www.cpcem.org](http://www.cpcem.org).

# Clinical Practice and Cases in Emergency Medicine

In Collaboration with the *Western Journal of Emergency Medicine*

## Table of Contents *continued*

- 246 **Lightning Burns and Electrical Trauma in a Couple Simultaneously Struck by Lightning**  
*SA Eyerly-Webb, R Solomon, SK Lee, R Sanchez, EH Carillo, DL Davare, C Kiffin, A Rosenthal*

### **IMAGES IN EMERGENCY MEDICINE**

- 251 **A Case of Erythema Nodosum with Coccidioidomycosis**  
*S Said, J Yanuck, MJ Burns*
- 253 **Paratracheal Cysts**  
*MR Mohebbi, CK Kraus*
- 256 **Moyamoya: A Rare Cause of Cerebral Vascular Accident**  
*B Merritt, M Pitzer, R King, J Ashurst*
- 258 **Right Atrial Thrombus or Chiari Network?**  
*P Fredericks, T Liu, J Colla*
- 260 **Aortoesophageal Fistula**  
*R Roten, R Peterfy*
- 262 **A Man with Cyanotic Digits**  
*T Wiskel, J Bass, J Feden*
- 265 **Adult Male with Neck Pain**  
*S Natsui, SE Frasure*
- 268 **Diagnosis of Septic Abortion with Point-of-care Ultrasound**  
*D Sherpa, BD Johnson, L Ben-Youssef, A Nagdev*
- 270 **Catecholamine-induced Ischemic Necrosis of the Hand**  
*DS Bostick, MT McCurdy*

### VITAL STATISTICS

*Clinical Practice and Cases in Emergency Medicine* (CPC-EM) is an internationally recognized journal affiliated with the MEDLINE-indexed *Western Journal of Emergency Medicine* (WestJEM). CPC-EM is distributed electronically to 23,278 emergency medicine scholars. This includes our sponsors: California ACEP, the American College of Osteopathic Emergency Physicians, California Chapter of AAEM, and over 80 academic department of emergency medicine subscribers as well as six AAEM State Chapters.

Official Journal of the California Chapter of the American College of Emergency Physicians, the American College of Osteopathic Emergency Physicians, and the California Chapter of the American Academy of Emergency Medicine



Available in Google Scholar.

Editorial and Publishing Office: CPCEM/Department of Emergency Medicine, UC Irvine Health, 333 City Blvd, West, Rt 128-01, Orange, CA 92868, USA

Office: 1-714-456-6389; Email: Editor@cpcem.org





# CALL FOR SECTION EDITORS!



- Behavioral Emergencies
- Cardiac Care
- Injury Prevention
- Neuroscience
- Pediatric Emergencies
- Public Health
- Trauma Care

Send your CV and letter of interest  
to [editor@westjem.org](mailto:editor@westjem.org)

## MEMC-GREAT 2017

**Lisa Moreno-Walton, MD, MS, MSCR, FAAEM**

Secretary-Treasurer, AAEM Board of Directors  
Executive Chair, MEMC-GREAT 2017

---

Dear Friends and Colleagues in Emergency Medicine: It is with great pleasure that I invite you to attend the premier international conference in Emergency Medicine: the Mediterranean Emergency Medicine Congress (MEMC), which will take place this year in Lisbon, Portugal from September 8-10, with pre-congress courses offered on September 6<sup>th</sup> and 7<sup>th</sup>. MEMC has a rich history of collaboration between the American Academy of Emergency Medicine (AAEM), our European colleagues in EM, and the Mediterranean Academy of Emergency Medicine. For the past 16 years, AAEM and our partners have sponsored this outstanding conference in Rome, Marseille (France), Kos (Greece), Valencia (Spain), Sorrento (Italy), Nice (France), Sitges (Spain) and Stresa (Italy), featuring the most outstanding speakers in Emergency Medicine. This year, our keynote speaker is Prof. Lee Wallis, a pioneer in establishing EM and EMS in South Africa and sitting President of the International Federation of Emergency Medicine (IFEM). Our plenary speakers will include many of your favorites from AAEM: Dr. Amal Mattu will update us on the most important cardiology research reports that will change your practice, and Dr. Kevin Rodgers, AAEM President, will get you savvy on how the business of EM impacts your practice no matter where in the world you work. An international favorite, Dr. Jim Ducharme, President Elect of IFEM and a world renowned expert on pain management will give you practical advice on the evidence based and sound management of pain, putting you in control of an aspect of your practice that most of us find challenging. The themes of this year's Congress are Diversity and Inclusion and Career Development, and highlighting these themes will be Middle Eastern luminaries Dr. Amin Antoine Kazzi, former president of AAEM and founder of the MEMC, discussing the merits of universal global standards for certification of emergency physicians, and Dr. Eveline Hitti, the Chair of Emergency Medicine at American University of Beirut who is doing ground breaking research on the barriers to the advancement of women in medicine (not just the glass ceiling, but also the "domestic tethers" that represent the uneven distribution of household and child rearing tasks in dual career households). Our newest partner, GREAT Italy (Global Research on Acute Conditions Team) will feature one of the most experienced researchers in cardiac emergencies, Dr. Frank Peacock, who will discuss the impact of highly sensitive troponins on ED practice.

Beyond the plenaries, our educational tracks will bring you the most current practices in toxicology, infectious disease, cardiac emergencies, pulmonary emergencies, EMS, updates in pediatric care, pain management, critical care, and more. We will also explore cutting edge topics such as the newest theories in medical education, ethical issues in the practice of global EM, the role of hyperbaric medicine in the ED, the role of the EP in combat medicine, and success stories from countries where EM is an emerging specialty. World leaders such as Prof. Juliusz Jakubaszko (Poland), Prof. Judith Tintinalli (US), Prof. Robin Roop (National Health Service-Wales), Dr. Jean O'Sullivan (Ireland), Dr. Hari Prasad (India), Dr. Fatima Rato (Portugal), Dr. Kelhan Golshani (Iran), Dr. Lim Swee Han (Singapore) and Dr. Nino Butskhrikidze (Republic of Georgia) will bring expertise from some of the 30 countries that will be represented at MEMC, enhancing our commitment to diversity and inclusion in the development of global emergency medicine. Under the direction of Drs. Mark Langdorf, Ed Panacek and their team, 300 cutting edge original research abstracts by up and coming young EM students, residents and junior faculty will be presented orally and as posters. Come and see the work being done by the colleagues you will be reading about in the coming decades!

This year's pre-courses are an outstanding line up. Dr. Terry Mulligan will return with his very popular course on ED Administration. Dr. Gary Gaddis will again lead his course on how to get your manuscript published, assisted by Editors in Chief of no less than five highly indexed EM publications ready and willing to help you see your manuscript in print. Ultrasound beginner and advanced courses, Amal Mattu's always sold out EKG course, critical care and resuscitation and our new simulation course will be augmented by the never before featured courses on management of chemical and radiation incidents (co-taught by Portuguese experts and AAEM's resident tox expert, Dr. Ziad Kazzi) and how to effectively manage in-flight emergencies (co-taught by Dr. Kumar Alagappan and a team of pilots and flight attendants).

And we want you to leave time to explore lovely, romantic Portugal! This is the land of golden sand beaches with some of the best surfing and swimming on earth; the soulful music of Fado; luscious Port wines; the medieval village of Obidos, perfectly preserved; religious shrines such as Fatima; the UNESCO heritage city of Sintra, where

you will walk in the footsteps of the Emperor Octavius, through the Moorish occupation and the Caliphate of Cordova, the conquest by Crusaders, the reign of King Ferdinand, into the world of modern Portugal. And modern Portugal is a traveler's dream. The Portuguese are foreigner- friendly, engaging, fun loving people. Most Portuguese natives speak fluent English. The country is safe, clean, and incredibly economical, offering the perfect mix of traditional churches and castles with modern night clubs and delightful restaurants and parks. The food is outstanding, and every major wine magazine is extolling the virtues of Portugal's emerging wine market. Be the first to taste the vintages that will soon be the most cherished! Our conference hotel, the Corinthia, is one of the most elegant and luxurious in Europe, and the staff is completely committed to your comfort and enjoyment.

I cannot imagine a better venue to combine education, friendship, family and fun than the MEMC 2017 in Lisbon. For me, the greatest pleasure will be welcoming you. If you are already a part of the MEMC family, it will be a joy to be with you again. If you are not, we invite you to make MEMC a tradition for yourself, your family and your friends, and to join us on the odd numbered years in the sultry Mediterranean for the best mix of learning and fun that you can imagine. Our incredible team will make you feel at home with a handshake, a kiss on the cheek, and a smile. Come and tell us what we can do to make the best conference even better. We want to meet and exceed your every wish for the finest learning experience and the most wonderful vacation. It is my hope that you will become a part of the MEMC family as a conference attendee, an abstract presenter and a speaker.

This is not the big, impersonal, "take a number and scan your badge" conference. Every attendee matters to us; everyone is a friend and a colleague. The exchange of ideas, collaborative research, sharing educational resources, providing opportunities for career growth, and lifelong friendships that span continents and languages are what we are about. We embrace the spirit of diversity and inclusion and career development, and we want you to be a part of the inclusive and nurturing environment taking place in one of the most beautiful places on earth. MEMC will not be the same if you are not there. Grace us with your ideas, your talent, your knowledge and experience. Be a teacher and a learner at MEMC. Check us out on our website: [www.emcongress.org](http://www.emcongress.org). I look forward to welcoming you in Lisbon!

---

*Address for Correspondence:* Lisa Moreno-Walton, MD, MS, MSCR, FAAEM. Secretary-Treasurer, AAEM Board of Directors, Executive Chair, MEMC-GREAT 2017.

*Conflicts of Interest:* By the WestJEM article submission agreement, all authors are required to disclose all affiliations, funding sources and financial or management relationships that could be perceived as potential sources of bias. No author has professional or financial relationships with any companies that are relevant to this study. There are no conflicts of interest or sources of funding to declare.

*Copyright:* © 2017 Moreno-Walton. This is an open access article distributed in accordance with the terms of the Creative Commons Attribution (CC BY 4.0) License. See: <http://creativecommons.org/licenses/by/4.0/>

---





## 29-year-old Woman with Dyspnea

Elizabeth England, MD\*

Michele Callahan, MD†

Laura J. Bontempo, MD, Med†

Zachary D.W. Dezman, MD, MS†

\*University of Maryland Medical Center, Baltimore, Maryland

†University of Maryland School of Medicine, Department of Emergency Medicine, Baltimore, Maryland

Section Editor: Rick A. McPheeters, DO

Submission history: Submitted April 10, 2017; Revision received May 22, 2017; Accepted June 1, 2017

Electronically published July 17, 2017

Full text available through open access at [http://escholarship.org/uc/uciem\\_cpccm](http://escholarship.org/uc/uciem_cpccm)

DOI: 10.5811/cpcem.2017.6.34490

[Clin Pract Cases Emerg Med.2017;1(3):152–158.]

### CASE PRESENTATION

A 29-year-old female presented to the emergency department (ED) with a chief complaint of worsening dyspnea over the prior three weeks. Her shortness of breath was exacerbated by exertion and lying down. It was also worse at night. Over the same time, she had developed a dry, raspy, non-productive cough, bilateral leg swelling, and chest tightness. She denied any fevers, chest or abdominal pain, recent travel, or viral illness. She had no medical problems or past surgical history. Her only home medication was ibuprofen and she had no known drug allergies. She denied any family history of sudden death, myocardial infarction, or heart failure. She denied tobacco or illicit drug use. She reported occasionally drinking alcohol. She had been employed as a welder for the past three years and had recently increased her work hours.

The patient had an initial blood pressure of 138/108 mmHg, heart rate of 126 beats per minute, respiratory rate of 18 breaths per minute, temperature of 36.7° Celsius, and an oxygen saturation of 99% on room air. Shortly after being placed in a room, the patient desaturated to 88% on room air. She was placed on two liters per minute of oxygen by nasal cannula, with improvement of her saturation to 95%. On physical exam, the patient was well developed, well nourished, and appeared to be her stated age. She was in no acute distress. Her head, eye, ear, nose and throat exams were all unremarkable. Neck exam showed no jugular vein distention and no goiter. On cardiac exam, she was found to be tachycardic with a regular rhythm and an audible s3 gallop. She was tachypneic without accessory muscle use. Rales were heard in all lung fields. Abdominal exam was unremarkable. She was noted to have trace pedal edema with normal range of motion of her joints and limbs. She was awake, alert and appropriately interactive without focality to her neurological examination. Skin examination showed no rashes or erythema.

Her laboratory results are shown in Tables 1-3. Her electrocardiogram (ECG) and chest radiography are shown in Images 1 and 2. A bedside ultrasound (US) was performed

and was notable for B-lines bilaterally and a grossly decreased ejection fraction, estimated to be approximately 20%. Following initial physician evaluation, the patient desaturated to 92% on nasal cannula and her oxygen flow was increased to four liters per minute. Shortly thereafter she was started on bilevel positive airway pressure (BiPAP) and given nitroglycerin, enalapril, and furosemide. This resulted in significant improvement in her symptoms. She was taken off BiPAP and had an oxygen saturation of 96% on three liters nasal cannula. She was admitted to the intermediate care unit. A diagnostic test was then performed, which confirmed her diagnosis.

### DISCUSSION

When we were first presented with this patient's case, several key points within the history of present illness jumped out immediately. First of all, this was a 29-year-old female presenting with fairly insidious onset of shortness of breath. Her report of dyspnea on exertion, bilateral lower extremity swelling, non-productive cough, and orthopnea seemed more fitting for a middle-aged patient than someone who had not yet reached 30 years of age.

A few additional pieces of information struck me as important. Her lack of a family history of early coronary artery disease or sudden death, although helpful in risk-stratifying many patients who present with chest pain or dyspnea, did not help to clarify the potential cause for her symptoms. When asked about social history, she reported only occasional alcohol use. This led me to question – was she being truthful? Could this be a disease process in the setting of heavier, longer-term alcohol abuse? I would certainly probe her for more specific details about her alcohol intake. In addition, her employment as a welder seemed as if it could play a significant role in her disease process. Different environmental exposures can manifest as pulmonary and cardiac disease, but I am unsure how long she would need to be exposed before these exposures became symptomatic. Including this environmental exposure certainly opens up interesting and rare diagnostic possibilities.

**Table 1.** Hematology and coagulation studies of a 29-year-old woman with dyspnea.

Complete blood cell count	
White blood cell count	7.9 K/mcL
Hemoglobin	14.3 g/dL
Hematocrit	41.30%
Platelets	297 K/mcL
Coagulation studies	
International normalized ratio	1.0
Prothrombin time	13.1 sec
Activated partial thromboplastin time	28 sec

**Table 2.** Chemistry results.

Sodium	142 mmol/L
Potassium	3.1 mmol/L
Chloride	105 mmol/L
Bicarbonate	27 mmol/L
Blood urea nitrogen	11 mg/dL
Creatinine	0.52 mg/dL
Glucose	92 mg/dL
Calcium	8.3 mg/dL
Total protein	6.9 g/dL
Albumin	3.9 g/dL
Aspartate aminotransferase	29 units/L
Alanine aminotransferase	23 units/L
Alkaline phosphatase	70 units/L
Total bilirubin	0.7 mg/dL

**Table 3.** Expanded testing results

Arsenic	6 ug/L
Lead	Not detected
Mercury	Not detected
Urine pregnancy	Negative
Troponin	<0.02 ng/mL
Human immunodeficiency virus assay	Not-reactive
Total serum triiodothyronine	151 ng/dL

Finally, her lack of risk factors, fever, recent travel, and viral prodrome is helpful in placing certain diagnoses, particularly infectious, lower on the differential.

Her physical examination was notable for a narrow pulse pressure, tachycardia, decreased oxygen saturation that

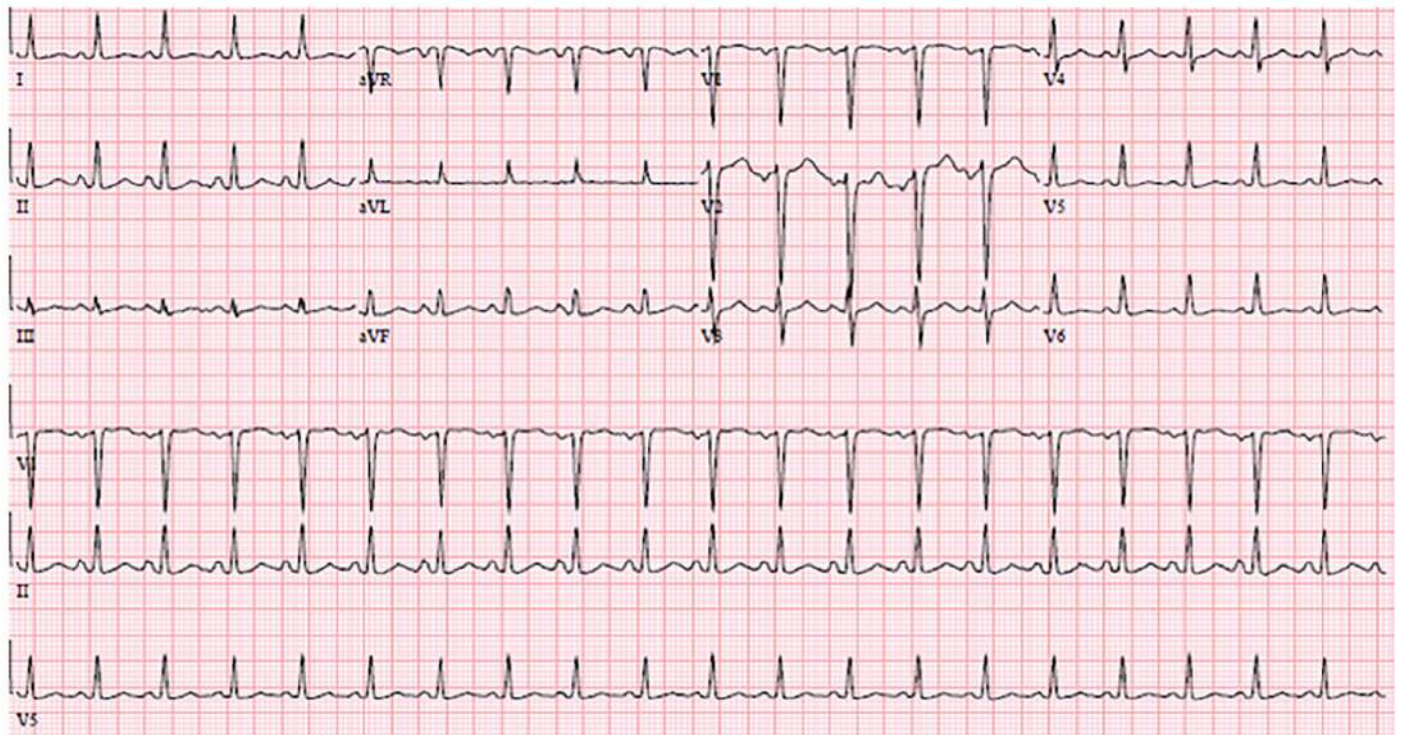
responded to oxygen supplementation, tachypnea with rales noted on lung auscultation, a gallop on cardiac auscultation, and pedal edema. Pertinent negatives included being afebrile as well as the lack of a murmur on examination. The rest of her examination was noncontributory.

When approaching the undifferentiated patient with dyspnea, it is helpful to think broadly about all categories of disease processes and then work backwards to see which fit best with the patient's presentation. There is often a "gut" feeling about what the diagnosis could be – for me, when I first read this case, I immediately felt this was a diagnosis of heart failure. However, approaching patients this way can lead to premature closure, anchoring, and ultimately misdiagnosis. We need to take a step back and explore the differential to ensure we do not miss a critical diagnosis.

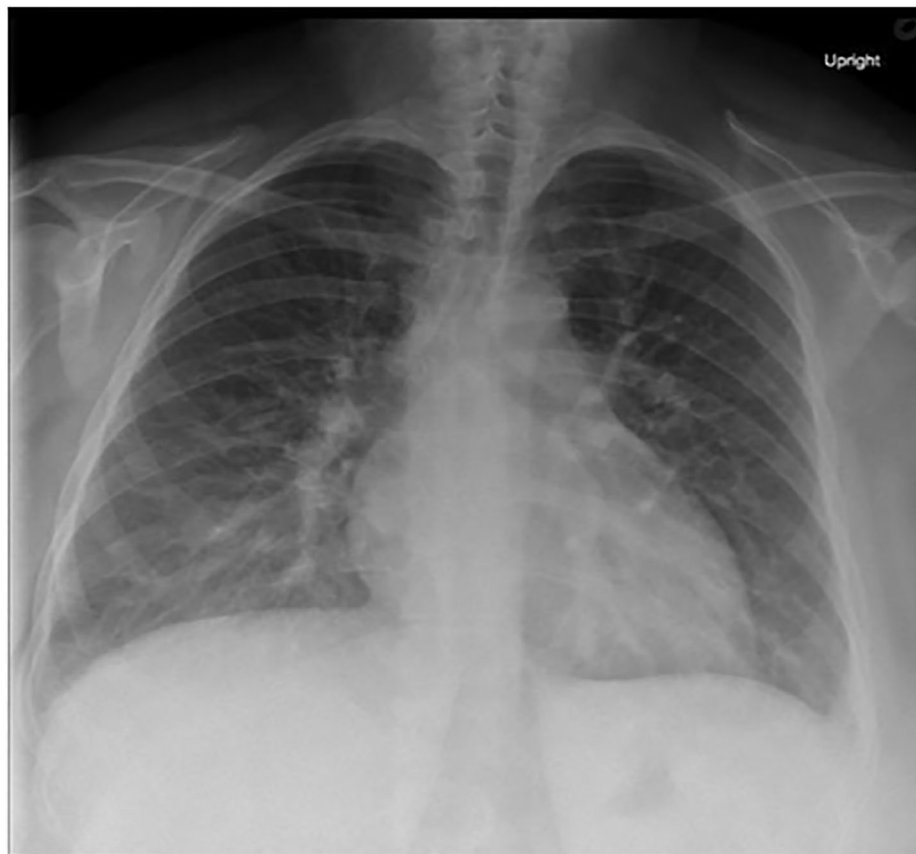
Ideally, there should be one final diagnosis that incorporates all of the "positive" and "negative" symptoms that are present or absent, respectively. Using a systematic approach can allow you to explore all of the possibilities and help to avoid missing an important diagnosis (or make an incorrect one). For a patient presenting with dyspnea, there are four broad categories of disease processes: pulmonary, cardiac, neuromuscular, and metabolic.<sup>1</sup> When exploring these options, we need to ensure that we are including, and evaluating for, the life-threatening causes of dyspnea within our differential.

Let's begin with discussion of the cardiac causes of dyspnea. Highest on my differential was a form of acute heart failure, possibly from a cardiomyopathy given such a young patient. We will return to this in a moment. Could this be an acute coronary syndrome? This seems less likely in the setting of three weeks of constant symptoms, a non-ischemic ECG, and a troponin level of <0.02 ng/mL. A pulmonary embolism (PE) could account for the dyspnea lasting several weeks (and potentially for right heart failure in the setting of elevated pulmonary pressures), but her risk factors for development of a PE are unclear. She does exhibit sinus tachycardia on the ECG, and thus we cannot apply the pulmonary embolism rule-out criteria (PERC) to this patient. Her ECG does not show any of the right-heart strain patterns that are suggestive of a PE: right bundle-branch block, T-wave inversions in the inferior and anterior leads, right axis deviation, or the classic S1Q3T3 pattern.<sup>2</sup> Note that these patterns are all specific, and not sensitive. But based on the risk factors presented and my clinical suspicion, I believe she is low risk for a pulmonary embolism. For now we will keep PE as an unlikely diagnosis that should be ruled out.

Valvular diseases may present with dyspnea. This patient does not have a murmur, and no risk factors for endocarditis are included in the history. A bedside US was done, which did not report any vegetations or valvular insufficiency, making valvular disease less likely. Similarly, there was no mention of a pericardial effusion



**Image 1.** Electrocardiogram on arrival to the emergency department.



**Image 2.** Initial anterior-posterior chest radiograph taken shortly after arrival to the emergency department.



or tamponade. I strongly suspect that if these things were present, they would have been reported. We can therefore also rule out tamponade. The patient's tachycardia supports myocarditis and/or pericarditis as possible causes of her dyspnea, but she is not pregnant, she did not have the viral prodrome, chest pain, friction rub, or an elevated troponin, despite three weeks of constant symptoms. Her ECG also does not demonstrate the "classic" findings one would expect with pericarditis, such as diffuse PR segment depression that is often most notable in the inferior leads, widespread ST segment elevation, or TP segment downsloping.<sup>2</sup> As with PE, ECG findings are not present in all cases of pericarditis or myocarditis, but we will move these diagnoses farther down on the list of possibilities. Finally, we know that the patient's symptoms are not due to a current arrhythmia like atrial fibrillation or atrial flutter based on her ECG, so we will take this off the differential for now.

The patient could have a primary pulmonary cause of her dyspnea such as undiagnosed chronic obstructive pulmonary disease or asthma. But given the patient was asymptomatic until three weeks ago, she does not smoke, there was no wheezing on exam, and her chest radiography does not show any hyperinflation, these diagnoses are less likely. The chest radiograph shows no evidence of a focal infiltrate, making a significant pneumonia unlikely. There is no evidence of a pneumothorax (tension or otherwise) on her chest radiograph or exam. Although the radiograph does demonstrate increased vascular congestion, there are no large pleural effusions noted. The patient demonstrates no signs of an upper airway obstruction such as stridor, drooling, or oropharyngeal edema. It is possible that she has developed a pneumonitis of an unclear cause, but the chest radiography provided shows no evidence of diffuse lung damage or fibrosis. Finally, the possibility of an interstitial lung disease with or without pulmonary hypertension is plausible given her occupational exposure to various materials like arsenic, lead, and mercury, but these tests were all negative and the chest radiograph shows no evidence of diffuse lung fibrosis.

Myasthenia gravis and Guillain-Barre syndrome are two neuromuscular diseases that can present as dyspnea in a young woman, but they are often accompanied by symptoms of generalized muscular weakness. The presence of severe kyphoscoliosis can make it difficult for patients to breathe efficiently, but her exam and chest radiograph show no evidence of significant spinal malformations. She does not manifest any symptoms of bulbar weakness, abnormal reflexes, or difficulty swallowing, and the history of three weeks of symptoms makes diseases such as botulism and poliomyelitis very unlikely. Finally, a stroke may present with difficulty controlling breathing (secondary to muscle weakness), but the patient manifests no other signs or symptoms consistent with this. Therefore, we can remove the neuromuscular and neurologic causes for dyspnea from our list of possibilities.

Finally, let us review potential metabolic and toxicologic causes for this patient's dyspnea. Anemia and thyrotoxicosis can cause dyspnea, but the laboratory values do not support these diagnoses. Metabolic acidosis should always be considered in patients who are tachypneic or appear dyspneic, as this can be a compensatory mechanism for a primary metabolic acidosis (e.g., diabetic ketoacidosis), but the laboratory results show she is not suffering from one. Anxiety is a fairly common cause for dyspnea, but should be considered a diagnosis of exclusion in the ED. The patient does not appear anxious, and anxiety would not account for the patient's symptoms of orthopnea, increased lower extremity edema, and poor oxygen saturation. Finally, iatrogenic or pharmacologic causes for dyspnea would include salicylates or beta-blockers, but as the patient denies drug use and only uses ibuprofen as needed, it is unlikely that her dyspnea is related to medication or drug use.

Narrowing down our broad differential, the diagnoses that remain include the following: heart failure (possibly in the setting of a cardiomyopathy), pulmonary embolism, myocarditis +/- pericarditis, and interstitial lung disease in the setting of an occupational exposure. We are given the results of her chest radiograph: increased interstitial markings, prominent hilar vasculature indicative of vascular congestion, interstitial edema, and developing alveolar edema, which is similar to the classic chest radiograph findings of heart failure. We are also given the results of a bedside echocardiogram, which describes an ejection fraction of approximately 20%, a dilated inferior vena cava, and no evidence of pericardial effusion. There is no comment about right heart dilation or other signs that would be concerning for a PE. From the information provided, we can make the following determinations: she has evidence of systolic failure, elevated central venous and right heart pressures, and does not have an obvious obstructive lesion such as tamponade or evidence of a massive PE.

Putting it all together, her historical features of orthopnea and bilateral lower extremity edema have positive likelihood ratios (+LR) of 2.2 and 2.3, respectively, to predict heart failure in patients presenting to the ED with dyspnea.<sup>3</sup> Her physical exam (S3 gallop +LR=11.0, rales +LR=2.8, edema +LR=2.1) and imaging (chest radiograph with pulmonary venous congestion +LR=12.0) were consistent with a diagnosis of heart failure as well.<sup>3</sup> We multiply LRs to obtain our post-test probability, but a LR>10 is generally considered diagnostic in common conditions. Ultimately, I believe this patient's symptoms and presentation are consistent with an episode of newly diagnosed heart failure. The etiology behind the heart failure is unclear. To further elucidate the cause for her symptoms, my recommendation would include both cardiac magnetic resonance imaging (MRI) as well as a myocardial biopsy.

## OUTCOME

Cardiac MRI revealed that the patient had non-ischemic dilated cardiomyopathy. Multiple segments within the mid cavity and apex demonstrated prominent trabeculation. The ratio of non-compacted to compacted muscle was greater than 2.3, suggestive of left ventricular non-compaction cardiomyopathy. The patient was admitted and treated with furosemide, lisinopril, and metoprolol. This resulted in significant improvement. The patient was discharged after a three-day admission with plans for a six-week follow-up echocardiogram.

At follow-up, her echocardiogram demonstrated an ejection fraction of 45-50%. The severity of her symptoms while on therapy are New York Heart Association class IC (Table 4).<sup>4</sup> She is currently planning on having a child and is working with a genetic counselor to estimate the risk of passing on her condition.

## RESIDENT DISCUSSION

Left ventricular non-compaction cardiomyopathy (LVNCCM) is a rare malformation of embryologic cardiac tissue. While the exact incidence is unknown, 0.014%-1.3% of patients undergoing echocardiography are found to have LVNCCM.<sup>5</sup> An estimated 3-4% of patients with heart failure have a diagnosis of LVNCCM. With improvement in diagnostic testing and increased awareness and recognition of the disease, it is likely that this incidence will increase.<sup>5</sup>

The pathophysiologic cause of ventricular non-compaction is an area of continued research. The most widely accepted theory is a failure in the process of compaction, proliferation, and organization of the tissue into the adult myocardial architecture, leading to decreased cardiac contractility and function. In the maturing embryo, cardiac tissue goes through several stages of development. Initially, the myocardium consists of two layers of cells that comprise the primitive tubular heart.<sup>5</sup> Within the first weeks of development, these layers form myocardial protrusions,

or trabeculations, which extend into both ventricular cavities. This trabecular formation allows for adequate oxygenation of cardiac tissue prior to development of the coronary arteries by increasing the tissue surface area contact with blood.<sup>5</sup> As the coronary arteries develop from the epicardium, the trabecular tissue begins to compact and proliferate. This compaction is more prominent in the left ventricle than the right, and right ventricular trabeculations can be seen in the healthy adult.

LVNCCM is diagnosed in various stages of life. A meta-analysis by Bhatia et al. examined 241 adult patients diagnosed with LVNCCM and found it was more prevalent in men than women (65% male), with a mean age of 41 years at the time of diagnosis.<sup>6</sup> Patients most often presented with symptoms of acute heart failure: shortness of breath (60%), palpitations (18%), and chest pain (15%).<sup>6</sup> In the pediatric population, patients are more frequently identified during regular screening exams. In a single center study performed by Brescia et al., 240 pediatric patients (median age=9.4 years, interquartile range of 3 months-13.8 years) were diagnosed with LVNCCM.<sup>7</sup> The most common presentation in symptomatic children was also acute heart failure (25%). However, nearly half of cases were identified through an abnormal screening exam: on physical exam (19%), ECG/chest radiography (16%), or echocardiography (14%).<sup>7</sup> In both age ranges, significant proportions of patients presented with arrhythmia, syncope, chest pain, and sudden cardiac death.<sup>6,7</sup> In adults, 14% of patients were deceased by 39-month follow-up, half of which were due to sudden cardiac death.<sup>6</sup> In children, 12.8% of patients had died four years later.<sup>7</sup>

The original and most commonly used diagnostic modality for ventricular non-compaction is echocardiography.<sup>8</sup> The Jenni criteria remain the most widely accepted criteria for echocardiographic diagnosis. The criteria include bilayered myocardium (a grossly trabeculated or non-compacted layer with a layer of

**Table 4.** New York Heart Association functional classification of heart failure.

Class	Patient symptoms
I	No limitation of physical activity. Ordinary physical activity does not cause undue fatigue, palpitation, dyspnea (shortness of breath).
II	Slight limitation of physical activity. Comfortable at rest. Ordinary physical activity results in fatigue, palpitation, dyspnea (shortness of breath).
III	Marked limitation of physical activity. Comfortable at rest. Less than ordinary activity causes fatigue, palpitation, or dyspnea.
IV	Unable to carry on any physical activity without discomfort. Symptoms of heart failure at rest. If any physical activity is undertaken, discomfort increases.
Objective assessment	
A	No objective evidence of cardiovascular disease. No symptoms and no limitation in ordinary physical activity.
B	Objective evidence of minimal cardiovascular disease. Mild symptoms and slight limitation during ordinary activity. Comfortable at rest.
C	Objective evidence of moderately severe cardiovascular disease. Marked limitation in activity due to symptoms, even during less-than-ordinary activity. Comfortable only at rest.
D	Objective evidence of severe cardiovascular disease. Severe limitations. Experiences symptoms even while at rest.

normal, compact myocardium), a non-compacted to compacted ratio >2:1, communications within the intertrabecular space demonstrated by Doppler, absence of coexisting cardiac abnormalities, and presence of multiple prominent trabeculations in end-systole.<sup>8</sup> Cardiac MRI has become an increasingly popular method to diagnose LVNCCM. A study by Peterson et al. compared healthy volunteers to those diagnosed with LVNCCM.<sup>9</sup> A ratio of non-compacted:compacted myocardium greater than 2.3 was found to be 86% sensitivity and 99% specificity for LVNCCM.<sup>10</sup>

While non-compaction cardiomyopathy is unlikely to be formally diagnosed in the ED, this case demonstrates how bedside ultrasonography can play a vital role in the evaluation of undifferentiated dyspnea and diagnosis of heart failure. Finding “B-lines” or “comet-tails” on bedside US is 92.5% sensitive and 65.1% specific for interstitial pulmonary edema. Additionally, left ventricular systolic function and volume status (via evaluation of the inferior vena cava) can be estimated for further differentiation of a cardiac or pulmonary cause and help direct medical therapy.<sup>11</sup>

Current recommendations for the initial management of LVNCCM are identical to traditional systolic heart failure management, with a focus on reducing afterload, optimizing volume status, and supporting respiratory function.<sup>12</sup> For comparison, diastolic heart failure arises from a too-stiff ventricular wall, which does not relax fully in diastole. This leads to decreased filling and decreased cardiac output, leading to dyspnea and other symptoms of heart failure. Long-term management of LVNCCM is largely similar, with continued debate regarding additional need for anticoagulation. At this time, data are largely lacking on the risk for cardioembolic events in LVNCCM as compared with other causes of heart failure. Some experts recommend initiating anticoagulation for patients with either atrial fibrillation or an ejection fraction less than 40%.<sup>12</sup> A number of cardiologists recommend using a Holter monitor to surveil for arrhythmias or placing an internal cardiac defibrillator because of the high risk of sudden cardiac death in these patients.<sup>7</sup> As EPs, we play a critical role in improving outcomes in these patients by recognizing and stabilizing their acute heart failure when it occurs.

## FINAL DIAGNOSIS

Final diagnosis was acute heart failure as a result of left ventricular non-compaction cardiomyopathy.

## TAKE-HOME POINTS

- When evaluating an undifferentiated patient with dyspnea, keep a broad differential (i.e., consider more than just cardiac and pulmonary causes) to avoid premature closure or other diagnostic errors.
- Bedside echocardiography is an important skill set for EPs. It allows for the rapid evaluation for many causes of acute dyspnea, including acute heart failure with pulmonary edema, pericardial effusion, or pneumothorax.

*Address for Correspondence:* Zachary D.W. Dezman, MD, MS, University of Maryland, Department of Emergency Medicine, 110 S Paca Street, 6th Floor, Suite 200, Baltimore, MD 21201. Email: zdezman@em.umaryland.edu.

*Conflicts of Interest:* By the CPC-EM article submission agreement, all authors are required to disclose all affiliations, funding sources and financial or management relationships that could be perceived as potential sources of bias. The authors disclosed none.

*Copyright:* © 2017 England et al. This is an open access article distributed in accordance with the terms of the Creative Commons Attribution (CC BY 4.0) License. See: <http://creativecommons.org/licenses/by/4.0/>

## REFERENCES

1. Sarko J, Stapczynski JS. Respiratory Distress. In: Tintinalli JE, Stapczynski JS, Ma OJ, Cline DM, Cydulka RK, Meckler GD, editors. *Tintinalli's Emergency Medicine: A comprehensive Study Guide*. 7th ed. New York: McGraw Hill; 2011.
2. Mattu A, Brady WJ. *ECGs for the Emergency Physician, Volume 1*. West Sussex (UK), Wiley-Blackwell Publishing, September 2003.
3. Wang CS, FitzGerald JM, Schulzer M, et al. Does this dyspneic patient in the emergency department have congestive heart failure?. *JAMA*. 2005;294(15):1944-56.
4. Adapted from: New York Heart Association. Criteria Committee, New York Heart Association. *Nomenclature and criteria for diagnosis of diseases of the heart and great vessels*. Little, Brown Medical Division; 1979.
5. Sedmera D., McQuinn T. Embryogenesis of the heart muscle. *Heart Fail Clin*. 2008;4(3):235-45.
6. Bhatia NL, Tajik AJ, Wilansky S, et al. Isolated noncompaction of the left ventricular myocardium in adults: a systematic overview. *J Card Fail*. 2011;17(9):771-8.
7. Brescia ST, Rossano JW, Pignatelli R, et al. Mortality and sudden death in pediatric left ventricular noncompaction in a tertiary referral center. *Circulation*. 2013;127(22):2202-8.
8. Jenni R, Oechslin E, Schneider J, et al. Echocardiographic and pathoanatomical characteristics of isolated left ventricular non-compaction: a step towards classification as a distinct cardiomyopathy. *Heart*. 2001;86(6):666-71.
9. Bennett CE, Freudenberger R. The Current Approach to Diagnosis and Management of Left Ventricular Noncompaction Cardiomyopathy: Review of the Literature. *Cardiol Res Pract*. 2016;2016:5172308.
10. Petersen SE, Selvanayagam JB, Wiesmann F, et al. Left ventricular non-compaction: insights from cardiovascular magnetic resonance imaging. *J Am Coll Cardiol*. 2005;46(1):101-5.
11. Lichtenstein D, Meziere G, Biderman P, et al. The comet-tail artifact: an ultrasound sign of alveolar-interstitial syndrome. *Am J Respir Crit Care Med*. 1997;156(5):1640-6.



- 
12. Kajimoto K, Madeen K, Nakayama T, et al. Rapid evaluation by lung-cardiac-inferior vena cava (LCI) integrated ultrasound for differentiating heart failure from pulmonary disease as the cause of acute dyspnea in the emergency setting. *Cardiovasc Ultrasound*. 2012;10(1):49.

# Accidental Ingestion of Hearing Aid with Exposed Battery

Ethan B. Kunstadt, MD  
Mark I. Langdorf, MD, MHPE

University of California, Irvine, Department of Emergency Medicine, Irvine, California

Section Editor: Rick A. McPheeters, DO

Submission history: Submitted December 6, 2016; Revision received December 30, 2016; Accepted January 15, 2017

Electronically published March 16, 2017

Full text available through open access at [http://escholarship.org/uc/uciem\\_cpem](http://escholarship.org/uc/uciem_cpem)

DOI: 10.5811/cpcem.2017.1.33281

A 59-year-old female presented to the emergency department (ED) three days after accidental ingestion of an intact in-the-ear hearing aid. This is the first report of ingestion of a complete hearing aid traveling past the gastroesophageal junction. Of concern was the exposed battery attached to the hearing aid that had advanced minimally in the three days since last evaluation. This case report discusses her ED testing, including gastroenterology consultation, and ultimately retrieval from her distal stomach. The authors conclude that this removal was not medically necessary. [Clin Pract Cases Emerg Med. 2017;1(3):159–161.]

---

## INTRODUCTION

Hearing loss occurs in some 30% of adults greater than 60, and has been associated with increased risk of dementia and falls.<sup>1,2</sup> Given the stigma that may arise from hearing loss, advances in design of hearing devices have taken us from conspicuous wearable metal “ears” and ear trumpets in the 17<sup>th</sup> and 18<sup>th</sup> centuries to the present-day technologies. Cochlear implants enhance sound transmission to the vestibulocochlear organ, and miniaturized within-ear devices amplify and compensate for conductive and sensorineural hearing loss.

In-the ear (ITE), in-the-canal, and completely-in-canal hearing aids are devices small enough to cause risk of ingestion in the elderly or cognitively impaired. Foreign body ingestion is a relatively common chief complaint in the emergency department (ED), but most cases occur in children with peak incidence between six months and six years of age. Eighty percent of foreign bodies pass spontaneously through the gastrointestinal tract; surgical intervention is required in only 12–16%. Death is extremely rare. One study reported no deaths among 852 adults, while another in children reported one out of 2,206.<sup>3</sup> Impaction, perforation, or other complications tend to occur at areas of gastrointestinal (GI) narrowing or angulation; however, once the object has passed the esophagus, almost all foreign bodies that are not sharp pass uneventfully.

We present the first reported case of an adult accidentally ingesting a complete hearing aid with exposed battery.

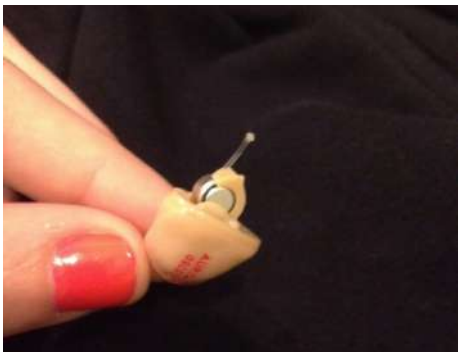## CASE REPORT

A 59-year-old Caucasian female presented to the ED with a chief complaint of accidentally swallowing her hearing aid. The patient denied symptoms aside from anxious thoughts regarding the ingestion. She swallowed the device accidentally three days before, when she grabbed a handful of acetaminophen from her night stand, which she takes each morning for osteoarthritis. The patient went to work on the day of the ingestion, but left early given mild discomfort in her chest and concern about the swallowed hearing aid. An abdominal radiograph done at an outside hospital revealed the foreign body at the gastroesophageal (GE) junction. The patient was sent home and instructed to carefully examine her stool for passage of the foreign body.

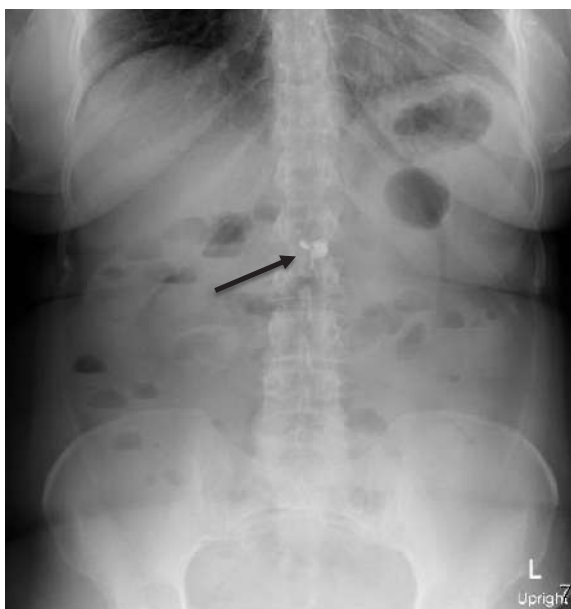On presentation to our ED, the patient’s chest discomfort was resolved; however, she was concerned because she had not seen the foreign body in any of her stools. She had taken polyethylene glycol 3350 (Miralax) daily in hopes this would promote passage. She denied shortness of breath, cough, dysphagia or odynophagia, abdominal pain, nausea, vomiting, or changes in bowel habits. The patient brought her matching hearing aid, which was not ingested: an ITE device, approximately 2cm in diameter with plastic casing. However, when the hearing aid is in the off position, as it was when it was ingested, a small battery protrudes from the device and is not protected within plastic casing (Image 1).

The patient had osteoarthritis, depression, and attention deficit hyperactivity disorder, with two caesarean sections, and she denied tobacco, alcohol, or illicit drugs.

On physical exam, the patient was well-appearing, in no apparent distress and was breathing comfortably. Initial vital signs were temperature 36.6C, blood pressure 153/93 mmHg, heart rate 106 beats per minute, respiratory rate 16 breaths per minute, and O<sub>2</sub> saturation 100% on room air. Tachycardia was resolved by the time of exam by the physician. Oropharynx revealed moist oral mucosa, no pharyngeal erythema, exudate or fullness, and uvula was midline. There was no reproducible chest wall discomfort or subcutaneous crepitus of the chest. Breathing was non-labored with no accessory muscle use. Breath sounds were clear and equal bilaterally with no wheezes or rhonchi. Cardiac auscultation was normal. Radial pulses were normal and equal. Her abdomen was soft, non-distended, and non-tender, with normal bowel sounds.



**Image 1.** An in-the-ear hearing aid similar to our patient's, in the off position with battery exposed.

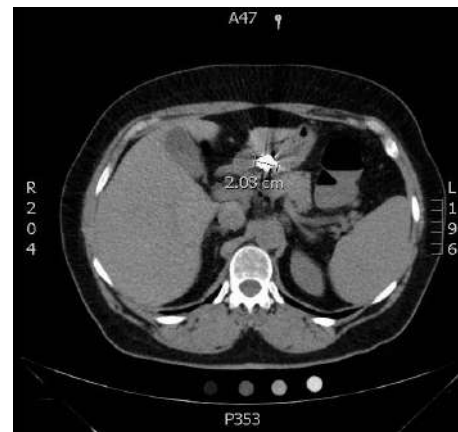


**Image 2.** Anterior-posterior upright film with foreign body visualized in mid-upper abdomen (arrow).

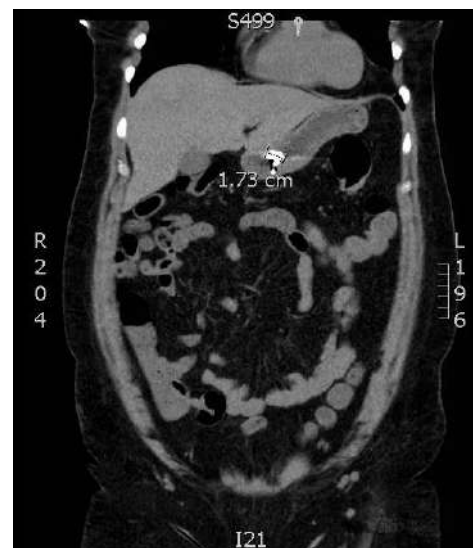
An abdominal radiograph was done to localize the foreign body, as the patient reported the hearing aid was easily identifiable in the distal esophagus on plain films three days prior (Image 2).

Final read of the plain films was: “3 closely grouped metallic densities measuring 2 mm, 6 mm and 12 mm in size project over the midline upper abdomen at the level of L1-2. Findings may represent the hearing aid/foreign body of interest.”

Emergency physicians (EP) consulted the gastroenterology service after the radiographs were shot; however, neither team could determine the precise location of the foreign body from these films alone. Non-contrast computed tomography (CT) of the abdomen and pelvis was then obtained per GI's request for further evaluation of the foreign body's size and location (Images 3 and 4).



**Image 3.** Axial view from computed tomography of abdomen and pelvis showing a 2cm foreign body in the stomach.



**Image 4.** Coronal view from computed tomography of the abdomen and pelvis noting the foreign body in the distal stomach.



While awaiting CT results, EPs spoke with the American Association of Poison Control Centers (1-800-222-1222) regarding this case. Their representative reassured us that exposed batteries are only a concern if they are still in the esophagus, due to constant contact with the esophageal mucosa, which allows for injury of the mucosa. Assuming the hearing aid was at least beyond the esophagus by that point, the patient was expected to safely pass the foreign body in the coming days.

The final radiology report concluded that the foreign body was in the mid-upper abdomen, but could not confidently state the exact location.

The GI team determined the object appeared to be in the distal gastric body/antrum. After examining the patient's other hearing aid, and the size of the object on CT, they felt the object would eventually pass uneventfully, even if the exposed battery were to entirely separate from the hearing aid. However, as the patient continued to express concern, she was offered an esophagogastroduodenoscopy.

The patient had a successful endoscopy under general anesthesia the following morning with retrieval. The hearing aid was removed intact with battery still in place using a Roth net. There was no evidence of esophagitis, erosions, or ulcerations. The patient tolerated the endoscopy well with only a mild sore throat.

## DISCUSSION

This is the first report of ingestion of an ITE hearing aid traveling past the gastroesophageal junction. We could find only one other case of an 86-year-old man accidentally ingesting a whole hearing aid, but this was a larger behind-the-ear (BTE) device.<sup>4</sup> He presented with acute dysphagia, and his device was discovered in the hypopharynx. The object was uneventfully removed once the connecting tube was disconnected from the coupling device, which had lodged in the upper esophageal sphincter. The remaining molded inner-ear hearing aid portion remained distal to the BTE portion in the proximal esophagus. This remaining portion was able to be removed with endoscopy and the patient was able to swallow immediately following the procedure.

## CONCLUSION

While foreign body ingestions are common, this case is unique because a potentially dangerous exposed battery remained in the stomach for three days with minimal advancement. Exposure of stomach mucosa to the battery with potential for impaction proximal to the pylorus is a unique situation. Consensus between EPs, GI and poison center determined the situation to be non-emergent. Although comforting to the patient, we believe that endoscopic removal of the hearing aid, despite the exposed battery, was unnecessary and it would have passed given sufficient time.

---

*Address for Correspondence:* Ethan B. Kunstadt, MD, University of California, Irvine, Irvine, CA 92697. Email: [e.kunstadt@gmail.com](mailto:e.kunstadt@gmail.com).

*Conflicts of Interest:* By the CPC-EM article submission agreement, all authors are required to disclose all affiliations, funding sources and financial or management relationships that could be perceived as potential sources of bias. The authors disclosed none.

*Copyright:* © 2017 Kunstadt et al. This is an open access article distributed in accordance with the terms of the Creative Commons Attribution (CC BY 4.0) License. See: <http://creativecommons.org/licenses/by/4.0/>

---

## REFERENCES

1. Lin FR, Metter EJ, O'Brien RJ, et al. Hearing loss and incident dementia. *Arch Neurol.* 2011;68(2):214-20.
2. Chien W and Lin FR. Prevalence of hearing aid use among older adults in the United States. *Arch Intern Med.* 2012;172(3):292-3.
3. Ikenberry SO, Jue TL, Anderson MA, et al. Management of ingested foreign bodies and food impactions. *Gastrointest Endosc.* 2011;73(6):1086-91.
4. Walther E. Case Report: Swallowed hearing aid. *Laryngo-Rhino-Otol.* 1995;74(11):700-1.

# Management of Complex Facial Lacerations in the Emergency Department

**Austin Badeau, MD\***  
**Shadi Lahham, MD, MS†**  
**Megan Osborn, MD, MHPE†**

\* University of California, Irvine, Department of Plastic Surgery, Orange, California  
† University of California, Irvine, Department of Emergency Medicine, Orange, California

Section Editor: Rick A. McPheeters, DO

Submission history: Submitted December 04, 2016; Revision received February 19, 2017; Accepted February 23, 2017

Electronically published May 9, 2017

Full text available through open access at [http://escholarship.org/uc/uciem\\_cpem](http://escholarship.org/uc/uciem_cpem)

DOI: 10.5811/cpcem.2017.2.33270

Laceration injuries comprise over 8% of all emergency department (ED) visits annually.<sup>1</sup> Given that laceration injuries represent a significant volume of ED visits, emergency physicians (EP) should be comfortable treating these types of injuries. We present the case of a 34-year-old male who presented to the ED as a trauma activation who suffered multiple injuries including complex full-thickness lacerations to his face. While there are scenarios in which consulting a specialist is necessary, knowledge and application of basic wound closure principles allows for many complex lacerations to be repaired by EPs. We provide a helpful systematic approach to evaluating and treating complex facial lacerations in the ED. [Clin Pract Cases Emerg Med. 2017;1(3):162–165.]

---

## INTRODUCTION

Approximately eight million patients present to emergency departments (ED) in the United States every year with laceration injuries.<sup>1</sup> These numbers do not reflect lacerations seen and repaired in urgent care centers. Given that laceration injuries represent a significant volume of ED visits, emergency physicians (EP) should be comfortable treating these injuries. We present a patient who suffered a complex facial laceration that was managed in the ED.

## CASE REPORT

A 34-year-old male presented to the ED as a trauma activation. He was the restrained driver in a single-car motor vehicle accident in which he sustained burns to the bilateral upper extremities, left-sided rib fractures, a right femoral neck fracture, open right tibia/fibula fractures, and full-thickness lacerations to his face. There were two main facial lacerations. The first was a stellate left forehead laceration that extended deep through the frontalis muscle and inferiorly through the left eyebrow (Image 1A). The second was a through-and-through upper lip laceration that extended into and violated the floor of the nose (Image 1B).

Laceration repair began with providing anesthesia via a combination of local infiltration and targeted nerve blocks. The lacerations were then copiously irrigated with sterile saline. The forehead laceration was closed in a layered fashion using 4-0 Monocryl to re-approximate the frontalis muscle; buried

interrupted 4-0 Monocryl placed in the deep dermis; and, lastly, 5-0 fast absorbing gut suture placed in a simple interrupted manner to close the epidermis (Image 2A). The upper lip laceration was closed in a similar layered fashion using 4-0 Monocryl to re-approximate the orbicularis oris muscle; buried interrupted 4-0 Monocryl placed in the deep dermis; and 5-0 fast absorbing gut suture placed in a simple interrupted manner to close the epidermis and dry vermillion of the lip (Image 2A/B). The internal oral and nasal mucosa was closed with 4-0 Vicryl suture in a simple interrupted manner.

## DISCUSSION

Laceration injuries comprise over 8% of all ED visits annually with up to 28% of these lacerations involving the face.<sup>1</sup> Simple, superficial lacerations are often repaired by EPs, while more complex lacerations in cosmetically and/or functionally sensitive regions are often deferred to plastic surgeons, otolaryngologists, and oral-maxillofacial surgeons. This is especially true at tertiary-care academic medical centers where a full armamentarium of surgical specialists is readily available. While there are scenarios in which consulting a specialist is necessary, knowledge and application of basic wound closure principles allows for many complex lacerations to be repaired by EPs.

Initial evaluation of all traumatic facial lacerations should begin after providing adequate anesthesia. This can be achieved through a combination of short- and long-

acting local anesthetics such as lidocaine and bupivacaine respectively. Anesthetics containing epinephrine will help decrease bleeding in the operative field and decrease the systemic distribution and potential toxicity of the local anesthetic. Additionally, 1ml of bicarbonate per 10ml of local anesthetic can also be added to the anesthetic mixture to neutralize the acidity of the anesthetic solution, increase the duration of action of the anesthetic, and decreases the pain with injection. Nearly painless local anesthesia can be provided by using a bicarbonate buffering solution, injecting with a small (27-30G) needle, and by always keeping a wheel of local anesthetic ahead of the needle while injecting.<sup>2</sup> One should consider using targeted nerve blocks when possible for multiple lacerations in the same neurosensory distribution.<sup>3</sup> This method can provide adequate anesthesia and decreases the total dosage of anesthesia. Nerve blocks also offer the advantage of providing anesthesia more remotely without distorting the local anatomy of the tissue needing repair, as opposed to when anesthetic is injected locally.<sup>3</sup> This issue is especially important when attempting to re-approximate linear and cosmetically sensitive areas such as the lips, eyebrows, ears, etc.<sup>3</sup>

Tap water or saline should then be used to copiously irrigate the wound. Thorough irrigation removes all macroscopic debris, helps identify active bleeding, and allows for adequate visual exploration of the wound. During inspection of the wound, active venous or arterial bleeding should be addressed with cautery or sutures. Adequate hemostasis is especially important when closing avulsion flaps, which can develop large hematomas. Visual and manual exploration of the wound should look to identify the peripheral and deep extent of the wound. A hemostat can be used to probe for injuries communicating from one anatomic space to another. Conservative sharp debridement of ragged, severely contused, and devitalized tissue should also be performed.<sup>4</sup> Lastly, visual inspection should aim to identify any major nerve, duct or other structural injuries that would require surgical consultation and operative repair.<sup>4</sup>

The basic principle of closing all lacerations is to realign anatomic structures (superficial and deep) in a tension-free manner. Performing a layered closure helps facilitate this goal by distributing tension into the deeper, strong soft-tissue layers so that the epidermis is nearly “kissing” by the time it is sutured closed. Muscle is generally the deepest layer that requires closure in the face. In the forehead and brow, the frontalis muscle and orbicularis oculi should be re-approximated using a 4-0 absorbable monofilament suture. In full-thickness lip lacerations the orbicularis oris muscle should similarly be brought together. Muscle tissue can be difficult to re-approximate, as the tissue is relatively weak causing sutures to tear through the fibers even under minimal tension; this is especially true in contused muscle. Distributing the tension of a suture over a greater surface area of muscle using a horizontal mattress suture can help mitigate

### *CPC-EM Capsule*

What do we already know about this clinical entity?

*Annually, over 8 million patients present to emergency departments in the US with laceration injuries. Emergency physicians should be comfortable treating the majority of these injuries.*

What makes this presentation of disease reportable?

*In our ever-specializing medical environment, this case demonstrates repair of complex facial lacerations repaired in the Emergency Department without sub-specialist consultation.*

What is the major learning point?

*An understanding of and adherence to basic traumatic wound care principles allows for the management of complex laceration repairs to be performed by Emergency physicians.*

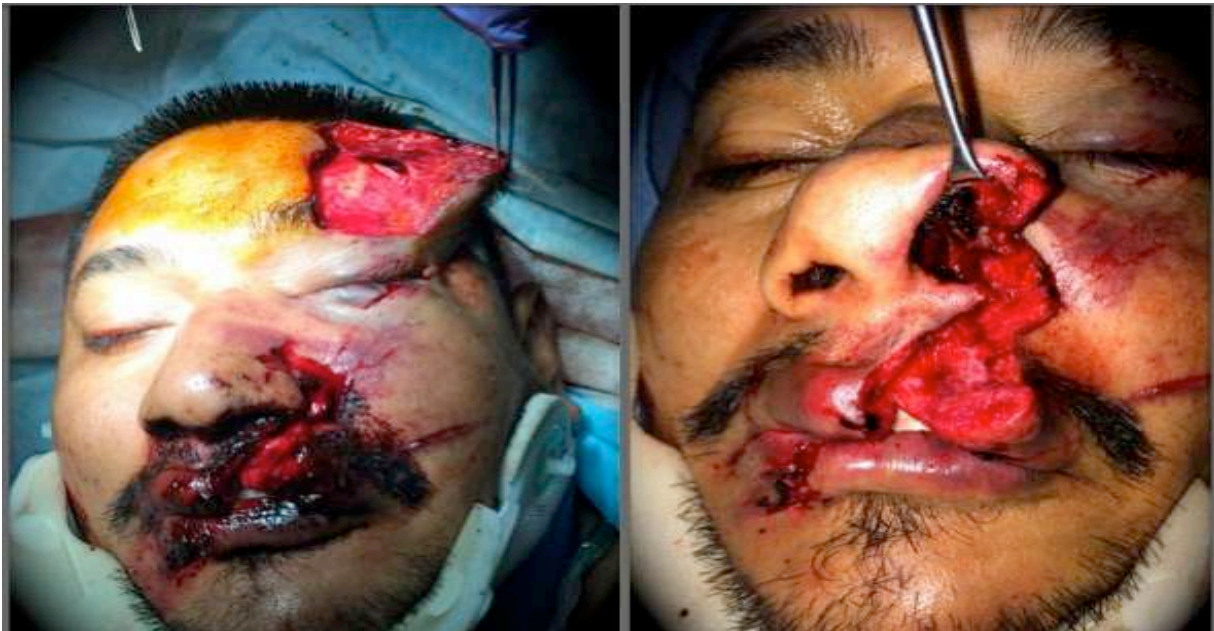How might this improve emergency medicine practice?

*For providers practicing in resource-limited environments, we demonstrate the type of laceration repairs that can be performed in the ED when surgical consultation is unavailable.*

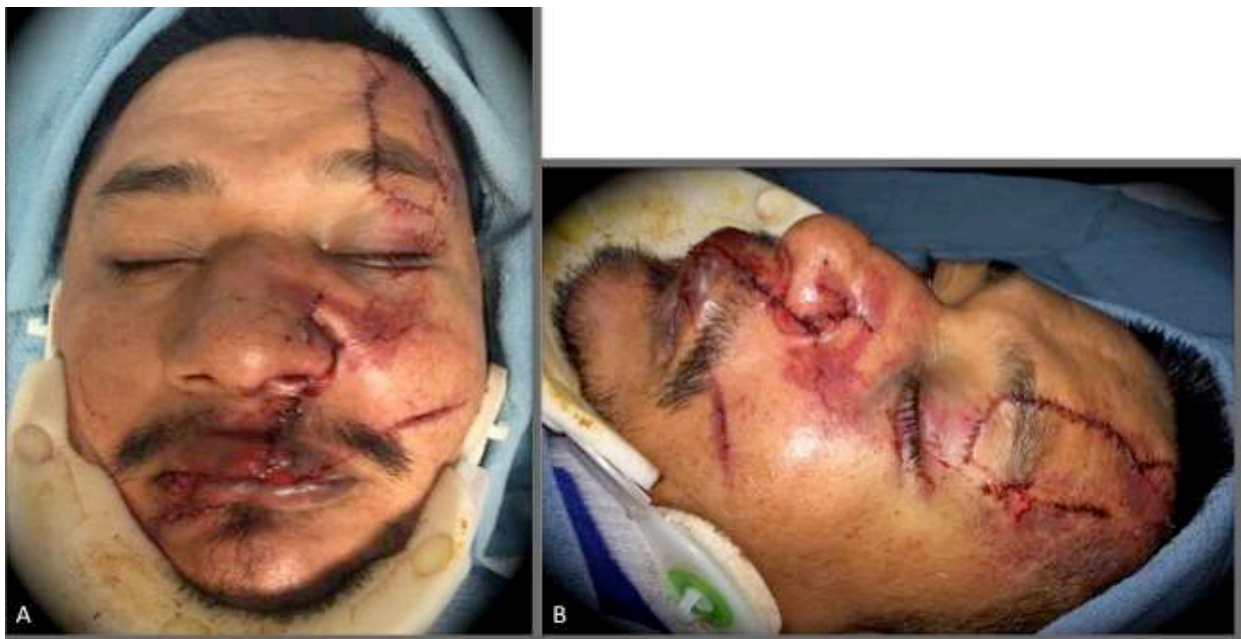this problem. Most importantly, it is important to identify and include the superficial fascia of the muscle during re-approximation because this strong fibrous component of the muscle will hold suture under normal tension. Failure to perform a proper muscle layer closure will result in non-contiguous healing of the muscle, which may cause animation deformities and depressed wide scars.

The next layer to be closed is the deep dermis and subcutaneous fat. This closure is best carried out with a 4-0 absorbable monofilament suture that is placed in simple interrupted manner with the knot buried. The suture needle should enter the subcutaneous fat and exit near the dermal-epidermal junction on one side of the laceration where it





**Image 1.** A) Full-thickness left forehead laceration. B) Full-thickness upper lip laceration extending through the floor of the nose and nasal ala.



**Image 2.** A) Repaired left forehead, upper lip, and nasal lacerations. B) Repaired left forehead, upper lip, and nasal lacerations.

will then travel across the wound and enter the dermal-epidermal junction and exit the subcutaneous tissue of the opposing side. Precise alignment of this layer is important for scar healing.

The epidermis is the most superficial layer that requires closure. When repairing the lip, it is crucial to precisely align the vermilion border where even a 1mm discrepancy is

discernable at conversational distance. This is best achieved with a 5-0 or 6-0 non-absorbable monofilament suture; a similar size un-dyed rapidly dissolving suture will also work and has the advantage of not needing to be removed. EPs should be especially mindful of the burden of suture removal in young children and patients with poor follow-up. When permanent sutures are placed in the epidermis of the face,

they should be removed in 5-7 days to prevent the unsightly “train-track” appearance of a scar where sutures have been left in for too long. Consider using a brightly dyed non-absorbable suture when repairing lacerations extending into the scalp of patients with dark hair, as this will make suture removal much easier. In either suture choice, the laceration should be repaired in a simple interrupted manner. Longer lacerations can be repaired with a continuous “baseball” stitch to increase speed of the repair. This advantage should be weighed against the disadvantage of relying on a single continuous stitch for the epidermal repair where rupture of the suture or tearing of the skin compromises the entire length of the repair.

Tissue glue, such as Dermabond, can also be used to close the epidermal layer of skin. In very superficial lacerations that do not fully penetrate the dermis, Dermabond can be used alone to re-approximate the superficial dermis and epidermis. Using Dermabond in this way is especially useful in pediatric patients where suturing may require monitored sedation. Dermabond is most commonly used in conjunction with other deep and superficial suture layers. Sealing wounds with Dermabond in this fashion adds another layer of strength and provides a watertight closure, which can be washed and left open to the air without concern for contamination from physical debris and bacteria. Of note, previous studies are undecided on the use of antibiotics. In wounds with high risk for infection consider starting prophylactic antibiotics.<sup>5</sup>

Nasal and oral mucosa should be repaired in a simple interrupted manner with a soft, braided absorbable suture. When repairing lip lacerations the oral mucosa should be repaired after the muscle layer is re-approximated, but before closure of the epidermis.

Most lacerations will be treated in regular, perhaps dimly lit, rooms rather than trauma bays with adjustable overhead spotlights. Accordingly, a camping-style headlamp is an invaluable and relatively cheap tool that EPs should purchase and can use for a variety of procedures including laceration repair. Lastly, always try to use a flat-surfaced needle holder/driver while suturing, especially when using small needles. Most EDs stock or can acquire separate surgical grade flat-surfaced needle holder/drivers. Unfortunately, pre-packaged suture kits often contain needle holder/drivers with serrations through which small needles can rotate and slide. This can be especially frustrating and time consuming when repairing large lacerations.

Closing complex facial lacerations is a professionally rewarding procedure. While some lacerations may require surgical consultation, many complex lacerations can be treated immediately by EPs with arrangement for sub-specialist follow-up on cosmetically and/or functionally sensitive injuries. Time constraints are a significant obstacle that may

preclude treating these types of complex facial injuries in the ED. This is especially true in single coverage EDs; conversely single coverage EDs may also be less likely to have on-call surgical sub-specialists available to treat these injuries. Management of large complex lacerations should be in the scope of all EPs and is a necessity for those whose practice includes rural emergency medicine, wilderness medicine, cruise ship medicine, expedition medicine, etc. When faced with any laceration injury, remember to first provide complete local anesthesia using local nerve blocks when possible. Next, perform thorough irrigation and exploration of the wound. Lastly, perform a multi-layered closure of the wound to achieve a tension-free re-alignment of the deep and superficial anatomy. Applying this approach should allow all EPs to successfully tackle a high percentage of laceration injuries.

---

*Address for Correspondence:* Austin Badeau, MD, 333 The City Blvd West, Rt 128-01, Suite 640, Orange, CA 92868. Email: abadeau@uci.edu.

*Conflicts of Interest:* By the CPC-EM article submission agreement, all authors are required to disclose all affiliations, funding sources and financial or management relationships that could be perceived as potential sources of bias. The authors disclosed none.

*Copyright:* © 2017 Badeau et al. This is an open access article distributed in accordance with the terms of the Creative Commons Attribution (CC BY 4.0) License. See: <http://creativecommons.org/licenses/by/4.0/>

---

## REFERENCES

1. Singer AJ, Thode HC, Hollander JE. National trends in ED lacerations between 1992 and 2002. *Am J Emerg Med.* 2006;24(2):183–8.
2. Mustoe TA, Buck DW, Lalonde DH. The safe management of anesthesia, sedation, and pain in plastic surgery. *Plast Reconstr Surg.* 2010;126(4):165e–76e.
3. Zide BA, Swift R. How to block and tackle the face. *Plast Reconstr Surg.* 1998;101(3):840–51.
4. Thorne CH, Beasley RW, Ashton SJ, et al, eds. Grabb and Smith's Plastic Surgery. 6<sup>th</sup> ed. Philadelphia: Lippincott Williams & Wilkins, 2007.
5. Cummings P, Del Beccaro MA. Antibiotics to prevent infection of simple wounds: a meta-analysis of randomized studies. *Am J Emerg Med.* 1995;13(4):396–400.

# Pediatric Death Due to Myocarditis After Exposure to Cannabis

Thomas M. Nappe, DO\*  
Christopher O. Hoyte, MD†

\*Denver Health and Hospital Authority, Rocky Mountain Poison and Drug Center,  
Denver, Colorado

†University of Colorado School of Medicine at Anschutz Medical Center, Department  
of Emergency Medicine, Aurora, Colorado

Section Editor: Shadi Lahham, MD, MS

Submission history: Submitted November 29, 2016; Revision received January 20, 2017; Accepted January 21, 2017

Electronically published March 16, 2017

Full text available through open access at [http://escholarship.org/uc/uciem\\_cpem](http://escholarship.org/uc/uciem_cpem)

DOI: 10.5811/cpcem.2017.1.33240

Since marijuana legalization, pediatric exposures to cannabis have increased.<sup>1</sup> To date, pediatric deaths from cannabis exposure have not been reported. The authors report an 11-month-old male who, following cannabis exposure, presented with central nervous system depression after seizure, and progressed to cardiac arrest and died. Myocarditis was diagnosed post-mortem and cannabis exposure was confirmed. Given the temporal relationship of these two rare occurrences – cannabis exposure and sudden death secondary to myocarditis in an 11-month-old – as well as histological consistency with drug-induced myocarditis without confirmed alternate causes, and prior reported cases of cannabis-associated myocarditis, a possible relationship exists between cannabis exposure in this child and myocarditis leading to death. In areas where marijuana is commercially available or decriminalized, the authors urge clinicians to preventively counsel parents and to include cannabis exposure in the differential diagnosis of patients presenting with myocarditis. [Clin Pract Cases Emerg Med. 2017;1(3):166–170.]

---

## INTRODUCTION

Since marijuana legalization, pediatric exposures to cannabis have increased, resulting in increased pediatric emergency department (ED) visits.<sup>1</sup> Neurologic toxicity is most common after pediatric exposure; however, gastrointestinal and cardiopulmonary toxicity are reported.<sup>1</sup> According to a retrospective review of 986 pediatric cannabis ingestions from 2005 to 2011, pediatric exposure has been specifically linked to a multitude of symptoms including, but not limited to, drowsiness, lethargy, irritability, seizures, nausea and vomiting, respiratory depression, bradycardia and hypotension.<sup>1</sup> Prognosis is often reassuring.<sup>1</sup> Specific myocardial complications related to cannabis toxicity that are well documented in adolescence through older adulthood include acute coronary syndrome, cardiomyopathy, myocarditis, pericarditis, dysrhythmias and cardiac arrest.<sup>2-4</sup> To date, there are no reported pediatric deaths from myocarditis after confirmed, recent cannabis exposure. The authors report an 11-month-old male who, following cannabis exposure, presented in cardiac arrest after seizure and died. Myocarditis was diagnosed post-mortem and cannabis exposure was confirmed. Analyses of serum cannabis metabolites, post-

mortem infectious testing, cardiac histopathology, as well as clinical course, support a potential link between the cannabis exposure and myocarditis that would justify preventive parental counseling and consideration of urine drug screening in this reported setting.

## CASE REPORT

An 11-month-old male with no known past medical history presented to the ED with central nervous system (CNS) depression and then went into cardiac arrest. The patient was lethargic for two hours after awakening that morning and then had a seizure. During the prior 24-48 hours, he was irritable with decreased activity and was later retching. He was noted to be healthy before developing these symptoms. Upon arrival in the ED, he was unresponsive with no gag reflex. Vital signs were temperature 36.1° Celsius, heart rate 156 beats per minute, respiratory rate 8 breaths per minute, oxygen saturation 80% on room air. Physical exam revealed a well-nourished, 20.5 lb., 11-month-old male, with normal development, no trauma, normal oropharynx, normal tympanic membranes, no lymphadenopathy, tachycardia, clear lungs, normal abdomen and Glasgow Coma Scale



rating of 4. He was intubated for significant CNS depression and required no medications for induction or paralysis. Post-intubation chest radiograph is shown in Image 2. He subsequently became bradycardic with a heart rate in the 40s with a wide complex rhythm. Initial electrocardiogram (ECG) was performed and is shown in Image 1. He then became pulseless, and cardiopulmonary resuscitation was initiated. Laboratory analysis revealed sodium 136 mmol/L, potassium 7.7 mmol/L, chloride 115 mmol/L, bicarbonate 8.0 mmol/L, blood urea nitrogen 24 mg/dL, creatinine 0.9 mg/dL, and glucose 175 mg/dL. Venous blood gas pH was 6.77. An ECG was repeated (Image 3). He received intravenous fluid resuscitation, sodium bicarbonate infusion, calcium chloride, insulin, glucose, ceftriaxone and four doses of epinephrine. Resuscitation continued for approximately one hour but the patient ultimately died.

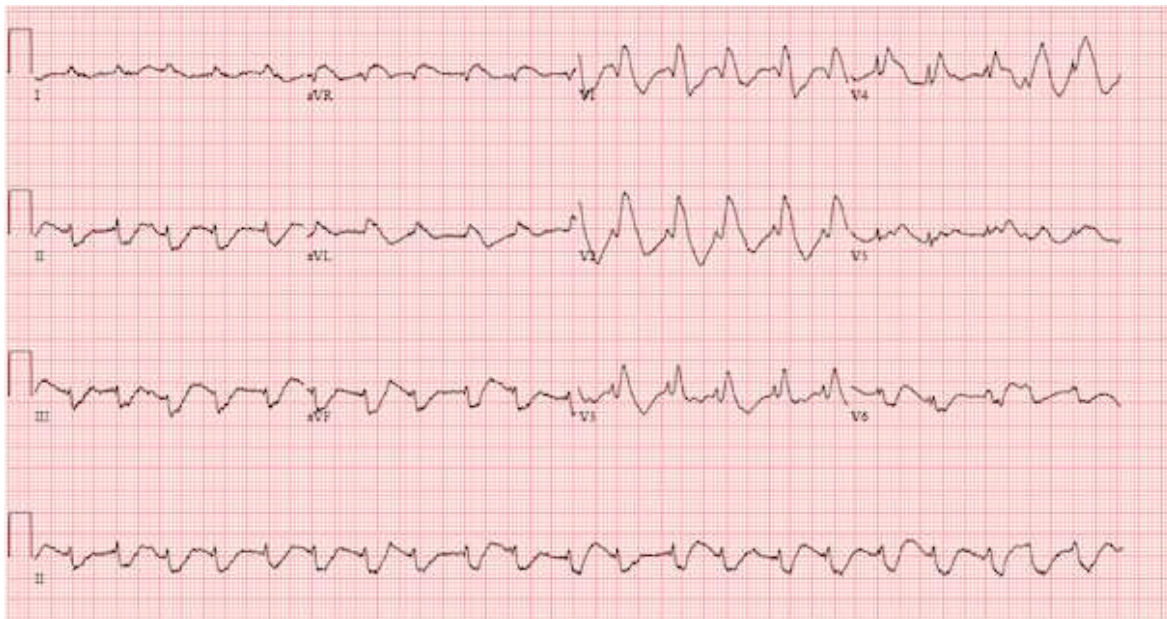Further laboratory findings in the ED included a complete blood count (CBC) with differential, liver function tests (LFTs), one blood culture and toxicology screen. CBC demonstrated white blood cell count 13.8 K/mcL with absolute neutrophil count of 2.5 K/mcL and absolute lymphocyte count of 10.7 K/mcL, hemoglobin 10.0 gm/dL, hematocrit 34.7%, and platelet count 321 K/mcL. LFTs showed total bilirubin 0.6 mg/dL, aspartate aminotransferase 77 IU/L, and alanine transferase 97 IU/U. A single blood culture from the right external jugular vein revealed aerobic gram-positive rods that were reported two days later as *Bacillus* species (not *Bacillus anthracis*). Toxicology screening revealed urine enzyme-linked immunosorbent assay positive for tetrahydrocannabinol-carboxylic acid (THC-

COOH) and undetectable serum acetaminophen and salicylate concentrations. Route and timing of exposure to cannabis were unknown.

Autopsy revealed a non-dilated heart with normal coronary arteries. Microscopic examination showed a severe, diffuse, primarily lymphocytic myocarditis, with a mixed cellular infiltrate in some areas consisting of histiocytes, plasma cells, and eosinophils. Myocyte necrosis was also observed. There was no evidence of concomitant bacterial or viral infection based on post-mortem cultures obtained from cardiac and peripheral blood, lung pleura, nasopharynx and cerebrospinal fluid. Post-mortem cardiac blood analysis confirmed the presence of  $\Delta$ -9-carboxy-tetrahydrocannabinol ( $\Delta$ -9-carboxy-THC) at a concentration of 7.8 ng/mL. Additional history disclosed an unstable motel-living situation and parental admission of drug possession, including cannabis.

## DISCUSSION

As of this writing, this is the first reported pediatric death associated with cannabis exposure. Given the existing relationship between cannabis and cardiovascular (CV) toxicity, as well as the temporal progression of events, post-mortem analysis, and previously reported cases of cannabis-induced myocarditis, the authors propose a relationship between cannabis exposure in this patient and myocarditis, leading to cardiac arrest and ultimately death. This occurrence should justify consideration of urine drug screening for cannabis in pediatric patients presenting with myocarditis of unknown etiology in areas where cannabis is widely used. In addition, parents should be counseled



**Image 1.** Initial electrocardiogram demonstrating wide-complex tachycardia.

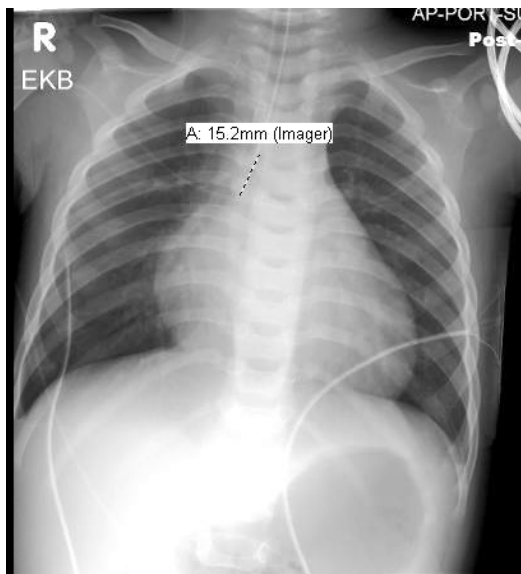
regarding measures to prevent such exposures.

The progressive clinical presentation of this patient during the prior 24-48 hours, including symptoms of somnolence, lethargy, irritability, nausea, seizure and respiratory depression are consistent with previously documented, known complications of recent cannabis exposure in the pediatric population.<sup>1</sup> It is well known that common CV effects of cannabis exposure include tachycardia and decreased vascular

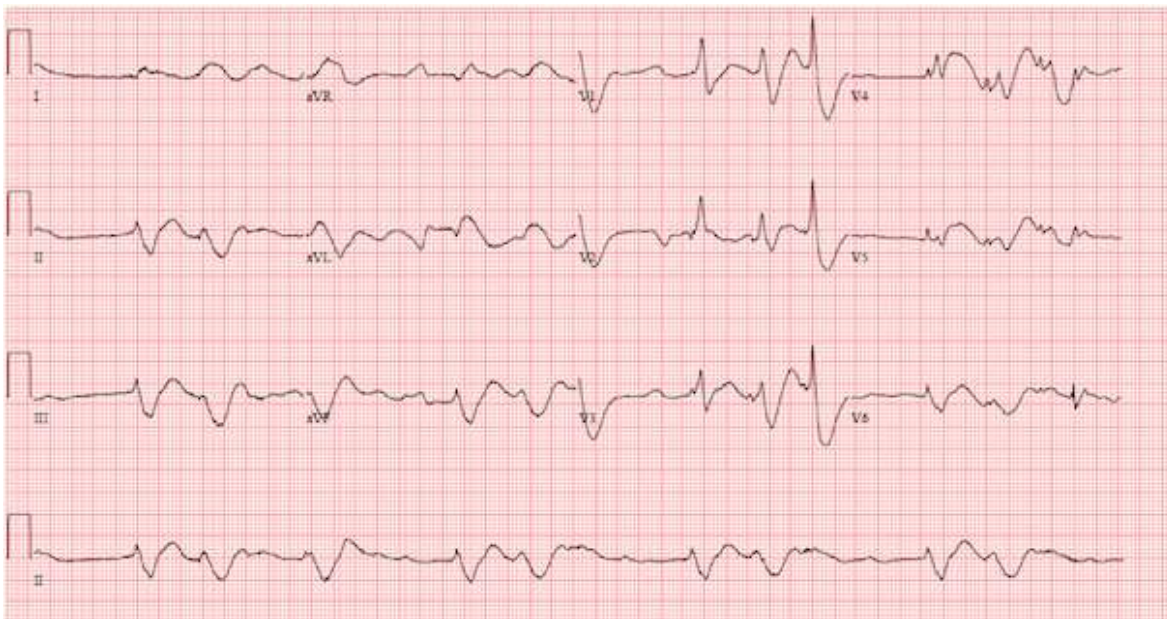resistance with acute use and bradycardia in more chronic use.<sup>2,5-7</sup> These effects are believed to be multifactorial, and evidence suggests that cannabinoid effect on the autonomic nervous system, peripheral vasculature, cardiac microvasculature, and myocardial tissue and Purkinje fibers are all likely contributory.<sup>2</sup> The pathogenesis of myocarditis is not fully understood. In general, myocarditis results from direct damage to myocytes from an offending agent such as a virus, or in this case, potentially a toxin. The resulting cellular injury leads to a local inflammatory response. Destruction of cardiac tissue may result in myocyte necrosis and arrhythmogenic activity, or cellular remodeling in chronic myocarditis.<sup>8,9</sup>

Autopsy findings in this patient were consistent with noninfectious myocarditis as a cause of death. The histological findings of myocyte necrosis with mature lymphocytic mixed cellular infiltrate are consistent with drug-induced, toxic myocarditis.<sup>10</sup> The presence of THC metabolites in the patient's urine and serum, most likely secondary to ingestion, is the only uncovered risk factor in the etiology for his myocarditis. This is highly unlikely attributable to passive exposure.<sup>11,12</sup>

It is difficult to extrapolate a specific time of cannabis ingestion given the unknown dose of THC, the individual variability of metabolism and excretion, as well as the lack of data on this topic in the pediatric population and post-mortem redistribution (PMR) kinetics. However, the THC metabolite detected in the patient's blood,  $\Delta$ -9-carboxy-THC, is known to peak in less than six hours and be detectable for at least a day, while the parent compound, tetrahydrocannabinol



**Image 2.** Post-intubation chest radiograph. Measurement indicates distance of endotracheal tube tip above carina.



**Image 3.** Repeat electrocardiogram showing disorganized rhythm, peri-arrest.



(THC), is expected to rapidly metabolize and distribute much more quickly, being potentially undetectable six hours after exposure in an infrequent user.<sup>13</sup> The parent compound was below threshold for detection in this patient's blood. In addition, if cannabis ingestion occurred the day of presentation, it would have been more likely that THC would have been detected with its metabolite after PMR.<sup>14,15</sup> Given this information, the authors deduce that cannabis consumption occurred within the recent two to six days, assuming this was a single, acute high-potency ingestion. This time frame would overlap with the patient's symptomatology and allow time for the development of myocarditis, thus supporting cannabis as the etiology.

The link between cannabis use and myocarditis has been documented in multiple teenagers and young adults.<sup>16-18</sup> In 2008 Leontiadis reported a 16-year-old with severe heart failure requiring a left ventricular assist device, associated with biopsy-diagnosed myocarditis.<sup>16</sup> The authors attributed the heart failure to cannabis use of unknown chronicity.<sup>16</sup> In 2014 Rodríguez-Castro reported a 29-year-old male who had two episodes of myopericarditis several months apart.<sup>17</sup> Each episode occurred within two days of smoking cannabis.<sup>18</sup> In 2016, Tournebize reported a 15-year-old male diagnosed with myocarditis, clinically and by cardiac magnetic resonance imaging, after initiating regular cannabis use eight months earlier.<sup>18</sup> There were no other causes for myocarditis, including infectious, uncovered by these authors, and no adulterants were identified in these patients' consumed marijuana.<sup>16-18</sup> Unlike our patient, all three of these previously reported patients recovered.

In the age of legalized marijuana, children are at increased risk of exposure, mainly through ingestion of food products, or "edibles."<sup>19</sup> These products are attractive in appearance and have very high concentrations of THC, which can make small exposures exceptionally more toxic in small children.<sup>19,20</sup>

Limitations in this report include the case study design, the limitations on interpreting an exact time, dose and route of cannabis exposure, the specificity of histopathology being used to classify etiology of myocarditis, and inconsistent blood culture results. The inconsistency in blood culture results also raises concern of a contributing bacterial etiology in the development of myocarditis, leading to the possibility that cannabis may have potentially induced the fatal symptomatology in an already-developing silent myocarditis. However, due to high contaminant rates associated with bacillus species and negative subsequent blood cultures, the authors believe this was more likely a contaminant.<sup>21</sup> In addition, the patient had no source of infection on exam or recent history and was afebrile without leukocytosis.<sup>22</sup> All of his subsequent cultures from multiple sites were negative.

## CONCLUSION

Of all the previously reported cases of cannabis-induced myocarditis, patients were previously healthy and

no evidence was found for other etiologies. All of the prior reported cases were associated with full recovery. In this reported case, however, the patient died after myocarditis-associated cardiac arrest. Given two rare occurrences with a clear temporal relationship – the recent exposure to cannabis and the myocarditis-associated cardiac arrest – we believe there exists a plausible relationship that justifies further research into cannabis-associated cardiotoxicity and related practice adjustments. In states where cannabis is legalized, it is important that physicians not only counsel parents on preventing exposure to cannabis, but to also consider cannabis toxicity in unexplained pediatric myocarditis and cardiac deaths as a basis for urine drug screening in this setting.

---

*Address for Correspondence:* Thomas M. Nappe, DO, Denver Health and Hospital Authority, Rocky Mountain Poison and Drug Center, 1391 Speer Blvd, Denver, CO 80204. Email: dr.thomas.nappe@gmail.com.

*Conflicts of Interest:* By the CPC-EM article submission agreement, all authors are required to disclose all affiliations, funding sources and financial or management relationships that could be perceived as potential sources of bias. The authors disclosed none.

*Copyright:* © 2017 Nappe et al. This is an open access article distributed in accordance with the terms of the Creative Commons Attribution (CC BY 4.0) License. See: <http://creativecommons.org/licenses/by/4.0/>

---

## REFERENCES

1. Wang GS, Roosevelt G, Le Lait MC, et al. Association of unintentional pediatric exposures with decriminalization of marijuana in the United States. *Ann Emerg Med.* 2014;63(6):684-9.
2. Panayiotides IM. What is the association of cannabis consumption and cardiovascular complications? *Subst Abuse.* 2015;9:1-3.
3. Bachs L, Mørland H. Acute cardiovascular fatalities following cannabis use. *Forensic Sci Int.* 2001;124(2-3):200-3.
4. Aryana A, Williams MA. Marijuana as a trigger of cardiovascular events: Speculation or scientific certainty? *Int J Cardiol.* 2007;118(2):141-4.
5. Jones RT. Cardiovascular system effects of marijuana. *J Clin Pharmacol.* 2002;42(11 Suppl):58S-63S.
6. Sidney S. Cardiovascular consequences of marijuana use. *J Clin Pharmacol.* 2002;42(11 Suppl):64S-70S.
7. Benowitz NL, Jones RT. Cardiovascular effects of prolonged delta-9-tetrahydrocannabinol ingestion. *Clin Pharmacol Ther.* 1975;18(3):287-97.

8. Kindermann I, Barth C, Mahfoud F, et al. Update on myocarditis. *J Am Coll Cardiol*. 2012;59(9):779-92.
9. Cooper LT Jr. Myocarditis. *N Eng J Med*. 2009;360(15):1526-38.
10. Aretz HT, Billingham ME, Edwards WD, et al. Myocarditis. A histopathologic definition and classification. *Am J Cardiovasc Pathol*. 1987;1(1):3-14.
11. Perez-Reyes M, Di Guiseppi S, Mason AP, et al. Passive inhalation of marijuana smoke and urinary excretion of cannabinoids. *Clin Pharmacol Ther*. 1983;34(1):36-41.
12. Cone EJ, Bigelow GE, Herrmann ES, et al. Nonsmoker exposure to secondhand cannabis smoke. III. Oral fluid and blood drug concentrations and corresponding subjective effects. *J Anal Toxicol*. 2015;39(7):497-509.
13. Huestis MA, Henningfield JE, Cone EJ. Blood cannabinoids. II. Models for the prediction of time of marijuana exposure from plasma concentrations of delta 9-tetrahydrocannabinol (THC) and 11-nor-9-carboxy-delta 9-tetrahydrocannabinol (THCCOOH). *J Anal Toxicol*. 1992;16(5):283-90.
14. Giroud C, Ménétrey A, Augsburger M, et al. Delta(9)-THC, 11-OH-Delta(9)-THC and Delta(9)-THCCOOH plasma or serum to whole blood concentrations distribution ratios in blood samples taken from living and dead people. *Forensic Sci Int*. 2001;123(2-3):159-64.
15. Holland MG, Schwoppe DM, Stoppacher R, et al. Postmortem redistribution of  $\Delta$ 9-tetrahydrocannabinol (THC), 11-hydroxy-THC (11-OH-THC), and 11-nor-9-carboxy-THC (THCCOOH). *Forensic Sci Int*. 2011;212(1-3):247-51.
16. Leontiadis E, Morshuis M, Arusoglu L, et al. Thoratec left ventricular assist device removal after toxic myocarditis. *Ann Thorac Surg*. 2008;86(6):1982-5.
17. Rodriguez-Castro CE, Alkhateeb H, Elfar A, et al. Recurrent myopericarditis as a complication of marijuana use. *Am J Case Rep*. 2014;15:60-2.
18. Tournebize J, Gibaja V, Puskarczyk E, et al. Myocarditis associated with cannabis use in a 15-year-old boy: A rare case report. *Int J Cardiol*. 2016;203:243-4.
19. Wang GS, Roosevelt G, Heard K. Pediatric marijuana exposures in a medical marijuana state. *JAMA Pediatr*. 2013;167(7):630-3.
20. MacCoun RJ, Mello MM. Half-baked—the retail promotion of marijuana edibles. *N Engl J Med*. 2015;372(11):989-91.
21. Hall KK, Lyman JA. Updated review of blood culture contamination. *Clin Microbiol Rev*. 2006;19(4):788-802.
22. Sard B, Bailey MC, Vinci R. An analysis of pediatric blood cultures in the postpneumococcal conjugate vaccine era in a community hospital emergency department. *Pediatr Emerg Care*. 2006;22(5):295-300.



# Posterior Reversible Encephalopathy Syndrome Presenting as Stroke Mimic

Daniel Frick, DO  
Martin Huecker, MD  
Hugh Shoff, MD

University of Louisville School of Medicine, Department of Emergency Medicine,  
Louisville, Kentucky

Section Editor: Rick A. McPheeters, DO

Submission history: Submitted April 16, 2016; Revision received January 24, 2017; Accepted January 24, 2017

Electronically published May 9, 2017

Full text available through open access at [http://escholarship.org/uc/uciem\\_cpchem](http://escholarship.org/uc/uciem_cpchem)

DOI: 10.5811/cpcem.2017.1.30607

We present the case of a 33-year-old male with end stage renal disease presenting to the emergency department (ED) with headache, dizziness, and unilateral weakness. Initial concern was for ischemic or hemorrhagic stroke. Magnetic resonance imaging confirmed posterior reversible encephalopathy syndrome (PRES). The patient was treated appropriately and made a full neurologic recovery. PRES is an under-recognized diagnosis in the ED. As a stroke mimic, PRES can lead the clinician on an incorrect diagnostic pathway with potential for iatrogenic harm. [Clin Pract Cases Emerg Med. 2017;1(3):171–174.]

---

## INTRODUCTION

Posterior reversible encephalopathy syndrome (PRES) is a neurologic condition characterized by localized vasogenic edema primarily affecting the occipital and parietal lobes.<sup>1</sup> While PRES is not yet completely understood, it is typically seen in the setting of common clinical scenarios: hypertension (HTN), cytotoxic medications, eclampsia, autoimmune, and systemic conditions.<sup>2</sup> The most commonly presenting symptoms of this disease are headaches, seizures, altered mental status, and visual changes or loss. Encephalopathy can range from mild confusion to a severe decrease in level of consciousness.<sup>3</sup> While the exact incidence of PRES is not known, reported cases exist in patients from 4-90 years old with predominance in female patients, with a mean age of 45 years.<sup>4,5</sup> Due to its rarity and variable presentation, PRES is difficult to diagnose without radiographic imaging. A noncontrast computerized tomography (CT) of the head is of little benefit and ultimately magnetic resonance imaging (MRI) of the brain is necessary to demonstrate vasogenic edema and other pathognomonic findings.

PRES is often overlooked due to clinical features shared with many common conditions including ischemic or hemorrhagic stroke, migraine, seizure, hypertensive urgency, and reversible cerebral vasoconstriction syndrome. Such a misdiagnosis can result in inappropriate use of thrombolytic therapy or other more invasive procedures, ultimately delaying appropriate treatment. Therefore, in a potential stroke patient with vision changes or altered mental status, PRES must be considered.

## CASE REPORT

A 33-year-old male with uncontrolled HTN and end stage renal disease (ESRD) presented to the emergency department (ED) just prior to scheduled hemodialysis due to severe HTN. Initial blood pressure was 248/165 mmHg and the patient complained of a worsening headache and throbbing pain behind his eyes. He admitted to missing his last session of dialysis and his laboratory values were remarkable for a blood urea nitrogen (BUN) of 53mg/dL, creatinine (Cr) 4.67mg/dL, and serum bicarbonate (CO<sub>2</sub>) 21 mEq/L. Remaining serum electrolytes and hepatic function panel were normal. Symptoms were attributed to volume overload due to missed dialysis, and treatment with furosemide 40mg intravenous (IV) was initiated. Repeat blood pressure was 197/134 mmHg, and the patient was transported to the dialysis unit.

Upon completion of dialysis he remained hypertensive and immediately returned to the ED with severe headache, dizziness, and unilateral weakness. His blood pressure was 200/135 mmHg, heart rate 93 beats per minute, respiratory rate 22 respirations per minute, temperature 98.9°F. Physical examination was significant for pupils equal and reactive to light bilaterally with extra ocular movements intact, cranial nerves II-XII intact, [3/5] strength in the right upper extremity, [5/5] strength in left upper extremity, [2/5] strength in the right lower extremity, [5/5] strength in left lower extremity. Laboratory values showed the following abnormalities: BUN 39mg/dL, Cr 3.67 mg/dL, and brain natriuretic peptide 42500 pg/mL; serum electrolytes, hepatic function and troponin were normal.

Initial noncontrast head CT showed hypodense areas in the right lentiform nucleus and the medial bilateral occipital lobes concerning for acute to subacute infarct. Potential hypodense areas in the cerebellar hemispheres concerning for acute to subacute infarct could not be distinguished from artifact from adjacent bony structures. The patient's unilateral right-sided weakness and CT findings brought stroke to the top of the differential diagnosis and the stroke team was consulted. The patient's blood pressure was initially treated with one sublingual nitroglycerin prior to IV access, followed by 10mg intravenous labetalol. One hour after the patient's arrival his blood pressure was 136/90 mmHg. The patient complained of continued headache and progressively worsening bilateral visual field deficits involving both inferior quadrants of each eye as well as bilateral loss of visual acuity. His blood pressure remained labile and he was subsequently placed on a nicardipine drip at 2.5mg/hr for more precise blood pressure titration.

Following blood pressure stabilization, an MRI brain without contrast (our institution's stroke protocol) was obtained. MRI showed extensive T2 fluid-attenuated inversion recovery (FLAIR) hyperintensities involving the occipital lobe gray matter and the subcortical white matter of the occipital, parietal, and frontal lobes. T2 FLAIR hyperintensities were also present in the deep gray and white matter, periventricular white matter, cerebellum, midbrain, and pons. A mixture of cytotoxic and vasogenic edema was seen as diffusion-weighted hyperintensities involving the left body of the corpus callosum and an area of deep white matter in the posterior right frontal lobes (Image).

### CPC-EM Capsule

What do we already know about this clinical entity?

*Posterior Reversible Encephalopathy (PRES) is vasogenic edema of the brain resulting in a spectrum of neurologic deficits ranging from headaches and vision loss to seizures and encephalopathy.*

What makes this presentation of disease reportable?

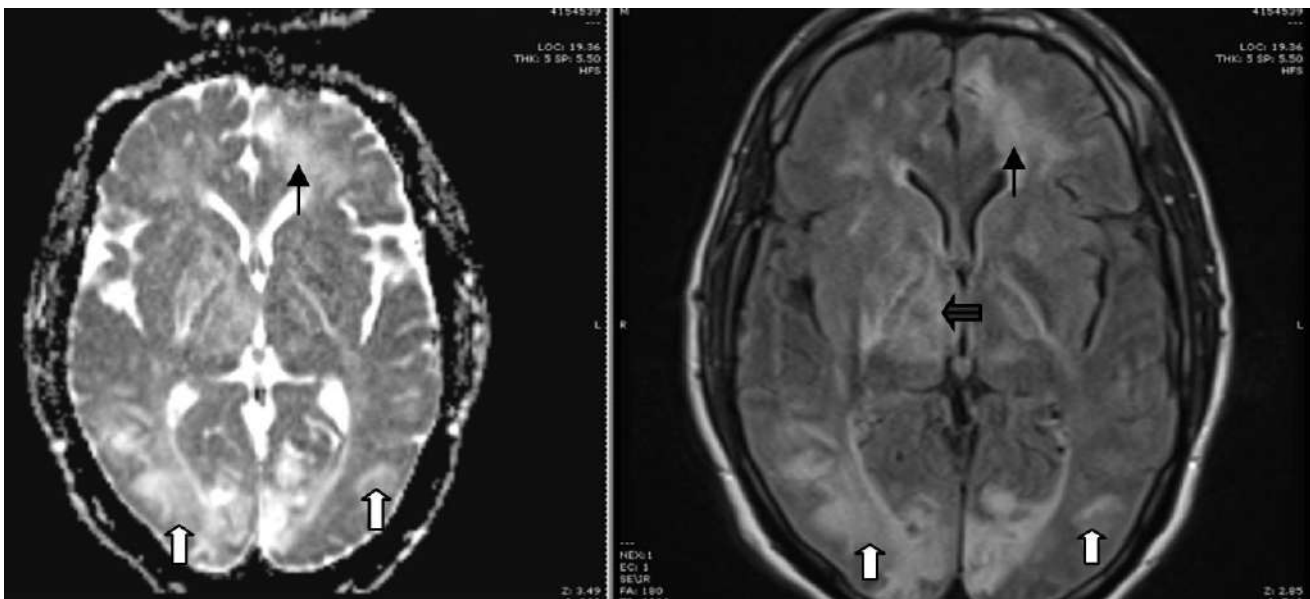
*PRES is often overlooked due to clinical features shared with common conditions. If promptly diagnosed and managed, PRES can result in favorable patient outcomes.*

What is the major learning point?

*Missed or delayed diagnosis of PRES may result in improper administration of thrombolytic therapy and iatrogenic adverse events.*

How might this improve emergency medicine practice?

*Maintaining a broad differential in patients with neurologic deficits will allow physicians to accurately diagnose and appropriately treat life-threatening conditions.*



**Image.** MRI Left: Diffusion imaging showing increased signal in the bilateral occipital lobes (white arrows) and left frontal lobe (black arrow). MRI Right: T2 FLAIR imaging showing correlating hyperintensities in bilateral occipital lobes (white arrows), left frontal lobe (black arrow) and right periventricular area (black bold arrow).

*MRI, magnetic resonance imaging; FLAIR, fluid attenuation inversion recovery*

The patient was admitted to the stroke service and was eventually transitioned to oral anti-hypertensive medications. His vision began to improve 24 hours after admission and upon discharge eight days later he had markedly improved visual acuity: 20/20 in the right eye with a mild right inferior quadrantanopia and 20/40 in the left eye. His hospital course was prolonged by dialysis requirements and transfer to the psychiatric floor due to suicidal ideation and depression stemming from his poor health and hospitalization.

## DISCUSSION

PRES was initially described in 1996 by Hinchey et al. as a clinical and radiologic diagnosis most often presenting with headaches (50%), vision changes (33%), seizures (60-75%), and less commonly focal neurologic deficits (10-15%).<sup>6,2</sup> Our patient presented with focal neurologic deficits involving the right upper extremity and right lower extremity as well as dizziness, headache, and vision changes. Our initial presumed diagnosis was stroke, and this appeared to be confirmed with the noncontrast head CT showing multiple hypodense areas. While PRES can be suspected based on clinical presentation, diagnosis is often confirmed radiographically. A noncontrast head CT rarely aids in the diagnosis; however, a CT perfusion (CTP) study may show increased cerebral blood volume, cerebral blood flow, and reduced time to peak blood flow.<sup>9</sup> In addition, hyperperfusion indicating high metabolic demand on CTP imaging may indicate seizure as a possible cause of neurologic deficits versus an acute ischemic insult.<sup>10</sup> Such CTP findings can facilitate rapid diagnosis of PRES and other stroke mimics, allowing for quicker initiation of appropriate therapy. PRES commonly manifests on MRI as vasogenic edema in the parieto-occipital regions of both cerebral hemispheres with involvement of the subcortical white matter and the cortex.

Given diverse presentation, PRES has three primary variations: a dominant parieto-occipital pattern, holo-hemispheric watershed pattern, and superior frontal sulcus pattern.<sup>7,8</sup> The diffuse intracranial involvement as seen on MRI in our patient appears to be an unusual presentation for PRES.

The vasogenic brain edema is believed to be the result of increased local perfusion pressure resulting in the failure of the blood brain barrier to maintain the compartmentalization of intravascular fluid. Capillary endothelial integrity is compromised due to increases in blood pressure, various systemic disease states, or cytotoxic medications. Blood pressure increase detected by cerebral endothelial mechanoreceptors leads to cerebral arteriolar vasoconstriction. The autoregulatory vasoconstriction system of the arterioles becomes overwhelmed and leads to an increase in cerebral blood flow.<sup>11,2</sup> If the hyperperfusion overwhelms the autoregulatory response, break down of the blood brain barrier can occur.

The relatively poor sympathetic innervation of the posterior fossa of the brain makes this area particularly

susceptible to hyperperfusion and vasogenic edema.<sup>2</sup> Our patient presented with multiple episodes of high blood pressure prior to the onset of his symptoms. This appears to have allowed ample time for disruption of the autoregulation of the cerebral vasculature, breakdown of the blood brain barrier, and ultimately vasogenic edema. While HTN is thought to be a large contributor to the development of PRES, 20-40% of patients are normotensive.<sup>12</sup>

Other pathophysiologic explanations include an inflammatory response affecting vascular permeability directly through cytokine release. Cytokines activate endothelial cells to secrete vasoactive factors, leading to increased vascular permeability and interstitial brain edema. It is postulated that autoimmune disorders can lead to PRES through a similar process of upregulation of cytokines and poorly controlled inflammatory state. PRES also occurs in patients taking immunosuppressive or cytotoxic drugs for malignancy or organ transplantation. Such medications can result in PRES immediately or several months after initiation of the drug, even when drugs are at therapeutic levels. This is thought to occur through dysregulation of vasoactive substrates such as tumor necrosis factor alpha and vascular endothelial growth factor. Probably least understood is the correlation between renal failure and the development of PRES (up to 55% of patients). Our patient's long-standing hypertension in the setting of ESRD predisposed him to the development of PRES.<sup>2</sup>

The treatment of PRES is challenging and multifaceted. Experts agree on the importance of blood pressure control, though no studies have been conducted to establish causation or to correlate blood pressure management with resolution of PRES.<sup>2</sup> Blood pressure reduction of 25% within the first few hours is recommended, but caution must be taken as the pressure is often labile. If PRES is attributed to a specific medication, the medication should be discontinued immediately. The risk and benefits of restarting the medication should be considered following the resolution of PRES.

The prognosis of PRES is typically good, with some sources citing 75-90% of patients making a full recovery with a mean time to recovery of 2-8 days. The most severe forms of PRES can result in death with a mortality range of 3-6% in 1-3 months.<sup>2,3</sup> Severe neurologic injury and death typically result from intracranial hemorrhage, posterior fossa edema with brainstem compression, or increased intracranial pressure resulting from diffuse cerebral edema.<sup>13,14</sup> In 10-20% of patients, long-term neurologic sequelae such as seizures, hemiparesis, decreased visual acuity, and residual dizziness have been noted.<sup>15,2,16</sup> PRES is recurrent in 5-10% of patients with uncontrolled HTN as compared to other causes of PRES.<sup>17</sup>

## CONCLUSION

Though uncommon, posterior reversible encephalopathy syndrome should be considered in patients with new onset visual loss, especially when accompanied by headaches and altered levels of consciousness. Due to significant overlap with

other neurologic disorders, PRES must be considered early and pursued with advanced radiographic imaging. Though often reversible, PRES can result in permanent brain injury and death if not recognized early and treated appropriately.

---

*Address for Correspondence:* Daniel Frick, DO, University of Louisville Hospital, 530 S. Jackson St., Louisville, KY 40202. Email: djfric01@louisville.edu.

*Conflicts of Interest:* By the *CPC-EM* article submission agreement, all authors are required to disclose all affiliations, funding sources and financial or management relationships that could be perceived as potential sources of bias. The authors disclosed none.

*Copyright:* © 2017 Frick et al. This is an open access article distributed in accordance with the terms of the Creative Commons Attribution ([CC BY 4.0](http://creativecommons.org/licenses/by/4.0/)) License. See: <http://creativecommons.org/licenses/by/4.0/>

---

## REFERENCES

- McKinney AM, Short J, Truwit CL, et al. Posterior reversible encephalopathy syndrome: incidence of atypical regions of involvement and imaging findings. *AJR Am J Roentgenol.* 2007;189(4):904-12.
- Fugate JE, Claassen DO, Cloft HJ, et al. Posterior reversible encephalopathy syndrome: associated clinical and radiologic findings. *Mayo Clin Proc.* 2010;85(5):427-32.
- Liman TG, Bohner G, Endres M, et al. Discharge status and in-hospital mortality in posterior reversible encephalopathy syndrome. *Acta Neurol Scand.* 2014;130(1):34-9.
- Ducros A, Bousser MG. Reversible cerebral vasoconstriction syndrome. *Pract Neurol.* 2009;9(5):256-67.
- Legriel S, Pico F, Azoulay E (n.d.). Understanding Posterior Reversible Encephalopathy Syndrome. In Vincent JL (Ed.), *Annual Update in Intensive Care and Emergency Medicine 2011.* 2011;631-53.
- Hinchey J, Chaves C, Appignani B, et al. A reversible posterior leukoencephalopathy syndrome. *N Engl J Med.* 1996;334(8):494-500.
- Bartynski WS, Boardman JF. Distinct imaging patterns and lesion distribution in posterior reversible encephalopathy syndrome. *AJNR Am J Neuroradiol.* 2007;28(7):1320-27.
- Mueller-Mang C, Mang T, Pirker A, et al. Posterior reversible encephalopathy syndrome: do predisposing risk factors make a difference in MRI appearance? *Neuroradiology.* 2009;51(6):373-83.
- Hedna VS, Stead LG, Bidari S, et al. Posterior reversible encephalopathy syndrome (PRES) and CT perfusion changes. *Int J Emerg Med.* 2012;5:12.
- Hedna VS, Shukla PP, Waters MF. Seizure mimicking stroke: role of CT perfusion. *J Clin Imaging Sci.* 2012;2:32.
- Feske SK. Posterior reversible encephalopathy syndrome: a review. *Semin Neurol.* 2011;31(2):202-15.
- Bartynski WS. Posterior reversible encephalopathy syndrome, part 1: fundamental imaging and clinical features. *AJNR Am J Neuroradiol.* 2008;29(6):1036-42.
- Grossbach AJ, Abel TJ, Hodis B, et al. Hypertensive posterior reversible encephalopathy syndrome causing posterior fossa edema and hydrocephalus. *J Clin Neurosci.* 2014;21(2):207-11.
- Lee SY, Dinesh SK, Thomas J. Hypertension-induced reversible posterior leukoencephalopathy syndrome causing obstructive hydrocephalus. *J Clin Neurosci.* 2008;15(4):457-9.
- Liman TG, Bohner G, Heuschmann PU, et al. The clinical and radiological spectrum of posterior reversible encephalopathy syndrome: the retrospective Berlin PRES study. *J Neurol.* 2012;259(1):155-64.
- Striano P, Striano S, Tortora F, et al. Clinical spectrum and critical care management of Posterior Reversible Encephalopathy Syndrome (PRES). *Med Sci Monit.* 2005;11(11):CR549-53.
- Li R, Mitchell P, Dowling R, et al. Is hypertension predictive of clinical recurrence in posterior reversible encephalopathy syndrome? *J Clin Neurosci.* 2013;20(2):248-52.



# Takotsubo Cardiomyopathy Presenting as Wellens' Syndrome

R. Scott Taylor, DO\*

Leif Skjerli, BS<sup>†</sup>

John Ashurst, DO, MSc\*

\*Duke LifePoint Conemaugh Memorial Medical Center, Department of Emergency Medicine, Johnstown, Pennsylvania

<sup>†</sup>Lake Erie College of Osteopathic Medicine, Erie, Pennsylvania

Section Editor: Rick A. McPheeters, DO

Submission history: Submitted September 2, 2016; Revision received January 13, 2017; Accepted January 23, 2017

Electronically published May 24, 2017

Full text available through open access at [http://escholarship.org/uc/uciem\\_cpem](http://escholarship.org/uc/uciem_cpem)

DOI: 10.5811/cpcem.2017.1.32297

Takotsubo cardiomyopathy, also known as apical ballooning syndrome and stress cardiomyopathy, is a transient systolic and diastolic left ventricular dysfunction with a variety of cardiac wall-motion abnormalities that is increasingly being associated with significant morbidity and mortality. Wellens' syndrome is an electrocardiographic (ECG) pattern in a pain-free patient that is indicative of critical occlusion of the left anterior descending coronary artery requiring immediate cardiac catheterization. The authors report a case of a patient presenting with ECG findings consistent with Wellens' syndrome that was later found to have Takotsubo cardiomyopathy with angiographically normal coronary arteries on cardiac catheterization after a seizure. [Clin Pract Cases Emerg Med. 2017;1(3):175–178.]

---

## INTRODUCTION

Electrocardiographic (ECG) recognition of ST-elevation myocardial infarction (STEMI) patterns decreases patient morbidity and mortality and is an essential skill for emergency physicians.<sup>1</sup> In addition, there has been increasing evidence, as well as social media blogs, stressing the importance of recognizing STEMI equivalent patterns on ECG. Wellens' syndrome is identified by a specific ECG pattern without complaint of chest pain and is typically indicative of critical occlusion of the left anterior descending coronary artery (LAD). Due to this, Wellens' syndrome is commonly referred to as a STEMI equivalent.<sup>2</sup> Alternatively, there are ECG findings that can appear to be a STEMI, but are rather STEMI mimics. One such instance is that of Takotsubo cardiomyopathy.<sup>2</sup> Takotsubo cardiomyopathy is commonly associated with elderly women experiencing an intense physical or emotional event. In this disease apical ballooning occurs, which causes ST segment changes on ECG consistent with STEMI. The authors report a case of a patient presenting with ECG findings consistent with Wellens' syndrome who was later found to have Takotsubo cardiomyopathy.

## CASE REPORT

A 65-year-old female with a history of a seizure disorder was brought to the emergency department (ED) by ambulance after experiencing three seizures earlier in the day. Emergency

medical services personnel were present for the third seizure and treated her with diazepam 5 mg intravenously prior to arrival to the hospital. Her family member stated that she had not taken any of her daily medications due to a two-day history of nausea, vomiting and diarrhea. On initial evaluation in the ED, the patient denied chest pain, dyspnea, or other complaints.

In addition to the seizure disorder, her medical history was significant for peripheral artery disease, obstructive sleep apnea, hypothyroidism, and migraines. Her home medications included clopidogrel, carbamazepine, lamotrigine, topiramate, and levothyroxine. She had denied current use of tobacco, alcohol, or illicit drugs.

Physical exam revealed that the patient had a fluctuating level of consciousness, consistent with a postictal state, but no lateralizing neurological deficits. Her vital signs were a temperature of 36.3 degrees Celsius, pulse of 118 beats per minute, respiratory rate of 20 breaths per minute, blood pressure of 146/69 mmHg, and an oxygen saturation of 96% on three liters of supplemental oxygen by nasal cannula. Her cardiovascular exam was only remarkable for a regular tachycardia. The remainder of the physical exam was unremarkable.

Chest radiograph and computed tomography of the head were unremarkable. An electrocardiogram upon arrival revealed sinus tachycardia with rate of 114 beats per minute with biphasic T-waves in leads V2-V4 with a noted 1 mm ST-elevation in V1 and a <1 mm ST-elevation in aVL (Image).

Remarkable labs included a white blood count of  $16 \times 10^3$  mm<sup>3</sup>, Troponin I of 2.42 ng/mL, CK-MB of 18.5 ng/mL, and a lactate of 3.0 mmol/L. Urinalysis was incidentally consistent with a urinary tract infection.

Interventional cardiology was consulted and it was determined that the patient would require urgent cardiac catheterization. In addition to her home dose clopidogrel, the patient was given aspirin 324 mg orally, metoprolol 5 mg IV and was given a weight-based dose of heparin. The patient was then taken for cardiac catheterization, which revealed angiographically normal coronary arteries, moderately impaired left ventricular function with ejection fraction (EF) of 35%, and wall-motion abnormalities of akinesis of the apical and apical septal wall, as well as severe hypokinesis of the anterolateral, diaphragmatic, and inferolateral wall. Interventional cardiology described the wall-motion abnormalities as being consistent with Takotsubo cardiomyopathy. Post-cardiac catheterization echocardiography revealed an EF of 30-35%, apical akinesis, severe hypokinesis of distal anteroseptal, anterior, lateral, and inferior walls, with compensatory basal hyperkinesis. She was started on a beta-blocker as well as an ACE inhibitor with recommended follow-up echocardiogram in three months to evaluate for improvement.

## DISCUSSION

Takotsubo cardiomyopathy, also known as apical ballooning syndrome or stress cardiomyopathy, is an acute-onset regional

### CPC-EM Capsule

What do we already know about this clinical entity?

*Wellens' syndrome is a STEMI equivalent that requires prompt interventional cardiology consultation. However, it is rarely associated with Takotsubo cardiomyopathy.*

What makes this presentation of disease reportable?

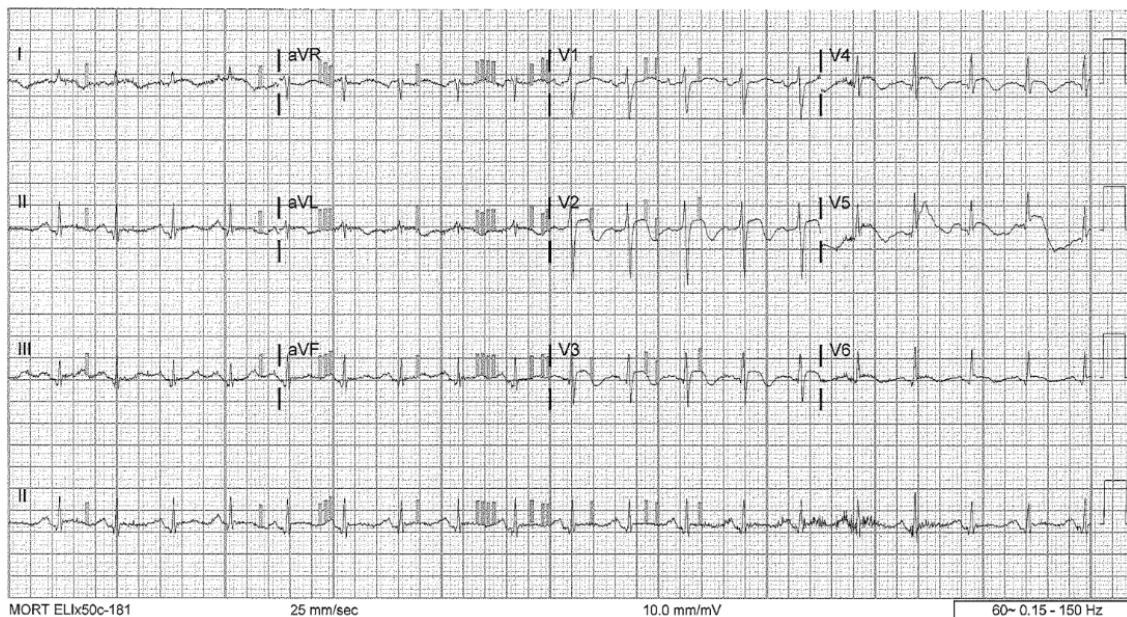*Although both Wellens' syndrome and Takotsubo cardiomyopathy have been reported in the literature, rarely are they seen in the same patient encounter.*

What is the major learning point?

*The emergency physician should keep a broad differential when faced with either a STEMI mimic or an equivalent.*

How might this improve emergency medicine practice?

*As more cases are reported, further studies may show an association between STEMI mimics and STEMI equivalents.*



**Image.** Electrocardiogram depicting Wellens' syndrome.

**Table.** Diagnostic criteria for the diagnosis of Takotsubo cardiomyopathy.<sup>5</sup>

1. Transient hypokinesis, akinesis, or dyskinesis of the left ventricular mid segments with or without apical involvement; the regional wall motion abnormalities extend beyond a single epicardial vascular distribution; a stressful trigger is often, but not always, present.
2. Absence of obstructive coronary disease or angiographic evidence of acute plaque rupture.
3. New ECG abnormalities (either ST-segment elevation and/or T-wave inversion) or modest elevation in cardiac troponin.
4. Absence of pheochromocytoma or myocarditis.

ECG, electrocardiogram

left ventricular dysfunction that is associated with chest pain and heart failure. It is becoming an increasingly recognized heart disease, affecting 5.2/100,000 women and 0.6/100,000 men in the United States.<sup>3</sup> The disease occurs most frequently in women greater than 55 years, although all ages and both sexes can be affected.<sup>3</sup> Although it is commonly preceded by an intense physical or emotional triggering event, such events are not identified in approximately one third of patients.<sup>4,5</sup> Affected patients typically present with chest pain, dyspnea, and transient ST-segment elevation, which mirrors the presentation of an acute myocardial infarction (MI).<sup>4,6,7</sup> Troponin I levels are usually elevated in this disease, but to a lesser extent than in a MI (1.8x vs 6x).<sup>4</sup> Diagnostic criteria were first proposed by the Mayo Clinic, and subsequently modified by Prasad et al. in 2008 (Table).<sup>5</sup>

As Takotsubo cardiomyopathy presents similarly to acute coronary artery occlusion, it is usually diagnosed by cardiac catheterization that shows normal coronary arteries and wall-motion abnormalities.<sup>6</sup> The cardiomyopathy is usually self-limited, and with supportive treatment, rapid return to normal cardiac function can be expected.<sup>8</sup> Although self-limiting, it is associated with ventricular tachycardia, ventricular thrombus, and ventricular rupture, which may increase the diseases morbidity and mortality.<sup>6</sup>

In our case, the patient presented with an ECG and clinical findings consistent with Wellen's syndrome but was found to have Takotsubo cardiomyopathy on cardiac catheterization. It is unusual for a STEMI mimic to manifest as a STEMI-equivalent finding on ECG. This case highlights the importance of considering a broader differential diagnosis when confronted with ECG findings suspected to be STEMI equivalents. However, there will still be a need for invasive cardiac testing in consultation with cardiology to rule out MI.

Interestingly, it was also hypothesized that the patient's triggering event may have been caused by seizure activity. In 2011, Stöllberger et al. reported several cases of Takotsubo cardiomyopathy triggered by seizure activity.<sup>12</sup> None of these cases were reported, or suspected, to have a Wellen's syndrome. Most of the patients in the case-series experience did, however, experience chest pain and/or hemodynamic deterioration, which was not present in our case. Wellen's syndrome is typically not preceded by seizure activity as the underlying etiology is a coronary lesion. No association of Wellen's syndrome with seizure activity could be found.

## CONCLUSION

Wellen's syndrome, originally described in 1982, is a characteristic ECG finding that signifies critical LAD stenosis; however, the patient is usually pain-free at the point the ECG is obtained.<sup>9,10</sup> It is important to recognize this syndrome to ensure timely transfer to the cardiac catheterization suite, as well as to avoid any testing that could induce MI, especially provocative stress imaging.<sup>11</sup> There are two types of ECG findings associated with this syndrome. Type A (25% of cases) is identified by biphasic T-waves in V2-3, while type B's findings are deeply inverted T-waves in V2-3.<sup>11</sup>

*Address for Correspondence:* John Ashurst DO, MSc, Duke LifePoint Conemaugh Memorial Medical Center, 1086 Franklin Street, Johnstown, Pa 15905. Email: Ashurst.john.32.research@gmail.com.

*Conflicts of Interest:* By the CPC-EM article submission agreement, all authors are required to disclose all affiliations, funding sources and financial or management relationships that could be perceived as potential sources of bias. The authors disclosed none.

*Copyright:* © 2017 Ashurst et al. This is an open access article distributed in accordance with the terms of the Creative Commons Attribution (CC BY 4.0) License. See: <http://creativecommons.org/licenses/by/4.0/>

## REFERENCES

1. Fesmire FM, Brady WJ, Hahn S, et al. Clinical policy: indications for reperfusion therapy in emergency department patients with suspected acute myocardial infarction. American College of Emergency Physicians Clinical Policies Subcommittee (Writing Committee) on Reperfusion Therapy in Emergency Department Patients with Suspected Acute Myocardial Infarction. *Ann Emerg Med.* 2006;48(4):358-83.
2. Shams M, Sullivan A, Abudureyimu S, et al. Optimizing electrocardiogram interpretation and catheterization laboratory



- activation in ST-segment elevation myocardial infarction: A teaching module for medical students. *J Am Coll Cardiol*. 2016;67(13\_S):643.
3. Deshmukh A, Kumar G, Pant S, et al. Prevalence of Takotsubo cardiomyopathy in the United States. *Am Heart J*. 2012;164(1):66-71.e1.
  4. Templin C, Ghadri JR, Napp LC. Takotsubo (stress) cardiomyopathy. *N Engl J Med*. 2015;373(27):2689-91.
  5. Prasad A, Lerman A, Rihal CS. Apical ballooning syndrome (Takotsubo or stress cardiomyopathy): a mimic of acute myocardial infarction. *Am Heart J*. 2008;155(3):408-17.
  6. Sharkey SW. Takotsubo cardiomyopathy: natural history. *Heart Fail Clin*. 2013;9(2):123-36.
  7. Thygesen K, Alpert JS, Jaffe AS, et al. Third universal definition of myocardial infarction. *Circulation*. 2012;126(16):2020-35.
  8. Akashi YJ, Goldstein DS, Barbaro G, et al. Takotsubo cardiomyopathy: a new form of acute, reversible heart failure. *Circulation*. 2008;118(25):2754-62.
  9. de Zwaan C, Bär FW, Wellens HJ. Characteristic electrocardiographic pattern indicating a critical stenosis high in left anterior descending coronary artery in patients admitted because of impending myocardial infarction. *Am Heart J*. 1982;103(4 Pt 2):730-6.
  10. de Zwaan C, Bär FW, Janssen JH, et al. Angiographic and clinical characteristics of patients with unstable angina showing an ECG pattern indicating critical narrowing of the proximal LAD coronary artery. *Am Heart J*. 1989;117(3):657-65.
  11. Rhinehardt J, Brady WJ, Perron AD, et al. Electrocardiographic manifestations of Wellens' syndrome. *Am J Emerg Med*. 2002;20(7):638-43.
  12. Stöllberger C, Wegner C, Finsterer J. Seizure-associated Takotsubo cardiomyopathy. *Epilepsia*. 2011;52(11):e160-7.

# Acute Myocardial Infarction with Simultaneous Gastric Perforation

Alon Kaplan, BS\*  
Dan Schwarzfuchs, MD\*  
Vladimir Zeldetz, MD\*  
Jing Liu, MD†

\* Ben Gurion University of the Negev, Soroka University Medical Center, Department of Emergency Medicine, Beer Sheva, Israel

† Kern Medical, Department of Emergency Medicine, Bakersfield, CA

Section Editor: Rick A. McPheeters, DO

Submission history: Submitted December 24, 2016; Revision received February 8, 2017; Accepted February 8, 2017.

Electronically published May 9, 2017

Full text available through open access at [http://escholarship.org/uc/uciem\\_cpem](http://escholarship.org/uc/uciem_cpem)

DOI: 10.5811/cpcem.2017.2.33433

Acute myocardial infarction and perforated peptic ulcer disease with associated peritonitis are both medical emergencies requiring urgent intervention. This patient presented with both emergencies simultaneously. Current literature is devoid of guidance as to which should be addressed initially. A multidisciplinary discussion was conducted leading to a unanimous decision for initiating percutaneous coronary intervention (PCI). After successful PCI, the patient was immediately taken to the operating room for laparoscopic repair of the perforated viscous. Subsequent to the operative repair, the patient became hemodynamically unstable and a repeat electrocardiogram demonstrated complete right coronary occlusion. Shock ensued and the patient died in the intensive care unit despite this plan of care. It is our opinion that this case reveals the need for expert panels to devise decision algorithms for concomitant presentations of life-threatening diseases. [Clin Pract Cases Emerg Med. 2017;1(3):179–182.]

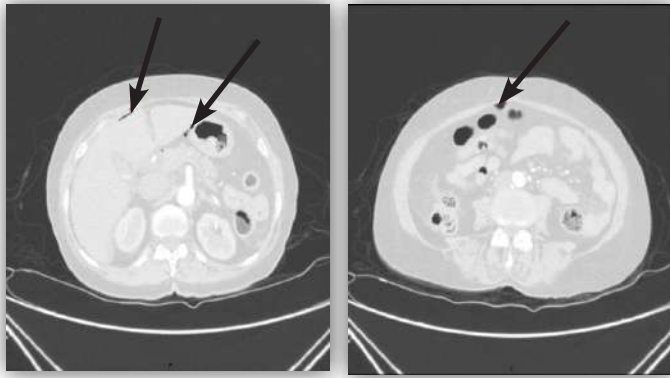
## INTRODUCTION

Acute myocardial infarction with ST-segment elevation is a medical emergency. A preponderance of literature supports that rapid treatment with cardiac catheterization within 90 minutes is associated with lower rates of in-hospital mortality.<sup>1</sup> This rapid “door-to-balloon” time is also associated with decreased mortality rates at 30 days as well as one year, and has become the standard of care in many healthcare settings.<sup>2,3</sup> Peptic ulcer perforation is a fatal complication of peptic ulcer disease, which occurs in 1.5-7.8 out of 100,000 people per year based on a study conducted among the Swedish population.<sup>4</sup> The mortality rate associated with peptic ulcer perforation is approximately 10%,<sup>4</sup> and delayed treatment of peptic ulcer perforation (more than 24 hours between symptom onset and hospital admission) has been established as an independent predictor of 30-day mortality by the peptic ulcer perforation (PULP) score.<sup>5</sup> When both of these time-sensitive medical emergencies present concomitantly, even experienced physicians may find difficulty in deciding which pathologic process to address first.

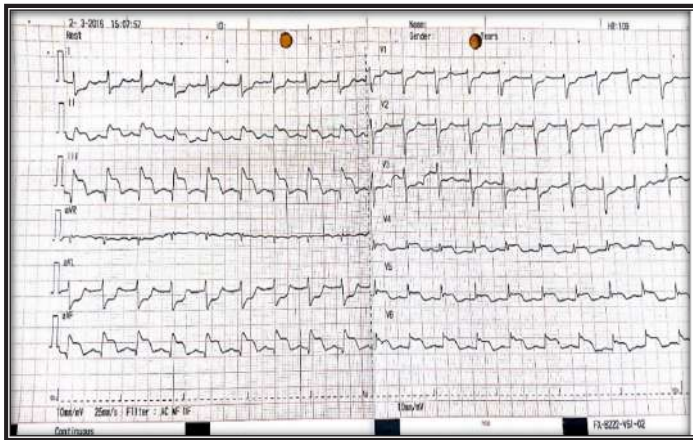
## CASE REPORT

A 66-year-old Bedouin woman with a past medical history of uncontrolled type 2 diabetes mellitus, dyslipidemia and hypertension presented to the emergency department (ED) with a chief complaint of abdominal pain for two days. She described the pain as sharp, constant, and located in the epigastric area radiating to her back. It was associated with nausea and vomiting. She denied any history of nonsteroidal anti-inflammatory drug or other analgesic use and had no known history of coronary artery disease or prior surgeries.

On presentation the patient appeared stable with normal vital signs. The physical exam was remarkable for a rigid abdomen with diffuse abdominal tenderness. An immediate acute abdominal series was non-diagnostic without evidence of pneumoperitoneum. Analysis of venous blood revealed significant metabolic acidosis (pH 7.29, HCO<sub>3</sub><sup>-</sup> 15.6 mmol/L, pCO<sub>2</sub> 26.2 mmHg, lactate 4 mmol/L). Computed tomography (CT) of the abdomen and pelvis was subsequently performed, which demonstrated free intraperitoneal air suggestive of a perforated viscous (Image 1). After the CT, the patient began to experience new-onset



**Image 1.** Computed tomography scan showing free air in the abdominal cavity.



**Image 2.** Electrocardiogram shows ST elevations in the inferior and lateral walls.

chest pain. An electrocardiogram (ECG) was obtained showing ST-segment elevation in the inferior leads II, III and AvF (Image 2).

Given the concomitant presentation of two emergent pathologies, a multidisciplinary discussion was conducted between the emergency physician, cardiologist and general surgeon to determine the proper course of treatment. They unanimously agreed that cardiac catheterization and percutaneous coronary intervention (PCI) would take precedence over laparoscopic surgical repair of the patient's perforated viscus. This decision was based on the clinical judgment that an acute STEMI was the more immediate threat to life compared to perforated viscus without evidence of active exsanguination. Consideration was also given to the rapid nature of PCI compared to laparoscopic surgery.

The patient received 80mg pantoprazole intravenously (IV) as a temporizing measure for suspected gastric perforation and was rushed to the catheterization laboratory.

### *CPC-EM Capsule*

What do we already know about this clinical entity?

*There is limited literature regarding the treatment of these two diseases occurring simultaneously and there are no guidelines regarding management of such complex patients.*

What makes this presentation of disease reportable?

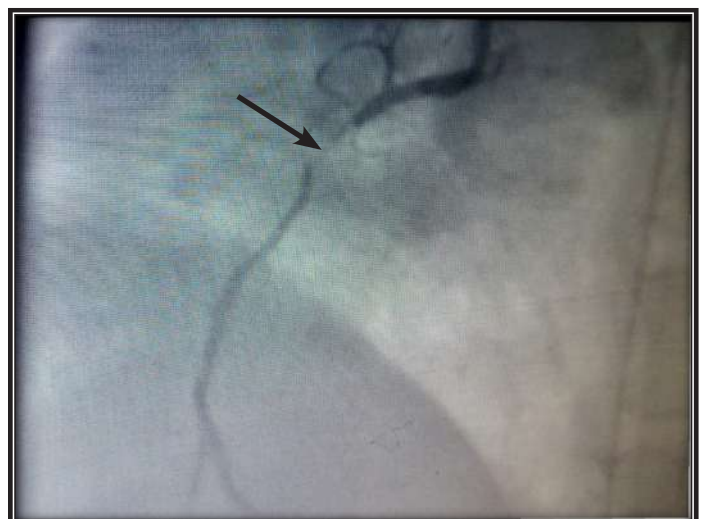
*Concomitant acute myocardial infarction and gastric ulcer perforation constitute a challenge both diagnostic and therapeutic leading to increased morbidity and mortality even with prompt diagnosis and treatment.*

What is the major learning point?

*In unstable patients, the emergency physician should consider another life-threatening diagnosis even in the presence of an ST elevation myocardial infarction.*

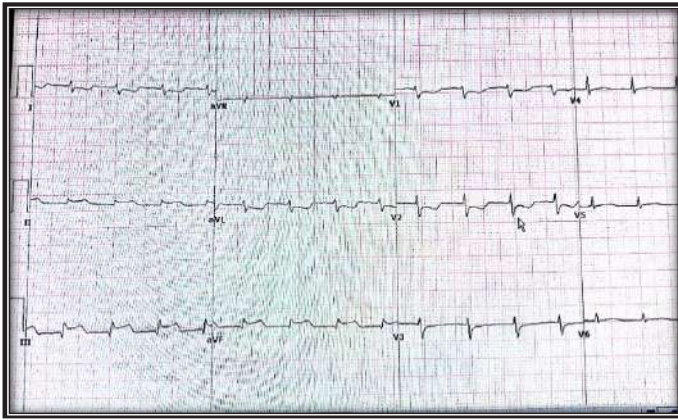
How might this improve emergency medicine practice?

*By maintaining a high index of suspicion for concomitant disease processes, future case reports may provide more clarity on how to approach this complex clinical scenario.*



**Image 3.** Percutaneous coronary intervention shows an occlusion in the right coronary artery.





**Image 4.** Electrocardiogram shows ST elevation in the inferior wall.

Prior to PCI she received 3000 units of heparin IV, 300mg of aspirin orally (PO) and 600mg of clopidogrel PO. Catheterization demonstrated significant coronary artery disease. The proximal right coronary artery (with right dominant anatomy) had near total occlusion of the artery (99%), consistent with thrombolysis in myocardial infarction (TIMI) grade 1 flow. Presence of a large coronary thrombus was seen, with minimal antegrade flow beyond the occlusion (Image 3). PCI with a bare metal stent (BMS) insertion was then performed successfully.

The patient was then transferred directly to the operating room (OR) in hemodynamically stable condition. She was sedated and intubated and laparoscopic surgery was initiated. A 2mm perforation was visualized in the prepyloric gastric antrum. The defect was repaired and an omental patch was placed. Operative time was less than 20 minutes. After the operative repair but while still in the OR, the patient became hemodynamically unstable with systolic blood pressure measuring 40mmHg. IV vasopressors were initiated and the patient was transferred to the ICU on a ventilator. She remained hemodynamically unstable 12 hours postoperatively despite resuscitative measures and maximal vasopressor support.

A repeat ECG was obtained, which again showed ST-segment elevation (Image 4). The patient was then taken for a second cardiac catheterization, which revealed a total occlusion of the right coronary artery due to early subacute stent thrombosis. The thrombus was partially evacuated but could not be completely removed. An additional BMS was inserted and the patient was transferred to the intensive coronary care unit where she continued to be hemodynamically unstable. The patient subsequently passed away an hour later.

## DISCUSSION

Acute MI occurring simultaneously with gastric ulcer perforation is an uncommon scenario that can have fatal consequences. Even with prompt diagnosis and treatment,

complications arising from these two disease processes are associated with increased morbidity and mortality.<sup>1-3,5,6</sup> There is limited literature regarding the treatment of these two diseases occurring simultaneously, and available literature consists mainly of case reports. Currently, there are no guidelines regarding management of such complex patients. Differentiating between STEMI and perforated viscus can also be quite challenging. While STEMI can manifest clinically with epigastric complaints, perforated viscus can also be accompanied by ischemic changes on ECG including ST-segment elevation.<sup>7</sup> A similar case was described in 1967, and the authors suggested that the association may be more common than previously thought. Without a high suspicion for cardiac pathology, these cases may easily be misdiagnosed as the result of peptic ulcer perforation alone.<sup>8</sup> Another report regarding concomitant perforation and acute MI suggested performing surgical treatment first; however, they do not cite any literature supporting this decision.<sup>9</sup>

A decision analysis in patients with acute MI and upper gastrointestinal (GI) bleeding has been proposed, resulting in esophagogastroduodenoscopy (EGD) prior to PCI as a strategy with better outcomes, but the distinction between non-STEMI and STEMI was not made in this study.<sup>10</sup> In a case of a patient with upper GI bleeding and acute MI, it is reasonable to perform EGD prior to PCI since the anticoagulation necessary to perform PCI has the potential to worsen GI bleeding. While this may be a reasonable approach, it is important to keep in mind that MI has higher rates of 30-day mortality as well as higher rates of in-hospital mortality.<sup>11</sup> It is also important to recognize upper GI bleeding and perforated gastric ulcers as distinct entities with differing prognosis and treatment. For example, it has been shown that ulcer perforation has higher mortality rates compared to upper GI bleeding especially in the elderly population.<sup>12</sup>

While there is lack of data regarding whether surgical repair of a perforated gastric ulcer or PCI for STEMI should come first,<sup>1</sup> there is comprehensive data supporting the superior outcomes of early revascularization for STEMI. Based on this, it is our opinion that PCI should be performed prior to surgical repair in patients presenting with simultaneous disease processes. Due to the rarity of this scenario, as well as ethical concerns, there is no option for a randomized clinical trial to compare the two approaches. By maintaining a high index of suspicion for concomitant disease processes, future case reports may provide more clarity on how to approach this scenario.

## CONCLUSION

The presence of two life-threatening diagnoses occurring simultaneously in a patient is rare but not unheard of. Recognizing the concomitant disease processes is crucial, but determining the most effective sequence of treatment is not always readily apparent. The establishment of a clear algorithm may facilitate the treatment of such patients,



such as those who suffer from acute myocardial infarction complicated by another medical emergency. We therefore suggest that an expert panel use available literature and expert opinion to devise a decision algorithm for future cases in order to provide optimal treatment for these complex cases.

---

*Address for Correspondence:* Kaplan, BS, Ben Gurion University of the Negev, P.O Box 151, Beer-Sheva 84101, Israel. Email: alonkaplan47@gmail.com.

*Conflicts of Interest:* By the CPC-EM article submission agreement, all authors are required to disclose all affiliations, funding sources and financial or management relationships that could be perceived as potential sources of bias. The authors disclosed none.

*Copyright:* © 2017 Kaplan et al. This is an open access article distributed in accordance with the terms of the Creative Commons Attribution (CC BY 4.0) License. See: <http://creativecommons.org/licenses/by/4.0/>

---

## REFERENCES

1. Rathore SS, Curtis JP, Chen J, et al. Association of door-to-balloon time and mortality in patients admitted to hospital with ST elevation myocardial infarction: national cohort study. *BMJ*. 2009;338:b1807.
2. De Luca G, Suryapranata H, Ottervanger JP, et al. Time delay to treatment and mortality in primary angioplasty for acute myocardial infarction: every minute of delay counts. *Circulation*. 2004;109(10):1223-5.
3. Berger PB, Ellis SG, Holmes DR Jr, et al. Relationship between delay in performing direct coronary angioplasty and early clinical outcome in patients with acute myocardial infarction: results from the global use of strategies to open occluded arteries in Acute Coronary Syndromes (GUSTO-IIb) trial. *Circulation*. 1999;100(1):14-20.
4. Hermansson M, Ekedahl A, Ranstam J, et al. Decreasing incidence of peptic ulcer complications after the introduction of the proton pump inhibitors, a study of the Swedish population from 1974-2002. *BMC Gastroenterol*. 2009;9(1):25.
5. Møller MH, Engebjerg MC, Adamsen S, et al. The Peptic Ulcer Perforation (PULP) score: a predictor of mortality following peptic ulcer perforation. A cohort study. *Acta Anaesthesiol Scand*. 2012;56(5):655-62.
6. Hermansson M, Staël von Holstein C, Zilling T. Surgical approach and prognostic factors after peptic ulcer perforation. *Eur J Surg*. 1999;165(6):566-72.
7. Murphy FD, Livezey MM. Electrocardiographic changes simulating those of acute myocardial infarction in a case of perforated gastric ulcer. *Am Heart J*. 1944;28(4):533-7.
8. Cassell P, Nicholson R. Perforation of peptic ulcer complicating myocardial infarction. *Br Heart J*. 1967;29(1):129-31.
9. Kürkciyan I, Schirmaier E, Frossard M, et al. [Concomitant perforated ulcer and acute myocardial infarction--a diagnostic challenge in emergency medicine]. *Wien Klin Wochenschr*. 1994;106(20):660-3.
10. Yachimski P, Hur C. Upper endoscopy in patients with acute myocardial infarction and upper gastrointestinal bleeding: results of a decision analysis. *Dig Dis Sci*. 2009;54(4):701-11.
11. Wilcox CM, Cryer BL, Henk HJ, et al. Mortality associated with gastrointestinal bleeding events: Comparing short-term clinical outcomes of patients hospitalized for upper GI bleeding and acute myocardial infarction in a US managed care setting. *Clin Exp Gastroenterol*. 2009;2:21-30.
12. Christensen S, Riis A, Nørgaard M, et al. Short-term mortality after perforated or bleeding peptic ulcer among elderly patients: a population-based cohort study. *BMC Geriatr*. 2007;7:8.

# Occult Iliac Deep Vein Thrombosis in Second Trimester Pregnancy: Clues on Bedside Ultrasound

Roopa Avula, BA\*  
Michael Niemann, BA, BS\*  
Nicole Dorinzi, MD†  
Kristine Robinson, MD†  
Melinda Sharon, MPH†  
Joseph Minardi, MD†

\*West Virginia University School of Medicine, Morgantown, West Virginia  
†West Virginia University, Department of Emergency Medicine, Morgantown, West Virginia

Section Editor: Shadi Lahham MD, MS

Submission history: Submitted January 9, 2017; Revision received January 24, 2017; Accepted January 24, 2017

Electronically published May 9, 2017

Full text available through open access at [http://escholarship.org/uc/uciem\\_cpccem](http://escholarship.org/uc/uciem_cpccem)

DOI: 10.5811/cpccem.2017.1.33536

Isolated pelvic deep vein thromboses (DVT) are rare and difficult to diagnose, but they are more common in pregnant women and carry an increased risk of embolization. Pulmonary embolism is the most common non-obstetric cause of death in pregnancy. Compression ultrasound is the first-line imaging test for suspected lower extremity DVT, but it cannot usually aid in directly visualizing or easily diagnosing isolated pelvic DVT. Nonetheless, point-of-care ultrasound (POCUS) may provide valuable clues to help rule in pelvic DVT and expedite initiation of anticoagulant therapy. Such findings include increased venous diameter, increased resistance to compression, visible venous reflux, and blunted phasicity. This case presents an example of how these findings on POCUS led the emergency physician to make the difficult diagnosis of pelvic DVT at the bedside within seconds. [Clin Pract Cases Emerg Med. 2017;1(3):183–186.]

---

## INTRODUCTION

Leg pain and swelling are common in pregnancy, which is a risk factor for deep vein thrombosis (DVT).<sup>1</sup> Isolated pelvic DVT, though uncommon, occurs more often during pregnancy.<sup>2,3</sup> Typically, compression ultrasound is first-line imaging for suspected lower extremity DVT, but it may not as easily identify isolated pelvic DVT unless a more comprehensive sonographic approach and technique is used.<sup>4</sup>

Pulmonary embolism (PE) is the most common non-obstetric cause of death in pregnant women.<sup>3,5</sup> Proximal DVT has a higher likelihood of embolization and mortality than calf DVT; thus, early detection is essential.<sup>6,7</sup>

Point-of-care ultrasound (POCUS) for DVT is accurate and widely employed by emergency physicians.<sup>8,9</sup> Typical findings include visualization of thrombus and lack of venous compressibility. For pelvic DVT, findings may not be as clear, but subtle clues may suggest the diagnosis.

We present a case of occult iliac DVT in which lower extremity veins were compressible, but other sonographic clues led to the rapid, accurate diagnosis immediately at the bedside. To our knowledge, this is the first report to describe the detailed POCUS findings that led to this uncommon diagnosis.

## CASE REPORT

A 26-year-old pregnant woman at 23 weeks gestation presented with three days of atraumatic left calf pain. Physical examination revealed circumferential swelling, tenderness, and mild redness to the left calf. Clinical likelihood of DVT was felt to be high and DVT POCUS was performed immediately.

Venous compression was performed including views of the proximal zone from the saphenofemoral junction to the common and deep femoral junctions, as well as the popliteal zone to the trifurcation. The deep veins were compressible in all zones but appeared distended and required higher than expected pressure to compress (Images 1A, 1B, 2A, and 2B; Supplemental video). These findings prompted comparison views and additional investigation with pulsed-wave spectral Doppler, revealing normal augmentation but blunted phasicity (Images 1C and 1D; Supplemental video). Deep veins of the unaffected leg were smaller in diameter and compressed more easily (Images 1A, 1B, 2A, and 2B; Supplemental video). These findings suggested a proximal venous thrombus on the left, and anticoagulation was initiated.

A magnetic resonance venogram (MRV) of the pelvis

was performed, confirming a near-occlusive thrombus in the left common iliac vein with extension into the external iliac vein, suggestive of May-Thurner syndrome, an anatomical variant where the left iliac vein is compressed by the right iliac artery (Images 2C and 2D).<sup>10</sup> POCUS findings were referenced by radiology.

The patient was admitted, continued therapy and her course was otherwise uneventful.

## DISCUSSION

DVT is a common consideration for emergency physicians treating pregnant patients with lower extremity symptoms. In pregnant women, proximal DVT is more likely (62%) than calf DVT (6%) compared to the non-pregnant population where 80% of DVTs occur in the calf.<sup>11</sup> The likelihood of fatal PE is considerably higher when proximal DVT is the source.<sup>6</sup>

Ultrasound for lower extremity DVT is generally accurate; however, its accuracy in cases of isolated pelvic DVT is not well established. In this case, although a clot was not directly visualized, there were clues on POCUS that suggested the diagnosis. These findings included the following:

1. Venous distention (increased diameter and difficulty in compression, specifically compared to the unaffected side)
2. Blunted phasicity (again, specifically compared to the unaffected side)
3. Visible venous reflux.

There is variability in the emergency medicine literature regarding the exact technique of DVT POCUS. We endorse a more comprehensive exam such as that described in this patient. Lack of compressibility suggests DVT, even if a clot is not directly visualized. The Doppler techniques commonly employed include these two:

1. Augmentation – the Doppler gate is placed within the vein of interest; the vein is squeezed distally to assess for a rapid increase in venous velocity, which suggests distal patency.
2. Phasicity – the Doppler gate is placed within the vein of interest and variation during respiration is observed. Blunted phasicity suggests proximal occlusion.

It should be noted that any patient with a high clinical likelihood of DVT and a negative ultrasound should undergo further diagnostic testing, such as computed tomography or MRV. As seen in this case, suggestive findings on POCUS may be adequate to initiate therapy until definitive imaging is obtained.

## CONCLUSION

Current literature endorses a two-point focused lower extremity compression examination for DVT,

### *CPC-EM Capsule*

What do we already know about this clinical entity?

*POCUS is commonly used by EPs to evaluate for lower extremity DVT. Isolated pelvic DVT is more difficult to identify, but carries a higher risk of embolization.*

What makes this presentation of disease reportable?

*This report details POCUS findings that may suggest the difficult diagnosis of isolated pelvic DVT.*

What is the major learning point?

*Increased venous diameter, difficulty in compression, and blunted phasicity may suggest pelvic DVT. Comparison to the unaffected extremity is useful.*

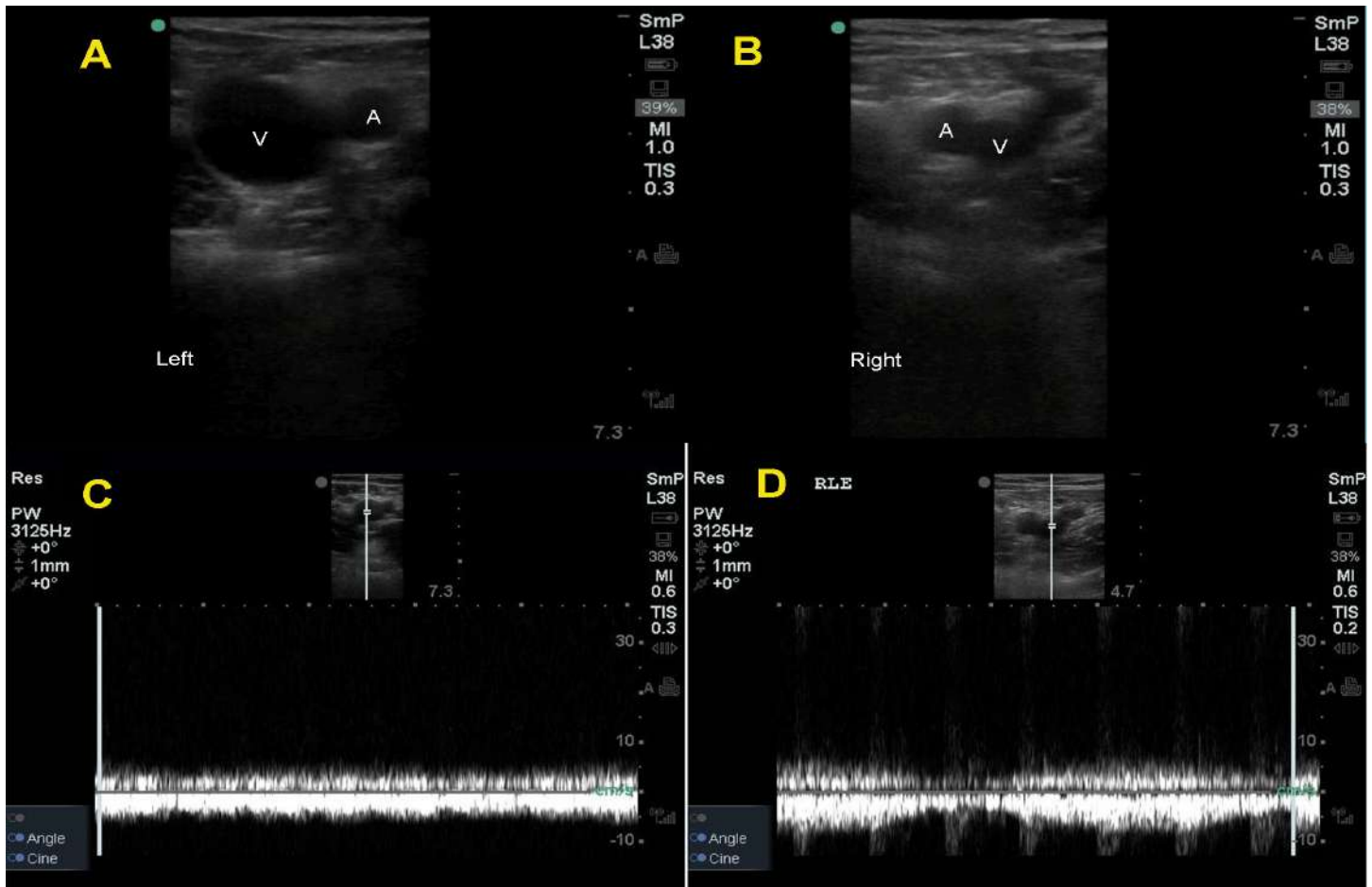
How might this improve emergency medicine practice?

*Recognition of these findings may suggest an otherwise difficult diagnosis and expedite treatment decisions.*

but we endorse a more comprehensive exam.<sup>8</sup> Pelvic DVTs are rarely identified in the emergency department (ED), and knowledge and attention to these techniques can help expedite diagnosis and management of this dangerous condition. A search of the literature identified only one other case of this diagnosis being made with POCUS in the ED, and the detailed findings were not as thoroughly described.<sup>12</sup> Our case illustrates use of a more comprehensive approach and suggestions for technique in using POCUS to diagnose pelvic DVT in the emergency setting. We present a case of a young woman in her second trimester of pregnancy with unilateral leg pain and swelling. Though lower extremity veins were compressible, careful attention to subtle clues on DVT POCUS led to the rare and difficult diagnosis of iliac DVT.

Our case demonstrates important teaching points that the use of POCUS in the ED to diagnose isolated pelvic DVT requires a more comprehensive approach and attention to technique that are not widely described in the current literature. The primary teaching points for any questionable cases are as follows:





**Image 1A, B.** Distended femoral vein. Note the increased diameter of the distended femoral vein (V) in panel A. Compare this to the image from the unaffected side in panel B, where the femoral vein (V) has a much smaller (normal) diameter.

(A - artery; V - vein)

**Image 1C, D.** Loss of phasicity. Note the flattened waveform in the spectral Doppler tracing in panel C, which represents a loss of normal variation during respiration known as phasicity. Compare this with panel D, which shows gradual changes in velocity of the spectral Doppler waveform corresponding to passive respiration, suggesting patency of the proximal vein. Panel D shows normal phasicity.

- Perform comparison views to the unaffected extremity
  - Assess for venous distention and compressibility
  - Assess for reflux and phasicity
- The findings that may suggest pelvic DVT include these:
- Increased venous diameter
  - Resistance to compression
  - Venous reflux
  - Blunted phasicity.

Further, we recommend routinely performing a more detailed DVT POCUS exam as described above in all patients suspected to have a lower extremity DVT.

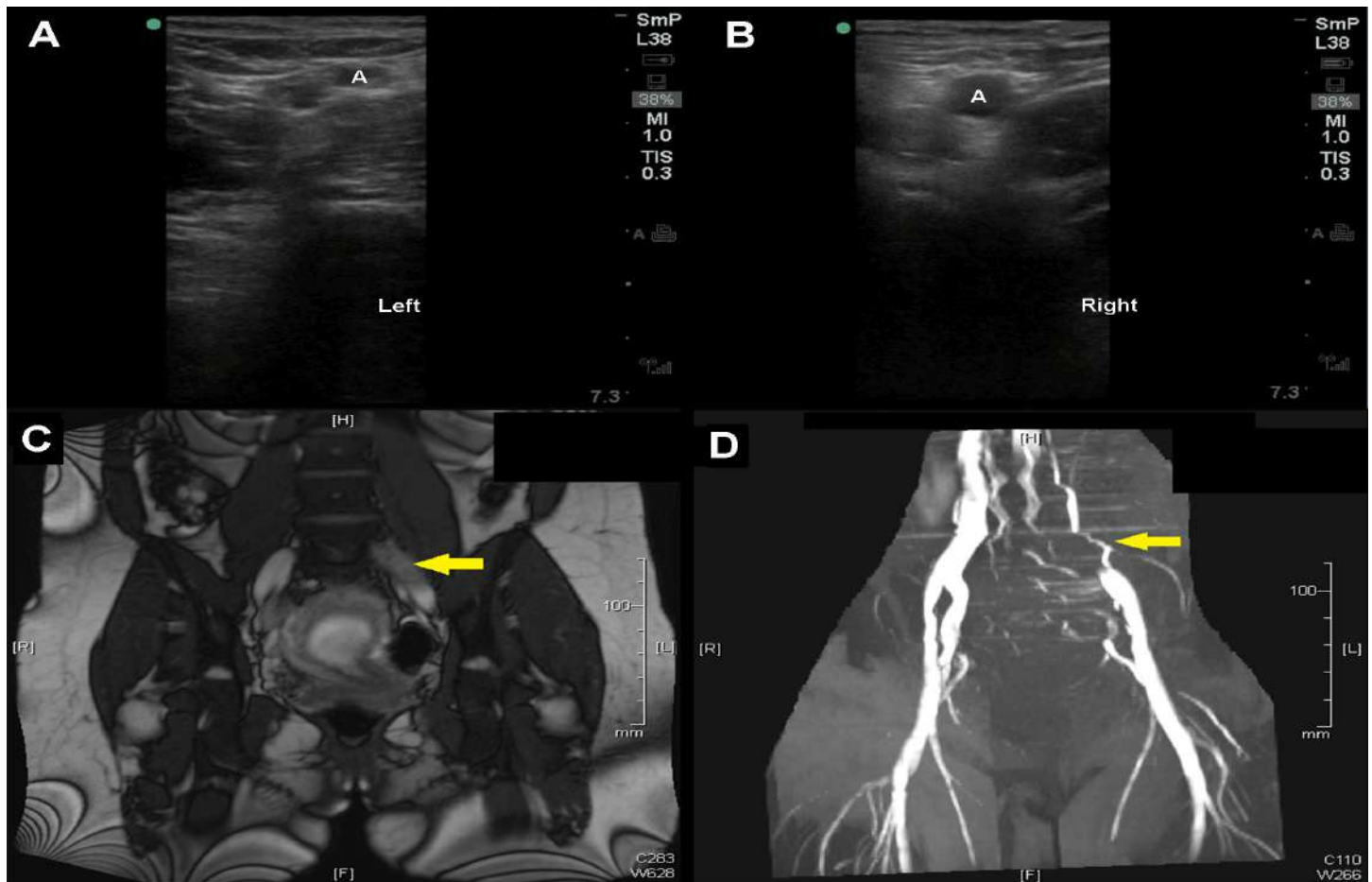
This case demonstrates the utility of a comprehensive approach and specific details on technique for POCUS in making rapid, accurate diagnoses. Recognition of subtle findings as described here can lead to the uncommon but potentially life-saving diagnosis of isolated pelvic DVT in the ED setting.

**Supplemental Video.** Iliac DVT Findings. In this narrated video, the findings that led to the diagnosis of iliac DVT are demonstrated. Findings include increased venous diameter, difficulty in compression, and loss of phasicity.

*Address for Correspondence:* Roopa Avula, BA, West Virginia University School of Medicine, 7413B HSS, 1 Medical Center Dr., Morgantown, WV 26506. Email: roavula@mix.wvu.edu.

*Conflicts of Interest:* By the CPC-EM article submission agreement, all authors are required to disclose all affiliations, funding sources and financial or management relationships that could be perceived as potential sources of bias. The authors disclosed none.

*Copyright:* © 2017 Avula et al. This is an open access article distributed in accordance with the terms of the Creative Commons Attribution (CC BY 4.0) License. See: <http://creativecommons.org/licenses/by/4.0/>



**Image 2A, B.** Difficulty in compression. In panel A, venous compression is only achieved with high pressure, as noted by the compressed artery (A). Compare this to panel B, where the vein is completely compressed while the artery (A) is able to maintain a normal diameter.

**Image 2C, D.** Common iliac thrombosis on magnetic resonance: venogram. In panel C, a thrombus is seen as a hypointense signal in the left common iliac vein (arrow). This finding, along with evidence of occlusion, is also evident in panel D (arrow).

## REFERENCES

- Parunov LA, Soshitova NP, Ovanesov MV, et al. Epidemiology of venous thromboembolism (VTE) associated with pregnancy. *Birth Defects Res C Embryo Today*. 2015;105(3):167-84.
- Springel E, Malhotra A. Thromboembolism in pregnancy: Practice essentials, background, pathophysiology. Medscape. Available at: <http://emedicine.medscape.com/article/2056380-overview>. Accessed September 12, 2016.
- Simcox LE, Ormesher L, Tower C, et al. Pulmonary thromboembolism in pregnancy: Diagnosis and management. *Breastfeed (Sheff)*. 2015;11(4):282-9.
- Spritzer CE, Arata MA, Freed KS. Isolated pelvic deep venous thrombosis: Relative frequency as detected with MR imaging. *Radiology*. 2001;219(2):521-5.
- Pregnancy Mortality Surveillance System. Centers for Disease Control and Prevention. Available at: <http://www.cdc.gov/reproductivehealth/maternalinfanthealth/pmss.html>. Accessed Sep 12, 2016.
- Kearon C. Natural history of venous thromboembolism. *Circulation*. 2003;107(23 Suppl 1):I22-30.
- Kesieme E, Kesieme C, et al. Deep vein thrombosis: A clinical review. *J Blood Med*. 2011;2:59-69.
- Grimm LJ, Manson W. Bedside ultrasonography in deep vein thrombosis. *Drugs & Diseases*. Available at: <http://emedicine.medscape.com/article/1362989-overview>. Accessed Sep 12, 2016.
- Poley RA, Newbigging J, Sivilotti ML. Estimated effect of an integrated approach to suspected deep venous thrombosis using limited compression ultrasound. *Acad Emerg Med*. 2014;21(9):971-80.
- Peters MD, Syed RK, Katz M, et al. May-Thurner syndrome: A not so uncommon cause of a common condition. *Proc (Bayl Univ Med Cent)*. 2012;25(3):231-3.
- Chan W, Spencer FA, Lee AY, et al. Safety of withholding anticoagulation in pregnant women with suspected deep vein thrombosis following negative serial compression ultrasound and iliac vein imaging. *CMAJ*. 2013;185(4):E194-200.
- Bramante RM, Raio CC. Near-miss in focused lower-extremity ultrasound for deep venous thrombosis. *J Emerg Med*. 2013;45(2):236-9.

# “A Large Hiatal Hernia”: Atypical Presentation of Gastric Volvulus

Amirali Kiyani, MD\*  
 Manraj Khosla, MD†  
 Veronika Anufreichik, MS‡  
 Keng-Yu Chuang, MD\*§

\*Maricopa Medical Center, Department of Internal Medicine, Phoenix, Arizona  
 † St. Joseph’s Medical Center, Department of Internal Medicine, Phoenix, Arizona  
 ‡ Creighton University School of Medicine, Omaha, Nebraska  
 § University of Arizona College of Medicine, Phoenix, Arizona

Section Editor: Rick A. McPheeters, DO

Submission history: Submitted: June 1, 2016; Revision received: January 26, 2017; Accepted: February 22, 2017

Electronically published June 6, 2017

Full text available through open access at [http://escholarship.org/uc/uciem\\_cpem](http://escholarship.org/uc/uciem_cpem)

DOI: 10.5811/cpem.2017.2.31075

Gastric volvulus is a rare condition defined as an abnormal rotation of the stomach by more than 180 degrees. Gastric volvulus could present atypically with simply nausea and vomiting. A high index of suspicion is required for prompt diagnosis and treatment, especially when a patient presents with subacute intermittent gastric volvulus. Here, we present the case of a 56-year-old female with lung cancer status post left lower lobectomy undergoing chemotherapy who presented with intermittent nausea and upper abdominal pain for a few weeks. Barium study and computed tomography revealed acute mesenteroaxial gastric volvulus and she was treated with urgent surgical intervention. [Clin Pract Cases Emerg Med. 2017;1(3):187–189.]

## INTRODUCTION

Acute gastric volvulus is rare and is considered a medical emergency. Acute gastric volvulus usually presents with Borchadt’s triad: unproductive retching, epigastric pain and distention, and the inability to pass a nasogastric tube. Early recognition of the condition followed by surgical correction of the gastric malrotation can be life-saving. Prompt diagnosis of intermittent gastric volvulus may be challenging, as a patient might not exhibit classical symptoms in Borchadt’s triad and be mistaken with more common causes of intermittent abdominal pain such as peptic ulcer disease, dyspepsia or cholecystitis.

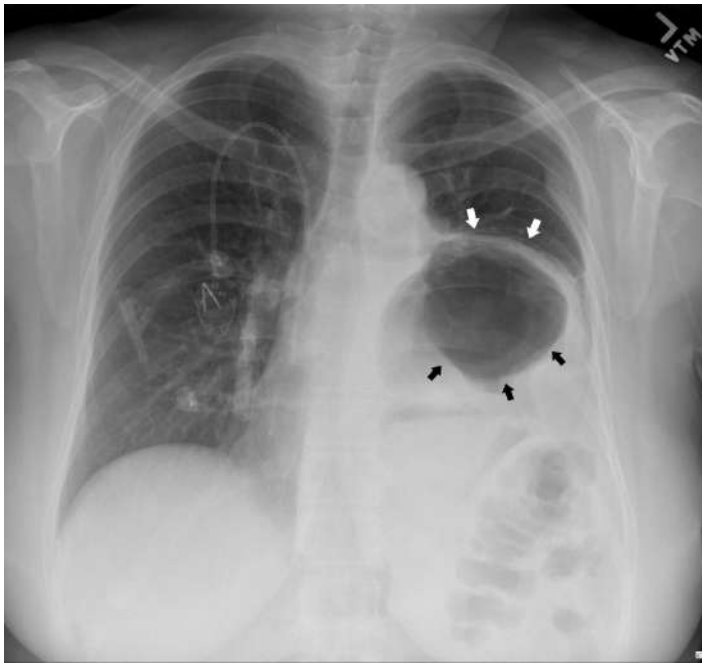
## CASE REPORT

A 56-year-old female with history of non-small cell lung cancer, hypertension, recently treated *H. pylori* infection and diabetes presented to a local emergency department (ED) twice in a week with the complaints of worsening nausea and bilious emesis over a one-month period while she was receiving chemotherapy. The patient also reported pain in the epigastrium that slowly progressed to the left chest. Patient had had left lower lobectomy with partial diaphragmatic resection a year prior as part of the treatment for the lung cancer. The patient had normal complete metabolic panel, magnesium, and lipase and a chest radiograph that was read as unremarkable besides “a large hiatal hernia.” She was discharged home the first time with antiemetics, but it was decided to admit her at the second ED

visit as she had laboratory abnormalities significant for severe hypokalemia (potassium: 2.4 mg/dL) and hypomagnesemia (magnesium: 0.6 mg/dL).

Physical examination was remarkable for decreased left lower lobe breath sounds as well as palpable tenderness in the epigastrium and the left chest wall. A chest radiograph revealed an air-filled, thick-walled structure overlying the left lower thorax with marked elevation of the left hemi-diaphragm (Image 1). The gastrointestinal (GI) service was requested to see the patient, and the consultant recommended a barium upper GI (UGI) series to define the gastric anatomy prior to performing an upper endoscopy. The barium UGI series revealed that about half of her stomach had migrated into the left thorax, occupying the space where her lung had been removed: the antrum was now situated above the diaphragm and was cephalad to the gastric body. Furthermore, the oral contrast administered could not empty into the duodenum despite the patient being placed in different positions (Image 2). A contrast-enhanced computed tomography (CT) of the chest, abdomen and pelvis next was performed and confirmed the diagnosis of mesenteroaxial gastric volvulus with gastric outlet obstruction (Image 3). The patient subsequently underwent emergent exploratory laparotomy for volvulus reduction, diaphragmatic defect repair and left tube thoracostomy. She tolerated the procedure well and experienced no complications. A control CT showed that the gastric body was in normal anatomic position (Image 4).

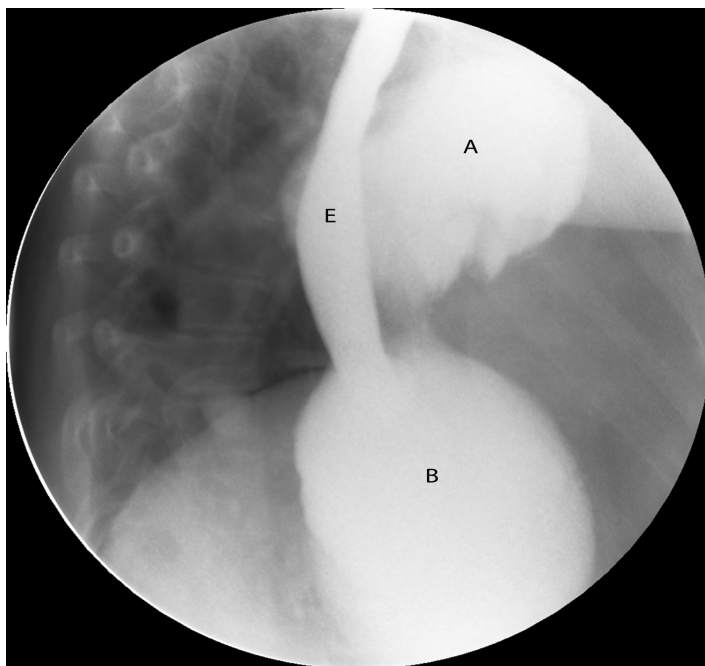




**Image 1.** Chest radiograph showing an air-filled, thick-walled structure (black arrows) overlying the left lower thorax with marked elevation of the left hemi-diaphragm (white arrows).

## DISCUSSION

Gastric volvulus is defined as an abnormal rotation of the stomach by more than 180 degrees and is classified as organoaxial (59%), mesenteroaxial (29%) or mixed.<sup>1</sup> Mesenteroaxial volvulus is more likely found in the pediatric population and is rarely described in adult individuals.<sup>2</sup> Risk



**Image 2.** Barium UGI series demonstrating mesenteroaxial gastric volvulus. Antrum (A). Gastric body (B). Esophagus (E). UGI, upper gastrointestinal

### CPC-EM Capsule

What do we already know about this clinical entity?

*Gastric volvulus is a rare but known entity. CT scan or upper GI series are the preferred diagnostic modalities. Treatment is surgical in most cases.*

What makes this presentation of disease reportable?

*Our patient presented with intermittent gastric volvulus, which can be very challenging to diagnose since it can mimic more common diseases such as peptic ulcer disease.*

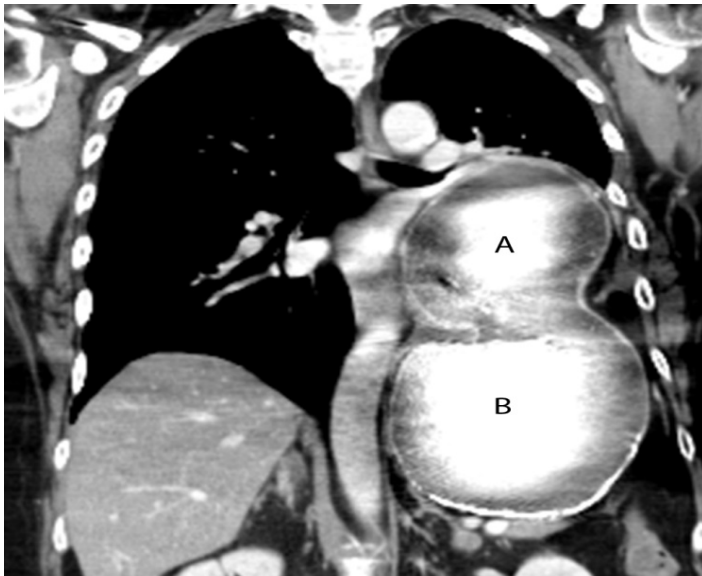
What is the major learning point?

*Physicians should consider gastric volvulus as a rare but possible differential diagnosis in patients with compatible history and exam but uncommon presentation.*

How might this improve emergency medicine practice?

*Any delay in diagnosis of gastric volvulus can have grave consequence and emergency physicians should have a high index of suspicion for prompt diagnosis and treatment.*

factors for gastric volvulus include patient age over 50, gastric ligament laxity, pyloric stenosis, rectal atresia, gastroduodenal tumors, diaphragmatic injury and eventration, left lung resection, or pleural adhesions.<sup>2,3</sup> Complications associated with gastric volvulus include bowel obstruction, strangulation, ischemia, necrosis, perforation and abdominal sepsis. Acute gastric volvulus is a medical emergency with mortality rates as high as 30-50%.<sup>4</sup> The diagnosis of gastric volvulus mainly relies on barium UGI series. A CT of the abdomen can confirm the gastric malrotation and define the transition point.<sup>5,6</sup> Upper abdominal defects including diaphragmatic eventration, paraesophageal hernia and wandering spleen can be seen associated with gastric volvulus on imaging studies. Gastric volvulus can sometimes be diagnosed through upper endoscopy and a tortuous appearance of the stomach; difficulty or inability for the endoscope to reach the pylorus can be encountered. Management is surgical and primarily involves decompression of the stomach, volvulus reduction



**Image 3.** Mesenteroaxial volvulus was seen on a coronal CT of the chest and abdomen where the antrum (A) has migrated above the left diaphragm and is cephalad to the gastric body (B). CT, computed tomography

and possible gastropexy or gastrostomy tube placement. Intra-abdominal defects should be corrected if contributory.<sup>4</sup>

Our patient with mesenteroaxial volvulus did not present with the typical Borchardt's triad. Instead, she presented with migrating pain from the epigastrium to the left chest over a one-month period, likely due to intermittent volvulus corresponding to the process of the stomach migrating through the post-lobectomy diaphragmatic defect leading to the eventual acute volvulus. The diagnosis of gastric volvulus

was not made during her first ED visit, as her symptoms, laboratory testing and the chest radiograph finding of "a large hiatal hernia" did not raise enough concern for additional imaging studies to be pursued. Fortunately, when she returned a week later, the correct diagnosis of gastric volvulus was made right away using barium UGI series and CT.

This experience demonstrates the importance of considering gastric volvulus as a rare but possible differential diagnosis when a patient has surgical history of left lobectomy and diaphragmatic injury, even if the patient does not present with a symptomology consistent with classic Borchardt's triad. Lack of prompt diagnosis could gravely change the patient's outcome.

#### ACKNOWLEDGMENTS

Dr. Kiyani and Dr. Khosla contributed equally to the writing of this paper.

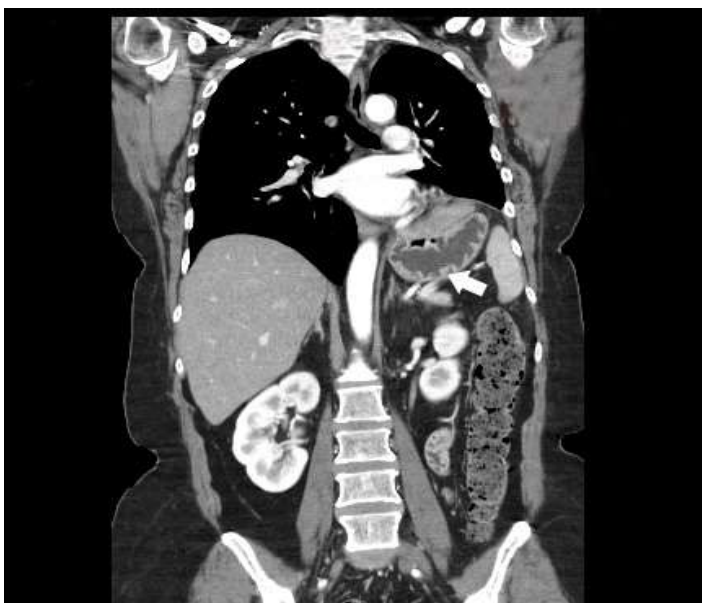---

*Address for Correspondence:* Amirali Kiyani, MD, Maricopa Medical Center, 2601 E Roosevelt St, Phoenix, Arizona 85008. Email: amirali.kiyani@mihs.org.

*Conflicts of Interest:* By the CPC-EM article submission agreement, all authors are required to disclose all affiliations, funding sources and financial or management relationships that could be perceived as potential sources of bias. The authors disclosed none.

*Copyright:* © 2017 Kiyani et al. This is an open access article distributed in accordance with the terms of the Creative Commons Attribution (CC BY 4.0) License. See: <http://creativecommons.org/licenses/by/4.0/>

---



**Image 4.** A control chest CT shows gastric body in normal anatomical position. CT, computed tomography

#### REFERENCES

- Rashid F, Thangarajah T, Mulvey D, et al. A review article on gastric volvulus: a challenge to diagnosis and management. *Int J Surg.* 2010;8(1):18–24.
- Darani A, Mendoza-Sagaon M, Reinberg O. Gastric volvulus in children. *J Pediatr Surg.* 2005;40(5):855-8.
- Chau B, Dufel S. Gastric volvulus. *Emerg Med J.* 2007;24(6):446-7.
- Lee HY, Park JH, Kim SG. Chronic Gastric Volvulus with Laparoscopic Gastropexy after Endoscopic Reduction: A Case Report. *J Gastric Cancer.* 2015;15(2):147-50.
- Kang DJ, D'Alessio M, Pan AS, et al. Difficulties in diagnosing an intermittent mesenteroaxial gastric volvulus. *J Surg Case Rep.* 2013;2013(10):pii:rjt078.
- Peterson CM, Anderson JS, Hara AK, et al. Volvulus of the gastrointestinal tract: appearances at multimodality imaging. *Radiographics.* 2009;29(5):1281–93.

# A Near Fatal Sneeze Spontaneous Splenic Rupture: A Case Report and Review of the Literature

Gregory W. Reinhold, DO\*  
Tina K. Melonakos, PharmD†  
Daniel T. Lyman, DO\*

\*Promedica Monroe Regional Hospital, Department of Emergency Medicine, Monroe, Michigan

†Promedica Monroe Regional Hospital, Department of Pharmacy, Monroe, Michigan

Section Editor: Rick A. McPheeters, DO

Submission history: Submitted October 13, 2016; Revision December 8, 2016 received; Accepted February 22, 2017.

Electronically published May 24, 2017

Full text available through open access at [http://escholarship.org/uc/uciem\\_cpchem](http://escholarship.org/uc/uciem_cpchem)

DOI: 10.5811/cpchem.2017.2.32847

A 79-year-old female called 911 for abdominal pain in her left upper quadrant with radiation through to her back and left shoulder for three hours. Upon arrival to the emergency department her physical exam was positive only for tenderness in the left upper quadrant of her abdomen. The patient denied any history of trauma but reported she “did sneeze three times” just prior to the onset of her pain. Computed tomography angiography of the abdomen and pelvis was obtained to evaluate for vascular pathology. The radiologist immediately called with concern for splenic laceration. The general surgeon took the patient directly to the operating room where she underwent a splenectomy and recovered without sequelae. This is the first case report of spontaneous splenic rupture that resulted after the act of sneezing. It is important to be aware of this rare clinical entity because early recognition can be life saving. [Clin Pract Cases Emerg Med. 2017;1(3):190-193]

## INTRODUCTION

Atraumatic splenic rupture (ASR) and spontaneous splenic rupture (SSR) are rare, life-threatening events, typically not at the top of a clinician’s differential for acute abdominal pain in the absence of trauma. The purpose of this paper is to bring this diagnosis to the forefront of clinicians’ minds, given the potential catastrophic sequelae if undiagnosed.

Historically, the first documented cases of ASR were by Rokitansky in 1861 and Atkinson in 1874.<sup>1</sup> In 1927 Weidemann defined “spontaneous splenic rupture” as that resulting from an incident without external force. In 1966 Knoblich further differentiated “non-traumatic rupture of a pathological spleen” from the extremely rare “non-traumatic splenic rupture of unknown etiology.”<sup>2</sup> In other words, this specified a true SSR as occurring in spleens without pathologic disease.

Etiology of ASR has largely been hypothesized to result from three primary mechanisms, the first being mechanical distention secondary to parenchymal infiltration associated with hematologic malignancy such as leukemia or lymphoma. The second is splenic infarct causing capsular hemorrhage and rupture, and the third is the existence of an underlying

coagulopathy.<sup>3</sup> It is important to note these mechanisms involve pathology of the spleen and thus would not be categorized as true SSRs.

Recent literature has found the incidence of true SSR varies from <1% to 7% with a mortality rate of approximately 12.2%.<sup>4,5</sup> SSRs are graded using the following criteria put forth by Orloff and Peskin: first, no history of trauma; second, no evidence of other organ disease known to adversely affect the spleen; third, no evidence of perisplenic adhesions or scarring of the spleen suggestive of prior trauma; and fourth, aside from hemorrhage and rupture, the spleen should be normal on gross inspection and histologic examination.<sup>6</sup> In 1991 Crate and Payne added a fifth criterion that full virological studies of acute and convalescent serum should show no significant rise in antibody titers.<sup>7</sup>

## CASE REPORT

Our case began with a 79-year-old female who called 911 from her home for transport to the emergency department (ED) for evaluation of abdominal pain in her left upper quadrant with radiation through to her back and left shoulder, which had been present for approximately three hours. The



patient had a past medical history significant for hypertension and hypercholesterolemia for which she took lisinopril and rosuvastatin daily.

Upon arrival at the patient's home, the emergency medical services (EMS) team reported that the patient initially appeared well with normal vital signs but then began to deteriorate. The patient's blood pressure fell to 61/38 mmHg and she had a near syncopal episode prompting EMS to administer intravenous (IV) fluids and commence transport to the ED for further evaluation.

When the patient arrived to the ED she was awake and alert with mild distress from her pain but interacting appropriately. Her vital signs were blood pressure of 101/56 mmHg, pulse rate of 74 beats per minute and an oxygen saturation of 100% on room air. Her physical exam was positive for tenderness in the left upper quadrant of her abdomen, but it was soft with no guarding or rigidity. She showed no signs of focal neurologic deficit, jugular venous distension, heart murmurs or abnormal lung sounds. Her extremities had equal distal pulses with good capillary refill. Her medical history provided no identifiable explanation for her pain. The patient denied any history of trauma but reported she "did sneeze three times" just prior to the onset of her pain. Given the patient's symptom of sudden onset abdominal pain with radiation to her back accompanied by hypotension, abdominal aortic aneurysm (AAA) was immediately considered. A bedside ultrasound was then performed but results were limited due to bowel gas present. Initial interpretation of her exam showed no obvious AAA, no definite free fluid and no evidence of pericardial tamponade. In the meantime vascular and general surgery were notified of the case, and since the patient's blood pressure had remained stable the decision was made to obtain computed tomography (CT) angiography of the abdomen and pelvis to further evaluate for vascular pathology.

Following the CT, the radiologist immediately called with preliminary results concerning for splenic laceration and hematoma with hemorrhagic abdominal and pelvic ascites (Image 1). After arriving back in the ED, the patient's blood pressure decreased to 68/45 mmHg. She was given a one-liter IV fluid bolus and was transfused one unit of packed red blood cells. The CT results and clinical deterioration were communicated to the general surgeon who took the patient directly to the operating room where she was found to have a ruptured spleen in multiple pieces with a large amount of free intraperitoneal blood. A splenectomy was performed and the patient recovered without sequelae. The pathology report revealed splenic fracture with otherwise-normal splenic tissue. Lab results showed the patient's initial liver functions and hemoglobin were within normal limits and a mononucleosis screen was negative.

During her recovery the patient was questioned concerning any sustained trauma or recent illness. She continued to deny any obvious inciting event but recalled she

### CPC-EM Capsule

What do we already know about this clinical entity?

*Spontaneous splenic rupture is a rare clinical entity and there has never been a case report documenting it as the result of sneezing.*

What makes this presentation of disease reportable?

*Splenic rupture is not typically in the differential for non-traumatic abdominal pain. This case illustrates why it should be considered even without history of trauma.*

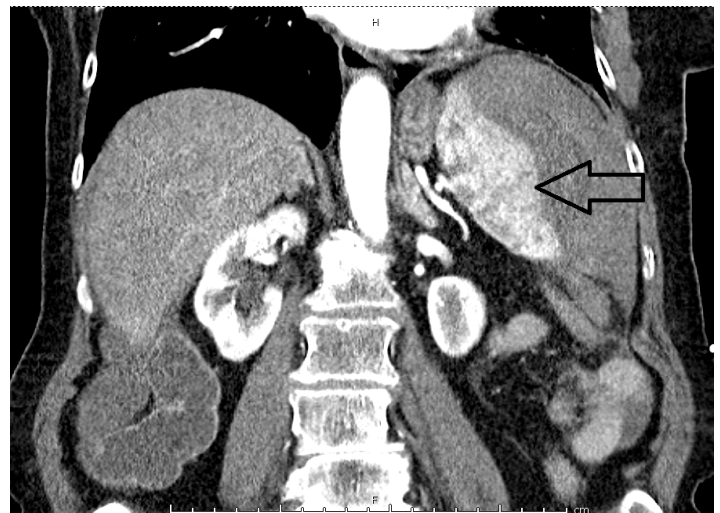
What is the major learning point?

*Trauma is not required to have splenic rupture.*

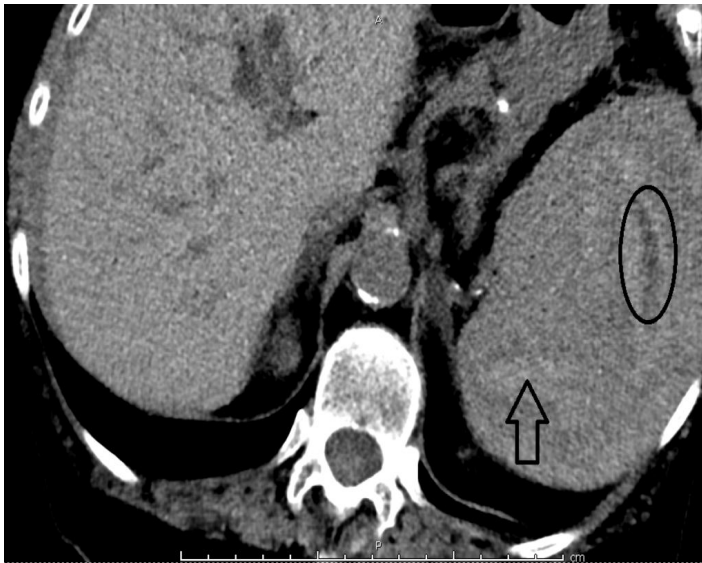
How might this improve emergency medicine practice?

*Clinicians who keep this case in mind are more likely to identify spontaneous splenic rupture in the absence of trauma.*

had three forceful sneezing episodes prior to the onset of her pain. From a clinical standpoint her sneezing episodes were the only identifiable trigger for this patient's SSR.



**Image 1.** Computed tomography of abdomen and pelvis in coronal view showing splenic laceration.



**Image 2.** Computed tomography of abdomen and pelvis in transverse view showing multiple hypoechoic densities within splenic parenchyma suggestive of splenic laceration (arrow) and hematoma formation (oval).

## DISCUSSION

SSR is a rare entity defined by the rupture of the spleen without antecedent injury. Most of the literature related to SSR is described in case reports. The term *spontaneous rupture* is often misleading. Wright and Prigot stated: “There is no such clinical entity as spontaneous rupture of the normal spleen.”<sup>9</sup> Johnson suggested that careful questioning will always elicit a history of injury.<sup>10</sup>

**Table.** Theories proposed to explain the spontaneous rupture of the spleen. <sup>[1-21]</sup>

1. Localized involvement of the spleen with a pathologic process where, upon rupture, all evidence of pathologic changes is destroyed.
2. Acute splenic congestion secondary to splenic vein spasm.
3. Splenic congestion secondary to chronic portal venous congestion.
4. Excessively mobile spleen causing mechanical obstruction and rupture.
5. Splenic artery aneurysm or degeneration.
6. Minor trauma that went overlooked.
7. Sudden elevation in abdominal pressure (i.e. a heavy meal, defecation, lifting, sexual intercourse, coughing, vomiting, pregnancy, colonoscopy, ERCP ).

ERCP, endoscopic retrograde cholangiopancreatography.

The pathologic features of SSR of a normal spleen are similar to those with a history of trauma. The main findings on macroscopic examination are a subcapsular hematoma, tears into the parenchyma, laceration of the pedicle, fragmentation and perisplenic hematoma.<sup>11</sup> The microscopic examination of the spleen is different between the two groups. Farhi and Ashfaq found that in traumatic splenic ruptures there was an increase in the germinal center proliferation and of marginal-zone hyperplasia compared to the non-traumatic spleens of corpses.<sup>12</sup>

Many theories have been proposed to explain spontaneous rupture of the spleen (Table 1). It has been postulated that the incidence of splenic rupture correlates with the size of the spleen, but in a retrospective study by Bauer et al., the percentage of normal-sized spleens that ruptured was as much as 48%.<sup>13</sup> The primary risk factors are splenic infiltration by hematologic disease, splenic infarct, male gender, adulthood, and severe splenomegaly.<sup>14</sup>

The diagnosis of SSR is in fact a diagnosis of exclusion. It is not considered to be a primary diagnosis in the evaluation of abdominal pain with hypotension in the absence of trauma. The most common presenting symptom is left upper quadrant pain and it is often associated with orthostatic symptoms. Two signs are particularly suggestive of splenic rupture: Kehr’s sign (left diaphragmatic irritation resulting in referred pain to the left shoulder), and Balance’s sign (palpable tender mass in the left upper quadrant). Classically, patients are found to be in hypovolemic shock with signs of peritonitis on exam. For our patient the exact diagnosis was not made until further imaging studies had been done.

The management of splenic ruptures is based upon a grading scale from low to high depending on whether the splenic capsule is intact or ruptured.<sup>3</sup> Low-grade splenic injuries may be managed conservatively as long as patients are hemodynamically stable. High-grade injuries typically require prompt surgical splenectomy to stabilize the patient.<sup>8</sup>

Confusing symptomatology arises for a couple of reasons. First, by virtue of the spleen’s position, local symptoms can be related to the left side of the chest, abdomen, and flank. Secondly, left-sided chest pain coupled with left shoulder pain and hemodynamic instability seen in splenic rupture can mimic myocardial infarction, pulmonary embolism or dissecting/ruptured aortic aneurysm. Finally, as a result of hemorrhage into the abdominal cavity, acute splenic rupture can masquerade as almost any cause of acute abdominal pain.

## CONCLUSION

This is the first documented case report of spontaneous splenic rupture that resulted after the act of sneezing. It was fortunate for our patient that the diagnosis was made quickly with the assistance of CT imaging and operative intervention was obtained in a timely manner. The patient recovered without sequelae. It is important to be aware of this rare clinical entity during practice because early recognition can be life saving.

**Address for Correspondence:** Gregory W. Reinhold, DO, Promedica Monroe Regional Hospital, 718 N. Macomb St., Monroe, MI 48162. Email: grein68237@gmail.com.

**Conflicts of Interest:** By the CPC-EM article submission agreement, all authors are required to disclose all affiliations, funding sources and financial or management relationships that could be perceived as potential sources of bias. The authors disclosed none.

**Copyright:** © 2017 Reinhold et al. This is an open access article distributed in accordance with the terms of the Creative Commons Attribution (CC BY 4.0) License. See: <http://creativecommons.org/licenses/by/4.0/>

## REFERENCES

- Rokitansky KF. Two recent cases of spontaneous rupture of the spleen. *Wochenblatt der Zeitschrift der k Gesellschaft der Aerzte in Wien*. 1861;17:42-4.
- Lieberman ME, Levitt MA. Spontaneous rupture of the spleen: A case report and literature review. *Am J Emerg Med*. 1989;7(1):28-31.
- Maqbool MS, Brush, RG, Northrup M. Atraumatic splenic rupture. *Ultrasound Q*. 2014;30(3):208-10.
- Renzulli P, Hostettler A, Schoepfer AM, et al. Systematic review of atraumatic splenic rupture. *Br J Surg*. 2009;96(10):1114-21.
- Laseter T, McReynolds T. Spontaneous splenic rupture. *Mil Med*. 2004;169(8):673-4.
- Orloff MJ, Peskin GW. Spontaneous rupture of the normal spleen; a surgical enigma. *Int Abstr Surg*. 1958;106(1):1-11.
- Crate ID, Payne MJ. Is the diagnosis of spontaneous rupture of a normal spleen valid? *J R Army Med Corps*. 1991;137(1):50-1.
- Weaver H, Kumar V, Spencer K, et al. Spontaneous splenic rupture: A rare life-threatening condition; Diagnosed early and managed successfully. *Am J Case Rep*. 2013;14:13-5.
- Wright LT, Prigot A. A traumatic subcutaneous rupture of the normal spleen. *Arch Surg*. 1939;39(4):551-76.
- Johnson N. Traumatic rupture of the spleen; a review of eighty-five cases. *Aust N Z J Surg*. 1954;24(2):112-24.
- Toubia NT, Tawk MM, Potts RM, et al. Cough and spontaneous rupture of a normal spleen. *Chest*. 2005;128(3):1884-6.
- Farhi DC, Ashfaq R. Splenic pathology after traumatic injury. *Am J Clin Pathol*. 1996;105(4):474-8.
- Bauer TW, Haskins GE, Armitage JO. Splenic rupture in patients with hematologic malignancies. *Cancer*. 1981;48(12):2729-33.
- Giagounidis AA, Burk M, Meckenstock G, et al. Pathologic rupture of the spleen in hematologic malignancies: two additional cases. *Ann Hematol*. 1996;73(6):297-302.
- Aubrey-Bassler FK, Sowers N. 613 cases of splenic rupture without risk factors or previously diagnosed disease: a systematic review. *BMC Emerg Med*. 2012;12:11.
- Wehbe E, Raffi S, Osborne D. Spontaneous splenic rupture precipitated by cough: A case report and a review of the literature. *Scand J Gastroenterol*. 2008;43(5):634-7.
- Kocael PC, Simsek O, Bilgin IA, et al. Characteristics of patients with spontaneous splenic rupture. *Int Surg*. 2014;99(6):714-8.
- Randriamarolahy A, Cucchi JM, Brunner P, et al. Two rare cases of spontaneous splenic rupture. *Clin Imaging*. 2010;34(4):306-8.
- Wang C, Tu X, Li S, et al. Spontaneous rupture of the spleen: a rare but serious case of acute abdominal pain in pregnancy. *J Emerg Med*. 2011;41(5):503-6.
- Anyfantakis D, Kastanakis M, Karona P, et al. Spontaneous rupture of the spleen masquerading as a pulmonary infection. *Case Rep Surg*. 2014;2014:196525.



# Repeat Point-of-Care Echocardiographic Evaluation of Traumatic Cardiac Arrest: A New Paradigm for the Emergency Physician

**Benjamin Thomas, MD\***  
**Edward Durant, MD\***  
**Sophie Barbant, MD†**  
**Arun Nagdev, MD\***

\*Highland General Hospital, Department of Emergency Medicine, Oakland, California

†Highland General Hospital, Department of Cardiology, Oakland, California

Section Editor: Rick A. McPheeters, DO

Submission history: Submitted October 29, 2016; Revision received February 9, 2017; Accepted February 22, 2017

Electronically published May 23, 2017

Full text available through open access at [http://escholarship.org/uc/uciem\\_cpem](http://escholarship.org/uc/uciem_cpem)

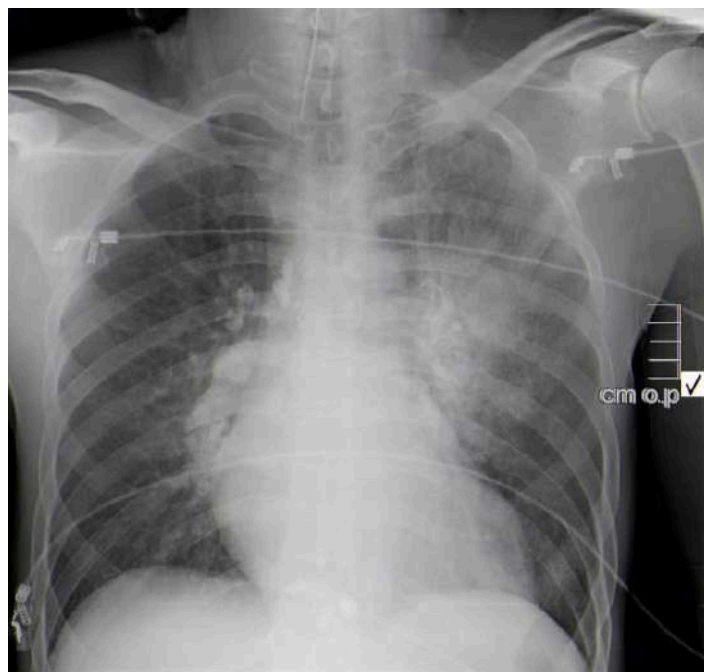
DOI: 10.5811/cpcem.2017.2.33021

We report a case of a 52-year-old man who presented to the emergency department (ED) in extremis (hypotensive with an altered sensorium) with subsequent cardiac arrest after a motor vehicle collision. The initial trauma evaluation did not reveal a source of the hemodynamic compromise. A point-of-care ultrasound revealed severe mitral regurgitation secondary to an anterolateral papillary muscle rupture. Patient underwent successful emergent mitral valve replacement after initial resuscitative efforts and intraaortic balloon pump placement. [Clin Pract Cases Emerg Med. 2017;1(3):194-196]

## INTRODUCTION

A 52-year-old man with an unknown history was transported in extremis by emergency medical services after a severe motor vehicle collision (MVC) into the side of a home. On arrival to the emergency department (ED), the patient's vital signs were blood pressure 90/50 mmHg, heart rate 110 beats per minute, respiratory rate 12 breaths per minute, oxygen saturation 95% on high flow non-rebreather mask, and a Glasgow coma score (GCS) of 8. During the primary survey, the patient was intubated due to labored breathing and a low GCS. The initial primary and secondary surveys did not reveal any signs of gross injury: his pelvis was stable, no long bone injuries were present, and rectal tone was intact prior to intubation. The initial extended focused assessment with sonography in trauma (EFAST) examination did not reveal free fluid in the chest, abdomen, pericardium, or pelvis. A modified pulmonary point-of-care ultrasound (POCUS) examination did not demonstrate a pneumothorax in either side of the chest, but did reveal significant B-lines in the left upper lung field that correlated with an AP chest radiograph (Image 1).

The pelvis was stabilized with a pelvic binder because of the persistent hypotension, and four units of packed



**Image 1.** Anterior posterior chest radiograph demonstrates unilateral (left sided) opacities.



red blood cells were transfused via a Level 1 infuser. An electrocardiogram (ECG) revealed sinus tachycardia with frequent ectopy, left axis deviation, right bundle branch block, ST depressions and T-wave inversions in multiple leads (anterior/septal, lateral) and hyperacute T waves in the inferior leads without obvious ST elevation, all of which were new compared with a prior ECG for the patient.

The patient was rapidly taken to computed tomography (CT) imaging because a clear source of hypotension could not be identified. After imaging, the patient was found to be in ventricular fibrillation, resulting in cardiac arrest as identified on a portable cardiac monitor, with a corresponding loss of pulses. Cardiopulmonary resuscitation and defibrillation were initiated and the patient regained spontaneous circulation within two minutes. CT revealed multifocal airspace consolidations, predominantly in the left upper lobe and right lower lobe, with no evidence of head, chest, or abdominal injury. Upon return to the trauma bay, a repeat POC echocardiogram was performed demonstrating hyperdynamic LV systolic function, severe mitral regurgitation (MR), and a ruptured anterolateral papillary muscle (Image 2A, 2B). An urgent cardiology consultation confirmed the POC echocardiography findings, and a diagnostic catheterization revealed no evidence of coronary occlusion. An intraaortic balloon pump was placed and the patient was emergently transferred to a surgical center for mitral valve replacement. The mitral valve replacement with a bioprosthesis was uncomplicated. Two weeks after the initial incident the patient was discharged with no cardiac or neurologic deficits, and followed up with cardiology services.

### *CPC-EM Capsule*

What do we already know about this clinical entity?

*The goal of POCUS in blunt trauma patients is to detect significant free fluid in the abdomen/thorax, and/or pericardial space and/or a significant pneumothorax.*

What makes this presentation of disease reportable?

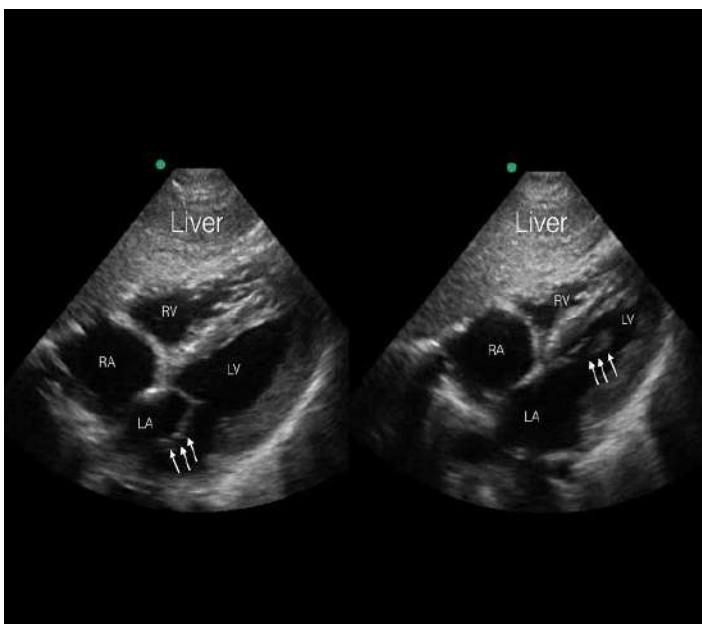*POCUS has utility in detecting more subtle findings (specifically cardiac) that are unrecognized during the initial resuscitation of the critically ill trauma patient.*

What is the major learning point?

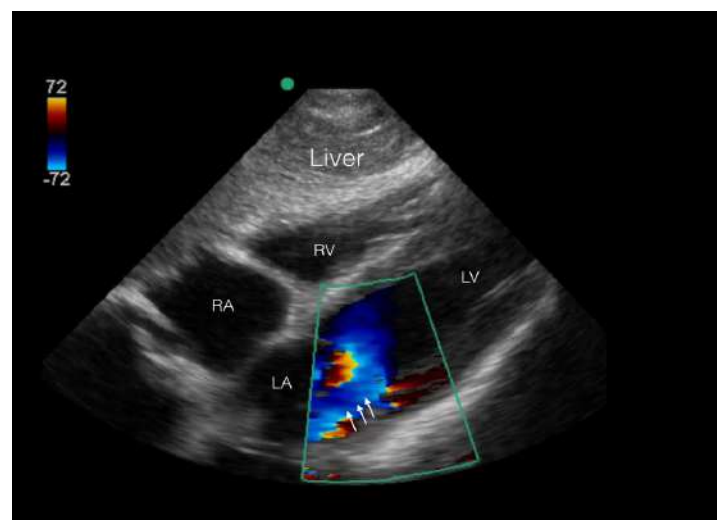
*Once the classic findings of trauma are ruled out in the unstable trauma patient, repeat the POCUS evaluation looking for gross valvular abnormalities.*

How might this improve emergency medicine practice?

*As clinicians become more facile with POCUS, important findings can be detected during the initial resuscitation of the critically ill trauma patient.*



**Image 2A.** A subxiphoid four chamber view of the heart demonstrates the mobile detached papillary muscle (arrows). RA, right atrium; RV, right ventricle; LA, left atrium; LV, left ventricle.



**Image 2B.** A subxiphoid four chamber view of the heart with color Doppler demonstrates a severe mitral regurgitation jet (arrows). RA, right atrium; RV, right ventricle; LA, left atrium; LV, left ventricle.

## DISCUSSION

Myocardial contusion is the most frequent cardiac injury observed after blunt chest trauma.<sup>1</sup> Valvular injury is less common. The aortic valve is the most frequently injured, followed by the mitral and tricuspid.<sup>2</sup> Acute MR due to papillary muscle rupture is a known complication of acute myocardial infarction. However, there are only a few cases of acute rupture secondary to blunt chest trauma, and no reported cases detected by POC echocardiography during the initial trauma resuscitation. Due to higher rates of MVCs, traumatic valvular rupture rates have increased, with clinical presentation varying from asymptomatic to cardiogenic shock.<sup>3,4</sup>

The mechanism of injury is thought to be due to the compression of the heart from sudden deceleration and transfer of kinetic energy to the patient's chest during late diastole. During this time in the cardiac cycle, the chambers are full and the valves are closing or closed. The valves are most vulnerable at this point to deceleration or compression injury.<sup>5-7</sup> On physical exam, the intensity of the murmur does not necessarily correlate with the severity of the murmur. Some patients with severe MR attributable to rupture have early equalization of left ventricular and left atrial pressures, resulting in silent MR (as in our patient) or a relatively soft, short, and indistinct murmur in as many as 50% of patients.<sup>8</sup>

One of the key diagnostic findings in this case was the presence of unilateral pulmonary edema (UPE) on the initial chest radiograph and POCUS. In a recent large, retrospective European study of patients referred to the intensive or coronary care units with cardiogenic shock, UPE was invariably associated with severe MR.<sup>9</sup> Although the finding of right-sided UPE was much more common, prolapse of the anterior leaflet, as was the case with our patient, was associated with left-side UPE.

POCUS has altered the framework for evaluating and managing the unstable trauma patient. EFAST evaluation allows for a directed evaluation of the abdomen, chest, and pericardium, which are cavities that can accumulate blood and cause hemodynamic compromise.<sup>10</sup> It can also be vital in the detection of a large pneumothorax that may prevent venous return to the heart. Conversely, a negative EFAST examination compels the clinician to look for other sources of hemodynamic decompensation (e.g. retroperitoneum, long bone fractures, spinal injury, etc.). A negative EFAST examination (with a negative CT of the chest and abdomen for hemorrhage) in a critically ill trauma patient should trigger the astute clinician to search for the underlying acute pathology that may have preceded the trauma. Given our experience, a detailed POC echocardiographic evaluation looking for ejection fraction, right ventricular size and gross valvular function has become our de facto protocol.

Papillary muscle rupture is a surgical emergency, and we conclude that the emergency physician's repeat, detailed POC echocardiography exam after the negative chest and abdomen CT in this patient prevented complete cardiac collapse. The emergency physician should entertain other sources of shock (cardiogenic, hypovolemic, distributive) in these difficult cases

Using POCUS is even more critical when initial standard imaging studies fail to find the source of the hemodynamic compromise. Without POCUS, our patient likely would not have survived the acute cardiac insult, reinforcing our belief that POCUS evaluation of the critically ill patient is imperative during both the initial trauma evaluation, and also during the re-evaluation when a clear source of shock is not detected.

---

*Address for Correspondence:* Arun Nagdev, MD, Highland General Hospital, 1411 East 31st Street, Oakland, CA 9460. Email: arunnagdev@gmail.com.

*Conflicts of Interest:* By the CPC-EM article submission agreement, all authors are required to disclose all affiliations, funding sources and financial or management relationships that could be perceived as potential sources of bias. The authors disclosed none.

*Copyright:* © 2017 Thomas. This is an open access article distributed in accordance with the terms of the Creative Commons Attribution (CC BY 4.0) License. See: <http://creativecommons.org/licenses/by/4.0/>

---

## REFERENCES

1. Attias D, Mansencal N, Auvert B, et al. Prevalence, characteristics, and outcomes of patients presenting with cardiogenic unilateral pulmonary edema. *Circulation*. 2010;122(11):1109-15.
2. Bakiler AR, Aydoğdu SA, Erişen S, et al. A case of mitral papillary muscle rupture due to blunt chest trauma. *Turk J Pediatr*. 2011;53(1):97-9.
3. Banning AP, Durrani A, Pillai R. Rupture of the atrial septum and tricuspid valve after blunt chest trauma. *Ann Thorac Surg*. 1997;64(1):240-2.
4. Bruschi G, Agati S, Iorio F, et al. Papillary muscle rupture and pericardial injuries after blunt chest trauma. *Eur J Cardiothorac Surg*. 2001;20(1):200-2.
5. Cuadros CL, Hutchinson JE 3rd, Mogtader AH. Laceration of a mitral papillary muscle and the aortic root as a result of blunt trauma to the chest. case report and review of the literature. *J Thorac Cardiovasc Surg*. 1984;88(1):134-40.
6. Liedtke AJ, DeMuth WE Jr. Nonpenetrating cardiac injuries: A collective review. *Am Heart J*. 1973;86(5):687-97.
7. Ma OJ, Mateer JR, Ogata M, et al. Prospective analysis of a rapid trauma ultrasound examination performed by emergency physicians. *J Trauma*. 1995;38(6):879-85.
8. Prêtre R, Chilcott M. Blunt trauma to the heart and great vessels. *N Engl J Med*. 1997;336(9):626-32.
9. Schreiber TL, Fisher J, Mangla A, et al. Severe "silent" mitral regurgitation. A potentially reversible cause of refractory heart failure. *Chest*. 1989;96(2):242-6.
10. Simmers TA, Meijburg HW, de la Rivière, AB. Traumatic papillary muscle rupture. *Ann Thorac Surg*. 2001;72(1):257-9.

# Unsuspected Clenbuterol Toxicity in a Patient Using Intramuscular Testosterone

Matthew K. Griswold, MD\*  
Eike Blohm, MD\*  
Roderick Cross, MD†  
Edward W. Boyer, MD, PhD\*  
Jennifer L. Carey, MD\*

\*University of Massachusetts School of Medicine, Department of Emergency Medicine, Division of Toxicology, Worcester, Massachusetts

†University of Massachusetts School of Medicine, Department of Emergency Medicine, Worcester, Massachusetts

Section Editor: Rick A. McPheeters, DO

Submission history: Submitted December 13, 2016; Revision received January 27, 2017; Accepted February 22, 2017

Electronically published May 23, 2017

Full text available through open access at [http://escholarship.org/uc/uciem\\_cpem](http://escholarship.org/uc/uciem_cpem)

DOI: 10.5811/cpem.2017.2.33318

Clenbuterol is a beta-agonist that has been abused by fitness-oriented individuals for muscle growth and weight loss. We report a case of a 46-year-old man who presented tachycardic, hypokalemic, and hyperglycemic after injecting testosterone obtained from Brazil. He developed refractory hypotension and was started on an esmolol infusion for suspected beta-agonist toxicity. Laboratory analysis showed a detectable clenbuterol serum concentration. Analysis of an unopened ampule contained boldenone undecylenate, clenbuterol, and vitamin E. This case illustrates a novel exposure that caused beta-agonist toxicity and was treated successfully with rapid-onset beta blocker. [Clin Pract Cases Emerg Med. 2017;1(3):197–200.]

## INTRODUCTION

Clenbuterol is a beta-agonist that has been abused by bodybuilders and other fitness-oriented individuals to promote muscle growth and weight loss by stimulating the  $\beta_3$  receptor. Clenbuterol in the past has been used as an adulterant for heroin.<sup>1</sup> Abuse of clenbuterol may produce hemodynamic compromise, life-threatening dysrhythmias and electrolyte disturbance.<sup>2</sup> Toxicity is easily confused with septic shock, but treatment is diametrically opposed; vasopressor therapy with additional  $\beta$ -agonism is detrimental to patients with clenbuterol toxicity as it will promote further tachycardia and subsequent hemodynamic collapse. Instead,  $\beta$ -antagonists are appropriate therapy for clenbuterol-induced hypotension.

## CASE REPORT

A 46-year-old man with a past medical history significant only for a traumatic back injury eight years prior, presented to the emergency department (ED) with acute onset of dizziness, nausea, and palpitations. His chronic back pain was refractory to standard anti-inflammatory medications and local corticosteroid injections. Six months prior to our encounter with the patient, he experienced symptom relief from a 1 mL intramuscular (IM) injection of a reported testosterone of unknown concentration,

which he had received from a friend. He had near-complete resolution and remained comfortable for a period of several months. The patient reported recurrence of his back pain; thus he decided to again attempt testosterone for pain relief. He self-



**Image 1:** Ampule of substance injected by patient with suspected clenbuterol toxicity.

administered a 2 mL injection of Testex Elmu Prolongatum 250 mg (testosterone cypionate) (Image 1).

The substance was contained in sealed-glass vials that had been purchased from Brazil and imported by a family member into the United States. Within minutes of the injection, he developed symptoms of palpitations, nausea and vomiting. He initially presented to a community hospital; however, he left prior to being evaluated by a physician. His symptoms persisted and the following day he returned to the same ED, where he was observed overnight. Serial troponin levels were negative and he was discharged the following day upon improvement of his symptoms.

Two months following the previous episode, the patient again self-injected intramuscular testosterone. Although product lot numbers were unavailable, the patient reported the vial originated from the same Brazilian shipment. Again, he experienced rapid onset of nausea, vomiting and palpitations. He initially presented to an affiliate hospital where he was found to have a heart rate of 130 beats per minute (bpm) and a blood pressure of 129/66 mmHg. An electrocardiogram (ECG) featured a junctional rhythm with QRS and QTc intervals of 92, and 608 msec respectively, and ST depression in the inferolateral leads indicative of myocardial strain (Image 2).

Labs were remarkable for potassium of 2.6 mmol/L (normal range: 3.5-5.3 mmol/L) and serum glucose of 261 mg/dL. His prolonged QTc was likely due to his hypokalemia. The patient denied history of diabetes mellitus. Serum troponin concentrations were undetectable (<0.02 ng/mL). Out of concern for a possible allergic reaction he was treated with one liter of intravenous (IV) normal saline, 50 mg IV diphenhydramine and 125 mg IV methylprednisolone. He was also administered 80 mEq oral potassium and 2 mg IV lorazepam. Subsequently, the patient developed acute hypotension with blood pressure falling to 70/33 mmHg, and he was given an additional 2.5 liters of normal saline. Fluid resuscitation failed to resolve his hypotension, and the patient was transferred to our tertiary care center for further evaluation and care.

Upon arrival to our facility, the patient's heart rate was 120 bpm and he remained hypotensive at 105/43 mmHg. We suspected the testosterone preparation contained clenbuterol, and out of concern for  $\beta$ -agonist toxicity he was started on esmolol (0.5 mg/kg bolus followed by a 50 mcg/kg/min infusion). Shortly after titration of esmolol, the patient's hypotension resolved and his tachycardia improved. He remained on the esmolol drip for a total of 12 hours. At the time of discharge, his heart rate was 98 bpm with a blood pressure of 120/66 mmHg. We recommended that the patient discontinue use of the testosterone product.

Laboratory workup during the patient's hospitalization included serial troponin serum levels, electrolyte monitoring and toxicology screens. Serial ECGs were performed, and the patient's rhythm improved to a sinus tachycardia at a rate of 109 bpm and a PR interval of 164 ms. The ST depression resolved. Serial serum troponin concentrations remained normal. A urine comprehensive drug screen (performed by gas chromatography

### *CPC-EM Capsule*

What do we already know about this clinical entity?

*Beta-agonist toxicity is described in toxicology literature, but it is not well known to other specialties. It may go unrecognized in the ED setting, as it mimics other pathologies such as sepsis.*

What makes this presentation of disease reportable?

*There are no published reports of clenbuterol adulterated testosterone. It is an important entity to recognize, as clenbuterol adulteration may appear elsewhere, such as to "cut" heroin.*

What is the major learning point?

*Consider beta-agonist toxicity in patients with tachycardia, hypokalemia and hyperglycemia. Short-acting beta antagonists improve hemodynamic output, particularly in hypotensive patients.*

How might this improve emergency medicine practice?

*Recognize beta-agonist toxicity (which mimics other common illnesses) and correctly treat it, despite therapy being diametrically opposed to "typical" therapy for tachycardia in a hypotensive patient.*

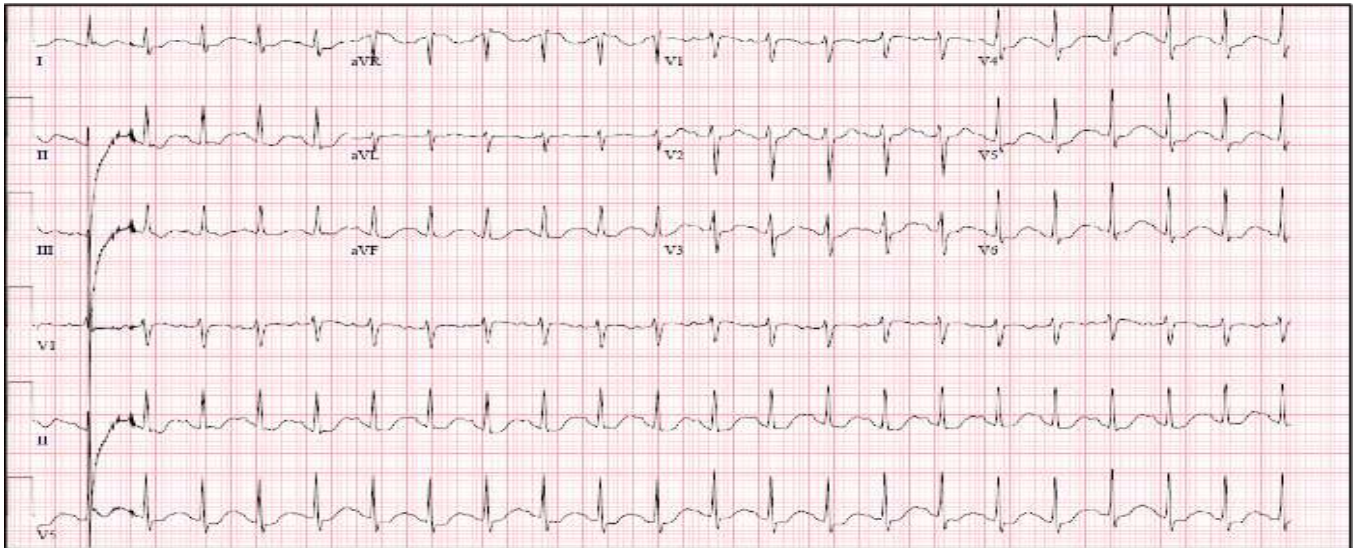
mass spectroscopy at our institution) was positive for caffeine and diphenhydramine. A quantitative caffeine level drawn two hours after the comprehensive drug screen was negative (<1 mcg/mL); hence methylxanthine toxicity was deemed unlikely. Qualitative analysis performed by NMS Laboratories (Willow Grove, PA) showed a positive clenbuterol serum concentration (>10 ng/mL). An unopened glass ampule provided by the patient was sent to NMS's crime laboratory. It was found to contain boldenone undecylenate, clenbuterol, and vitamin E.

## **DISCUSSION**

### **Differential Diagnosis**

The patient in this case presented with tachycardia, hypotension, hyperglycemia, and hypokalemia. In developing the differential diagnosis and treatment plan for this patient, dividing the signs and symptoms into hemodynamic and metabolic





**Image 2.** ECG at time of arrival.

categories was an effective approach.<sup>3</sup> Hemodynamically the patient was tachycardic and hypotensive, while metabolically the patient exhibited hyperglycemia and hypokalemia. This method will lead to distinct differential diagnoses for each category. Subsequently, the potential diagnoses can be compared across categories for similarities.

Toxicological etiologies of tachycardia include sympathomimetics, anticholinergics, hallucinogenics,  $\beta$ -adrenergic agonists, methylxanthines (such as caffeine or theophylline), and drug withdrawal.<sup>4</sup> Causes of hypotension include alpha-1 adrenergic antagonists (including tricyclic antidepressants), alpha-2 adrenergic agonists such as clonidine,  $\beta$ -adrenergic agonists, nitrates, carbon monoxide, cyanide, opiates, sedative hypnotics, and calcium channel blockers.<sup>5,6</sup> Hyperglycemia can be induced by  $\beta$ -adrenergic agonists, methylxanthines, and calcium channel blockers.<sup>7,8</sup> Moreover, adrenergic agonists, methylxanthines, and diuretics will cause hypokalemia.<sup>9</sup> Regarding the patient in this vignette,  $\beta$ -adrenergic agonists or methylxanthines explained the hemodynamic and metabolic abnormalities and suggested the likely toxicological etiology. In this presentation, methylxanthine toxicity was less likely as the patient did not have the other manifestations of severe methylxanthine overdose such as protracted emesis, seizure, or altered mental status.

### Pathophysiology

Clenbuterol is an agonist at  $\beta_1$ ,  $\beta_2$ , and  $\beta_3$  receptors. It is not approved for human use in the U.S., but is available in several European countries and Mexico as a bronchodilator ( $\beta_2$  agonist) for acute asthma exacerbation.<sup>10</sup> Daily regimens range from 20-200 mcg given 1-3 times daily. The drug is available as an IV/IM injection as well as an oral formulation with a bioavailability of 70-80%, and an elimination half-life of 25-39

hours.<sup>11</sup> Clenbuterol is abused by bodybuilders for lean muscle development and to reduce adipose tissue. Abuse of clenbuterol produces rhabdomyolysis, myocardial infarction, as well as life-threatening dysrhythmias and electrolyte disturbance.<sup>2,12</sup> High levels of clenbuterol can cause prolonged tachycardia, hypokalemia, and hypophosphatemia.<sup>2</sup>

The effects desired by bodybuilders are mediated by adipocyte  $\beta_3$  receptors, which stimulate lipolysis to reduce adipose tissue, as well as striated muscle  $\beta_2$  agonism, which increases muscle mass by nutrient partitioning.<sup>13</sup> Toxicity from clenbuterol is predominately caused by  $\beta_2$  agonism which mediates most of the drug's toxicity, including tachycardia, peripheral vasodilation, hypokalemia, and hyperglycemia.

In addition to the desired actions of clenbuterol, activation of the adrenergic system also leads to undesired side effects via a  $\beta_2$  adrenergic G-protein linked receptor. This results in increased chronotropy, intracellular shift of potassium and subsequently low serum potassium concentrations, and hyperglycemia.<sup>3,5,10</sup> Patients with clenbuterol toxicity present with tremor, palpitations, anxiety, shortness of breath, and vomiting.<sup>10,14</sup> Expected vital signs include tachycardia and hypotension. Laboratory workup may show hyperglycemia, hypokalemia, hypophosphatemia, and hypomagnesemia.<sup>2,10</sup> In addition, patients may have leukocytosis and an anion-gap acidosis.<sup>15</sup>

### Treatment

Clenbuterol toxicity can be easily confused with septic shock, but treatment is diametrically opposed. While intravenous crystalloid resuscitation is appropriate in both conditions, vasopressor therapy with additional  $\beta$ -agonism is detrimental to patients with clenbuterol toxicity as it will promote further tachycardia and subsequent hemodynamic collapse. Instead, the hemodynamic changes in clenbuterol toxicity should be treated

with  $\beta$ -antagonists.<sup>10</sup> Short-acting  $\beta$ -antagonists that allow for easy titration, such as esmolol, are preferred. Patients may require treatment of up to 72 hours.<sup>10</sup> Electrolyte abnormalities should be corrected early in the course of treatment.

Patients who progress to cardiac arrest with ventricular tachycardia or fibrillation should receive chest compressions and defibrillation, but epinephrine boluses should be withheld as they can cause further  $\beta$ -agonism and worsen the patient's condition. There are no data to support this recommendation apart from the understanding of the pathophysiology in this toxicity.

## CONCLUSION

$\beta$ -agonist toxicity is an uncommon but potentially dangerous condition that can be associated with the increased use of pharmaceuticals or bodybuilding, increasing fitness, and weight loss.<sup>12</sup> It has a relatively specific toxidrome that can commonly be overlooked when treating the undifferentiated hypotensive, tachycardic patient. Definitive treatment of  $\beta$ -agonist toxicity is with a  $\beta$ -antagonist; however, this can be counter-intuitive in the treatment of the hypotensive patient. We illustrate a case of a patient presenting with symptoms mimicking other common conditions such as sepsis or anaphylaxis. Emergency clinicians must be astute and consider a variety of alternative diagnoses, which includes  $\beta$ -agonist toxicity, as the treatment for this is diametrically opposed to standard treatments.

---

*Address for Correspondence:* Matthew K. Griswold, MD, University of Massachusetts, Department of Emergency Medicine, Division of Toxicology, 55 Lake Ave North, Worcester, MA. Email: [Matthew.Griswold@umassmemorial.com](mailto:Matthew.Griswold@umassmemorial.com).

*Conflicts of Interest:* By the CPC-EM article submission agreement, all authors are required to disclose all affiliations, funding sources and financial or management relationships that could be perceived as potential sources of bias. The authors disclosed none.

*Copyright:* © 2017 Griswold et al. This is an open access article distributed in accordance with the terms of the Creative Commons Attribution (CC BY 4.0) License. See: <http://creativecommons.org/licenses/by/4.0/>

---

## REFERENCES

- Hoffman RS, Kirrane BM, Marcus SM, et al. A descriptive study of an outbreak of clenbuterol-containing heroin. *Ann Emerg Med*. 2008;52(5):548-53.
- Hoffman RJ, Hoffman RS, Freyberg CL, et al. Clenbuterol ingestion causing prolonged tachycardia, hypokalemia, and hypophosphatemia with confirmation by quantitative levels. *J Toxicol Clin Toxicol*. 2001;39(4):339-44.
- Holstege CP, Borek HA. Toxidromes. *Crit Care Clin*. 2012;28(4):479-98.
- Boyle JS, Bechtel LK, Holstege CP. Management of the critically poisoned patient. *Scand J Trauma, Resusc and Emerg Med*. 2009;17(1):29.
- Lamont RF. The pathophysiology of pulmonary edema with the use of beta-agonists. *BJOG*. 2000;107(4):439-44.
- Erickson TB, Thompson TM, Lu JJ. The approach to the patient with an unknown overdose. *Emerg Med Clin North Am*. 2007;25(2):249-81.
- Levine M, Boyer EW, Pozner CN, et al. Assessment of hyperglycemia after calcium channel blocker overdoses involving diltiazem or verapamil. *Crit Care Med*. 2007;35(9):2071-5.
- Nelson H. Is there a problem with inhaled long-acting  $\beta$ -adrenergic agonists? *J Allergy Clin Immunol*. 2006;117(1):3-16.
- Gennari FJ. Hypokalemia. *N Engl J Med*. 1998;339(7):451-8.
- Daubert GP, Mabasa VH, Leung VWY, et al. Acute clenbuterol overdose resulting in supraventricular tachycardia and atrial fibrillation. *J Med Toxicol*. 2007;3(2):56-60.
- Yamamoto I, Iwata K, Nakashima M. Pharmacokinetics of plasma and urine clenbuterol in man, rat, and rabbit. *J Pharmacobiodyn*. 1985;8(5):385-91.
- Brett J, Dawson AH, Brown JA. Clenbuterol toxicity: a NSW Poisons Information Centre experience. *Med J Aust*. 2014;200(4):219-21.
- Grimmer NM, Gimbar RP, Bursua A, et al. Rhabdomyolysis secondary to clenbuterol use and exercise. *J Emerg Med*. 2016;50(2):e71-4.
- Yen M, Ewald MB. Toxicity of weight-loss agents. *J Med Toxicol*. 2012;8(2):145-52.
- Bilkoo P, Thomas J, Riddle CD, et al. Clenbuterol toxicity: an emerging epidemic. A case report and review. *Conn Med*. 2007;71(2):89-91.

# Compartment and Crush Syndromes After Sleep Deprivation and a Therapeutic Dose of Zolpidem

Martin R. Huecker, MD  
Eric Yazel, MD

University of Louisville School of Medicine, Department of Emergency Medicine,  
Louisville, Kentucky

Section Editor: Rick A. McPheeters, DO

Submission history: Submitted May 08, 2016; Revision received April 12, 2017; Accepted April 18, 2017

Electronically published July 6, 2017

Full text available through open access at [http://escholarship.org/uc/uciem\\_cpsem](http://escholarship.org/uc/uciem_cpsem)

DOI: 10.5811/cpcem.2017.4.30837

Despite extensive review in the literature, compartment syndrome and crush syndrome remain difficult to diagnose. Trauma, toxins and reperfusion have been associated with these syndromes. Cases involving alcohol and drug abuse have described patients “found down” compressing an extremity. We present a case of a registered nurse who developed compartment syndrome in multiple limbs due to prolonged sleep after sleep deprivation and zolpidem use. To our knowledge, this is the first case of compartment syndrome or crush syndrome to have occurred in the setting of zolpidem use. Sleep disruption in healthcare workers represents a public health issue with dangerous sequelae, both acute and chronic. [Clin Pract Cases Emerg Med. 2017;1(3):201–204.]

---

## INTRODUCTION

A shift worker is defined as “anyone who works extended-duration shifts and other variable and nonstandard hours ... late into the night or very early in the morning.”<sup>1</sup> Nurses and hospital staff implemented shift-based scheduling long ago. Emergency physicians (EP) adopted the practice early in the evolution of the specialty. Hospitals are non-stop businesses with high rates of error occurring at very high stakes. Hospital staff and physicians who work night shifts and swing shifts are subjected to circadian disruption that leads to fatigue, poor performance, and patient harm. Many shift workers find themselves unable to obtain satisfactory quality or quantity of sleep due to rotating schedules. Sleep deprivation has been shown to impair vigilance, cognition, memory and fine motor skills.<sup>2</sup> Night shift work and subsequent circadian disturbance have independent deleterious effects on these parameters.<sup>2</sup> Cognitive performance decline from sleep deprivation appears similar to alcohol intoxication, with 17 hours of wakefulness correlating to a blood alcohol concentration of 0.05% and 24 hours to 0.10%.<sup>3</sup>

Compartment syndrome refers to the pressure increase in a closed fascial space to the point of reduced capillary perfusion.<sup>4</sup> Usually due to long bone fracture, these pressure increases can ensue when a limb is crushed by a person’s own bodyweight.

With severe or prolonged crushing force, muscle necrosis occurs with subsequent life-threatening systemic effects: rhabdomyolysis, renal failure, hyperkalemia, and death. We present the case of a registered nurse who used pharmaceuticals to “catch up” on sleep, waking up 30 hours later with crush and compartment syndromes in multiple limbs.

## CASE REPORT

An African-American female in her early thirties with normal body mass index and no past medical history sought rest after 30 hours without sleep. The patient took 50 milligrams (mg) of diphenhydramine and five mg of immediate-release zolpidem. She awoke unable to move her right upper and lower extremities and had severe pain in the right side of her body. The patient contacted staff in her emergency department (ED) and was encouraged to call emergency medical services for transport to the hospital.

Initial vital signs were as follows: temperature 98.0 F, heart rate 112 beats/minute, respirations 14/minute, blood pressure 130/76 mmHg, oxygen saturation 96% on room air. Physical exam was remarkable for tense swelling over the right chest, shoulder and proximal arm. The induration extended to her right flank and proximal gluteal area. The patient was unable to lift her right upper and lower extremities



against gravity. Minimal digit flexion/extension was achievable. Radial and ulnar pulses were not palpable but could be obtained with Doppler.

Initial laboratory findings were significant for leukocytosis ( $45.2 \times 10^3/\text{mcL}$ ), potassium 6.1 mEq/L, bicarbonate 18 mmol/L, blood urea nitrogen (BUN) and creatinine (Cr) = 47mg/dL and 4.3 mg/dL. Urinalysis showed large blood and >50 red blood cells per high power field; lactate was 4.5 mmol/L and total creatine kinase (CK) was 346,866 IU/L. Aspartate aminotransferase and alanine aminotransferase were 3,200 U/L and 1,145 U/L. The EP was concerned for both a cerebrovascular event and compartment syndrome. Due to objective hemiparesis and rapid availability of magnetic resonance imaging (MRI), MRI brain, cervical spine, and right shoulder were obtained. MRI brain and spinal canal were normal, but the soft tissues and muscles of the neck and the shoulder displayed extensive edema concerning for myonecrosis.

Central venous access was obtained and the patient received normal saline with sodium bicarbonate. A urinary catheter yielded 50cc of tea-colored urine. The treatment team initiated transfer to a tertiary care center for hand surgery consultation and fasciotomy, nephrology evaluation, and intensive care unit coordination of care.

On arrival to our academic center, right upper extremity and right lower extremity compartment pressures were measured with a Stryker Intra-Compartmental Pressure Monitor: 75 and 35mmHg, respectively. Surgical consultants performed fasciotomies of the following compartments: right lateral thigh, right upper arm anterior and posterior compartment, right forearm volar and dorsal, and right hand thenar, hypothenar, dorsal, and volar interosseous compartments. Bicarbonate-rich intravenous (IV) fluids were continued. By hospital day three, her BUN and Cr had increased to 72 mg/dL and 7.5 mg/dL; total CK was 115,000 IU/L. Her urine output decreased.

The patient gradually regained sensation and motor function of the right upper and right lower extremities. She underwent multiple debridements and eventual closure of her fasciotomy sites. Her course was complicated by multiple episodes of symptomatic anemia requiring transfusion. She was discharged on hospital day 18. The last total CK was checked on hospital day eight and was 6,848 IU/L. Discharge BUN was 15 mg/dL and Cr was 1.3 mg/dL. One month after the injury the patient could ambulate with minimal limp and write and perform other fine motor tasks at near preinjury levels.

## DISCUSSION

To our knowledge, this is the first case of compartment or crush syndrome associated with the use of zolpidem. Compartment syndrome has been described in the setting of diphenhydramine overdose with coingestion of alcohol.<sup>5</sup> We believe zolpidem and diphenhydramine had synergistic effects in this case that led to prolonged down time, although we cannot conclude a direct causal link between zolpidem and

### *CPC-EM Capsule*

What do we already know about this clinical entity?

*Compartment and crush syndromes can be difficult to diagnose. In addition, sleep deprivation and circadian disruption affect all emergency care providers.*

What makes this presentation of disease reportable?

*To our knowledge, this is the first case of compartment and crush syndromes to have occurred in the setting of sleep deprivation or zolpidem use.*

What is the major learning point?

*Sleep disruption in healthcare workers represents a public health issue with dangerous, potentially fatal sequelae, both acute and chronic.*

How might this improve emergency medicine practice?

*EM practitioners should have suspicion for these syndromes. In addition, we should protect ourselves against the consequences of shift work.*

rhabdomyolysis. This case is also remarkable for the presence of compartment syndrome in multiple extremities induced only by pressure from body weight. Cases of multiple-limb compartment syndrome typically occur in natural disasters and collapsed buildings, or in patients with preexisting hematologic disease.<sup>6,7</sup> The sadly *common* aspect of our case is the sleep deprivation and circadian disruption that led to our patient's presentation. Sleep loss causes many acute performance and health effects. Memory and learning are disrupted, performance and judgment are impaired, and musculoskeletal injuries are more common.<sup>8</sup> The cycle of poor sleep and shift work leads to chronic health consequences: obesity, metabolic syndrome, cardiovascular disease, gastrointestinal disease, dysmenorrhea, psychological disorders, cancer, and motor vehicle collisions.<sup>1,8,9</sup> Chronic low levels of sleep loss cause similar impairments to acute sleep loss, and synergy exists between acute sleep loss and chronic sleep loss with circadian disruption.<sup>8</sup> Two weeks of sleeping less than six hours daily equates to the performance deficit of 24 continuous hours without sleep.<sup>10</sup> One week of sleeping four hours per night yields the performance deficit



similar to 48 consecutive hours without sleep.<sup>10</sup> Daytime sleep following a night shift is typically of short duration (5.5-6 hours) and low quality.<sup>11</sup> This contrasts with what occurred in the case presented.

The impaired clinical performance in sleep-deprived healthcare workers impacts patient safety. Errors by resident physicians are seven times more common in those working five or more 24-hour shifts in a month.<sup>9</sup> Needlesticks and motor vehicle accidents also increase with fatigue.<sup>9</sup> A review by Lockley et al. collated the many negative effects of working recurrent 24-hour shifts: five times the diagnostic errors, twice the attentional failures, 61% more needlestick injuries, and 300% more fatigue-related preventable adverse events leading to patient demise.<sup>10</sup> Fatigue is underappreciated in the person who is fatigued. Study participants in the lowest alertness category often rate themselves as “only slightly sleepy.”<sup>8</sup> In 2011, the Joint Commission issued a *Sentinel Event Alert* to draw awareness to shift length and work schedule effect on quality and quantity of sleep.<sup>12</sup> Nurses working 12-hour shifts have higher rates of burnout and job dissatisfaction.<sup>13</sup> In the *Sentinel Event Alert*, the Joint Commission urged healthcare organizations to educate staff on sleep hygiene and how fatigue impacts patient safety.<sup>12</sup> A fatigue management plan should be followed and fatigue should be investigated as a contributing factor in review of all adverse events.<sup>12</sup>

Pharmaceuticals are used in an attempt to mitigate fatigue and sleep disruption. Stimulants to increase alertness are cycled with sedatives to aid with sleep, often to the detriment of the person using the substances. In one survey of 226 emergency medicine residents, the use of sedatives approached 36%.<sup>14</sup> The American Academy of Sleep Medicine (AASM) cautions against the use of sedative-hypnotics due to side effects.<sup>15</sup> Sedative-hypnotics can worsen sleep-related breathing issues or cause subjective mood worsening, and do not reliably improve performance and safety.<sup>15</sup> Zolpidem is a sedative-hypnotic drug, FDA approved since 1992 for short-term treatment of insomnia.<sup>16</sup> Side effects range from daytime drowsiness, dizziness, hallucinations, agitation, and sleepwalking to committing crimes and driving or eating while asleep.<sup>16</sup> To our knowledge, zolpidem has not been implicated in a case of compartment or crush syndrome. Though some medications have been implicated in direct muscle damage, we believe zolpidem in this case caused a sedative effect and prolonged downtime. Considering all of the evidence for and against zolpidem use, the AASM includes zolpidem in its collection of drugs with minimal benefit in shift-work disorder.

### Compartment Syndrome

From Volkmann describing the contracture in 1881 to the current day, compartment syndrome has been challenging to diagnose.<sup>17,18</sup> The morbidity of a nonviable limb along with potential for death make compartment syndrome a prominent

medico-legal concern, with an average payout of \$426,000.<sup>18</sup> Compartment syndrome most often occurs after an extremity injury, though 30% of cases have no evidence of fracture.<sup>17</sup> Less common causes include infection, surgical positioning, constricting casts or splints, bleeding diathesis, reperfusion, toxins and burns.<sup>17,19</sup> The classic “P’s” (pain, paresthesia, pallor, paresis and pulse deficit) are not adequately sensitive and are often found only after irreversible muscle damage has occurred.<sup>17</sup> The patient will often have pain at rest and out of proportion to the physical examination findings. Passive stretching of the muscles in the involved compartment is one of the earlier signs.<sup>17</sup> The consensus on diagnosis of compartment syndrome designates clinical exam as the most important factor. Measurement of compartment pressures should be done in cases with equivocal exam findings, communication barriers (including pediatric patients), analgesia or anesthesia, multiple injuries, or comatose state.<sup>4,17</sup>

The decision to perform fasciotomy is made by surgical consultants when available. Most experts agree on surgical management by fasciotomy for the following cases: hypotensive patients with compartment pressure greater than 20mmHg; unconscious patients with compartment pressure greater than 30mmHg; and normotensive awake patients with positive clinical findings.<sup>18</sup> All affected compartments should be decompressed.<sup>4</sup> Cases of compartment syndrome in multiple extremities, as in our patient, have been described. However, this occurs almost exclusively in whole-body crush injury or in patients with predisposing comorbidities: sickle cell disease, capillary leak syndrome, and chronic myeloid leukemia.<sup>7</sup> Cases of compartment syndrome in multiple extremities not associated with one of these scenarios are rare to nonexistent.

### Crush Syndrome

First described in 1941 after the Battle of London, crush syndrome occurs when local tissue damage leads to systemic effects: rhabdomyolysis, hyperkalemia, and renal failure.<sup>6,19,20</sup> Commonly encountered causes are natural disasters and building collapse, or conditions causing prolonged down time: stroke, mental illness, intoxication with alcohol, heroin, or other sedatives.<sup>6,19</sup>

The manifestations of crush syndrome can be categorized by the body systems affected. Elevated serum potassium, urate and phosphorous can precipitate arrhythmias even in the first hour.<sup>6,20</sup> The local effects of the crush injury may cause hemorrhage and third spacing, exacerbating the shock state and disrupting cardiovascular stability.<sup>6,20</sup> Renal injury represents the complication with the highest mortality. Pulmonary, hematologic and infectious concerns also complicate the course of the crush victim. Acute respiratory distress syndrome, fat emboli, disseminated intravascular coagulation, shock liver, and wound infections can lead to

morbidity and mortality in this population.<sup>6</sup> After the ABCs, the crush syndrome patient needs early aggressive IV fluids.<sup>20</sup> Patients may require 6-12 liters per day of IV fluids to yield a recommended urine output of 200-300 cc/hr.<sup>6,7,20</sup>

Treatment with mannitol and sodium bicarbonate fluids is controversial, although physiologically sound. In most studies these two interventions are combined, making it difficult to parse the role of each. No randomized controlled trial has been conducted to establish or disconfirm a benefit with either of these therapies.<sup>6</sup> Both therapies remain reasonable depending on individual patient characteristics.

When hyperkalemia, volume overload or severe acidosis are present, renal replacement may be necessary, although hemodialysis does not actually remove the very large myoglobin molecule from the circulation.<sup>6</sup> Our patient received sustained low-efficiency dialysis for 72 hours to treat hyperkalemia and volume overload.

Crush syndrome has a relatively good prognosis with early recognition and initiation of IV fluids, proper supportive care, and local management of compartment syndrome when present.<sup>6</sup>

## CONCLUSION

Acute and chronic deleterious health effects will invariably follow the sleep and circadian disruption associated with shift work. Sedative-hypnotic drugs have limited application in the maintenance of healthy sleep schedules in those working extended hours and night shifts. This case of compartment syndrome and crush syndrome represents a rare but representative example of the acute effects of sleep deprivation on the healthcare worker. Early diagnosis and aggressive management of these complications allowed for an almost complete recovery. The emergency physician must remain vigilant in considering these limb and life-threatening diagnoses, and in ensuring his/her own wellness.

---

*Address for Correspondence:* Martin R. Huecker, MD, Department of Emergency Medicine, University of Louisville, 530 South Jackson St C1H17, Louisville, KY 40202. Email: martin.huecker@louisville.edu.

*Conflicts of Interest:* By the CPC-EM article submission agreement, all authors are required to disclose all affiliations, funding sources and financial or management relationships that could be perceived as potential sources of bias. The authors disclosed none.

*Copyright:* © 2017 Huecker et al. This is an open access article distributed in accordance with the terms of the Creative Commons Attribution (CC BY 4.0) License. See: <http://creativecommons.org/licenses/by/4.0/>

---

## REFERENCES

- Barger LK, Lockley SW, Rajaratnam SM, et al. Neurobehavioral, health, and safety consequences associated with shift work in safety-sensitive professions. *Curr Neurol Neurosci Rep*. 2009;9(2):155-64.
- Phillibert I. Sleep loss and performance in residents and nonphysicians: a meta-analytic examination. *Sleep*. 2005;28(11):1392-402.
- Dawson D, Reid K. Fatigue, alcohol and performance impairment. *Nature*. 1997;388(6639):235.
- Tiwari A, Hag AI, Myint F, et al. Acute compartment syndromes. *Br J Surg*. 2002;89(4):397-412.
- Vearrier D, Curtis JA. Case files of the medical toxicology fellowship at Drexel University. Rhabdomyolysis and compartment syndrome following acute diphenhydramine overdose. *J Med Toxicol*. 2011;7(3):213-9.
- Genthon, A, Wilcox SR. Crush syndrome: a case report and review of the literature. *J Emerg Med*. 2014;46(2):313-9.
- Sever MS, Vanholder R, Lameire N. Management of crush-related injuries after disasters. *N Engl J Med*. 2006; 354(10):1052-63.
- Eanes L. CE: The potential effects of sleep loss on a nurse's health. *Am J Nurs*. 2015;115(4):34-40
- Boivin DB, Boudreau P. Impacts of shift work on sleep and circadian rhythms. *Pathol Biol (Paris)*. 2014;62(5): 292-301.
- Lockley SW, Barger LK, Ayas NT, et al. Effects of health care provider work hours and sleep deprivation on safety and performance. *Jt Comm J Qual Patient Saf*. 2007;33(11 Suppl): p. 7-18.
- Vidacek S, Kaliterna L, Radosević-Vidacek B, et al. Productivity on a weekly rotating shift system: circadian adjustment and sleep deprivation effects? *Ergonomics*. 1986;29(12):1583-90.
- Health care worker fatigue and patient safety. *Sentinel Event Alert*. 2011;(48):1-4.
- Martin, DM. Nurse Fatigue and Shift Length: A Pilot Study. *Nurs Econ*. 2015;33(2):81-7.
- Shy, BD, Portelli I, Nelson LS. Emergency medicine residents' use of psychostimulants and sedatives to aid in shift work. *Am J Emerg Med*. 2011;29(9):1034-6.e1.
- Roth T. Appropriate therapeutic selection for patients with shift work disorder. *Sleep Med*. 2012;13(4):335-41.
- Mitka M. Zolpidem-related surge in emergency department visits. *JAMA*. 2013;309(21):2203.
- von Keudell AG, Weaver MJ, Appleton PT. Diagnosis and treatment of acute extremity compartment syndrome. *Lancet*. 2015;386(10000):1299-1310.
- Mabvuure NT, Malahias M, Hindocha S. Acute compartment syndrome of the limbs: current concepts and management. *Open Orthop J*. 2012;6: 535-43.
- Kikta MJ, Meyer JP, Bishara RA, et al. Crush syndrome due to limb compression. *Arch Surg*. 1987;122(9):1078-81.
- Smith J, Greaves I. Crush injury and crush syndrome: a review. *J Trauma*, 2003;54(5 Suppl):S226-30.

# When Too Much Is Enough: Pediatric Cyproheptadine Overdose with Confirmatory Level

**Terrance McGovern, DO, MPH\***

**Justin McNamee, DO†**

**Steven Marcus, MD‡**

**Josh Kashani, DO\***

\*St. Joseph's Regional Medical Center, Department of Emergency Medicine, Paterson, New Jersey

†Emergency Medicine Professionals, Ormond Beach, Florida

‡Rutgers University Hospital, Department of Emergency Medicine, Newark, New Jersey

Section Editor: Rick A. McPheeters, DO

Submission history: Submitted December 11, 2016; Revision received February 25, 2017; Accepted March 10, 2017

Electronically published July 6, 2017

Full text available through open access at [http://escholarship.org/uc/uciem\\_cpccm](http://escholarship.org/uc/uciem_cpccm)

DOI: 10.5811/cpcem.2017.2.33313

Cyproheptadine is an H-1 antihistamine with anticholinergic and antiserotonergic effects. Cyproheptadine's most common use has been in the management cold-induced urticaria. It is often used in primary care for its side effect of appetite stimulation. Recently there has been increasing interest in its use in the treatment of drug-induced serotonin syndrome. Cyproheptadine overdose is uncommonly reported in the medical literature. We report the rare case of a pediatric cyproheptadine overdose with a confirmatory cyproheptadine level. [Clin Pract Cases Emerg Med. 2017;1(3):205–207.]

## INTRODUCTION

Cyproheptadine is an antagonist at muscarinic, H-1 histaminic and serotonin receptors.<sup>1</sup> Previously reported cases of pediatric cyproheptadine toxicity reflect the antimuscarinic nature of the drug with resulting anticholinergic signs and symptoms.<sup>2,3,4</sup> Only one prior reported case confirms the exposure with a supporting drug level.<sup>5</sup> We report a case of symptomatic pediatric cyproheptadine overdose with a confirmatory therapeutic drug level.

## CASE REPORT

A 5-year-old female with no significant past medical history began to experience urinary incontinence, ataxia, confusion, visual and auditory hallucinations while at home with her mother. Shortly thereafter, the patient's mother found her recently prescribed cyproheptadine bottle empty, which previously contained approximately 15-20 (4 mg) tablets for appetite stimulation. Emergency medical services was contacted and she was transported to the emergency department (ED). Upon arrival her physical examination revealed a blood pressure of 111/89 mmHg, heart rate of 140 beats per minute, respiratory rate of 26 breaths per minute, axillary temperature of 97° F and an oxygen saturation of 100% on room air. On physical exam she was found to be disoriented to person, place, time and situation. While she was confused throughout her ED course, she would follow commands when asked to do so. Additionally, she had ongoing visual and auditory hallucinations during her stay. Her pupils

were 3 mm, equal and reactive. The oral mucosa, as well as the axillae, were dry. Bowel sounds were present and her abdomen was soft and non-tender throughout. She had clear lung sounds and aside from the tachycardia a benign cardiovascular exam. No apparent petechiae, purpura or skin abnormalities were noted.

Laboratory evaluation including a complete blood count and basic metabolic profile were within normal limits with the exception of a slightly decreased CO<sub>2</sub> of 22 mmol/L. Alcohol, acetaminophen and salicylate levels were negative. An electrocardiogram showed sinus tachycardia with a ventricular rate of 151 beats per minute with normal axis and intervals. A urine enzyme-mediated immunotransferase screen for drugs of abuse was negative, and human immunodeficiency screen was also negative. A cyproheptadine level obtained approximately 12 hours after exposure was 0.054 mg/L (therapeutic range 0.02 – 0.1 mg/L). After consultation with the toxicology service the recommendation was for the patient to be admitted overnight for observation and supportive care. She was subsequently admitted to the pediatric stepdown unit and had a progressive improvement in her symptoms. After 24 hours of inpatient observation she was asymptomatic and discharged home.

## DISCUSSION

Cyproheptadine is an antagonist at muscarinic, H-1 histaminic and serotonergic receptors. It is used in the management of serotonin syndrome, migraine prophylaxis, cold-induced urticaria, appetite stimulation and the management



of allergic reactions.<sup>6-11</sup> The diverse nature of cyproheptadine allows it to be used for a variety of clinical indications.

Previously reported cases of pediatric cyproheptadine overdose describe patients with various anticholinergic signs and symptoms. Our patient also exhibited signs and symptoms that were consistent with anticholinergic toxicity with the exception of urinary incontinence. Urinary incontinence, although not classically associated with anticholinergic toxicity, may occur as a result of overflow incontinence.<sup>12</sup>

In our patient we obtained a confirmatory level 12 hours after exposure via gas chromatography – mass spectrometry (GC/MS) of 0.054 mg/L (therapeutic range 0.02 – 0.1 mg/L, per hospital's laboratory). She was not on any additional medications and therefore cross-reactivity was not likely; nor are there any reports of cross-reactivity interfering with quantitative levels in the medical literature. The therapeutic level of cyproheptadine in the setting of obvious toxicity is consistent with the large volume of distribution and largely unknown human pharmacokinetics. The suspected maximum dose consumed by the patient (weight=16.2 kg) was 80mg or 4.94mg/kg. The recommended dose for patients between two- and six-years-old is 0.25 mg/kg/day, which for our patient would have been a total dose of 4.05 mg/day.<sup>13</sup> Although the ingestion was not witnessed, the history, supporting level and clinical presentation make it the likely etiology for her presentation.

## CONCLUSION

This case highlights the development of cyproheptadine toxicity in the setting of a therapeutic serum level in a pediatric patient. She was managed conservatively and was discharged without further complication. While there has been one previous pediatric case with a confirmatory serum level reported by Yuan et al., the patient's serum cyproheptadine level was supratherapeutic based on their cited therapeutic range of cyproheptadine concentration.<sup>5</sup> We believe that this is the first reported case of a pediatric cyproheptadine toxicity with a supporting therapeutic drug level.

*Address for Correspondence:* Terrance McGovern, DO, MPH, St. Joseph's Regional Medical Center, 703 Main Street, Paterson, NJ 07503. Email: terrance.mcgovern@gmail.com.

*Conflicts of Interest:* By the CPC-EM article submission agreement, all authors are required to disclose all affiliations, funding sources and financial or management relationships that could be perceived as potential sources of bias. The authors disclosed none.

*Copyright:* © 2017 McGovern et al. This is an open access article distributed in accordance with the terms of the Creative Commons Attribution (CC BY 4.0) License. See: <http://creativecommons.org/licenses/by/4.0/>

### CPC-EM Capsule

What do we already know about this clinical entity?

*Cyproheptadine is a muscarinic, H-1 histaminic and serotonergic antagonist that can clinically present with an anticholinergic toxicity in the setting of an overdose.*

What makes this presentation of disease reportable?

*This is the first pediatric ingestion of cyproheptadine that clinically presented with evidence of toxicity despite having a therapeutic serum drug level.*

What is the major learning point?

*Especially in toxicologic emergencies, clinicians should focus on the clinical signs and symptoms of the patient rather than the quantitative serum levels obtained.*

How might this improve emergency medicine practice?

*This case highlights the need for clinicians to continue to rely on their physical exam when evaluating patients with suspected toxic overdose.*

## REFERENCES

1. Remy DC, Raab AW, Rittle KE, et al. A comparison of the antiserotonin, antihistamine, and anticholinergic activity of cyproheptadine with analogues having furan nuclei fused to the 10,11-vinylene bridge. *J Med Chem.* 1977;20(6):836-8.
2. Watemberg NM, Roth KS, Alehan FK, et al. Central anticholinergic syndrome on therapeutic doses of cyproheptadine. *Pediatrics.* 1999;103(1):158-60.
3. Richmond M, Seger D. Central anticholinergic syndrome in a child: a case report. *J Emerg Med.* 1985;3(6):453-6.
4. Blaustein BS, Gaeta TJ, Balentine JR, et al. Cyproheptadine-induced central anticholinergic syndrome in a child: a case report. *Pediatr Emerg Care.* 1995;11(4):235-7.
5. Yuan C, Spandorfer P, Miller S, et al. Evaluation of tricyclic antidepressant false positivity in a pediatric case of cyproheptadine (Periactin) Overdose. *Ther Drug Monit.* 2003;25(3):299-304.
6. Gaudins A, Stearman A, Chan B. Treatment of the serotonin syndrome with cyproheptadine. *J Emerg Med.* 1998;16(4):615-9.

7. McDaniel WW. Serotonin syndrome: early management with cyproheptadine. *Ann Pharmacother*. 2001;35(7-8):870-3.
8. Lewis DW, Diamond S, Scott D, et al. Prophylactic treatment of pediatric migraine. *Headache*. 2004;44(3):230-7.
9. Bentley B 2nd. Cold-induced urticaria and angioedema: diagnosis and management. *Am J Emerg Med*. 1993;11(1):43-6.
10. Silverstone T, Schuyler D. The effect of cyproheptadine on hunger, calorie intake and body weight in man. *Psychopharmacologia*. 1975;40(4):335-40.
11. Beakey JF. An allergist looks at urticaria. *Cutis*. 1976;18(2):247-9.
12. Smith DR, Tanagho EA, McAninch JW. *Smith's General Urology*. 17<sup>th</sup> ed. New York: Lange Medical Books/McGraw-Hill; 2008.
13. Cyproheptadine Hydrochloride Tablets USP [package insert]. Emcure Pharmaceuticals LTD. Hinjwadi, Pune, India; 2007.

# An Unusual Case of Posterior Reversible Encephalopathy Syndrome

**Robert P. Zemple, MD\***  
**Tomer Pelleg, DO†**  
**Moises R. Cossio, DO‡**

\*Carilion Clinic, Department of Emergency Medicine, Roanoke, Virginia  
†Carilion Clinic, Department of Internal Medicine, Roanoke, Virginia  
‡Carilion Clinic, Department of Pulmonary Critical Care, Roanoke, Virginia

*Section Editor:* Rick A. McPheeters, DO

Submission history: Submitted May 22, 2016; Revision received February 24, 2017; Accepted March 10, 2017

Electronically published July 14, 2017

Full text available through open access at [http://escholarship.org/uc/uciem\\_cpem](http://escholarship.org/uc/uciem_cpem)

DOI: 10.5811/cpcem.2017.3.30999

A 21-year-old pregnant female with no significant past medical history presented with acute onset headache and nausea as well as tonic-clonic seizures, then rapidly decompensated into a coma with complete absence of brainstem reflexes. The patient was ultimately diagnosed with hemolysis, elevated liver enzymes, and low platelets (HELLP syndrome) and subsequent posterior reversible encephalopathy syndrome (PRES) with brainstem involvement. Emergent delivery and blood pressure control resulted in rapid and complete neurologic recovery. [Clin Pract Cases Emerg Med.2017;1(3):208-211]

---

## INTRODUCTION

Posterior reversible encephalopathy syndrome (PRES), first described by Hinchey et al in 1996,<sup>1</sup> is a reversible condition classically associated with headache, altered mental status, seizures, and visual deficits. Vasogenic edema, most commonly manifesting as posterior white matter changes, is frequently appreciated.<sup>2</sup> Encephalopathy is the most common presenting symptom, which has been described in approximately 92% of patients, followed closely by seizure 75-87%, and headache in 53%.<sup>3</sup> Without immediate management and definitive treatment, significant morbidity and mortality can result.

## CASE REPORT

A 21-year-old female with no significant past medical history presented to an outside hospital accompanied by her father, following two witnessed episodes of generalized tonic-clonic movement. Initial seizure activity was controlled with a single, appropriate dose of intravenous lorazepam; however, she quickly became obtunded and required intubation for airway protection. A bedside ultrasound revealed a previously unknown pregnancy of 32-35 weeks gestation. Basic laboratory evaluation demonstrated a mildly elevated serum creatinine and no other abnormalities. An emergent non-contrast head computed topography (CT) demonstrated findings of diffuse anoxic brain injury. With no signs of neurologic recovery the patient was transferred to a

tertiary academic medical center.

Upon arrival to the accepting institution the patient was tachycardic at 129 beats per minute and hypertensive with a blood pressure of 229/158 mm Hg. Initial physical examination revealed an unresponsive and gravid female, intubated and mechanically ventilated. Neurologic exam demonstrated the complete absence of a gag reflex with no active paralytic on board from the outside facility. Her pupils were non-reactive and she had no corneal reflexes; doll's eyes phenomena were present. Invasive arterial monitoring and central venous access were rapidly acquired. Immediate hypertensive management with a continuous intravenous nicardipine infusion was initiated. The patient also received a concomitant magnesium infusion for seizure control. Complete laboratory analysis demonstrated transaminitis (aspartate aminotransferase [AST] 569 IU/L, alanine aminotransferase [ALT] 159 IU/L), thrombocytopenia (43,000/ml), and anemia, consistent with HELLP syndrome.

The patient underwent emergent cesarean section and a live female infant was delivered. Post-delivery repeat non-contrast head CT (initial at outside hospital) revealed slender lateral ventricles and diffuse cerebral swelling; low-density areas were seen in the parieto-occipital region as well as indistinct areas of the basal ganglia, putamen and thalamus (Image), suggesting either anoxic brain injury or atypical posterior reversible encephalopathy syndrome.

Following delivery, the patient's blood pressure continued to improve and the nicardipine infusion was discontinued. Antiepileptic therapy was initiated and the magnesium infusion was gradually tapered. Shortly thereafter, the patient's brainstem reflexes began to return; six hours post-delivery the patient's pupils were reactive and she demonstrated voluntary movement of all four extremities. Her neurologic status continued to improve over the next 16 hours and she was liberated from ventilatory support the subsequent morning.

The subsequent neurological examination revealed no cognitive or reflexive deficits; she was able to ambulate and communicate appropriately. Her laboratory data began to improve and she was transferred to the postpartum unit the following day where she continued to recover. On hospital day six, the patient was discharged with a healthy baby girl.

## DISCUSSION

New-onset seizures, in the context of an unknown pregnancy, established the diagnosis of eclampsia in a patient with laboratory-confirmed HELLP syndrome resulting in a distinctly unusual presentation of PRES. PRES-induced brainstem areflexia and coma is a remarkable and unusual entity, representing one of the few rapidly reversible causes of catastrophic neurologic insult. HELLP syndrome has limited and non-specific neurologic findings, often with headache or blurred vision, similar to findings in eclampsia, making the distinction difficult without laboratory or radiographic evaluation.

This constellation of symptoms represents a neurologic emergency. Imaging in the form of a head CT most commonly reveals the development of vasogenic edema to support the diagnosis. The vasogenic edema is generally

### CPC-EM CAPSULE

What do we already know about this clinical entity?

*We know the clinical presentation of PRES, but rarely see complete, rapid resolution of all neurology symptoms in patients presenting comatose without brainstem reflexes.*

What makes this presentation of disease reportable?

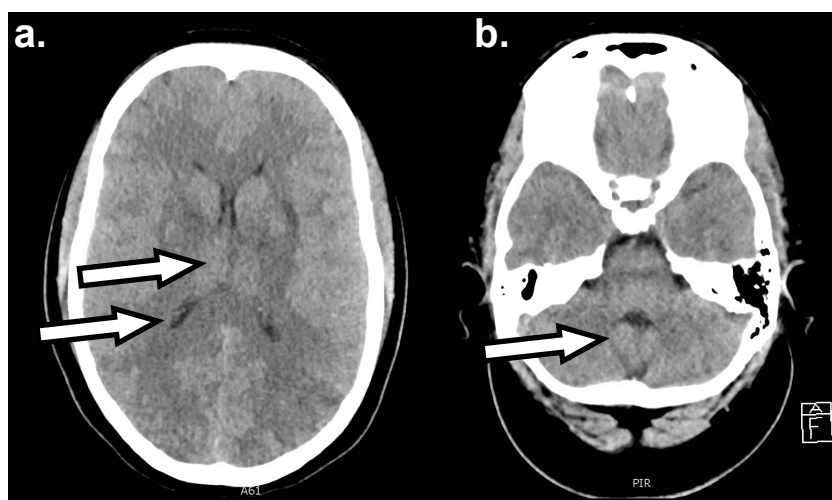
*This case is an unusual presentation of two potentially morbid conditions associated with pregnancy that need aggressive treatment stemming from rapid recognition.*

What is the major learning point?

*It supports aggressive treatments for this condition, as complete neurologic resolution is possible, as well as the use of other first line antihypertensive agents in pregnant patients.*

How might this improve emergency medicine practice?

*Further supports the notion in emergency medicine we need to think beyond a single diagnosis to explain all presentations, as occasionally 2 major pathologies present.*



**Image.** Image of computed topography of head, axial view. **a.** There is no midline shift. The lateral ventricles are extremely slender. This may reflect diffuse cerebral swelling. There are multiple areas of indistinctness surrounding the basal ganglia, putamen, and lateral thalami. **b.** The same findings in 'a' can be extended to this more caudal section. Note diffuse indistinctness of the sulci and slender ventricles.



found in the posterior white matter of the cerebral hemispheres and is frequently seen in the parieto-occipital lobes bilaterally; however, it has been reported throughout the brain.<sup>4,5</sup> Diffusion-weighted imaging is used to better differentiate between cytotoxic and vasogenic edema.

The neurologic findings associated with PRES can be directly attributed to the vasogenic edema found on head CT. Although the presence of vasogenic edema is well documented with PRES, the inciting pathophysiology remains disputed. Early postulates suggested that intense cerebral autoregulatory vasoconstriction occurs in response to acute elevations in blood pressure. This vasoconstriction leads to decreased cerebral blood flow and resultant ischemia, which in turn causes edema in the watershed arterial regions. More recently, investigators proposed that the marked hypertensive state leads to forced vasodilatation through failure of the cerebral autoregulatory system resulting in hydrostatic extravasations of fluid into the interstitium.<sup>2,4</sup>

While the pathophysiology of PRES remains controversial, there is a significant amount of literature detailing the multiple conditions that have been associated with the development of PRES. Most commonly, significant elevations in blood pressure are noted. Certain medications, especially cyclosporine, tacrolimus and other chemotherapeutic agents, have been associated with the development of PRES. Regardless of the etiology, the clinical prognosis is often excellent. Given appropriate supportive intensive care, control of hypertension, and removal of the offending agents, PRES is often completely reversible with minimal lasting neurologic deficits.<sup>6</sup> In the setting of eclampsia, parturition remains the definitive means to recovery.

## CONCLUSION

PRES in the setting of eclampsia is a well-established occurrence;<sup>5, 7-10</sup> however, concomitant HELLP syndrome and coma remains a rare entity. It is unlikely that the appropriate dose of benzodiazepenes to control the seizure onset contributed significantly to her obtunded state at presentation. Moreover, brainstem areflexia represents an extremely poor prognostic factor and may portend brain death.<sup>13</sup> Neurologic recovery in the face of such brain stem dysfunction is a truly exceptional event. It is important to recognize this condition clinically, as CT head imaging demonstrates only 40% correlate to magnetic resonance imaging (gold standard) when making this diagnosis, and CT is the imaging modality of choice in the emergency department.<sup>14</sup> Particularly interesting is the rapid and full clinical recovery within 30 hours from onset of encephalopathy leading to hospital discharge just six days after the initial presentation.

*Address for Correspondence:* Robert P. Zemple, MD, Carilion Clinic, Department of Emergency Medicine, 1916 Laura Rd NW, Roanoke, VA 24017. Email: bobzemple@gmail.com.

*Conflicts of Interest:* By the CPC-EM article submission agreement, all authors are required to disclose all affiliations, funding sources and financial or management relationships that could be perceived as potential sources of bias. The authors disclosed none.

*Copyright:* © 2017 Zemple et al. This is an open access article distributed in accordance with the terms of the Creative Commons Attribution (CC BY 4.0) License. See: <http://creativecommons.org/licenses/by/4.0/>

## REFERENCES

1. Hinchey J, Chaves C, Appignani B, et al. A reversible posterior leukoencephalopathy syndrome. *N Engl J Med.* 1996;334(26):494–500.
2. Lamy C, Oppenheim C, Mas JL. Posterior reversible encephalopathy syndrome. *Handb Clin Neurol.* 2014;121:1687-701.
3. Lee VH, Wijdicks EF, Manno EM et al. Clinical spectrum of reversible posterior leukoencephalopathy syndrome. *Arch Neurol.* 2008;65(2):205-10.
4. Yoon SD, Cho BM, OH SM, et al. Clinical and radiologic spectrum of posterior reversible encephalopathy syndrome. *J Cerebrovasc Endovasc Neurosurg.* 2013;15(3):206-13.
5. Brewer J, Owens MY, Wallace K, et al. Posterior reversible encephalopathy syndrome in 46 of 47 patients with eclampsia. *Am J Obstet Gynecol.* 2013;208(6):468.e1-6.
6. Legriel S, Schraub O, Azoulay E, et al. Determinants of recovery from severe posterior reversible encephalopathy syndrome. *PLoS One.* 2012;7(9):e44534.
7. Paul B, Juneja S, Paul G, et al. Spectrum of neurologic complications in HELLP syndrome. *Neurol India.* 2013;61(5):467-71.
8. Maggi G, Lombana VA, Marcos EA, et al. (2013). Posterior leukoencephalopathy syndrome: Postpartum focal neurologic deficits: A report of three cases and review of the literature. *Saudi J Anaesth.* 2013;7(2): 205-9.
9. Min Z, Gnann JW Jr. Reversible posterior encephalopathy syndrome. *Intern Emerg Med.* 2014;9:341-2.
10. Grossbach AJ, Abel TJ, Hodis B, et al. Hypertensive posterior reversible encephalopathy syndrome causing posterior fossa edema and hydrocephalus. *J Clin Neurosci.* 2014;21(2):207-11.
11. Keswani SC, Wityk R. Don't throw in the towel! A case of reversible coma. *J Neurol Neurosurg Psychiatry.* 2002;73(1):83-4.
12. Grzesuik AK, Melo R, Carvalho AR. HELLP Syndrome, reversible posterior leukoencephalopathy syndrome and eclampsia. *Arq*

*Neurosiquiatr.* 2009;67(4):1103-5.

13. Bernat JL, Lorincz M. Brain death. *Neurology Medlink*. Original Release 1994 May 9.
14. Dandoy CE, LL Linscott, SM Davies, et al. Clinical utility of computed

tomography and magnetic resonance imaging for diagnosis of posterior reversible encephalopathy syndrome after stem cell transplantation in children and adolescents. *Bio Blood Marrow Transplant.* 2015;21(11):2028-32.

# Life-threatening Vesicular Bronchial Injury Requiring Venovenous Extracorporeal Membrane Oxygenation Rescue in an Electronic Nicotine Delivery System User

Thomas Carter, DO\*†

Dalkeith Tucker, DO\*†

Ahmet Kilic, MD‡

Thomas J. Papadimos, MD, MPH§†

Andrew Barlow, DO\*†

Ellen Berry, BA¶

\*Ohio University Heritage College of Osteopathic Medicine, Department of Emergency Medicine, Portsmouth, Ohio

†Southern Ohio Medical Center, Department of Emergency Medicine, Portsmouth, OH

‡The Ohio State University Wexner Medical Center, Department of Cardiac Surgery, Columbus, Ohio

§The Ohio State University Wexner Medical Center, Department of Anesthesiology, Columbus, Ohio

¶Ohio University Heritage College of Osteopathic Medicine, Athens, Ohio

Section Editor: Rick A. McPheeters, DO

Submission history: Submitted November 16, 2016; Revision received February 24, 2017; Accepted March 10, 2017

Electronically published July 14, 2017

Full text available through open access at [http://escholarship.org/uc/uciem\\_cpem](http://escholarship.org/uc/uciem_cpem)

DOI: 10.5811/cpcem.2017.3.33171

The use of electronic nicotine delivery systems (ENDS) is increasing across the United States as tobacco bans increase and more people use these devices in an attempt to quit smoking. They are unregulated by the Food and Drug Administration, and there is significant concern that ENDS could produce several toxic byproducts.

In this case a 35-year-old female presented to the emergency department with sudden-onset dyspnea. She denied current tobacco smoking, but she was a user of ENDS. When bronchoscopy was performed, an extensive pattern of suspected chemical injury was noted in her airways. She required transfer to a tertiary center where she required extracorporeal membranous oxygenation.

Despite public opinion that ENDS are generally safe, or at least safer than tobacco smoking, contrary evidence is mounting. We postulate that her injuries were likely suffered secondary to use of an ENDS. [Clin Pract Cases Emerg Med.2017;1(3):212-217]

## INTRODUCTION

Electronic nicotine delivery systems (ENDS) are considered by many to be an alternative to conventional tobacco cigarettes. ENDS do not burn or use tobacco leaves but instead vaporize a solution that the user then inhales. They represent an array of battery-powered devices containing a cartridge with a liquid and an atomizer (vaporization chamber with a heating element).<sup>1</sup> The main constituents of the solution may include a variety of items, such as nicotine, propylene glycol, glycerol, and or flavoring agents.<sup>1</sup> The atomizer heats the liquid, forming a vapor that a person then inhales. ENDS' solutions and emissions after heating contain other chemicals,

some of them considered to be toxicants.<sup>2</sup> Open-system vaporizers are refillable with any solution, and e-cigarettes are cartridge based or disposable whereas the solution is purchased for that device alone. This use, termed "vaping," is increasing in popularity with poll estimates at about 10% of the United States (U.S.) population.<sup>3</sup> Open-system vaporizers and e-cigarettes are competing industries that generated more than 2.5 billion dollars in 2014.<sup>4</sup>

The industry is currently unregulated unless the e-cigarette is marketed for therapeutic purposes such as smoking cessation.<sup>5</sup> This has allowed the rapid expansion of proprietary blends and ad hoc recipes for different liquid nicotine

concentrations, flavors, and heating temperatures. Evidence is growing that toxicants and irritants are being vaporized and new chemical compounds are being inhaled through this process.<sup>6-9</sup> Here we present a life-threatening case of toxic inhalation of ENDS vapor that required a veno-venous extracorporeal membrane oxygenation (ECMO) rescue.

### CASE REPORT

A 35-year-old female presented to the emergency department via ambulance with a chief complaint of chest pain and dyspnea for two hours, described as constant in nature and sudden in onset. She could identify no precipitating events and was resting in bed when it started. The patient complained of severe pain in the back of her neck and left arm, which worsened with inhalation. She found nothing to relieve the symptoms and denied fever, chills, productive cough, leg pain, and lower extremity swelling.

Her medical history included coronary artery disease, uncontrolled diabetes mellitus type 2, obesity, deep vein thrombosis, dyslipidemia, gastroesophageal reflux, headaches, and hypertension. Her surgical history was significant for three-vessel coronary artery bypass grafting. Her medications and allergies were reviewed but not pertinent. The patient used caffeine daily and denied having ever used alcohol or recreational drugs. She reported on her last primary care visit to be a former smoker. Initial examination revealed tachycardia at 126 beats per minute, 18 labored respirations per minute, temperature of 98°F and blood pressure of 140/90 mmHg, and was 97% on 2 liters (L) of oxygen. Emergency medical services initiated their chest pain protocol as well as oxygen but did not obtain room air saturation. The patient was noted to be awake, alert, and oriented to person, place, and time, with an anxious affect. Head, ears, eyes, nose, and throat exam was unremarkable. Respiratory exam showed increased work of breathing with moderate distress, but no adventitious lung sounds. Cardiac auscultation revealed a regular rhythm, without murmur, rub, or gallop. Abdominal exam was notable for obesity but non-tender. Lower extremity exam revealed no edema or calf pain.

The patient was treated with aspirin, hydromorphone, ondansetron, diphenhydramine for itching, 2L per minute oxygen via nasal cannula, and 1L of normal saline bolus followed by 100 ml/hr continuous infusion. She was placed in the clinical decision unit and an extensive investigation was undertaken. Acute coronary syndrome, pulmonary emboli, and pneumonia led the differential diagnoses. The patient received a repeat dose of hydromorphone due to sustained pain. Her electrocardiogram (ECG) showed sinus tachycardia normal axis and nonspecific t-wave changes similar to prior. She was found to have an unchanged chest radiograph compared to two years prior with hyperlucent lungs, sternotomy wires, and vascular clips. Specifically, no pneumothorax, consolidations, vascular redistribution patterns, or pleural fluid were

### CPC-EM CAPSULE

What do we already know about this clinical entity?

*With rapid increase in use we have seen many complications of electronic nicotine delivery systems (ENDS); the cluster around catastrophic mechanical failure of the batteries and heating elements has dominated case reports and lay press accounts. This is the first that raises to clinicians the prospect of inhalational injury.*

What makes this presentation of disease reportable?

*With heavy use of ENDS this patient developed rapid, profound, non-inflammatory acute respiratory failure, and no underlying source of the injury was found until bronchoscopy showed vesicular disease in the airways.*

What is the major learning point?

*ENDS are not regulated unless they are for therapeutic use. Any combination of chemicals and ingredients, when repeatedly heated, can be more volatile and hence more likely to cause harm to tissue. Acute effects have the potential for comorbidity and mortality.*

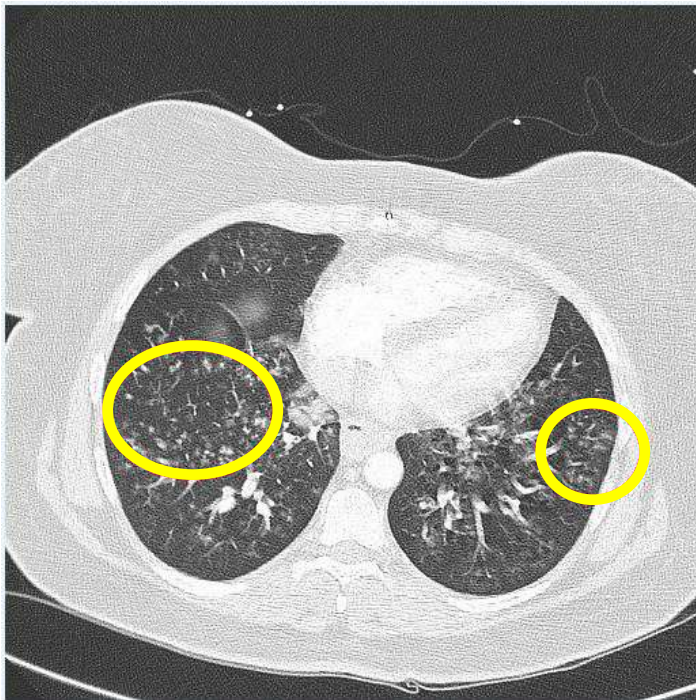
How might this improve emergency medicine practice?

*Clinicians should be aware of the potential for electronic nicotine delivery systems to deliver toxic compounds that could cause inhalational injury, independent of thermal or mechanical failure risk.*

identified. She had a normal complete blood count, procalcitonin, creatine kinase, and troponin. A measured glucose of 667 mg/dL with pseudohyponatremia 128mmol/L, chloride of 96 mmol/L, and her D-Dimer was noted to be slightly elevated. She received eight units of subcutaneous insulin and a second liter of normal saline.

A computed tomography (CT) angiogram of the chest was ordered to rule out pulmonary emboli. Before receiving the CT, the patient experienced a brief oxygen desaturation to 83% and was subsequently placed on a 5L per minute high-flow oxygen mask. During the CT, she was slightly confused and refused to lie flat. She then experienced several episodes





**Image 1:** Computed tomography of the lower lung and heart with demonstration of nodular infiltrates at the lung bases, which are circled.

of desaturation and at that point was requiring 12L per minute on a high-flow oxygen mask to maintain 90% saturation by pulse oximetry. After completing the CT, the patient had an arterial blood gas performed to clarify the extent of her hypoxia. Her pH was 7.42, PaCO<sub>2</sub> 36 mmHg, PaO<sub>2</sub> 50 mmHg, and HCO<sub>3</sub> 23 mEq/L. methemoglobin was 0.4% and carboxyhemoglobin was 1.1%. Arterial lactate was 2.4 mmol/L. Biphasic positive airway pressure (BIPAP) support was initiated in an attempt to supplement the patient's respiratory efforts and prevent intubation.

The CT was reported with nodular infiltrates centered in the lower lung zones (Image 1) with some confluence at the lung bases not previously seen on chest radiograph. Mediastinal adenopathy not previously seen on CT from two years prior and a nodular thickening of the hila were also noted. In addition, there was a 1.5 x 1.5 cm collection of hypodense fluid and loss of distinction in the cortex of the right kidney suggestive of trauma.

A broader history was elicited from the patient and husband to discern a possible infectious or inflammatory etiology of the observed lower respiratory pneumonitis/ inhalational injury pattern. The patient and her spouse denied trauma, fever, "huffing" paint, methamphetamine use or production, bonfires, and open fires at home. The husband interjected with commentary on the patient's heavy use of ENDS. The patient admitted to daily use of two refill

containers she knew to be 2.5%/ml or 25mg/ml in nicotine concentration, which she believed was equal to a pack of cigarettes. The husband was unable to identify the single refill product that was the most recently used at home, and the patient had three different ENDS.

The patient was transferred to the intensive care unit (ICU) and upon arrival she was noted to have extensive rales, with notable work of breathing that caused truncated speech. The patient tolerated the BIPAP well, but became increasingly dyspneic despite pressure support from the BIPAP. Her increased work of breathing and impending respiratory failure urged endotracheal intubation and mechanical ventilation. A bronchoscopy was performed that demonstrated erythema of the tracheal tissues extending to the carina that appeared cobblestoned and/or leathery. The main bronchi had a yellow, vesicular appearance with interspersed erythema and increased friability of the tissue. The right mainstem bronchus and remaining airways had a rust-colored appearance along with erythema extending into the visible lower airways (Image 2). The pattern was postulated to be inhalational injury by pulmonary medicine.

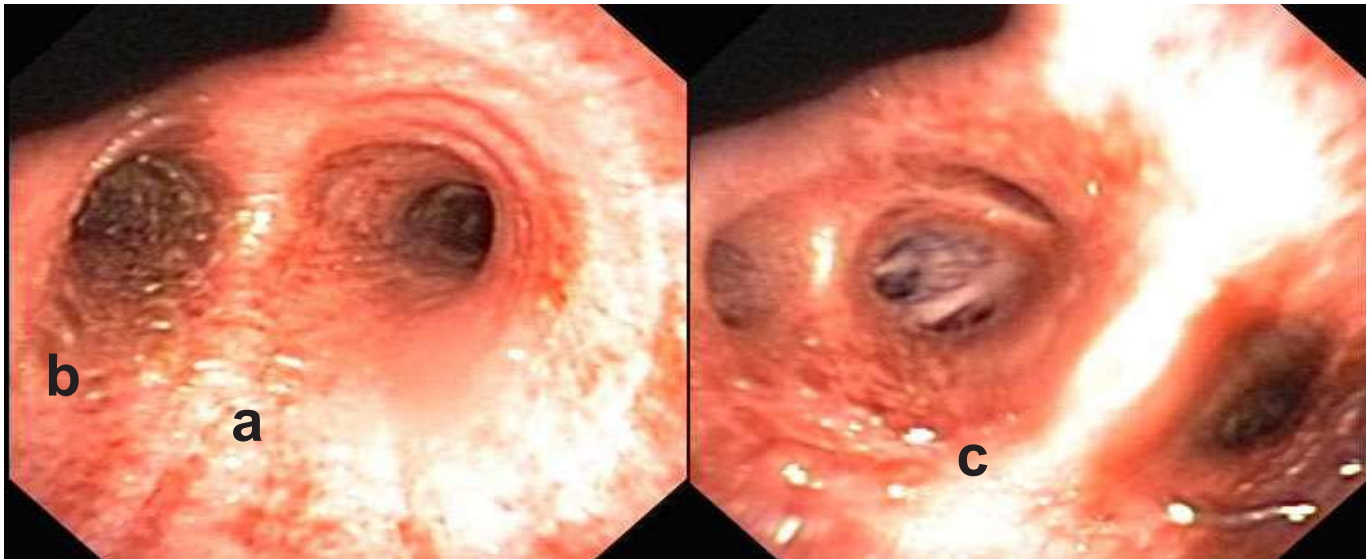
Upon ICU admission the patient was treated empirically for bacterial pneumonia with meropenem levofloxacin and vancomycin. The right lower lobe bronchial alveolar lavage culture resulted in heavy growth of methicillin-resistant *Staphylococcus aureus* (MRSA) 48 hours after admission. Her urine culture was positive for *Escherichia coli*.

The patient continued to decline over the next 48 hours. She was transferred to a tertiary care center for possible ECMO, burn expertise, and continued intensive care.

Upon arrival to the tertiary care center, she was persistently hypoxemic and failed a trial of mechanical ventilation with inhaled epoprostenol. Repeat bronchoscopy was performed showing persistent vesicular injury pattern (Image 3). She underwent emergent placement of veno-venous ECMO. She was stabilized and subsequent examinations showed a left hemiparesis. The neurologic insult was diffuse on magnetic resonance imaging and read as hypoxic, toxic and or metabolic insult. She improved on ECMO, eventually receiving a tracheostomy, which was decannulated 14 days later. She was returned to the long-term rehabilitation unit at the initial treatment center. There she progressed well, where she was ambulating with an assist device and made significant progress toward an independent return to home.

## DISCUSSION

Previous research has shown that ENDS are capable of heating their liquid nicotine solutions to a temperature of 350°C. At this temperature the compounds that make up the solvents for the nicotine solution, mostly glycerin and propylene glycol, undergo chemical conversion/breakdown to several low molecular-weight carbon compounds including formaldehyde, acetaldehyde, acetone, acrolein, propanal,

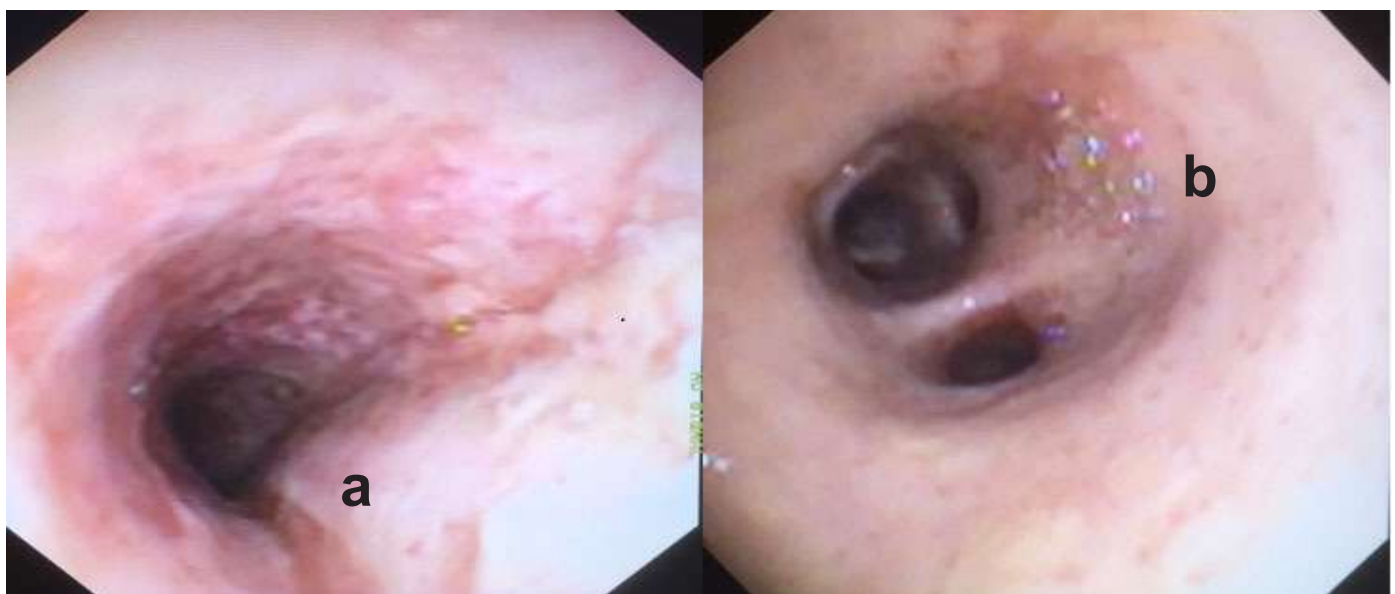


**Image 2.** Bronchoscopy images of the (a) carina appearance of cobblestones or leathery (b) the left mainstem bronchus with yellow vesicles; (c) the right lower lobe bronchus with rust-colored appearance along with erythema extending into the visible lower airways.

butanal, glyoxal, and methylglyoxal.<sup>10</sup> Several government organizations have commented on the toxicity of these compounds. The U.S. Environmental Protection Agency recognizes acrolein, formaldehyde, and acetaldehyde as pulmonary irritants. Formaldehyde is also considered a probable carcinogen, and acetaldehyde is known to potentially cause necrosis of living tissues at high enough doses.<sup>11-13</sup> The Canadian Center for Occupational Health and Safety recognizes acetone as an inhalational irritant.<sup>14</sup> According to

the National Institute of Health, butanal is capable of causing toxic pneumonitis, propanal can cause pulmonary edema, and methylglyoxal is a known respiratory irritant.<sup>15-17</sup> Basic chemistry principles dictate that the more these compounds are heated, the more volatile and reactive they become.

This has caused such concern that the American Association for Cancer Research, the American Society of Clinical Oncology, and the American College of Physicians have published policy positions against ENDS use.<sup>18,19</sup> In fact,



**Image 3.** Repeat bronchoscopy images after 48 hours of intensive care ventilation and pulmonary suctioning (a) extensive cobblestone appearance persisted in the carina, and (b) persistent vesicant injury pattern in the right lower bronchus.



the World Health Organization has been uncompromising in its view and has called upon all countries to be restrictive in precautionary measures and to ban advertising.<sup>20</sup> The Cochrane Review has yet to find any definitive risk associated with ENDS use.<sup>21</sup> The health science community, in regard to ENDS, has now started to voice more concern about the perils of these devices and their effects on children, the general health of adults, whether they truly help ameliorate nicotine addiction, and whether counseling is in order for users.<sup>22-2</sup>

We postulate that our patient suffered her injuries due to repeated heavy use of these high-temperature vaporizers and the toxic byproducts produced by their use. This case has significant limitations to assert this conclusion. It lacks definitive diagnosis and is devoid a tissue biopsy to confirm toxic substances via liquid chromatography. This technology was unavailable at the community hospital where the patient presented. Uncertainty would remain, however, without persistent toxin present. In living tissue, chemical reactions would continuously reduce the amount of detectable toxin that potentially caused the insult. On repeat bronchoscopy persistent vesicular injury provided some conformation bias and subsequent clinicians did not perform tissue biopsy, due to continued appearance of an inhalational pattern with lower lobe predominance. A biopsy of the tissue with or without liquid chromatography may have elucidated a different diagnosis.

Further confounding the case, the patient had two positive cultures; however, a positive culture without signs of systemic or overwhelming infection would be rare in a MRSA pneumonia. An absence of a metabolic acidosis makes overwhelming infection even less likely. Sudden severe hypoxia is more likely to be from more common disease such as pulmonary embolus, congestive heart failure, or pulmonary hypertension, each of which was excluded in the initial evaluation. Lastly, spectrum bias infers this is a rare, very susceptible, individual patient who has multiple comorbid illnesses at a relatively young age, and is not representative of the general population. We felt the appearance, severity and course of disease were not representative of progression of any of the patient co-morbid diseases.

## CONCLUSION

In conclusion, with the use of ENDS, it is reasonable to assume that more cases like the one discussed above will be seen in emergency departments around the country. The fact that these devices and their compounds are currently unregulated by the Food and Drug Administration means that proprietary blends of these compounds can consist of many different flavoring substances in addition to the primary solvents discussed above. Given the high temperature to which these compounds are heated to induce vaporization, the nature and number of different byproducts can vary widely. As physicians, our line of questioning should specifically address the use of these devices by our patients.

*Address for Correspondence:* Thomas Carter, DO, Ohio University Heritage College of Osteopathic Medicine, 1735 27th Street Waller Bldg., Suite B-06, Portsmouth, OH 45662. Email: thomasecarter@gmail.com.

*Conflicts of Interest:* By the CPC-EM article submission agreement, all authors are required to disclose all affiliations, funding sources and financial or management relationships that could be perceived as potential sources of bias. The authors disclosed none.

*Copyright:* © 2017 Carter et al. This is an open access article distributed in accordance with the terms of the Creative Commons Attribution (CC BY 4.0) License. See: <http://creativecommons.org/licenses/by/4.0/>

## REFERENCES

1. WHO | Electronic cigarettes (e-cigarettes) or electronic nicotine delivery systems. WHO. Available at: [http://www.who.int/tobacco/communications/statements/electronic\\_cigarettes/en/](http://www.who.int/tobacco/communications/statements/electronic_cigarettes/en/). Accessed July 10, 2015.
2. Furber A. Electronic cigarettes: reasons to be cautious. *Thorax*. 2015;70(4):307-8.
3. E-cigarette usage surges in past year: Reuters/Ipsos poll. *Reuters*. Available at: <http://www.reuters.com/article/2015/06/10/us-usa-ecigarette-poll-analysis-idUSKBN0Q0CA20150610>. Published June 10, 2015. Accessed July 10, 2015.
4. Esterl M. Big Tobacco's E-Cigarette Push Gets a Reality Check. *Wall Street Journal*. Available at: <http://www.wsj.com/articles/big-tobaccos-e-cig-push-gets-a-reality-check-1409078319>. Published August 26, 2014. Accessed July 10, 2015.
5. Products C for T. Public Health Focus - Electronic Cigarettes (e-Cigarettes). Available at: <http://www.fda.gov/NewsEvents/PublicHealthFocus/ucm172906.htm>. Accessed July 10, 2015.
6. Hutzler C, Paschke M, Kruschinski S, et al. Chemical hazards present in liquids and vapors of electronic cigarettes. *Arch Toxicol*. 2014;88(7):1295-1308.
7. Jensen RP, Luo W, Pankow JF, Strongin RM, et al. Hidden formaldehyde in e-cigarette aerosols. *N Engl J Med*. 2015;372(4):392-4.
8. McAuley TR, Hopke PK, Zhao J, Babaian S. Comparison of the effects of e-cigarette vapor and cigarette smoke on indoor air quality. *Inhal Toxicol*. 2012;24(12):850-7.
9. Varlet V, Farsalinos K, Augsburger M, et al. Toxicity assessment of refill liquids for electronic cigarettes. *Int J Environ Res Public Health*. 2015;12(5):4796-815.
10. Kosmider L, Sobczak A, Fik M. Carbonyl compounds in electronic cigarette vapors: effects of nicotine solvent and battery output voltage. *Nicotine Tob Res*. 2015;16(10):1319-26.
11. Acrolein. *EPATechnology Transf Netw-Air Toxics Web Site*.

- September 2009. Available at: <http://www.epa.gov/ttnatw01/hlthef/acrolein.html>.
12. Formaldehyde. *EPATechnology Transf Netw-Air Toxics Web Site*. January 2000. Available at: <http://www.epa.gov/ttnatw01/hlthef/formalde.html>.
  13. Acetaldehyde. *EPATechnology Transf Netw-Air Toxics Web Site*. January 2000. Available at: <http://www.epa.gov/ttnatw01/hlthef/acetalde.html>.
  14. Acetone. *Can Cent Occup Health Saf-OSH Fact Sheet*. July 2015. Available at: [http://www.ccohs.ca/oshanswers/chemicals/chem\\_profiles/acetone.html](http://www.ccohs.ca/oshanswers/chemicals/chem_profiles/acetone.html).
  15. Butyraldehyde. *Natl Libr Med Inst Health Haz-Map*. February 2015. Available at: <http://hazmap.nlm.nih.gov/category-details?table=copytblagents&id=96>.
  16. Propionaldehyde. *Natl Libr Med Inst Health Haz-Map*. February 2015. Available at: <http://hazmap.nlm.nih.gov/category-details?id=102&table=copytblagents>.
  17. Methylglyoxal/Pyruvaldehyde. *Natl Libr Med Inst Health Haz-Map*. February 2015. Available at: <http://hazmap.nlm.nih.gov/category-details?id=6108&table=copytblagents>.
  18. Brandon TH, Goniewicz ML, Hanna NH, et al. Electronic nicotine delivery systems: a policy statement from the American Association for Cancer Research and the American Society of Clinical Oncology. *J Clin Oncol*. 2015;33(8):952-63.
  19. Crowley RA. Electronic nicotine delivery systems: executive summary of a policy position paper from the American College of Physicians. *Ann Intern Med*. 2015;162(8):583.
  20. Zhu S-H, Sun JY, Bonnevie E, et al. Four hundred and sixty brands of e-cigarettes and counting: implications for product regulation. *Tob Control*. 2014;23(Supplement 3):iii3-iii9.
  21. Fairchild AL, Bayer R. Public health. Smoke and fire over e-cigarettes. *Science*. 2015;347(6220):375-6.
  22. Collaco JM, Drummond MB, McGrath-Morrow SA. Electronic cigarette use and exposure in the pediatric population. *JAMA Pediatr*. 2015;169(2):177.
  23. Pisinger C. Why public health people are more worried than excited over e-cigarettes. *BMC Med*. 2014;12(1):226.
  24. Rom O, Pecorelli A, Valacchi G, et al. Are E-cigarettes a safe and good alternative to cigarette smoking?: E-cigarettes: pros and cons. *Ann N Y Acad Sci*. 2015;1340(1):65-74.
  25. Galandiuk S. E-cigarettes: an asset or liability in efforts to lessen tobacco smoking and its consequences. *Mayo Clin Proc*. 2015;90(1):1-3.



# Hematometrocolpos in a Pubescent Girl with Abdominal Pain

Haleigh C. Kotter, MD  
Daniel Weingrow, MD  
Caleb P. Canders, MD

UCLA Medical Center, Department of Emergency Medicine, Los Angeles, California

Section Editor: Rick A. McPheeters, DO

Submission history: Submitted December 17, 2017; Revision received March 12, 2017; Accepted March 30, 2017

Electronically published July 6, 2017

Full text available through open access at [http://escholarship.org/uc/uciem\\_cpem](http://escholarship.org/uc/uciem_cpem)

DOI: 10.5811/cpem.2017.3.33369

Hematometrocolpos is a rare congenital abnormality of the female urogenital system that leads to an imperforate hymen and subsequent retrograde menstruation. We present the case of a 14-year-old female patient who presented to the emergency department with amenorrhea and abdominal pain, and was found to have an imperforate hymen and hematometrocolpos on transabdominal point-of-care ultrasound. It is important for emergency physicians to consider this diagnosis in pubescent female patients presenting with abdominal pain, as missed diagnosis can lead to infertility and other complications. [Clin Pract Cases Emerg Med. 2017;1(3):218–220.]

---

## INTRODUCTION

Hematometrocolpos is a rare congenital abnormality that is infrequently diagnosed in the emergency department (ED). The hymen, which is part of the urogenital sinus, fails to perforate during genitourinary development in approximately one in 2,000 females.<sup>1-2</sup> Patients subsequently develop retrograde menstruation and hematometrocolpos. The classic presentation of hematometrocolpos is a pubescent female who presents with episodic, cramping lower abdominal and pelvic pain. We present the case of a young female patient who presented with abdominal pain and vomiting, and was found to have hematometrocolpos complicated by hydronephrosis bilaterally on transabdominal point-of-care ultrasound (POCUS). Emergency physicians should consider imperforate hymen with hematometrocolpos in the differential diagnosis of pelvic pain in young female patients, as physical exam and POCUS can lead to rapid diagnosis and treatment and prevent complications of the disease, including infertility.

## CASE REPORT

A 14-year-old female patient presented to the ED with intermittent lower abdominal pain for three weeks. Her pain was bilateral and cramping, with episodes of intense worsening that were associated with non-bloody, non-bilious emesis. She reported abdominal distension, constipation, and breast tenderness, and denied urinary changes, vaginal bleeding, or

discharge. She had not yet experienced menarche and she denied sexual activity. The patient had seen her pediatrician at symptom onset, and it was documented that the patient had Tanner Stage IV development but no menstruation. No genitourinary exam had been performed. At that visit, the patient was diagnosed with constipation and counseled on diet changes. Two weeks later, the patient returned to her pediatrician for the same symptoms, and an outpatient transabdominal US was ordered to evaluate her pelvic organs. Her pain worsened prior to her scheduled US, so she presented to the ED.

The patient was afebrile with a pulse of 105 beats per minute, blood pressure of 125/91 mmHg, respiratory rate of 18 breaths per minute, and oxygen saturation of 100%. She was actively vomiting and reporting abdominal pain. Abdominal examination was notable for mild distension, suprapubic tenderness, and a palpable mass in the lower abdomen and pelvis. Bowel sounds were normal. Pelvic examination was notable for a bulging, tense, blue, imperforate hymen. Transabdominal POCUS showed a distended vaginal canal, markedly enlarged uterus, and moderate hydronephrosis bilaterally (Video). Renal function was normal on a chemistry panel. She was diagnosed with hematometrocolpos, and gynecology was consulted. The patient was taken to the operating room for hymenectomy, which drained 900 mL of dark brown fluid. She recovered without complication and had normal menstruation one month later.

## DISCUSSION

While rare, imperforate hymen and hematometrocolpos are important diagnoses to consider in pubescent females who have not yet menstruated and present with abdominal pain. Patients with this congenital abnormality are typically asymptomatic until menarche. Most patients present symptomatic during menstruation, as the retained blood and endometrial tissue accumulates and distends the vaginal canal (hematocolpos), uterus (hematometra), or both (hematometrocolpos). Patients commonly present with abdominal pain, pelvic pain, and vomiting. Less common symptoms include back pain, constipation, urinary retention, or urinary incontinence.<sup>2-4</sup> Physical exam findings of hematometrocolpos include a palpable pelvic mass and a bulging hymen, which is often blue or white in appearance.

Ultrasonography is the preferred imaging modality to evaluate for hematometrocolpos, given that it is rapidly performed at the bedside and does not expose the patient to radiation. Transabdominal POCUS typically reveals a large, hypoechoic mass with smooth walls just posterior to the bladder. Depending on the extent of dilation of the pelvic organs, the uterus may appear normal or be dilated. The blood and endometrial tissue within the uterus appears hypoechoic.<sup>3,5</sup> In the case of hematometrocolpos, the volume of fluid can be measured to assist the surgical team in preparation for operation. POCUS can also be used to assess for complications of hematometrocolpos, including hydronephrosis (due to compressive effects of the fluid collection) and free fluid in the abdomen from uterine perforation.

Treatment of imperforate hymen consists of surgical repair, ideally after the tissues have undergone estrogen stimulation. An elliptical incision is made in the membrane adjacent to the hymenal ring, followed by evacuation of the blood and tissue. Redundant hymenal tissue is also removed. If the diagnosis of hematometrocolpos is missed or delayed, patients may develop retrograde menstruation, endometriosis, pelvic adhesions, fallopian tube damage, and infertility.<sup>3,6</sup>

## CONCLUSION

Hematometrocolpos is a rare congenital abnormality of the female urogenital system that leads to an imperforate hymen and subsequent retrograde menstruation. Complications of hematometrocolpos include abdominal and pelvic pain, hydronephrosis from extrinsic compression of the ureters, and infertility. It is therefore important to consider the diagnosis of hematometrocolpos in young female patients presenting with abdominal pain, which can be confirmed by examination and transabdominal POCUS.

### *CPC-EM Capsule*

What do we already know about this clinical entity?

*Hematometrocolpos is caused by an imperforate hymen and subsequent retrograde menstruation. It presents in young women and can have damaging consequences.*

What makes this presentation of disease reportable?

*Imperforate hymen is a congenital abnormality that is rarely seen in the emergency department. In this case, the diagnosis was made with thorough physical examination and point-of-care ultrasound (POCUS).*

What is the major learning point?

*Consider the diagnosis of hematometrocolpos in pubescent women with abdominal pain who have the appropriate findings on exam and POCUS.*

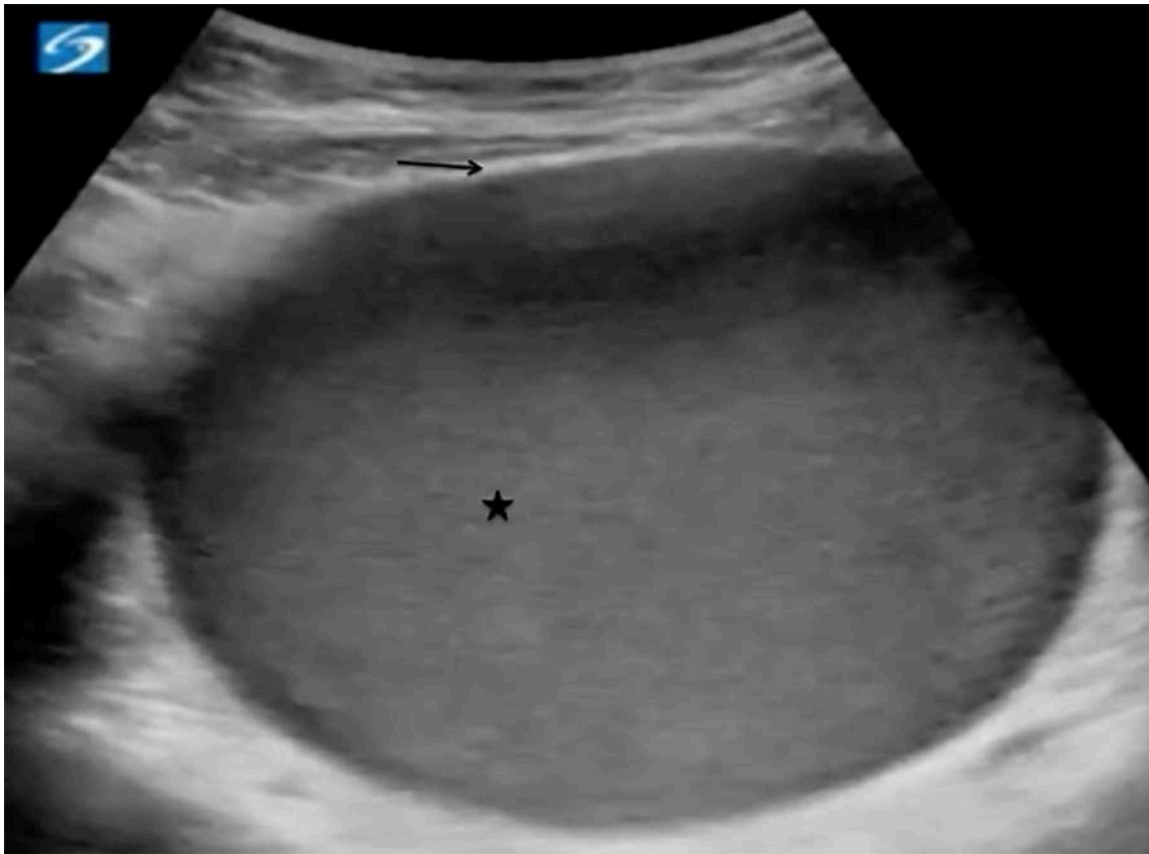
How might this improve emergency medicine practice?

*Early suspicion and confirmation of hematometrocolpos can lead to early treatment, preventing unnecessary pain and complications, including infertility.*

*Address for Correspondence:* Caleb P. Canders, MD, Department of Emergency Medicine, David Geffen School of Medicine at UCLA, 924 Westwood Boulevard, Suite 300 | Box 951777, Los Angeles, CA 90095-1777. Email: ccanders@mednet.ucla.edu.

*Conflicts of Interest:* By the CPC-EM article submission agreement, all authors are required to disclose all affiliations, funding sources and financial or management relationships that could be perceived as potential sources of bias. The authors disclosed none.

*Copyright:* © 2017 Canders et al. This is an open access article distributed in accordance with the terms of the Creative Commons Attribution (CC BY 4.0) License. See: <http://creativecommons.org/licenses/by/4.0/>



**Image.** Transabdominal point-of-care ultrasound in transverse view showing a distended uterus measuring 6.0 x 4.4 x 6.8cm and containing hypoechoic blood and endometrial tissue (star), consistent with hematometrocolpos. Internal echotexture of the blood and tissue can be variable, and low-level echoes may be seen. The uterine wall appears hyperechoic (arrow).

**Video.** Bedside ultrasound showing a distended uterus measuring 6.0 x 4.4 x 6.8cm and containing hypoechoic blood and endometrial tissue, consistent with hematometrocolpos.

## REFERENCES

1. Parazzini F, Cecchetti G. The frequency of imperforate hymen in northern Italy. *Int J Epidemiol.* 1990;19(3):763-4.
2. Gyimadu A, Sayal B, Guven S, et al. Hematocolpos causing severe urinary retention in an adolescent girl with imperforate hymen: an uncommon presentation. *Arch Gynecol Obstet.* 2009;280(3):461-3.
3. Drakonaki E, Tritou I, Pitsoulis G, et al. Hematocolpometra due to an imperforate hymen presenting with back pain: sonographic diagnosis. *J Ultrasound Med.* 2010;29(2):321-2.
4. Lollgen RM, Sabo J, Mettler A, et al. Unique Presentation of Hematometrocolpos Mimicking Cauda Equina Syndrome: Severe Back Pain and Urinary Incontinence in an Adolescent Girl. *J Emerg Med.* 2016;51(2):e19-23.
5. Kloss BT, Nacca NE, Cantor RM. Hematocolpos secondary to imperforate hymen. *Int J Emerg Med.* 2010;3(4):481-2.
6. Wall EM, Stone B, Klein BL. Imperforate hymen: a not-so-hidden diagnosis. *Am J Emerg Med.* 2003;21(3):249-50.

# Testicular Rupture: A Tough Nut to Crack

**Tyler L. Holliday, MD\***  
**Kristine S. Robinson, MD†**  
**Nicole Dorinzi, MD†**  
**Andrew W. Vucelik, MD†**  
**Erin L. Setzer, MD†**  
**Debra L. Williams, MS†**  
**Melinda J. Sharon, MPH†**  
**Joseph J. Minardi, MD†**

\*West Virginia University, School of Medicine, Morgantown, West Virginia

†West Virginia University, Department of Emergency Medicine, Morgantown, West Virginia

Section Editor: Rick A. McPheeters, DO

Submission history: Submitted December 16, 2016; Revision received March 8, 2017; Accepted March 29, 2017

Electronically published July 6, 2017

Full text available through open access at [http://escholarship.org/uc/uciem\\_cpem](http://escholarship.org/uc/uciem_cpem)

DOI: 10.5811/cpem.2017.3.33348

Blunt scrotal injury represents a diagnostic dilemma for emergency physicians (EP). Consequently, point-of-care ultrasound (POCUS) has emerged as a tool for early investigation of the acute scrotum in the emergency department. We describe a case where an EP used scrotal POCUS to immediately visualize the loss of testicular contour and underlying heterogeneous parenchyma to rapidly make the diagnosis of testicular rupture in a young male presenting with scrotal trauma. The use of POCUS in this case expedited therapy, likely improving the patient's outcome. To our knowledge, this is the first detailed description of testicular rupture diagnosed with POCUS by an EP. [Clin Pract Cases Emerg Med. 2017;1(3):221–224.]

---

## INTRODUCTION

Acute scrotal pain is a common complaint in the emergency department (ED).<sup>1,2</sup> Etiologies of the acute scrotum include testicular torsion, infection, and trauma. The majority of traumatic injuries are blunt impacts, most commonly in adolescents and young adults.<sup>2-4</sup> Evaluation of these patients poses a significant challenge, as history and physical examination findings are often equivocal. Thus, point-of-care ultrasound (POCUS) has increasingly been used for early investigation of the acute scrotum.<sup>1</sup> Many studies have shown scrotal US to be fast and reliable in differentiating a broad range of time-sensitive pathologies, including testicular torsion, fracture, and rupture, as well as differentiating surgical and non-surgical emergencies where delays in care may lead to poor outcomes.<sup>1,3,4-7</sup> However, the use of POCUS in these patients by emergency physicians (EP) is limited to a single case series from 2001.<sup>1</sup> We present a case of testicular rupture diagnosed by an EP using scrotal POCUS that led to expedited care and surgical intervention.

## CASE REPORT

An 18-year-old male presented to the ED with left testicular pain and swelling following blunt scrotal trauma sustained during a wrestling match. The pain was immediate, but did not necessitate removal from play. Post-injury, the pain progressed, prompting presentation to our ED. The patient denied dysuria, hematuria, or any other symptoms. Past medical and surgical histories were unremarkable. Vital signs were normal. On physical examination, the left testis was tender to palpation, grossly swollen, and tense compared to the right. The remaining physical examination, including abdominal exam, was unremarkable.

Scrotal POCUS was carried out by the EP using a Sonosite Edge system using an L13-6 linear transducer operating at 10 MHz. Sagittal and transverse images of the affected testis along with comparison views of the unaffected side were obtained. Analysis with color and spectral Doppler was performed. The left testis was enlarged with a grossly heterogeneous texture as seen in Image 1 and the Supplemental Video. Discontinuity of the tunica albuginea and irregularity of the testicular margins



were noted as seen in Image 2 and the Supplemental Video. Additionally, a hypoechoic complex fluid collection consistent with hematocele was present in the left hemiscrotum, and blood flow was not uniformly identified throughout the left testis. The left epididymis was unremarkable. The right testis appeared normal with homogenous parenchyma, intact tunica albuginea, smooth, preserved borders, and uniform distribution of blood flow throughout by color Doppler analysis (seen in Image 1, panel A, Supplemental Video). No fluid collection was observed within the right hemiscrotum and the right epididymis was unremarkable. A rapid diagnosis of left testicular rupture was made in the ED, and urology was consulted.

The patient was taken to the operating room for scrotal exploration. The left testis was found to be fractured, without viability of the lower segment. All nonviable tissue was removed, and bleeding was controlled. The upper pole was preserved, the tunica albuginea and vaginalis were re-approximated, and the scrotum was closed. The patient was admitted overnight for observation and discharged the following morning. At six-week follow-up, the patient had returned to normal activity.

**DISCUSSION**

Blunt trauma to the scrotum may result in a number of injuries, including hematocele, testicular fracture, and testicular rupture. Typically, these patients will present with non-specific symptoms, such as scrotal swelling and severe pain, which often make physical examination difficult to perform. Historically, blunt scrotal traumas were managed non-operatively, with surgical exploration reserved for cases with resulting complications. Higher rates of adverse outcomes (impaired fertility, hypogonadism, testicular loss) were associated with this delay in care.<sup>8</sup> In the case of testicular rupture, salvage rates are as high as 90% when surgery is performed within 72 hours. When surgical intervention is delayed beyond 72 hours, salvage rates

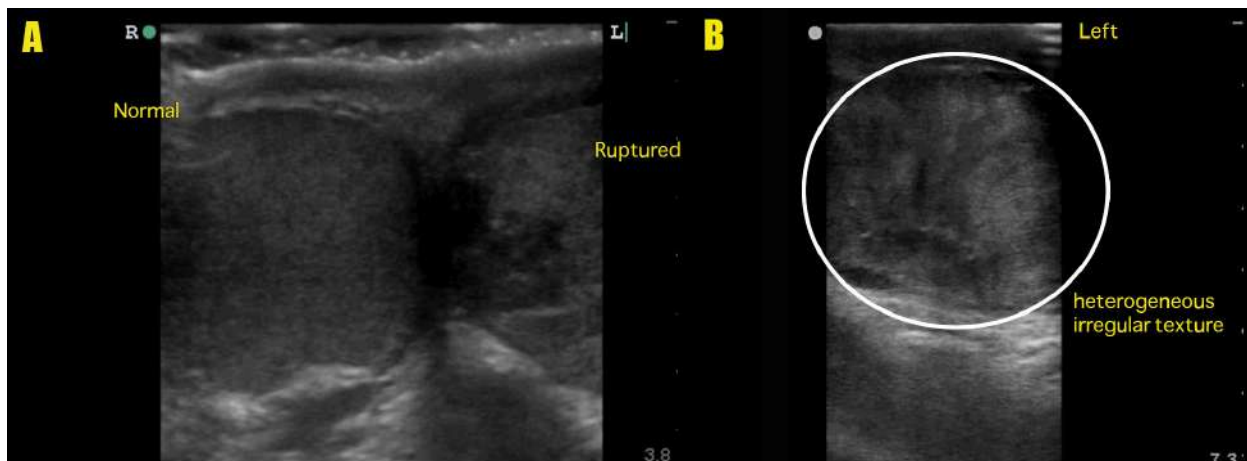
*CPC-EM Capsule*

What do we already know about this clinical entity?  
*Injuries from blunt scrotal trauma are difficult to diagnose. Ultrasound is the preferred imaging modality to visualize scrotal pathologies and differentiate surgical and non-surgical diagnoses.*

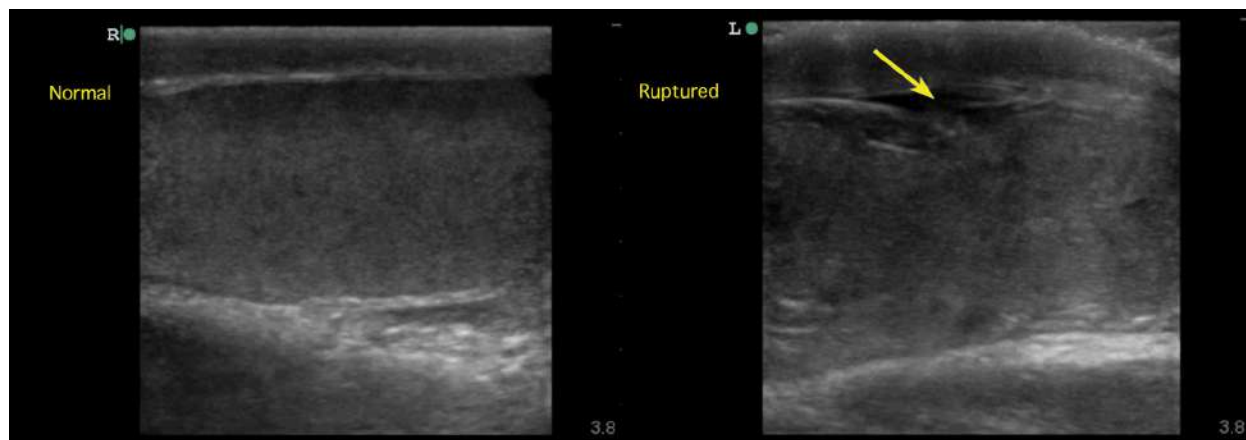
What makes this presentation of disease reportable?  
*To our knowledge, this is the first detailed description of testicular rupture diagnosed with point-of-care ultrasound (POCUS) by an emergency physician (EP).*

What is the major learning point?  
*The findings of testicular rupture, including loss of tunica albuginea integrity and testicular heterogeneity can be identified sonographically by EPs in a rapid fashion. Rapid recognition of these findings can influence timing of consultation and expedite surgery, which should improve outcomes.*

How might this improve emergency medicine practice?  
*Rapidly recognizing and/or excluding the findings of testicular rupture can decrease the need for consultative imaging, expedite definitive management and streamline patient care.*



**Image 1.** A: Side-by-side comparison of right and left testicles demonstrating normal right testis with homogenous parenchyma, intact tunica albuginea, and preserved testicular contour and ruptured left testis with heterogeneous parenchyma. B: Ruptured left testis. Long-axis view demonstrating heterogeneous irregular parenchyma (circle).



**Image 2.** Long-axis comparison of normal and ruptured testicles. Right image demonstrates a normal testis with homogeneous parenchyma, intact tunica albuginea, and preserved testicular contour. Left image demonstrates testicular rupture with findings of heterogeneous parenchyma, discontinuity of tunica albuginea (arrow), and abnormal testicular contour.

decline to approximately 45%.<sup>9</sup>

US has emerged as the preferred modality for examining the acute scrotum. It can be rapidly employed to provide high quality imaging that can accurately guide clinical decisions and differentiate surgical from non-surgical pathologies. Scrotal POCUS, in the hands of an EP, provides an opportunity to reduce time to diagnosis and reduce dependence on sonographers and radiology departments, which may not be available at all hours. EPs with significant US experience, even in the absence of formal testicular US training, are highly accurate in diagnosing scrotal pathologies.<sup>1</sup>

Ultrasonic imaging of the scrotum should be undertaken with a high-frequency (7-12MHz) linear transducer. The scrotum should be supported by a towel placed between adducted thighs with the penis displaced away from the scrotum. The hand holding the transducer should be supported against the thigh and a generous amount of gel should be used in order to provide adequate acoustic contact between the scrotum and transducer. Each testis should be visualized in multiple planes of the long and short axes with and without color Doppler. If one structure is abnormal, the contralateral side should be used to calibrate the grayscale and color Doppler gain settings for examination of the symptomatic testicle.<sup>9</sup>

Using ultrasonography, a normal post-pubertal testis should appear as a homogeneous ovoid structure of medium echogenicity measuring approximately 5x3x2cm. The tunica albuginea surrounds the testis and appears as a thin echogenic band. The epididymis should appear as a long, tapering tubular structure bordering the posterior aspect of the testis. Typically, the epididymis is isoechoic to hyperechoic and homogeneous.<sup>4,9</sup>

With scrotal POCUS, hematocele, testicular fracture, and testicular rupture can be quickly identified and treated in patients reporting to the ED with blunt scrotal trauma. Hematoceles appear as extratesticular fluid collections of increased

echogenicity acutely after traumas but become hypoechoic and septated over time.<sup>4,9</sup> Surgical management is recommended for large (>5 cm) or expanding hematoceles. Otherwise, conservative management is recommended.<sup>10</sup> Testicular fracture is identified by a linear hypoechoic band that divides the testicular parenchyma within an intact tunica albuginea. If blood flow is preserved, the fractures are treated conservatively (scrotal support, NSAIDs, ice packs, bed rest, and serial ultrasounds). If the segment is avascular, emergent surgical intervention is necessitated.<sup>3,4,10</sup> Testicular rupture is identified by loss of testicular contour with underlying heterogeneity of the parenchyma. Diagnosis requires emergent surgery to preserve testicular function.<sup>2,4,6,7</sup>

The accuracy of US for the evaluation of these pathologies has been established through retrospective studies that have compared sonographic findings against those found on subsequent scrotal exploration, the traditional gold standard for diagnostic and therapeutic evaluation.<sup>6,8</sup> The post-traumatic ultrasonic evaluation for hematocele has been shown to be 85-87% sensitive and 75-89% specific according to two studies of 24 and 33 patients, respectively.<sup>6,8</sup> Three studies, consisting of 33, 65, and 24 patients, have reported the sonographic findings for testicular rupture to be 92-100% sensitive while being 50-93.5% specific.<sup>6-8</sup> The accuracy of US in the diagnosis of testicular fracture is less well established since the diagnosis is uncommon and most of these patients are managed non-operatively.

## CONCLUSION

In summary, we report a case of testicular rupture diagnosed by an EP using POCUS. To our knowledge, this diagnosis identified with POCUS has not been detailed in the emergency medicine literature. Our case demonstrates an opportunity for EPs to expedite the diagnosis of acute scrotal

pathologies, and reduce dependence on radiology departments, which may not be readily available. Furthermore, use of routine scrotal POCUS may be used to stratify patients in need of emergent urologic consultation, help to reduce time to surgical intervention, and reduce the need for additional evaluation, thus improving resource use and patient outcomes.

**Supplemental Video.** This brief, narrated video reviews the findings in this case which led to the immediate diagnosis of testicular rupture. The findings include enlarged testicle with irregular, heterogeneous echogenicity, as well as loss of integrity of the tunica albuginea.

---

*Address for Correspondence:* Tyler L. Holliday, MD, West Virginia University, School of Medicine, 1 Medical Center Drive, 7413B HSS, Morgantown, WV 26506. Email: thollid1@mix.wvu.edu.

*Conflicts of Interest:* By the CPC-EM article submission agreement, all authors are required to disclose all affiliations, funding sources and financial or management relationships that could be perceived as potential sources of bias. The authors disclosed none.

*Copyright:* © 2017 Holliday et al. This is an open access article distributed in accordance with the terms of the Creative Commons Attribution (CC BY 4.0) License. See: <http://creativecommons.org/licenses/by/4.0/>

---

## REFERENCES

1. Blaivas M, Sierzenski P, Lambert M. Emergency evaluation of patients presenting with acute scrotum using bedside ultrasonography. *Acad Emerg Med.* 2001;8(1):90-3.
2. Wright S, Hoffmann B. Emergency ultrasound of acute scrotal pain. *Eur J Emerg Med.* 2015;22(1):2-9.
3. Singh A. Testicular fracture and rupture. *Emergency Radiology: Imaging of Acute Pathologies.* 2013;103.
4. Deurdulian C, Mittelstaedt CA, Chong WK, et al. US of acute scrotal trauma: Optimal technique, imaging findings, and management. *Radiographics.* 2007;27(2):357-69.
5. Pearl MS, Hill MC. Ultrasound of the scrotum. *Semin Ultrasound CT MR.* 2007;28(4):225-48.
6. Guichard G, El Ammari J, Del Coro C, et al. Accuracy of ultrasonography in diagnosis of testicular rupture after blunt scrotal trauma. *Urology.* 2008;71(1):52-6.
7. Buckley JC, McAninch JW. Use of ultrasonography for the diagnosis of testicular injuries in blunt scrotal trauma. *J Urol.* 2006;175(1):175-8.
8. Abd Elkader OA, El Nashar AE, Mohy El Den KM. Accuracy of ultrasound diagnosis after blunt scrotal trauma (10 years experience). *Afr J Urol.* 2010;16(3):73-8.
9. Cokkinos DD, Antypa E, Tserotas P, et al. Emergency ultrasound of the scrotum: A review of the commonest pathologic conditions. *Curr Probl Diagn Radiol.* 2011;40(1):1-14.
10. Coleman S, Goel R, Park A, et al. Acute testicular fracture. *J Urol.* 2014;192(5):1525-6.

# Cervical Artery Dissection and Choosing Appropriate Therapy

Jonathan T. Lau, MD\*  
John S. Hunt, Jr, MD\*  
David I. Bruner, MD†  
Andrea L. Austin, MD\*

\*Naval Medical Center, Department of Emergency Medicine, San Diego, California

†Scripps Mercy, Department of Emergency Medicine, San Diego, California

Section Editor: Rick A. McPheeters, DO

Submission history: Submitted December 8, 2016; Revision received February 23, 2017; Accepted March 30, 2017

Electronically published July 6, 2017

Full text available through open access at [http://escholarship.org/uc/uciem\\_cpchem](http://escholarship.org/uc/uciem_cpchem)

DOI: 10.5811/cpcem.2017.3.33296

Cervical artery dissection is a common cause of stroke in young adults. This may result from head and neck trauma; it can also occur spontaneously or secondary to genetic connective tissue or vascular disorders. Neurologic symptoms arise as a result of thromboembolism and hypoperfusion causing cerebral ischemia. We present a case of a previously healthy male who was found to have a cervical internal carotid artery dissection and the decision to use antiplatelet therapy instead of anticoagulation to prevent stroke. Data is lacking regarding the efficacy of one therapy over the other. [Clin Pract Cases Emerg Med. 2017;1(3):225–228.]

---

## INTRODUCTION

Cervical artery dissection is a common cause of stroke in young adults with an incidence of 2.6-2.9 per 100,000 patients. It is classified based on the artery involved (vertebral vs. carotid) and location (intracranial vs. extracranial). The most common dissection is an extracranial internal carotid artery (ICA) dissection. Dissection is defined by the separation of arterial wall layers, which creates a false lumen allowing blood to escape and expand. This may result from head and neck trauma or can occur spontaneously or secondary to genetic connective tissue or vascular disorders, such as Ehlers-Danlos syndrome, Marfan syndrome and most commonly fibromuscular dysplasia. Neurologic symptoms arise as a result of thromboembolism and hypoperfusion causing cerebral ischemia. Mass effect of the dissecting artery may also cause local nerve root compression resulting in Horner's syndrome.

## CASE REPORT

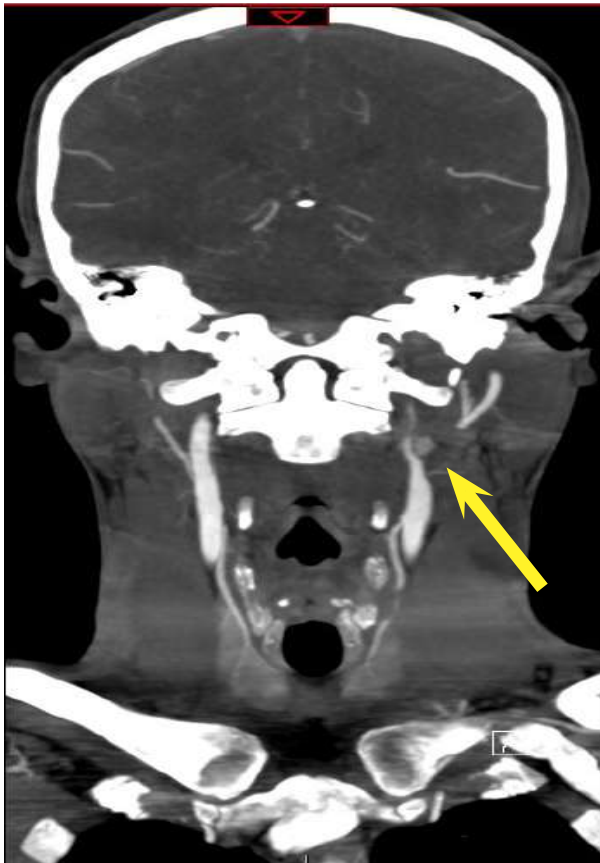
We present a case of a 30-year-old previously healthy male who presented to the emergency department (ED) with complaints of a new gradual onset left-sided throbbing headache with transient right-sided paresthesias and a right hemianopsia that occurred at rest. There was no associated weakness or other focal neurologic deficits. His symptoms spontaneously resolved on arrival to the ED. He reported recent chiropractic manipulation of the cervical spine one

week prior to presentation. He also noted remote trauma, having been involved in a motorcycle accident approximately nine months prior sustaining a left clavicle fracture that was initially treated non-operatively. However, he required surgical repair due to malunion. At the time of ED presentation, his neurologic exam was unremarkable.

Non-contrast head computerized tomography (CT) was unremarkable. CT angiography (CTA) of the head and neck was performed because of his reported transient neurologic deficits, and it revealed a left cervical ICA dissection 1.7cm from the carotid bifurcation extending to the base of the skull and a 7mm pseudoaneurysm near the proximal aspect of the dissection (Image 1 and 2). Both neurology and neurosurgery were consulted, and there was no consensus on stroke prophylaxis.

The patient was ultimately started on oral aspirin 325mg daily and atorvastatin 80mg daily and admitted to the medical intensive care unit. Magnetic resonance imaging (MRI) with angiography of the head and neck were subsequently performed revealing no large perfusion defects (Image 3 and 4). Angiogram was performed, further demonstrating the left ICA dissection and pseudoaneurysm. Two ICA stents were placed given concerns for the patient's long-term risk for stroke. He was then transitioned to dual antiplatelet therapy with clopidogrel and aspirin and discharged home. The patient had follow-up weeks later and remained asymptomatic.





**Image 1.** Computerized tomography angiography (CTA) coronal view demonstrating the dissection with the pseudoaneurysm (yellow arrow).

*Population Health Research Capsule*

What do we already know about this clinical entity?

*Cervical artery dissection is a common cause of stroke in young adults and can occur spontaneously, after trauma, or due to a connective tissue or vascular disorder.*

What makes this presentation of disease reportable?

*This patient presented with symptoms of a transient ischemic attack and had a history of recent trauma to the left neck and chiropractic manipulation.*

What is the major learning point?

*Either antiplatelet or anticoagulation medications should be initiated promptly – evidence is limited supporting efficacy of one over the other.*

How might this improve emergency medicine practice?

*Recognition of cervical artery dissection and initiating appropriate therapy early may reduce the potential for any permanent or prolonged neurologic dysfunction.*

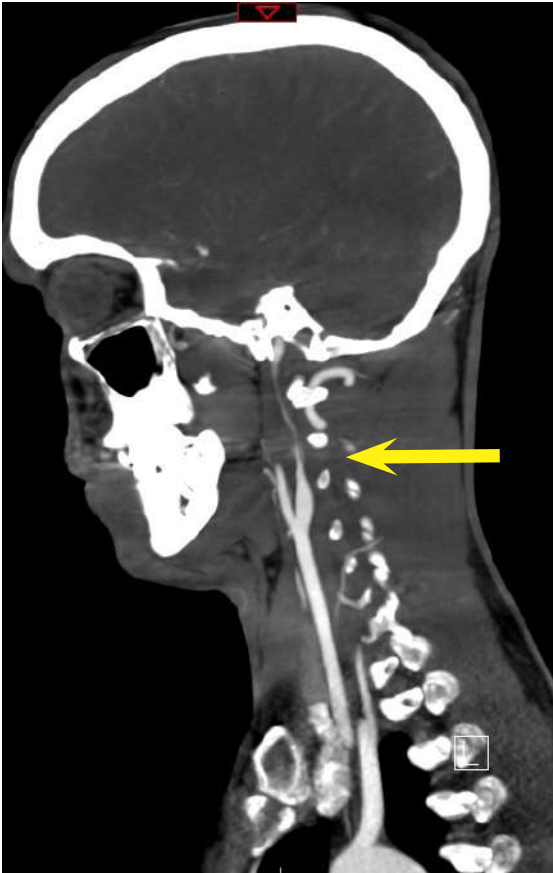
## DISCUSSION

Cervical artery dissection usually presents with a combination of transient ischemic attack or ischemic stroke, headache, and neck pain. Reportedly, 56% of patients present with symptoms of cerebral ischemia and 25% with Horner's syndrome. Head and neck pain are the most common symptoms of cervical artery dissection, found in 60%-90% of cases, but only 20% have sudden thunderclap headaches. Other presentations include tinnitus and scalp tenderness. The mean age of occurrence is approximately 45 years with a slightly higher male predominance (53-57%). Risk of recurrent stroke is 2-3%, typically occurring in the first two weeks after dissection.

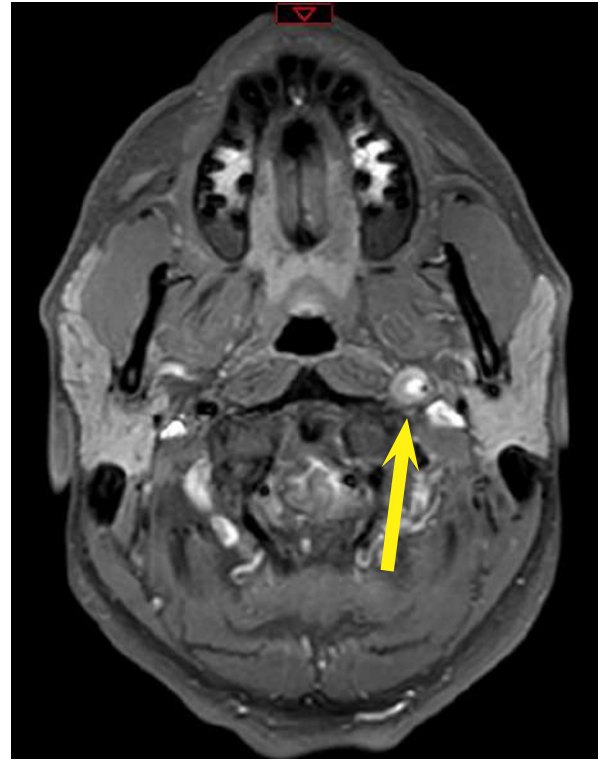
Associations between cervical spine manipulation (CSM) and cervical artery dissection have been described in case reports and case control studies. In 2016, a systematic review and meta-analysis was published that concluded the quality of data on this relationship is low and there is no convincing evidence to support a causal link between CSM and cervical artery dissection. It concluded that associations were likely biased by the strong possibility that patients with early dissection-related symptoms, such as neck pain, seek chiropractic care prior to developing a stroke. With these studies

in mind the American Heart Association and American Stroke Association (AHA/ASA) released a scientific statement, updated in November 2016, that while incidence of cervical artery dissection in CSM is probably low and causality remains difficult to prove, physicians should consider the possibility of cervical artery dissection in this patient population and inform patients of the possible connection.

On presentation, standard approaches to management should be performed including blood pressure regulation, fluid administration, glycemic control, and other correction of metabolic derangements, with the primary goal in treatment of cervical artery dissection to prevent stroke. Treatment is sometimes started in the ED with antithrombotic or anticoagulation medication. However, research is limited regarding the efficacy of one therapy over the other. In 2010, a Cochrane review showed no randomized control trials comparing either antiplatelet or anticoagulant drugs with control or directly comparing them to each other, concluding that there was no evidence to support their routine use or any significant difference



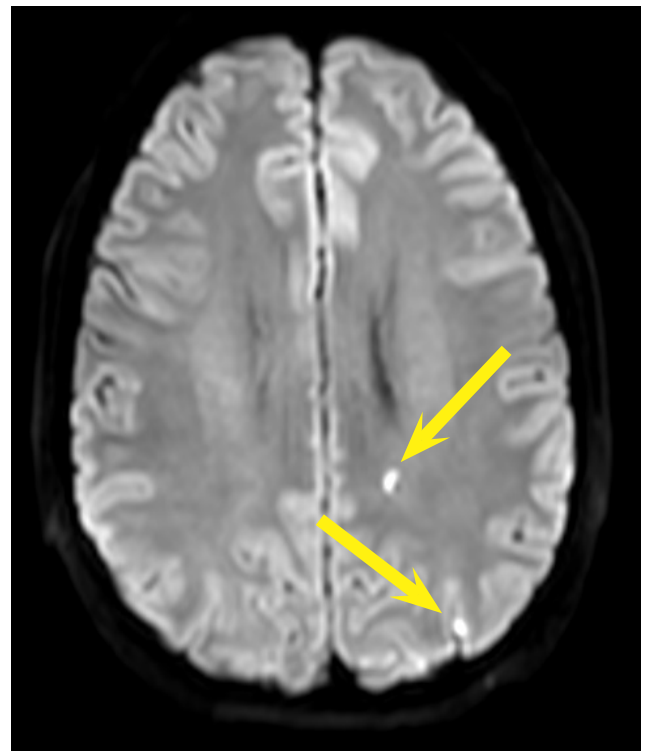
**Image 2.** CTA sagittal view showing “carotid string sign” (yellow arrow) referring to the thin string of intravenous contrast material distal to the stenotic focus in the internal carotid artery.



**Image 3.** Magnetic resonance imaging (MRI) angiography T1 fat-saturated transverse view showing left internal carotid artery with significantly diminished lumen size and showing enhancement of thrombus (yellow arrow).

in efficacy in extracranial cervical artery dissection. In 2015, a meta-analysis of 38 (non-randomized) studies showed no significant difference between antiplatelet versus anticoagulation therapy with respect to death or disability. The Cervical Artery Dissection in Stroke Study (CADISS Trial) randomized 250 patients within seven days of stroke onset to antiplatelet or anticoagulation therapy, which showed no difference in stroke risk. A major limitation of this study was that it was underpowered given the low stroke recurrence rates in both groups. It is estimated that a trial with adequate power to show any potential difference would require approximately 4,800 patients in each treatment group. Conducting a study requiring such a large cohort with its low recurrence rates is impractical.

The AHA 2011 guidelines state that the relative efficacy of anticoagulation versus antiplatelet therapy is unknown, and antithrombotic treatment was recommended for three to six months for those who sustain a stroke or transient ischemic attack. The same year, an executive summary released from the American College of Cardiology Foundation and the ASA made Class IIa recommendations to initiate treatment with anticoagulation followed by antiplatelet therapy.



**Image 4.** MRI transverse view showing areas with small ischemic lesions (yellow arrows).

## CONCLUSION

This case highlights the need to have a high index of suspicion regarding cervical artery dissection after remote trauma. There is limited evidence to suggest a causal link between cervical spinal manipulation and cervical artery dissection. Symptoms may be mistaken for a migraine headache, musculoskeletal neck pain, or cerebral infarction/hemorrhage. MRI angiography, CTA, or angiography confirm the diagnosis and should be considered as part of the diagnostic workup in the ED when there are even transient or subjective neurologic complaints. Until there is further evidence to support one antithrombotic therapy over the other, decisions regarding anticoagulation versus antiplatelet therapy can be made in conjunction with the consulting physician and performed on a case-by-case basis.

---

*Address for Correspondence:* Jonathan T. Lau, MD, Naval Medical Center, Department of Emergency Medicine, 34800 Bob Wilson Dr, San Diego, CA 92134. Email: dr.jtlau@gmail.com.

*Conflicts of Interest:* By the CPC-EM article submission agreement, all authors are required to disclose all affiliations, funding sources and financial or management relationships that could be perceived as potential sources of bias. John S. Hunt, MD, discloses the following: "I retain no rights to the article. I have no financial interest in the drugs, devices or procedures described in the forgoing article."

*Copyright:* © 2017 Lau et al. This is an open access article distributed in accordance with the terms of the Creative Commons Attribution (CC BY 4.0) License. See: <http://creativecommons.org/licenses/by/4.0/>

---

## REFERENCES

1. Lee VH, Brown RD Jr, Mandrekar JN, et al. Incidence and outcome of cervical artery dissection: a population-based study. *Neurology*. 2006;67(10):1809.
2. Thanvi B, Munshi SK, Dawson SL, et al. Carotid and vertebral artery dissection syndromes. *Postgraduate Medical Journal*. 2005;81:383-8
3. de Bray JM, Marc G, Pautot V, et al. Fibromuscular dysplasia may herald symptomatic recurrence of cervical artery dissection. *Cerebrovasc Diseases*. 2007;23(5-6):448.
4. Ji R, Schwamm LH, Pervez MA, et al. Ischemic stroke and transient ischemic attack in young adults: risk factors, diagnostic yield, neuroimaging, and thrombolysis. *JAMA Neurology*. 2013 Jan;70(1):51-7.
5. Mitsias P, Ramadan NM. Headache in ischemic cerebrovascular disease. Part I: Clinical features. *Cephalalgia*. 1992;12(5):269.
6. Lee VH, Brown RD Jr, Mandrekar JN, et al. Incidence and outcome of cervical artery dissection: a population-based study. *Neurology*. 2006;67(10):1809.
7. Arnold M, Kappeler L, Georgiadis D, et al. Gender differences in spontaneous cervical artery dissection. *Neurology*. 2006; 67:1050-2.
8. Blum, C, Yaghi, S. Cervical artery dissection: A review of the epidemiology, pathophysiology, treatment, and outcome. *Archives of Neuroscience*. 2015;2(4).
9. Church EW, Sieg EP, Zalatimo O, et al. Systematic review and meta-analysis of chiropractic care and cervical artery dissection: No evidence for causation. *Cureus*. 2016;8(2):e498.
10. Biller J, Sacco RL, Albuquerque FC, et al. Cervical arterial dissections and association with cervical manipulative therapy. A statement for healthcare professionals from the American Heart Association/American Stroke Association. *Stroke*. 2014;45:3155-74.
11. Lyrer P, Engelter S. Antithrombotic drugs for carotid artery dissection. *Cochrane Database of Systematic Reviews*. 2010;10: CD000255
12. Chowdhury MM, Sabbagh CN, Jackson D, et al. Antithrombotic treatment for acute extracranial carotid artery dissections: A meta analysis. *Eur J Vasc Endovasc Surg*. 2015;50:148e156
13. Markus HS, Hayter E, Levi C, et al. Antiplatelet treatment compared with anticoagulation treatment for cervical artery dissection (CADISS): A randomised trial. *The Lancet Neurology*. 2015;14:361-7.
14. Gross B, Albuquerque F. Antiplatelets versus anticoagulation for cervical artery dissection. *World Neurosurgery*. 2015;8(1):21-2
15. Furie KL, Kasner SE, Adams RJ, et al. Guidelines for the prevention of stroke in patients with stroke or transient ischemic attack: A guideline for healthcare professionals from the American Heart Association/American Stroke Association. *Stroke*. 2011;42:227-76.
16. Brott TG, Halperin JL, Abbara S, et al. Guideline on the management of patients with extracranial carotid and vertebral artery disease: Executive Summary. *Journal of the American College of Cardiology*. 57,8:1002-44.

# *Abiotrophia defectiva* Endocarditis: An Easy Miss

Erica Escarcega, MD\*

Caitlin Trovato, PA-C†

Osamudiamen Idahosa, MMBS†

John Gillard, PA-C†

Holly Stankewicz, DO\*

\*St. Luke's University Hospital, Department of Emergency Medicine, Bethlehem, Pennsylvania

†St. Luke's University Hospital, Department of Critical Care Medicine, Bethlehem, Pennsylvania

Section Editor: Rick A. McPheeters, DO

Submission history: Submitted November 15, 2016; Revision received January 25, 2017; Accepted February 22, 2017

Electronically published July 14, 2017

Full text available through open access at [http://escholarship.org/uc/uciem\\_cpccm](http://escholarship.org/uc/uciem_cpccm)

DOI: 10.5811/cpcem.2017.3.33126

Subacute endocarditis often presents with an indolent course. A potentially lethal form generated by infection with *Abiotrophia defectiva* may be easily overlooked early in its presentation. This report discusses the case of an 18-year-old male discovered to have severe endocarditis after presenting to the emergency department with the chief complaint of foot pain. [Clin Pract Cases Emerg Med. 2017;1(3):229-231]

---

## INTRODUCTION

*Abiotrophia defectiva*, once classified as a nutritionally variant strain of streptococci, is a rare but important cause of infective endocarditis with potentially devastating consequences due to its high rates of embolization, bacteriological failure and mortality.<sup>1,2</sup> This little-known bacteria is part of the normal oral flora making dental procedures a commonly implicated source of infection.<sup>2,3,4</sup> Unfortunately, this bacteria is often pleomorphic on Gram stain and is difficult to isolate, requiring specialized media and, therefore, may be the cause of some cases of culture-negative endocarditis.<sup>2,3</sup> Here we describe a case of subacute bacterial endocarditis in a previously healthy young male with history of bicuspid aortic valve.

## CASE REPORT

An 18-year-old male with history of bicuspid aortic valve presented to the emergency department (ED) the day after his senior prom with the chief complaint of right foot pain that had been gradually worsening over the prior three days. He had awoken at 4:30 am that morning and found that he could no longer bear weight on the right foot due to the intensity of the pain and had been using an old set of crutches to ambulate around his home. The patient indicated that the pain was primarily over the dorsal aspect of the foot, radiated up the back of the calf and was worse with bearing weight and movement. He had taken ibuprofen at home with no improvement in his symptoms. He denied

any recent strenuous activity or injury to the foot, but had been dancing at his prom the previous night. He had been treated for plantar fasciitis in both feet by his podiatrist and had received a cortisone shot in the left foot three weeks earlier. Patient had also been having symptoms of fatigue, night sweats and fever for which his primary care physician had prescribed levofloxacin. He had completed one 10-day course 2-3 weeks prior to his presentation with only minimal improvement in his symptoms and had been started on a second 10-day course. The patient had been afebrile for the prior week, but he had continued to have problems with fatigue and night sweats and had recently developed exertional dyspnea. He denied intravenous drug use or recent dental procedures.

On initial examination, the patient was well appearing, but tachycardic at 118 beats per minute (bpm) with a grade 2/6 systolic murmur. He had normal breath sounds, was not tachypneic, and had a normal oxygen saturation. On examination of the right foot and ankle, he had tenderness over the dorsum of the foot and pain with range of motion of the ankle. Distal perfusion and sensation of the foot were intact. There were no overlying skin changes. The classic skin findings of endocarditis, including Janeway lesions, Osler nodes and splinter hemorrhages, were not present. A radiograph of the right foot was negative for fractures or dislocations. Basic labs including a blood count and basic metabolic panel were drawn that were significant only for an unexplained anemia with a hemoglobin of 8.9 g/dL.



The patient was given a 1 L bolus of normal saline, but remained tachycardic on re-examination with a heart rate as high as 134 bpm. His electrocardiogram was otherwise normal. The decision was made to draw a D-dimer, which came back elevated at 721 µg/L. After a discussion with the patient and his mother, a computed tomography (CT) with contrast to rule out pulmonary embolism (PE) was ordered. Although negative for PE, his CT had concerning findings including an ascending thoracic aortic aneurysm measuring 4.1 cm, as well as ground-glass densities of the lungs. The patient was admitted to the hospital for an urgent echocardiogram, which revealed severe endocarditis affecting both the mitral and aortic valves (Image). Blood cultures were drawn and he was started on vancomycin and ceftriaxone.

The patient remained hemodynamically stable; however, three days after his admission, he developed multiple embolic phenomena manifesting as a left frontal infarct as well as an acute thrombus to the right internal jugular. After a negative magnetic resonance image of the ankle, a duplex ultrasound revealed the presence of an acute deep vein thrombosis of the right posterior tibial vein. Blood cultures were positive for *Abiotrophia defectiva*, but due to the difficulty in growing the organism the sample was sent to an outside facility and sensitivities were delayed. When sensitivities resulted, the organism was found to be sensitive to the empiric regimen. Notably, the organism was also sensitive to levofloxacin. The use of this antibiotic prior to his presentation may have contributed to his relatively benign initial presentation. The patient underwent bovine aortic and mitral valve replacements after which he was extubated and weaned off vasopressor and inotropic support. On post operative day 1, he developed a severe systemic inflammatory state with multi-organ system failure requiring re-intubation, escalation of vasopressors and inotropes, continuous renal replacement therapy and urgent venoarterial extracorporeal membrane oxygenation support due to refractory shock. A bedside echocardiogram revealed biventricular failure with ejection fraction of 5%. A biventricular assist device was later inserted, and approximately two months later the patient underwent successful heart transplantation.

## DISCUSSION

This case highlights the need for increased awareness of the potentially indolent presentation as well as the severity, morbidity and mortality related to *Abiotrophia defectiva* endocarditis. There are case reports of *Abiotrophia defectiva* endocarditis affecting both the young and the old, and patients with underlying heart disease and even those without.<sup>2,4,5</sup> This diagnosis is difficult as patients often present with signs more typical of subacute endocarditis that are often nonspecific, including low-grade fever, weakness, fatigue and myalgias.<sup>6</sup> Classically taught manifestations of endocarditis such as Roth's spots, Janeway lesions, Osler nodes and

### Population Health Research Capsule

What do we already know about this clinical entity?

*Endocarditis is a difficult diagnosis to make in the emergency department. Patients may present with classic signs and symptoms or may have a more indolent course with nonspecific symptoms.*

What makes this presentation of disease reportable?

*This is a case of a young male that presented with a very benign complaint despite having severe disease. Investigation of unexplained tachycardia led to his eventual diagnosis.*

What is the major learning point?

*Subacute endocarditis often presents with vague symptomatology including musculoskeletal complaints.*

How might this improve emergency medicine practice?

*Considering subacute endocarditis in patients with vague presentations and unexplained tachycardia may uncover cases that may be otherwise missed.*

splenomegaly are less common in children regardless of the bacterial etiology.<sup>6</sup> Penicillins in combination with gentamicin are recommended as first-line therapy for *Abiotrophia* endocarditis by American Heart Association guidelines.<sup>3</sup> However, although there is little resistance reported to gentamicin or vancomycin, this potentially deadly bacteria has shown resistance to penicillins.<sup>2,7</sup> Making treatment even more difficult, *Abiotrophia defectiva* has been found to have a slow metabolic rate, which is believed to contribute to the higher rate of treatment failures.<sup>4</sup>

## CONCLUSION

Devastating complications, such as subarachnoid hemorrhage from mycotic cerebral aneurysms and heart failure, have been reported in association with this form of endocarditis, highlighting the need for keeping a high degree of suspicion when treating these patients who, early on, may have very mild presentations.<sup>2,8</sup>

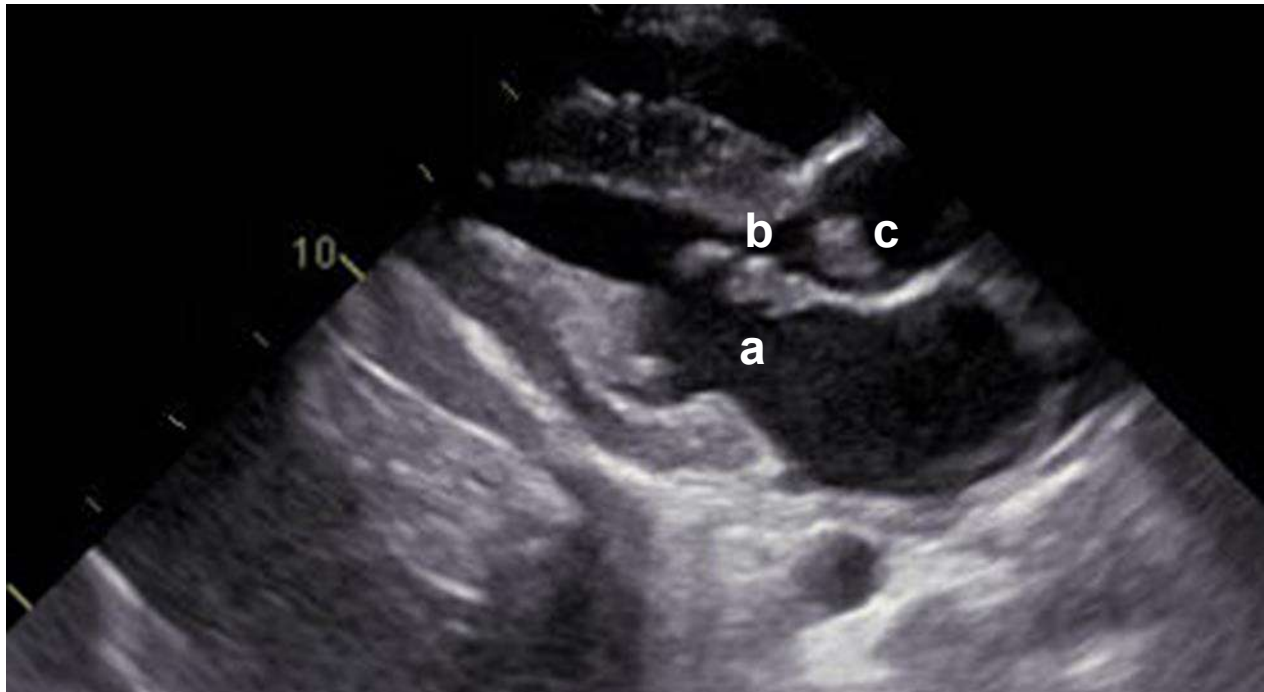**Address for Correspondence:** Erica Escarega, MD, St. Luke's University Hospital, 801 Ostrum Street, Bethlehem, PA 18015. Email: Erica.escarcega@sluhn.org.

**Conflicts of Interest:** By the CPC-EM article submission agreement, all authors are required to disclose all affiliations, funding sources and financial or management relationships that could be perceived as potential sources of bias. The authors disclosed none.

**Copyright:** © 2017 Escarega et al. This is an open access article distributed in accordance with the terms of the Creative Commons Attribution (CC BY 4.0) License. See: <http://creativecommons.org/licenses/by/4.0/>

## REFERENCES

- Stein, DS, Nelson KE. Endocarditis due to nutritionally deficient streptococci: therapeutic dilemma. *Rev Infect Dis.* 1987;9(5):908-16.
- Lin C, Hsu R. Infective endocarditis caused by nutritionally variant streptococci. *Am J Med Sci.* 2007;334(4):235-9.
- Baddour LM, Wilson WR, Bayer AS, et al. Infective endocarditis in Adults: diagnosis, antimicrobial therapy, and management of complications: A scientific statement for healthcare professionals from the American Heart Association. *Circulation.* 2015;132(15):1435-86.
- Chang HH, Lu CY, Hsueh PR, et al. Endocarditis caused by *Abiotrophia defectiva* in children. *Pediatr Infect Dis J.* 2002;21(7):697-700.
- Guiliano S, Caccese R, Carfagna P, et al. Endocarditis caused by nutritionally variant streptococci: a case report and literature review. *Infez Med.* 2012;20(2):67-74.
- Ferrieri P, Gewitz MH, Gerber MA, et al. Unique features of infective endocarditis in childhood. *Circulation.* 2002;105(17):2115-26.
- Alberti MO, Hindler JA, Humphries RM. Antimicrobial susceptibilities of *Abiotrophia defectiva*, *Granulicatella adiacens*, and *Granulicatella elegans*. *Antimicrob Agents Chemother.* 2016;60(6):3868.
- Kohok DD, Parashar A, Punnam V, et al. Subarachnoid hemorrhage in a patient with *Abiotrophia defectiva* endocarditis. *Am J Med Sci.* 2011;341(2):157-9.



**Image.** Transthoracic echocardiogram showing focal thickening of the anterior leaflet of the mitral valve (a) with a large perforation (b), as well as increased thickness of the aortic valve with vegetations (c).

# Sub-acute Tamponade and the Value of Point-of-Care Ultrasound for Rapid Diagnosis: A Case Report

Daniel C. Kolinsky, MD\*

Albert J. Kim, MD\*

Enyo A. Ablordepey, MD, MPH†

\*Washington University School of Medicine, Department of Emergency Medicine, St. Louis, Missouri

†Washington University School of Medicine, Department of Anesthesiology, Division of Critical Care, St. Louis, Missouri

Section Editor: Rick A. McPheeters, DO

Submission history: Submitted December 21, 2016; Revision received March 26, 2017; Accepted March 30, 2017

Electronically published July 14, 2017

Full text available through open access at [http://escholarship.org/uc/uciem\\_cpem](http://escholarship.org/uc/uciem_cpem)

DOI: 10.5811/cpcem.2017.3.33413

Minoxidil is a strong oral vasodilator that is used to treat patients with hypertension refractory to first-line medications. We report a case of minoxidil-associated subacute cardiac tamponade diagnosed by point-of-care ultrasound (POCUS) in a hypertensive patient. A 30-year-old male with a past medical history of poorly controlled hypertension (treated with minoxidil) and chronic kidney disease presented with 2-3 days of chest pain and shortness of breath with markedly elevated blood pressures. A point-of-care transthoracic echocardiogram revealed a massive pericardial effusion with sonographic tamponade physiology. We review the risk factors for developing pericardial effusions that progress to cardiac tamponade, the utility of diagnosing these patients by POCUS, and the incidence of patients who present with sonographic signs of cardiac tamponade without hypotension. [Clin Pract Cases Emerg Med. 2017;1(3):232–237.]

---

## INTRODUCTION

In the emergency department (ED), point-of-care ultrasound (POCUS) can help determine the diagnosis, alter the management plan, or assist in procedures. The conventional form ultrasound imaging uses brightness mode (B-Mode, 2D mode), which produces two-dimensional images. However, more recently the utility of motion mode (M-mode) in the ED has been recognized. M-mode is a unique mode of sonographic imaging that displays one-dimensional movement over time. This feature can be used for calculating left ventricular systolic function, looking for pneumothorax, or in this case, diagnosing cardiac tamponade.<sup>1</sup>

Minoxidil is a strong oral vasodilator that acts directly on vascular smooth muscle and is commonly used for treatment of refractory hypertension.<sup>2</sup> A known potential complication of minoxidil therapy is development of a pericardial effusion, which may progress to cardiac tamponade.<sup>3,4</sup> We report a case of minoxidil-associated cardiac tamponade diagnosed by POCUS in a hypertensive patient.

## CASE REPORT

A 30-year-old male with a past medical history including hypertension, chronic kidney disease (formerly

end-stage renal disease on hemodialysis), and congestive heart failure presented with 2-3 days of chest pain associated with dyspnea on exertion and orthopnea. He was on multiple antihypertensive medications including clonidine, lisinopril, labetalol, hydralazine, hydrochlorothiazide, furosemide, and minoxidil.

Upon arrival to the ED, his initial vital signs were temperature of 39.1 degrees Celsius, heart rate of 109 beats per minute, respiratory rate of 38 breaths per minute, blood pressure of 236/155 millimeters of mercury, oxygen saturation of 97% on room air. His physical exam was notable for moderate respiratory distress secondary to tachypnea and accessory muscle use, diffuse expiratory wheezes in all lung fields, and bilateral lower extremity swelling.

Laboratory evaluation revealed a white blood cell count of 7.4 K/cumm, sodium of 136 mmol/L, and creatinine of 2.64 mg/dL. His troponin was 0.39 ng/ml and brain natriuretic peptide of 233 pg/ml. The electrocardiogram was notable for left ventricular hypertrophy, inferolateral T-wave inversions, and electrical alternans. The patient was started on a nitroglycerin infusion at 60 mcg/min for hypertensive emergency. A chest radiograph (Image

1) revealed an enlarged cardiac silhouette prompting the clinician to perform a point-of-care transthoracic echocardiogram (Images 2B and 3B).

The transthoracic echocardiogram revealed a large pericardial effusion with tamponade physiology, although his blood pressure remained elevated with a peak of 236/155 millimeters of mercury. The nitroglycerin infusion was immediately lowered to 20mcg/min based on the transthoracic echocardiogram findings. The patient was admitted to the cardiac intensive care unit where an urgent pericardiocentesis was performed with approximately one liter fluid removed.

## DISCUSSION

Several case series have been published reporting the association of pericardial effusion with minoxidil.<sup>5-7</sup> The overall incidence of minoxidil-associated pericardial effusion is 3%.<sup>4</sup> Many patients who take minoxidil for hypertension have co-existing chronic/end-stage renal disease which, in itself, can predispose patients to uremic pericardial effusions.<sup>7</sup> Thus, it is difficult to estimate the true incidence of pericardial effusions due to minoxidil alone.<sup>7</sup> In patients undergoing hemodialysis and taking minoxidil compared to patients who are only undergoing hemodialysis, the rate of pericardial effusions was statistically greater (81% vs 23%,  $p < 0.0005$ ) in those taking minoxidil.<sup>8</sup>

Patients who continue to take minoxidil are at risk of developing a pericardial effusion that can progress to tamponade, especially if they are not followed with surveillance echocardiograms. In the study by Martin et al., of the 52 patients with minoxidil-associated pericardial effusions, 21 of them progressed to pericardial tamponade.<sup>4</sup> Furthermore, of the 21 patients who developed tamponade, 70% were on hemodialysis compared to 22% who were not.

POCUS is becoming more common in the evaluation of critically ill patients in the ED. Regardless of hemodynamic status, POCUS diagnosis of cardiac tamponade physiology is suggested by three findings: (1) collapse of the right ventricle and right atrium in diastole; (2) exaggerated respiratory variations of transmitral and transtricuspid doppler inflow velocities; and (3) inferior vena cava plethora.<sup>9</sup> Collapse of the right ventricular free wall in diastole is highly specific, and is the most recognized sonographic sign of cardiac tamponade.<sup>10</sup> This is demonstrated by placing M-mode over the mitral valve in the parasternal long-axis view (Images 2A and 3A) and observing movement of the right ventricular free wall towards the intra-ventricular septum as the mitral valve opens in early diastole (Image 3B).

Although our patient had a massive pericardial effusion with sonographic signs of cardiac tamponade, his blood pressure was markedly elevated. One retrospective review

### *CPC-EM Capsule*

What do we already know about this clinical entity?

*A known potential complication of minoxidil therapy is the development of a pericardial effusion that may progress to cardiac tamponade.*

What makes this presentation of disease reportable?

*This is the first case of minoxidil-associated subacute cardiac tamponade diagnosed by point-of-care ultrasound in the emergency department.*

What is the major learning point?

*Point-of-care-ultrasound in motion mode can be used to diagnose sonographic cardiac tamponade in the ED.*

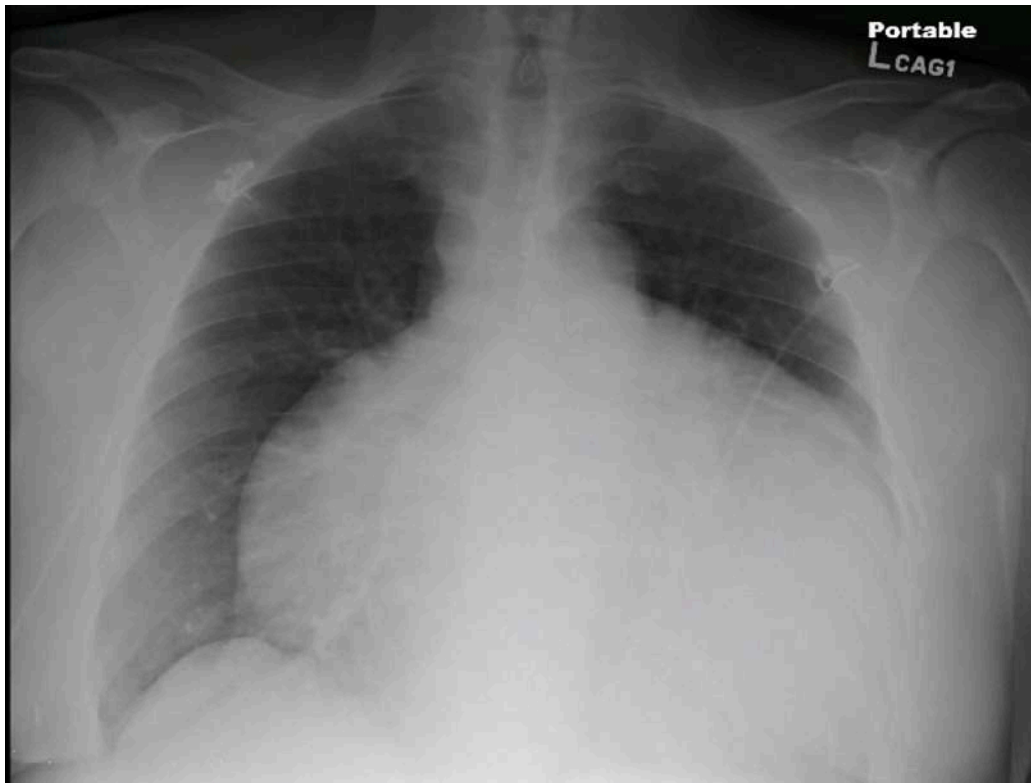
How might this improve emergency medicine practice?

*Early diagnosis of subacute cardiac tamponade can lead to earlier intervention and avoidance of potential complications, leading to improved outcomes.*

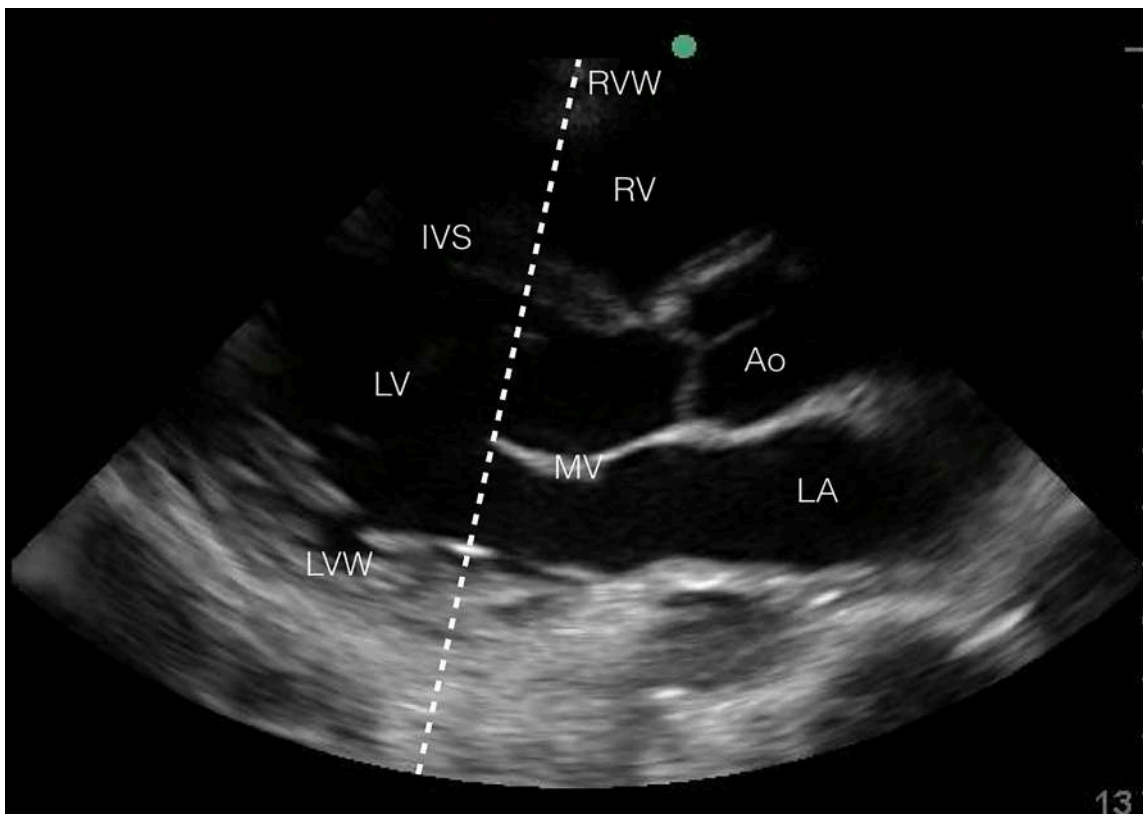
found that the majority of patients who present with subacute non-traumatic cardiac tamponade will not be hypotensive (15%), but actually normotensive (50%) or even hypertensive (35%).<sup>10</sup> The existing literature suggests that the incidence of patients with sonographic cardiac tamponade who are hypertensive ranges between 27% to 43%.<sup>12-15</sup> Preexisting hypertension,<sup>14-15</sup> and advanced renal disease,<sup>14</sup> both of which are present in our patient, are risk factors for developing sonographic cardiac tamponade without hypotension.

We report a case of a patient with minoxidil-associated pericardial effusion with sonographic evidence of tamponade despite being hypertensive, diagnosed by POCUS. Given the increased risk of enlarging pericardial effusion progressing to tamponade with minoxidil use (especially in those with pre-existing renal disease) these patients should have a POCUS performed to screen for sonographic cardiac tamponade even without hypotension.

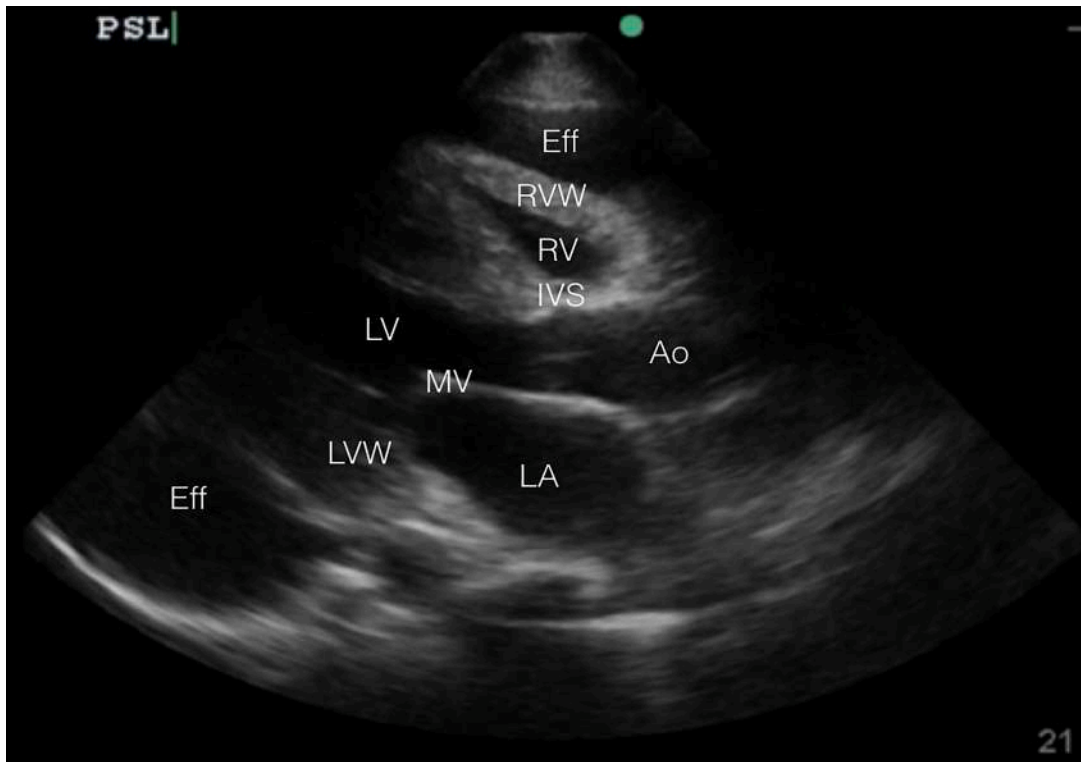




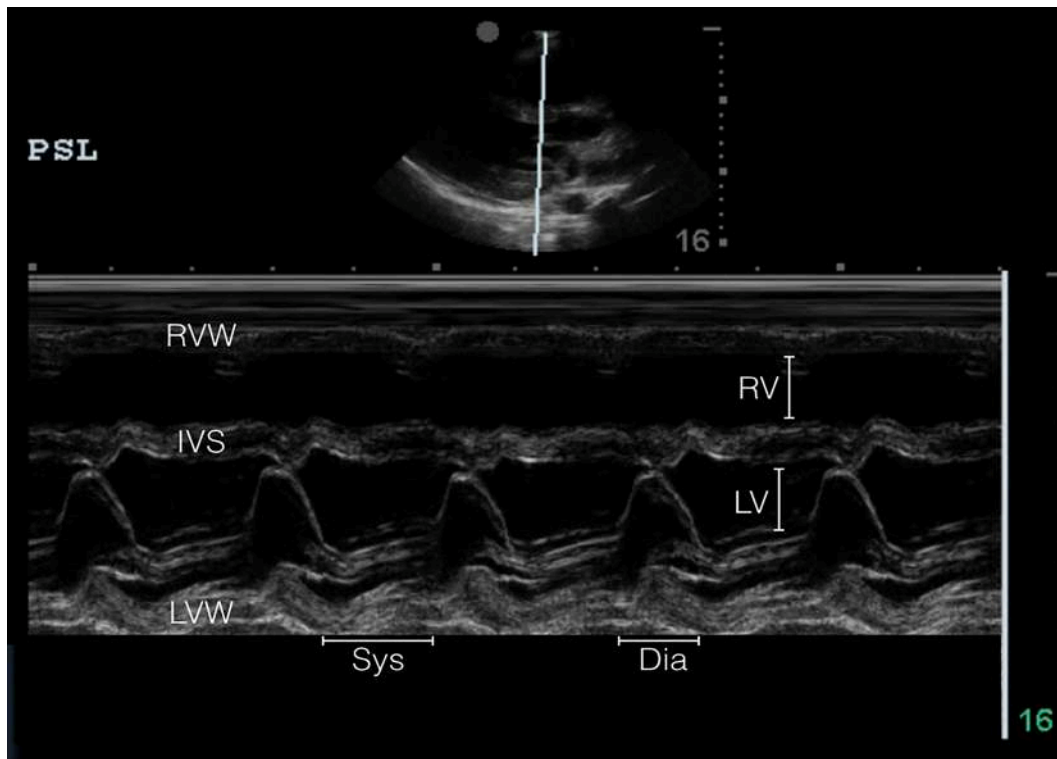
**Image 1.** Anterior-posterior chest radiograph demonstrating massively enlarged cardiac silhouette suggestive of a large pericardial effusion



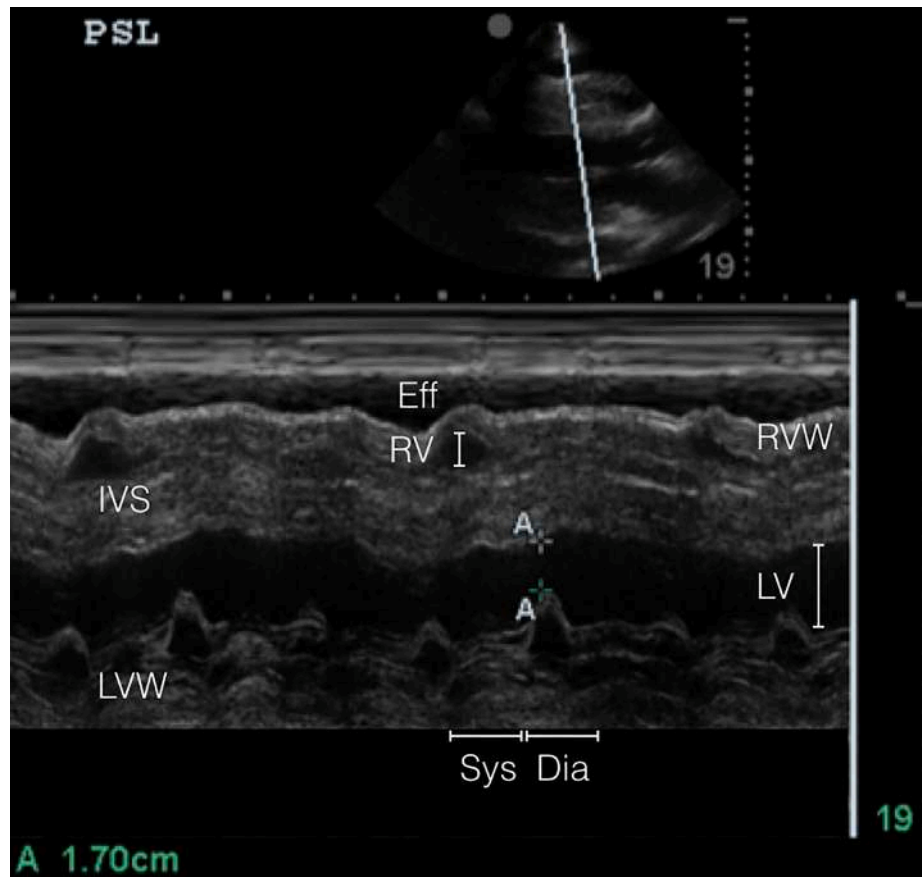
**Image 2A.** Normal comparison point-of-care transthoracic echocardiogram (parasternal long axis in 2D-mode) – Superimposed (dashed) line overlying the tip of the mitral valve indicating proper motion-mode striker placement.  
*RVW*, right ventricular wall; *RV*, right ventricle; *IVS*, intraventricular septum; *LV*, left ventricle; *Ao*, aorta; *MV*, mitral valve; *LVW*, left ventricular wall; *LA*, left atrium.



**Image 2B.** Abnormal point-of-care transthoracic echocardiogram (parasternal long axis in 2D-mode) – circumferential pericardial effusion *Eff*, effusion; *RVW*, right ventricular wall; *RV*, right ventricle; *IVS*, intraventricular septum; *LV*, left ventricle; *Ao*, aorta; *MV*, mitral valve; *LVW*, left ventricular wall; *LA*, left atrium.



**Image 3A.** Normal comparison point-of-care transthoracic echocardiogram (parasternal long axis in m-mode) – m-mode tracing showing opening (diastole) or closing (systole) of mitral valve. RV free wall with no diastolic collapse. *RVW*, right ventricular wall; *RV*, right ventricle; *IVS*, intraventricular septum; *LV*, left ventricle; *LVW*, left ventricular wall; *Sys*, systole; *Dia*, diastole.



**Image 3B.** Abnormal point-of-care transthoracic echocardiogram (parasternal long axis in M-mode) - right ventricular wall collapse as the mitral valve begins to open in early diastole.

*Eff*, effusion; *RV*, right ventricle; *RVW*, right ventricular wall; *IVS*, intraventricular septum; *LV*, left ventricle; *LVW*, left ventricular wall; *Sys*, systole; *Dia*, diastole.

*Address for Correspondence:* Daniel Kolinsky, MD, Washington University School of Medicine, 660 South Euclid, Box 8072. St. Louis, MO 63110. Email: [dkolinsky@gmail.com](mailto:dkolinsky@gmail.com).

*Conflicts of Interest:* By the *CPC-EM* article submission agreement, all authors are required to disclose all affiliations, funding sources and financial or management relationships that could be perceived as potential sources of bias. The authors disclosed none.

*Copyright:* © 2017 Kolinsky et al. This is an open access article distributed in accordance with the terms of the Creative Commons Attribution ([CC BY 4.0](https://creativecommons.org/licenses/by/4.0/)) License. See: <http://creativecommons.org/licenses/by/4.0/>

## REFERENCES

1. Saul T, Siadecki SD, Berkowitz R, et al. M-mode ultrasound applications for the emergency medicine physician. *J Emerg Med*. 2015;49(5):686-92.
2. DuCharme DW, Freyburger WA, Graham BE, et al. Pharmacologic properties of minoxidil: a new hypotensive agent. *J Pharmacol Exp Ther*. 1973;184(3):662-70.
3. Houston MC, McChesney JA, Chatterjee K. Pericardial effusion associated with minoxidil therapy. *Arch Intern Med*. 1981;141(1):69-71.
4. Martin WB, Spodick DH, Zins GR. Pericardial disorders occurring during open-label study of 1,869 severely hypertensive patients treated with minoxidil. *J Cardiovasc Pharmacol*. 1980;2 Suppl 2:S217-27.
5. Svahn DS. Minoxidil and cardiac enlargement. *JAMA*. 1978;240(16):1713-4.
6. Mitchell HC, Pettinger WA. Long-term treatment of refractory hypertensive patients with minoxidil. *JAMA*. 1978;239(20):2131-8.
7. Marquez-Julio A, From GL, Uldall PR. Minoxidil in refractory hypertension: benefits, risks. *Proc Eur Dial Transplant Assoc*. 1977;14:501-8.
8. Zarate A, Gelfand MC, Horton JD, et al. Pericardial effusion associated with minoxidil therapy in dialyzed patients. *Int J Artif Organ*. 1980;3(1):15-7.
9. Nagdev A, Stone MB. Point-of-care ultrasound evaluation of pericardial effusions: does this patient have cardiac tamponade?

- Resuscitation*. 2011;82(6):671-3.
10. Saul T, Siadecki SD, Berkowitz R, et al. M-Mode Ultrasound Applications for the Emergency Medicine Physician. *J Emerg Med*. 2015;49(5):686-92.
  11. Kapoor T, Locurto M, Farina GA, et al. Hypotension is uncommon in patients presenting to the emergency department with non-traumatic cardiac tamponade. *J Emerg Med*. 2012;42(2):220-6.
  12. Reddy PS, Curtiss EI, O'Toole JD, et al. Cardiac tamponade: hemodynamic observations in man. *Circulation*. 1978;58(2):265-72.
  13. Sagristà-Sauleda J, Angel J, Sambola A, et al. Low-pressure cardiac tamponade: clinical and hemodynamic profile. *Circulation*. 2006;114(9):945-52.
  14. Brown J, MacKinnon D, King A, et al. Elevated arterial blood pressure in cardiac tamponade. *N Engl J Med*. 1992;327(7):463-6.
  15. Argulian E, Herzog E, Halpern DG, et al. Paradoxical hypertension with cardiac tamponade. *Am J Cardiol*. 2012;110(7):1066-9.



# Cranial Neuropathies and Neuromuscular Weakness: A Case of Mistaken Identity

Daniel Z. Adams, MD  
Andrew King, MD  
Colin Kaide, MD

The Ohio State University Wexner Medical Center, Department of Emergency  
Medicine, Columbus, Ohio

Section Editor: Rick A. McPheeters, DO

Submission history: Submitted January 27, 2017; Revision received April 9, 2017; Accepted April 20, 2017

Electronically published July 14, 2017

Full text available through open access at [http://escholarship.org/uc/uciem\\_cpccem](http://escholarship.org/uc/uciem_cpccem)

DOI: 10.5811/cpccem.2017.4.33728

We describe a case of wound botulism initially thought to represent Miller-Fisher variant Guillain-Barré syndrome (MFS). Botulism classically presents with the so-called “four D’s” (diplopia, dysarthria, dysphagia, dry mouth) with symmetric, descending weakness. MFS presents with a triad of limb-ataxia, areflexia, and ophthalmoplegia, with variable cranial nerve and extremity involvement. The distinction can be difficult but is important as early initiation of botulinum antitoxin is associated with improved patient outcomes in cases of botulism. Furthermore, it is important to recognize intravenous drug use as a risk factor in the development of botulism, especially given an increase in injection drug use. [Clin Pract Cases Emerg Med. 2017;1(3):238–241.]

---

## INTRODUCTION

Botulism is a rare, neurotoxin-mediated illness produced by the gram positive, anaerobic, spore-forming bacilli *Clostridium botulinum*.<sup>1,2</sup> For the purpose of surveillance, cases are described as transmitted through four different categories to include foodborne, wound, infant, and other. There are eight different known strains of *C. botulinum*, each with a different antigenic variant. Regardless of the means of acquisition, weakness and paralysis result when the toxin irreversibly binds with presynaptic peripheral cholinergic nerve endings (i.e. neuromuscular junction and autonomic ganglia) and prevents stimulation-induced acetylcholine release by the presynaptic nerve.<sup>2,3</sup> Recovery results only when new nerve terminals sprout and form new synaptic contacts, a process that can take months. We present a case of wound botulism in an injection drug user that highlights the importance of vigilance in this difficult-to-diagnose illness.

## CASE REPORT

A 30-year-old male with a past medical history of type 1 diabetes presented to our emergency department (ED) with three days of worsening diplopia, dysarthria, and dysphagia. The patient stated his initial symptoms included headache and blurred vision for which he was evaluated at an outside

hospital and treated for a migraine headache. Thereafter, the headache resolved, but he noted progressive diplopia with the onset of dysphagia, dysarthria, and hoarseness. The morning of his presentation to our ED he complained of inability to swallow and had difficulty handling his secretions with progressive drooling. He also noted facial weakness and difficulty ambulating. Review of systems was significant for two children at home with upper respiratory illnesses. He was otherwise well prior to his presentation.

Vital signs in the ED were normal. His physical exam was significant for a well-appearing healthy male with pooling secretions and upright posturing requiring frequent suctioning of his oropharynx. Neurologically he had significant dysarthria and hoarseness, as well as bilateral and symmetric ptosis and ophthalmoplegia (cranial nerve 3 and 6 palsies), with a weak gag reflex. He had symmetrically decreased 1/4 upper extremity reflexes and 2/4 lower extremity reflexes with ataxia on ambulation. His motor and sensory exams were otherwise normal. His labs were unremarkable including a white blood cell count, serum chemistry, liver function testing, and urinalysis. Bedside negative inspiratory force was -40 cm H<sub>2</sub>O (normal -80 to -100 cm H<sub>2</sub>O), and his vital capacity was 2.8 liters (normal 3 to 5 liters). The differential diagnosis at that time included concern for Guillain-Barré syndrome

(GBS), specifically Miller-Fisher syndrome (MFS), as well as neuromuscular junction disorders such as myasthenia gravis, infiltrative central nervous system processes (i.e. lymphoma, metastatic cancer), sarcoidosis, Lyme disease, botulism and tick paralysis.

Neurology was consulted with continued monitoring in the ED. Magnetic resonance imaging of his brain was unremarkable, as were the results of lumbar puncture. Extensive laboratory testing looking for infectious or autoimmune causes were negative, including human immunodeficiency virus testing, Lyme disease titers, acetylcholine receptor antibody, and a ganglioside antibody panel. He was admitted to our step-down unit for close monitoring and empirically started on intravenous immunoglobulin for MFS while awaiting other studies. Early during his admission, it was disclosed to house staff that he was an IV drug user and shared needles with multiple persons. He had withheld this information because he did not want his family to know about his drug addiction. Given his worsening inability to handle oropharyngeal secretions, he was intubated and transferred to intensive care.

An electromyography (EMG) was performed during this interval showing decreased compound muscle action potential (CMAP) amplitudes, strongly suggesting the diagnosis of botulism. Both the state health department and Centers for Disease Control and Prevention (CDC) were contacted with an immediate request for botulinum anti-toxin. Confirmatory studies for botulism were sent and empiric penicillin G was given. Botulism antitoxin was received and administered with extubation the morning after administration. Ten days after his initial presentation he was discharged well and continued to improve on outpatient follow-up.

## DISCUSSION

Wound botulism case definitions include probable and confirmed cases. A probable case is defined as “a clinically compatible case in a patient who has no suspected exposure to contaminated food and who has either a history of a fresh, contaminated wound during the 2 weeks before onset of symptoms, or a history of injection drug use within the 2 weeks before onset of symptoms.” A confirmed case is defined as “a clinically compatible case that is laboratory confirmed in a patient who has no suspected exposure to contaminated food and who has a history of a fresh, contaminated wound during the 2 weeks before onset of symptoms, or a history of injection drug use within the 2 weeks before onset of symptoms.”<sup>4</sup> According to the CDC, in 2014 there were 161 confirmed and 16 probable cases of botulism reported in the United States,<sup>5</sup> the vast majority of laboratory-confirmed cases were infant botulism (80%), followed by wound botulism (10%), foodborne (9%), and botulism of unknown or other etiology (1%). Of the probable cases, the majority were wound botulism cases

### *CPC-EM Capsule*

What do we already know about this clinical entity?

*Wound botulism is a rare clinical entity that may present with subtle initial findings. Common symptoms include diplopia, dysarthria, dysphagia, and dry mouth.*

What makes this presentation of disease reportable?

*Injection drug use is rising in the U.S. This paper presents a case of wound botulism that resulted from injection drug use, a rare vector of botulism.*

How might this improve emergency medicine practice?

*Wound botulism is a rare condition. Treatments including early administration of botulinum antitoxin and possible early mechanical ventilation can improve mortality.*

How might this improve emergency medicine practice?

*Given rising injection-drug abuse in the U.S., consider botulism in the differential diagnosis. Prompt identification could be life-saving.*

(69%) followed by foodborne botulism (31%). Of note, a major outbreak of foodborne botulism was reported in 2015 associated with a church potluck, causing one of the largest outbreaks in U.S. history and resulting in one death. As it pertains to our case, IV drug use is a risk factor for the acquisition of botulism and something that is likely to be seen more often with the current increase in injection drug use in the U.S.<sup>7-10</sup>

Patients with botulism classically present with acute onset bilateral cranial nerve palsies and bulbar symptoms (the so-called “four Ds:” diplopia, dysarthria, dysphagia, and dry mouth) with a symmetric and descending flaccid weakness<sup>11</sup> (Table 1). Symptoms are noticed 18-36 hours after exposure but may take days to manifest.<sup>12</sup> Patients are afebrile unless there is an infected source wound. With illness onset, patients may complain of blurred vision, difficulty speaking, and difficulty swallowing as cranial nerves become involved. Physical exam will reveal ptosis, extraocular muscle weakness or palsy, and a suppressed gag reflex. Pupils are typically dilated

**Table 1.** Signs and symptoms of botulism.

Cranial nerves	Diplopia, dysarthria, dysphagia, dysphonia, ophthalmoplegia (CN II, IV, VI), facial paralysis (CN VII), mydriasis, photophobia
Autonomic nervous system	Urinary retention/incontinence, ileus, dry mouth, orthostatic hypotension, respiratory failure
Peripheral nervous system	Descending weakness with loss of deep tendon reflexes

and may be unreactive to light.<sup>12</sup> With illness progression, patients develop symmetric descending weakness initially involving the head and neck. Deep tendon reflexes may be diminished, and patients may have difficulty with coordination.<sup>13,14</sup> As would be anticipated, autonomic dysfunction may lead to ileus, urinary retention, orthostatic hypotension, reduced salivation and lacrimation. The illness becomes life-threatening when respiratory muscle function is compromised and may require intubation and prolonged mechanical ventilation<sup>1,13,14</sup>. While wound botulism would be expected to have an identifiable source, such as an abscess, it has been associated with simple abrasions, lacerations, open fractures, surgical incisions, and hematoma.<sup>15</sup>

The differential diagnosis for causes of acute, life-threatening weakness and descending paralysis are listed in Table 2.<sup>1</sup> Other considerations include electrolyte (i.e. hypo-hyperkalemia, hypo-hypercalcemia, hypo-hypermagnesemia, hypophosphatemia), metabolic (i.e. hypoglycemia, hyperthyroidism, hypothyroidism), endocrine (i.e. adrenal insufficiency) and toxicologic causes (i.e., organophosphate poisoning, carbon monoxide poisoning).

Our initial impression of this patient's presentation was MFS given the predominant cranial nerve findings and minimal motor weakness. MFS is a GBS variant that classically presents with a triad of limb-ataxia, areflexia, and ophthalmoplegia with

or without pupillary areflexia.<sup>16,17</sup> Many patients, however, will not have all three classic findings. About half of patients with MFS present with facial nerve involvement with other cranial nerves variably affected. Mild sensory involvement has been reported as well. Extremity involvement in MFS is rare but can occur in about one-third of cases, as would be seen in GBS.<sup>23</sup> In cases that do not progress, clinical improvement is seen in 2-4 weeks, with near complete resolution by six months. Given the similarity in symptoms between MFS and botulism, a thorough history, including recent infection, intravenous drug use, case clustering, etc., and physical examination are paramount for guiding the appropriate diagnostics and treatment. A strong recommendation can be made to specifically question patients presenting in this fashion about intravenous drug use after they have been separated from family members to facilitate truthful responses and honest communication.

Diagnosis of the various types of botulism varies, but history and physical examination are essential, as many of the diagnostic assays may be negative or take a prolonged time to result. Regarding wound botulism, attempts to isolate *C. botulinum* from a potential source wound should be attempted. Serum assays for botulinum toxin are typically negative and not helpful, and stool studies will not be helpful in wound botulism. Of patients tested in one study, only 68% of 73 patients with wound botulism had positive serum assays for botulinum toxin.<sup>19</sup> EMG findings of decreased CMAP amplitudes, an incremental

**Table 2.** Differential diagnosis of acute weakness.

Disease	Signs/symptoms	Diagnosis
Guillain-Barré syndrome (GBS)	Symmetric ascending weakness and paralysis with loss of deep tendon reflexes +/- autonomic dysfunction	CSF studies, EMG
Miller-Fisher variant GBS	Triad of ophthalmoplegia, ataxia, and areflexia	CSF studies, EMG
Myasthenia gravis	Proximal muscle and bulbar muscle weakness with cranial nerve deficits that worsen with exertion	Ice-pack test, edrophonium stimulation test, acetylcholine receptor antibodies
Lambert-Eaton Syndrome	Proximal > distal and lower > upper extremity weakness that worsens with illness or elevated temperature and improves with repetition; may have ptosis, diplopia, and dysarthria	Voltage-gate calcium channel antibodies, search for underlying malignancy
Tick paralysis	Symmetric ascending flaccid paralysis with loss of deep tendon reflexes	Clinical diagnosis with resolution of symptoms on tick removal

response to stimulation (post-activation facilitation), absence of post-activation exhaustion, and post-activation facilitation longer than two minutes are diagnostic.<sup>20,21</sup>

As for any cause of acute weakness in the ED, our focus should be on initial airway management, either for prevention of aspiration or impending respiratory failure. Monitoring of vital signs and respiratory parameters, such as negative inspiratory force and vital capacity, are crucial in identifying the patient's trajectory and those that require early intubation. Thereafter, initiation of treatment for botulism should be presumptive given the diagnosis is likely to be delayed and early initiation of treatment with botulinum antitoxin might decrease mortality and reduce duration of mechanical ventilation.<sup>22,23</sup> A heptavalent botulinum antitoxin is the only antitoxin available in the U.S. for patients older than one-year, with a human-derived botulinum immune globulin used for infants less than one year old. The state health department and/or CDC (770-488-7100) should be contacted immediately for early acquisition and administration of heptavalent antitoxin or the California Department of Public Health Infant Botulism Treatment and Prevention Program (510-231-7600) for acquisition of BabyBIG® when appropriate.<sup>1</sup>

## CONCLUSION

It is increasingly important to consider botulism in the differential diagnosis of acute weakness given the increase in injection drug use seen in the U.S. A high degree of suspicion should be maintained in any person presenting with features of cranial nerve and autonomic dysfunction with or without evidence of descending weakness or paralysis. When cases are identified, early administration of botulinum antitoxin can improve outcomes. Regardless, patients may still require prolonged hospitalization and mechanical ventilation. Although a rare illness, it is important to keep botulism in the differential for patients presenting with weakness, as timely diagnosis and appropriate treatment are critical to the patient's outcome.

---

*Address for Correspondence:* Daniel Z. Adams, MD, The Ohio State University Wexner Medical Center, 760 Prior Hall 376 West 10th Avenue, Columbus, Ohio 43210. Email: daniel.adams2@osumc.edu.

*Conflicts of Interest:* By the CPC-EM article submission agreement, all authors are required to disclose all affiliations, funding sources and financial or management relationships that could be perceived as potential sources of bias. The authors disclosed none.

*Copyright:* © 2017 Adams et al. This is an open access article distributed in accordance with the terms of the Creative Commons Attribution (CC BY 4.0) License. See: <http://creativecommons.org/licenses/by/4.0/>

---

## REFERENCES

- Ganti L, Rastogi V. Acute generalized weakness. *Emerg Med Clin North Am.* 2016;34(4):795-809.
- Brook I. Botulism: the challenge with diagnosis and treatment. *Rev Neurol Dis.* 2006;3(4):182-9.
- Sugiyama H. Clostridium botulinum neurotoxin. *Microbiol Rev.* 1980;44(3):419-48.
- Centers for Disease Control and Prevention (CDC). CSTE Botulism Surveillance Summary 2014. Available at: [https://www.cdc.gov/nationalsurveillance/pdfs/botulism\\_cste\\_2014.pdf](https://www.cdc.gov/nationalsurveillance/pdfs/botulism_cste_2014.pdf). Accessed on January 3, 2017.
- McCarty CL, Angelo K, Beer KD, et al. Large outbreak of botulism associated with a church potluck meal – Ohio, 2015. *MMWR Morb Mortal Wkly Rep.* 2015;64(29):802-3.
- Wenham TN. Botulism: a rare complication of injection drug use. *Emerg Med J.* 2008;25(1):55-6.
- Kalka-Moll WM, Aurbach U, Schaumann R, et al. Wound botulism in injection drug users. *Emerg Infect Dis.* 2007;13(6):942-3.
- Werner SB, Passaro D, McGee J, et al. Wound botulism in California, 1951-1998: recent epidemic in heroin injectors. *Clin Infect Dis.* 2000;31(4):1018-24.
- Drug Enforcement Administration (DEA). National Heroin Threat Assessment Summary. Available at: [https://www.dea.gov/divisions/hq/2016/hq062716\\_attach.pdf](https://www.dea.gov/divisions/hq/2016/hq062716_attach.pdf). Accessed on January 3, 2017.
- Bleck TP. Clostridium botulinum (botulism). In: Principles and Practice of Infectious Disease, 6<sup>th</sup> ed, Mandel GL, Bennet JE, Dolin R (Eds), Churchill Livingstone, Philadelphia 2005. P.2822.
- Hughes JM, Blumenthal JR, Merson MH, et al. Clinical features of types A and B food-borne botulism. *Ann Intern Med.* 1981;95(4):442-5.
- Wenham TN. Botulism: a rare complication of injection drug use. *Emerg Med J.* 2008;25(1):55-6.
- Sobel J. Botulism. *Clin Infect Dis.* 2005;41(8):1167.
- Mechem CC, Walter FG. Wound botulism. *Vet Hum Toxicol.* 1994;36(3):233.
- Wheeler C, Inami G, Mohle-Boetani J, et al. Sensitivity of mouse bioassay in clinical wound botulism. *Clin Infect Dis.* 2009;48(12):1669.
- Cherington M. Electrophysiologic methods as an aid in diagnosis of botulism: a review. *Muscle Nerve.* 1982;5(9S):S28-9.
- Meriggioli MN, Sanders DB. Advances in the diagnosis of neuromuscular junction disorders. *Am J Phys Med Rehabil.* 2005;84(8):627-38.
- Tacket CO, Shandera WX, Mann JM, et al. Equine antitoxin use and other factors that predict outcome in type A foodborne botulism. *Am J Med.* 1984;76(5):794-8.
- Kongsangdao S, Samintarapanya K, Rusmeechan S, et al. An outbreak of botulism in Thailand: clinical manifestations and management of severe respiratory failure. *Clin Infect Dis.* 2006;43(10):1247-56.



# Remote Management of Atrial Fibrillation: A Case Report

Alexander Chiu, MD, MBA  
Michael Kasper, MD  
John Rimmer, DO  
Meaghan Donnelly, MHS  
Yangmin Chen, Pharm-D  
Caroline Chau, BS  
Lauren Sidow, BS  
Adam Ash, DO

Rapid Outpatient Setting Stress (ROSS) Clinical Research Organization, Saddle River, New Jersey

Section Editor: Rick A. McPheeters, DO

Submission history: Submitted January 9, 2017; Revision received April 24, 2017; Accepted April 19, 2017

Electronically published July 14, 2017

Full text available through open access at [http://escholarship.org/uc/uciem\\_cpchem](http://escholarship.org/uc/uciem_cpchem)

DOI: 10.5811/cpchem.2017.4.33539

We report a case of new-onset atrial fibrillation with rapid ventricular response in a 37-year-old male who presented to the emergency department. This patient was not admitted to the hospital or placed on observation, but rather placed on a cellular outpatient 12-lead telemetry (COTLT) device with emergency response capabilities and discharged home. We define a new modality that allows these patients to be managed via telemedicine and receive care similar to that which would be rendered in a hospital or observation unit. [Clin Pract Cases Emerg Med. 2017;1(3):242–245.]

## INTRODUCTION

Atrial fibrillation (AF) is the most prevalent supraventricular tachycardia encountered in current hospital practice.<sup>1,2</sup> Over the past 20 years there has been a 66% increase in hospital admissions for AF, and this growth is expected to continue due to the aging population, rising prevalence of chronic heart disease, and improvements in monitoring and diagnostic devices.<sup>3-7</sup> By 2050, the prevalence of AF in the United States is predicted to be between 5.6 and 12 million.<sup>8</sup> AF is also one of the most expensive conditions treated in U.S. hospitals today. In 2005, the national annual costs for AF treatment totaled approximately \$6.65 billion.<sup>6</sup> It is estimated that the current annual cost of treating one patient for AF in the U.S. is \$3,600. Hospitalization is the number one expense, followed by consultations, loss of work, and paramedical procedures.<sup>5</sup> Several new clinical strategies are being introduced to manage the cost of AF-related medical care, many involving the rapidly evolving field of telemedicine. We report a case of a patient with new-onset AF with rapid ventricular response (RVR) who presented to the emergency department (ED) and was managed via a cellular outpatient 12-lead telemetry (COTLT) device with emergency response capabilities in the outpatient setting, rather than being admitted to the hospital.

## CASE REPORT

A 37-year-old male with no significant past medical history presented to the ED with a chief complaint of heart palpitations. He appeared well and was hemodynamically stable. His electrocardiogram (ECG) showed AF with RVR at a rate of 129 beats per minute. Lab work, including a complete blood count and comprehensive metabolic panel were unremarkable, and his troponin was negative. He had a normal echocardiogram and received 30 mg of intravenous diltiazem over a four-hour period in the ED after which time he remained in AF with a heart rate in the 80s.

Our virtual hospital service, the Center for Remote Medical Management (CRMM), was consulted and the patient's care was transferred to two CRMM remote physicians (an internist and a cardiologist). He was given aspirin and 150 milligrams of oral diltiazem prior to leaving the hospital. We then used a COTLT device to manage his care from home.

The device includes technology in which a 12-lead ECG heart monitor tracks real-time telemetry data sent over 3G/4G/WIFI to be monitored remotely. In the event of an emergency, the patient's location can be pinpointed using geolocation, so that emergency services may be notified. This also allows for activation of the local catheterization lab, if necessary and available.

The patient applied the device, established a continuous connection with CRMM and was transported to his home. At home the patient had 49 episodes of AF with RVR (HR > 100 bpm), many of which were in close proximity to one another, for which the CRMM cardiologist was consulted and who directed the patient to take oral diltiazem. The image shows real-time monitoring and interpretation of one episode of home AF with RVR managed remotely by the cardiologist. All episodes of AF with RVR were rate controlled with oral diltiazem. Emergency response was never initiated. The patient was consented in writing prior to transfer of care to CRMM and is also registered with the Western Institutional Review Board.

Early the following morning while the patient was sleeping, he spontaneously converted to sinus rhythm as captured on remote telemetry. After sustained normal sinus rhythm a video cardiology consult was performed, for which non-emergent stress test and repeat echo were ordered. Given spontaneous cardioversion, lack of symptoms and lack of risk factors, the remote telemetry was discontinued and he was discharged from CRMM.

Follow-up at seven days revealed maintained sinus rhythm. The platform provided a reliable alternative to inpatient admission, with decreased cost, increased patient satisfaction, decreased exposure to nosocomial infections, and anticipated equivalent outcome of diagnostic results

## DISCUSSION

Within the rapidly emerging field of telemedicine, cardiac patients have become a major target population. There are increasing efforts to manage these patients in an outpatient setting by initiating remote cardiac management through implantable devices.<sup>9</sup> As depicted in this case, the patient was first treated with intravenous diltiazem to achieve rate control and sent home with a remote monitoring device.

There are no universally accepted guidelines or hospital admission criteria for patients with AF, and low-to-intermediate risk patients are often either unnecessarily admitted to the hospital, or discharged without monitoring prior to follow-up with a cardiologist. The patient in our case was low risk and likely could have been discharged home safely. However, even low-risk patients are frequently admitted to telemetry beds or placed unnecessarily in observation units. Additionally, we believe this technology to be of potential use in slightly higher risk patients, who still may not require hospital admission. We have also used it in low-risk chest pain patients.<sup>10</sup>

Previously, only monitoring devices have been employed in AF to reduce hospital visits and admissions. Holter monitors, for example, allow monitoring over a 24-hour to two-week period, but do not allow for remote transmission of information.<sup>9</sup> Continuous-loop monitoring is also available but is a more costly approach.<sup>9</sup> Subcutaneous devices have been increasing in popularity, but these are invasive and may result in procedural complications.<sup>12</sup>

### *CPC-EM Capsule*

What do we already know about this clinical entity?

*Although multiple devices exist for the outpatient monitoring of cardiac dysrhythmias, the majority of them are recorders that do not allow real-time analysis.*

What makes this presentation of disease presentable?

*We present a case of atrial fibrillation managed remotely with a real-time telemetry monitor that allowed real-time interventions.*

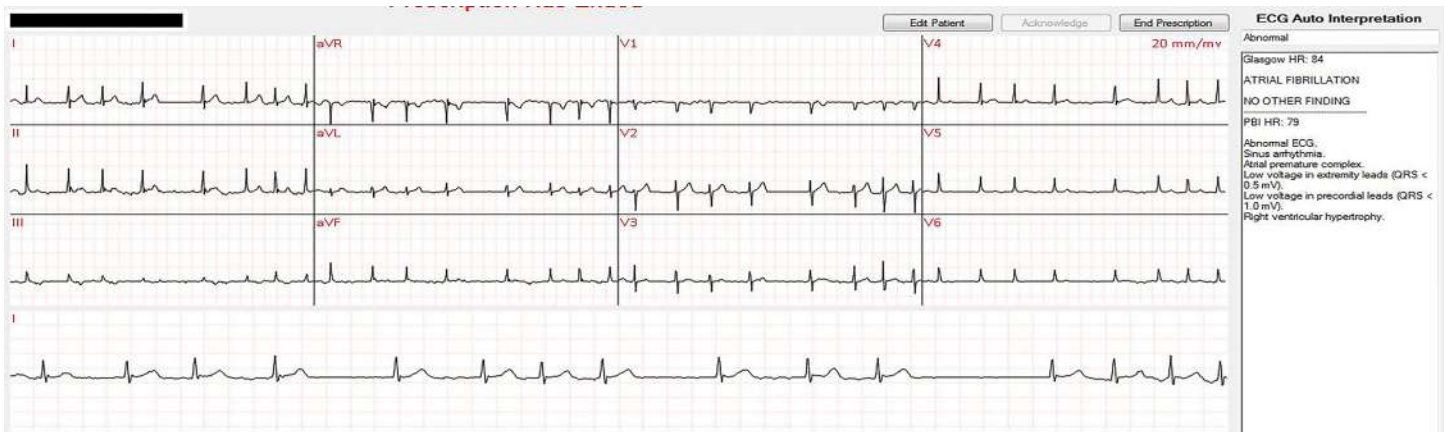
What is the major learning point?

*In the appropriate patient population, atrial fibrillation, and potentially other cardiac dysrhythmias, could be safely managed remotely via real-time telemetry monitors.*

How might this improve emergency medicine practice?

*Many low-to-intermediate risk patients with atrial fibrillation are unnecessarily admitted to hospitals. This strategy offers a safe alternative to admission in certain cases.*

In a study by Shacham et al. in 2010, establishing long-term connections with AF patients using a remote monitoring device resulted in 80% successful AF management out of the hospital, avoiding unnecessary facility visits.<sup>13</sup> Additionally, the accessibility of a call center encouraged a quicker response time in patients who were symptomatic. Larger European trials, such as the Clinical Evaluation of Remote Notification to Reduce Time to Clinical Decision (CONNECT) and Safely RedUceS RouTine Office Device Follow-Up (TRUST) trials, resulted in a significant reduction in office visits by up to 63%.<sup>14-16</sup> Furthermore, management with remote monitoring systems had a much lower cost compared to ambulatory care and reduced the risk of stroke via earlier detection of AF.<sup>17</sup> Patients felt reassured and more confident in their disease management with telemonitoring services.<sup>18</sup> In REFORM, a small randomized trial, remote monitoring resulted in abundant potential to maximize healthcare resources, including reduction in hospital visits, physician time, and cost of transport to counterbalance the cost of implementing new technology.<sup>9</sup>



**Image.** Telemetry monitoring with CardiacLinx platform exhibiting atrial fibrillation with rapid ventricular response at 135 beats per minute.

## CONCLUSION

With admissions replacement on a COTLT platform, it is possible to conduct medical operations that traditionally necessitate hospital admission (such as telemetric monitoring, serial cardiac enzymes, and other laboratory tests) outside of the facility, thus further reducing hospitalization rates and costs. These devices can provide continuous real-time communication between the patient and medical team, alert the nearest emergency medical services if necessary, and deliver the highest medical care based on the patient's own location. With this strategy, patient care is no longer limited by the facility to which the patient is admitted and will benefit from a broader range of options, enhancing the quality of medical management. Further research on this topic is needed to determine the subset of atrial fibrillation patients who will safely benefit from this technology.

*Address for Correspondence:* Alexander Chiu MD, MBA, Rapid Outpatient Setting Stress (ROSS) Clinical Research Organization 82 E. Allendale Road Suite 8A, Saddle River, NJ 07458. Email: Adamash4@gmail.com.

*Conflicts of Interest:* By the CPC-EM article submission agreement, all authors are required to disclose all affiliations, funding sources and financial or management relationships that could be perceived as potential sources of bias. The authors disclosed none.

*Copyright:* © 2017 Chiu et al. This is an open access article distributed in accordance with the terms of the Creative Commons Attribution (CC BY 4.0) License. See: <http://creativecommons.org/licenses/by/4.0/>

## REFERENCES

- King DE, Dickerson LM, Sack JL. Acute management of atrial fibrillation: Part I. Rate and rhythm control. *Am Fam Physician.* 2002;66(2):249-56.
- Sanoski CA and Bauman JL. Chapter 8. The Arrhythmias. In: DiPiro JT, Talbert RL, Yee GC, Matzke GR, Wells BG, Posey L. eds. *Pharmacotherapy: A Pathophysiologic Approach, 9e.* New York, NY: McGraw-Hill; 2014. Available at: <http://accesspharmacy.mhmedical.com.proxy.libraries.rutgers.edu/content.aspx?bookid=689&Sectionid=48811457>. Accessed July 3, 2015.
- Fuster V, Rydén LE, Cannom DS, et al. 2011 ACCF/AHA/HRS focused updates incorporated into the ACC/AHA/ESC 2006 Guidelines for the management of patients with atrial fibrillation: a report of the American College of Cardiology Foundation/American Heart Association Task Force on Practice Guidelines developed in partnership with the European Society of Cardiology and in collaboration with the European Heart Rhythm Association and the Heart Rhythm Society. *J Am Coll Cardiol.* 2011;57(11):e101-98.
- Zamani P, Verdino RJ. Management of Atrial Fibrillation. *J Intensive Care Med.* [Epub ahead of print]. 2014:1-15.
- Heist EK, Mansour M, Ruskin JN. Rate control in atrial fibrillation: targets, methods, resynchronization considerations. *Circulation.* 2011;124(24):2746-55.
- January CT, Wann LS, Alpert JS, et al. 2014 AHA/ACC/HRS guideline for the management of patients with atrial fibrillation: executive summary: a report of the American College of Cardiology/American Heart Association Task Force on practice guidelines and the Heart Rhythm Society. *Circulation.* 2014;130(23):2071-104.
- Decker WW, Smars PA, Vaidyanathan L, et al. A prospective, randomized trial of an emergency department observation unit for acute onset atrial fibrillation. *Ann Emerg Med.* 2008;52(4):322-8.
- Go AS, Mozaffarian D, Roger VL, et al. Heart disease and stroke

- statistics--2014 update: a report from the American Heart Association. *Circulation*. 2014;129(3):e28-e292.
9. Varma N, Ricci RP. Telemedicine and cardiac implants: what is the benefit? *Eur Heart J*. 2013;34(25):1885.
  10. Chiu A, Shumaker K, Del Corral C, et al. Remote management of low to intermediate risk chest pain: A case series. *Am J Emerg Med*. 2017 Feb 16 (Epub ahead of print). Available at: <http://www.rossmedco.com/press-releases/>. Accessed March 2, 2017.
  11. Gussak I, Vukajlovic D, Vuckcevic V, et al. Wireless remote monitoring of reconstructed 12-lead ECGs after ablation for atrial fibrillation using a hand-held device. *J Electrocardiol*. 2012;45(2):129-35.
  12. Shacham J, Birati EY, Malov N, et al. Telemedicine for diagnosing and managing paroxysmal atrial fibrillation in outpatients. The phone in the pocket. *Int J Cardiol*. 2012;157(1):91-5.
  13. Crossley GH, Boyle A, Vitense H, et al. The CONNECT (Clinical Evaluation of Remote Notification to Reduce Time to Clinical Decision) trial: the value of wireless remote monitoring with automatic clinician alerts. *J Am Coll Cardiol*. 2011;57(10):1181-9.
  14. Varma N, Epstein AE, Irimpen A, et al. Efficacy and safety of automatic remote monitoring for implantable cardioverter-defibrillator follow-up: the Lumos-T Safely Reduces Routine Office Device Follow-up (TRUST) trial. *Circulation*. 2010;122(4):325-32.
  15. Dubner S, Auricchio A, Steinberg JS, et al. ISHNE/EHRA expert consensus on remote monitoring of cardiovascular implantable electronic devices (CIEDs). *Europace*. 2012;14(2):278-93.
  16. Lorenzoni G, Folino F, Soriani N, et al. Cost-effectiveness of early detection of atrial fibrillation via remote control of implanted devices. *J Eval Clin Pract*. 2014;20(5):570-7.
  17. Dimengo J, Stegall G. Team-Based Care for External Telemonitoring in Patients with Heart Failure. *Heart Fail Clin*. 2015;11(3):451-65.



# Lightning Burns and Electrical Trauma in a Couple Simultaneously Struck by Lightning

Stephanie A. Eyerly-Webb, PhD  
Rachele Solomon, MPH  
Seong K. Lee, MD  
Rafael Sanchez, MD  
Eddy H. Carrillo, MD  
Dafney L. Davare, MD, MBA  
Chauniqua Kiffin, MD  
Andrew Rosenthal, MD, MBA

Memorial Regional Hospital, Division of Acute Care Surgery and Trauma,  
Hollywood, Florida

Section Editor: Rick A. McPheeters, DO

Submission history: Submitted January 23, 2017; Revision received April 13, 2017; Accepted April 19, 2017

Electronically published July 17, 2017

Full text available through open access at [http://escholarship.org/uc/uciem\\_cpccem](http://escholarship.org/uc/uciem_cpccem)

DOI: 10.5811/cpcem.2017.4.33706

More people are struck and killed by lightning each year in Florida than any other state in the United States. This report discusses a couple that was simultaneously struck by lightning while walking arm-in-arm. Both patients presented with characteristic lightning burns and were admitted for hemodynamic monitoring, serum labs, and observation and were subsequently discharged home. Despite the superficial appearance of lightning burns, serious internal electrical injuries are common. Therefore, lightning strike victims should be admitted and evaluated for cardiac arrhythmias, renal injury, and neurological sequelae. [Clin Pract Cases Emerg Med. 2017;1(3):246–250.]

## INTRODUCTION

In the United States, the National Weather Service estimates the odds of being struck by lightning in a given year as approximately one in a million. In Florida, the heat and humidity of the subtropical climate creates optimal conditions for thunderstorms; the density of lightning strikes is approximately 30 strikes/km<sup>2</sup> per year, relatively high on the global scale and the highest in the U.S.<sup>1</sup> The risk presented by this high strike density in conjunction with the large population density and favorable climate for outdoor and water activities has earned Florida the reputation as the “Lightning Capital of the United States.”<sup>2,3</sup> Although being struck by lightning is considered an uncommon occurrence, Florida has more than twice as many lightning-related casualties and fatalities than any other state and averages approximately 10 fatalities per year.<sup>3,4</sup>

While several published case reports describe the injuries of individuals struck by lightning, this report presents a couple that was simultaneously struck by lightning while walking arm-in-arm in the rain holding an umbrella between them. Their unique lightning burns and treatment are discussed.

## CASE PRESENTATION

### Patient 1

A 40-year-old male was struck by lightning while walking in a rainstorm holding an umbrella in an open parking lot. He presented with superficial and partial thickness cutaneous injuries. He recalled falling to his knees and losing sensation in his left leg and subsequently suffered loss of consciousness for a very short period of time post-strike.

The patient presented, alert, oriented, and responsive with a Glasgow Coma Score (GCS) of 15, but complained of diffuse pain. His vitals were normal and he was in normal sinus rhythm (NSR) with no heart murmurs. A focused assessment with sonography for trauma (FAST) and abdominal examination were negative and there was no evidence of compartment syndrome or internal injury. Chest and pelvic radiography as well as computed tomography (CT) of the head and cervical spine were normal.

He sustained multiple burn injuries, including superficial burns on the anterior trunk and legs (Image 1). Small abrasions were also observed above the scrotum area and the left nipple, and partial thickness punctate burns were observed on the anterior left thigh and over the left nipple (Images 1A and 1B). Minor

superficial thermal contact burns were observed below his belt buckle (Image 1A). Superficial flash burns were also observed on the patient's trunk and anterior thighs, and ecchymosis was observed on the patient's knees, resulting from his fall to the ground. Distinct Lichtenberg figure lesions were observed on the anterior right thigh (Image 1A) as well as on the right and left lateral thighs (Image 1C). The patient also presented with an open wound on the left lateral ankle; his shoe had been burnt and blown off by the strike.

The patient tested positive for blood (3+) and albumin (1+) in the urine, and was diagnosed with myoglobinuria and admitted to the intensive care unit for hemodynamic monitoring and resuscitation. The patient's troponin-T, creatinine kinase myocardial b fraction (CK-MB), and total CK levels were monitored to identify any cardiac or global muscle damage. His total CK levels were elevated (1,654 unit/L) upon arrival and trended down over his 68-hour hospital course. Troponin-T and CK-MB levels remained normal. The patient remained neurologically intact with no sequelae and was subsequently discharged home.

## Patient 2

A 30-year-old female was simultaneously struck by lightning while holding the umbrella with Patient 1. She sustained small partial thickness burns to the right cheek and the inside of her right index finger where she was holding the umbrella. Lichtenberg figure lesions were observed on the patient's chest (Image 2A). The patient was alert and oriented with a GCS of 15 on arrival.

She presented with normal vital signs. There was no evidence of compartment syndrome and a FAST scan and abdominal examination were normal. Radiography of the chest and pelvic area as well as CTs of the head and cervical spine were normal.

The patient was mildly tachycardic (~100 beats per minute) on arrival with complaint of "pressure"-like discomfort in her chest despite having a normal rhythm (Image 2B), no heart murmurs, and normal troponin-T and CK-MB levels. She was admitted to the hospital for monitoring. Serum labs at six and nine hours showed slightly elevated troponin-T (troponin-T<sub>6hr</sub> = 0.05 ng/mL, troponin-T<sub>9hr</sub> = 0.02 ng/mL) and CK-MB (CK-MB<sub>9hr</sub> = 5.6 ng/mL) levels and a follow-up electrocardiogram (ECG) exhibited an abnormal ST-segment, all of which could be predictive of an adverse cardiac event (Image 2C). Her total CK-MB levels returned to normal range within 24 hours, and the ECG returned to normal before discharge. Her CK total levels were slightly elevated (>300 unit/L) but returned to normal. She remained neurologically intact and was discharged with no sequelae after 66 hours.

## DISCUSSION

A lightning strike creates a short duration (10-100 ms) discharge circuit (30,000-50,000A) between the clouds and

### CPC-EM Capsule

What do we already know about this clinical entity?

*Lightning injuries, although rare, are serious and life-threatening. While risk is somewhat geographical, lightning-related injuries have the potential to affect large populations.*

What makes this presentation of disease reportable?

*This report illustrates the case of a couple simultaneously struck by lightning, which has rarely been reported.*

What is the major learning point?

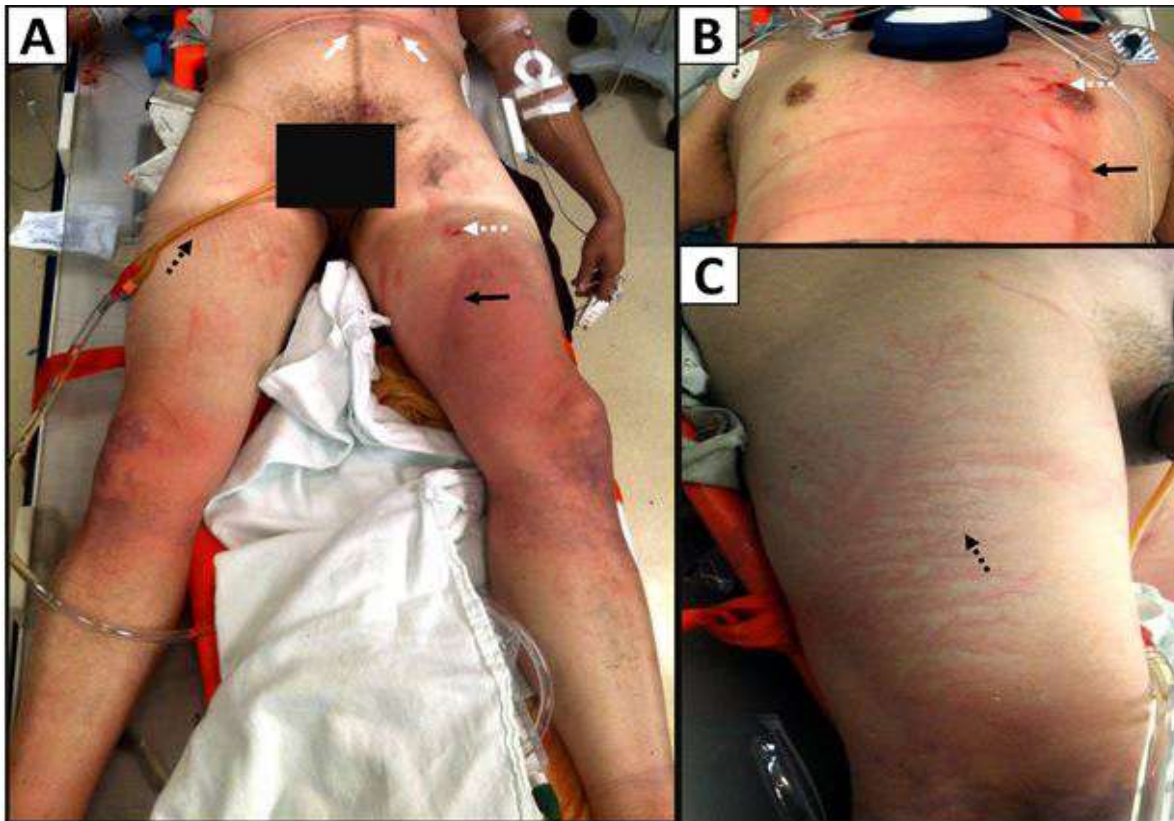*A single lightning strike can inflict both external and internal injuries on multiple patients; all injuries require timely diagnosis and treatment.*

How might this improve emergency medicine practice?

*Although most clinicians will never treat a patient struck by lightning, they must be prepared to recognize and treat this potentially lethal injury.*

strike location.<sup>5-7</sup> Peak discharge point is typically 2-5 cm in diameter and spreads radially across the strike surface.<sup>8</sup> Direct lightning strikes are uncommon and often fatal and comprise approximately 5% of strike events.<sup>6,9</sup> The vast majority of lightning-related injuries are indirect.<sup>6,9</sup> Indirect injury methods include the following: 1) side flash or "splash" contact injury, where the victim is in contact with the struck object, 2) ground current, where the current passes across the victim from a nearby ground strike point, and 3) blast injury from sonic-wave thunder, which includes primary injury methods such as sonic rupture of tympanic membranes or tertiary injury methods such as blunt trauma if the victim falls or is thrown.<sup>5,7,9</sup> Ultimately 10-30% of lightning strike victims die, and most deaths are either immediate or due to cardiac or respiratory arrest.<sup>5,7,9,10</sup>

Lightning strike victims often present with cutaneous injuries, which include linear or flash burns, punctate burns, thermal burns, or Lichtenburg figure lesions. Linear flash burns are in effect scald burns caused by the rapid heating and evaporation of water from the surface of the skin. These burns are often superficial and occur where there is moisture (sweat, rain) on the skin.<sup>5,10</sup> Punctate burns are small, circular burns



**Image 1.** Cutaneous injuries on patient one: (A) Small superficial thermal burns where the patient's belt buckle contacted the skin (white arrows). Lichtenberg figure lesions on anterior right thigh (black dotted arrow). Superficial punctate burn on left anterior thigh (white dotted arrow). Dark linear flash burn on left anterior thigh (black arrow). Dark purple ecchymosis is visible on the patient's knees from his fall to the ground after the strike; (B) Superficial linear flash burn (black arrow), punctate burns (white dotted arrow), and small abrasions over left nipple; (C) Lichtenberg figure lesions on the lateral right thigh (black dotted arrow).

that can be superficial or full thickness. They are typically very small and do not require medical treatment.<sup>7,11</sup> Patients struck by lightning may also suffer serious thermal burns from metallic accessories or objects contacting their skin. The short contact duration (tens of milliseconds) and relatively high resistance of the epidermis often prevents significant direct tissue heating damage due to the electrical current alone; but the strike can quickly heat any metallic objects, such as a necklace or belt buckle, that in turn can cause severe thermal contact burns.<sup>7,12-14</sup> Thermal burns may also occur if a victim's clothing ignites.

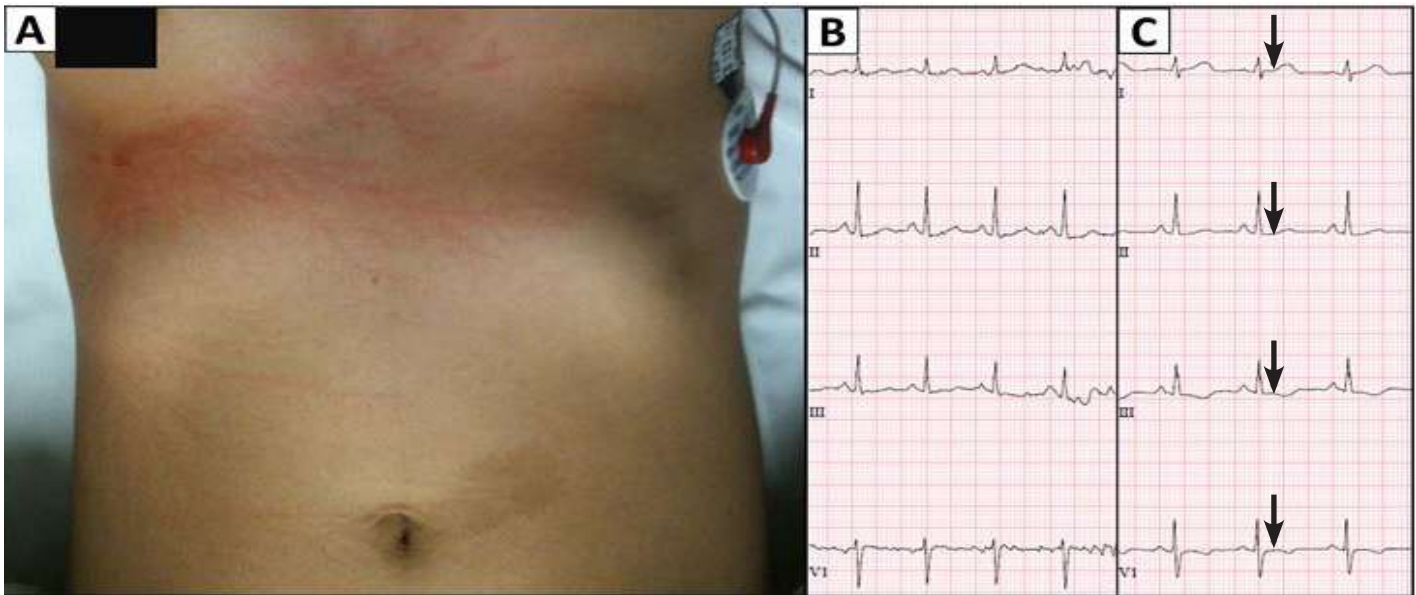
A less common cutaneous injury unique to lightning strike victims are unusual superficial lesion patterns known as Lichtenberg figures. They are also known as arborization or "fern," "feathering" lesions based on their unique fractal appearance.<sup>4-7</sup> Lichtenberg figure lesions are exclusively caused by lightning and are not technically burns, as they are not thermal injuries and the dermis and epidermis remain intact.<sup>4,10</sup> Rather, the lightning energy spreads in a fractal pattern across the skin, which causes a transient extravasation of blood and subsequent discoloration in the subcutaneous

tissue.<sup>4,10</sup> These dramatic marks typically fade within days as the tissue returns to normal. Overall, the short duration of the lightning strike and high resistance of the skin results in minimal cutaneous damage; lightning burns and lesions are typically minor, superficial, and require little treatment.<sup>5,6,10,14</sup>

Despite the superficial appearance of burns on lightning strike victims, occult internal electrical injuries can be deadly and do not correlate with the severity of cutaneous injuries. Internal muscles and organs are highly conductive and can be severely damaged by the energy of the strike.<sup>10,14</sup> For example, immediate cardiorespiratory arrest or ventricular fibrillation cardiac arrest are the primary causes of death for lightning strike victims.<sup>10,15</sup> Lightning strikes can also cause acute cardiovascular conditions such as arrhythmias, myocardial ischemia, and even myocardial contusion.<sup>7,14-17</sup> Monitoring the patient's ECG and cardiac enzymes such as troponin-T and CK-MB may be useful for determining the extent of myocardial damage inflicted by the electrical trauma.<sup>14-16,18</sup>

In addition to cardiac complications, 3-15% of lightning strike victims may develop acute renal failure.<sup>19</sup> The electrical trauma of the strike can cause severe muscle damage along





**Image 2.** (A) Lichtenberg figure lesions on the chest; (B) Normal electrocardiogram upon admittance; (C) Subsequent electrocardiogram nine hours after admittance demonstrating abnormal ST-segments and inverted T-waves (arrows).

the conduction pathway; when this necrotic muscle tissue breaks down it releases excessive amounts of toxic muscle-cell components, such as CK, into circulation.<sup>19</sup> This can lead to myoglobinuria and potentially catastrophic renal failure.<sup>7,15,19</sup> Patient total CK levels have been shown to predict the amount of muscle injury and should be monitored to prevent lasting renal issues.<sup>18,19</sup> Sensory damage (eye, ear) and neurological sequelae, such as hypoxic ischemic neuropathy, intracranial hemorrhage, motor neuron disease, and movement disorders, are also common in strike victims.<sup>5-10,14,20</sup> Thorough follow-up for all these potential complications is recommended as approximately 75% of strike survivors are at risk of long-term or permanent sequelae.<sup>5,10</sup>

## CONCLUSION

The National Weather Service advises everyone to immediately seek shelter if lightning and thunder are present, and asserts that remaining outside during a storm places individuals at greater risk. Prevention measures should be taken seriously in Florida, which consistently has the largest number of lightning strike casualties and fatalities in the nation due to frequent tropical storms and enthusiasm for outdoor leisure activities. If struck by lightning, an individual can suffer a multitude of serious external and internal injuries. Strike victims should be admitted and evaluated for long-term issues such as cardiac arrhythmias, renal injury and myoglobinuria, sensory damage, and neurological sequelae.

*Address for Correspondence:* Andrew Rosenthal, MD. Memorial Regional Hospital, Division of Acute Care Surgery and Trauma, 3501 Johnson Street, Hollywood, FL 33021. Email: anrosenthal@mhs.net.

*Conflicts of Interest:* By the CPC-EM article submission agreement, all authors are required to disclose all affiliations, funding sources and financial or management relationships that could be perceived as potential sources of bias. The authors disclosed none.

*Copyright:* © 2017 Eyerly-Webb et al. This is an open access article distributed in accordance with the terms of the Creative Commons Attribution (CC BY 4.0) License. See: <http://creativecommons.org/licenses/by/4.0/>

## REFERENCES

1. Christian HJ, Blakeslee RJ, Boccippio DJ, et al. Global frequency and distribution of lightning as observed from space by the Optical Transient Detector. *J Geophys Res.* 2003;108(D1):ACL 4-1-ACL 4-15.
2. Jensenius Jr JS. A detailed analysis of lightning deaths in the United States from 2006 through 2014. National Weather Service NOAA. 2015.
3. Curran EB, Holle RL, López RE. Lightning casualties and damages in the United States from 1959 to 1994. *J Climate.* 2000;13(19):3448-64.
4. Resnik BI, Wetli CV. Lichtenberg Figures. *Am J Forensic Med Pathol.* 1996;17(2):99-102.



5. Ritenour AE, Morton MJ, McManus JG, Barillo DJ, Cancio LC. Lightning injury: a review. *Burns*. 2008;34(5):585-94.
6. Cooray V, Cooray C, Andrews CJ. Lightning caused injuries in humans. *J Electrostat*. 2007;65(5-6):386-394.
7. O'Keefe Gatewood M, Zane RD. Lightning injuries. *Emerg Med Clin North Am*. 2004;22(2):369-403.
8. Bier M, Chen W, Bodnar E, Lee RC. Biophysical injury mechanisms associated with lightning injury. *Neurorehabilitation*. 2005;20(1):53-62.
9. Pfortmueller CA, Yikun Y, Haberkern M, et al. Injuries, sequelae, and treatment of lightning-induced injuries: 10 years of experience at a Swiss trauma center. *Emerg Med Int*. 2012;2012:167698.
10. Forster SA, Silva IM, Ramos MLC, et al. Lightning burn - Review and case report. *Burns*. 2013;39(2):e8-e12.
11. Fahmy FS, Brinsden MD, Smith J, et al. Lightning: the multisystem group injuries. *J Trauma Acute Care Surg*. 1999;46(5):937-40.
12. Herrero F, Garcia-Morato V, Salinas V, et al. An unusual case of lightning injury: a melted silver necklace causing a full thickness linear burn. *Burns*. 1995;21(4):308-9.
13. Bayramoglu AA, Uzkeser M, Kamaci U. Lichtenberg Figures. *Duzce Medical Journal*. 2012;14(3).
14. Cooper MA. Emergent care of lightning and electrical injuries. *Semin Neurol*. 1995;15(3):268-78.
15. McIntyre WF, Simpson CS, Redfearn DP, et al. The lightning heart: a case report and brief review of the cardiovascular complications of lightning injury. *Indian Pacing Electrophysiol J*. 2010;10(9):429-34.
16. Lichtenberg R, Dries D, Ward K, Marshall W, Scanlon P. Cardiovascular effects of lightning strikes. *J Am Coll Cardiol*. 1993;21(2):531-6.
17. Dundon BK, Puri R, Leong DP, Worthley MI. Takotsubo cardiomyopathy following lightning strike. *BMJ Case Reports*. 2009;2009:bcr0320091646.
18. Teodoreanu R, Popescu S, Lascar I. Electrical injuries. Biological values measurements as a prediction factor of local evolution in electrocutions lesions. *J Med Life*. 2014;7(2):226.
19. Okafor UV. Lightning injuries and acute renal failure: a review. *Ren Fail*. 2005;27(2):129-34.
20. Cherington M, Yarnell P, London S. Neurologic complications of lightning injuries. *West J Med*. 1995;162(5):413.

## A Case of Erythema Nodosum with Coccidioidomycosis

Saema Said, BS  
Justin Yanuck, MD, MS-BATS  
Michael J. Burns, MD

University of California Irvine School of Medicine, Department of Emergency  
Medicine, Irvine, California

Section Editor: Rick A. McPheeters, DO

Submission history: Submitted; Submitted November 16, 2017; Revision received March 6, 2017; Accepted March 30, 2017

Electronically published July 14, 2017

Full text available through open access at [http://escholarship.org/uc/uciem\\_cpem](http://escholarship.org/uc/uciem_cpem)

DOI: 10.5811/cpem.2017.3.33177

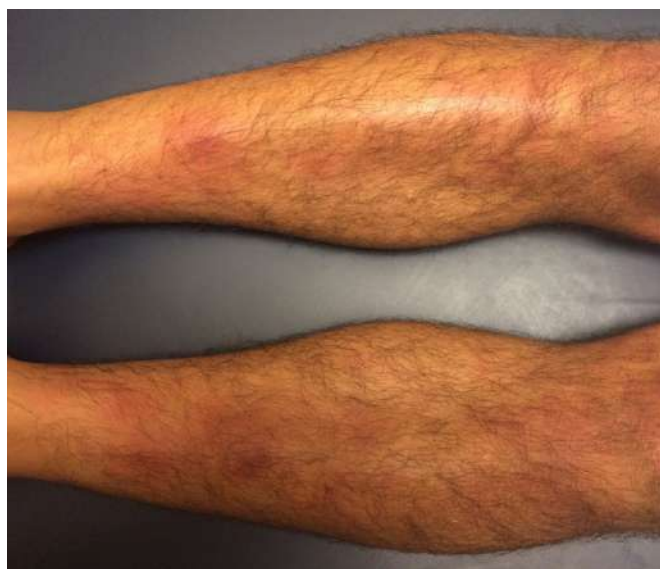Erythema nodosum (EN) is associated with many systemic diseases and infections. This case report provides an image of erythematous nodules, an overview of the various causes of EN, and the laboratory tests and imaging that can be done in the emergency department to narrow its broad differential diagnosis. [Clin Pract Cases Emerg Med.2017;1(3):251–252.]

### CASE PRESENTATION

A 26-year-old male presented to an emergency department (ED) in Southern California with two days of symmetrical, erythematous, and painful subcutaneous nodules. The nodules began on his thighs and spread to his anterior lower legs (Image). He also complained of two weeks of fever, cough, arthralgia, generalized weakness, and dyspnea, and had right upper-lobe consolidation and mediastinal adenopathy on imaging. He had been seen in the ED two weeks earlier for these symptoms and discharged with azithromycin. Since his initial visit, he had no improvement of symptoms with azithromycin and had newly developed leg lesions. Further evaluation as an inpatient confirmed the diagnosis of erythema nodosum (EN) caused by acute coccidioidomycosis. He was started on fluconazole with outpatient follow-up.

### DISCUSSION

EN is a panniculitis resulting from a delayed hypersensitivity reaction.<sup>1</sup> It presents as tender, warm, and erythematous nodules, usually on the anterior legs.<sup>2</sup> The nodules are symmetric and 1-5 cm in diameter.<sup>1</sup> EN is often preceded 1-3 weeks by a prodrome of fever, malaise, arthralgia, cough, and weight loss.<sup>3</sup> Additional signs and symptoms vary depending on etiology. Although most cases are idiopathic, EN is also associated with various infections (*Streptococcus pyogenes*, yersiniosis, *Chlamydia*, histoplasmosis, coccidioidomycosis, tuberculosis, *Campylobacter*), drugs (estrogens/oral contraceptives, sulfonamides, penicillin), systemic illnesses such as



**Image.** Erythematous nodules on bilateral anterior legs.

inflammatory bowel disease and sarcoidosis, pregnancy, and malignancy.<sup>3</sup> Differential diagnosis includes  $\alpha_1$ -antitrypsin deficiency, cytophagic histiocytic panniculitis, lupus panniculitis, and nodular fat necrosis.<sup>4</sup> Tests performed in the workup of EN should depend on the patient's geographic location, travel history, and presenting symptoms.<sup>4</sup> For example, patients with EN and upper respiratory symptoms in the western United States should be tested for

coccidioidomycosis. EN is self-limited; however, nonsteroidal anti-inflammatory drugs and measures, such as leg rest, elevation, and compression, can reduce pain and edema.<sup>1,3</sup> Definitive management is treatment of underlying trigger.

---

*Address for Correspondence:* Saema Said, BS, University of California Irvine School of Medicine, Department of Emergency Medicine, 333 City Blvd. West, Suite 640, Orange, CA 92868. Email: saemas@uci.edu.

*Conflicts of Interest:* By the CPC-EM article submission agreement, all authors are required to disclose all affiliations, funding sources and financial or management relationships that could be perceived as potential sources of bias. The authors disclosed none.

*Copyright:* © 2017 Said et al. This is an open access article distributed in accordance with the terms of the Creative Commons Attribution (CC BY 4.0) License. See: <http://creativecommons.org/licenses/by/4.0/>

---

## REFERENCES

1. Blake T, Manahan M, Rodins K. Erythema nodosum - a review of an uncommon panniculitis. *Dermatol Online J.* 2014;20(4):22376.
2. González-Gay MA, García-Porrúa C, Pujol RM, et al. Erythema nodosum: a clinical approach. *Clin Exp Rheumatol.* 2001;19(4):365-8.
3. Gilchrist H, Patterson JW. Erythema nodosum and erythema induratum (nodular vasculitis): diagnosis and management. *Dermatol Ther.* 2010;23(4):320-7.
4. Schwartz RA, Nervi SJ. Erythema nodosum: a sign of systemic disease. *Am Fam Physician.* 2007;75(5):695-700.

### *CPC-EM Capsule*

What do we already know about this clinical entity?

*Erythema nodosum (EN) presents as tender, erythematous cutaneous nodules. It can be idiopathic or associated with various infections, systemic diseases, and drugs.*

What is the major impact of the image(s)?

*The image in this case report demonstrates the classic findings seen with EN: symmetrical, erythematous nodules on anterior lower legs.*

How might this improve emergency medicine practice?

*Given the broad spectrum of conditions associated with EN, this case report addresses how to recognize and efficiently workup EN in the emergency department.*

## Paratracheal Cysts

Mohammad R. Mohebibi, MD\*  
Chadd K. Kraus, DO, DrPH, MPH†

\* University of Missouri-Columbia, Department of Emergency Medicine, Columbia, Missouri

† Geisinger Health System, Department of Emergency Medicine, Danville, Pennsylvania

Section Editor: Rick A. McPheeters, DO

Submission history: Submitted December 8, 2016; Revision received January 25, 2017; Accepted February 23, 2017

Electronically published July 6, 2017

Full text available through open access at [http://escholarship.org/uc/uciem\\_cpem](http://escholarship.org/uc/uciem_cpem)

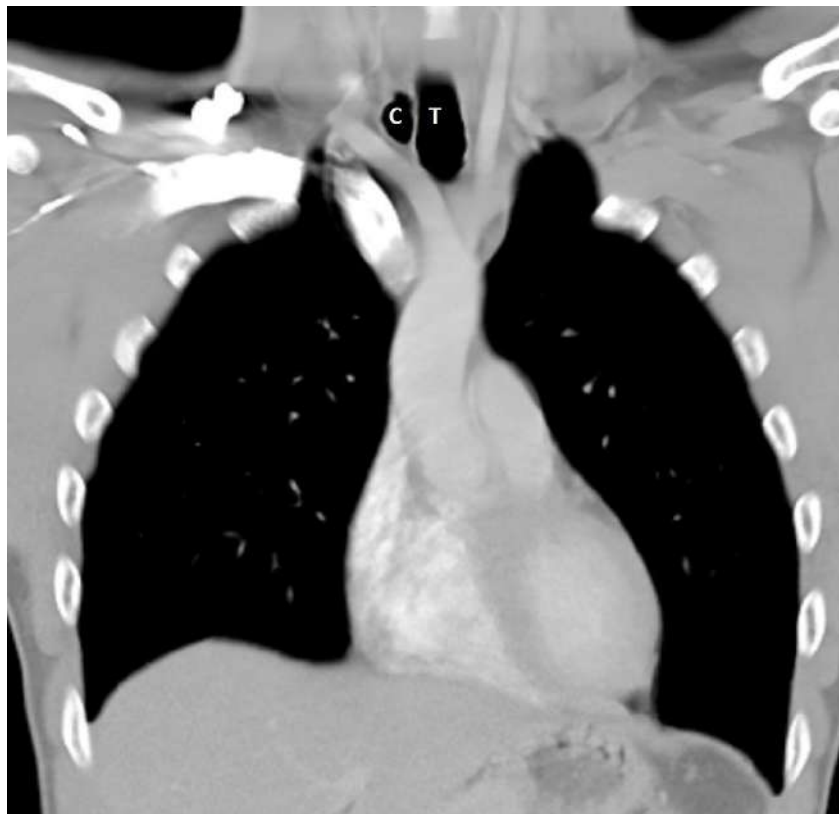DOI: 10.5811/cpcem.2017.2.33297

[Clin Pract Cases Emerg Med. 2017;1(3):253–255.]

### CASE PRESENTATION

A 38-year-old male with no significant past medical history presented to the emergency department with pain and swelling on the left mandibular area and the right upper quadrant of the abdomen after a reported assault in which he was punched in the face and kicked in the right chest wall during a fight at a bar. The patient reported that he had been drinking alcohol but denied loss of consciousness. Vital signs were within normal limits and physical exam was otherwise

unremarkable. Due to the patient's history and intoxication, computed tomography (CT) of the head, cervical spine, chest and abdomen were obtained and were unremarkable with the exception of a collection of air on the right side of the upper trachea and anterior to the right lung apex (Image 1). It did not seem to communicate with either the lung or trachea and there was no evidence of lung tissue in the air collection in the lung window images (Image 2). However, the patient had reported trauma to the right chest/abdominal wall. After consulting the



**Image 1.** Right-sided paratracheal cyst in the thoracic outlet.  
T, trachea; C, paratracheal cyst.



otolaryngology and pulmonology services, a conclusion was made that this was an incidental finding of paratracheal cyst and unrelated to the trauma reported by the patient.

## DISCUSSION

Right paratracheal cysts are a common finding on CT and are reported in just under 4% of the United States population.<sup>1</sup> In the setting of trauma, paratracheal cysts can mimic pneumomediastinum. The nature of the paratracheal cyst is diverse; however, they could be considered to be tracheal diverticula,<sup>2</sup> although a tract to the trachea or tracheal mucosal is not always found on bronchoscopy. There is a potential association of paratracheal cysts with obstructive lung disease<sup>1,2</sup> and chronic cough,<sup>3</sup> although the cysts have been found in pediatric patients as well.<sup>1,4</sup> Paratracheal cysts are usually an incidental finding on CT imaging. It is important for emergency physicians to be aware of this entity and be mindful of this benign finding, especially in the setting of trauma, where it could be confused with an injury depending on the history, mechanism of injury and clinical exam. The anatomic location of the cysts could also complicate certain procedures such as central venous catheterization of the internal jugular vein or make these procedures more difficult.

### *CPC-EM Capsule*

What do we already know about this clinical entity?

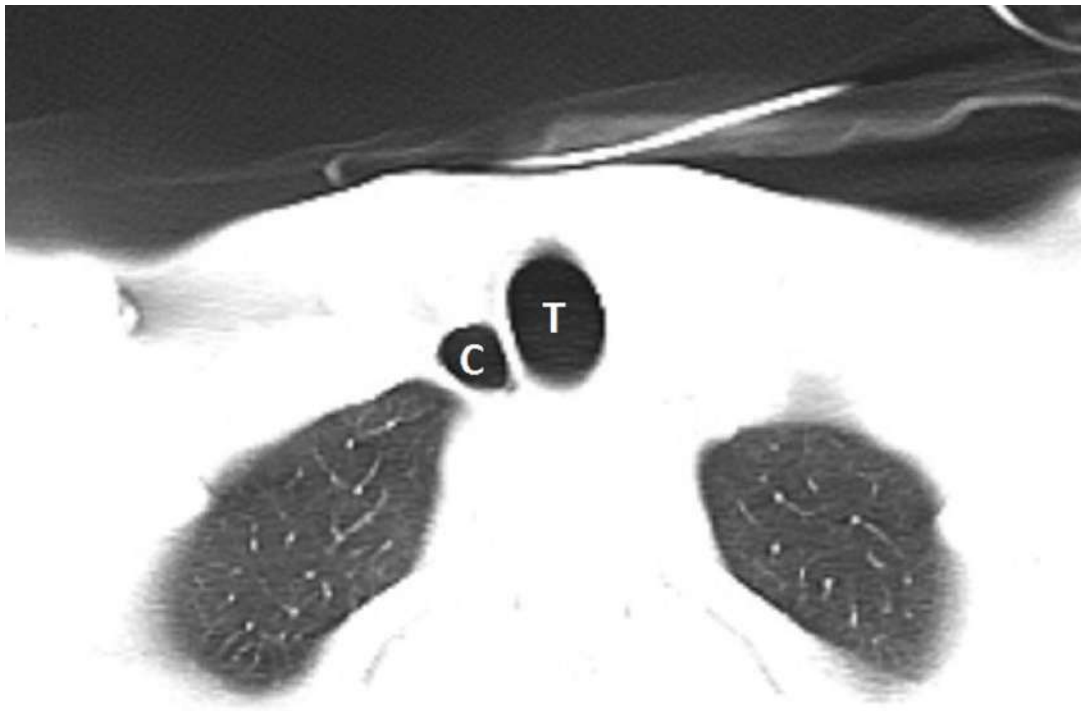
*Paratracheal cysts are a common finding on CT. They can mimic pneumomediastinum. There is a potential association with chronic obstructive pulmonary disease, and chronic cough. The cysts have also been reported in children.*

What is the major impact of the image(s)?

*This incidental benign finding can be a diagnostic dilemma in the setting of trauma and could be confused with an acute injury.*

How might this improve emergency medicine practice?

*Emergency physicians should be mindful of this benign finding, especially in the setting of trauma. The anatomic location of the cysts may also complicate procedures such as internal jugular line placement.*



**Image 2.** No evidence of lung tissue in the air collection in the lung window image. T, trachea; C, paratracheal cyst.

---

*Address for Correspondence:* Mohammed Reza Mohebbi, MD, University of Missouri-Columbia, 1 Hospital Dr, Columbia, MO 65212. Email: mrmohebbi@gmail.com.

*Conflicts of Interest:* By the CPC-EM article submission agreement, all authors are required to disclose all affiliations, funding sources and financial or management relationships that could be perceived as potential sources of bias. The authors disclosed none.

*Copyright:* © 2017 Mohebbi et al. This is an open access article distributed in accordance with the terms of the Creative Commons Attribution (CC BY 4.0) License. See: <http://creativecommons.org/licenses/by/4.0/>

---

## REFERENCES

1. Buterbaugh JE, Erly WK. Paratracheal air cysts: a common finding on routine CT examinations of the cervical spine and neck that may mimic pneumomediastinum in patients with traumatic injuries. *AJNR Am J Neuroradiol.* 2008;29(6):1218-21.
2. Goo JM, Im JG, Ahn JM, et al. Right paratracheal air cysts in the thoracic inlet: clinical and radiologic significance. *AJR Am J Roentgenol.* 1999;173(1):65-70.
3. Infante M, Mattavelli F, Valente M, et al. Tracheal diverticulum: a rare cause and consequence of chronic cough. *Eur J Surg.* 1994;160(5):315-6.
4. Early EK, Bothwell MR. Congenital tracheal diverticulum. *Otolaryngol Head Neck Surg.* 2002;127(1):119-21.

# Moyamoya: A Rare Cause of Cerebral Vascular Accident

Brian Merritt, BS\*  
 Matt Pitzer, DO†  
 Robyn King, DO†  
 John Ashurst, DO, MSc†

\* Lake Erie College of Osteopathic Medicine, Erie, Pennsylvania  
 † Duke LifePoint Conemaugh Memorial Medical Center, Department of Emergency  
 Medicine, Johnstown, Pennsylvania

Section Editor: Rick A. McPheeters, DO  
 Submission history: Submitted September 14, 2016; Revision received January 27, 2017; Accepted February 22, 2017  
 Electronically published May 24, 2017  
 Full text available through open access at [http://escholarship.org/uc/uciem\\_cpchem](http://escholarship.org/uc/uciem_cpchem)  
 DOI: 10.5811/cpchem.2017.2.32483  
 [Clin Pract Cases Emerg Med. 2017;1(3):256–257.]

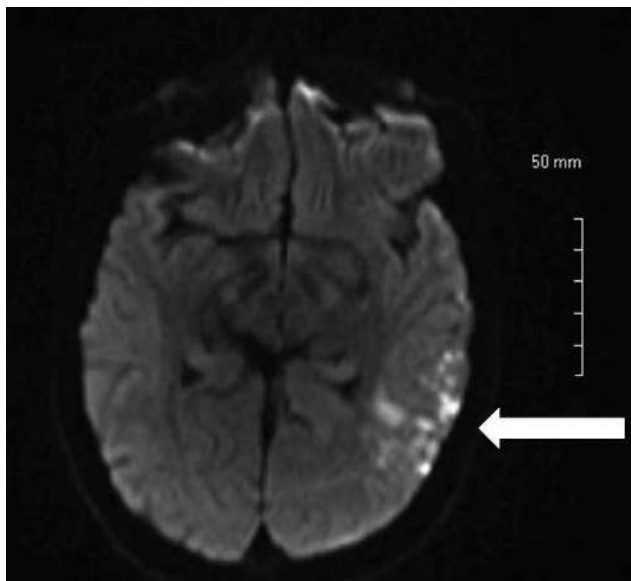
## CASE REPORT

A 20-year-old Caucasian female presented with an altered mental status that began one day prior to arrival. The patient claimed to know the answers to questions, but was only able to reply with the answers of “yes” or “I don’t know.” Her past medical history consisted of aortic insufficiency. Her pulse was 109, with a blood pressure of 144/99. Neurological exam revealed that she had expressive aphasia but no facial droop, localized weakness or sensory deficits. A computed tomography of the head showed no acute intracranial hemorrhage, but did show areas of decreased attenuation within the deep white matter of the left frontal lobe without discernible mass effect. A magnetic resonance image (MRI) of

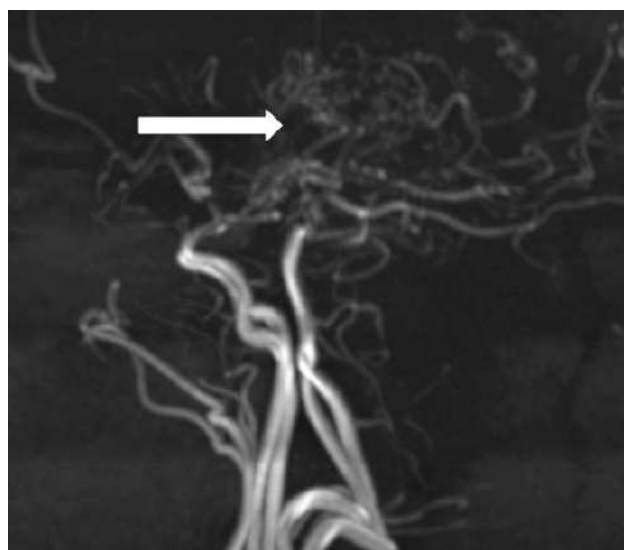
the brain showed multiple foci of subacute infarcts (Image 1), while an MR angiogram (MRA) revealed stenosis involving the A1, M1, and P1 segments bilaterally (Image 2).

## DISCUSSION

Moyamoya disease (MMD) is an occlusive cerebrovascular disease characterized by stenosis of the terminal aspect of the internal carotid artery and an abnormal network of basal vessels.<sup>1</sup> The etiology of MMD is unknown, but both congenital and acquired processes may play a role in its development. The incidence of disease is 4.6 times higher in Asian Americans as compared to their Caucasian counterparts and shows a predominance



**Image 1.** MRI of the brain showing multiple foci of subacute infarcts.  
*MRI*, Magnetic resonance imaging



**Image 2.** MRA of the brain depicting the classic “puff of smoke” with associated stenosis involving the A1, M1, and P1 segments bilaterally.  
*MRA*, Magnetic resonance angiogram

for females.<sup>1</sup> Catheter angiography is the gold standard for diagnosis, but due to its invasive nature MRA has gained in popularity. On MRA, the classic “puff of smoke” may be visualized due to collateral vessel formation after arterial stenosis. Patients who are conservatively managed experience stroke at a rate of 3.2%-15.0% annually.<sup>2</sup> In those who underwent postoperative direct revascularization, the annual stroke rate decreased to 0.0%- 1.6%, while those who had undergone postoperative indirect revascularization presented an annual stroke rate of 0%-14.3% annually.<sup>2</sup>

---

*Address for Correspondence:* John Ashurst DO, MS, Duke LifePoint Conemaugh Memorial Medical Center, 1086 Franklin Street, Johnstown, PA 15905. Email: Ashurst.john.32.research@gmail.com.

*Conflicts of Interest:* By the *CPC-EM* article submission agreement, all authors are required to disclose all affiliations, funding sources and financial or management relationships that could be perceived as potential sources of bias. The authors disclosed none.

*Copyright:* © 2017 Ashurst et al. This is an open access article distributed in accordance with the terms of the Creative Commons Attribution ([CC BY 4.0](http://creativecommons.org/licenses/by/4.0/)) License. See: <http://creativecommons.org/licenses/by/4.0/>

---

### *CPC-EM Capsule*

What do we already know about this clinical entity?

*Moyamoya is a rare clinical entity characterized by stenosis of the internal carotid artery causing those afflicted to have stroke like symptoms.*

What is the major impact of the image(s)?

*The image depicts the classic “puff of smoke” seen in those with Moyamoya.*

How might this improve emergency medicine practice?

*Although classically seen in those with Asian descent, the emergency physician must be aware of the diagnosis in all patient populations.*

### REFERENCES

1. Kim JS. Moyamoya disease: epidemiology, clinical features, and diagnosis. *J Stroke*. 2016;18(1):2-11.
2. Kim T, Oh CW, Band JS, et al. Moyamoya disease: treatment and outcomes. *J Stroke*. 2016;18(1):21-30.



## Right Atrial Thrombus or Chiari Network?

Peter Fredericks, BS\*

Theresa Liu, BS\*

Joseph Colla, MD, RDMS†

\*University of Illinois-College of Medicine, Chicago, Illinois

†University of Illinois at Chicago, Department of Emergency Medicine, Chicago, Illinois

Section Editor: Rick A. McPheeters, DO

Submission history: Submitted October 10, 2016; Revision received February 14, 2017; Accepted February 22, 2017

Electronically published May 9, 2017

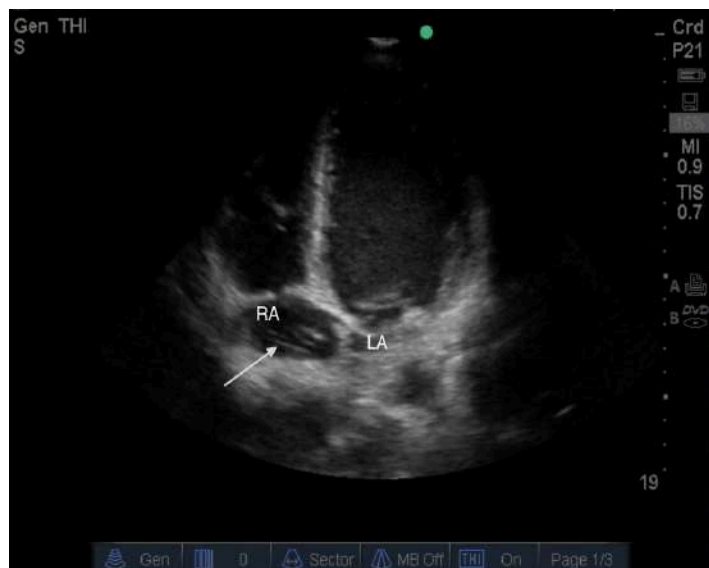Full text available through open access at [http://escholarship.org/uc/uciem\\_cpem](http://escholarship.org/uc/uciem_cpem)

DOI: 10.5811/cpem.2017.2.32820

[Clin Pract Cases Emerg Med. 2017;1(3):258–259.]

### CASE REPORT

A 31-year-old African-American male with known sickle cell disease presented to the emergency department (ED) with a one-week history of chest pain and bilateral leg pain. Physical examination showed an afebrile and hemodynamically stable but uncomfortable appearing male. Cardiac and respiratory exam were unremarkable. A bedside focused cardiac ultrasound (FOCUS) exam performed by the attending emergency physician (EP) revealed four dilated chambers and a hyperechoic mobile body in the right atrium (Image). The FOCUS images were forwarded to a senior cardiology fellow who confirmed that the hyperechoic body was a Chiari network and not a right atrial clot. The patient was admitted for a sickle cell vaso-occlusive crisis that was managed with morphine and intravenous fluids.



**Image.** Apical four chamber view demonstrating a right atrial Chiari Network (arrow).

### CPC-EM Capsule

What do we already know about this clinical entity?

*Chiari's network is a collection of reticula found in the right atrium that has been associated with some cardiac pathologies such as arrhythmia, paradoxical emboli, and thrombi formation.*

What is the major impact of image(s)?

*The major impact of this image is to inform providers of this disease entity, emphasize its defining characteristics, and highlight the associated pathologies.*

How might this improve emergency medicine practice?

*A Chiari's network can prove a diagnostic challenge for emergency physicians, at times mimicking a right atrial mass, thrombus, or vegetation which may in turn lead to mistreatment.*

### DISCUSSION

Found in 2% of the population, Chiari network is a collection of reticula in the right atrium that results from incomplete resorption of the Eustachian valve.<sup>1</sup> The network is visualized on echocardiogram as a pulsating network of threads and fibers attached to the posterior wall of the right atrium or atrial septum. This sonographic appearance can prove to be a diagnostic

challenge for EPs using point-of-care ultrasound because it could be mistaken for a right atrial mass, thrombus, or vegetation instead of an embryological remnant, which may in turn lead to mistreatment.<sup>2</sup> Key elements noted on echocardiography that distinguish Chiari network include identification of at least two normal-appearing tricuspid valve leaflets and the presence of a rotary, highly mobile target that does not move into the right ventricular outflow tract or the right ventricle during diastole. While typically considered a benign anatomical variant, it has been associated with cardiac pathologies such as arrhythmia, paradoxical emboli, persistent patent foramen ovale, formation of an atrial septal aneurysm, thrombi formation, and entrapment of thrombi or catheters.<sup>1,3,4</sup> Differentiating Chiari network from a more acutely pathological process is critical in the evaluation and management of hypercoagulable patients.

**Video 1.** An apical four chamber view displaying a prominent Chiari network within the right atrium.

**Video 2.** An apical four chamber view displaying a right atrial thrombus to contrast with the Chiari network found in Video 1.

*Address for Correspondence:* Peter Fredericks, BS, University of Illinois-College of Medicine, 808 South Wood St, Chicago, IL 60612. Email: peter.fredericks@gmail.com.

*Conflicts of Interest:* By the CPC-EM article submission agreement, all authors are required to disclose all affiliations, funding sources and financial or management relationships that could be perceived as potential sources of bias. The authors disclosed none.

*Copyright:* © 2017 Fredericks et al. This is an open access article distributed in accordance with the terms of the Creative Commons Attribution (CC BY 4.0) License. See: <http://creativecommons.org/licenses/by/4.0/>

## REFERENCES

1. Loukas M, Sullivan A, Tubbs RS, et al. Chiari's network: review of the literature. *Surg Radiol Anat.* 2010;32(10):895-901.
2. Werner JA, Cheitlin MD, Gross BW, et al. Echocardiographic appearance of the Chiari network: differentiation from right-heart pathology. *Circulation.* 1981;63(5):1104-9.
3. Schneider B, Hofmann T, Justen MH, et al. Chiari's network: normal anatomic variant or risk factor for arterial embolic events? *J Am Coll Cardiol.* 1995;26(1):203-10.
4. Schwimmer-Okike N, Niebuhr J, Schramek G, et al. The presence of a large Chiari network in a patient with atrial fibrillation and stroke. *Case Rep in Cardiol.* 2016;2016:4839315.

## Aorto-esophageal Fistula

Ryan Roten, DO  
Ryan Peterfy, DO

Desert Regional Medical Center, Department of Emergency Medicine, Palm Springs, California

Section Editor: Rick A. McPheeters, DO

Submission history: Submitted; Submitted November 16, 2016; Revision received February 10, 2017; Accepted February 22, 2017

Electronically published July 6, 2017

Full text available through open access at [http://escholarship.org/uc/uciem\\_cpccem](http://escholarship.org/uc/uciem_cpccem)

DOI: 10.5811/cpcem.2017.2.33141

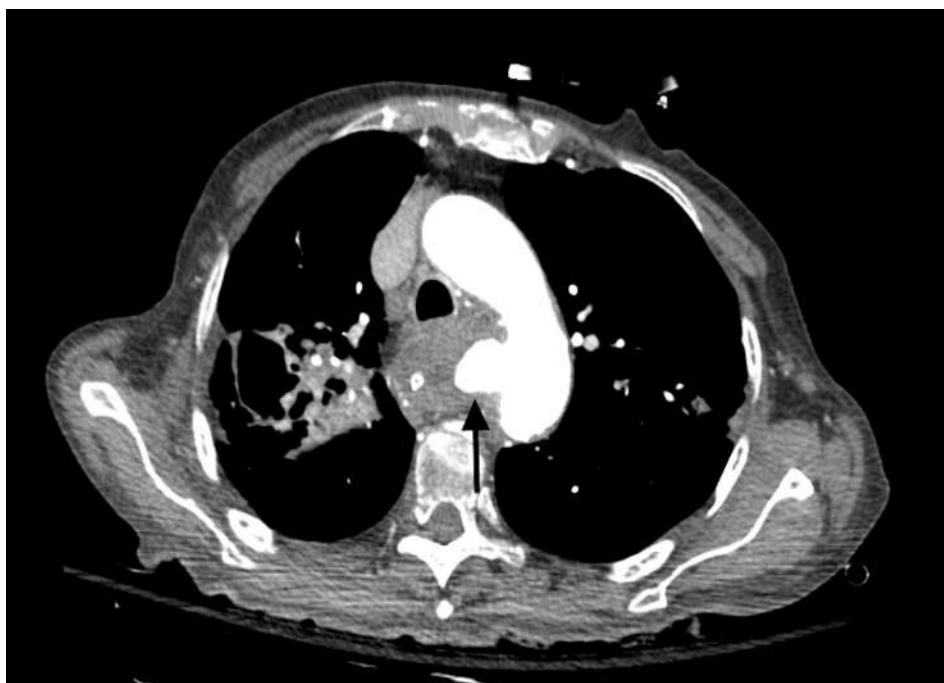
[Clin Pract Cases Emerg Med. 2017;1(3):260–261.]

### CASE PRESENTATION

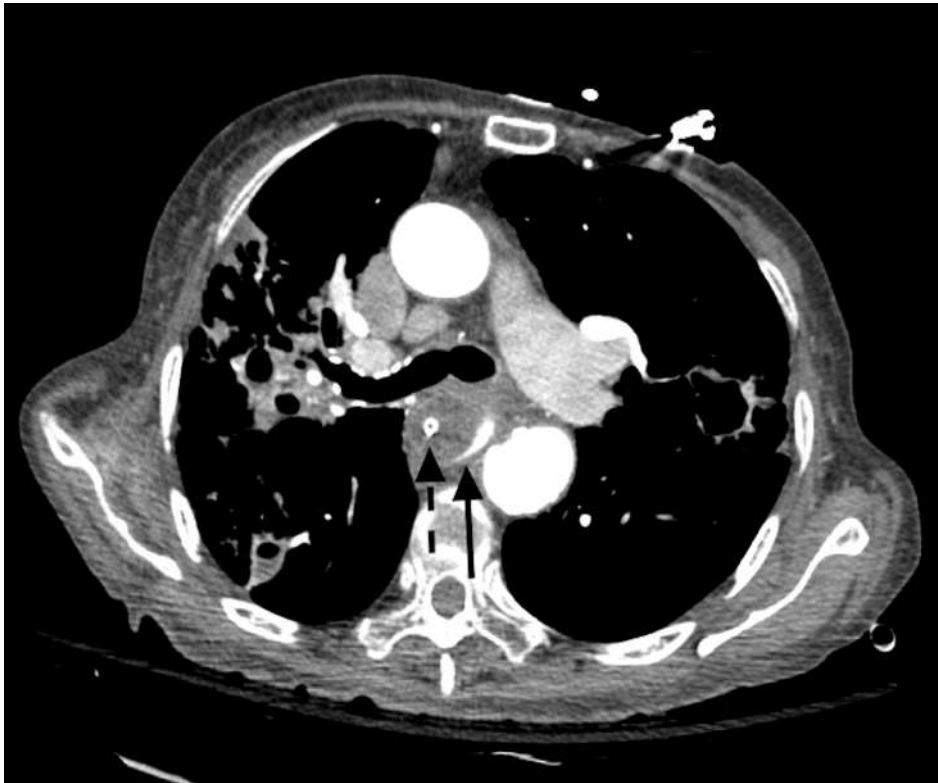
A 90-year-old female presented after sudden collapse with a Glasgow Coma Score of 3, and profound hypotension. Shortly after endotracheal intubation, the patient developed significant hematemesis, and massive transfusion protocol was subsequently instituted. Computed tomography angiogram of the chest revealed active bleeding from an aorto-esophageal fistula (Image 1). During the resuscitation, over four liters of blood were collected via oral gastric tube and manual suctioning by nursing staff before the resuscitation was terminated at the family's request.

### DISCUSSION

The most common causes of aorto-esophageal fistulas are thoracic aortic aneurysm, foreign body ingestion, postoperative complications, and esophageal malignancy. The classic presentation of mid-thoracic chest pain and sentinel arterial hemorrhage followed by exsanguination is known as Chiari's triad.<sup>1</sup> If the abnormality is identified early during the asymptomatic period using endoscopy or computed tomography angiogram of the chest, survival is possible with immediate surgical intervention or endovascular stenting.<sup>2</sup> Medical providers must be familiar with the presentation, diagnostics, rapid interruption of diagnostics and treatment of aorto-esophageal fistulas to make survival of this rare and typically fatal pathology possible.



**Image 1.** Computed tomography of the chest with contrast-filled aorto-esophageal fistula (arrow).



**Image 2.** Computed tomography of the chest with contrast filling the esophagus (solid arrow) and adjacent oral gastric tube (dashed arrow).

*Address for Correspondence:* Ryan Roten, DO, Desert Regional Medical Center, 1150 N. Indian Canyon Dr., Palm Springs, CA 92262. Email: ryanroten@cep.com.

*Conflicts of Interest:* By the CPC-EM article submission agreement, all authors are required to disclose all affiliations, funding sources and financial or management relationships that could be perceived as potential sources of bias. The authors disclosed none.

*Copyright:* © 2017 Roten. This is an open access article distributed in accordance with the terms of the Creative Commons Attribution (CC BY 4.0) License. See: <http://creativecommons.org/licenses/by/4.0/>

## REFERENCES

1. Heckstall RL, Hollander JE. Aortoesophageal fistula: recognition and diagnosis in the emergency department. *Ann Emerg Med.* 1998;32(4): 502-5.
2. Ayyildiz T, Nas OF, Yildirim C, et al. A rare upper gastrointestinal system case: aortoesophageal fistula. *J Exp Clin Med.* 2014;31:51-3.

### *CPC-EM Capsule*

What do we already know about this clinical entity?

*Aortoesophageal fistula is a rare and typically fatal pathology that presents as massive upper gastrointestinal hemorrhage.*

What is the major impact of the image(s)?

*This is a rarely seen image, given the degree of extremis and high mortality of patients with aortoesophageal fistula at emergency department presentation.*

How might this improve emergency medicine practice?

*Emergency medicine providers must be familiar with the presentation, diagnostics, rapid interruption of diagnostics and treatment of aortoesophageal fistulas.*



## A Man with Cyanotic Digits

Tess Wiskel, MD\*  
Jonathan Bass, MD†  
Jeffrey Feden, MD\*

\*Brown University Warren Alpert Medical School, Department of Emergency Medicine, Providence, Rhode Island

†Brown University Warren Alpert Medical School, Department of Plastic and Reconstructive Surgery, Providence, Rhode Island

Section Editor: Rick A. McPheeters, DO

Submission history: Submitted December 18, 2016; Revision received February 7, 2017; Accepted February 23, 2017

Electronically published July 6, 2017

Full text available through open access at [http://escholarship.org/uc/uciem\\_cpccem](http://escholarship.org/uc/uciem_cpccem)

DOI: 10.5811/cpcem.2017.2.33371

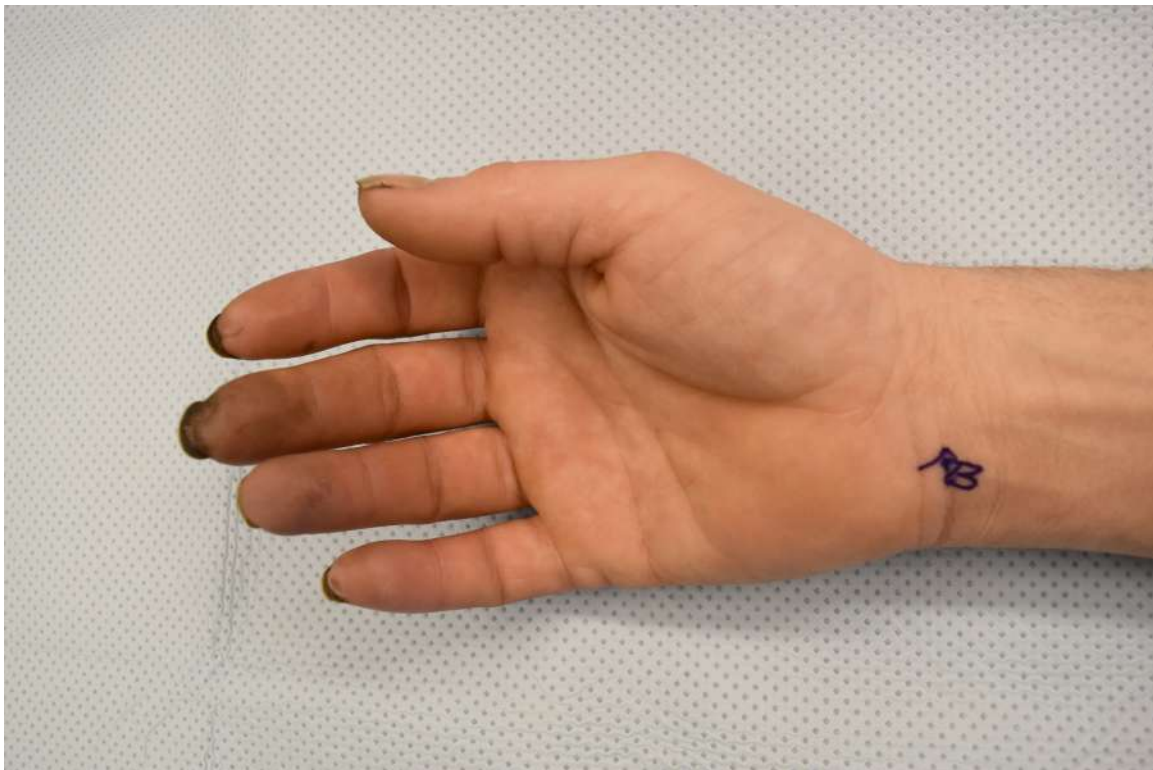
[Clin Pract Cases Emerg Med. 2017;1(3):262–264.]

### CASE PRESENTATION

A 37-year-old right-handed male auto mechanic with a 40 pack-year smoking history presented to the emergency department with progressive digital pain, cyanosis and paresthesias to his right hand over the prior month. Physical exam revealed cyanosis of the second through fifth digits with sparing of the thumb, absent digital artery Doppler signals, and a diminished deep palmar arch signal (Image 1).

Conventional angiography of the hand revealed an

aneurysmal appearance of the palmar ulnar artery adjacent to the hook of the hamate, and abrupt truncations to the digital arteries consistent with hypothenar hammer syndrome (Image 2a). The patient returned two weeks later for surgical intervention with right ulnar artery reconstruction and ulnar nerve decompression (Image 2b). Following surgery, the cyanosis resolved and there was return of biphasic digital artery signals, normal capillary refill, motion, sensibility, and good wound healing.



**Image 1.** Initial appearance of hand with cyanotic digits 2-5.

## DISCUSSION

Hypothenar hammer syndrome is characterized by vascular insufficiency of the digits. It often results from repetitive blunt trauma to the hypothenar eminence causing ulnar artery damage, likely against the hook of the hamate, resulting in arterial thrombosis or aneurysm.<sup>1,2</sup> This rare syndrome occurs most commonly in athletes and industrial workers.<sup>3</sup> The differential diagnosis includes other causes of digital ischemia, such as Raynaud's disease, Buerger's disease, atherosclerotic and embolic disease, vasculitis, and thoracic outlet syndrome.<sup>2</sup> The gold standard for diagnosis is arterial imaging, preferably angiography, which demonstrates the classic corkscrew or aneurysmal appearance of the ulnar artery. Additionally, point of care ultrasound has been used to aid in diagnosis of this syndrome.<sup>4</sup> Management ranges from conservative medical management to endovascular thrombolysis or surgical grafting, as in this case.<sup>2</sup>

### *CPC-EM Capsule*

What do we already know about this clinical entity?

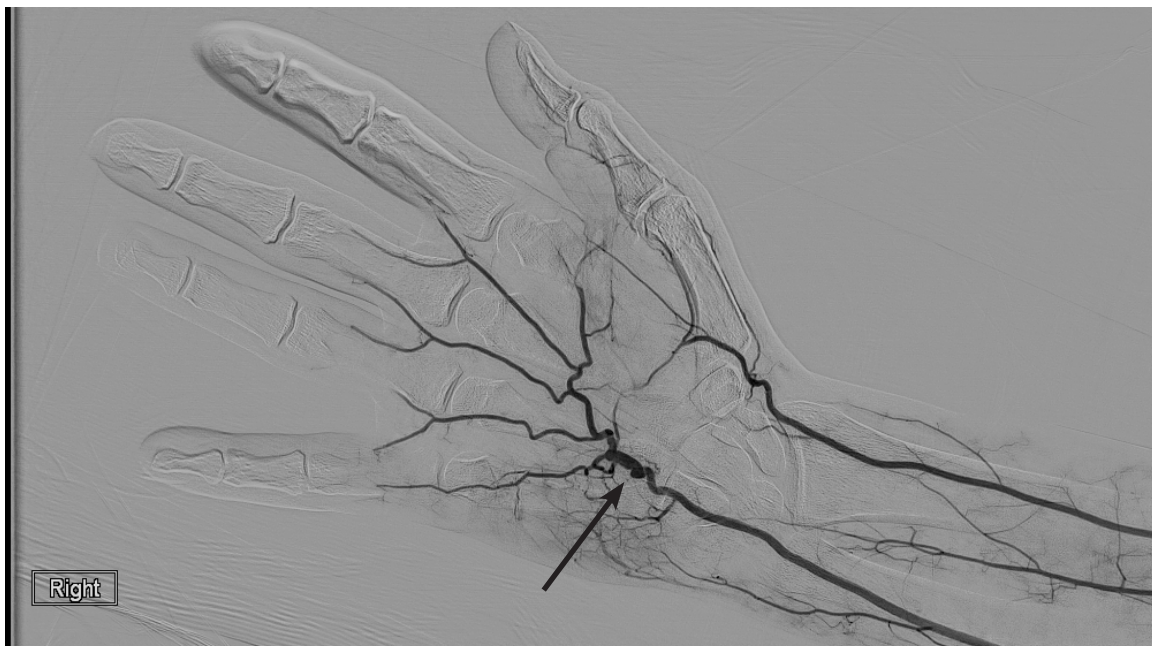
*Hypothenar hammer syndrome is characterized by vascular insufficiency to the digits from repetitive blunt trauma to the hypothenar eminence, which results in arterial aneurysm or thrombosis.*

What is the major impact of the image(s)?

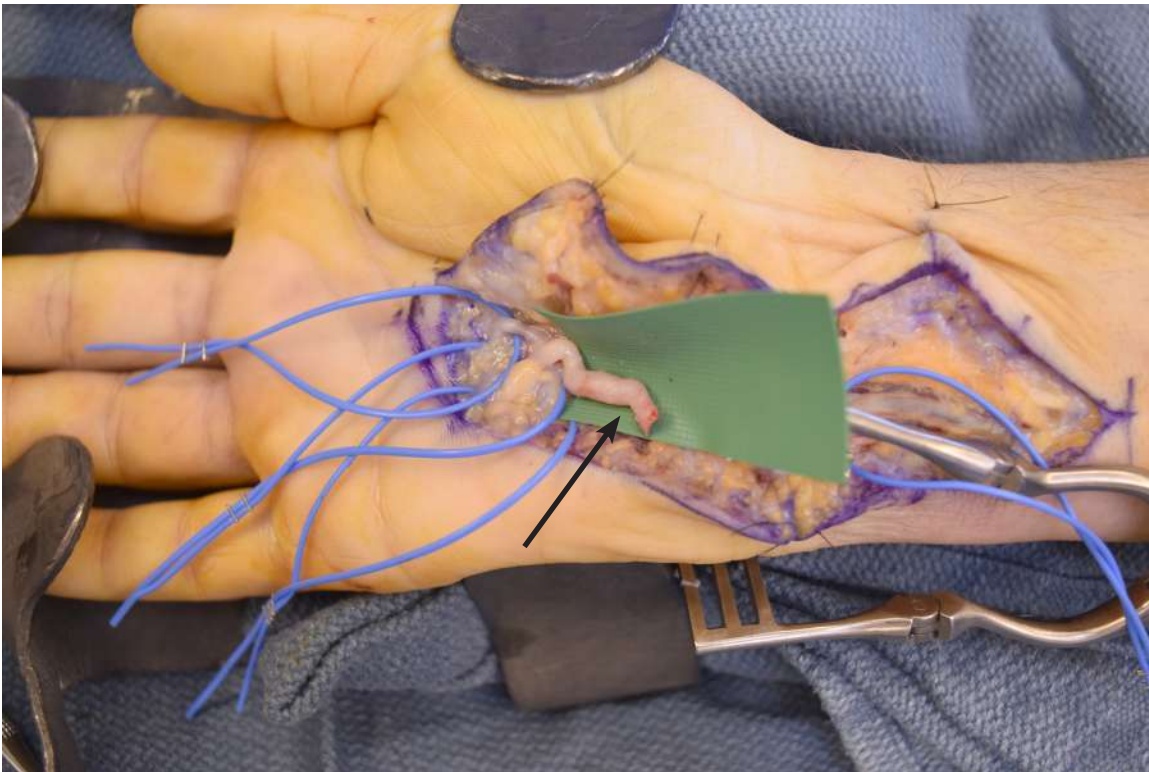
*These images illustrate the physical exam findings of digital ischemia, the underlying vascular pathology demonstrated by angiography and the intra-operative gross anatomic dissection.*

How might this improve emergency medicine practice?

*Hypothenar hammer syndrome is a rare condition not often encountered in emergency medicine practice or literature, and these images intend to increase awareness in clinical practice.*



**Image 2a.** Angiogram demonstrating abnormal aneurysmal appearance of ulnar artery (arrow).



**Image 2b.** Intra-operative aneurysmal ulnar artery with corkscrew appearance (arrow).

*Address for Correspondence:* Tess Wiskel, MD, Brown University Warren Alpert Medical School, 593 Eddy Street Claverick 100, Providence, RI 02903. Email: Tess\_wiskel@brown.edu.

*Conflicts of Interest:* By the CPC-EM article submission agreement, all authors are required to disclose all affiliations, funding sources and financial or management relationships that could be perceived as potential sources of bias. The authors disclosed none.

*Copyright:* © 2017 Wiskel et al. This is an open access article distributed in accordance with the terms of the Creative Commons Attribution (CC BY 4.0) License. See: <http://creativecommons.org/licenses/by/4.0/>

## REFERENCES

1. Carter PM, Hollinshead PA, Desmond JS. Hypothenar hammer syndrome: case report and review. *J Emerg Med.* 2013;45(1):22-5.
2. Yuen JC, Wright E, Johnson LA, et al. Hypothenar hammer syndrome: an update with algorithms for diagnosis and treatment. *Ann Plast Surg.* 2011;67(4):429-38.
3. Rabczyński M, Kuźnik E, Guziński M, et al. Critical ischemia of the fingers in an auto mechanic as a result of occupational exposure. *Int J Occup Med Environ Health.* 2015;28(1):169-73.
4. Ken J, Khangura D, Stickles SP. Point-of-care ultrasound to identify distal ulnar artery thrombosis: case of hypothenar hammer syndrome. *West J Emerg Med.* 2015;16(4):565-7.

## Adult Male with Neck Pain

Shaw Natsui, MD  
Sarah E. Frasure, MD

Brigham and Women's Hospital, Department of Emergency Medicine, Boston, Massachusetts

Section Editor: Rick A. McPheeters, DO

Submission history: Submitted December 1, 2016; Revision received January 11, 2017; Accepted March 10, 2017

Electronically published July 14, 2017

Full text available through open access at [http://escholarship.org/uc/uciem\\_cpem](http://escholarship.org/uc/uciem_cpem)

DOI: 10.5811/cpcem.2017.3.33250

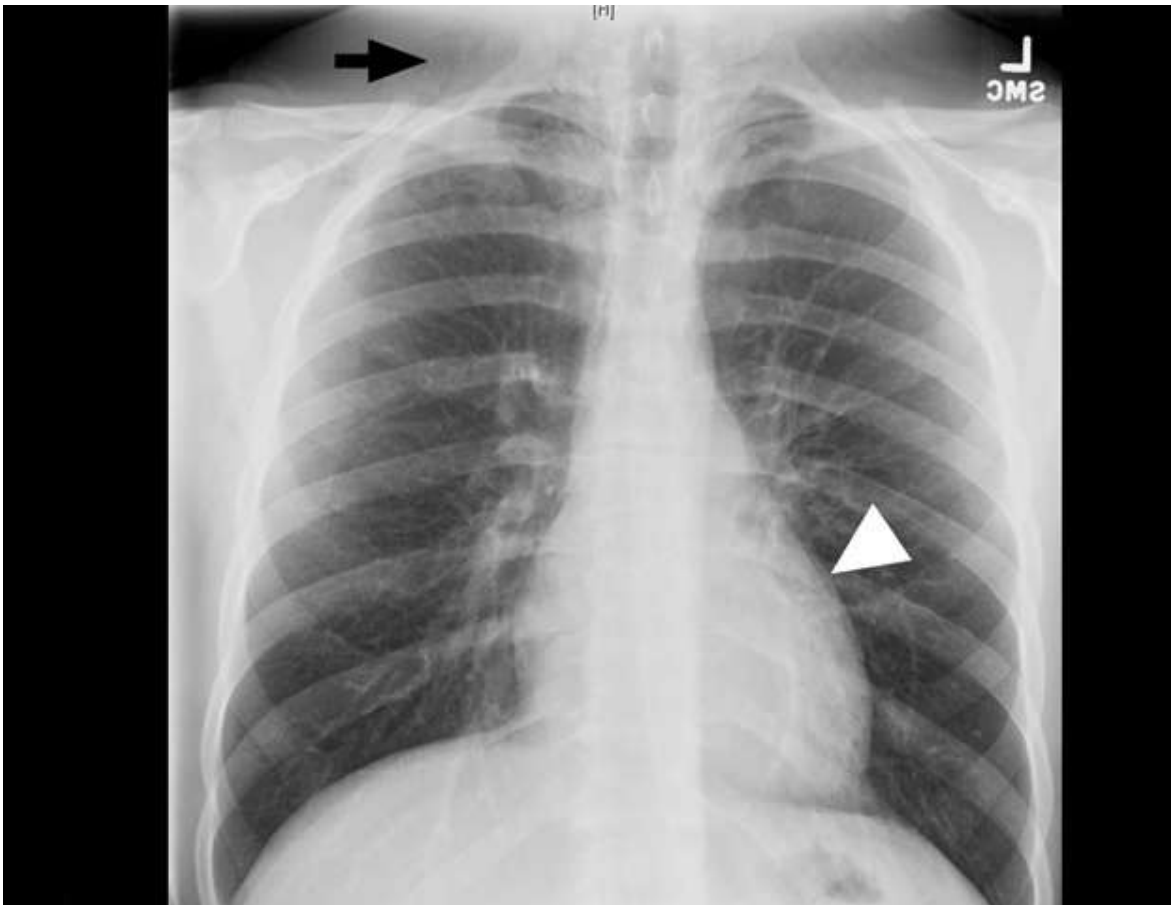
[Clin Pract Cases Emerg Med. 2017;1(3):265–267.]

---

### CASE PRESENTATION

A 19-year-old male presented to the emergency department after a fall while playing soccer. He attempted to head the ball but instead fell backwards, hitting his head and neck on the ground. He did not lose consciousness but developed immediate pain along the right side of his neck. He also described pleuritic chest pain. He denied vision changes, nausea, vomiting, dyspnea,

abdominal pain, paresthesias, or extremity weakness. His vital signs were normal. His physical exam was notable for palpable crepitus over the right supraclavicular area. He had clear breath sounds bilaterally. His neurologic exam was intact. Laboratory tests were unremarkable. A chest radiograph was performed (Image 1), and the patient was subsequently evaluated by the trauma service. Thereafter, a computed tomography of the neck,



**Image 1.** Plain radiograph demonstrates subcutaneous emphysema (arrow) and pneumomediastinum (arrowhead).



chest, abdomen, and pelvis was performed (Images 2 and 3), and the patient was admitted to the hospital.

## DISCUSSION

*Pneumomediastinum and pneumorrhachis.* The patient was admitted to the surgical service for close airway monitoring and a barium-swallow study to assess for esophageal perforation. No surgical intervention was necessary. Pneumorrhachis is the presence of air within the spinal canal and was first described in 1977.<sup>1,2</sup> Conditions that produce elevated intrathoracic pressure, such as coughing, sneezing or vomiting, can lead to the entrapment of air in the paraspinal soft tissues and epidural space via the neural foramina.<sup>3</sup> The majority of cases appear to involve young males.<sup>1,4</sup> The association between pneumorrhachis and subcutaneous emphysema due to barotrauma is well described. The mechanism behind the association of pneumomediastinum with pneumorrhachis, however, is poorly understood.<sup>1</sup> Related phenomena include pneumocephalus, pneumothorax, and pneumopericardium. Given the rarity of pneumorrhachis no standard management guidelines exist.<sup>5</sup> Fortunately, the majority of cases of pneumorrhachis are self-

### *CPC-EM Capsule*

What do we already know about this clinical entity?

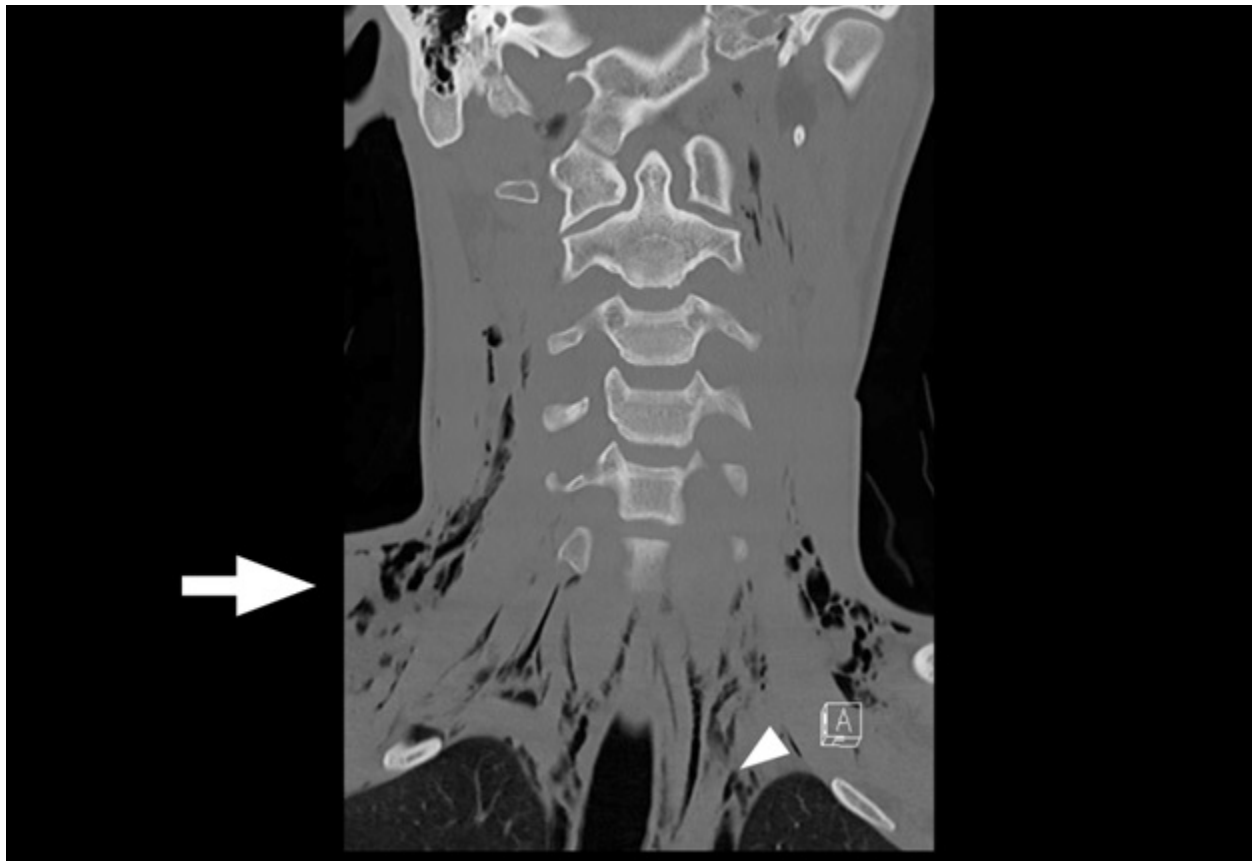
*Pneumorrhachis is the presence of air within the spinal canal, caused by conditions that create elevated intrathoracic pressure.*

What is the major impact of the image(s)?

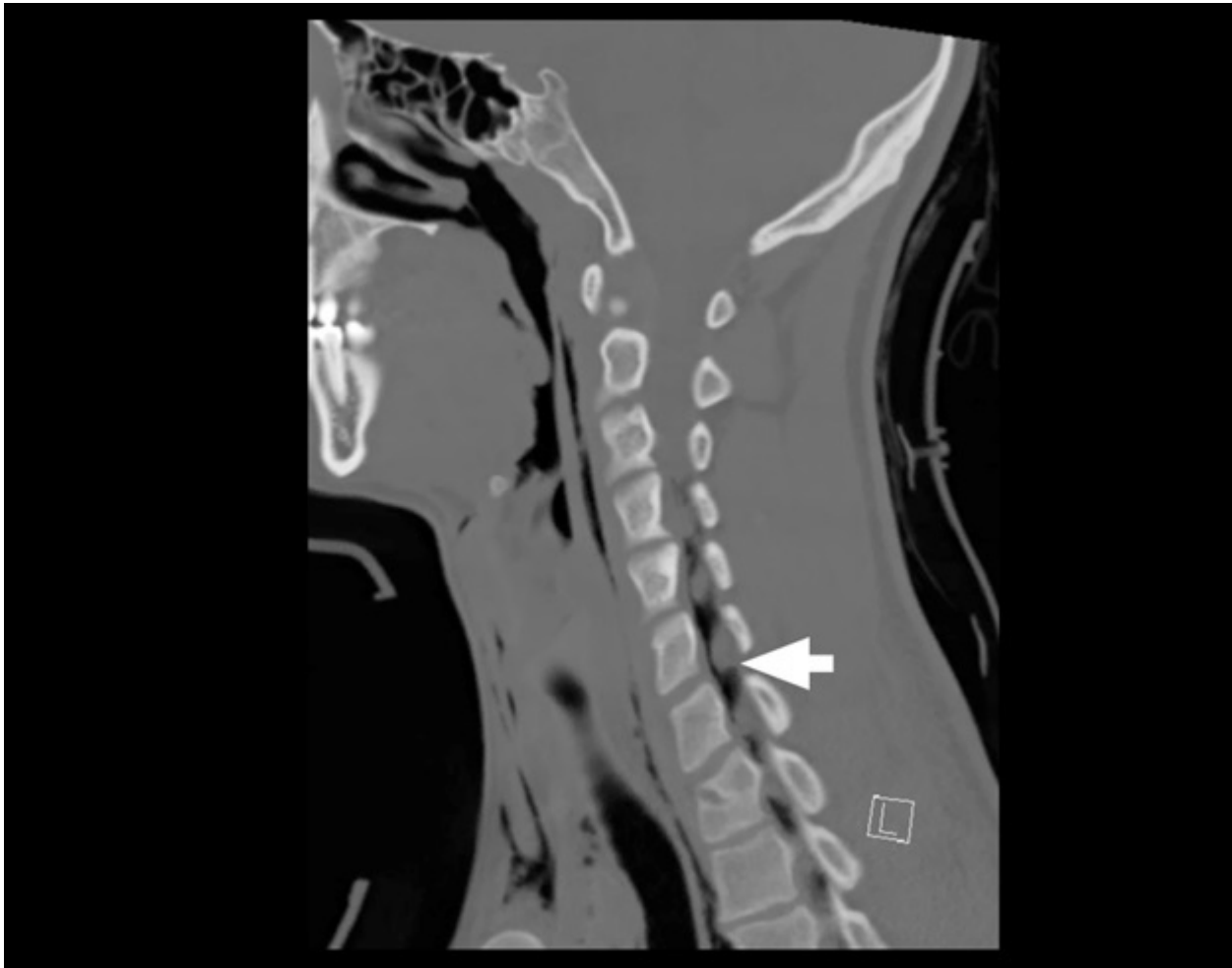*The images illustrate the association of pneumorrhachis with other pathology such as subcutaneous emphysema and pneumomediastinum.*

How might this improve emergency medicine practice?

*The presence of subcutaneous emphysema or pneumomediastinum on plain film imaging for a trauma patient should raise suspicion for associated pneumorrhachis.*



**Image 2.** Coronal view of computed tomography of the patient's neck demonstrates subcutaneous emphysema (arrow) and pneumomediastinum (arrowhead).



**Image 3.** Sagittal view of the patient's neck computed tomography demonstrates pneumorrhachis (arrow).

limiting and successfully managed without surgical intervention.

---

*Address for Correspondence:* Sarah E. Frasure, MD, Brigham and Women's Hospital, Neville House – 236A, 75 Francis St., Boston, MA 02115. Email: sarahfrasure@yahoo.com.

*Conflicts of Interest:* By the CPC-EM article submission agreement, all authors are required to disclose all affiliations, funding sources and financial or management relationships that could be perceived as potential sources of bias. The authors disclosed none.

*Copyright:* © 2017 Natsui et al. This is an open access article distributed in accordance with the terms of the Creative Commons Attribution (CC BY 4.0) License. See: <http://creativecommons.org/licenses/by/4.0/>

---

## REFERENCES

1. Hadjigeorgiou GF, Singh R, Stefanopoulos P et al. Traumatic pneumorrhachis after isolated closed head injuries: an up-to-date review. *J Clin Neurosci.* 2016;34:44–46.
2. Gordon IJ, Hardman DR. The traumatic pneumomyelogram. A previously undescribed entity. *Neuroradiology.* 1977;13(2):107–8.
3. Aujayeb A, Doe S, Worthy S. Pneumomediastinum and pneumorrhachis: a lot of air about nothing? *Breathe.* 2012;8(4).
4. Belotti EA, Rizzi M, Rodoni-Cassis P et al. Air within the spinal canal in spontaneous pneumomediastinum. *Chest.* 2010;137(5):1197–200.
5. Manden PK, Siddiqui AH. Pneumorrhachis, pneumomediastinum, pneumopericardium and subcutaneous emphysema as complications of bronchial asthma. *Ann Thorac Med.* 2009;4(3):143–5.

## Diagnosis of Septic Abortion with Point-of-care Ultrasound

Dawa Sherpa, MD\*

Brian D. Johnson, MD, MPH†

Leila Ben-Youssef, MD, MA\*

Arun Nagdev, MD\*‡

\*Alameda Health System – Highland Hospital, Oakland, California

†University of Washington – Valley Medical Center, Renton, Washington

‡University of California, San Francisco, San Francisco, California

Section Editor: Rick A. McPheeters, DO

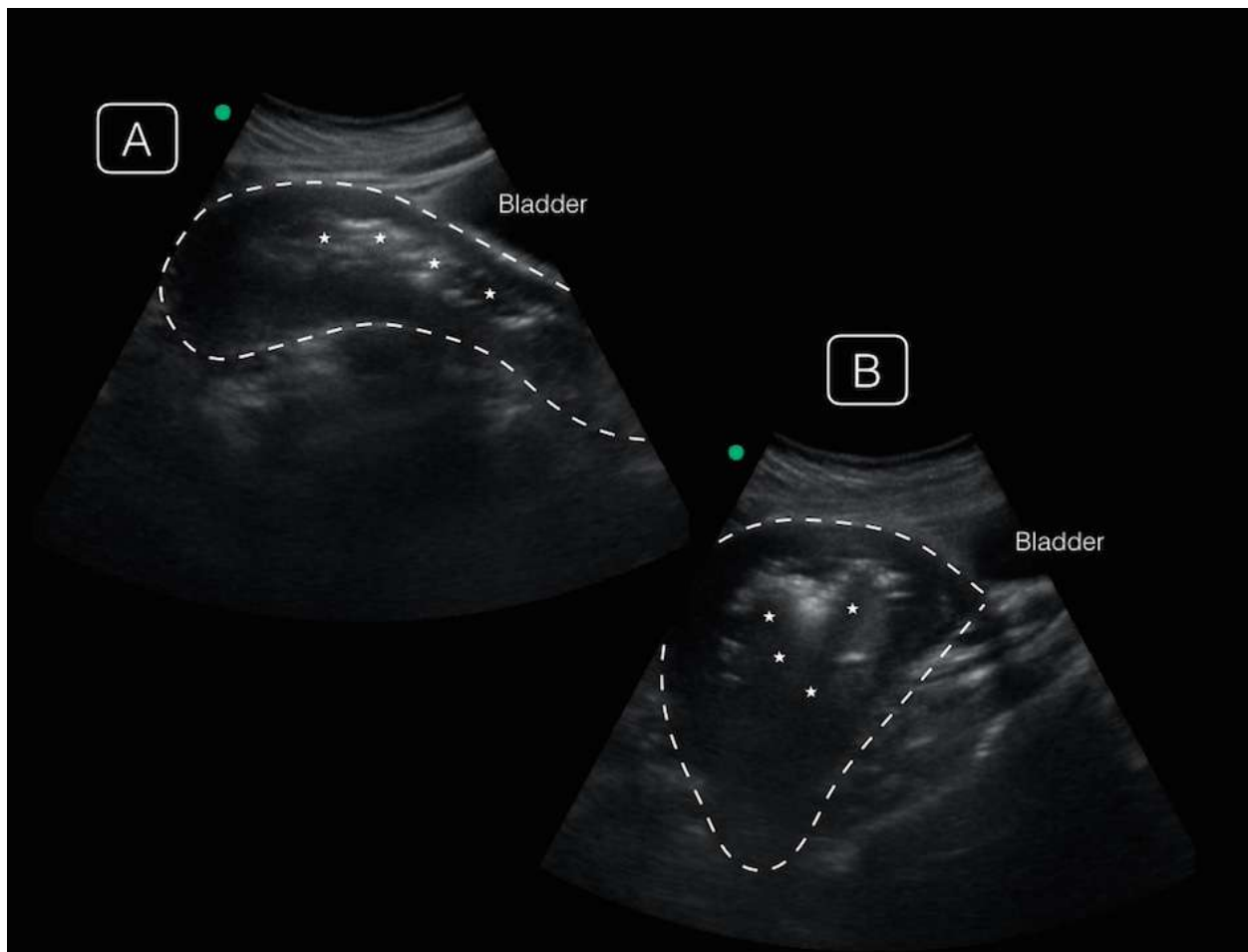
Submission history: Submitted January 11, 2017; Revision received March 1, 2017; Accepted March 31, 2017

Electronically published July 6, 2017

Full text available through open access at [http://escholarship.org/uc/uciem\\_cpccem](http://escholarship.org/uc/uciem_cpccem)

DOI: 10.5811/cpcem.2017.3.33574

[Clin Pract Cases Emerg Med.2017;1(3):268–269.]



**Image.** Point-of-care ultrasonographic transabdominal images of the uterus in midline (A) and off-axis sagittal views (B), demonstrating an enlarged uterus (dotted line) with irregular echogenic endometrial debris (asterisk) casting shadows from the endometrium.

**Video.** Transabdominal ultrasound of the uterus with debris and air with shadowing artifact.

## CASE PRESENTATION

A 19-year-old recently immigrated female presented with severe lower abdominal pain, fever, and vaginal bleeding after a syncopal episode. On examination, she was febrile with diffuse tenderness to palpation of her lower abdomen with an enlarged uterus palpable to just below the umbilicus. The patient initially denied pregnancy, but had a positive urine pregnancy with a quantitative beta-human chorionic gonadotropin of 19,773 mIU/mL. Pelvic exam revealed scant amount of blood in the vaginal canal with malodorous discharge. A point-of-care ultrasound revealed an enlarged uterus with a large amount of air and echogenic debris within the endometrium (Image). Over the course of the emergency department (ED) stay, the patient became hypotensive and was found to have anemia and leukocytosis requiring a blood transfusion, antibiotics and emergent gynecological intervention.

## DISCUSSION

The patient was admitted to the obstetric service and started on broad-spectrum antibiotics for incomplete septic abortion. She underwent a vacuum-assisted dilation and curettage with removal of uterine contents. Surgical pathology revealed degenerating and focal necrotic chorionic villi consistent with intra-uterine pregnancy. While rare in developed countries, septic abortion is a life-threatening infection of the placenta and fetus of a previable pregnancy typically associated with unsafe abortion practices.<sup>1</sup> Diagnosis is made clinically and confirmed by ultrasound, computed tomography or magnetic resonance imaging that can show an enlarged uterus with hemorrhage, retained intrauterine material, free fluid, abscess formation and/or air.<sup>2</sup> Intrauterine air is theorized to arise from gas-forming organisms or secondary to perforation from unsafe abortion practices. The ultrasonographic finding of air in the uterus must be recognized by the emergency physician in order to expedite ED and consultative care. With the reduction in funding for healthcare services for at-risk populations and possible defunding of Planned Parenthood, we believe that this uncommon finding may become more prevalent for providers on the front line.<sup>4,5</sup> Treatment consists of broad-spectrum antibiotics, prompt removal of infected tissue and hysterectomy in severe, refractory cases.<sup>3</sup>

*Address for Correspondence:* Dawa Sherpa, MD, Highland Hospital – Alameda Health System, 1411 East 31st Street, Oakland, CA 94602. Email: [dsherpa@alamedahealthsystem.org](mailto:dsherpa@alamedahealthsystem.org).

*Conflicts of Interest:* By the CPC-EM article submission agreement, all authors are required to disclose all affiliations, funding sources and financial or management relationships that could be perceived as potential sources of bias. The authors disclosed none.

### CPC-EM Capsule

What do we already know about this clinical entity?

*Septic abortion is a life-threatening infection associated with unsafe abortion practices that is diagnosed clinically and confirmed with ultrasound.*

What is the major impact of the image(s)?

*Our ultrasound video demonstrates septic abortion-associated uterine free air, a novel finding that has yet to be discussed in the point-of-care ultrasound (POCUS) emergency medicine literature.*

How might this improve emergency medicine practice?

*POCUS allows for prompt identification of septic abortion and swift consultation with obstetrics for definitive care.*

*Copyright:* © 2017 Sherpa et al. This is an open access article distributed in accordance with the terms of the Creative Commons Attribution (CC BY 4.0) License. See: <http://creativecommons.org/licenses/by/4.0/>

## REFERENCES

1. Unsafe abortion - global and regional estimates of the incidence of unsafe abortion and associated mortality in 2008. *Department of Reproductive Health and Research, World Health Organization.* 2011:1-66.
2. Saultes TA, Devita D, Heiner JD. The back alley revisited: sepsis after attempted self-induced abortion. *West J Emerg Med.* 2009;10(4):278-80.
3. Stubblefield PG, Grimes DA. Septic abortion. *N Engl J Med.* 1994;331(5):310-4.
4. "The Mexico City Policy - Memorandum for the Secretary of State[,] the Secretary of Health and Human Services[, and] the Administrator of the United States Agency for International Development". Federal Register. 25 January 2017.
5. Sengupta, Somini (2017-01-23). "Trump Revives Ban on Foreign Aid to Groups That Give Abortion Counseling." *The New York Times.* ISSN 0362-4331. Accessed January 24, 2017.



## Catecholamine-induced Ischemic Necrosis of the Hand

David S. Bostick, MD, MPH\*  
Michael T. McCurdy, MD†

\* University of Maryland Medical Center, Department of Emergency Medicine,  
Baltimore, Maryland

† University of Maryland School of Medicine, Division of Pulmonary and Critical Care,  
Baltimore, Maryland

Section Editor: Rick A. McPheeters, DO

Submission history: Submitted January 6, 2017; Revision received May 11, 2017; Accepted April 19, 2017

Electronically published July 14, 2017

Full text available through open access at [http://escholarship.org/uc/uciem\\_cpem](http://escholarship.org/uc/uciem_cpem)

DOI: 10.5811/cpem.2017.4.33513

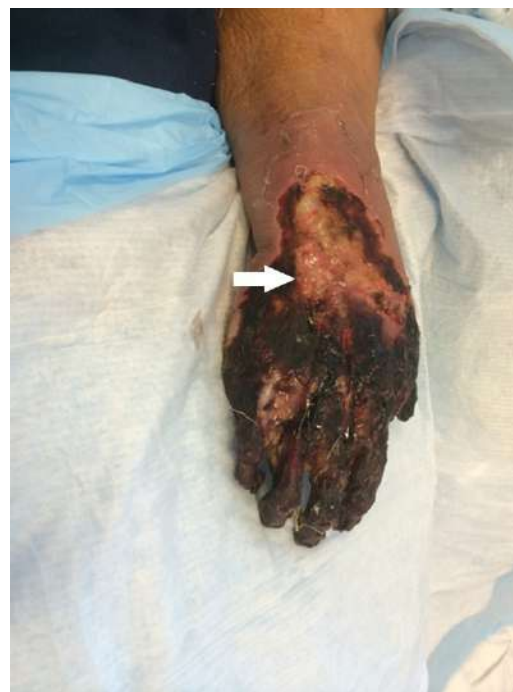This case highlights the rare complication of ischemic hand necrosis following peripheral administration of epinephrine and norepinephrine. [Clin Pract Cases Emerg Med.2017;1(3):270–271.]

### CASE PRESENTATION

A 60-year-old woman with chronic obstructive pulmonary disease and other co-morbidities presented to the emergency department with dyspnea. Her symptoms were severe enough to require mechanical ventilation. During her stay, she suffered a cardiac arrest during which a total of three separate doses of epinephrine were administered through a peripheral intravenous (IV) catheter on the dorsum of her right hand. Following return of spontaneous circulation she was continued on a norepinephrine infusion through the same peripheral IV catheter for 24 hours for post-arrest hypotension in the setting of septic shock. Two days after her arrest, she was noted to have skin changes consistent with ischemic necrosis of her right hand, which can be seen in the image.

### DISCUSSION

Diagnosis of extravasation injuries can be quite challenging; clinical signs may include pain, swelling, erythema, pain, blistering, or blanching of the skin overlying the site of infusion. Prompt recognition of these signs and appropriate intervention should occur within 4 - 6 hours from the time of injury, although reports have shown benefit of intervening up to 12 hours after injury.<sup>1</sup> Vigilant monitoring is essential as compartment syndrome can develop after prolonged vasospasm or with large-volume extravasation.<sup>1</sup> Early management includes simple immobilization, frequent neuromuscular checks, elevation, local application of warming blankets, and injectable or topical vasodilators.<sup>1,2</sup> If unsuccessful, as in this case, open surgical debridement can be used.<sup>2</sup>



**Image.** Ischemic necrosis of the right hand following peripheral catecholamine administration.

Our patient did have local debridement. Despite this, she eventually required amputation at the wrist 43 days after the initial arrest. After a prolonged hospitalization, she was liberated from the ventilator and discharged to subacute rehabilitation.

*Address for Correspondence:* David S. Bostick, MD, MPH, University of Maryland Medical Center, Department of Emergency Medicine, 6th Floor, Suite 200, 110 South Paca Street, Baltimore, MD 21201. Email: [dbostick@umem.org](mailto:dbostick@umem.org).

*Conflicts of Interest:* By the CPC-EM article submission agreement, all authors are required to disclose all affiliations, funding sources and financial or management relationships that could be perceived as potential sources of bias. The authors disclosed none.

*Copyright:* © 2017 Bostick. This is an open access article distributed in accordance with the terms of the Creative Commons Attribution (CC BY 4.0) License. See: <http://creativecommons.org/licenses/by/4.0/>

## REFERENCES

1. van der Rijt R, Martin-Smith JD, Clover AJ. Reversal of hand peripheral ischaemia due to extravasation of adrenaline during cardiopulmonary resuscitation. *J Plast Reconstr Aesthet Surg.* 2013;66(9):e260-3.
2. Hannon MG, Lee SK. Extravasation injuries. *J Hand Surg Am.* 2011;36(12):2060-5.

### *CPC-EM Capsule*

What do we already know about this clinical entity?

*Extravasation injuries are challenging to diagnose; however, is important that they are recognized and treated early. This becomes even more important when administering catecholamines peripherally in critically ill patients.*

What is the major impact of the image?  
*It is a reminder that patients receiving catecholamines peripherally are at risk for serious complications.*

How might this improve emergency medicine practice?

*This image serves as a reminder that it is important to heavily weight the risks and benefits of administering catecholamines through a peripherally inserted intravenous catheter and to discuss the risk of injury with patients or their families.*

# Join or Renew Today!



**AAEM** **RSA**

**Innovate. Educate. Advocate.**

American Academy of Emergency Medicine Resident & Student Association

## Join AAEM/RSA or Renew Your Membership!

[www.aemrsa.org/renew](http://www.aemrsa.org/renew) | 800-884-2236

Join RSA or renew for the 2017-2018 year for continued academic and career planning benefits, outstanding opportunities for involvement, and premier education.

## Are You Moving? Keep in Touch!

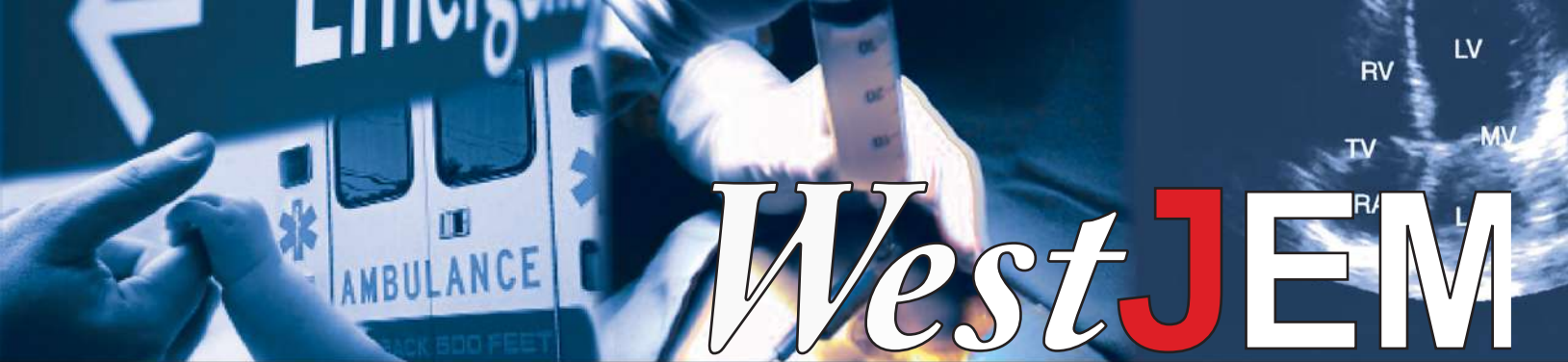If you are a graduating resident or medical student and your email address is changing, we recommend you update your address to one outside of your institution to ensure your benefits will continue without interruption. Log in to your members only account at [aaemrsa.org/myrsa](http://aaemrsa.org/myrsa) to list any changes to your name, mailing address, email address or phone number.



# Call for

# - REVIEWERS -

Please send your CV and letter  
of interest to  
[editor@westjem.org](mailto:editor@westjem.org)



*Western Journal of  
Emergency Medicine*

*Integrating Emergency Care with Population Health*

is proud to partner with  
AAEM to publish 25 of the best  
research abstracts related to  
Emergency Care and Population Health  
from:

**MEMC-GREAT 2017**

<http://www.emcongress.org/2017/abstracts/top-50>



UC Irvine Health





# MEMC-GREAT 2017 Joint Congresses

6-10 SEPTEMBER 2017 – LISBON, PORTUGAL

**Call for Abstracts and Posters**

Learn more at [emcongress.org](http://emcongress.org)



## Showcase Your Research!

Call for Abstracts and Posters

### Important Deadlines:

- 1 May 2017 Oral and Poster Abstract Submission
- 1 June 2017 Late Breaking Abstract Submission
- 1 July 2017 Abstract Acceptance Notification
- 1 August 2017 Late Breaking Abstract Acceptance Notification

The IX<sup>th</sup> MEMC is jointly organized by the American Academy of Emergency Medicine (AAEM), the Global Research on Acute Conditions Team (GREAT), and the Mediterranean Academy of Emergency Medicine (MAEM).

**Topics:** Cutting Edge Tracks, Clinical Updates, Reviews, Research, ED Management, and more

Speakers include the Who's Who in EM and an exceptional selection from EM departments and societies from all over the world.



## GREAT NETWORK CONGRESS

FOCUS ON INNOVATIONS AND TRANSLATIONAL  
RESEARCH IN EMERGENCY MEDICINE



**JOIN  
CAL/AAEM!**


*Championing  
individual physician rights  
and workplace fairness*

**BENEFITS**

- Western Journal of Emergency Medicine Subscription
- CAL/AAEM News Service email updates
- Discounted AAEM pre-conference fees
- And more!

**CAL/AAEM NEWS SERVICE**

- Healthcare industry news
- Public policy
- Government issues
- Legal cases and court decisions



In collaboration with our official journal

**WestJEM** Integrating Emergency Care  
with Population Health



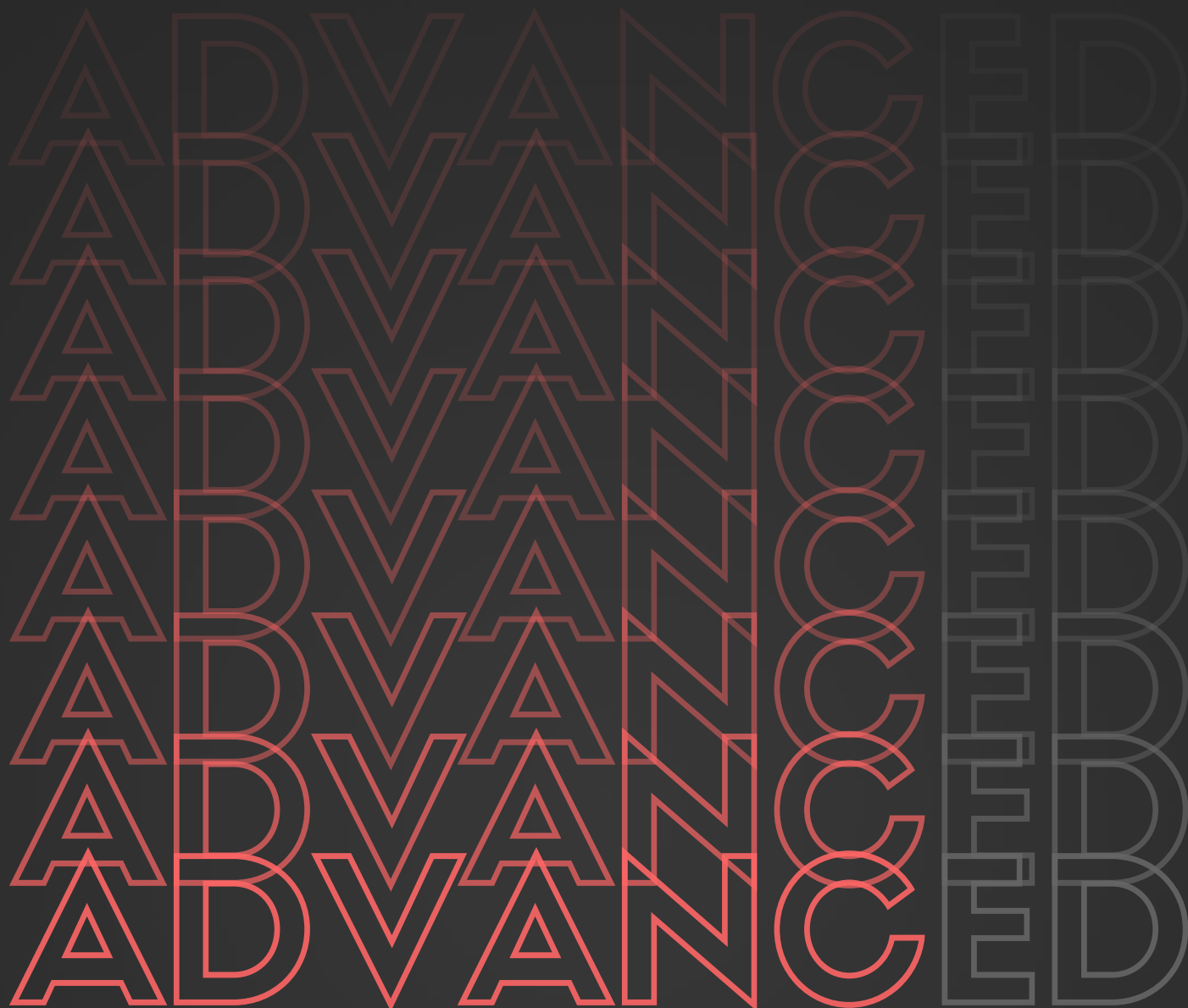FACEBOOK.COM/CALAAEM



FOLLOW US @CALAAEM

[HTTP://WWW.CALAAEM.ORG](http://www.calaaem.org)





# ADVANCED

WHEN

SATURDAY  
SEPTEMBER 23

WHAT

CALIFORNIA ACEP'S  
ANNUAL ASSEMBLY

WHERE

THE WESTIN  
PASADENA