

CPC Emergency Medicine

Volume IV, Number 3, August 2020

Open Access at www.cpcem.org

ISSN: 2474-252X

Clinical Practice and Cases in Emergency Medicine

In Collaboration with the *Western Journal of Emergency Medicine*

Clinicopathological Cases from the University of Maryland

- 272 **36-year-old Male with Syncope**
King SA, Spangler R, ZDW Dezman, Bontempo LJ

Clinicopathological Cases

- 277 **37-year-old Transgender Man with Fevers, Dysuria, and Sudden Decompensation**
Fleming ER, Gatz JD

Astonishing Cases and Images in Emergency Medicine

- 283 **The Prisoner Who Cried Wolf, and Then Swallowed a Sprinkler Head**
Hysell M, Finch J, McClendon DE

Medical Legal Case Reports

- 285 **Duty to Warn in the Emergency Department: Three Medical Legal Cases That Illustrate Providers' Broad Risk and Liability**
Pfaff R, Berkeley RP, Moore G, Heniff M

Case Series

- 289 **Using Lung Point-of-care Ultrasound in Suspected COVID-19: Case Series and Proposed Triage Algorithm**
Duggan NM, Liteplo AS, Shokoohi H, Goldsmith AJ
- 295 **Patients with Mild COVID-19 Symptoms and Coincident Pulmonary Embolism: A Case Series**
Joseph JW, Roberts JC, Anderson JS, Wong ML
- 299 **COVID-19 and Pulmonary Emboli: A Case Series and Literature Review**
Greenan-Barrett J, Perera A
- 304 **Ruptured Splenic Artery Aneurysm in the Postpartum Patient: A Case Series**
Rochester A, Lance T, Smith DE, Pfennig C, Tyson A, Moschella P
- 308 **Alternative Diagnostic Strategy for the Assessment and Treatment of Pulmonary Embolus: A Case Series**
Aghayev A, Memon AA, Greenough PG, Nayak L, Zheng S, Siedlecki AM

Contents continued on page iii



UC Irvine Health



A Peer-Reviewed, International Professional Journal



**ACOEP stands with all emergency
physicians and providers on the
front line. We thank you for your
tireless work and effort.**



www.acoep.org

Clinical Practice and Cases in Emergency Medicine

Indexed in PubMed and full text in PubMed Central

Rick A. McPheeters, DO, Editor-in-Chief
Kern Medical/UCLA- Bakersfield, California

Manish Amin, DO, Associate Editor
Kern Medical/UCLA- Bakersfield, California

Mark I. Langdorf, MD, MHPE, Associate Editor
University of California, Irvine School of Medicine- Irvine, California

Shadi Lahham, MD, MS, Associate Editor
University of California, Irvine School of Medicine- Irvine, California

Shahram Lotfipour, MD, MPH, Managing Associate Editor
University of California, Irvine School of Medicine- Irvine, California

Anna McFarlin, MD, Section Editor
Louisiana State University Health Science Center- New Orleans, Louisiana

Austin Smith, MD, Section Editor
Vanderbilt University Medical Center-Nashville, Tennessee

Christopher Sampson, MD, Section Editor
University of Missouri- Columbia, Missouri

Joel Moll, MD, Section Editor
Virginia Commonwealth University School of Medicine- Richmond, Virginia

Scott Goldstein, DO, Section Editor
Sidney Kimmel College of Medicine- Philadelphia, Pennsylvania

Steven Walsh, MD, Section Editor
Einstein Medical Center Philadelphia-Philadelphia, Pennsylvania

John Ashurst, DO, Section Editor
Kingman Regional Health Network, Arizona

Melanie Heniff, MD, Section Editor
University of Indiana School of Medicine- Indianapolis, Indiana

Editorial Board

Amin A. Kazzi, MD, MAAEM
The American University of Beirut, Beirut,
Lebanon

Anwar Al-Awadhi, MD
Mubarak Al-Kabeer Hospital, Jabriya,
Kuwait

Arif A. Cevik, MD
United Arab Emirates University
College of Medicine and Health Sciences, Al
Ain, United Arab Emirates

Abhinandan A. Desai, MD
University of Bombay Grant Medical
College, Bombay, India

Bandr Mzahim, MD
King Fahad Medical City, Riyadh, Saudi
Arabia

Barry E. Brenner, MD, MPH
Case Western Reserve University

Brent King, MD, MMM
University of Texas, Houston

Daniel J. Dire, MD
University of Texas Health Sciences Center
San Antonio

David F.M. Brown, MD
Massachusetts General Hospital/Harvard
Medical School

Edward Michelson, MD
Texas Tech University

Edward Panacek, MD, MPH
University of South Alabama

Erik D. Barton, MD, MBA
Icahn School of Medicine, Mount Sinai,
New York

Francesco Dellacorte, MD
Azienda Ospedaliera Universitaria "Maggiore
della Carità," Novara, Italy

Francis Counselman, MD
Eastern Virginia Medical School

Gayle Galletta, MD
Sorlandet Sykehus HF, Akershus
Universitetssykehus, Lorenskog, Norway

Hjalte Björnsson, MD
Icelandic Society of Emergency Medicine

Jacob (Kobi) Peleg, PhD, MPH
Tel-Aviv University, Tel-Aviv, Israel

Jonathan Olshaker, MD
Boston University

Katsuhiko Kanemaru, MD
University of Miyazaki Hospital, Miyazaki, Japan

Khrongwong Musikatavorn, MD
King Chulalongkorn Memorial Hospital,
Chulalongkorn University, Bangkok, Thailand

Leslie Zun, MD, MBA
Chicago Medical School

Linda S. Murphy, MLIS
University of California, Irvine School of
Medicine Librarian

Nadeem Qureshi, MD
St. Louis University, USA
Emirates Society of Emergency Medicine,
United Arab Emirates

Niels K. Rathlev, MD
Tufts University School of Medicine

Pablo Aguilera Fuenzalida, MD
Pontificia Universidad Católica de Chile,
Región Metropolitana, Chile

Peter A. Bell, DO, MBA
Liberty University
College of Osteopathic Medicine

Peter Sokolove, MD
University of California, San Francisco

Robert M. Rodriguez, MD
University of California, San Francisco

Robert Suter, DO, MHA
UT Southwestern Medical Center

Robert W. Derlet, MD
University of California, Davis

Rosidah Ibrahim, MD
Hospital Serdang, Selangor, Malaysia

Samuel J. Stratton, MD, MPH
Orange County, CA, EMS Agency

Scott Rudkin, MD, MBA
University of California, Irvine

Scott Zeller, MD
University of California, Riverside

Steven Gabaeff, MD
Clinical Forensic Medicine

Steven H. Lim, MD
Changi General Hospital, Simei, Singapore

Terry Mulligan, DO, MPH, FIFEM
ACEP Ambassador to the Netherlands Society of
Emergency Physicians

Vijay Gautam, MBBS
University of London, London, England

Wirachin Hoonpongmanont, MD, MSBATS
Siriraj Hospital, Mahidol University, Bangkok,
Thailand

Advisory Board

Amal Khalil, MBA
UC Irvine Health School of Medicine

Elena Lopez-Gusman, JD
California ACEP
American College of Emergency Physicians

Adam Levy, BS
American College of Osteopathic Emergency
Physicians

John B. Christensen, MD
California Chapter Division of AAEM

Lori Winston, MD
California ACEP
American College of Emergency Physicians
Kaweah Delta Healthcare District

Mark I. Langdorf, MD, MHPE
UC Irvine Health School of Medicine

Jorge Fernandez, MD
California ACEP
American College of Emergency Physicians
University of California, San Diego

Peter A. Bell, DO, MBA
American College of Osteopathic Emergency
Physicians
Liberty University, College of Osteopathic Medicine

Robert Suter, DO, MHA
American College of Osteopathic Emergency
Physicians
UT Southwestern Medical Center

Shahram Lotfipour, MD, MPH
UC Irvine Health School of Medicine

Brian Potts, MD, MBA
California Chapter Division of AAEM
Alta Bates Summit-Berkeley Campus

Editorial Staff

Leila Danishgar, BS
Editorial Director

Nicholas Gossett, BS
CPC-EM Associate Editorial Director
Associate Marketing Director

Maria Nguyen, BS
WestJEM Associate Editorial Director

June Casey, BA
Copy Editor

Alissa Fiorentino, BA
WestJEM Staff Liaison

Cassandra Saucedo, BS
CPC-EM Publishing Director

Ishan Shah, BS
CPC-EM Associate Publishing Director
Associate Marketing Director

Christine Louis, BS
WestJEM Publishing Director

Isabelle Nepomuceno, BS
WestJEM Associate Publishing Director
Associate Marketing Director

Official Journal of the California Chapter of the American College of Emergency Physicians, the American College of Osteopathic Emergency Physicians, and the California Chapter of the American Academy of Emergency Medicine



Available in MEDLINE, PubMed, PubMed Central, Google Scholar, eScholarship, DOAJ, and OASPA.

Editorial and Publishing Office: WestJEM/Department of Emergency Medicine, UC Irvine Health, 333 City Blvd, West, Rt 128-01, Orange, CA 92866, USA

Office: 1-714-456-6389; Email: Editor@westjem.org

Clinical Practice and Cases in Emergency Medicine

Indexed in PubMed and full text in PubMed Central

This open access publication would not be possible without the generous and continual financial support of our society sponsors, department and chapter subscribers.

Professional Society Sponsors

AMERICAN COLLEGE OF OSTEOPATHIC EMERGENCY PHYSICIANS
CALIFORNIA ACEP

CALIFORNIA CHAPTER DIVISION OF
AMERICAN ACADEMY OF EMERGENCY MEDICINE

Academic Department of Emergency Medicine Subscribers

Albany Medical College Albany, NY	INTEGRIS Health Oklahoma City, OK	Robert Wood Johnson University Hospital New Brunswick, NJ	University of Florida, Jacksonville Jacksonville, FL
American University of Beirut Beirut, Lebanon	Kaweah Delta Health Care District Visalia, CA	Rush University Medical Center Chicago, IL	University of Illinois at Chicago Chicago, IL
Arrowhead Regional Medical Center Colton, CA	Kennedy University Hospitals Turnersville, NJ	Southern Illinois University Carbondale, IL	University of Illinois College of Medicine Peoria, IL
Augusta University Augusta GA	Kern Medical Bakersfield, CA	St. Luke's University Health Network Bethlehem, PA	University of Iowa Iowa City, IA
Baystate Medical Center Springfield, MA	Lakeland HealthCare St. Joseph, MI	Stanford/Kaiser Emergency Medicine Residency Program Stanford, CA	University of Louisville Louisville, KY
Beaumont Hospital Royal Oak, MI	Lehigh Valley Hospital and Health Network Allentown, PA	Staten Island University Hospital Staten Island, NY	University of Maryland Baltimore, MD
Beth Israel Deaconess Medical Center Boston, MA	Loma Linda University Medical Center Loma Linda, CA	SUNY Upstate Medical University Syracuse, NY	University of Michigan Ann Arbor, MI
Boston Medical Center Boston, MA	Louisiana State University Health Sciences Center New Orleans, LA	Temple University Philadelphia, PA	University of Missouri, Columbia Columbia, MO
Brigham and Women's Hospital Boston, MA	Madigan Army Medical Center Tacoma, WA	Texas Tech University Health Sciences Center El Paso, TX	University of Nebraska Medical Center Omaha, NE
Brown University Providence, RI	Maimonides Medical Center Brooklyn, NY	University of Alabama, Birmingham Birmingham, AL	University of South Alabama Mobile, AL
Carl R. Darnall Army Medical Center Fort Hood, TX	Maricopa Medical Center Phoenix, AZ	University of Arkansas for Medical Sciences Little Rock, AR	University of Southern California/Keck School of Medicine Los Angeles, CA
Conemaugh Memorial Medical Center Johnstown, PA	Massachusetts General Hospital Boston, MA	University of California, Davis Medical Center Sacramento, CA	University of Tennessee, Memphis Memphis, TN
Desert Regional Medical Center Palm Springs, CA	Mayo Clinic College of Medicine Rochester, MN	University of California Irvine Orange, CA	University of Texas, Houston Houston, TX
Doctors Hospital/Ohio Health Columbus, OH	Mt. Sinai Medical Center Miami Beach, FL	University of California, Los Angeles Los Angeles, CA	University of Texas Health San Antonio, TX
Eastern Virginia Medical School Norfolk, VA	North Shore University Hospital Manhasset, NY	University of California, San Diego La Jolla, CA	University of Warwick Library Coventry, United Kingdom
Einstein Healthcare Network Philadelphia, PA	Northwestern Medical Group Chicago, IL	University of California, San Francisco San Francisco, CA	University of Washington Seattle, WA
Emory University Atlanta, GA	Ohio State University Medical Center Columbus, OH	UCSF Fresno Center Fresno, CA	University of Wisconsin Hospitals and Clinics Madison, WI
Genesys Regional Medical Center Grand Blanc, Michigan	Ohio Valley Medical Center Wheeling, WV	University of Chicago, Chicago, IL	Wake Forest University Winston-Salem, NC
Hartford Hospital Hartford, CT	Oregon Health and Science University Portland, OR	University of Colorado, Denver Denver, CO	Wright State University Dayton, OH
Hennepin County Medical Center Minneapolis, MN	Penn State Milton S. Hershey Medical Center Hershey, PA	University of Florida Gainesville, FL	
Henry Ford Hospital Detroit, MI	Presence Resurrection Medical Center Chicago, IL		

State Chapter Subscribers

ARIZONA CHAPTER DIVISION OF THE
AMERICAN ACADEMY OF EMERGENCY MEDICINE
CALIFORNIA CHAPTER DIVISION OF THE
AMERICAN ACADEMY OF EMERGENCY MEDICINE
FLORIDA CHAPTER DIVISION OF THE
AMERICAN ACADEMY OF EMERGENCY MEDICINE

GREAT LAKES CHAPTER DIVISION OF THE
AMERICAN ACADEMY OF EMERGENCY MEDICINE
TENNESSEE CHAPTER DIVISION OF THE
AMERICAN ACADEMY OF EMERGENCY MEDICINE

UNIFORMED SERVICES CHAPTER DIVISION OF THE
AMERICAN ACADEMY OF EMERGENCY MEDICINE
VIRGINIA CHAPTER DIVISION OF THE
AMERICAN ACADEMY OF EMERGENCY MEDICINE

International Society Partners

EMERGENCY MEDICINE ASSOCIATION OF TURKEY
LEBANESE ACADEMY OF EMERGENCY MEDICINE
MEDITERRANEAN ACADEMY OF EMERGENCY MEDICINE

NORWEGIAN SOCIETY FOR EMERGENCY MEDICINE
SOCIEDAD ARGENTINA DE EMERGENCIAS

SOCIEDAD CHILENO MEDICINA URGENCIA
THAI ASSOCIATION FOR EMERGENCY MEDICINE

To become a *WestJEM* departmental sponsor, waive article processing fee, receive print and copies for all faculty and electronic for faculty/residents, and free CME and faculty/fellow position advertisement space, please go to <http://westjem.com/subscribe> or contact:

Alissa Fiorentino
WestJEM Staff Liaison
Phone: 1-800-884-2236
Email: sales@westjem.org

JOURNAL FOCUS

Clinical Practice and Cases in Emergency Medicine (CPC-EM) is a MEDLINE-indexed internationally recognized journal affiliated with the *Western Journal of Emergency Medicine* (WestJEM). It offers the latest in patient care case reports, images in the field of emergency medicine and state of the art clinicopathological and medicolegal cases. CPC-EM is fully open-access, peer reviewed, well indexed and available anywhere with an internet connection. CPC-EM encourages submissions from junior authors, established faculty, and residents of established and developing emergency medicine programs throughout the world.

Table of Contents *continued*

- 312 Decompression of Subdural Hematomas Using an Intraosseous Needle in the Emergency Department: A Case Series**

B Barro, S Kobner, A Ansari

Case Reports

- 316 An Unusual Case Report of COVID-19 Presenting with Meningitis Symptoms and Shingles**
R Packwood, G Galletta, J Tennyson
- 321 A Case Report of Acute Transverse Myelitis Following Novel Coronavirus Infection**
D Sarma, LA Bilello
- 324 A Case Report of Coronavirus Disease 2019 Presenting with Tremors and Gait Disturbance**
S Klein, F Davis, A Berman, S Koti, J D'Angelo, N Kwon
- 327 Optimizing Non-invasive Oxygenation for COVID-19 Patients Presenting to the Emergency Department with Acute Respiratory Distress: A Case Report**
D Zodda, A Hanson, A Berns
- 332 Cardioembolic Stroke in a Patient with Coronavirus Disease of 2019 (COVID-19) Myocarditis: A Case Report**
JS Ford, JF Holmes, RF Jones
- 336 Case Report: Disposition of Symptomatic Probable COVID-19**
A Jaffery, J Slakey, D Zodda, D Finefrock
- 340 A Case Report: Co-presenting COVID-19 Infection and Acute Drug Intoxication**
J Riekana, I Lee, A Lui, MV Mempin
- 344 Acute Transverse Myelitis Secondary to Severe Acute Respiratory Syndrome Coronavirus 2 (SARS-CoV-2): A Case Report**
M Durrani, K Kucharski, Z Smith, S Fien
- 349 Mixed Purpuric and Maculopapular Lesions in a Patient with COVID-19: A Case Report**
R Beaupre II, C Petrie, A Toledo
- 352 A Case Report of Acute Motor and Sensory Polyneuropathy as the Presenting Symptom of SARS-CoV-2**
MR Kopscik, BK Giourgas, BC Presley
- 355 Point-of-care Ultrasound Detection of Cataract in a Patient with Vision Loss: A Case Report**
K Dornhofer, M Alkhatabi, S Lahham
- 358 A Case Report on Paget-Schroetter Syndrome Presenting as Acute Localized Rhabdomyolysis**
JB Lee, A Kurzweil, S Lahham

Policies for peer review, author instructions, conflicts of interest and human and animal subjects protections can be found online at www.cpcem.org.

Table of Contents *continued*

- 362 **Intracavernous Internal Carotid Artery Aneurysm Presenting as Acute Diplopia: A Case Report**
A Brown, H Jolliff, D Poe, M Weinstock
- 366 **Detection of Migrainous Infarction with Formal Visual Field Testing: A Case Report**
W Bylund, R Patrick, A Macdonald
- 371 **Ingestion of A Common Plant's Leaves Leads to Acute Respiratory Arrest and Paralysis: A Case Report**
BM Kear, RW Lee, SB Church, FA Youssef, A Arguija
- 375 **A Case Report of Widely Disseminated Tuberculosis in Immunocompetent Adult Male**
SB Esposito, J Levi, ZM Amaducci, DM Richardson
- 376 **Medial Pontomedullary Stroke Mimicking Severe Bell's Palsy: A Case Report**
B Boodaie, M Amin, K Sabetian, D Quesada, T Torrico
- 384 **A Case Report of Cake Frosting as a Source of Copper Toxicity in a Pediatric Patient**
HS Tsao, L Allister, T Chiba, J Barkley, RH Goldman
- 389 **Euglycemic Diabetic Ketoacidosis Precipitated by SGLT-2 Inhibitor Use, Pericarditis, and Fasting: A Case Report**
RA Mendelsohn, AN Taveras, BA Mazer, LM Clayton
- 393 **Acute Acalculous Cholecystitis from Infection with Epstein–Barr Virus in a Previously Healthy Child: A Case Report**
R Langenohl, S Young, K Couperus
- 397 **Pneumocephalus and Facial Droop on an Airplane: A Case Report**
I Sanjeevan-Cabeza, M Oakland
- 400 **Respiratory Failure Due to a Large Mediastinal Mass in a 4-year-old Female with Blast Cell Crisis: A Case Report**
CI Wade, CJ Couperus-Mashewske, ME Geurts, N Derfler, J Ngo, KS Couperus
- 404 **Point-of-care Ultrasound Identification of Iliopsoas Abscess in Emergency Department: A Case Report**
NA Al-Sadhan, O Liebmann, KH Dwyer
- 407 **A Case Report: Point-of-care Ultrasound in the Diagnosis of Post-Myocardial Infarction Ventricular Septal Rupture**
AJ Portuguese, KH Abdulla, M Vormovitsk, J DeAngelis
- 411 **Infected Recurrent Thyroglossal Duct Cyst: A Case Report**
J Foti, F Grimaldo
- 414 **Spontaneous Isolated Celiac Artery Dissection: A Case Report**
CL Freeman, AJ Lacy, A Miner, Dm Rogers, AT Smith, KS Shah
- 417 **Spinal Arteriovenous Fistula, A Manifestation of Hereditary Hemorrhagic Telangiectasia: A Case Report**
J Spangler, B Watsjold, JS Ilgen

Clinical Practice and Cases in Emergency Medicine (CPC-EM) is a open-access Medline-indexed internationally recognized journal affiliated with the *Western Journal of Emergency Medicine* (WestJEM). CPC-EM is distributed electronically to 19,000 emergency medicine scholars. This includes our sponsors California ACEP, the American College of Osteopathic Emergency Physicians, California Chapter of AAEM, and over 83 academic department of emergency medicine subscribers and 8 AAEM State Chapters.

Table of Contents *continued*

- 421 **Tranexamic Acid in a Case Report of Life-threatening Nontraumatic Hemorrhage in Immune Thrombocytopenic Purpura**
MM Randall, J Nurse, KP Singh
- 420 **Point-of-care Echocardiogram as the Key to Rapid Diagnosis of a Unique Presentation of Dyspnea: A Case Report**
M Moore, B Dilcher, J Minardi, K Quedado, E Shaver
- 428 **A Case Report: The Challenging Diagnosis of Spontaneous Cervical Epidural Hematoma**
FL Counselman, JM Tondt, H Lustig
- 432 **Atypical Cause of Sepsis from Bilateral Iliopsoas Abscesses Seeded from Self-mutilation: A Case Report**
S Langberg, S Azizi
- 436 **A Case Report of a Migrated Pelvic Coil Causing Pulmonary Infarct in an Adult Female**
A Guerrero, RG Theophanous
- 440 **A Missed Celiac Artery Aneurysm Leading to Rupture: A Case Report**
J Della Vecchia, E Blazar
- 443 **A Case Report of Nebulized Tranexamic Acid for Posttonsillectomy Hemorrhage in an Adult**
M Poppe, F Grimaldo
- 446 **An Unusual Presentation of Retinal Detachment and Conjunctivitis: A Case Report**
B Pierce, SM Alter, K Gerakopoulos, J Parmar
- 450 **Rectal Foreign Body Removal in the Emergency Department: A Case Report**
S Nesemann, KA Hubbard, MI Siddiqui, WG Fernandez
- 454 **A Rare Case Report of Lemierre Syndrome from the Anterior Jugular Vein**
N Rejali, M Heyer, D Finefrock

Images in Emergency Medicine

- 458 **COVID-19 with Hypoxic Respiratory Failure**
MA Martinez-Romo, S Lotfipour, CE McCoy
- 461 **Crazy-Paving: A Computed Tomographic Finding of Coronavirus Disease 2019**
M Gillespie, P Flannery, JA Schumann, N Dincher, R Mills, A Can
- 464 **48-year-old with Coronavirus Disease 2019**
H Gil, RM Finn, NP Raukar
- 466 **Pulmonary Artery Dissection Post-blunt Thoracoabdominal Trauma**
D Quesada, LA Morsky, A Jones, AL Capote
- 468 **Chest Wall Pain after Minor Trauma**
D Chandwani, J Arnold, J Terrusa
- 470 **Abdominal Computed Tomography with a Twist: The 'Whirl Sign' for Mesenteric Volvulus**
J Spangler, J Ilgen

Clinical Practice and Cases in Emergency Medicine (CPC-EM) is a open-access Medline-indexed internationally recognized journal affiliated with the *Western Journal of Emergency Medicine* (WestJEM). CPC-EM is distributed electronically to 19,000 emergency medicine scholars. This includes our sponsors California ACEP, the American College of Osteopathic Emergency Physicians, California Chapter of AAEM, and over 83 academic department of emergency medicine subscribers and 8 AAEM State Chapters.

Table of Contents *continued*

- 472 **Keratolysis Associated with Methamphetamine Use –Incidental Diagnosis of Corneal Melt in a Patient with Acute Methamphetamine Intoxication**
JS Heer, S Heavey, D Quesada, P Aguiñiga-Navarrete, MB Garrett, K Barkataki
- 474 **Symptomatic Aortic Endograft Occlusion in a 70-year-old Male**
J Cardenas, B Khazaeni
- 476 **De Winter T-wave Pattern in Proximal Left Anterior Descending Artery Occlusion**
D Gregory, B Wexler, B Becker
- 478 **Rare Cause of Syncope in a Gravid Female**
A Bellino, K Stats, J Ngo
- 480 **Hirschsprung’s Disease: A Rare Adult Diagnosis**
K Schmutz, G McGaig, BJ Theiling
- 482 **Tubelight Adrenals in Diabetic Ketoacidosis**
P Yadav, A Kumar, R Mathur, P Garg, M Gopalakrishnan, M Kumar Garg
- 485 **Use of Point-of-care Ultrasound for the Seizing Infant: An Adjunct for Detection of Abusive Head Trauma**
J Rowland, D Fouchia, M Favot
- 487 **A Case of a Missing Proximal Humerus**
JL Williams, SM Hochman
- 489 **Carotid Artery Dissection as a Result of Penetrating Ear Trauma**
N Peairs, J Stillings
- 491 **Bilateral Foot Skin Eruption in a Hepatitis C Patient**
S Davis, A Credit
- 493 **Point-of-care Ultrasound for Long Head of the Biceps Tendon Rupture**
BS Wayman, R Joseph
- 495 **Point-of-care Ultrasound in the Diagnosis of Calciphylaxis**
N Tobarran, M Collin
- 497 **Man with Penile Pain**
J Wray, RE Bridwell, MJ Yoo, CN Belcher, JJ Oliver

Clinical Practice and Cases in Emergency Medicine (CPC-EM) is a open-access Medline-indexed internationally recognized journal affiliated with the *Western Journal of Emergency Medicine* (WestJEM). CPC-EM is distributed electronically to 19,000 emergency medicine scholars. This includes our sponsors California ACEP, the American College of Osteopathic Emergency Physicians, California Chapter of AAEM, and over 83 academic department of emergency medicine subscribers and 8 AAEM State Chapters.

CPC**EM** Clinical Practice & Cases

CALL FOR SUBMISSIONS

- Patient Care Case Reports
- Images in Emergency Medicine

Fully open-access, peer reviewed,
well indexed: CPC-EM is available
anywhere with an internet
connection at **CPCEM.org**

***Clinical
Practice and
Cases in
Emergency
Medicine*** is an
internationally
recognized
journal
affiliated with
the MEDLINE-
indexed
***Western
Journal of
Emergency
Medicine***

**CPC-EM encourages submissions from junior authors and
countries with developing emergency medicine programs**

CPC**EM** Clinical Practice & Cases

CALL FOR CPC-EM SECTION EDITORS!

- Medical-Legal Case Reports
- Case Reports/Images in
Emergency Medicine

**Send your CV and letter of interest to
editor@cpcem.org**

WestJEM Integrating Emergency Care
with Population Health

CPCEM Clinical
Practice
& Cases

Call for Reviewers!

Please send your CV and letter of interest to
editor@westjem.org

CALL FOR SUBMISSIONS

Team Based Learning ▪ Podcasts ▪ Lectures ▪
Small Group Learning and Workshops ▪ Oral
Boards ▪ Simulation ▪ Curricula ▪ Innovations

CALL FOR REVIEWERS

JETem is an online,
open access, peer-
reviewed journal-
repository for EM
educators.

VISIT JETem.org
to learn more about
submissions or if
you're interested
in being a JETem
reviewer.



Journal of Education & Teaching in Emergency Medicine

A Journal of CORD

36-year-old Male with Syncope

Samantha A. King, MD*

Ryan Spangler, MD†

Zachary D.W. Dezman, MD, MS, MS†

Laura J. Bontempo, MD, MEd†

*University of Maryland Medical Center, Department of Emergency Medicine, Baltimore, Maryland

†University of Maryland School of Medicine, Department of Emergency Medicine, Baltimore, Maryland

Section Editor: Rick A. McPheeters, DO

Submission history: Submitted May 25, 2020; Revision received May 26, 2020; Accepted June 1, 2020

Electronically published July 20, 2020

Full text available through open access at http://escholarship.org/uc/uciem_cpccem

DOI: 10.5811/cpcem.2020.6.48419

Case Presentation: A 36-year-old incarcerated male presented to the emergency department (ED) after an episode concerning for syncope. The patient had nystagmus and ataxia on initial examination.

Discussion: There is a broad differential diagnosis for syncope, and for patients presenting to the ED we tend to focus on cardiogenic and neurologic causes. This case takes the reader through the differential diagnosis and systemic work-up of a patient presenting to the ED with syncope. [Clin Pract Cases Emerg Med. 2020;4(3):272–276.]

Keywords: *CPC; syncope; toxicology.*

CASE PRESENTATION (Samantha A. King, MD)

A 36-year-old male who was currently incarcerated presented to the emergency department (ED) with a chief complaint of syncope. The patient reported that the event occurred after he stood up from dinner. There were no witnesses, but the patient believes that he hit his head. He said he had a headache since the fall, and it had not responded to the acetaminophen that he received from the prison infirmary. He denied any tongue biting or loss of bowel or bladder control. The patient stated that he had felt dizzy and lightheaded over the prior few days, and that sensation continued in the ED. He also felt numb across his shoulders and had been nauseous since the fall.

He had a past medical history of seizures and bipolar disorder. His last seizure was several years prior and was described as “whole body shaking.” The patient reported compliance with his medications, which were fluoxetine, phenytoin, ranitidine, and valproic acid. He had no prior surgical history. His family history included diabetes in his grandmother. The patient drank alcohol socially and had used marijuana and abused prescription drugs in the past but had not used any substances recently.

On physical examination, he was awake, alert, and in no acute distress. He was afebrile (36.9° Celsius) with a heart rate of 84 beats per minute, a blood pressure of 116/72

millimeters of mercury, respiration 16 breaths per minutes, and oxygen saturation of 99% while breathing room air. He was 167.6 centimeters (cm) tall and weighed 63.5 kilograms (body mass index of 22.6 kg/m²), and was well nourished and well developed. There was a 2 cm x 2 cm hematoma and an overlying abrasion on his left forehead. Another abrasion on his upper lip was not actively bleeding. His external ears were normal without evidence of trauma. His nose was normal. His oropharynx was clear and moist. His pupils were 3 millimeters (mm) equal, round, and reactive to light and accommodation, and eyes were without scleral icterus. His neck was supple without tracheal deviation. He had normal range of motion of his neck and he had no cervical spinous process or paraspinal muscular tenderness. His heart was regular rate and rhythm without murmurs, rubs, or gallops. He had capillary refill of less than two seconds in all extremities. His lungs were clear to auscultation bilaterally without wheezes, rhonchi, or rales. He had regular respiratory effort without accessory muscle use. His abdomen was soft with normal bowel sounds without tenderness, rebound, or guarding. There was no costovertebral tenderness. His extremities exhibited no edema, tenderness, or deformity, and had 2+ pulses throughout. He had no spinous process or paraspinal process tenderness in his thoracic or lumbar spine.

His cranial nerves (II-XII) were intact. He was found to have bilateral and direction-changing horizontal nystagmus that was provoked on lateral gaze. No vertical or torsional nystagmus was seen. He had 5/5 strength with normal muscle tone throughout his upper and lower extremities bilaterally. He had decreased sensation across his shoulders bilaterally, but the remainder of his sensation was intact. He had slow finger to nose with overshoot bilaterally. His ambulation was limited secondary to feeling unsteady. He was oriented to person, place and time, answered questions appropriately, and followed commands without difficulty.

Initial laboratory results are shown in Table 1. His electrocardiogram (ECG) is shown in Image 1. He had a chest radiograph (Image 2). Computed tomography (CT) of his head and neck were performed (Image 3; full study is found in Supplemental Material 1). A diagnostic test was then performed, which confirmed the diagnosis.

CASE DISCUSSION (Ryan Spangler, MD)

The number of possible causes for this patient's presentation was daunting. He has a range of subacute and acute symptoms, and it is challenging to determine which one is the root cause, necessitating a wide differential diagnosis. The combination of syncope and other neurologic symptoms brought to mind five categories of illness:

- Cardiovascular (syncope/dizziness)
- Primary neurologic (seizure)
- Neurovascular (stroke)
- Traumatic
- Toxicologic

The patient did not experience chest pain, trouble breathing, or other symptoms that I would attribute to atypical angina to suggest an ischemic event. The fact that he had dizziness for several days could possibly indicate persistent arrhythmia or hypotension. However, his physical exam and vital signs do not indicate signs of either of these, and his ECG confirms that he does not have an arrhythmia currently despite being symptomatic. Therefore, I eliminated a cardiovascular etiology from my differential.

Primary neurologic causes, such as seizures, would certainly be plausible in a patient with his past medical history. However, the history provided does not describe specific seizure-like activity and does not describe a notable post-ictal period. Furthermore, the patient has been compliant with his seizure medications and, from the information I have, does not have a clear reason to have a lower seizure threshold. This makes seizure an unlikely primary diagnosis.

Stroke (thrombotic, embolic, or direct vascular injury) is certainly a diagnosis that must be explored in any patient

Table 1. Initial laboratory test results of a 36-year-old male with syncope.

	Lab values	Normal values
Complete blood count		
White blood cells	4.0 K/mcL	4.5 – 11.0 K/mcL
Hemoglobin	13.9 g/dL	12.6 – 17.4 g/dL
Hematocrit	40.1%	37.0 – 50.0%
Platelets	192 K/mcL	153 – 367 K/mcL
Serum chemistries		
Sodium	138 mmol/L	136 – 145 mmol/L
Potassium	3.9 mmol/L	3.5 – 5.1 mmol/L
Chloride	102 mmol/L	98 – 107 mmol/L
Bicarbonate	28 mmol/L	21 – 30 mmol/L
Blood urea nitrogen	10 mg/dL	9 – 20 mg/dL
Creatinine	0.7 mg/dL	0.66 – 1.25 mg/dL
Glucose	108 mg/dL	70 – 99 mg/dL
Calcium	9.1 mg/dL	8.6 – 10.2 mg/dL
Magnesium	1.6 mg/dL	1.6 – 2.6 mg/dL
Total protein	7.7 g/dL	6.3 – 8.2 g/dL
Albumin	4.3 g/dL	3.5 – 5.2 g/dL
Aspartate aminotransferase	26 u/L	17 – 59 u/L
Alanine aminotransferase	32 u/L	21 – 71 u/L
Alkaline phosphatase	84 u/L	38 – 126 u/L
Bilirubin	0.4 mg/dL	0.3 – 1.2 mg/dL

K, thousand; g, grams; mg, milligrams; mmol/L, millimole; L, liter; mcL, microliter; dL, deciliter; u, units.

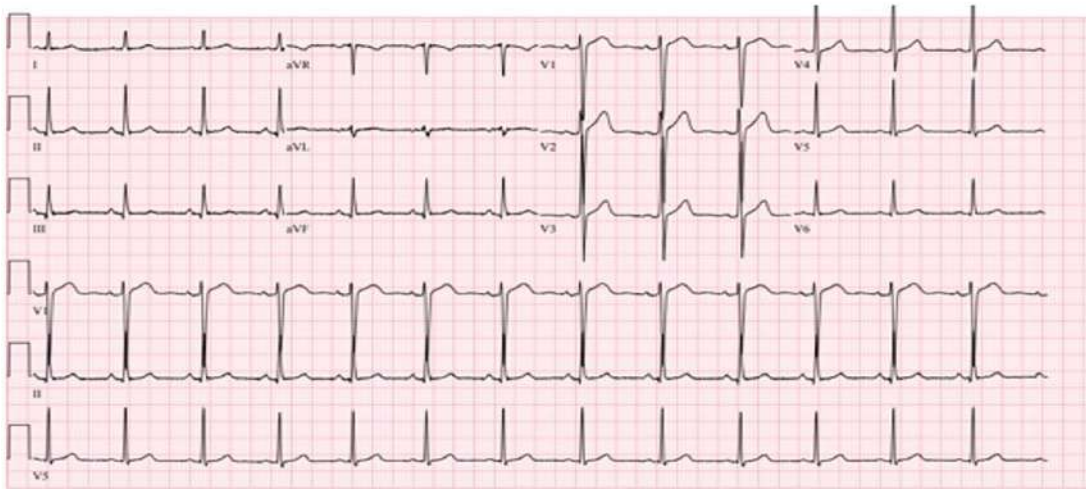


Image 1. Electrocardiogram of a 36-year-old male with syncope.

with dizziness, with particular attention being paid to the cerebellum and posterior fossa. The patient's history included a prodrome of dizziness for several days prior to falling. It does not provide significant further information regarding the timing and triggers of the dizziness. The patient "passing out" when standing up today, supports an alternate cause being more likely than an acute stroke since ischemic strokes are unlikely to cause syncope.

The patient has nystagmus, dysmetria and ataxia, but his cranial nerve exam is normal, including full extraocular motions and equally reactive pupils. The patient also has intact strength and overall sensation, with the exception of the neck and shoulders. This exam does not support a focal cranial infarct as the etiology. Basilar artery strokes can sometimes present with several days of subacute or flow-dependent symptoms, but I would expect many more global symptoms if this were the case. While a small posterior ischemic stroke is still possible, I believe other investigation is needed.

The presentation of headache with neurologic symptoms raises concern for a subarachnoid bleed. Generally, I would expect the history of a "sudden-onset" or "thunderclap" type onset, which was not given. The CT of the head was also negative. Although lumbar puncture would be considered the gold standard test for this diagnosis, I think the likelihood of the diagnosis being an occult subarachnoid hemorrhage is unlikely based on the history provided. I was told that the patient struck his head when he passed out. This brings into question whether there is actually a traumatic injury causing some of his presenting symptoms.

His history of prodromal dizziness tends to lead me away from this; however, he complains of, and on examination is found to have, numbness across the neck and shoulders. Injury to the cervical spine could possibly cause injury in this dermatome; however, he does not have any weakness in the upper or lower extremities, any distal sensation deficits, or tenderness on his neck exam. Overall, I think that although he

does have this complaint of numbness, his overall history and exam makes it unlikely that he has a cervical spine injury.

Another traumatic etiology to consider is vertebral artery dissection since this can cause posterior neurologic symptoms such as gait instability and dysmetria. Most of his symptoms, however, are bilateral. It would be extremely unlikely for the patient to injure both vertebral arteries simultaneously. Although the patient is presenting after a fall, this likely represents a "red herring" in the case.

When considering toxicologic etiologies of the patient's presentation, his examination is intriguing. The direction-changing horizontal nystagmus, bilateral dysmetria, and limited ambulation found on his examination are all concerning for a central neurologic injury but can also be due to other centrally acting insults, such as medication toxicity. Phenytoin and valproic acid toxicity can each present with diffuse or vague neurologic symptoms. Valproic acid toxicity typically causes tachycardia, thermal dysregulation, respiratory depression, and hypotension. Our patient has not experienced any of these effects. Phenytoin toxicity classically causes nystagmus, nausea, confusion, and ataxia. I believe this leads to the answer and can explain his bilateral neurologic symptoms.

The remaining question is this: Why would this patient have phenytoin toxicity without a recent change in dose or medication? The answer lies in his medication list. Fluoxetine and valproic acid are known to increase the systemic concentration of phenytoin due to similar cytochrome P450 metabolism, and there are case reports of both agents causing phenytoin toxicity. I believe that this interaction increased his risk of phenytoin toxicity over a longer period of time, even though there were no changes in his dosing and he was compliant. The confirmatory test will be a phenytoin level.

CASE OUTCOME (Samantha A. King, MD)

The diagnostic test was a total phenytoin level, which confirmed phenytoin toxicity. The patient had a total phenytoin

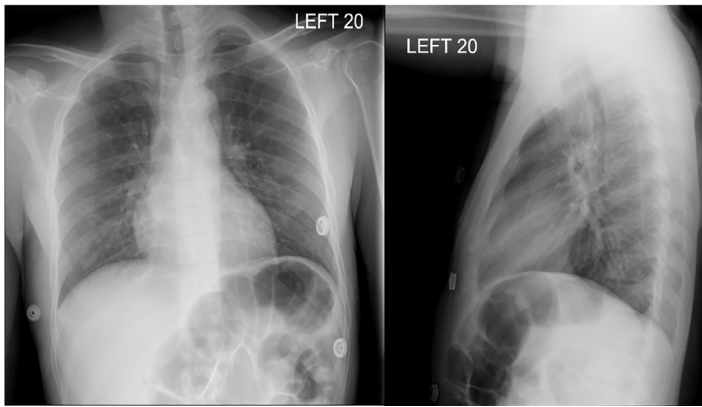


Image 2. Chest radiograph posterior-anterior (left) and lateral (right) of a 36-year-old male with syncope.

level of 27.4 micrograms/milliliter (mcg/mL). He was given intravenous (IV) fluids and ondansetron for his nausea. He was admitted to the internal medicine service, his phenytoin was held, and his phenytoin levels were trended. His phenytoin level reached a peak of 32.0 mcg/mL on hospital day (HD) 2. He thereafter had resolution of his symptoms and return of normal gait. He was ultimately discharged back to prison on HD 6. During his hospitalization, neurology was consulted. That service thought the patient's presentation was consistent with mild phenytoin toxicity. Neurology recommended changing his valproic acid medication to alternate mood stabilizer due to concern for possible interaction. After discharge, he remained stable on his phenytoin but had other presentations to the ED for musculoskeletal injuries.

RESIDENT DISCUSSION

Phenytoin toxicity occurs when a patient develops an excess of phenytoin in the blood related to either an acute ingestion or chronic accumulation of the drug.¹ According to the American Association of Poison Control Centers, in 2015 there were 1606 single-agent phenytoin exposures, and of those exposures there were 33 reported "major outcomes" and two reported deaths.² Phenytoin is considered one of the World Health Organization's essential medications; and in 2016 there were a reported 2,751,980 prescriptions written for it in the United States.^{3,4} However, phenytoin has become less popular as other anti-epileptics have come into use and so phenytoin toxicity is expected to become less common with time.^{2,4,5}

Phenytoin is a voltage-gated sodium channel blocker with predominant targets in neuronal and cardiac tissue.⁶ In neuronal tissue, it particularly targets high-frequency neurons, which lends to its anti-epileptic properties.⁶ It is metabolized through the cytochrome P450 system via first-order kinetics, but at higher levels it becomes metabolized through zero-order kinetics, which can be important in clearance when at toxic levels. Phenytoin is available 70% by oral ingestion and is 90% protein bound after ingestion.^{6,7} The high percentage of protein-bound phenytoin means that it can be greatly impacted by hypoalbuminemic states

such as pregnancy and malnutrition. This fact becomes important when interpreting serum phenytoin levels. Most institutions will only have total phenytoin levels, which is typically related to the available phenytoin in the blood, but one should consider ordering a free phenytoin level if suspecting a low-protein state.⁶

Phenytoin toxicity can affect a multitude of systems including neurologic, cardiac, skin, and immunologic. The degree of neurologic toxicity occurs in relatively predictable manner in correlation to the concentration of phenytoin in the blood⁶ (Table 2). The drug levels in the patient presented here correlate with some of his physical exam findings including nystagmus and ataxia. It is also important to note that an excess of phenytoin can lead to seizures, and other anti-epileptics have also been shown to have this effect.^{8,9} Additionally, given that phenytoin is a sodium channel blocker, it has effects on cardiac tissue. However, this effect is rarely, if ever, seen with oral phenytoin toxicity. It is more commonly occurs with IV phenytoin toxicity, seen often with rapid infusion.¹⁰ These effects include QRS widening, PR lengthening, and alterations of the ST-T wave segment.¹⁰ Additionally, it had been thought that the propylene glycol, which is used as the diluent for phenytoin, was the only cause of these effects; however, there are case reports of cardiac effects with both phenytoin and fosphenytoin infusions.¹ Other toxic effects of phenytoin include "purple glove syndrome," due to vasoconstriction after IV phenytoin infusion, and hypersensitivity syndromes.^{6,11}

Neurologic phenytoin toxicity can occur from a variety of mechanisms. A patient may have an acute toxicity secondary to either an accidental or intentional ingestion.¹ Patients with hypoalbuminemic conditions may suffer from a chronic phenytoin toxicity.^{1,6} Phenytoin is metabolized through the cytochrome P450 system, allowing for many potential adverse drug interactions that can precipitate chronic phenytoin toxicity.¹ In this case, the patient was taking valproic acid to treat his bipolar disorder. Valproic acid inhibits the P450 system, so medications like phenytoin last longer than expected in the body, which could result in a phenytoin toxicity. Lastly, phenytoin is sometimes mixed with cocaine, and there are cases in the literature of phenytoin toxicity occurring in cocaine users.¹²

Table 2. Symptoms of phenytoin toxicity as related to total phenytoin level.⁶

Total phenytoin level	Neurologic symptoms
< 10 mg/L	Rare side effects
10 - 20 mg/L	Occasional mild horizontal nystagmus on lateral gaze (therapeutic level)
20 - 30 mg/L	Nystagmus
30 - 40 mg/L	Ataxia, slurred speech, nausea, vomiting
40 - 50 mg/L	Lethargy, confusion, hyperactivity
> 50 mg/L	Coma, seizures

mg, milligrams; L, liter.

Treatment of phenytoin toxicity revolves predominantly around supportive care. Fatality from phenytoin poisoning is rare, with only two deaths reported in 2015.^{2,6} If a patient presents acutely ill, the focus of care should be resuscitation including, if needed, airway control, cardiovascular support with fluids or vasopressors, and control of seizures using agents such as benzodiazepines and barbituates. Treatment should also be targeted at symptoms including treatment with anti-emetics and institution of fall precautions.⁶ While there is not a directed reversal or binding agent, activated charcoal has been proposed as a mechanism for possible prevention of absorption in acute ingestions.⁵ However, instead of the standard single dose, multiple doses of activated charcoal have also been proposed in a case report as a method of possible treatment.¹³ Given the protein-bound nature of phenytoin, there is current debate over the clinical effectiveness of using other mechanisms such as hemodialysis for treatment.^{1,6}

FINAL DIAGNOSIS

Phenytoin toxicity

KEY TEACHING POINTS

1. Phenytoin toxicity can present with a range of symptoms and signs depending on the phenytoin level; common early symptoms include nystagmus and ataxia.
2. Phenytoin toxicity treatment focuses first on resuscitation and then supportive care.
3. Too much or too little phenytoin can cause seizures.

The authors attest that their institution requires neither Institutional Review Board approval, nor patient consent for publication of this clinicopathological case. Documentation on file.

REFERENCES

1. Craig S. Phenytoin poisoning. *Neurocrit Care*. 2005;3(2):161-70.
2. Mowry J, Spyker D, Brooks D, et al. 2015 Annual Report of the American Association of Poison Control Centers' National Poison Data System (NPDS): 33rd Annual Report. *Clin Toxicol*. 2016;54(10):924-1109.
3. World Health Organization. World Health Organization Model List of

Address for Correspondence: Laura Bontempo, MD, MEd, University of Maryland, Department of Emergency Medicine, 110 S Paca Street, Baltimore, MD 21201. Email: lbontempo@som.umaryland.edu.

Conflicts of Interest: By the CPC-EM article submission agreement, all authors are required to disclose all affiliations, funding sources and financial or management relationships that could be perceived as potential sources of bias. The authors disclosed none.

Copyright: © 2020 King et al. This is an open access article distributed in accordance with the terms of the Creative Commons Attribution (CC BY 4.0) License. See: <http://creativecommons.org/licenses/by/4.0/>

- Essential Medicines, 21st List. 2019. Available at: who.int/medicines/publications/essentialmedicines/en/. Accessed November 14, 2019.
4. ClinCalc. Phenytoin: Drug Usage Statistics, United States, 2006 - 2016. 2018. Available at: <https://clincalc.com/DrugStats/Drugs/Phenytoin>. Accessed November 5, 2019.
5. Brownstein AC, Spyker DA, Cantilena LR Jr, et al. 2011 Annual Report of the American Association of Poison Control Centers' National Poison Data System (NPDS): 29th Annual Report. *Clin Toxicol*. 2012;50(10):91-1164.
6. Iorga A and Horowitz B. (2019). Phenytoin toxicity. Treasure Island, FL: StatPearls.
7. Gugler R, Manion C, Azarnoff D. Phenytoin: Pharmacokinetics and bioavailability. *Clin Pharmacol Ther*. 1976;19(2):135.
8. Perucca E, Gram L, Avanzini G, et al. Antiepileptic drugs as a cause of worsening seizures. *Epilepsia*. 1998;39(1):5-17.
9. Bauer J. Seizure-inducing effects of antiepileptic drugs: a review. *Acta Neurol Scand*. 1996;94(6):367-77.
10. Guldiken B, Remi J, Noachtar S. Cardiovascular adverse effects of phenytoin. *J Neurol*. 2016;263(5):861-70.
11. Kirsch S, Bayard M, Darraj K. Distal upper extremity edema and discoloration. *Am Fam Physician*. 2007;75(6):889-91.
12. Roldan C. Phenytoin toxicity from cocaine adulteration. *West J Emerg Med*. 2014;15(2):127-30.
13. Weichbrodt G and Elliot D. Treatment of phenytoin toxicity with repeated doses of activated charcoal. *Ann Emerg Med*. 1987;16(12):1387-9.

37-year-old Transgender Man with Fevers, Dysuria, and Sudden Decompensation

Emily R. Fleming, MD*
J. David Gatz, MD†

*University of Wisconsin University Hospital, BerbeeWalsh Department of Emergency Medicine, Madison, Wisconsin

†University of Maryland School of Medicine, Department of Emergency Medicine, Baltimore, Maryland

Section Editor: Joel Moll, MD

Submission history: Submitted November 21, 2019; Revision received March 20, 2020; Accepted April 1, 2020

Electronically published July 20, 2020

Full text available through open access at http://escholarship.org/uc/uciem_cpchem

DOI: 10.5811/cpchem.2020.4.45956

Introduction: Patients in the emergency department may experience sudden decompensation despite initially appearing stable.

Case Presentation: A 37-year-old transgender man presented to the emergency department (ED) with several months of fevers, myalgias, and weight loss. The patient acutely became febrile, tachycardic, and hypotensive after an initially reassuring assessment in the ED.

Discussion: This case takes the reader through the differential diagnosis and work-up of the decompensating patient initially presenting with subacute symptoms. [Clin Pract Cases Emerg Med.2020;4(3):277–282.]

Keywords: *Clinicopathological cases; infectious disease; drug reaction.*

CASE PRESENTATION (Dr. Emily Fleming):

A 37-year-old transgender man presented to the emergency department (ED) of an urban, academic medical center in May with a four-month long course of symptoms including intermittent fevers, dysuria, and generalized malaise. He reported seeing his primary care provider (PCP) in January for dysuria and malaise after unprotected sex, tested positive for chlamydia, and was treated with azithromycin. He presented to his PCP again in March for what was now two months of weight loss, dysuria, fatigue, and body aches. Laboratory testing at that time included a complete blood count, basic metabolic panel, and thyroid stimulating hormone that were all within normal limits. A mononucleosis spot test and human immunodeficiency virus (HIV) test were both negative, and a urinalysis at that time was unrevealing.

In the ED the patient reported continued weakness, headaches, weight loss, and whole-body aches. He also reported intermittent fevers over the prior two weeks, measured at home as high as 101° Fahrenheit (F), coupled with 5-10 days of dysuria and suprapubic discomfort without

any vaginal or rectal discharge. He received moderate relief from acetaminophen and ibuprofen at home.

He reported a history of anxiety, depression, type 2 diabetes, hyperlipidemia, polycystic ovarian syndrome, asthma, and prior pulmonary embolism (PE). His prior surgeries included cholecystectomy, hysterectomy, and double mastectomy. He was taking sertraline, trazadone, amitriptyline, metformin, and testosterone. He denied any tobacco, alcohol, or illicit drug use. He reported being sexually active with male partners and not routinely using barrier protection. He reported an allergy to hydrocodone-acetaminophen.

Vital signs were as follows: temperature 98.5°F, blood pressure 125/76 millimeters of mercury (mmHg), pulse 69 beats per minute (bpm), respiratory rate 16 breaths per minute, oxygen saturation 99% on room air, and a body mass index of 28.2 kilograms per meter squared. Physical exam revealed an anxious but non-toxic man. Head was normal in appearance and atraumatic. Conjunctivae were normal. Mucus membranes were slightly dry. Neck was supple, with no pain on flexion, and no lymphadenopathy. The heart rate was normal, and

the rhythm was regular. There was no murmur. Lungs were clear to auscultation bilaterally and breathing was unlabored. The chest wall was notable for post-mastectomy scars. The abdomen was soft and nondistended, but with suprapubic tenderness to palpation. The extremities were warm and well perfused, and not edematous. Cranial nerves II-XII were intact, and gait and strength assessments were unremarkable. Skin was normal in appearance, without any lesions or rashes. Vaginal exam revealed a surgically absent cervix, and no bleeding, discharge, or adnexal tenderness. There were no hemorrhoids or other fluctuant mass palpable on rectal examination, but the patient did report moderate discomfort.

The patient's laboratory results, summarized in Table 1, did not require immediate intervention. He was treated in the ED with intravenous (IV) fluids, a nonsteroidal anti-inflammatory medication (NSAID), and was empirically treated with oral azithromycin and intramuscular (IM) ceftriaxone. Approximately one to two hours later a nurse went to discharge the patient but found his vitals to be grossly abnormal, including a temperature of 102.6°F, blood pressure 90/50 mmHg, pulse 135 bpm, respiratory rate 20 breaths per minute, and an oxygen saturation of 99% on room air. He now reported significant 8/10 full-body aches and severe headache. On examination he was now diaphoretic, rigoring, and tachycardic. His lungs remained clear to auscultation, while his abdomen remained soft and nondistended but still tender to palpation over the suprapubic region. Blood cultures and a lactate were sent because of this acute change. The patient additionally had an electrocardiogram (Image 1) and chest radiograph (Image 2). An additional test was sent from the ED, which confirmed the diagnosis.

FACULTY DISCUSSION (Dr. J. David Gatz):

A TALE OF TWO PATIENTS

What a case! And what a story! I cannot help but look across my desk to the bookshelf housing my haphazard collection of classic literature mixed between emergency medicine texts. I have always believed that each patient has a story to tell. While

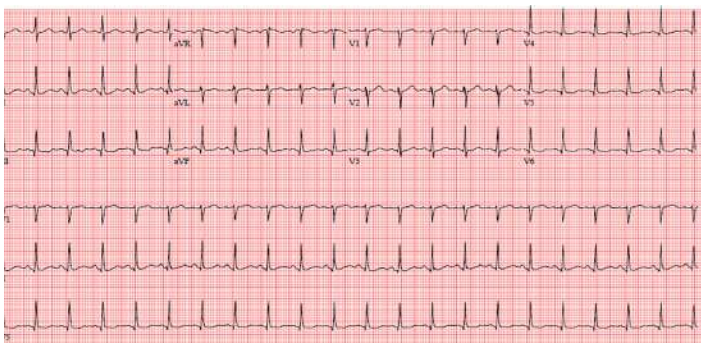


Image 1. Electrocardiogram of a 37-year-old male with sudden decompensation, taken while in the emergency department.

CPC-EM Capsule

What do we already know about this clinical entity?

The Jarisch-Herxheimer reaction is commonly encountered when treating syphilis with a penicillin and can cause significant changes in a patient's vital signs.

What makes this presentation of disease reportable?

This case describes an unexpected Jarisch-Herxheimer reaction while empirically treating a patient for gonorrhea with ceftriaxone.

What is the major learning point?

The Jarisch-Herxheimer reaction can occur while treating spirochetes other than syphilis, and while using antibiotics other than penicillin.

How might this improve emergency medicine practice?

Clinicians should anticipate this possible reaction given the high prevalence of syphilis and common use of empiric antibiotics for sexually transmitted infections.

some stories are action and others tragedy, many stories from the ED are mystery. We are presented in this case with a puzzling “pan-positive” review of systems and a small novel of additional information; it's overwhelming to know where to begin! Faced with such a task, I have elected to channel my own inner Charles Dickens and map out this patient's story.

The scene is set with a 37-year-old trans-male patient with an assortment of common chronic medical conditions. His medications appropriately match these diagnoses. The patient's testosterone supplementation and prior surgical procedures are also consistent with his gender transition. Foreshadowing or red herring, the patient has an otherwise unexplained history of PE. I must assume it was provoked from a prior surgery and successfully treated given that the patient is not on any chronic anticoagulation.

The story begins to build as we learn about unprotected receptive intercourse requiring prior treatment of chlamydia. There were otherwise no unique exposures. A couple months later our protagonist experienced dysuria and numerous systemic symptoms including weight loss and myalgias despite grossly negative laboratory studies. Fast forward two

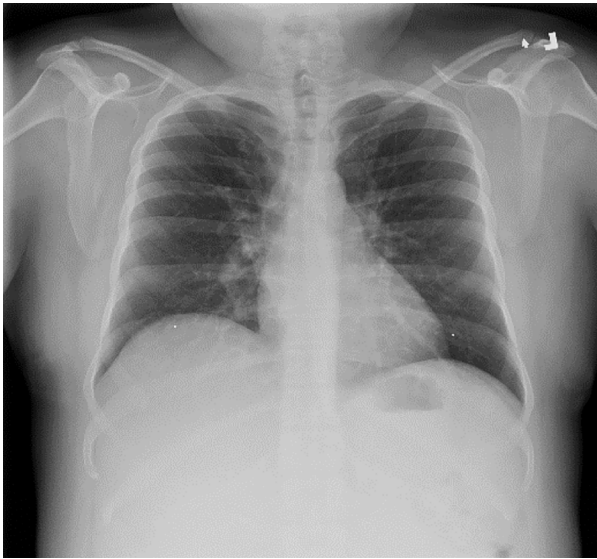


Image 2. Anterior-posterior chest radiograph of a 37-year-old transgender male with sudden decompensation while in the emergency department.

more months and these symptoms were joined by headaches, fevers, chills, and suprapubic discomfort. A fresh set of laboratory studies were, once again, grossly normal.

The patient was empirically treated with NSAIDs and typical empiric antibiotics for sexually transmitted infections, at which point we as readers suddenly experience a major plot twist! One of my favorite plotlines is in Dickens' *A Tale of Two Cities*, which features several characters traveling back and forth to Paris and London in the late 1700s. These cities are in stark contrast to one another. While London prospers, Paris descends into the chaos preceding the French Revolution. We witness a similar stark contrast in the story of our patient – who suddenly went from relatively stable to hypotensive, tachycardic, tachypneic, and febrile.

But what was the source of this sudden decompensation? And how did it tie into our protagonist's backstory? After careful deliberation I have narrowed it to four major possibilities. First, you will recall, our patient has a history of otherwise unexplained venous thromboembolism. An acute PE, especially if massive, could cause tachycardia, tachypnea, hypotension, and even fever!¹ But this fails to explain any of the subacute symptoms that led our patient to present in the first place. An underlying oncologic process could have predisposed the patient to PE and caused generalized malaise, but there is nothing specific to support such a diagnosis. Similarly, an ingestion could have caused a sudden change in vital signs. A sympathomimetic causes tachycardia, tachypnea, and an increased body temperature, but typically induces *hyper*-tension instead of *hypo*-tension. Similarly, an anticholinergic ingestion could cause tachycardia and

Table 1. Laboratory results of a 37-year-old transgender male with sudden decompensation.

Lab test	Value	Units	Normal range
White blood cell count	9.5	K/mcL	4.5 - 11.0
Hemoglobin	11.7	g/dL	12.6 - 17.4
Hematocrit	34.0	%	37.0 - 50.0
Platelets	335	K/mcL	153 - 367
Sodium	133	mmol/L	136 - 145
Potassium	4.0	mmol/L	3.5 - 5.1
Chloride	99	mmol/L	98 - 107
Bicarbonate	21	mmol/L	21 - 30
Glucose	107	mg/dL	70 - 99
Creatinine	0.75	mg/dL	0.66 - 1.25
Blood urea nitrogen	11	mg/dL	7-20
Urine glucose	Negative		Negative
Urine specific gravity	1.015		1.002-1.030
Urine ketones	Trace		Negative
Urine nitrites	Negative		Negative
Urine leukocyte esterase	Trace		Negative
Urine WBC	0-5	/hpf	0-5
Urine RBC	0-5	/hpf	0-5
HIV	Nonreactive		Nonreactive
Wet prep	Negative		Negative
Fungal smear	Negative		Negative
Gonorrhea testing	Pending		Negative
Chlamydia testing	Pending		Negative

K, kilogram; *mcL*, microliter; *g*, grams; *dL*, deciliter; *mmol*, millimoles; *L*, liter; *mg*, milligrams; *WBC*, white blood cells; *RBC*, red blood cells; *hpf*, high-power field; *HIV*, human immunodeficiency virus.

an increase in body temperature. But we are not given any indication or history of such exposures and, once again, this fails to explain the preceding subacute course of symptoms.

This leaves us looking for more clues from the patient's exam. He noted discomfort during the vaginal and rectal exam. Is it possible the provider was palpating a tender abscess? The indolent growth of an abscess could explain many of the patient's chronic symptoms, and a sudden rupture from palpation could have seeded a bolus of bacteria into the patient's bloodstream and precipitated an onset of sepsis. Tachycardia, tachypnea, fever, and hypotension are all hallmarks of severe sepsis. While this is beginning to look like a possibility, it raises the question of where and how this patient could have developed an abscess. A review of available case reports reveals numerous examples of ovarian and tubo-ovarian abscesses presenting years to over a

decade following an initial hysterectomy.²⁻⁶ This patient was also uniquely at risk of an uncommon sexually transmitted infection (STI) that is on the rise within certain populations including men who have sex with men – lymphogranuloma venereum (LGV).⁷ This serovar of *Chlamydia trachomatis* is specifically noted to cause lower abdominal pain following rectal inoculation from retroperitoneal and pelvic lymph nodes that practitioners are often unable to palpate on exam. As this infection progresses from secondary to tertiary, patients can develop a perirectal abscess and many of the constitutional symptoms this patient experienced.

The final possible etiology of this patient’s symptoms is a potential drug reaction from the antibiotics administered a few hours before his decompensation. The only allergic reaction that could occur within that time frame would be a Type I, immunoglobulin E-mediated anaphylactic reaction. While anaphylaxis is commonly characterized by respiratory symptoms and hypotension, it does not typically cause fever and does not explain the patient’s chronic symptoms.⁸ The azithromycin and ceftriaxone the patient received are common and appropriate treatments for chlamydia and gonorrhea. But ceftriaxone can be used to treat other STIs as well, including chancroid and syphilis.

The treatment of syphilis, intentional or not, can also cause a different type of reaction. It is worth noting that secondary syphilis can cause many of the chronic symptoms we have been attempting to explain: fever, headaches, weight loss, myalgias, and fatigue. Interestingly, patients may exhibit a rash so faint that patients and providers do not notice it. When treated, many spirochetes like syphilis can cause a Jarisch-Herxheimer reaction.⁹ The symptoms of this reaction are contrasted to those of anaphylaxis in Table 2. Taking these symptoms into account, we believe such a reaction seems like a reasonable etiology of this patient’s striking presentation. This reaction is usually associated with penicillin, but has been previously reported after administration of ceftriaxone.¹⁰

Ultimately, we seek a single diagnosis that unifies what is seemingly a tale of two patients. The previous discussion has left us with two reasonable choices: an LGV abscess or a Jarisch-Herxheimer reaction. A computed tomography or nucleic acid amplification test might diagnose the former, while a rapid plasma regain (RPR) or venereal disease research laboratory test (VDRL) should confirm the latter. In deciding between these, I cannot help but think back to one of the key characters from Dickens’ *A Tale of Two Cities*, Sydney Carton. Mr. Carton ultimately met his demise in the turbulent chaos of Paris and, like many Europeans of the time, was suspected of having a specific venereal disease – syphilis! Hopefully this patient’s story concludes with a far more favorable outcome!

Clinical Diagnosis

Jarisch-Herxheimer reaction following empiric treatment of syphilis.

Table 2. Similarities and differences between Jarisch-Herxheimer reaction and anaphylaxis.

	Jarisch-Herxheimer Reaction	Anaphylaxis
Onset	<ul style="list-style-type: none"> Varies by spirochete Occurs within hours to days of antibiotic administration 	<ul style="list-style-type: none"> Within minutes to hours of stimulus
Symptoms	<ul style="list-style-type: none"> Tachycardia Hypotension Hyperventilation Worsening rash Fever Chills Rigors Headache Myalgias Shock (rarely) 	<ul style="list-style-type: none"> Tachycardia Hypotension Bronchoconstriction Rash/Hives Angioedema Nausea/Vomiting Chest tightness Flushing Shock (possible) Death (possible)

CASE OUTCOME (Dr. Emily Fleming)

Multiple labs were sent after the patient’s change, including blood cultures and lactate. Ultimately a positive RPR confirmed the diagnosis. Given the patient’s vital signs and overall appearance, he was kept overnight in an observation unit and treated supportively with IV fluids and antipyretics. He felt much better and was discharged to the following morning to follow up with his PCP.

Unfortunately, despite just having completed three weeks of IM penicillin, the patient returned to the ED with a severe headache, photophobia, and word-finding difficulties. He also reported that his generalized malaise and weakness had yet to fully resolve. He had a normal neurologic exam and head computed tomography and felt better after a “headache cocktail” of medications, but he presented once again a week later with severe headache and slurred speech and was ultimately diagnosed with neurosyphilis after a positive lumbar puncture. Infectious disease was consulted, a peripherally inserted central catheter line was placed, and the patient received two weeks of IV ceftriaxone in the treatment of neurosyphilis.

RESIDENT DISCUSSION

The Jarisch-Herxheimer reaction is an acute febrile reaction that occurs within the first 24 hours of treatment. The pathophysiology is poorly understood but is thought to be due to a cytokine storm caused by the sudden release of bacterial products from injured or killed bacteria. This reaction has been reported in up to 30% of primary syphilis and up to 90% of secondary syphilis cases. Signs and symptoms include fever, myalgias, rigors, hypotension and rash.

Syphilis has been called the “great imitator” given its varied presentations. Primary syphilis is a local infection

that will present as a painless ulcer, known as a chancre. It is often accompanied by moderate regional lymphadenopathy. This presents on average 21 days after infection. It is often missed by patients given its painless and self-resolving nature. Secondary syphilis occurs approximately 4-12 weeks after initial infection. At this point the infection is now systemic, and patients often endorse constitutional symptoms (myalgias, fatigue, weight loss). Rash is the most easily identifiable sign of secondary syphilis. It is classically diffuse, maculopapular, and is also found on the palms and soles (making it somewhat unique). Secondary syphilis can less commonly cause hepatitis, acute nephritis, and synovitis.¹¹

Following early syphilis, there is often an asymptomatic period termed "latent syphilis." Approximately 40% of patients with untreated early syphilis will develop tertiary syphilis anywhere from 1-30 years after initial infection. The manifestations of late syphilis are varied, but most commonly affect the cardiovascular and central nervous systems. While neurosyphilis is often thought of as a complication of tertiary syphilis, it can occur in any stage of the disease. Early neurosyphilis often presents with meningitis (fever, headache), uveitis (decreased visual acuity), or infectious arteritis (stroke-like symptoms). Late neurosyphilis classically presents as general paresis or tabes dorsalis. General paresis is associated with personality changes and progresses to severe dementia. Tabes dorsalis affects the posterior column of the spinal cord resulting in sensory ataxia.¹²

Lumbar puncture is recommended in patients with known syphilis and any neurologic symptoms, HIV, or an RPR > 1:32. Cerebrospinal fluid (CSF) studies will often show high white blood cell and protein counts. The VDRL test is a highly specific but poorly sensitive CSF study whereas the fluorescent treponemal antibody absorption test is highly sensitive but is often a send-out lab.¹³ Treatment of syphilis depends on the stage of the disease. Early syphilis is treated with a single IM dose of 2.4 million units penicillin G. Late syphilis, or syphilis of unknown duration, requires once weekly injections of 2.4 million units of penicillin G for three weeks. Neurosyphilis at any stage requires two weeks of IV penicillin or ceftriaxone.¹⁴

FINAL DIAGNOSIS

Jarisch-Herxheimer reaction following treatment of neurosyphilis.

KEY TEACHING POINTS

1. LGV should be considered in high-risk groups such as men who have sex with men, and can lead to constitution symptoms and abscess formation if allowed to progress to tertiary stages.
2. The symptoms of anaphylaxis and a Jarisch-Herxheimer reaction can be clinically similar, but the latter typically occurs later (hours to days after drug

administration), can cause hyperthermia, and should cause a worsening of the patient's existing rash (in contrast to the hives that develop in anaphylaxis).

3. The classic rash associated with syphilis is made of diffusely spread asymptomatic maculopapular lesions that include the palms and soles, and may be so faint that it is overlooked by providers.

ACKNOWLEDGMENT

The authors thank the Council of Residency Directors in Emergency Medicine for hosting the Clinical Pathologic Case Competition and for supporting the publication of this manuscript.

The authors attest that their institution requires neither Institutional Review Board approval, nor patient consent for publication of this clinicopathological case. Documentation on file.

Address for Correspondence: J. David Gatz, MD, University of Maryland School of Medicine, Department of Emergency Medicine, 110 S Paca Street, 6th Floor, Suite 200, Baltimore, MD 21201. Email: jgatz@som.umaryland.edu

Conflicts of Interest: By the CPC-EM article submission agreement, all authors are required to disclose all affiliations, funding sources and financial or management relationships that could be perceived as potential sources of bias. The authors disclosed none.

Copyright: © 2020 Fleming et al. This is an open access article distributed in accordance with the terms of the Creative Commons Attribution (CC BY 4.0) License. See: <http://creativecommons.org/licenses/by/4.0/>

REFERENCES

1. Saad M, Shaikh DH, Mantri N, et al. Fever is associated with higher morbidity and clot burden in patients with acute pulmonary embolism. *BMJ Open Respir Res.* 2018;5(1):e000327.
2. Mendez L, Bhoola S, Horowitz I. Bilateral tubo-ovarian abscesses four years after total abdominal hysterectomy. *Infect Dis Obstet Gynecol.* 1998;6(3):138-40.
3. Powers K, Lazarou G, Greston WM, et al. Rupture of a tuboovarian abscess into the anterior abdominal wall: a case report. *J Reprod Med.* 2007;52(3):235-7.
4. Lau M, Cross CA, Berens P, et al. Ovarian abscess 15 months after vaginal hysterectomy. A case report. *J Reprod Med.* 1997;42(10):669-71.
5. Canas AM, Holloran-Schwartz B, Myles T. Tuboovarian abscess 12 years after total abdominal hysterectomy. *Obstet Gynecol.*

- 2004;104(5 Pt 1):1039-41.
6. Tohya T, Yoshimura T, Onoda C. Tubo-ovarian abscess occurring 16 years after supracervical hysterectomy. *Infect Dis Obstet Gynecol*. 2003;11(3):167-9.
 7. Ceovic R and Gulin SJ. Lymphogranuloma venereum: diagnostic and treatment challenges. *Infect Drug Resist*. 2015; 8:39-47.
 8. McLendon K and Sternard BT. (Updated 2019). Anaphylaxis. In: StatPearls [Internet]. Treasure Island, FL; StatPearls Publishing.
 9. Butler T. The Jarisch–Herxheimer reaction after antibiotic treatment of spirochetal infections: a review of recent cases and our understanding of pathogenesis. *Am J Trop Med Hyg*. 2017;96(1):46-52.
 10. Chan DJ, Michelmore HM, Gold J. A diagnosis unmarked by an unusual reaction to ceftriaxone therapy for gonorrheal infection. *Med J Aust*. 2003;178(8):404-5.
 11. Chapel TA. The signs and symptoms of secondary syphilis. *Sex Transm Dis*. 1980;7(4):161-4.
 12. French P. Syphilis. *BMJ*. 2007;334(7585):143-7.
 13. Marra CM, Maxwell CL, Smith SL, et al. Cerebrospinal fluid abnormalities in patients with syphilis: association with clinical and laboratory features. *J Infect Dis*. 2004; 189(3):369-76.
 14. Clement ME, Okeke NL, Hicks CB. Treatment of syphilis: a systematic review. *JAMA*. 2014; 312(18):1905-17.

The Prisoner Who Cried Wolf, and Then Swallowed a Sprinkler Head

Matthew Hysell, MD*
Jennifer Finch, MD†
David E. McClendon, MS‡

*Spectrum Health-Lakeland, Department of Emergency Medicine, St. Joseph, Michigan
†Holy Family Memorial Medical Center, Department of Emergency Medicine, Manitowoc, Wisconsin
‡Michigan State University College of Osteopathic Medicine, Department of Emergency Medicine, East Lansing, Michigan

Section Editor: Rick A. McPheeters, DO

Submission history: Submitted January 13, 2020; Revision received April 7, 2020; Accepted April 1, 2020

Electronically published May 18, 2020

Full text available through open access at http://escholarship.org/uc/uciem_cpccem

DOI: 10.5811/cpcem.2020.4.46449

Case Presentation: A 37-year-old man presented from jail reporting foreign body ingestion of a sprinkler head. While initial radiography did not reveal the foreign body, subsequent imaging with computed tomography demonstrated the sprinkler head. When confronted with this discrepancy the patient admitted to having the sprinkler head in his possession and choosing to swallow it after his initial radiography.

Discussion: This case demonstrates the importance of maintaining a high threshold for real illness in situations where there is suspected malingering, a situation not infrequently encountered in the emergency department. [Clin Pract Cases Emerg Med. 2020;4(3):283–284.]

Keywords: *prisoner; swallow; incarceration; malingering.*

CASE PRESENTATION

A 37-year-old man presented to the emergency department (ED) from jail reporting foreign body ingestion. The patient reported other prisoners had repeatedly punched him; guards informed him a provider would see him the following day. He then reported swallowing his jail cell's sprinkler head, successfully triggering evaluation. Physical exam demonstrated periorbital ecchymosis. Head computed tomography (CT) revealed facial fractures. Chest radiograph was unremarkable (Image A). The negative chest radiograph was discussed with the patient, who vehemently insisted he had swallowed the sprinkler head and reported globus. Chest CT demonstrated a metallic foreign body in the upper esophagus (Image B) at a level visualized by radiography. The patient later admitted to possession of the sprinkler head through his course in the ED, ultimately swallowing it covertly after the radiograph. Endoscopic removal was successful.

DISCUSSION

Ingestion of foreign bodies by inmates and psychiatric patients is well documented.^{1,2} The delay in medical treatment following the patient's assault offers a possible motive for his

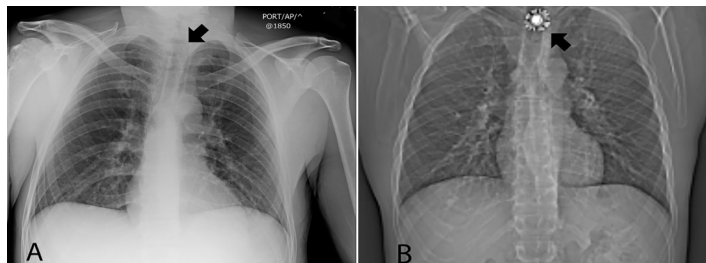


Image. A. Normal initial chest radiograph absent of any ingested sprinkler head (arrow). B. Computed tomography scout view of chest now demonstrating the ingested sprinkler head (arrow).

claim to have swallowed the foreign body. However, it was only after the patient arrived to the hospital and received medical care that he chose to swallow the sprinkler head. With negative initial testing it would have been easy for providers to have followed the actions of the villagers in “The Boy Who Cried Wolf” and to terminate further work-up. In this case the patient cried wolf so to speak, and then proceeded to release the wolf in the form of the sprinkler head ultimately demonstrated in the upper esophagus. While the patient's rationale for the ingestion of the foreign body

remains unclear, it is possible he wished to avoid return to jail where he had just been assaulted.³ This case demonstrates that maintaining a high threshold for real illness and listening to the patient, even in situations where malingering is suspected, is always necessary in the ED.

The authors attest that their institution requires neither Institutional Review Board approval, nor patient consent for publication of this case report. Documentation on file.

Address for Correspondence: Matthew Hysell, MD, Spectrum Health-Lakeland, Department of Emergency Medicine, 1234 Napier Ave., St. Joseph, MI 49085. Email: mhysell@lakelandhealth.org.

Conflicts of Interest: By the *CPC-EM* article submission agreement, all authors are required to disclose all affiliations, funding sources and financial or management relationships that could be perceived as potential sources of bias. The authors disclosed none.

Copyright: © 2020 Hysell et al. This is an open access article distributed in accordance with the terms of the Creative Commons Attribution ([CC BY 4.0](http://creativecommons.org/licenses/by/4.0/)) License. See: <http://creativecommons.org/licenses/by/4.0/>

REFERENCES

1. Evans D. Intentional ingestions of foreign objects among prisoners: a review. *World J Gastrointest Endosc.* 2015;7(3):162.

2. O'Sullivan S, Reardon C, McGreal G, et al. Deliberate ingestion of foreign bodies by institutionalized psychiatric hospital patients and prison inmates. *Ir J Med Sci.* 1996;165(4):294-6.
3. Berry S. Deciphering when patients feign symptoms to avoid incarceration. *JEMS.* 2014;8(39):66.

CPC-EM Capsule

What do we already know about this clinical entity?

The ingestion of foreign objects by inmates is well documented. Clinicians are also frequently faced with histories that may not be accurate.

What is the major impact of the image(s)?

First image demonstrates that initially provided history of foreign body ingestion was inaccurate. But upon subsequent imaging the foreign body was clearly visualized.

How might this improve emergency medicine practice?

This case demonstrates the importance of maintaining a high threshold for real illness even in situations where malingering is suspected or even demonstrated.

Duty to Warn in the Emergency Department: Three Medical Legal Cases That Illustrate Providers' Broad Risk and Liability

Rosemary Pfaff, BS*
Ross P. Berkeley, MD†
Gregory Moore, MD, JD‡
Melanie Heniff, MD, JD§

*Baylor University School of Medicine, Department of Emergency Medicine, Houston, Texas
†University of Nevada, Las Vegas School of Medicine, Department of Emergency Medicine, Las Vegas, Nevada
‡Mayo Clinic, Department of Emergency Medicine, Rochester, Minnesota
§Indiana University School of Medicine, Department of Emergency Medicine, Indianapolis, Indiana

Section Editor: Rick A. McPheeters, DO

Submission history: Submitted: March 4, 2020; Revision received: May 24, 2020; Accepted: May 27, 2020

Electronically published July 20, 2020

Full text available through open access at http://escholarship.org/uc/uciem_cpccem

DOI: 10.5811/cpcem.2020.5.47222

This article presents three medical-legal cases that define a physician's duty to warn and include caveats on medical practice within the scope of the law. Some physicians may not recognize that these legal and liability requirements extend not only to physical danger, but also to infectious diseases, medical illness, and drug effects. [Clin Pract Cases Emerg Med. 2020;4(3):285–288.]

Keywords: *duty to warn; emergency providers.*

INTRODUCTION

Many emergency physicians and providers are aware of their duty to warn in situations where a patient expresses ideation of harming another person(s) physically. However, fewer may understand the specific legal obligations of this duty and who should be warned. Also, physicians may not be aware that this legal duty extends to infectious disease, other diseases, and medications, which opens them to broad legal liability. Three cases below will give representative examples of this “duty to warn” and will be followed by other enlightening and classic cases with legal and medical caveats.

CASES

Case 1: Anonymous versus Anonymous – North Carolina

A patient presented to the ED on two occasions reporting thoughts of killing his wife. He seemed relatively reasonable and stated that he could control these urges and would seek psychiatric follow-up care. After discharge from the ED, he killed his wife and children. He lived in his house with the dead bodies for several weeks before killing himself. The case settled for \$11.5 million.¹

Case 2: Washington versus Pediatric Cool Care – Washington

A 14-year-old female presented to a pediatric urgent care with symptoms of depression. She was evaluated and

prescribed citalopram. After the initial visit, the patient had one follow-up appointment with a nurse practitioner in the same facility. Five months later, the patient committed suicide by overdosing on the citalopram that was prescribed. Citalopram has a black box warning advising that it should not be prescribed to adolescents as it may cause suicidal ideation. Her parents brought suit claiming that there was no discussion with the patient or her mother with regard to side effects. They also were not advised to read the package insert. The mother was not encouraged to observe her child closely for worsening symptoms or suicidal ideation. The plaintiffs also claimed that referral to a psychiatrist or psychologist for evaluation was not initiated by the primary providers either. After hours of deliberation, a jury awarded the plaintiffs \$7.65 million.²

Case 3: Kochik versus Hanna et al

A patient was diagnosed with partially controlled and unpredictable seizures and received treatment from onset forward. Defendant Dr. Moore, her family practice physician, and defendant Dr. Zind, a neurologist, provided the patient's care together. Evidence of whether the physicians advised her that it was unsafe for her to drive was conflicting. Six years after the diagnosis, the patient was driving home and had a seizure, which caused her to lose consciousness and control of

her vehicle. She crossed the centerline and struck an automobile carrying four people, causing their deaths. The plaintiff brought this action against the defendants for their negligence regarding their failure to warn her not to drive due to her seizure disorder. The Court found that it is clearly foreseeable that the defendants' alleged failure to warn the patient not to drive would endanger the motoring public, which would include the decedents in this case. Specifically, the Court found that the likelihood of injury to a third party due to an automobile accident arising from the physicians' failure to inform her not to operate a motor vehicle is not so rare or unusual an occurrence as to be considered unforeseeable. Furthermore, warning the patient that it was unsafe for others if she drove did not violate physician-patient confidentiality as those in danger would not be aware of her condition.³ The case has yet to be fully adjudicated for damages.

Ms. Pfaff

On October 27, 1969, Prosenjit Poddar killed Tatiana Tarasoff. Prior to the murder, Poddar disclosed his intention to kill Tarasoff to his psychologist, Dr. Lawrence Moore. Dr. Moore attempted to have Poddar detained after the admission. Poddar was released after the police determined Poddar to be of a rational state of mind. Dr. Moore's superior directed that no further action be taken in the attempt to detain Poddar. Following this sequence of events, Poddar murdered Tatiana Tarasoff by shooting her with a pellet gun and repeatedly stabbing her with a kitchen knife. Upon conviction, Poddar was diagnosed with paranoid schizophrenia, a diagnosis previously suggested by Dr. Moore during his psychiatric care.

The victim's plaintiff parents filed a claim that the psychiatrists in question breached their duties to provide reasonable care. Initially, the claim was dismissed by the Superior Court of Alameda (California), under the assertion that Dr. Moore's duty to provide reasonable care to Poddar, his patient, was fulfilled in his attempts to treat and detain, maintaining doctor-patient confidentiality. The plaintiffs amended their claim, citing that the psychiatrist had a duty to warn either Tatiana or her immediate family of the imminent danger. The Supreme Court of California held that the defendants did, in fact, fail in their duty to warn, weighing the societal benefits over the need to maintain patient confidentiality. This set a new precedent for the responsibilities of mental health providers.

Defendants argued that setting a precedent for a duty to warn would lead to a majority of erroneous warnings, compromising a patient's trust in confidentiality and hindering adequate patient care. The burden of correctly identifying potentially dangerous patients would reside on the provider, and the provider would inevitably err on the side of caution and report his or her patient and warn potential victims. The court's ruling emphasizes that these risks to the patient-provider relationship are justified by

the societal good and safety that comes with the warning of a potential threat. Providers today are responsible for warning persons directly threatened by a patient, or individuals close to the potential victim, if the provider suspects a legitimate danger. As it stands, however, the law supports that a physician's duty extends beyond that of his patient's care, and thus a duty to warn potentially vulnerable individuals is necessary.

It is important to highlight that while many providers are aware of this landmark case, few realize that notifying the police did not absolve them of responsibility or liability.⁴

Dr. Heniff

Identifying those who are legally at risk is subject to vague and wide interpretation by courts, making the task very difficult for front-line healthcare providers. A recent court case further affirmed and seemed to expand the duty to warn.⁵ A patient with bipolar disorder saw a psychiatrist on an outpatient basis over the course of 10 years. The patient had a history of poor compliance with medication and on several occasions expressed homicidal and suicidal thoughts. After his wife divorced him, he suffered worsening depression and again expressed suicidal and homicidal thoughts but assured his physician that he would not act on the thoughts. Two years later, the patient fell in love and became engaged to a woman who had three sons. The woman moved herself and her sons out of the home after he hit one of her sons. The patient then saw his psychiatrist for what would be the final time and stated he was experiencing some suicidal ideation but would not act on it. He indicated that he was stable and getting back together with his fiancée and didn't express homicidal ideation.

Three months later, the patient shot and killed his fiancée and one of her sons. He then returned to his home where he committed suicide.

The family of the victims brought suit against the psychiatrist and the psychiatric clinic. The case was appealed to the Supreme Court of Washington, which found that the psychiatrist's duty extended to all foreseeable victims, not just readily identifiable potential victims. The court stated that the psychiatrist in Volk had "a duty to protect anyone who might foreseeably be endangered by the patient's 'dangerous propensities.'"

The lone dissenting justice in Volk objected to the court's broadening of the duty to warn without articulating the "precise scope of this new duty, to whom it will apply, and why we make such a change."

Emergency department patients often make threats when influenced by drugs, alcohol, or anger. Since emergency physicians are usually meeting their patients for the first time it is very difficult to assess the seriousness of the threat and even more challenging to identify any foreseeable victims. When an emergency physician evaluates a patient he or she clearly establishes a duty to that particular patient, but at what point a duty to third parties is established is more difficult to define. In

tort law the likelihood of harm is not enough; the likelihood must also be foreseeable. Foreseeability often involves considerations such as the ability to “anticipate future events or to anticipate dangerous conditions that already exist.” This foreseeability is difficult to define but often focuses on what a person should have known at the time of alleged negligence. Such determinations are fact specific and vary from case to case. The decision of whether or not something is foreseeable is left to the factfinder (jury or judge depending on the type of trial). To find a person liable for negligence in a duty-to-warn case, the factfinder will be asked to decide whether the harm that occurred was reasonably foreseeable by the person accused of negligence.⁶ What remains unclarified in case law or statutes is exactly how a physician could possibly identify and specifically warn any foreseeable victim of a mentally ill or potentially violent patient.

Dr. Berkeley

In the landmark Tarasoff case the court also iterated a duty to warn those with infections or other diseases. In an illustrative, classic court case a patient presented to an ED with a headache, fevers and chills, and myalgias, and was admitted. His condition deteriorated and he died four days later due to Rocky Mountain spotted fever (RMSF). Throughout the course of the patient’s treatment, his physician had never informed his wife that her husband had died from RMSF, which is transmitted through the bite of an infected tick. A week after the death of her husband, she was admitted to another hospital with similar symptoms and, despite treatment for presumed RMSF, she died three days later. Her son brought suit against the first physician for negligence in failing to warn his mother that she was at risk of exposure to RMSF. During a jury trial, a plaintiff’s expert testified that family members of patients with RMSF are at risk of contracting the disease due to the geographic clustering activity of infected ticks, and a verdict was returned against the physician defendant.

The Tennessee Supreme Court subsequently granted an appeal “to determine whether a physician has a legal duty to warn a non-patient of the risk of exposure to the source of his patient’s noncontagious disease.” In its decision, the court noted that although RMSF is not contagious “it is likely that others in the patient’s household may have come into contact with infected ticks.” The court concluded that a physician has “an affirmative duty to warn identifiable third persons in the patient’s immediate family against foreseeable risks emanating from a patient’s illness...” and held that Dr. Daniel “had a duty to warn his patient’s wife of her risk of contracting Rocky Mountain Spotted Fever...”

This case serves as a cautionary tale of the duty to warn third parties of the risks relating to infectious diseases. The court’s decision is alarming due to the fact that RMSF is not transmissible between humans; thus, the infected patient’s wife was not in danger of contracting the disease from her

husband. However, the court held that the physician had a legal duty to warn the patient’s wife of her “foreseeable risk” of potential exposure to infected ticks and contracting RMSF. It must be recognized that this duty may place a significant burden on a provider. Although this case did not happen to involve an emergency physician, the key lesson to take away is that physicians may be liable if they fail to warn identifiable members of a patient’s immediate family if they are foreseeably at risk of exposure to the patient’s disease. From the risk management perspective, such notification should be documented in the medical record.⁷

Dr. Moore

The Tarasoff case also mandated a duty to warn when medications and their side effects may lead to harm to others. This duty is defined further in the following two legal cases.

In the first case, a 12-year-old boy was diagnosed with attention deficit hyperactivity disorder ADHD by his physician and it was decided to begin desipramine (Norpramin). The physician testified that she showed the patient’s mother an entry for tricyclic antidepressants in the *Physician’s Desk Reference*. The entry described common side effects associated with the group of antidepressants, such as dry eyes and mouth and increased pulse rate. The physician also explained that the child should be watched closely for rapid heartbeat. Two years later, after multiple medical visits to a variety of settings, for multiple complaints, the child died from hypereosinophilic syndrome, which is a rare but known complication of desipramine. The parents brought suit against Walmart alleging that it was negligent in the sale of desipramine “by failing to properly warn intended users of the hazards and harms associated with the use of the product.” The court ruled that the pharmacist had no duty to warn the patient of side effects. The physician was held liable for \$1.012 million.⁶

Thus, a pharmacist is not held to have a duty to warn a patient of side effects; this is considered the physician’s responsibility. Multiple state courts have reached the same conclusion. Courts feel that “to impose a duty to warn on the pharmacist would be to place the pharmacist in the middle of the doctor-patient relationship, without the physician’s knowledge of the patient.”⁶

The emergency physician erroneously may think that the pharmacist will tell the patient what side effects to watch for, and put labels on the bottles. Although this may happen, the courts do not feel this is the pharmacist’s duty or obligation.⁸

In a second case, a 52-year-old woman came to the ED with chronic migraines and was given nalbuphine (Nubain) and promethazine (Phenergen) in dosages that had been administered to the same patient 200 times before in the ED. No warning was given to the patient. One hour after discharge, she was involved in a single-car motor vehicle accident that left her a quadriplegic. The patient recovered \$1.3 million, despite the fact that she appeared alert at discharge.⁹

Not all states recognize the concept of the duty to warn or have variations of the doctrine. It behooves providers to either know their state's law or more simply warn in every situation and not fret over their particular state's statute. A list of state laws regarding the duty-to-warn mandate follows below.¹⁰

- States that mandate duty to warn: Arizona, California, Colorado, Connecticut, Delaware, Idaho, Illinois, Indiana, Iowa, Kentucky, Louisiana, Maryland, Massachusetts, Michigan, Minnesota, Missouri, Montana, Nebraska, New Hampshire, New Jersey, New York, Ohio, Pennsylvania, Tennessee, Utah, Vermont, Virginia, Washington, West Virginia, Wisconsin.
- States that are “permissive” (may report, not required): Alaska, Arkansas, District of Columbia, Florida, Hawaii, Kansas, Mississippi, New Mexico, Oklahoma, Oregon, Rhode Island, South Carolina, South Dakota, Texas, Wyoming.
- No duty to warn: Maine, Nevada, North Carolina, North Dakota.
- No state position: Georgia.

CONCLUSION

We have presented medical-legal cases that define a physician's duty to warn and include caveats on medical practice within the scope of the law. Some physicians may not recognize that these legal and liability requirements extend not only to physical danger but also to infectious diseases, medical illness, and drug effects.

Take-home Points

1. “Duty to warn” encompasses a broad area of responsibility for emergency physicians including not only physical harm but also harm from medications and infectious diseases.
2. The key legal concept is if the injured party is “foreseeable.” Foreseeability is subject to wide and uncertain interpretation by both juries and judges.
3. With regard to duty to warn on medications, the physician is obligated to warn of risks related to the drug; the pharmacist is tasked with safely dispensing the medication.
4. Not all state laws acknowledge the duty to warn, but it behooves physicians to comply and have less concern about possible liability.¹

The authors attest that their institution requires neither Institutional Review Board approval, nor patient consent for publication of this medical legal case report. Documentation on file.

Address for Correspondence: Gregory Moore, MD, JD, Mayo Clinic, Department of Emergency Medicine, 1507 Nisqually Street, Steilacoom, WA 98388. Email: gmoore4408@aol.com.

Conflicts of Interest: By the *CPC-EM* article submission agreement, all authors are required to disclose all affiliations, funding sources and financial or management relationships that could be perceived as potential sources of bias. The authors disclosed none.

Copyright: © 2020 Pfaff et al. This is an open access article distributed in accordance with the terms of the Creative Commons Attribution ([CC BY 4.0](http://creativecommons.org/licenses/by/4.0/)) License. See: <http://creativecommons.org/licenses/by/4.0/>

REFERENCES

1. Anonymous v Anonymous (North Carolina). *Risk Management Monthly in Emergency Medicine*. 2018;12(11):4.
2. Washington v Pediatric Cool Care. Ginger Washington and Brad Washington for Avery Washington v Pediatric Cool Care et al. Ellis County (Tx) District Court No.88970.
3. Danita Dawn Kochick, Administratrix of the Estates of Carl T. Sumler, Brenda J. Sumler, and Danny C. Sumler, v. Sheryl W. HANNA, Craig Beaty Moore, MD, and Nabila Hassan Elzind, MD, United States District Court, W.D. Oklahoma No. CIV-08-882-M. April 29, 2010.
4. Tarasoff v. Regents of the University of California, 17 Cal. 3d 425, 551 P.2d 334, 131 Cal. Rptr. 14 (Cal. 1976).
5. Volk v. Demeerleer, 386 P.3d 254 (Wash. 2016).
6. Ellen M and Bublick A. (2013). Concise Restatement of Torts 62, 3rd ed. Philadelphia, PA: The American Law Institute.
7. Bradshaw v. Daniel Supreme Court of Tennessee June 1, 1993 854 S.W.2d 865 (Tenn. 1993).
8. Moore JJ and Matlock AG. Shared liability? Consultants, pharmacists, and the emergency physician: legal cases and caveats. *J Emerg Med*. 2014;46(5):612-6.
9. West v Columbia Med. Center (Texas 5th Circuit Court No. cv00594 1997).
10. National Conference of State Legislatures. Mental Health Professionals' Duty to Warn. Available at: <https://www.ncsl.org/research/health/mental-health-professionals-duty-to-warn.aspx>. Accessed February 28, 2020.

Using Lung Point-of-care Ultrasound in Suspected COVID-19: Case Series and Proposed Triage Algorithm

Nicole M. Duggan, MD*

Andrew S. Liteplo, MD*

Hamid Shokoohi, MD, MPH*

Andrew J. Goldsmith, MD, MBA†

*Massachusetts General Hospital, Division of Ultrasound in Emergency Medicine, Department of Emergency Medicine, Boston, Massachusetts

†Brigham and Women's Hospital, Division of Emergency Ultrasound, Department of Emergency Medicine, Boston, Massachusetts

Section Editor: Rick A. McPheeters, DO

Submission history: Submitted April 27, 2020; Revision received June 22, 2020; Accepted July 3, 2020.

Electronically published July 16, 2020

Full text available through open access at http://escholarship.org/uc/uciem_cpchem

DOI: 10.5811/cpchem.2020.7.47912

Introduction: First detected in December 2019, the severe acute respiratory syndrome coronavirus 2 pandemic upended the global community in a few short months. Diagnostic testing is currently limited in availability, accuracy, and efficiency. Imaging modalities such as chest radiograph (CXR), computed tomography, and lung ultrasound each demonstrate characteristic findings of coronavirus disease 2019 (COVID-19). Lung ultrasound offers benefits over other imaging modalities including portability, cost, reduced exposure of healthcare workers as well as decreased contamination of equipment such as computed tomography scanners.

Case Series: Here we present a case series describing consistent lung ultrasound findings in patients with confirmed COVID-19 despite variable clinical presentations and CXR findings. We discuss a triage algorithm for clinical applicability and utility of lung point-of-care ultrasound in the setting of COVID-19 and advocate for judicious and targeted use of this tool.

Conclusion: Lung point-of-care ultrasound can provide valuable data supporting diagnostic and triage decisions surrounding suspected cases of COVID-19. Prospective studies validating our proposed triage algorithm are warranted. [Clin Pract Cases Emerg Med. 2020;4(3):289–294.]

Keywords: lung; ultrasound; POCUS; COVID-19; SARS-CoV-2; coronavirus.

INTRODUCTION

Coronavirus disease 2019 (COVID-19), the illness caused by severe acute respiratory syndrome coronavirus 2 (SARS-CoV-2) infection, ranges in presentation from mild cold-like symptoms to hypoxemic respiratory failure.^{1,2} As of late-June 2020, there are nearly nine million confirmed cases, and more than 400,000 deaths worldwide attributable to COVID-19.³ SARS-CoV-2 infection is confirmed by reverse-transcriptase polymerase chain reaction (RT-PCR). This presents challenges for physicians as testing availability is often limited and results delayed. RT-PCR demonstrates imperfect sensitivity, often requiring multiple tests to confirm a patient's status.⁴ Additionally RT-PCR cannot predict clinical course or outcomes. Emergency department (ED) physicians caring for patients with suspected COVID-19 often must make quick and consequential clinical

decisions. Data that can be rapidly gathered in real-time to support or refute this diagnosis is invaluable.

Characteristic chest computed tomography (CT) and radiograph (CXR) findings are described in COVID-19 particularly in peripheral and posterior lung distributions.⁵⁻⁷ While the sensitivity of CT for COVID-19 ranges between 86-97%, CXR sensitivity is as low as 59%.^{5,8} As a result, CT is proposed as a screening tool for COVID-19 when confirmatory tests are lacking.⁴ CT scans have high accuracy in detecting the presence and severity of lung involvement but logistical challenges such as exposing additional healthcare workers, patients, and the CT scanner itself to the virus limit its utility.

Lung point-of-care ultrasound (POCUS) is crucial for assessing patients with dyspnea in the ED.⁹⁻¹² Lung POCUS has higher sensitivity than CXR for detecting viral and bacterial

pneumonia.¹⁰⁻¹³ In limited reports on the use of lung POCUS in COVID-19, findings appear similar to features typically seen in viral and bacterial pneumonia or interstitial syndrome.¹⁴⁻¹⁶ Here we present a series of cases of lung POCUS findings in patients with confirmed COVID-19. Given our experience, we propose a five-tier model for responsible and clinically applicable use of lung POCUS in patients with suspected COVID-19.

CASE SERIES

Case 1

A 93-year-old female with a history of atrial fibrillation and congestive heart failure presented from a nursing facility with three days of cough and fevers in acute respiratory distress. On arrival to the ED, her oxygen saturation was 93% on a non-rebreather mask at 15 liters per minute. She was tachypneic with respiratory rates in the mid-30s, tachycardic to 130 beats per minute, and febrile to 102° Fahrenheit. A CXR was performed that was read as negative (Image 1A). A lung POCUS was performed and showed posterior subpleural consolidations (Image 1B) and diffuse B-lines bilaterally (Image 1C). After a conversation with the family about a presumed diagnosis of COVID-19, the patient was confirmed to be do not resuscitate/do not intubate and admitted to the medicine floor on supplemental oxygen. An RT-PCR for SARS-CoV-2 resulted positive the next day.

Case 2

A 66-year-old female with a history of hypertension presented with several weeks of fatigue, fevers, and shortness of breath. On arrival to the ED, she was tachypneic with a respiratory rate in the mid-30s, and an oxygen saturation of 90% on 2 liters of oxygen by nasal cannula. Her vital signs and physical exam were otherwise unremarkable. CXR revealed bilateral diffuse patchy opacities distributed peripherally (Image 2A). A lung POCUS was notable for diffuse bilateral confluent B-lines anteriorly (Image 2B) and an irregular pleural line posteriorly with multiple consolidations (Image 2C). Despite

maintaining oxygen saturations between 90-95% on supplemental oxygen, after discussion with the patient and family, the decision was made to pursue early intubation and admission to the intensive care unit (ICU) given her remarkable lung POCUS and expected clinical course. Definitive testing for SARS-CoV-2

CPC-EM Capsule

What do we already know about this clinical entity?

Coronavirus disease 2019 (COVID-19) has variable presentation and progression. Appropriate triage of these patients is key to minimizing morbidity and mortality.

What makes this presentation of disease reportable?

In each presented case, data provided by point-of-care ultrasound (POCUS) was used to guide clinical care and triage decisions in patients with suspected COVID-19.

What is the major learning point?

COVID-19 demonstrates characteristic lung POCUS findings including an irregular pleural line, B-lines, and subpleural consolidations.

How might this improve emergency medicine practice?

Lung POCUS may be used as an inexpensive and accessible tool for diagnosis and triage in patients with suspected COVID-19 in various settings.

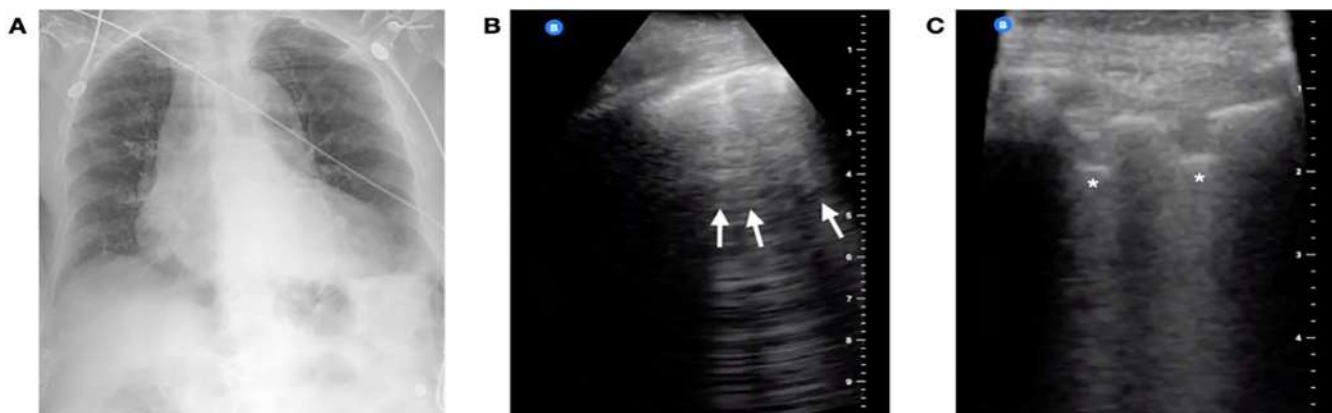

Image 1. Case 1 imaging findings: (A) Anterior-posterior chest radiograph was read as negative, (B) Lung point-of-care ultrasound revealed B-lines anteriorly (arrows), (C) and an irregular pleural line with subpleural consolidations posteriorly (asterisks).

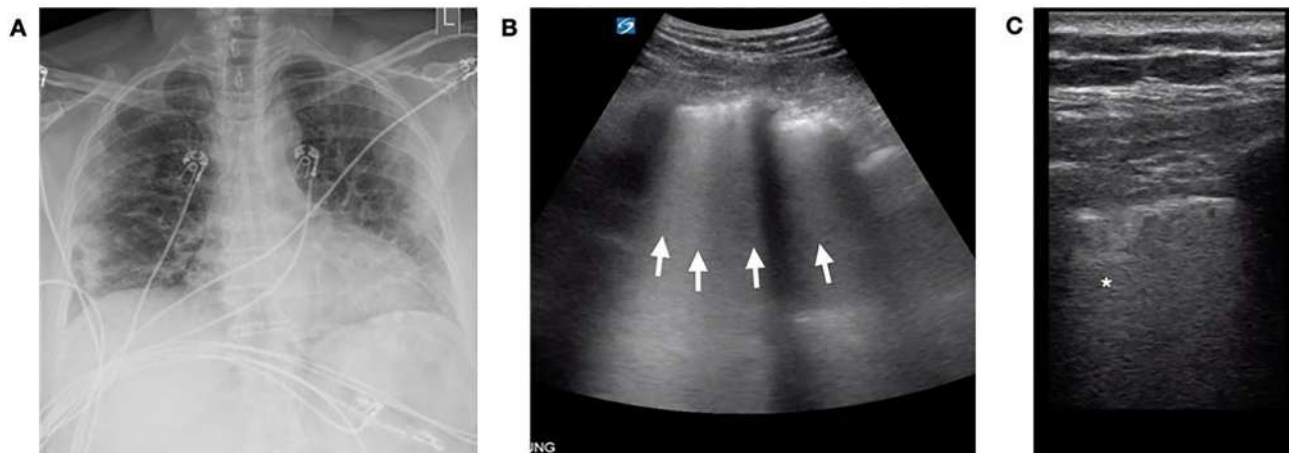


Image 2. Case 2 imaging findings: (A) Anterior-posterior chest radiograph notable for peripherally distributed bilateral patchy opacities. Lung point-of-care ultrasound was notable for diffuse B-lines coalescing to involve the entire rib space (arrows) laterally (B), while posterior views revealed irregular pleural lines and subpleural consolidations (asterisk, C).

in the form of RT-PCR resulted in positive days later. She was successfully extubated on hospital day ten and later transferred to the medical floor in stable condition.

Case 3

A 56-year-old female with a history of fibromyalgia, hyperlipidemia, depression, and travel to New York City ten days earlier presented with respiratory distress after one week of progressive fevers, chills, and a dry cough. She presented to urgent care five days prior where vital signs and a CXR at that time were normal. She was sent home with an albuterol inhaler, steroid taper, and instructions to socially isolate. In the ED, she was hypoxic to 70% on room air, which improved to 90-94% on a non-rebreather mask at 15 liters per minute. A CXR showed bilateral diffuse interstitial opacities (Image 3A). A lung POCUS revealed bilateral confluent B-lines, an irregular pleural line, and consolidations in the posterior and lateral fields (Image 3B and 3C). She was emergently intubated for hypoxemic respiratory failure and admitted to the ICU. Definitive testing for SARS-CoV-2 resulted positive the following day. Despite refractory hypoxemia, she was successfully extubated on hospital day sixteen, and was eventually transferred to a rehabilitation facility.

DISCUSSION

Here, we describe a case series of SARS-CoV-2-positive patients with variable clinical presentations. We present lung POCUS findings seen in COVID-19, notably B-lines, an irregular pleural line, and subpleural consolidations (Table). Representative clips of these findings are seen in Videos 1 and 2. Given our experience, we propose a five-tier model to guide decision-making for integrating lung POCUS in assessing patients with suspected COVID-19 (Figure 4).

In case one, lung ultrasound aided in the diagnosis of COVID-19. While COVID-19 was suspected from clinical history, CXR was not consistent with clinical findings, and

confirmatory RT-PCR result was not immediately available. As is common in these cases, further studies were needed to support the diagnosis and direct clinical care. Lung POCUS confirmed that a bacterial and/or viral pneumonia was most likely and provided physicians with actionable information in a rapid and non-invasive manner.

In areas with high disease prevalence, lung POCUS consistent with bilateral viral or bacterial pneumonia is highly suggestive of COVID-19. In these cases, lung POCUS can serve as a screening tool for suspected viral infection and may obviate the need for CT. This is particularly important in resource-limited settings where CXR, CT, or RT-PCR may not be readily available. CT is more sensitive than CXR for findings of COVID-19, thus it too is suggested as a screening tool. Routine use of CT scan presents challenges beyond limited availability, however. Safely moving a patient with cardiopulmonary instability to the CT scanner is not always feasible and often requires multiple healthcare workers. From an infection control standpoint, exposing additional healthcare workers and the CT scanner to coronavirus increases the risk of disease spread. In our cases, physicians were able to forgo CT scans, thus avoiding unnecessary viral exposure to additional staff, patients, and equipment.

Screening via lung POCUS could occur in many settings, including triage tents, EDs, and under-resourced environments with limited access to other diagnostic studies. It is likely that in many areas, globally, nasal swabs or serologic testing are not available, whereas ultrasounds may be. Given that only a power source is needed to operate, ultrasound machines could have a prominent role in screening for COVID-19 in these settings.

In case two, lung POCUS helped guide decision-making surrounding early intubation and ICU admission (i.e., tier four in Figure). Often the disposition of ED patients can be made on clinical grounds alone. At times, however, imaging can help guide these decisions. When POCUS findings are more prominent than CXR findings, a worse clinical disease could be

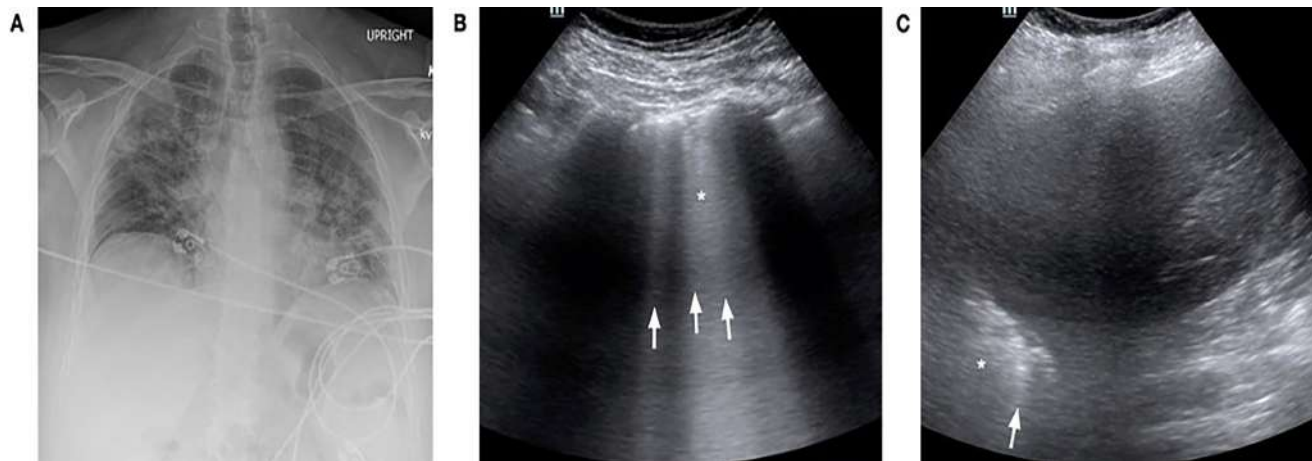


Image 3. Case 3 imaging findings: (A) Anterior-posterior chest radiograph at the time of presentation to the emergency department demonstrating diffuse peripherally-based bilateral patchy opacities. Lung point-of-care ultrasound in the emergency department was remarkable for confluent B-lines posterior (B, arrows), as well as an irregular pleural line with subpleural consolidations (asterisk). A lateral view (C) in the mid-anterior axillary line showed similar B-lines (arrow) and an irregular pleural line (asterisk).

suspected and upgrades in the level of care initiated. In this case, the patient clearly required admission, but the extent of disease and need for interventions such as intubation were uncertain from exam and CXR alone. Our POCUS and the patient's borderline respiratory status triggered a meaningful discussion with the patient regarding her expected clinical course. She confirmed her preference for early intubation, and the procedure was performed in a controlled setting. Here, lung POCUS dictated our decision to upgrade the patient's clinical care.

Similarly, patients being considered for admission could also benefit from lung POCUS (i.e., tier two in Figure). As in case one, since ultrasound is more sensitive than CXR for early pulmonary disease, lung POCUS may reveal findings consistent with COVID-19 when CXR remains negative. For patients who have borderline dispositions, lung POCUS can help lower the threshold for admission. Conversely, if both CXR and ultrasound are negative, providers may feel more comfortable discharging patients home with follow up. Lung POCUS has the potential for high clinical utility in these cases, and the benefits of use likely outweigh risks.

In case three, though ultrasound findings were prominent, they did not affect the patient's clinical course. In cases where disposition and management are clear, ultrasound may not be necessary (i.e., tier five in Figure), and its use should be carefully considered. As lung POCUS did not change our management, it was likely not worth the additional exposure risk to physicians. Similarly, on the opposite end of the spectrum, lung POCUS may also not be indicated in patients with suspected COVID-19 who are well-appearing, have adequate oxygen saturations, and are otherwise well enough for discharge (i.e., tier one in Figure). Lung POCUS may not contribute to the medical decision-making in these cases, and thus risks of increased viral exposure from performing POCUS likely outweigh the benefits of performing ultrasonography.

In patients who require admission but are stable for the medical floor, ultrasound may also not be indicated (i.e., tier three in Figure). In these patients CXR is likely positive, and clinical symptoms such as dyspnea, tachypnea, or hypoxia support admission. While lung POCUS can always be used to assess for alternative causes of dyspnea, in patients with a clinical history and workup consistent with COVID-19, lung ultrasound likely has limited clinical benefit. Judicious use of lung POCUS is advised in these patients, given the likely limited clinical utility compared to the risks of increased exposure.

LIMITATIONS

While lung POCUS may provide rapid and actionable clinical data for patients with suspected COVID-19, this imaging modality also has limitations. Though often more sensitive than CXR, lung POCUS findings described here are not specific to COVID-19. These findings are seen in a range of alveolar-interstitial syndromes, thus are not definitively diagnostic of SARS-CoV-2 infection. For cases of suspected COVID-19,

Table. Summary comparison of findings in chest radiograph and lung point-of-care ultrasound (POCUS) in coronavirus disease 2019.

Chest radiograph	Lung POCUS
Patchy ground glass opacities	Irregular pleural line
Unable to assess peri-pleural edema	Peri-pleural edema
Dense consolidations with increasing severity of disease	Sub-pleural consolidations
Minimal to no findings possible	Diffuse B-lines
Pleural effusions rare	Minimal to absent pleural effusions
Peripheral and basal findings predominant	Posterior and basal findings predominant

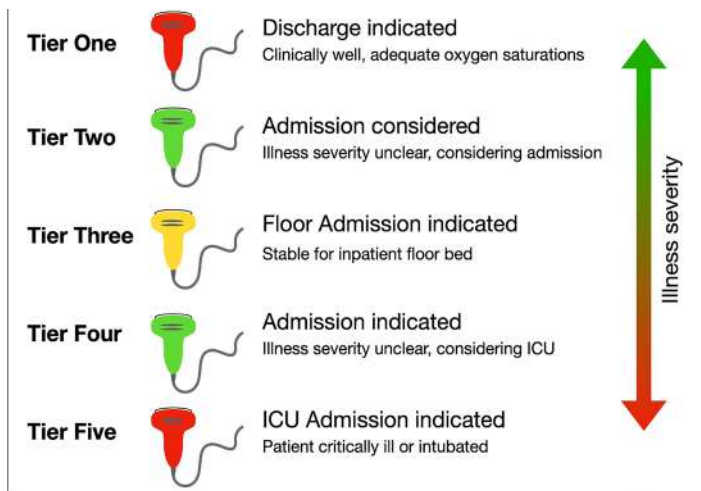


Figure. Proposed triage model of lung point-of-care ultrasound (POCUS) indications when evaluating patients with suspected coronavirus disease 2019. In tier one, patients for whom discharge is indicated, lung POCUS likely does not contribute to clinical decision making thus has limited utility (indicated by the red probe). In tier two, for patients who do not clearly meet admission criteria, lung POCUS may reveal increased severity of disease and indicate the need for admission. Thus, has high utility potential (indicated by the green probe). For patients who meet admission criteria but are stable for the medical floor, lung POCUS may contribute to clinical decision making and should be used at the discretion of the emergency department provider (i.e., tier three, indeterminate clinical utility indicated by the yellow probe). For patients who should be admitted but may require advanced interventions such as intubation or intensive care unit (ICU) admission, lung POCUS likely could help guide clinical decision-making (i.e., tier four). In patients who are critically ill and immediately warrant ICU admission, lung POCUS will rarely change the clinical course and is often not indicated (i.e., tier five).

our experience and the experience of others suggest lung POCUS may have higher utility than CXR for detecting early disease, though little is known regarding POCUS prognostic capabilities.^{14,15} As suggested by others, combining lung POCUS with additional clinical data such as vital signs and serum laboratory results may likely provide the highest clinical utility.¹⁷⁻¹⁹ Further studies focused on diagnostic and prognostic capabilities of lung POCUS in COVID-19 are needed.

An exception to consider in our model is that for any patient, POCUS can be used to identify alternative causes of respiratory distress.²⁰ In areas of high disease prevalence for COVID-19, our model can be used to dictate the safe and effective use of lung POCUS in patients under investigation of SARS-CoV-2 infection. For patients with comorbidities or clinical pictures inconsistent with COVID-19; however, cardiac and pulmonary POCUS should be considered to assess for alternative diagnoses. In the era of COVID-19, the risk/benefit ratio of performing POCUS must be carefully considered for each case. Given these limitations, prospective studies assessing our proposed triage algorithm are needed to further assess its utility in clinically undifferentiated patients in a variety of healthcare settings.

Currently, supportive care is the mainstay treatment for COVID-19. As further research identifies targeted treatment algorithms, earlier and more rapid diagnosis may have management implications. In the future, lung POCUS screening may play a role in cases requiring earlier diagnoses, and its utility in assessing patients with suspected COVID-19 should be continuously re-evaluated as this pandemic evolves.

CONCLUSION

The now-ubiquitous nature of COVID-19 demands a more rapid, safe, and accurate clinical evaluation than CXR, CT, or RT-PCR can currently provide. Lung POCUS offers valuable clinical data to first-line responders when assessing patients with suspected COVID-19. Given risks of exposure to providers and possible device contamination, POCUS is no longer considered risk-free. Though valuable, this tool should be used judiciously and reserved for cases in which it may alter patients' clinical course. Providers must be thoughtful about the cases in which we pursue POCUS and ensure our efforts will confer the highest clinical benefit while minimizing risk overall.

Video 1. Ultrasound clip demonstrating coalescent and individual B-lines in a patient with coronavirus disease 2019. This image was obtained using a curvilinear transducer positioned at the anterior chest wall.

Video 2. Ultrasound clip demonstrating an irregular pleural line and subpleural consolidations in a patient with coronavirus disease 2019. This image was obtained using a linear transducer positioned at the posterior thoracic wall.

The authors attest that their institution requires neither Institutional Review Board approval, nor patient consent for publication of this case series. Documentation on file.

Address for Correspondence: Nicole M. Duggan, MD, Massachusetts General Hospital, Department of Emergency Medicine, Division of Ultrasound in Emergency Medicine, 5 Emerson Place, Suite 101, Boston, MA 02114. Email: nmduggan@partners.org.

Conflicts of Interest: By the CPC-EM article submission agreement, all authors are required to disclose all affiliations, funding sources and financial or management relationships that could be perceived as potential sources of bias. The authors disclosed none.

Copyright: © 2020 Duggan et al. This is an open access article distributed in accordance with the terms of the Creative Commons Attribution (CC BY 4.0) License. See: <http://creativecommons.org/licenses/by/4.0/>

REFERENCES

1. Xu Z, Shi L, Wang Y, et al. Pathological findings of COVID-19 associated with acute respiratory distress syndrome. *Lancet Respir Med.* 2020;8(4):420-2.
2. Chan JF, Yuan S, Kok KH, et al. A familiar cluster of pneumonia associated with the 2019 novel coronavirus indicating person-to-person transmission: a study of a family cluster. *Lancet.* 2020;395(10223):514-23.
3. Johns Hopkins Coronavirus Resource Center. Home. 2020. Available at: <https://coronavirus.jhu.edu/map.html>. Accessed April 18, 2020.
4. Ai T, Yang Z, Hou H, et al. [Ahead of Print]. Correlation of Chest CT and RT-PCR Testing in Coronavirus Disease 2019 (COVID-19) in China: A Report of 1014 Cases. *Radiology.* February 26, 2020.
5. Shi H, Han X, Jiang N, et al. Radiological findings from 81 patients with COVID-19 pneumonia in Wuhan, China: a descriptive study. *Lancet Infect Dis.* 2020;20(4):425-34.
6. Bernheim A, Mei X, Huang M, et al. Chest CT Findings in Coronavirus Disease-19 (COVID-19): Relationship to Duration of Infection. *Radiology.* 2020;295(3):200463.
7. Zhou S, Wang Y, Zhu T, et al. CT Features of Coronavirus Disease 2019 (COVID-19) Pneumonia in Wuhan, China. *AJR Am J Roentgenol.* 2020;214(6):1287-94.
8. Guan WJ, Ni ZY, Hu Y, et al. Clinical Characteristics of Coronavirus Disease 2019 in China. *N Engl J Med.* 2020;382:1708-20.
9. Lichtenstein DA. BLUE-protocol and FALLS-protocol: two applications of lung ultrasound in the critically ill. *Chest.* 2015;147(6):1659-70.
10. Buhmaid RE, Bourque JS, Shokoohi H, et al. Integrating Point-Of-Care Ultrasound in the ED Evaluation Of Patients Presenting With Chest Pain and Shortness Of Breath. *Am J Emerg Med.* 2019;37(2):298-303.
11. Cortellaro F, Colombo S, Coen D, et al. Lung Ultrasound Is an Accurate Diagnostic Tool for the Diagnosis Of Pneumonia in the Emergency Department. *Emerg Med J.* 2012;29(1):19-23.
12. Soldati G, Demi M, Smargiassi A, et al. The Role Of Ultrasound Lung Artifacts in the Diagnosis Of Respiratory Distress. *Expert Rev Respir Med.* 2019;13(2):163-72.
13. Iorio G, Capasso M, Prisco S, et al. Lung Ultrasound Findings Undetectable by Chest Radiography in Children With Community-Acquired Pneumonia. *Ultrasound Med Biol.* 2018;44(8):1687-93.
14. Huang Y, Wang S, Liu Y, et al. [Ahead of Print]. A preliminary study on the ultrasonic manifestations of peripulmonary lesions of non-critical novel coronavirus pneumonia (COVID-19). *Research Square.* February 26, 2020.
15. Peng QY, Wang XT, Zhang LN, et al. Findings of Lung Ultrasound of Novel Corona Virus Pneumonia During the 2019-2020 Epidemic. *Intensive Care Med.* 2020;46(5):849-50.
16. Soldati G, Smargiassi A, Inchingolo R, et al. Is There a Role For Lung Ultrasound During the COVID-19 Pandemic? *J Ultrasound Med.* 2020;39(7):1459-62.
17. Piliago C, Strumia A, Stone MB, et al. [Ahead of Print]. The Ultrasound Guided Triage: A New Tool for Prehospital Management of COVID-19 Pandemic. *Anest Analg.* April 27, 2020.
18. Volpicelli G and Gargani L. Sonographic Signs and Patterns of COVID-19 Pneumonia. *Ultrasound J.* 2020;12(1):22.
19. Soldati G, Smargiassi A, Inchingolo R, et al. Proposal for International Standardization of the Use of Lung Ultrasound for Patients With COVID-19; A Simple, Quantitative, Reproducible Method. *J Ultrasound Med.* 2020;39(7):1413-9.
20. Lichtenstein DA and Meziere GA. Relevance of Lung Ultrasound in the Diagnosis of Acute Respiratory Failure. *Chest.* 2008;134(1):117-25.

Patients with Mild COVID-19 Symptoms and Coincident Pulmonary Embolism: A Case Series

Joshua W. Joseph, MD, MS, MBE*
Jonathan C. Roberts, MD†
Cheri N. Weaver, MD†
Jonathan S. Anderson, MD†
Matthew L. Wong, MD, MPH*

*Beth Israel Deaconess Medical Center, Department of Emergency Medicine, Boston, Massachusetts

†Beth Israel Lahey - Milton Hospital, Department of Emergency Medicine, Milton, Massachusetts

Section Editor: Rick A. McPheeters, DO

Submission history: Submitted May 16, 2020; Revision received June 25, 2020; Accepted July 9, 2020

Electronically published July 20, 2020

Full text available through open access at http://escholarship.org/uc/uciem_cpccem

DOI: 10.5811/cpcem.2020.7.48254

Introduction: Frequent thrombotic complications have been reported in patients with severe coronavirus disease 2019 (COVID-19) infection. The risk in patients with mild disease is unknown.

Case Report: We report a case series of three individuals recently diagnosed with COVID-19, who presented to the emergency department with chest pain and were found to have pulmonary emboli. The patients had mild symptoms, no vital sign abnormalities, and were negative according to the pulmonary embolism rule-out criteria.

Conclusion: This suggests that patients with active or suspected COVID-19 should be considered at elevated risk for pulmonary embolism when presenting with chest pain, even without common risk factors for pulmonary embolism. [Clin Pract Cases Emerg Med. 2020;4(3):295–298.]

Keywords: *Coronavirus; pulmonary embolism; emergency medicine; coagulation.*

INTRODUCTION

Severe infection with coronavirus disease 2019 (COVID-19) has been associated with coagulopathy, with complications ranging from a high rate of pulmonary embolism (PE) in intubated patients, to an increased frequency of premature stroke in young patients. However, the prevalence of clinically significant thrombotic complications in patients with milder symptoms is less clear, and the relative risk imparted by COVID-19 compared to other thrombotic risk factors is unknown. We report a case series of three young patients with confirmed COVID-19 and PE, who presented to the same small, suburban emergency department (ED) over a one-week period. The ED sees an average of 32,000 visits per year, and had approximately 200 confirmed cases of COVID-19 by the time of the last case. The patients had previously been diagnosed with COVID-19, and due to their relatively mild symptoms (including no exertional symptoms and no desaturation), they had been discharged home after

ED visits in the previous two weeks. None of the patients had pre-existing comorbidities for venous thromboembolism. We explore their presentations in detail, in order to alert clinicians to the heightened risk of PE in all patients with COVID-19, not only those with critical presentations.

CASE SERIES

Case 1

Patient 1 was a 40-year-old man who presented to the ED with mild left-sided chest pain. He had been seen nine days earlier due to fever and cough, and was diagnosed with COVID-19. However, during that visit, he had no shortness of breath, no significant decrease in oxygenation while ambulating, a normal sinus rhythm electrocardiogram (ECG) with no significant ST-segment changes, and was discharged home on precautions. Since his prior visit, he reported no immobility or significant change in daily activities, and he had no significant past medical history and took no medications.

Repeat EKG demonstrated no ST-segment changes. The emergency physician caring for the patient was concerned that COVID-19 could be a risk factor for PE, and ordered a D-dimer, which was elevated at 4489 nanograms per milliliter (ng/mL) (reference range 0-499 ng/mL). Troponin and brain natriuretic peptide (BNP) levels were normal. A computed tomography angiogram (CTA) demonstrated bilateral pulmonary emboli and bilateral lower lobe ground-glass opacities consistent with COVID-19 pneumonia. He was discharged on a course of rivaroxaban.

Case 2

Patient 2 was a 48-year-old man who presented with right-sided chest pain, which was sharp in character and pleuritic. He reported no accompanying dyspnea or worsening of the pain with exertion. His ECG demonstrated normal sinus rhythm without significant ST-segment changes. He reported a past medical history of gout, but was on neither prophylactic treatment nor active treatment for a flare in the months prior to presentation. He had been seen 14 days prior, during which he had presented with similar symptoms, but also with an accompanying fever and dyspnea. During that visit, he underwent a CTA which showed multifocal ground-glass infiltrates, consistent with COVID-19 infection, and was discharged home on isolation precautions.

During his return visit, he underwent D-dimer testing, which was elevated at 2183 ng/mL (reference range 0-499 ng/mL). A CTA demonstrated a right upper segmental PE, multiple subsegmental pulmonary emboli, and progression in the size of ground-glass infiltrates (which were not associated with vascular filling defects). He was briefly admitted to the medical service, and discharged after a two-day admission on a course of apixaban.

Case 3

Patient 3 was a 47-year-old woman who presented with left-sided chest pain, which was pressure-like in character and non-pleuritic. She noted some worsening of her symptoms with exertion, but the pain was also present at rest. Her ECG showed sinus rhythm without significant ST-segment changes, and an initial troponin was negative (<0.01 ng/mL). She had been seen nine days previously, with cough and dyspnea, and had undergone an evaluation including ECG and chest radiograph, and discharged home on precautions with a presumptive diagnosis of COVID-19. This was confirmed on outpatient testing two days later.

Relative to her initial presentation, she reported that the chest pain she was experiencing was new, but the sensation of dyspnea and the frequency of her cough had lessened significantly. She reported no significant change in activity while at home, and reported no hormone use or other risk factors for PE. A D-dimer was drawn and elevated at 5821 ng/mL (ref: 0-499 ng/mL). CTA was performed and demonstrated emboli throughout the right upper segmental branch and bilateral lower lobe segmental and

CPC-EM Capsule

What do we already know about this clinical entity?

Coronavirus Disease 2019 (COVID-19) has been associated with coagulopathy in severe cases, leading to high rates of pulmonary embolism among hospitalized patients.

What makes this presentation of disease reportable?

We report several patients with COVID-19 who developed significant pulmonary emboli, despite having mild symptoms of both COVID-19 infection and pulmonary embolism.

What is the major learning point?

These cases suggest that COVID-19 should be treated as an independent risk factor for pulmonary embolism.

How might this improve emergency medicine practice?

Clinicians should have a high index of suspicion for pulmonary embolism in patients with COVID-19 infection who present with chest pain.

subsegmental branches. Due to her clot burden, she was admitted to the medical service and started on apixaban. An inpatient echocardiogram demonstrated no evidence to suggest cor pulmonale, and she was discharged after two days.

DISCUSSION

Critically ill patients with COVID-19 and acute respiratory distress syndrome have been observed to have a high frequency of PE, as well as diffuse intravascular coagulation.¹⁻³ Several mechanisms have been proposed for these findings, including inflammatory cytokine production, vascular endothelial disruption within the lungs, and hyaline microemboli formation, which may be complementary factors. This multifactorial coagulopathy likely has an additive effect to existing risk factors for PE in the critically ill, which include immobility, invasive procedures, respiratory failure, and mechanical ventilation.⁴⁻⁵ Accordingly, some authors have proposed using markers of coagulation, such as D-dimer, platelet count, and partial thromboplastin time as markers of disease severity.⁶⁻⁸

Extrapulmonary vascular complications of COVID-19 have also been reported, including large-vessel strokes in young patients, and portal venous and mesenteric arterial thrombosis.⁹⁻¹⁰ However, these thrombotic complications have

not clearly correlated with the severity of patients' respiratory or systemic COVID-19-related symptoms. Troublingly, in the case series of large-vessel stroke reported by Oxley et al, two of the five patients reported no antecedent respiratory or systemic symptoms to suggest COVID-19 infection.⁹

The patients in our case series are notable because despite having pulmonary emboli, their symptoms of both COVID-19 and PE were relatively mild, and none reported periods of immobility or other clear antecedent risk factors. This is particularly concerning in light of the fact that these patients were initially judged to have a low risk of PE via the pulmonary embolism rule-out criteria (PERC) [Table]. The PERC rule, introduced by Kline et al, is a well-validated decision tool for screening patients at low risk for PE, with the goal of reducing unnecessary CT imaging by avoiding the D-dimer test and its high rate of false positives.¹¹ The rate of PE among patients who are very low risk per the PERC rule is estimated to be less than 2%; thus, many clinicians use the rule in lieu of D-dimer screening for low-risk patients. Its use is widespread throughout emergency medicine.¹²

While our findings represent a relatively small case series, when viewed in the larger context of coagulopathy seen in patients with COVID-19, they suggest that clinicians may need to view a diagnosis or presumed diagnosis of COVID-19 as an independent risk factor for PE, for which the PERC rule cannot be used in lieu of D-dimer testing. More research is needed to examine the ultimate validity of the PERC rule in this population. Considerable debate exists over the use of prophylactic anticoagulant use in patients with COVID-19, with recommendations depending on the degree of associated coagulopathy and inpatient status.¹³⁻¹⁵ However, we do not believe that there are data to support such a recommendation for outpatients without either clear evidence of thrombosis or until we have a better understanding of the true prevalence of thrombosis in COVID-19.

CONCLUSION

Our case series demonstrates a concerning frequency of pulmonary embolism in otherwise healthy patients presenting with mild symptoms of COVID-19 and chest

Table. Clinical characteristics of three patients presenting with COVID-19 and coincident pulmonary embolism.

Patient	1	3	4
Age	40	48	47
Sex	Male	Male	Female
Chief complaint	Chest pain	Chest pain	Chest pain
Medical history	None	Gout	Hypertension, Migraine, Anxiety
Risk factors for pulmonary embolism	None	None	None
Medications	None	Colchicine (episodic, not at time of diagnosis)	Amitriptyline, amlodipine, hydrochlorothiazide, lisinopril
Initial visit signs and symptoms of COVID-19	Cough, fever	Dyspnea, fever	Dyspnea
ECG (rhythm)	Sinus	Sinus	Sinus
ECG (ST-segment changes)	T-wave flattening (nonspecific)	None	None
Signs and symptoms of pulmonary embolism	Chest pain	Chest pain	Chest pain
Negative by PERC Criteria	Yes	Yes	Yes
WBC (4.0 – 11.0 k/ μ L)	6.0 k/ μ L	11.1 k/ μ L	10.7 k/ μ L
Troponin (<0.01 ng/mL)	<0.01 ng/mL	<0.01 ng/mL	<0.01 ng/mL
D-dimer (0-499 ng/mL)	4489 ng/mL	2183 ng/mL	5821 ng/mL
BNP (0-125 pg/mL)	<5.0 pg/mL	Not measured	48.8 pg/mL
Location of clot	Right upper, right middle and bilateral lower lobe lobar pulmonary arteries	Proximal right upper lobe segmental pulmonary artery, subsegmental right upper lobe pulmonary arteries	Right upper lobe and bilateral lower lobe segmental and subsegmental branches
Disposition and outcome	Discharged from ED on rivaroxaban	Admitted for two days, discharged on apixiban	Admitted for two days, discharged on apixiban

ECG, electrocardiogram; PERC, Pulmonary Embolism Rule-out Criteria; WBC, white blood cell count; k, thousand; μ L, microliter; ng, nanogram; mL, milliliter; BNP, B-type natriuretic peptide; pg, picogram; ED, emergency department.

pain. More research is needed to determine whether specific subpopulations with COVID-19 are at increased risk of PE. However, clinicians may need to treat COVID-19 as an independent risk factor for PE in patients presenting with chest pain, and tailor their diagnostic heuristics accordingly, using a D-dimer and Wells' score rather than the PERC rule.

ACKNOWLEDGMENTS

The authors would like to dedicate this case series in the memory of their colleague Dr. John Mahoney.

The authors attest that their institution requires neither Institutional Review Board approval, nor patient consent for publication of this case series. Documentation on file

Address for Correspondence: Joshua W. Joseph, MD, MS, MBE, Beth Israel Deaconess Medical Center, Department of Emergency Medicine, 330 Brookline Avenue, Boston, MA 02215. Email: jwjoseph@bidmc.harvard.edu.

Conflicts of Interest: By the *CPC-EM* article submission agreement, all authors are required to disclose all affiliations, funding sources and financial or management relationships that could be perceived as potential sources of bias. The authors disclosed none.

Copyright: © 2020 Joseph et al. This is an open access article distributed in accordance with the terms of the Creative Commons Attribution ([CC BY 4.0](http://creativecommons.org/licenses/by/4.0/)) License. See: <http://creativecommons.org/licenses/by/4.0/>

REFERENCES

1. Klok FA, Kruij MJHA, Van der Meer NJM, et al. Incidence of thrombotic complications in critically ill ICU patients with COVID-19. *Thromb Res.* 2020;191:145-7.
2. Dolhnikoff M, Duarte-Neto AN, de Almeida Monteiro RA, et al. Pathological evidence of pulmonary thrombotic phenomena in severe COVID-19. *J Thromb Haemost.* 2020;18(6):1517-9.
3. Han H, Yang L, Liu R, et al. Prominent changes in blood coagulation of patients with SARS-CoV-2 infection. *Clin Chem Lab Med.* 2020;58(7):1116-20.
4. Minet C, Potton L, Bonadona A, et al. Venous thromboembolism in the ICU: main characteristics, diagnosis and thromboprophylaxis. *Crit Care.* 2015;19(1):287.
5. Shapira-Rootman M, Beckerman M, Soimu U, et al. The prevalence of pulmonary embolism among patients suffering from acute exacerbations of chronic obstructive pulmonary disease. *Emerg Radiol.* 2015;22(3):257-60.
6. Zhou F, Yu T, Du R, et al. Clinical course and risk factors for mortality of adult inpatients with COVID-19 in Wuhan, China: a retrospective cohort study. *Lancet.* 2020;395(10229):1054-62.
7. Thachil J, Tang N, Gando S, et al. ISTH interim guidance on recognition and management of coagulopathy in COVID-19. *J Thromb Haemost.* 2020;18(5):1023-6.
8. Lippi G, Plebani M, Henry BM. Thrombocytopenia is associated with severe coronavirus disease 2019 (COVID-19) infections: A meta-analysis. *Clin Chim Acta.* 2020;506:145-8.
9. Oxley TJ, Mocco J, Majidi S, et al. Large-vessel stroke as a presenting feature of COVID-19 in the young. *N Engl J Med.* 2020;382(20):e60.
10. a Beccara L, Pacioni C, Ponton S, et al. Arterial mesenteric thrombosis as a complication of SARS-CoV-2 infection. *Eur J Case Rep Intern Med.* 2020;7(5):001690.
11. Kline JA, Courtney DM, Kabrhel C, et al. Prospective multicenter evaluation of the pulmonary embolism rule-out criteria. *J Thromb Haemost.* 2008;6(5):772-80.
12. Singh B, Mommer SK, Erwin PJ, et al. Pulmonary embolism rule-out criteria (PERC) in pulmonary embolism—revisited: a systematic review and meta-analysis. *Emerg Med J.* 2013;30(9):701-6.
13. Kollias A, Kyriakoulis KG, Dimakakos E, et al. Thromboembolic risk and anticoagulant therapy in COVID-19 patients: emerging evidence and call for action. *Br J Haematol.* 2020;189(5):846-7.
14. Tang N, Bai H, Chen X, et al. Anticoagulant treatment is associated with decreased mortality in severe coronavirus disease 2019 patients with coagulopathy. *J Thromb Haemost.* 2020;18(5):1094-9.
15. Connors JM and Levy JH. COVID-19 and its implications for thrombosis and anticoagulation. *Blood.* 2020;135(23):2033-40.

COVID-19 and Pulmonary Emboli: A Case Series and Literature Review

James Greenan-Barrett, MBBS, MA
Adrian Perera, MRCEM, MBChB, MSc

Royal Free Hospital, Department of Emergency Medicine,
Hampstead, London, United Kingdom

Section Editor: Rick A. McPheeters, DO

Submission history: Submitted May 13, 2020; Revision received June 25, 2020; Accepted July 9, 2020

Electronically published July 16, 2020

Full text available through open access at http://escholarship.org/uc/uciem_cpchem

DOI: 10.5811/cpcem.2020.7.48174

Introduction: There is recent evidence that coronavirus disease 2019 (COVID-19) infection results in a prothrombotic state that may increase the risk of venous thromboembolism. Both COVID-19 infection and pulmonary emboli can present with dyspnoea, tachypnoea, hypoxaemia and an elevated D-dimer. Identifying a pulmonary embolus in a patient with COVID-19 and differentiating it from the typical clinical and biochemical features of COVID-19 is challenging.

Case Reports: We report four cases, and reviewed two further cases in the literature, of a pulmonary embolus in patients who presented to the emergency department with COVID-19 and no other risk factor for a pulmonary embolus.

Conclusion: We identified a series of atypical features that should raise suspicion for a pulmonary embolus: pleuritic chest pain; haemoptysis; atrial fibrillation; tachycardia; hypotension; late onset deterioration; evidence of right heart strain; or a disproportionately elevated D-dimer in comparison to ferritin. [Clin Pract Cases Emerg Med. 2020;4(3):299–303.]

Keywords: *Pulmonary embolus; COVID-19.*

INTRODUCTION

Coronavirus disease 2019 (COVID-19) is a novel disease that usually presents with mild symptoms; however, in 14% of patients it can result in a severe disease requiring hospitalisation.¹ The severe form of the disease is characterised by severe hypoxaemia that is predominantly thought to be secondary to acute respiratory distress syndrome (ARDS).² There have been a limited number of reports of pulmonary emboli in COVID-19 patients which may also contribute to hypoxaemia.³⁻⁶ However, the significant crossover between the presenting features of COVID-19 and pulmonary emboli makes differentiating this cohort challenging. We report four cases of COVID-19 complicated by a pulmonary embolus, and we analysed the literature to establish common “red flag” features that should raise clinical suspicion for a pulmonary embolus.

CASE SERIES

Case 1

A 72-year-old woman presented to the emergency department (ED) after she attended the hospital for a routine

ophthalmology appointment and felt dyspnoeic. She had experienced one week of lethargy, feeling generally unwell and loss of taste, and one day of dyspnoea, palpitations, and diarrhoea. She did not complain of fevers, cough, or chest pain. She was entirely independent and had a history of hypertension, seasonal asthma, and glaucoma. On assessment she was tachypnoeic (32 breaths per minute) with increased work of breathing and had oxygen saturations of 90% on 15 litres of oxygen via a non-rebreather mask. She was in atrial fibrillation with a rapid ventricular response (125-170 beats per minute) and was hypotensive (87/62 millimetres of mercury [mmHg]).

Venous and arterial blood samples were taken and sent for analysis (Table 1). A chest radiograph (CXR) showed widespread bilateral infiltrates suspicious for COVID-19. A computed tomography pulmonary angiogram (CTPA) demonstrated extensive bilateral pulmonary emboli with no evidence of right heart strain and extensive, patchy ground-glass changes in keeping with COVID-19. She was given intravenous (IV) fluids, magnesium sulphate and verapamil which reduced

her heart rate to 115 beats per minute, but she remained in atrial fibrillation and remained hypotensive (95/60 mmHg). She was chemically cardioverted with IV amiodarone although she remained hypotensive. She was given treatment dose tinzaparin before being switched to rivaroxaban. Her case was discussed with interventional radiology, cardiology, and intensive care regarding catheter-directed and systemic thrombolysis; a decision was made that thrombolysis was not appropriate due to the risk of pulmonary haemorrhage and that the persistent hypotension was likely related to verapamil therapy. A nasopharyngeal aspirate confirmed COVID-19 infection on reverse transcription-polymerase chain reaction (RT-PCR).

Case 2

A 62-year-old man was brought into the ED by ambulance with three days of worsening dyspnoea, reduced appetite, myalgia, intermittent diarrhoea, abdominal cramping and one episode of vomiting, but no chest pain. He had experienced a fever three weeks previously and tested positive for COVID-19 before self-isolating and completing a course of azithromycin. He was previously independent and his only medical history was hypertension and hypercholesterolaemia. On assessment in the ambulance he had oxygen saturations of 52% on room air which improved to 88% on 15 litres of oxygen via a non-rebreather mask. In the ED he was tachypnoeic (24 breaths per minute), with saturations of 97% on 15 litres of oxygen. He was tachycardic (113 breaths per minute), normotensive (100/72 mmHg), and an electrocardiogram (ECG) showed sinus tachycardia with no evidence of right heart strain.

A CXR showed extensive, bilateral peripheral patchy opacification suspicious for COVID-19. A CTPA demonstrated bilateral acute pulmonary emboli with no features of right heart strain and extensive peripheral ground-glass and peribular consolidation consistent with COVID-19. The patient was treated with treatment dose tinzaparin and high-flow oxygen. A nasopharyngeal aspirate confirmed COVID-19 infection RT-PCR.

Case 3

A 78-year-old man was brought into the ED by ambulance with four days of fever, dry cough, lethargy, myalgia, coryza, dyspnoea and one episode of haemoptysis, but no chest pain. He had a history of benign prostate hyperplasia and hypercholesterolaemia, but was otherwise active and independent. On assessment with the ambulance service he was in respiratory distress and had oxygen saturations of 60% on room air. On assessment in the ED he had oxygen saturations of 88% on 15 litres of oxygen via a non-rebreather mask and tachypnoeic (35 breaths per minute). He was normotensive (120/94 mmHg) but had cool peripheries with a peripheral capillary refill time of five seconds. An ECG showed he was in atrial fibrillation with a rapid ventricular response (140 beats per minute) with ST depression in lateral leads and no evidence of right heart strain.

CPC-EM Capsule

What do we already know about this clinical entity?

Coronavirus disease 2019 (COVID-19) infection can cause significant hypoxaemia that is predominantly thought to be secondary to acute respiratory distress syndrome.

What makes this presentation of disease reportable?

These patients with COVID-19 infection developed pulmonary emboli; these cases highlight atypical features that should raise suspicion for a pulmonary embolus.

What is the major learning point?

Emergency clinicians should consider a pulmonary embolus in patients with COVID-19 who present with atypical clinical and biochemical features.

How might this improve emergency medicine practice?

This may reduce the rate of undiagnosed pulmonary emboli that can be treated to improve outcomes in patients with COVID-19.

A CXR showed bilateral consolidation suspicious for COVID-19. A point-of-care echocardiogram showed reduced right ventricular free wall contractility. A CTPA showed multiple subsegmental pulmonary emboli throughout the right hemithorax and left lower lobe with evidence of right heart strain (right ventricle:left ventricle ratio >1:1) and extensive ground-glass changes. The patient was taken to the intensive care unit (ICU) due to progressive hypoxia where he was intubated and ventilated and treated with treatment dose tinzaparin. A nasopharyngeal aspirate confirmed COVID-19 infection RT-PCR.

Case 4

A 63-year-old man presented with two weeks of myalgia, fever and lethargy, and three days of haemoptysis and pleuritic chest pain. He was independent with no comorbidities. He had normal observations and a normal examination. An ECG showed new right bundle branch block. A CXR showed bilateral peripheral areas of consolidation suspicious for COVID-19. A CTPA demonstrated bilateral pulmonary emboli with complete occlusion to the left lower lobar artery, a right sided pulmonary infarct, right heart strain (right ventricle:left ventricle ratio of 1.4:1), and patchy ground-glass shadowing suggestive of COVID-19. He was treated with treatment dose tinzaparin.

Table 1. Laboratory features of cases 1-4 of COVID-19 patients presenting with an acute pulmonary embolus.

	Case 1	Case 2	Case 3	Case 4	Reference range
White cell count (10 ⁹ /L)	10.10	8.82	9.68	13.49	3.5-11
Lymphocyte count (10 ⁹ /L)	0.61	1.12	1.34	1.14	1-4
Neutrophil count (10 ⁹ /L)	9.03	6.97	7.51	13.49	2-7.5
Platelet count (10 ⁹ /L)	166	203	238	353	150-400
Prothrombin time (s)	11.1	13	11.9	11.4	10-13
Fibrinogen (g/L)	5.4	6.4	6.6	6.1	1.5-4.5
D-dimer (ng/mL)	9892	>80,000	23,068	11,448	<400
C-reactive protein (mg/L)	152	114	293	114	<5
Ferritin (ug/L)	1745	2197	1029	871	10-350
Troponin (ng/L)	27	25	65	15	<4
Alanine aminotransferase (u/L)	25	124	42	75	<42
N terminal probrain natriuretic peptide (ng/L)	229	N/A	1129	76	<300
Lactate (mmol/L)	1.67	2.11	6.85	1.45	<2
Partial pressure of oxygen (kPa) [mmHg] on 15 litres of oxygen	7.9 [60]	8.44 [63.3]	7.27 [54.5]	N/A	
Partial pressure of carbon dioxide (kPa) [mmHg] on 15 litres of oxygen	4.79 [35.9]	4.19 [31.425]	3.61 [27.1]	N/A	

COVID-19, coronavirus disease 2019; L, litre; g, gram; ng, nanogram; mg, milligram; ug, microgram; mmol, millimole; kPa, kilopascal; mmHG, millimetres mercury.

DISCUSSION

There has been one case report of a pulmonary embolus in a patient with COVID-19 who was identified after an echocardiogram demonstrated right heart strain (dilated + hypokinetic right ventricle with a raised pulmonary arterial pressure).³ Another case report documents a patient with chest pain, haemoptysis, and ECG evidence of right heart strain (S1Q3T3 pattern and right-axis deviation).⁴ Table 2 compares the clinical and biochemical features of the four patients that we report and the two further cases in the literature.

In the context of COVID-19, raising clinical suspicion for a pulmonary embolus and distinguishing it from the typical features of COVID-19 is difficult as 30% of inpatients with COVID-19 are dyspnoeic, 76% are hypoxaemic, and 29% are tachypnoeic (respiratory rate >24 breaths per minute).^{2,7} However, only 1-2% of inpatients with COVID-19 present with hypotension (systolic blood pressure <90 mmHg), tachycardia (heart rate >125 beats per minute), chest pain, or haemoptysis.⁸ Therefore, it is important to consider a pulmonary embolus in patients with COVID-19 who present with these atypical features. Additionally, there are no published cases of patients presenting with new-onset atrial fibrillation. Features of right heart strain on ECG and echocardiogram are also seen in pulmonary emboli, due to a rapid increase in pulmonary vascular resistance, and a pulmonary embolus should be excluded. The median time from illness onset to dyspnoea was eight days (interquartile range 5-13) and to admission to the ICU was 12 days (interquartile range 8-15). Any patients

with late onset dyspnoea should be assessed further for a pulmonary embolus.⁷

All four patients we reported had significantly elevated D-dimer values; however, as both a marker of thrombosis and acute inflammation, the diagnostic value of the D-dimer is poor. Ninety percent of inpatients with COVID-19 have an elevated D-dimer, although a value of >1000 nanograms per microlitre (ng/mL) (normal range <400 ng/mL) is an independent risk factor for death.⁷ In a study of 25 patients with COVID-19 who received a CTPA, the 10 patients who were diagnosed with acute pulmonary emboli had on average significantly higher D-dimer values than those who did not (11,070 v 2440 ng/mL).⁴ In another study, 25 out of 81 COVID-19 patients on the ICU had a lower limb deep vein thrombosis, and the strongest correlator was D-dimer; a value of >1500 ng/mL predicted a deep vein thrombosis with 85% sensitivity and 89% specificity.⁹ The patients we reported had significantly elevated D-dimer values of between 9892->80,000 ng/mL (normal range <400 ng/ml), equating to a 25-200 fold increase above the upper limit of normal.

Ferritin is another acute phase protein that is elevated in patients with COVID-19, with higher levels in non-survivors than with survivors but does not appear to be elevated as a result of venous thrombosis.⁷ The patients we reported had modestly elevated ferritin values of between 871-2197 micrograms per litre (ug/L) (normal range 10-350 ug/L), equating to a 2-6 fold increase above the upper limit of normal. Thus, we suggest that in a patient with COVID-19, a disproportionately elevated D-dimer

Table 2. Age, day of illness, suspicious clinical features, electrocardiogram findings, D-dimer value, ferritin value, and evidence of right heart strain in cases 1-4 and 2 cases in the literature.

	Case 1	Case 2	Case 3	Case 4	Danzi et al ²	Casey et al ³
Age	72	62	78	63	75	42
Day of illness	7	21	4	14	10	12
Suspicious clinical features	Hypotension Tachycardia	Tachycardia Delayed onset	Haemoptysis Tachycardia	Haemoptysis Pleuritic chest pain Tachycardia	Echocardiogram evidence of right heart strain	Chest pain Haemoptysis
ECG	Atrial fibrillation with rapid ventricular response	Sinus tachycardia	Atrial fibrillation with rapid ventricular response	Right bundle branch block	Normal sinus rhythm	S1Q3T3 pattern + right-axis deviation
D-dimer (<400 ng/L)	9,892	>80,000	23,068	11,448	21,000	4,800
Ferritin (10-350 ug/L)	1,745	2,197	1,029	871	N/A	N/A
Evidence of right heart strain	Nil	Nil	CTPA + echocardiogram	ECG + CTPA	Echocardiogram	ECG

ECG, electrocardiogram; ng, nanogram; L, litre; ug, microgram; Nil, none; S1Q3T3, deep S wave in lead I, a Q wave and inverted T wave in lead III; CTPA, computed tomography pulmonary angiogram.

in comparison to ferritin should raise suspicion for a pulmonary embolus.

Concerns have been raised of using contrast in a patient population that may be at increased risk of acute kidney injury.³ However, in a study of 116 COVID-19 confirmed patients, none of them met the criteria for diagnosis of an acute kidney injury and none of the patients we reported had a deterioration in renal function after contrast.¹⁰ Thus, we suggest that in a patient with sufficient renal function, that a CTPA should not be avoided if a pulmonary embolus is suspected.

In all cases in this series, there were no pre-existing risk factors for venous thromboembolism, although COVID-19 itself may be a risk factor. Seventy-one percent of non-survivors with COVID-19 met the criteria for disseminated intravascular coagulation which appears to be predominantly prothrombotic.¹¹⁻¹² Post-mortem lung dissection found microvascular thrombosis in a COVID-19 patient and a series of patients with the related SARS-CoV1.¹³⁻¹⁴ A case series of three COVID-19 patients found significant coagulopathy with peripheral ischaemia and bilateral cerebral infarctions in multiple vascular territories; notably all three patients had positive antiphospholipid antibodies.¹⁵

All patients were treated with treatment dose tinzaparin whilst thrombolysis was avoided due to the risk of haemorrhage. One study found that heparin prophylaxis in COVID-19 positive inpatients with a D-dimer >3000 ng/L reduced the 28-day mortality.¹¹

CONCLUSION

We reported four cases of COVID-19 patients presenting with an acute pulmonary embolus. It is important to be aware of atypical features of COVID-19 infection that may

be more suggestive of a pulmonary embolus such as pleuritic chest pain, haemoptysis, atrial fibrillation, tachycardia, hypotension, late onset deterioration, evidence of right heart strain, or a disproportionately elevated D-dimer in comparison to ferritin.

Further investigation is required into the role of prophylactic anticoagulation in COVID-19 patients and the pathogenesis of the hypercoagulable state including the role of antiphospholipid antibody. A regression analysis exploring predictive factors to the identification of PE will aid the pre-test probability, distinguishing those needing CTPA.

The authors attest that their institution requires neither Institutional Review Board approval, nor patient consent for publication of this case series. Documentation on file.

Address for Correspondence: James Greenan-Barrett, MBBS, Royal Free Hospital, Department of Emergency Medicine, Pond Street, Hampstead, London, United Kingdom, NW32QG. Email: james.greenan@nhs.net.

Conflicts of Interest: By the CPC-EM article submission agreement, all authors are required to disclose all affiliations, funding sources and financial or management relationships that could be perceived as potential sources of bias. The authors disclosed none.

Copyright: © 2020 Greenan-Barrett et al. This is an open access article distributed in accordance with the terms of the Creative Commons Attribution (CC BY 4.0) License. See: <http://creativecommons.org/licenses/by/4.0/>

REFERENCES

1. Zhonghua, Liu, Bing, et al. The epidemiological characteristics of an outbreak of 2019 novel coronavirus diseases (COVID-19) in China. *Chin J Epidemiol.* 2020;41(2);145-51.
2. Chen N, Zhou M, Dong X, et al. Epidemiological and clinical characteristics of 99 cases of 2019 novel coronavirus pneumonia in Wuhan, China: a descriptive study. *Lancet.* 2020;395(10223);507-13.
3. Danzi GB, Loffi M, Galeazzi G, et al. Acute pulmonary embolism and COVID-19 pneumonia: a random association? *Eur Heart J.* 2020;41(19);1858.
4. Casey K, Iteen A, Nicolini R, et al. COVID-19 pneumonia with hemoptysis: acute segmental pulmonary emboli associated with novel coronavirus infection. *Am J Emerg Med.* 2020;38(7):1544.e1-3.
5. Chen J, Wang X, Zhang S, et al. Findings of acute pulmonary embolism in COVID-19 patients. *Lancet Infect Dis.* 2020;2000678.
6. Xie Y, Wang X, Yang P, et al. COVID-19 complicated by acute pulmonary embolism. *Radiology.* 2020;2(2):e200067.
7. Zhou F, Yu T, Du R, et al. Clinical course and risk factors for mortality of adult inpatients with COVID-19 in Wuhan, China: a retrospective cohort study. *Lancet.* 2020;395(10229);1054-62.
8. Xu XW, Wu XX, Jiang XG, et al. Clinical findings in a group of patients infected with the 2019 novel coronavirus (SARS-Cov-2) outside of Wuhan, China: retrospective case series. *BMJ.* 2020;368:m606.
9. Cui S, Chen S, Li X, et al. Prevalence of venous thromboembolism in patients with severe novel coronavirus pneumonia. *J Thromb Haemost.* 2020;18(6);1421-4.
10. Wang L, Li X, Chen H, et al. Coronavirus disease 19 Infection does not result in acute kidney injury: an analysis of 116 hospitalized patients from Wuhan, China. *Am J Nephrol.* 2020;51(5):343-8.
11. Tang N, Bai H, Chen X, et al. Anticoagulant treatment is associated with decreased mortality in severe coronavirus disease 2019 patients with coagulopathy. *Thromb Haemost.* 2020;18(5);1094-9.
12. Li T, Lu H, Zhang W. Clinical observation and management of COVID-19 patients. *Emerg Microbes Infect.* 2020;9(1):687-90.
13. Luo W, Yu H, Gou J, et al. Clinical pathology of critical patient with novel coronavirus pneumonia (COVID-19). *Preprints.* 2020;202002.0407.v1.
14. Franks TJ, Chong PY, Chui P, et al. Lung pathology of severe acute respiratory syndrome (SARS): a study of 8 autopsy cases from Singapore. *Human Pathol.* 2003;34(8):743-8.
15. Zhang Y, Xiao M, Zhang S, et al. Coagulopathy and antiphospholipid antibodies in patients with Covid-19. *N Engl J Med.* 2020;382(17):e38.

Ruptured Splenic Artery Aneurysm in the Postpartum Patient: A Case Series

Angel Rochester, MD, MBA*

Tracy Lance, MD*

Dane E. Smith, MD†

Camiron Pfennig, MD, MHPE*

Adam Tyson, MD‡

Phillip Moschella, MD, PHD*

*Prisma Health Upstate, Department of Emergency Medicine, Greenville, South Carolina

†Prisma Health Upstate, Department of Surgery, Greenville, South Carolina

‡Prisma Health Upstate, Department of Obstetrics and Gynecology, Greenville, South Carolina

Section Editor: Rick A. McPheeters, DO

Submission history: Submitted February 13, 2020; Revision received April 18, 2020; Accepted April 30, 2020

Electronically published July 15, 2020

Full text available through open access at http://escholarship.org/uc/uciem_cpem

DOI: 10.5811/cpcem.2020.4.46946

Introduction: The evaluation of an unstable peripartum patient in the emergency department includes a differential diagnosis spanning multiple organ systems. Splenic artery aneurysm (SAA) is one of those rare diagnoses with potentially high morbidity and mortality.

Case Series: This case series explores two unusual cases of postpartum SAAs. Despite differences in presentation, both patients had a ruptured SAA.

Conclusion: Often, SAAs are misdiagnosed. Early diagnosis is key, especially for the fetus. If the patient presents in shock, the expedited diagnosis and treatment can be lifesaving for both the mother and the fetus. [Clin Pract Cases Emerg Med. 2020;4(3):304–307.]

Keywords: *splenic artery aneurysm; postpartum complications; antepartum complications.*

INTRODUCTION

The evaluation of an unstable pregnant or postpartum patient includes vast differential diagnoses that span multiple organ systems. Splenic artery aneurysm (SAA) is a dilation in a focal area of the splenic artery leading to potential instability. A rare diagnosis with high morbidity and mortality that is not well understood or recognized in the literature, SAA should be included in the discussion of potential pathology in this patient population, especially by emergency physicians. Often, SAAs are missed or misdiagnosed and found only in the operating room after rupture or in autopsy, with necropsy rates of as high as 10%.^{6,8} The expedited diagnosis and subsequent repair or embolization can be lifesaving for both the mother and the fetus. This report highlights a small case series of patients to display the varying presentations of SAAs, and the diagnostic and treatment options associated with this disease.

CASE SERIES

Case 1

A 29-year-old gravida 1 para 1 female, postpartum day four from an uncomplicated spontaneous vaginal delivery,

arrived at the emergency department (ED) by emergency medical services, unstable but awake, complaining of abdominal pain that started 24 hours prior. She was initially found by paramedics on the bathroom floor awake with an initial blood pressure of 60/40 millimeters of mercury (mmHg); thus, an intravenous (IV) catheter was placed and the patient received a 1000 milliliter (mL) bolus of normal saline. On arrival to the ED, the patient was pale, diaphoretic, and actively vomiting with a heart rate of 134 beats per minute, temperature 36.8 degrees Celsius (°C) (98.2 degrees Fahrenheit [°F]), respirations of 28 per minute, and a blood pressure of 84/31 mmHg.

A focused assessment with sonography in trauma (FAST) exam was performed and showed a significant amount of fluid across all abdominal views. The patient's initial lactic acid was 9.5 millimoles per liter (mmol/L) (reference range 0.5 – 2.5 mmol/L) and her hemoglobin was 5 grams per deciliter (g/dL) (reference range 14 – 18 g/dL). At this point both the general surgery and obstetrics/gynecology services were consulted. Point-of-care ultrasonography (POCUS) performed by obstetrics showed no abnormalities of the uterus. The patient's

declining hemodynamic status necessitated transfusion, and she received four units of packed red blood cells and one unit of fresh frozen plasma. Despite this aggressive resuscitation, the patient's mental status declined requiring intubation for airway protection, and she was taken by both general surgery and obstetrics for emergency exploratory laparotomy. During the exploratory laparotomy, she was found to have a hemorrhage secondary to a ruptured SAA. The patient was managed laparoscopically with suture ligation of the SAA and a splenectomy. Her postoperative recovery was uneventful. She was discharged on day three postoperatively, and at her six-month follow-up she remained healthy with no complications.

Case 2

A 46-year-old gravida 11 para 9 woman with history of hypertension and an uncomplicated caesarean section four months prior arrived complaining of sudden onset of mid to lower back pain and cramping that radiated to her upper abdomen and chest with associated shortness of breath with exertion. Physical exam showed a tachycardic, moderately anxious female without back or abdominal tenderness on palpation. Her initial vital signs were documented as follows: heart rate 130 beats per minute; blood pressure 116/82 mmHg; respiratory rate 16 breaths per minute; temperature 36.3°C (97.4°F); and O₂ saturation 100%.

A FAST exam was negative for free fluid, and her initial labs were unremarkable. Despite fluid resuscitation, she remained tachycardic. Blood pressure readings were obtained in both of her upper extremities and a 20 mmHg difference was noted, increasing the concern for dissecting aortic aneurysm. A computed tomography (CT) of the chest with IV contrast showed a splenic abnormality vs colonic gas. At that time, a subsequent CT of abdomen and pelvis with oral contrast was obtained that revealed a large amount of fluid within the greater peritoneal cavity and lesser sac. General surgery was consulted and vascular SAA was identified and coiled. During her hospital course she remained stable. She was discharged on day three postoperatively and has not had any other complications to date.

DISCUSSION

SAA, first reported in 1770, are the most common visceral aneurysm and the third most common intra-abdominal aneurysm, behind those affecting the aorta and iliac artery.¹ Typically, unruptured SAAs are asymptomatic; but occasionally they will present with vague complaints including abdominal pain. A ruptured SAA is often fatal and therefore must be included in your differential of abdominal pain. The general population has a prevalence of 0.78%, with a female predominance of 4:1 and necropsy rates as high as 10%.^{6,8} Risk factors for a SAA include female sex, pregnancy, multiparity, portal hypertension (cirrhosis and liver transplant), collagen vascular disease, medial fibrodysplasia, atherosclerosis, and splenomegaly.^{5,8}

CPC-EM Capsule

What do we already know about this clinical entity?

Splenic artery aneurysm (SAA) is an often overlooked and unrecognized diagnosis with high mortality, especially in women.

What makes this presentation of disease reportable?

Two postpartum patients one week and three months postpartum: Both were unstable, but rapid diagnosis and interventions led to good clinical outcomes.

What is the major learning point?

Pregnancy increases the development of SAAs that could rupture at any time in the life of a woman. When they rupture, there is a "double rupture" phenomenon.

How might this improve emergency medicine practice?

Awareness of this rare clinical entity could spur more rapid diagnosis to prevent significant morbidity and mortality to one or possibly two lives, mother and baby.

Both patients in our cases likely developed SAAs during their pregnancies. In fact, of the more than 400 cases reported in the international literature of ruptured SAAs, 30% occurred during pregnancy, and 6% in the postpartum phase.^{2,3} Multiparity is a strong risk factor with a mean of 3.5 pregnancies.^{2,4} The risk factors for rupture include aneurysm size greater than two centimeters (cm), female of childbearing age, pregnancy, cirrhosis, liver transplant, and alpha-1 antitrypsin deficiency.^{5,7}

The association with pregnancy is not understood, but changes related to the hormones and hemodynamics likely contribute. Estrogen, progesterone, and relaxin have vasodilatory effects and can increase the compliance and elasticity of vessel walls resulting in evidence of elastin formation failure, disruption of the internal elastic lamina, and elastic fiber fragmentation as a result of the elevated hormone levels. The hormones also cause degeneration of smooth muscle. Hemodynamically, the enlarging uterus compresses the surrounding vascular structures leading to higher pressure and flow in the splenic artery. This hemodynamic change is secondary to higher blood volumes, as the plasma portion is increased by up to 50%; increased cardiac output; and relative portal congestion.

The generalized risk of splenic rupture is approximately 5%, but this is increased in pregnancy and with larger overall aneurysm size greater than 2 cm.^{5,7} The mortality secondary to splenic rupture is 25-36%, but increases to 75% if the patient is pregnant.⁶ If found during pregnancy, the risk rises to 95% rupture with a fetal mortality of 95%.⁶ Splenic rupture can occur at any time in pregnancy, including the postpartum period, which is less common but possible, as highlighted in both of these cases.

SAAAs are difficult to diagnose, especially if asymptomatic. If symptomatic, patients usually have vague complaints of abdominal, back, or chest pain with radiation to the left shoulder. In pregnancy, SAAAs are misdiagnosed as uterine rupture up to 70% of the time.⁶ Other common diagnoses include ectopic pregnancy, placental abruption, amniotic fluid embolism, and perforated ulcer.

Approximately 25% of SAA ruptures are described in the literature as the “double rupture” phenomenon.⁷⁻⁹ Both cases are consistent with this phenomenon as the initial rupture spills into the lesser sac, which is posterior to the stomach and lesser omentum, leading only to mild symptoms as the local anatomic structures tamponades the hemorrhage in this area. Once a critical volume is reached, the hemorrhage spills through the foramen of Winslow into the greater sac (the larger portion of the peritoneal cavity) resulting in severe symptoms and hemodynamic instability, which often evolves within 6–96 hours after initial symptom onset.⁷⁻⁹ During pregnancy, hypotension may not be evident until approximately 35% of the circulating blood volume is lost making high clinical suspicion required for improved outcomes.

Although our patient in case one did not suffer any trauma, a FAST exam was instrumental in rapid diagnosis and treatment as it demonstrated free fluid in the hepatorenal, splenorenal, and pelvic views. The FAST exam in case two was likely “negative” because of the known limits of detection for free fluid for this exam and the “double rupture” phenomenon.

SAAAs are treated either endovascularly or surgically. If unruptured or uncomplicated, then endovascular embolization is preferred. If rupture is suspected, an emergent exploratory laparotomy is indicated. Since 80% of these aneurysms are located distally (Image), the treatment is usually resection and splenectomy.^{1,8}

CONCLUSION

Although rare, splenic artery aneurysms should be included in the differential diagnosis of abdominal pain, especially in the unstable peripartum patient. The risk of rupture is 5% but increases with pregnancy and can have a mortality rate of up to 75%.⁶ Emergency physicians should consider splenic artery aneurysm early in the patient evaluation and use varied imaging modalities (i.e., POCUS or CT) to aid in rapid evaluation and subsequent consultation for definitive management to improve outcomes for both the mother and the fetus.

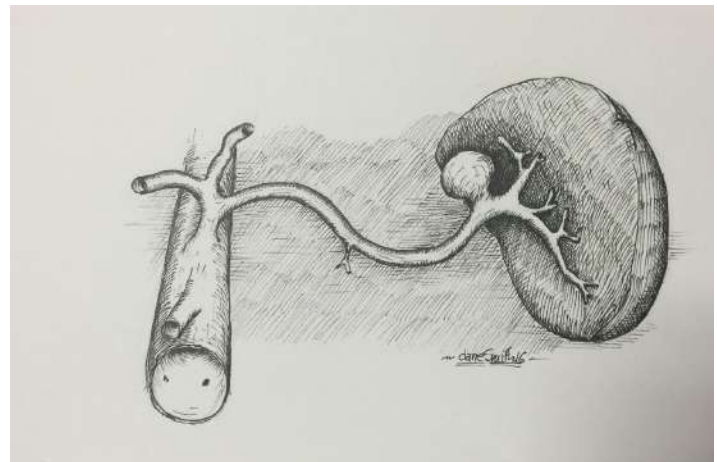


Image. Drawing of a distal splenic artery aneurysm under the spleen. Artist: Dane Smith.

The Institutional Review Board approval has been documented and filed for publication of this case series.

Address for Correspondence: Angel Rochester, MD, MBA, Prisma Health Upstate, Department of Emergency Medicine, 701 Grove Road, Greenville SC 29605. Email: Angel.Rochester@prismahealth.org.

Conflicts of Interest: By the CPC-EM article submission agreement, all authors are required to disclose all affiliations, funding sources and financial or management relationships that could be perceived as potential sources of bias. The authors disclosed none.

Copyright: © 2020 Rochester et al. This is an open access article distributed in accordance with the terms of the Creative Commons Attribution (CC BY 4.0) License. See: <http://creativecommons.org/licenses/by/4.0/>

REFERENCES

1. Bhagya Lakshmi A, Ayeesha Begum S, Reddi BR, et al. Splenic artery aneurysm: a case report with review of literature. *Int J Res Med Sci.* 2014;2:1220-2.
2. Abbas MA, Stone WM, Fowl RJ, et al. Splenic artery aneurysms: two decades experience at Mayo Clinic. *Ann Vasc Surg.* 2002;16(4):442-9.
3. McMahon DP, Ward WH, Harwood JL, et al. An institutional review of splenic artery aneurysm in childbearing-aged females and splenic artery aneurysm rupture during pregnancy. Is screening justified? *Mil Med.* 2012;177(1):96-8.
4. Jackson HT, Diaconu SC, Maluso PJ, et al. Ruptured splenic artery aneurysms and the use of an adapted FAST protocol in reproductive age women with hemodynamic collapse: a case series. *Case Rep Emerg Med.* 2014;2014:454923.

5. Trastek VF, Pairolero PC, Joyce JW. Splenic artery aneurysms. *Surg.* 1982;91(6):694-9.
6. Selo-Ojeme DO and Welch CC. Review: spontaneous rupture of splenic artery aneurysm in pregnancy. *Eur J Obstet Gynecol Reprod Bio.* 2003;109(2):124-7.
7. Manjula D, Al Mashini S, Golash V. Rupture of splenic artery aneurysm during pregnancy: a report of two cases. *Oman Med J.* 2011;26:1-3.
8. Mattar SG and Lumsden AB. The management of splenic artery aneurysms: experience with 23 cases. *Am J Surg.* 1995;169:580-4.
9. Remy D and Linder JL. Splenic aneurysm rupture: case report and review of the literature. *Acta Chir Belg.* 1993;93:54-7.

Alternative Diagnostic Strategy for the Assessment and Treatment of Pulmonary Embolus: A Case Series

Ayaz Aghayev, MD*

Aliza A. Memon, MBBS†

Paul Gregg Greenough, MD, MPH‡

Lakshmi Nayak, MD§

Sijie Zheng, MD, PhD¶

Andrew M. Siedlecki, MD†

*Brigham and Women's Hospital, Department of Radiology, Boston, Massachusetts

†Brigham and Women's Hospital, Department of Internal Medicine, Boston, Massachusetts

‡Brigham and Women's Hospital, Department of Emergency Medicine, Boston, Massachusetts

§Dana Farber Cancer Institute, Boston, Massachusetts

¶Kaiser Permanente, Oakland, California

Section Editor: Rick A. McPheeters, DO

Submission history: Submitted February 14, 2020; Revision received April 29, 2020; Accepted May 5, 2020

Electronically published June 22, 2020

Full text available through open access at http://escholarship.org/uc/uciem_cpem

DOI: 10.5811/cpcem.2020.5.46517

Introduction: Ferumoxylol-enhanced magnetic resonance angiography (FeMRA) can be used as an alternate and safe method to diagnose patients with compromised renal function who present with acute pulmonary embolus in the emergency department (ED) setting.

Case Report: A 62-year old man with a history of renal transplant and lymphoproliferative disease described new onset of breathlessness. His clinical symptoms were suggestive of pulmonary embolus. He underwent FeMRA in the ED to avoid exposure to intravenous iodinated contrast. FeMRA demonstrated a left main pulmonary artery embolus, which extended to the left interlobar pulmonary artery. Afterward, the patient initiated anticoagulation therapy. With preserved renal function he was able to continue his outpatient chemotherapy regimen.

Conclusion: This case highlights a safe imaging technique for emergency physicians to diagnose pulmonary embolus and subsequently guide anticoagulation therapy for patients in whom use of conventional contrast is contraindicated. [Clin Pract Cases Emerg Med. 2020;4(3):308–311.]

Keywords: *FE-MRA; pulmonary embolus; renal transplant; lymphoproliferative.*

INTRODUCTION

Kidney transplant recipients are frequently evaluated in the emergency department (ED) setting with a visit rate of 1.4 per patient-year.¹ The majority of these encounters are in the first two years after transplant, which vary based on the center as well as patient characteristics.² Most often, an infectious etiology is identified in the first year post-transplant whereas cardiopulmonary disease and malignancy are detected after the first year of engraftment.^{3,4} Patients receiving a solid organ transplant have increased rates of post-transplant lymphoproliferative disease due to chronic immunosuppressive therapy and a dysfunctional immune system.⁵ Renal transplant patients

have an eight-fold increased risk of thromboembolism compared to the general population.⁶

These characteristics present a diagnostic challenge for the emergency physician when assessing for pulmonary embolus in kidney transplant recipients. As a result this population is at risk for iodine contrast-induced nephropathy at higher rates than patients with bilateral native kidney function with similar estimated glomerular filtration rate (eGFR)^{7,8}; however, it is unclear whether this broadly applies to patients with chronic kidney disease (CKD) and a decreased renal reserve in the setting of a solitary kidney transplant since this group is either excluded or under-represented in multivariate analyses.⁹ We report the use of ferumoxylol-

enhanced magnetic resonance angiography (FeMRA) as an alternative diagnostic tool to assess for pulmonary embolus in patients at risk of iodine contrast-induced nephropathy. Awareness of alternative imaging techniques in the ED setting for patients with severe CKD or kidney transplant recipients with CKD may offer expedited diagnosis and treatment.

CASE SERIES

Patient 1

A 62-year-old male with end stage renal disease due to autosomal dominant polycystic kidney disease received a living unrelated donor kidney transplant in 2017 that was complicated by post-transplant lymphoproliferative disease involving the central nervous system, which developed in 2018. He was initiated on a course of intravenous (IV) rituximab and high-dose methotrexate. Due to new symptoms of fatigue and shortness of breath he was seen in his outpatient oncology clinic. There he described the fatigue to occur after walking four city blocks. The patient felt the symptoms were mild but did not recall having them three days prior. After discussing his concerns with his wife and oncologist, he was referred to the ED for workup of possible pulmonary embolism.

Physical exam revealed an anxious man with warm, well-perfused extremities and 2+/4 pitting edema in his right ankle. Upon questioning, he noted the swelling had developed after his last methotrexate infusion. Cardiac exam revealed a regular heart rate without third and fourth heart sounds. The neurological exam was non-focal. The patient had an eGFR of 48 milliliters (mL) per minute (min) per 1.73 squared meter (m²) (normal eGFR > 89 mL/min/m²). Fifth-generation serum troponin was not detectable. A chest radiograph revealed new trace bilateral pleural effusions and bibasilar atelectasis. Lower extremity Doppler ultrasonography showed fully compressible deep venous structures. Electrocardiograph showed normal sinus rhythm without axis deviation.

The patient was recommended to undergo computed tomographic angiography of the pulmonary arteries but was reluctant for concern that his scheduled chemotherapy the following week would be postponed due to a decline in kidney function following iodinated contrast exposure. Due to mild shortness of breath and no need for supplemental oxygen the patient was prepared to be discharged from the ED when a d-dimer level was reported to be 3254 nanograms (ng) per mL, which was 6.5-fold above the upper limit of the central laboratory normal range (0-500 ng/mL).

The renal transplant service was consulted for further recommendations. Considering his progressive shortness of breath, chronic kidney disease, malignancy, and elevated d-dimer, diagnostic imaging was considered. The patient was offered ferumoxytol-enhanced cardiothoracic angiography and counseled about risks and benefits of FeMRA as an alternative to iodinated contrast-enhanced radiologic imaging. The patient described neither an allergy to IV iron nor a history of iron deposition disease. The patient, his treating

CPC-EM Capsule

What do we already know about this clinical entity?

Imaging plays a crucial role in the diagnosis and management of an acute pulmonary embolism, and often chest computed tomography angiogram or ventilation-perfusion scan is used.

What makes this presentation of disease reportable?

Ferumoxytol-enhanced magnetic resonance angiography (FeMRA) provided a rapid diagnosis of a life-threatening illness, which prompted the delivery of life-saving treatment.

What is the major learning point?

FeMRA of the cardiopulmonary vasculature can be used for the assessment of pulmonary embolism in patients with compromised renal function.

How might this improve emergency medicine practice?

This technique has the potential to be employed in emergency departments by using clinical resources already available.

emergency physician, attending oncologist, attending transplant nephrologist, and attending radiologist were in agreement to use ferumoxytol off-label as a radiologic contrast agent. Therefore, IV ferumoxytol was then infused over 10 minutes with no evidence of anaphylaxis reported by the patient or observed by the nephrologist who was present during the duration of the infusion. The patient was required to lie flat. Images were acquired over a 20-minute period using a standard thoracic imaging protocol. FeMRA demonstrated a distal left main pulmonary artery embolus that extended to the left interlobar pulmonary artery (Images 1 and 2) without evidence of right heart strain by transthoracic echocardiography.

The patient was admitted to the oncology service for initiation of anticoagulation with apixaban (10 mg tablet) to be given daily for one week and then 5 mg twice a day thereafter. The patient was discharged the following day and proceeded to outpatient chemotherapy infusion the following week. Four days afterward, non-contrasted magnetic resonance imaging (MRI) of the spine and brain was performed without gadolinium contrast. The repeat MRI occurred 93 hours after administration of ferumoxytol. There was no evidence of residual ferumoxytol obscuring the radiologist's interpretation of the images.

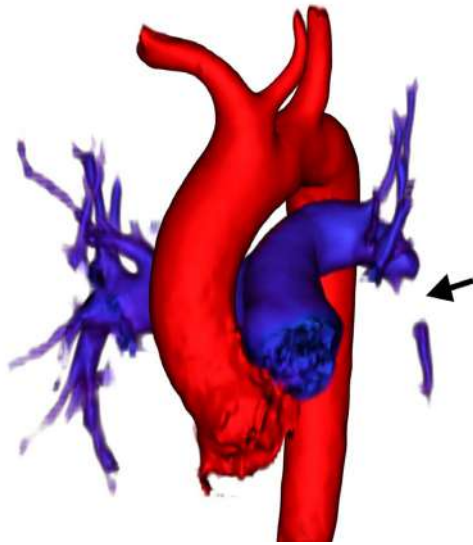


Image 1. Patient 1, three-dimensional reconstruction of pulmonary embolus in left interlobar pulmonary artery (anterior view) (black arrow) visualized by ferumoxytol-enhanced magnetic resonance angiography demonstrating total occlusion of the intravascular lumen.

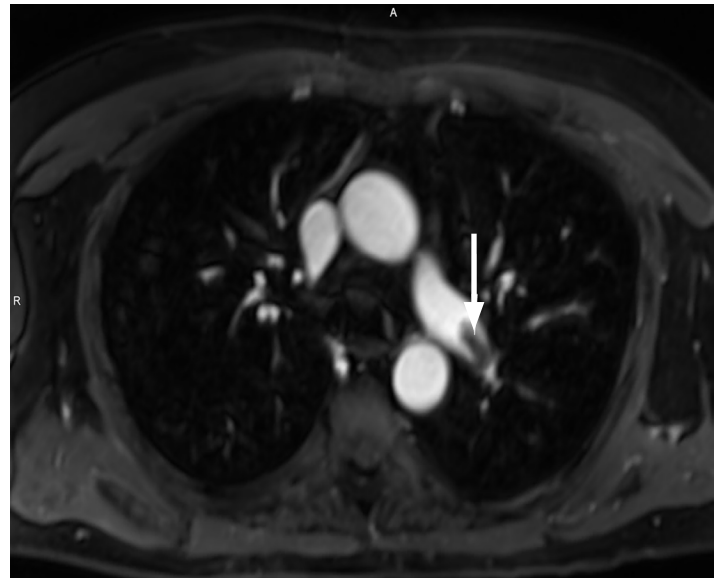


Image 2. Patient 1, three-dimensional reconstruction of pulmonary embolus in left interlobar pulmonary artery (axial view) (white arrow) visualized by ferumoxytol-enhanced magnetic resonance angiography demonstrating total occlusion of the intravascular lumen.

Patient 2

A 69-year-old male with CKD 5 (eGFR 11mL/min/1.73m²) was evaluated for kidney transplantation and utilized as a negative historical control. He had a history of pulmonary embolus 12 years prior without recurrence. At the time of transplant evaluation the patient was in his usual state of health. Due to a history of pulmonary embolus, coronary artery disease, CKD stage 5 and maintained urine output, FeMRA was performed. Images were acquired over a 20-minute period. Pulmonary vasculature was well visualized showing no defect of the lobar or interlobar pulmonary arteries. This patient demonstrated widely patent left and right pulmonary artery circulation with similar resolution compared to Patient #1 (Image 3). (All primary data is publicly available online: <http://dx.doi.org/10.17632/s787bx8w52.2>)

DISCUSSION

Although, FeMRA of the abdominal vasculature has high diagnostic specificity and sensitivity,¹⁰ it has not been previously used to guide the treatment of acute pulmonary embolus. Ferumoxytol has also been used in the outpatient, inpatient, and ED settings for radiologic assessment of cardiothoracic pathology.¹¹⁻¹³ Institutional safety protocols often require that a physician be present through the duration of each FeMRA procedure for concern of the theoretical risk of anaphylaxis. To avoid this reaction, infusion can be extended over a 10-minute period with a total dose based on ideal body weight of no more than 3 mg per kilogram (kg). Images can be fully acquired within 20 minutes of infusion, reducing the extended period of time often necessary to perform ventilation/perfusion

scintigraphy. The rate of patient or healthcare staff reporting an allergic or anaphylactic reaction using the current protocol approximates 2%.¹⁴ The minimum adequate dose for clinically acceptable imaging is unknown for each anatomical site of interest. The current dosing regimen (3 mg/kg) is unlikely necessary for imaging of non-cardiothoracic vasculature in the abdomen where motion artifact can be readily attenuated. Such low-dose protocols may assist in further reducing the theoretical risk of iron overload.

Limitations of ferumoxytol use include active infection, iron deposition disease, and allergy to IV iron. Iron oxide facilitates bacterial growth and should not be used in patients suspected to have a diagnosis of sepsis. Iron deposition disease due to chronic IV iron use is well described. Finally, anaphylaxis with ferumoxytol has been reported to approach a rate of one event per 3000 patients infused with 510 mg of IV ferumoxytol over a 60-second period.¹⁵ The incidence of anaphylaxis using 10-minute infusion duration is unknown but anticipated to be less. Patients with prior allergy to IV iron, let alone anaphylaxis, should avoid ferumoxytol infusion.

The patient that we report here had a scheduled MRI study for re-staging of his malignancy four days after FeMRA and there was no evidence of retained ferumoxytol obscuring areas of the central nervous system where malignancy was first detected.

CONCLUSION

Sequela of a pulmonary embolus is commonly encountered in the ED and can be life-threatening if not diagnosed and treated in a timely manner. Use of FeMRA represents a new

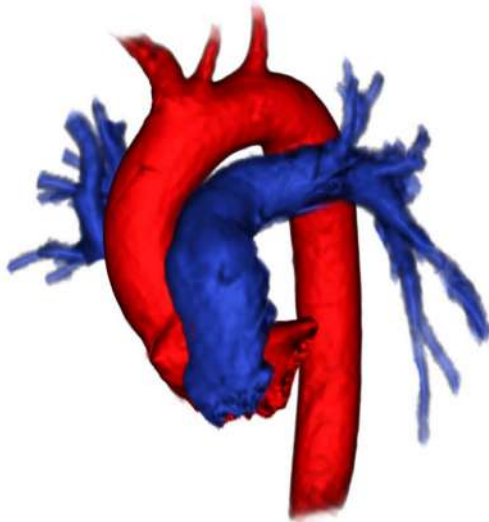


Image 3. Patient 2, three-dimensional reconstruction of pulmonary arteries visualized by ferumoxytol-enhanced magnetic resonance angiography demonstrating widely patent intravascular lumens.

tool that may offer expedited evaluation in patients with kidney dysfunction requiring intravascular contrast.

The Institutional Review Board approval has been documented and filed for publication of this case series.

Address for Correspondence: Andrew M Siedlecki, MD, Transplantation Research Center, Brigham and Women's Hospital, Department of Emergency Medicine, 77 Avenue Louis Pasteur, Boston, MA 02115, Email: asiedlecki@bwh.harvard.edu.

Conflicts of Interest: By the CPC-EM article submission agreement, all authors are required to disclose all affiliations, funding sources and financial or management relationships that could be perceived as potential sources of bias. AMAG Pharmaceuticals, Inc., in part, funded the efforts reported here. This agreement is an investigator sponsored research grant. BWH retains rights to all data generated in this study. K08DK089002, NIH/NIDDK (Bethesda, MD) (A.M.S.); AMAG Pharmaceuticals, Inc (Waltham, MA), Investigator-sponsored research grant #2016D004506 (A.M.S.). The authors disclosed no conflicts of interest.

Copyright: © 2020 Aghayev et al. This is an open access article distributed in accordance with the terms of the Creative Commons Attribution (CC BY 4.0) License. See: <http://creativecommons.org/licenses/by/4.0/>

REFERENCES

1. United States Renal Data System. USRDS ANNUAL DATA REPORT | VOLUME 2: ESRD IN THE UNITED STATES. Chapter 4: Hospitalizations, readmissions, emergency department visits, and observation stays. 2018. Available at: <https://www.usrds.org/adr.aspx>. Accessed April 25, 2020.
2. Schold JD, Elfadawy N, Buccini LD, et al. Emergency department visits after kidney transplantation. *Clin J Am Soc Nephrol*. 2016;11(4):674-83.
3. Unterman S, Zimmerman M, Tyo C, et al. A descriptive analysis of 1251 solid organ transplant visits to the emergency department. *West J Emerg Med*. 2009;10(1):48-54.
4. Einollahi B, Rostami Z, Nourbala MH, et al. Incidence of malignancy after living kidney transplantation: a multicenter study from Iran. *J Cancer*. 2012;3:246-56t
5. Au E, Wong G, Chapman JR. Cancer in kidney transplant recipients. *Nat Rev Nephrol*. 2018;14(8):508-20.
6. Verhave JC, Tagalakis V, Suissa S, et al. The risk of thromboembolic events in kidney transplant patients. *Kidney Int*. 2014;85(6):1454-60.
7. Heldal K, Midtvedt K, Hartmann A, et al. Estimated Glomerular Filtration Rate in Stable Older Kidney Transplant Recipients-Are Present Algorithms Valid? A National Cross-Sectional Cohort Study. *Transpl Int*. 2018;31(6):629-38.
8. Fananapazir G, Troppmann C, Corwin MT, et al. Incidences of acute kidney injury, dialysis, and graft loss following intravenous administration of low-osmolality iodinated contrast in patients with kidney transplants. *Abdom Radiol (NY)*. 2016;41(11):2182-6.
9. Hinson JS, Ehmman MR, Fine DM, et al. Risk of acute kidney injury after intravenous contrast media administration. *Ann Emerg Med*. 2017;69(5):577-86.e4.
10. Schwenk MH. Ferumoxytol: A new intravenous iron preparation for the treatment of iron deficiency anemia in patients with chronic kidney disease. *Pharmacotherapy*. 2010;30(1):70-9.
11. Mukundan S, Steigner ML, Hsiao LL, et al. Ferumoxytol-enhanced magnetic resonance imaging in late-stage CKD. *Am J Kidney Dis*. 2016;67(6):984-8.
12. Toth GB, Varallyay CG, Horvath A, et al. Current and potential imaging applications of ferumoxytol for magnetic resonance imaging. *Kidney Int*. 2017;92(1):47-66.
13. Stoumpos S, Hennessy M, Vesey AT, et al. Ferumoxytol-enhanced magnetic resonance angiography for the assessment of potential kidney transplant recipients. *Eur Radiol*. 2018;28(1):115-23.
14. Nguyen KL, Yoshida T, Kathuria-Prakash N, et al. Multicenter safety and practice for off-label diagnostic use of ferumoxytol in MRI. *Radiology*. 2019;293(3):554-64.
15. Wang C, Graham DJ, Kane RC, et al. Comparative risk of anaphylactic reactions associated with intravenous iron products. *JAMA*. 2015;314(19):2062-8.

Decompression of Subdural Hematomas Using an Intraosseous Needle in the Emergency Department: A Case Series

Brett Barro, MD*
Scott Kobner, MD*
Ashkon Ansari, MD†‡

*LAC+USC Medical Center, Department of Emergency Medicine, Los Angeles, California
 †Keck School of Medicine of USC, Department of Emergency Medicine, Los Angeles, California
 ‡Antelope Valley Hospital, Department of Emergency Medicine, Lancaster, California

Section Editor: Christopher Sampson, MD

Submission history: Submitted December 4, 2019; Revision received June 11, 2020; Accepted June 17, 2020

Electronically published July 14, 2020

Full text available through open access at http://escholarship.org/uc/uciem_cpem

DOI: 10.5811/cpcem.2020.6.46069

Introduction: Traumatic subdural hematomas beget significant morbidity and mortality if not rapidly decompressed. This presents a unique challenge to the emergency physician without immediate neurosurgical support.

Case Report: We report two cases of patients in Los Angeles County with traumatic subdural hematomas and clinical deterioration in the emergency department (ED) who were treated with decompression using an intraosseous needle drill.

Discussion: We believe these cases represent the first use of this technique to temporize a subdural hematoma in the ED. [Clin Pract Cases Emerg Med. 2020;4(3):312–315.]

Keywords: *emergency medicine; extra-axial hematoma; burr hole.*

INTRODUCTION

Extra-axial hematomas (EAH), typically subdural (SDH) and epidural hematomas (EDH), are collections of blood surrounding the brain between the skull and various layers of meninges. Both entities represent neurosurgical emergencies for which surgical decompression, if indicated, is required to prevent secondary brain injury.¹⁻⁴ Unfortunately, the time to definitive care by a neurosurgeon may be delayed due to various barriers such as hospital transfer times.

In addition to medical management, temporizing emergent trephinations (ie, burr holes) have long been performed by neurosurgeons in an attempt to decompress the intracranial space before taking patients to the operating room (OR). In the event of a delay, non-neurosurgeons have also performed this procedure successfully with favorable outcomes.⁵ This has most recently been reported for EDH using an intraosseous needle in the emergency department (ED).⁶ We present two separate cases of SDH evacuation with the use of the intraosseous needle (IO) by emergency physicians.

CASE SERIES

Case Report 1

A 65-year-old man with no known past medical history presented to a Level 1 trauma center after sustaining severe blunt head trauma. The patient was agitated with a Glasgow Coma Scale (GCS) of 11 (Eye(E): 3; Verbal(V): 3; Motor(M): 5). His physical exam revealed trauma to the left temporal area including palpable crepitus, a large hematoma, and bloody discharge from the left ear. Focused assessment with sonography in trauma (FAST) was negative for intraperitoneal and pericardial fluid. Plain films of his chest and pelvis were negative for acute injuries.

While being prepared for transport for computed tomography (CT), the patient became profoundly bradycardic and was treated for a suspected increase in intracranial pressure (ICP) with standard neuroprotective measures including elevation of his head, hypertonic saline, and mechanical hyperventilation. Despite these maneuvers, the patient went into cardiac arrest without a shockable rhythm. He was transfused two units type O positive blood and

given epinephrine, sodium bicarbonate, calcium chloride, and tranexamic acid. Repeat FAST exam revealed no intraperitoneal or pericardial fluid.

After eight minutes of cardiopulmonary resuscitation (CPR), the decision was made to attempt decompression of a suspected EAH. An 11-blade scalpel was used to make a vertical incision three centimeters (cm) anterior and two cm superior to the left tragus over the temporal scalp where the culprit hematoma was thought to be located. A hemostat was then used to perform a subgaleal dissection. A 45-millimeter (mm) EZ-IO needle (Teleflex, Morrisville, NC) was subsequently inserted through the incision into the cranium. Using a syringe, roughly 10 milliliters (mL) of dark blood was evacuated from the extra-axial space with sudden return of spontaneous circulation.

Despite these efforts, the patient became pulseless again five minutes later while being stabilized for CT. CPR was resumed, and further attempts to evacuate blood through the IO needle were unsuccessful. CPR was eventually terminated. Post-mortem evaluation by the coroner confirmed the location of the IO needle in a subdural hematoma and verified the needle did not violate brain parenchyma. Unfortunately, the patient had concomitant subarachnoid hemorrhage with severe hydrocephalus leading to tonsillar herniation.

Case Report 2

A 30-year-old man with no past medical history presented to a community hospital after sustaining significant blunt head trauma. Diagnostic imaging revealed a 16-mm, left-sided SDH and trace subarachnoid hemorrhage without evidence of herniation. No other clinically significant injuries were identified. Standard neuroprotective measures were undertaken and neurosurgery was consulted immediately.

Approximately 30 minutes after his initial imaging, the patient became bradycardic with a heart rate of 34 beats per minute (bpm) and hypertensive to 186/109 millimeters of mercury. The patient's GCS deteriorated from 13 (E4V4M5) to 4T (E1V1TM2) without sedation or a long-acting paralytic. Hypertonic saline and mannitol were administered intravenously. Repeat imaging demonstrated an increase in SDH size to 20 mm, with new evidence of cisternal effacement, 12 mm of midline shift, and herniation. Neurosurgery was notified and the decision was made to transfer the patient to the OR for emergent craniotomy. Unfortunately, given the home-to-hospital commute time for the consultant, the soonest the patient could undergo surgery was over 30 minutes. After discussion with the neurosurgeon, the decision was made to attempt decompression with an EZ-IO.

Using CT guidance, the location of maximal clot depth was identified. Similar to the previous case, the IO needle was inserted into the extra-axial space. Using a three-milliliter (mL) syringe, roughly 15 mL of dark blood was evacuated and the

CPC-EM Capsule

What do we already know about this clinical entity?

Expanding subdural hematomas, if not decompressed in a timely fashion, often progress to brain herniation and irreversible neurological damage and death.

What makes this presentation of disease reportable?

The first two known cases of emergent decompression of subdural hematomas causing herniation utilizing an EZ-IO performed by emergency physicians without neurosurgical assistance.

What is the major learning point?

In austere environments, emergency physicians are capable of using EZ-IO needles to perform emergent trephinations and decompress extra-axial intracranial hemorrhages.

How might this improve emergency medicine practice?

As a heroic measure, emergency physicians can utilize this technique to temporize patients who may have impending herniation in order to get them to definitive neurosurgical care.

patient's heart rate increased from 30 bpm to 70 bpm. He was taken to the OR for craniotomy approximately one hour after the suspected herniation. Unfortunately, during his hospital stay, he did not have improvement in his neurologic status. Tracheostomy and gastrostomy tube placement were performed, and the patient was transitioned to a skilled nursing facility.

DISCUSSION

It has previously been reported that a delay as short as 70 minutes from onset of anisocoria or coma with EAH portends a poor neurological outcome.⁷ Unfortunately, standard medical therapy for increases in ICP rapidly reach their limits of effectiveness. In such cases where herniation is inevitable, there is growing interest in the utility of emergent trephination after exhaustive medical treatment and prior to transfer to definitive surgery. This is of particular importance in the ED, where a large number of patients die from herniation syndromes after presenting with a neurologically intact exam, suggesting little-to-no primary brain insult.

Unfortunately, not all patients with an EAH and evidence of herniation present to a medical facility that has a

neurosurgeon available to perform operative decompression in an acceptable time frame. In contrast to EDHs where burr holes may be a sufficient intervention, SDHs tend to have a large clot burden and persistent bleeding requiring a craniotomy or bone flap. It is, therefore, imperative that any ED trephination not delay transfer to the OR. However, as suggested by the Monro-Kellie doctrine, even small evacuations of blood can lead to dramatic decreases in ICP, reducing the risk of herniation while the patient awaits definitive care. There have been several case series where patients with an EAH and evidence of herniation were found to have improvement in Glasgow outcome scores after undergoing skull trephination by non-neurosurgeons prior to transfer.^{8,9} Although study results are inconsistent, it is difficult to dismiss a relatively simple procedure that potentially improves chances for favorable neurological recovery.^{10,11}

The decision to perform an emergent trephination requires great deliberation. Required tools are not always available, the clinical scenario arises infrequently and, historically, this procedure is considered outside the scope of practice for generalists. This makes it challenging for emergency physicians to maintain a level of competency with the procedure or become credentialed. IO needles are readily available in most EDs and are a tool that all emergency physicians are proficient with, obviating the need to learn traditional trephination techniques. In addition, use of the IO theoretically reduces the risk of damaging the parenchyma as needle size can be chosen based on hematoma diameter measured on CT. Even with traditional trephination, non-neurosurgeons have similarly low rates of complications compared to neurosurgeons.⁵ It therefore seems prudent for emergency physicians to become familiar with this potentially life-saving procedure, particularly when working in austere environments. However, this intervention ought to be considered a heroic measure, only to be performed in circumstances when other life-saving interventions are not immediately available.

Recently, there was a report of non-neurosurgeons using an IO needle for decompression of an EDH as a temporizing measure in the United Kingdom.⁶ This technique was previously shown to be effective when used by neurosurgeons in a patient herniating from an EDH while awaiting operating room availability.¹² We demonstrate that the EZ-IO can also be employed for relatively successful decompression of an acute SDH by non-neurosurgeons.

The described procedure took approximately 10 minutes to complete, which is consistent with previous reports.^{6,7} This amount of time should not cause any delay in transfer to definitive care and can be performed while transport is being arranged. We also advocate for the use of CT guidance and neurosurgical consultation before performing this procedure as done in *Case 2*. This involves placing a landmark (i.e., electrode sticker) on scalp prior to CT and measuring the distance to the center of the hematoma radiographically from this landmark (Image). Unfortunately, the patient in *Case 1* went into cardiac

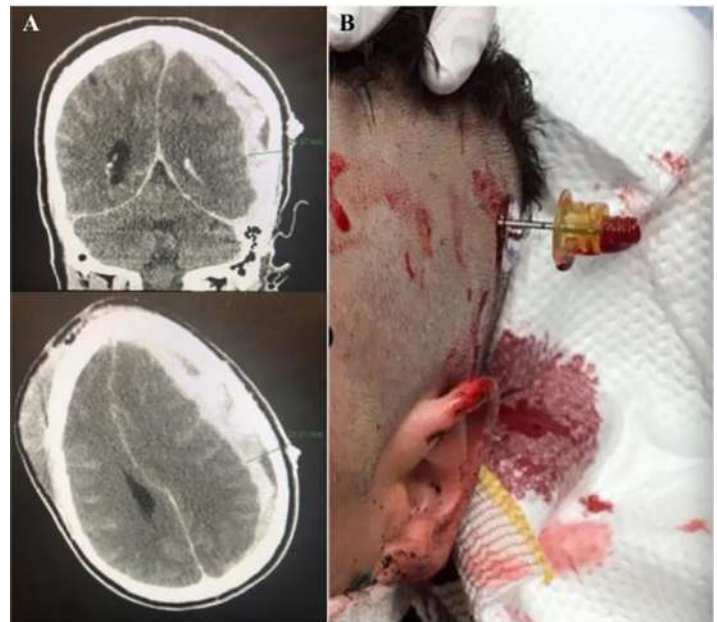

Image. Intraosseous needle positioned on scalp (B) placed just inferior and anterior to marker seen on computed tomography (A) with maximal depth of hematoma measured to guide advancement of needle.

arrest before imaging. In this extreme circumstance, the decision was made to perform a landmark-based evacuation ipsilateral to the cranial trauma as a life-saving attempt. Before CT scanners became ubiquitous, emergent exploratory craniotomy for EAH was often performed using anatomical landmarks alone.¹³

Neither of the patients described survived to meaningful neurological recovery. This is the unfortunate outcome of most instances of brain herniation. Indeed, patients with EAH who arrive with GCS less than 6 or in cardiac arrest have minimal chance of meaningful recovery. However, a clinical improvement was initially established with emergent IO decompression. As emergency providers, we are tasked with making invasive intervention decisions that carry a low probability of conferring a positive morbidity or mortality outcome for patients. In the face of almost certain death, imparting a chance at survival should be weighed carefully.

CONCLUSION

Emergent trephination in the appropriate clinical situation remains an active area of research. When approved by a neurosurgeon, the EZ-IO needle has been proposed as a useful tool to temporize well-selected patients with CT-confirmed EAH and clinical decompensation, when definitive care is delayed. We stress that emergency physicians should only consider employing this procedure in conjunction with neurosurgical consultation and in resource-limited settings so long as it does not delay transfer to the OR.

The authors attest that their institution requires neither Institutional Review Board approval, nor patient consent for publication of this case report. Documentation on file.

Address for Correspondence: Brett Barro, MD, LAC+USC Medical Center, 1200 N State Street, Los Angeles, CA 90033. Email: bab_156@usc.edu.

Conflicts of Interest: By the CPC-EM article submission agreement, all authors are required to disclose all affiliations, funding sources and financial or management relationships that could be perceived as potential sources of bias. The authors disclosed none.

Copyright: © 2020 Barro et al. This is an open access article distributed in accordance with the terms of the Creative Commons Attribution (CC BY 4.0) License. See: <http://creativecommons.org/licenses/by/4.0/>

REFERENCES

1. Bulters D and Belli A. A prospective study of the time to evacuate acute subdural and extradural haematomas. *Anaesthesia*. 2009;64(3):277-281.
2. Mendelow AD, Karmi MZ, Paul KS, et al. Extradural haematoma: effect of delayed treatment. *Br Med J*. 1979;1(6173):1240-2.
3. Fountain DM, Koliass AG, Lecky FE, et al. Survival trends after surgery for acute subdural hematoma in adults over a 20-year period. *Ann Surg*. 2017;265(3):590-6.
4. Ghajar J. Brain Trauma Foundation. Guidelines for the Surgical Management of TBI (last updated in 2006). 1986. Available at: <https://www.braintrauma.org/guidelines/guidelines-for-the-surgical-management-of-tbi#:~:guideline/surgical-management-of-acute-epidural-hematomas>. Accessed November 20, 2019.
5. Smith SW, Clark M, Nelson J, et al. Emergency department skull trephination for epidural hematoma in patients who are awake but deteriorate rapidly. *J Emerg Med*. 2010;39(3):377-83.
6. Durnford S, Bulstrode A, Durnford A, et al. Temporising an extradural haematoma by intraosseous needle craniostomy in the District General Hospital by non-neurosurgical doctors: a case report. *J Intensive Care Soc*. 2018;19(1):76-9.
7. Cohen JE, Montero A, Israel ZH. Prognosis and clinical relevance of anisocoria-craniotomy latency for epidural hematoma in comatose patients. *J Trauma*. 1996;41(1):120-2.
8. Nelson JA. Local skull trephination before transfer is associated with favorable outcomes in cerebral herniation from epidural hematoma. *Acad Emerg Med*. 2011;18:78-85.
9. Rinker CF, McMurry FG, Groeneweg VR, et al. Emergency craniotomy in a rural III trauma center. *J Trauma*. 1998;44(6):984-9.
10. Shibahashi K, Sugiyama K, Kashiura M, et al. Emergency trepanation as an initial treatment for acute subdural hemorrhage: a multicenter retrospective cohort study. *World Neurosurg*. 2017;106:185-92.
11. Liu X, Qiu Y, Zhang J, et al. Emergent single burr hole evacuation for traumatic acute subdural hematoma with cerebral herniation: a retrospective cohort comparison analysis. *World Neurosurg*. 2018;120:e1024-30.
12. Bulstrode H, Kabwama S, Durnford A, et al. Temporising extradural haematoma by craniostomy using an intraosseous needle. *Injury*. 2017;48(5):1098-1100.
13. Springer MF and Baker FJ. Cranial burr hole decompression in the emergency department. *Am J Emerg Med*. 1988;6(6):640-6.

An Unusual Case Report of COVID-19 Presenting with Meningitis Symptoms and Shingles

Rebecca Packwood, MD
Gayle Galletta, MD
Joseph Tennyson, MD

University of Massachusetts, Department of Emergency Medicine,
Worcester, Massachusetts

Section Editor: Rick A. McPheeters, DO

Submission history: Submitted April 4, 2020; Revision received April 17, 2020; Accepted April 17, 2020

Electronically published April 29, 2020

Full text available through open access at http://escholarship.org/uc/uciem_cpem

DOI: 10.5811/cpcem.2020.4.47557

Introduction: As severe acute respiratory syndrome coronavirus 2 (SARS-CoV-2) spreads across the globe, physicians face the challenges of a contagious pandemic including which patients to isolate, how to conserve personal protective equipment, and who to test. The current protocol at our hospital is to place anyone with new cough, dyspnea, or fever into airborne and contact precautions and consider them for testing. Unfortunately, the symptomatic presentations of coronavirus disease 2019 (COVID-19) are proving more variable than previously thought.

Case Report: Our case of COVID-19 presented with headache and then progressed to a meningitis-like illness with co-existing shingles rash.

Conclusion: COVID-19 can have a variety of initial presentations that are not the classic respiratory symptoms and fever. These presenting symptoms of COVID-19 can include a meningitis-like illness, as our case report indicates. The wide variety of presentations of COVID-19 may warrant widespread testing to identify cases, protect healthcare workers, and prevent the spread of this pandemic. [Clin Pract Cases Emerg Med. 2020;4(3):316–320.]

Keywords: COVID-19; novel coronavirus; meningitis; shingles; presenting symptoms.

INTRODUCTION

The year 2020 will forever be defined by the spread of severe acute respiratory syndrome coronavirus 2 (SARS-CoV-2, previously 2019-nCoV), which causes coronavirus disease 2019 (COVID-19). COVID-19 can cause a devastating bilateral, multilobar pneumonia, acute respiratory distress syndrome, and death. The first identified cases appeared in Wuhan, China, in December 2019. The World Health Organization declared COVID-19 a public health emergency in February 2020, and the United States (US) currently has the highest burden of cases of any country.⁷

One of the highest priorities for patients and healthcare workers is identifying the presenting symptoms of COVID-19. Studies from China indicate that fever, cough, and dyspnea are among the most common presentations of the disease. Huang et al published one of the first prospective case studies of 41

patients in Wuhan and found that the most common symptoms were fever (98%) and cough (76%).³ The complete range of clinical manifestations included fever, non-productive cough, dyspnea, myalgia, and fatigue.³

Here in the US, patients with “concerning symptoms” are placed in isolation. Our institution’s COVID-19 triage screening includes new cough, new shortness of breath, fever, recent travel, or known COVID-19 contacts. Initially, patients who screened positive for multiple risk factors were placed in a negative pressure room (if available) on airborne and contact precautions. However, as cases increased, the screening criteria expanded to patients who screened positive for any of the screening questions above. While these questions are consistent with the most common presenting symptoms, the range of clinical symptoms of this disease is varied and our screening questions are missing patients. This has

clinical significance for both the patients, who have delayed diagnosis, as well as the healthcare providers who experience unprotected COVID-19 exposures.

CASE REPORT

A 58-year-old-male with history of hyperlipidemia presented to the emergency department (ED) with the chief complaints of headache, abdominal pain, and constipation. The patient started having mid-to-lower abdominal discomfort associated with constipation two days prior to presentation. On the day of presentation, his discomfort worsened and he noted a fever of 100.7 degrees Fahrenheit (F). He also developed a progressively worsening headache located in bilateral occiputs and radiating to his neck. He denied a history of migraines. Patient denied international travel but had traveled to Florida the week prior. No cough, dyspnea, or known COVID-19 contacts were reported.

Vital signs revealed a temporal temperature of 36.6° Celsius (C), heart rate 93 beats per minute (bpm), respiratory rate 18 breaths per minute, blood pressure 130/83 millimeters of mercury (mmHg), and oxygen saturation (SpO₂) 98% on room air. He had clear lung sounds bilaterally, a normal cardiovascular exam, and mild tenderness in the right upper quadrant. He was also tender at the bilateral inserts of the suboccipital muscles. The patient was neurologically intact with a Glasgow Coma Scale of 15, normal cranial nerves, and no motor or sensory deficits. He had full range of motion of his neck and no meningismus.

Laboratory results were remarkable for a normal white blood cell count of 5.3 x 10³ microliters per liter (uL) (reference range 4.3-10.8 x10³/uL) but with lymphopenia of 0.4 x10³/uL (reference range 0.9-3.4 x10³/uL). Lactic acid, basic metabolic panel, hepatic panel, and lipase were within normal limits. Computed tomography (CT) of the abdomen/pelvis showed no acute abnormality but did note minimal bibasilar atelectasis.

The patient's headache initially improved with intravenous (IV) fluids and metoclopramide but later recurred. Due to the location of his headache and tenderness at the suboccipital muscle inserts, a bilateral occipital nerve block with 0.5% bupivacaine was performed with improvement of his pain. Shared decision-making was conducted with the patient and a lumbar puncture (LP) was declined. He was discharged home with a diagnosis of non-specific viral syndrome and strict return precautions.

Three days after his initial presentation, the patient continued to have fevers, headaches, and developed a dermatomal rash. He was started on famciclovir for presumed shingles.

The patient re-presented to an affiliated ED six days after his initial presentation for fever, headache, neck pain, and diffuse abdominal pain. He also noted fatigue, myalgias, dyspnea, congestion, and rash. Vital signs revealed a temperature of 37.1° F, heart rate 94 bpm, respiration rate 16 breaths per minute, blood pressure 96/66 mmHg and SpO₂ 98% on room air. The physical exam was now more concerning for meningitis with neck rigidity

CPC-EM Capsule

What do we already know about this clinical entity?
Severe acute respiratory syndrome coronavirus 2 (SARS-CoV2) which causes coronavirus disease 19 (COVID-19) appeared in Wuhan, China in December, 2019. It reportedly presents with shortness of breath, cough and fever.

What makes this presentation of disease reportable?
Our case report reviews a meningitis-like presentation of COVID-19 including symptoms of headache, meningismus and fever. Due to the unusual presentation, this patient had a delay in diagnosis.

What is the major learning point?
COVID-19 presents with a more varied array of symptoms than previously identified which places patients at risk for delayed diagnosis and caregivers at risk of exposure.

How might this improve emergency medicine practice?
As our testing capability expands, all patients presenting to the emergency department should be placed on precautions and tested in order to improve diagnosis and prevent caregiver exposures.

and pain with neck movement. A vesicular rash along the right ninth and tenth thoracic dermatomes was also noted. The patient was otherwise neurologically intact and his pulmonary exam was normal. Due to the presence of the shingles rash, he was placed on strict airborne and contact precautions for concern of disseminated herpes zoster infection.

An LP was performed due to concern for meningitis and the patient was started on IV acyclovir, vancomycin, and ceftriaxone. The LP revealed an opening pressure of 21 centimeters of water (cm H₂O) (normal range 10-20 cm H₂O), elevated glucose of 84 milligrams per deciliter (mg/dL) (normal range 45-80 mg/dL or greater than 60% of serum glucose), elevated protein of 48 mg/dL (normal less than 45 mg/dl), and one white blood cell (WBC) in both tubes one and four (normal range 0-5 cells/microliter). Infectious disease consult later remarked that there was a low suspicion for meningitis based on his LP. A chest radiograph (CXR) showed subtle, patchy infiltrates in the lung bases (Image 1) suggesting early pneumonia, so the patient's antibiotics were expanded to include IV doxycycline to cover atypical bacteria.

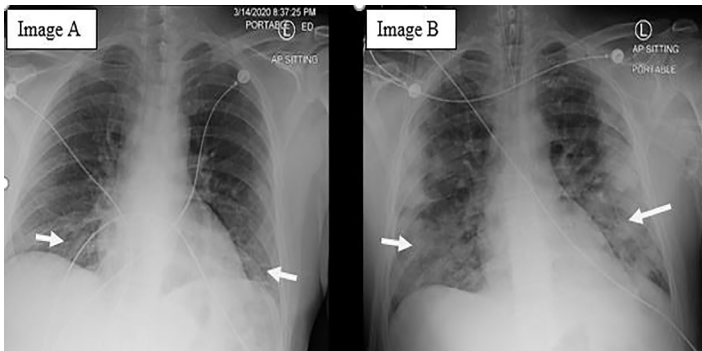


Image 1. A) Portable chest radiograph on presentation to the emergency department, demonstrating subtle, patchy infiltrates visible in the lung bases suggesting early pneumonia (arrows). B) An anterior posterior chest radiograph two days after admission, demonstrating significant interval progression of peripherally located patchy opacities throughout both lungs (arrows) with areas of consolidation at the lung bases and right upper lobe.

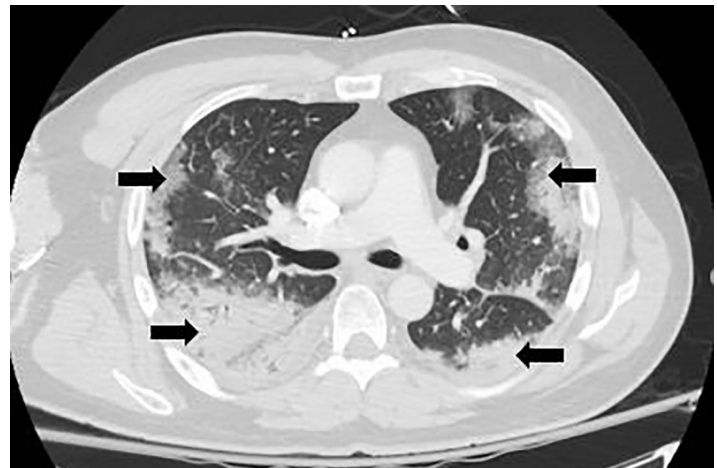


Image 2. Computed tomography of the chest two days after admission demonstrating extensive, bilateral multifocal pneumonia most notable in the lower lobes (arrows).

The patient was admitted to the general medicine floor for observation pending cerebrospinal fluid culture results. On day seven after his initial presentation, precautions were reduced from strict airborne to droplet and contact precautions. He symptomatically improved until the early morning of day eight after his initial presentation, when he started to complain of acute left-sided, pleuritic chest pain and shortness of breath. A rapid response was called. The patient was treated for possible acute coronary syndrome and further evaluated with a CXR and CT-pulmonary embolism protocol. Both the CXR (Image 1) and CT (Image 2) showed a multilobar peripheral pneumonia, which was highly concerning for COVID-19 infection.

Eight days after his initial presentation (day two of hospitalization), the patient was placed on strict airborne, contact, and droplet precautions. His respiratory status continued to deteriorate and he was transferred to the intensive care unit (ICU) on high-flow nasal cannula and required intubation later that day. His COVID-19 test via the Department of Public Health was presumptive positive.

The patient was intubated in the ICU from day two of hospitalization until day 15. During his extensive ICU course, various treatments were trialed including lopinavir/ritonavir, a six-day course of hydroxychloroquine and azithromycin, as well as remdesivir starting hospital day 19. He was also continued on his course of antibiotics.

In a study from Wuhan the average time from onset of first symptoms to dyspnea was five days, to admission was seven days and to acute respiratory distress syndrome was eight days.⁴ This patient was admitted on day nine, decompensated on day 11 and was intubated for a total of 13 days. The patient’s clinical course is summarized in Table 1.

DISCUSSION

This case draws to light the significant COVID-19 exposure risk to both the ED and medical floor staff. This patient had two ED visits as well as two days on the general medicine floor prior to initiation of full airborne and contact precautions due to his atypical symptoms on presentation.

A literature review revealed that while the most common presenting symptoms are fever and cough, there is a dramatic range of symptoms, which can be associated with COVID-19. In a single-center, retrospective study of 54 healthcare workers

Table 1. Clinical course from onset of atypical symptoms until discharge of patient with presumptive coronavirus 19.

Timeline	Event
Day 1	Symptoms including abdominal pain, constipation start. Progresses to include headache, fever.
Day 3	Initial presentation with headache, fever, abdominal pain. Discharged from emergency department.
Day 9	Re-presents with headache, fever, and concern for meningitis. Undergoes lumbar puncture and admitted to general medicine for meningitis-like presentation.
Day 11	Respiratory decompensation with evidence of bilateral multilobar pneumonia on chest radiograph and computed tomography of the chest.
Day 24	Extubated to nasal cannula in the intensive care unit, suffered from encephalopathy.
Day 27	Patient stable and transferred to the floor.
Day 32	Patient discharged home.

who succumbed to COVID-19 in Wuhan, fever was the most common presenting symptom followed by cough.¹ Another retrospective study of 138 patients in Wuhan also confirmed that the most common presenting symptoms were fever, fatigue, and cough.⁴ However, both of these studies also showed significant prevalence of other symptoms such as myalgias, headache, nausea and diarrhea, which are typically not represented in our screening questions. Between 4-13% of patients presented with headache. Notably, no cases described a meningitis-like presentation as our patient specifically demonstrated. In addition, the *New England Journal of Medicine* published a meta-analysis of 1099 patients hospitalized across 552 sites as of January 29, 2020. In terms of clinical symptoms on presentation, only 43.8% of patients had fever on presentation but 88.7% developed fever during hospitalization. A fever was defined as axillary temperature of greater than 99.5° F (37.5° C). Cough was noted in 67.8% and headache in 13.6% of patients. See Table 2 for a full table reviewing symptom prevalence in each of these studies.

Interestingly, Deng et al compared the presenting symptoms of patients with COVID-19 who progressed to severe respiratory illness vs those who remained mildly symptomatic. This retrospective study of 225 patients found statistically significant differences in the presenting clinical symptoms of these patients.⁵ Patients who presented with dyspnea, expectoration, low oxygen saturations, and severe illness were more likely to progress to death.⁵ In addition, the average day of admission for the group who recovered was day seven while the average day of admission for the group who died was day 10.⁵ Patients who presented later in their clinical course appeared

to progress to more severe illness.⁵ While our patient presented later and did progress to severe illness, he survived COVID-19 and was extubated after 13 days.

CONCLUSION

This case report adds to the current literature as there are no other current reports of meningitis-like presentation of COVID-19 or herpes zoster. We would also like to draw attention to the patient's waxing and waning symptoms. As this virus spreads, patients are more likely to present with COVID-19. In addition, clinical studies from South Korea are concerning for an asymptomatic population of ~30% of all virus carriers. The asymptomatic population as well as the varied presentations make a compelling argument for placing every ED patient under precautions on arrival. When and if widespread accurate testing is available, it would be prudent to be able to test all patients, especially those admitted to the hospital in order to decrease healthcare-related exposures. This paradigm would represent a shift in medicine as pre-test probability and testing based on symptoms is critical in our evaluation of patients. However, in a pandemic that is widespread and variable, a different tactic may be indicated.

Documented patient informed consent has been obtained and filed for publication of this case report.

Table 2. Literature review of coronavirus 19 symptom presentation.

	Jiaojiao et al ¹ (n =54)	Easom et al ² (n=68)	Huang et al ³ (n=41)	Wang et al ⁴ (n=138)	Deng et al ⁵ (n = 225)	Guan et al ⁶ Meta-analysis (n=1099)
Fever	66.7%	40%	98%	98.6%	80.5%	43.8% (initial) 88.6% (total)
Cough	31.5%	78%	76%	59.4%	37.7%	67.8%
Sputum production	5.6%	28%	-	26.8%	21.7%	33.7%
Fatigue	6.7%	-	44% includes myalgia	69.6%	25.3% includes myalgia	38.1%
Dyspnea	9.3%	25%	5%	31.2%	44%	18.7%
Chest pain/palpitations	7.4%	13%	-	-	10.6%	-
Myalgia	5.6%	16%	See fatigue	34.8%	See fatigue	14.9%
Anorexia	5.6%	-	-	39.9%	-	-
Diarrhea	-	13%	3%	10.1%	14.6%	3.8%
Headache	-	4%	8%	6.5%	5.7%	13.6%
Sore throat	-	1.9%	-	17.4%	-	-
Hemoptysis	-	-	5%	-	3.1%	0.9%
Nasal congestion	1.9%	29%	-	-	-	4.8%

Address for Correspondence: Rebecca Packwood, MD, University of Massachusetts, Department of Emergency Medicine, 55 Lake Avenue North, Worcester, MA 01655. Email: Rebecca.packwood@umassmemorial.org.

Conflicts of Interest: By the *CPC-EM* article submission agreement, all authors are required to disclose all affiliations, funding sources and financial or management relationships that could be perceived as potential sources of bias. The authors disclosed none.

Copyright: © 2020 Packwood et al. This is an open access article distributed in accordance with the terms of the Creative Commons Attribution ([CC BY 4.0](https://creativecommons.org/licenses/by/4.0/)) License. See: <http://creativecommons.org/licenses/by/4.0/>

REFERENCES

1. Chu J, Yang N, Wei Y, et al. [Ahead of Print]. Clinical characteristics of 54 medical staff with COVID-19: a retrospective study in a single center in Wuhan, China. *J Med Virol*. March 29, 2020.
2. Easom N, Moss P, Barlow G, et al. 68 consecutive patients assessed for COVID-19 infection: experience from a UK regional infectious disease unit. *Influenza Other Respir Viruses*. March 6, 2020.
3. Huang C, Wang Y, Li X, et al. Clinical features of patients infected with 2019 coronavirus in Wuhan, China. *Lancet*. 2020;395(10223):497-506.
4. Wang D, Hu B, Hu C, et al. [Ahead of Print]. Clinical characteristics of 138 hospitalized patients with 2019 novel coronavirus-infected pneumonia in Wuhan, China. *JAMA*. February 7, 2020.
5. Deng Y, Liu W, Liu K, et al. [Ahead of Print]. Clinical characteristics of fatal and recovered cases of coronavirus disease 2019 (COVID-19) in Wuhan, China: a retrospective study. *Chin Med J*. March 20, 2020.
6. Guan W, Ni Y, Hu Y, et al. [Ahead of Print]. Clinical characteristics of coronavirus disease 2019 in China. *N Engl J Med*. February 28, 2020.
7. World Health Organization. Coronavirus disease 2019 (COVID-19) Situation Report 71. 2020. Available at: https://www.who.int/docs/default-source/coronaviruse/situation-reports/20200331-sitrep-71-covid-19.pdf?sfvrsn=4360e92b_8. Accessed April 1, 2020.

A Case Report of Acute Transverse Myelitis Following Novel Coronavirus Infection

Deesha Sarma, MD
Leslie A. Bilello, MD

Harvard Medical School, Beth Israel Deaconess Medical Center, Department of
Emergency Medicine, Boston, Massachusetts

Section Editor: Anna McFarlin, MD

Submission history: Submitted April 28, 2020; Revision received May 5, 2020; Accepted May 6, 2020

Electronically published May 12, 2020

Full text available through open access at http://escholarship.org/uc/uciem_cpem

DOI: 10.5811/cpcem.2020.5.47937

Introduction: During the coronavirus disease 2019 (COVID-19) pandemic, emergency providers are not only seeing an increasing number of patients with COVID-19 infections, but also associated complications and sequelae of this viral illness.

Case Report: We present the case of a 28-year-old female patient who presented after a confirmed COVID-19 infection with lower back pain, bilateral symmetric upper and lower extremity numbness, and urinary retention. The patient was diagnosed with acute transverse myelitis. She required intravenous corticosteroids and plasma exchange with significant improvement in symptoms and minimal residual effects.

Conclusion: This case illustrates the importance of prompt recognition and treatment of sequelae of COVID-19 infections. [Clin Pract Cases Emerg Med. 2020;4(3):321–323.]

Keywords: COVID-19; transverse myelitis; autoimmune; coronavirus.

INTRODUCTION

The novel coronavirus pandemic has resulted in significant mortality and morbidity, with almost two million cases and over 100,000 deaths worldwide as of mid-April 2020.¹ Coronavirus disease 2019 (COVID-19), the illness caused by the severe acute respiratory syndrome coronavirus 2 (SARS-CoV-2), presents similarly to other viral respiratory illnesses with common symptoms including fever, cough, fatigue, myalgias, and diarrhea. Some patients develop respiratory distress requiring supplemental oxygen or ventilator support, while others have mild cases without complications. Given the recent and rapidly progressing nature of the pandemic, exact statistics are unknown, although estimates suggest that 80% of patients experience mild illness.² Less appreciated still are the complications, sequelae, and long-term effects of COVID-19. We present a case of acute transverse myelitis following COVID-19 infection in a young and otherwise healthy patient.

CASE REPORT

A 28-year-old female with a history of hypothyroidism on levothyroxine developed symptoms of productive cough, low-

grade temperatures, low back pain, myalgias, and rhinorrhea during the novel coronavirus pandemic. She tested positive for COVID-19 via an at-home swab ordered by her primary doctor. Her upper respiratory symptoms resolved over the next week, but her lumbosacral back pain persisted and worsened, although without radiation. In addition, she developed paresthesias in her lower extremities, which progressed to total loss of sensation and with ascension of symptoms up to her mid-chest below the nipple line and bilateral upper extremities, as well as numbness to the tip of her tongue. She also reported approximately 48 hours of urinary retention as well as nausea and vomiting. She did not have any headaches, dysarthria or dysphagia, vision changes, or dyspnea. She was admitted to a large, academic, tertiary care center in Denmark.

The patient's neurologic exam was notable for symmetrically decreased sensation below the fifth thoracic vertebra level but preserved two-point discrimination and lower-extremity motor strength. She experienced decreased proprioception and four out of five strength in bilateral upper extremities with intact reflexes throughout. Lhermitte's sign (electric shock-like sensation down the back triggered by

bending the head forward) was positive and she had a wide-based gait. She retained 1.4 liters (L) of urine in her bladder, which was relieved after Foley catheter insertion. Lumbar puncture showed 125/per microliter (μl) mononuclear cells (laboratory reference range 0-5/ μl); 0.6 grams per liter (g/L) protein (laboratory reference range 0.15 to 0.6 g/L); normal glucose (laboratory reference range 45-80 milligram per deciliter); negative antibodies; and gram stain and culture negative for infection. Magnetic resonance imaging (MRI) with and without contrast of the cervical, thoracic, and lumbar spine showed widespread elongated signal changes throughout the spinal cord to the conus medullaris and involving the medulla, with no disc pathology or spinal canal narrowing. These findings were consistent with longitudinally extensive acute transverse myelitis (given involvement of more than three spinal cord segments), thought to be reactive in the setting of recent COVID-19 infection. The patient was started on prednisolone and received two plasma exchange treatments with rapid improvement of symptoms. After eight days in the hospital, she was discharged on a steroid taper with improved symptoms including normal urinary function. Her residual symptoms included decreased sensation in the lower extremities up to the mid-thighs bilaterally.

DISCUSSION

Transverse myelitis is a rare, acquired neurologic condition characterized by focal inflammation and injury of the spinal cord. There is a wide array of potential etiologies. Transverse myelitis is a recognized complication of viral or bacterial infections, although it can also be the first sign of neurologic conditions such as multiple sclerosis or neuromyelitis optica or associated with systemic autoimmune diseases such as lupus or sarcoidosis.³ Despite extensive workup, as many as 60% of cases may remain idiopathic, meaning the exact pathophysiology of the disease is unknown and varies based on etiology.⁴ When related to an infectious cause, it is often attributed to an autoimmune-mediated response as opposed to direct invasion and injury of the spinal cord.⁵ In these cases, intravenous corticosteroids are started immediately to suppress the inflammatory response and plasma exchange is a potential treatment option to remove auto-antibodies.⁶

This patient presented with the hallmark symptoms of transverse myelitis including bilateral symmetric sensory changes and extremity weakness, lower back pain, and bladder dysfunction, and had classic contrast-enhancing lesions on MRI. Given the onset of these findings in the setting of a confirmed COVID-19 case, as well as her marked improvement with steroids and plasma exchange, it is likely that this was an autoimmune-mediated response to the novel coronavirus. Furthermore, she had no visual symptoms such as eye pain or vision loss that are classically seen in multiple sclerosis or neuromyelitis optica, nor the immunoglobulin G auto-antibodies or oligoclonal bands that are the immunological hallmarks of these diseases.⁷ Likewise her anti-nuclear antibody test, very sensitive for autoimmune

CPC-EM Capsule

What do we already know about this clinical entity?

Transverse myelitis is a rare neurological condition causing inflammation of the spinal cord and is believed to develop via autoimmune mechanisms.

What makes this presentation of disease reportable?

Transverse myelitis is a known sequelae of viral illnesses such as influenza, but has heretofore not been associated with novel coronavirus infections.

What is the major learning point?

Patients can develop serious complications with lasting neurological effects even after initial recovery from novel coronavirus infection.

How might this improve emergency medicine practice?

Emergency providers can prevent significant morbidity by recognizing post-infectious complications of novel coronavirus, including transverse myelitis.

disorders including lupus, was negative, nor did she have any other system involvement such as skin rash or nodules, cardiac arrhythmias, or arthritis, which are also seen with conditions like lupus or sarcoidosis.⁸

CONCLUSION

As the number of COVID-19 infections continues to rise, more patients are presenting to the emergency department with novel coronavirus-related symptoms and associated complications. Healthcare workers, especially emergency providers on the frontlines, treat these affected patients and bear witness to their different presentations and clinical courses. This case report emphasizes the importance of remaining cognizant of the atypical and less-prevalent sequelae of viral infections in patients with recent or concurrent COVID-19 infections, as prompt recognition and management are important to prevent significant morbidity. It also highlights that young and otherwise healthy patients who have seemingly recovered from COVID-19 infection can still develop serious complications. These are important takeaways

for emergency providers in the midst of providing care during this global pandemic.

The authors attest that their institution requires neither Institutional Review Board approval, nor patient consent for publication of this case report. Documentation on file.

Address for Correspondence: Deesha Sarma, MD, Beth Israel Deaconess Medical Center, Department of Emergency Medicine, 1 Deaconess Road, Boston, MA 02215. Email: dsarma@bidmc.harvard.edu.

Conflicts of Interest: By the CPC-EM article submission agreement, all authors are required to disclose all affiliations, funding sources and financial or management relationships that could be perceived as potential sources of bias. The authors disclosed none.

Copyright: © 2020 Sarma et al. This is an open access article distributed in accordance with the terms of the Creative Commons Attribution (CC BY 4.0) License. See: <http://creativecommons.org/licenses/by/4.0/>

REFERENCES

1. World Health Organization. Coronavirus 2019 disease (COVID-19) situation report - 85. 2020. Available at: https://www.who.int/docs/default-source/coronaviruse/situation-reports/20200414-sitrep-85-covid-19.pdf?sfvrsn=7b8629bb_4. Accessed April 23, 2020.
2. World Health Organization. Coronavirus 2019 disease (COVID-19) situation report - 41. 2020. Available at https://www.who.int/docs/default-source/coronaviruse/situation-reports/20200301-sitrep-41-covid-19.pdf?sfvrsn=6768306d_2. Accessed April 23, 2020.
3. Jacob A and Weinshenker BG. An approach to the diagnosis of acute transverse myelitis. *Semin Neurol.* 2008;28(1):105-20.
4. Sui V, Seals M, Pope B, et al. Idiopathic transverse myelitis: observations from 60 clinical cases at UAB. *Neurology.* 2019;92(15):P1.2-0.77.
5. Kerr DA and Ayetey H. Immunopathogenesis of acute transverse myelitis. *Curr Opin Neurol.* 2002;15(3):339-47.
6. West TW. Transverse myelitis - a review of the presentation, diagnosis, and initial management. *Discov Med.* 2013;16(88):167-77.
7. Jarius S and Wildemann B. The history of neuromyelitis optica. *J Neuroinflammation.* 2013;10(8):1-12.
8. Loke WSJ, Herbert C, Thomas PS. Sarcoidosis: immunopathogenesis and immunological markers. *Int J Chronic Dis.* 2013;2013:1-14.

A Case Report of Coronavirus Disease 2019 Presenting with Tremors and Gait Disturbance

Sharon Klein, BA*
Frederick Davis, DO, MPH†
Adam Berman, MD, MS*†
Shruti Koti, BA*
John D'Angelo, MD†
Nancy Kwon, MD, MPA*†

*Donald and Barbara Zucker School of Medicine at Hofstra/Northwell, Department of Emergency Medicine, Hempstead, New York
†Long Island Jewish Medical Center, Department of Emergency Medicine, New Hyde Park, New York

Section Editor: Rick A. McPheeters, DO

Submission history: Submitted May 4, 2020; Revision received May 6, 2020; Accepted May 11, 2020

Electronically published May 20, 2020

Full text available through open access at http://escholarship.org/uc/uciem_cpem

DOI: 10.5811/cpem.2020.5.48023

Introduction: Neurologic symptoms present as significant complications of coronavirus disease 2019 (COVID-19) infection. This report describes a novel manifestation of tremors triggered by severe acute respiratory syndrome coronavirus 2 infection.

Case Presentation: We describe a case of a 46-year-old man with COVID-19 infection complicated by a bilateral intention tremor and wide-based gait. Although neurological manifestations have been reported related to COVID-19, tremulousness has not yet been described.

Conclusion: Considering the evolving diversity of neurologic manifestations in this infection, emergency physicians should be vigilant of possible COVID-19 infection in patients presenting with unexplained neurologic symptoms. [Clin Pract Cases Emerg Med. 2020;4(3):324–326.]

Keywords: COVID-19; neurology; tremor.

INTRODUCTION

Coronavirus disease 2019 (COVID-19) was first reported in December 2019, originating from Wuhan, China, as an aggressive viral pneumonia with poorly understood pathophysiology. As the caseload has grown exponentially across the United States, we are seeing a variety of clinical presentations affecting a multitude of organ systems. Emergency providers need to be able to recognize these presentations as possible sequelae of COVID-19 infection to triage and isolate patients during evaluation. Neurologic symptoms present as significant complications of COVID-19 infection. This report describes a novel manifestation of tremors triggered by severe acute respiratory syndrome coronavirus 2 (SARS-CoV-2) infection.

CASE REPORT

A 46-year-old male was brought to the emergency department (ED) with complaints of two weeks of cough,

fever, generalized myalgias, sore throat, with progressively worsening of shortness of breath, and night sweats. He was initially treated with amoxicillin-clavulanate for pneumonia for seven days as prescribed by his primary care physician. On day eight he began to have tremors without fevers, which resulted in difficulty ambulating. He denied any nausea, vomiting, diarrhea, constipation, chest or abdominal pain. He had no other relevant medical history, denied taking any other medications, and denied history of alcohol use. Before going into self-quarantine he noted that some of his co-workers were having flu-like symptoms but he was unaware whether they had been tested for COVID-19.

On physical examination in the ED his vital signs were blood pressure 130/87 millimeters of mercury, temperature 36.6° Celsius (97.9° Fahrenheit), pulse rate 108 beats per minute, respiratory rate 22 breaths per minute, and oxygenating at 96% on room air. On respiratory exam, he

had clear and equal breath sounds bilaterally. Neurologic exam revealed intact mental status that was oriented to self, date, and place. He had no dysarthria, aphasia, or neglect. His cranial nerves exam was significant for saccadic intrusions with smooth pursuit. A generalized tremor was noted when the patient was lying down, which worsened with movement, and there was a postural tremor in all extremities. Heel-to-shin exam was non-dystaxic although tremulous, and there was a bilateral intention tremor. On motor exam, he had normal tone and five out of five strength of all muscle groups in the upper and lower extremities. He was noted to have a wide-based gait with unsteadiness, but there was no dysmetria, pronator drift or truncal ataxia. His sensation was intact to light touch. No other abnormalities were noted on physical exam.

In the ED he was evaluated by neurology due to the constant tremors. Computed tomography (CT) of the head and CT angiogram did not reveal any significant findings, toxicology report came back negative, and thyroid-stimulating hormone, thiamine, and folate levels were normal. Chest radiograph showed clear lungs without any focal consolidation. Magnetic resonance imaging (MRI) done during his hospital stay showed hyperintense foci in the bifrontal subcortical and deep white matter on scattered T2-weighted, fluid-attenuated inversion recovery. These findings likely represent sequelae of microangiopathic ischemic changes. His hospital course was uncomplicated, and respiratory status improved with supportive measures. Final impression by neurology was that these were essential tremors, and the decision was made to treat with propranolol from which patient reported some mild improvement of symptoms.

DISCUSSION

Virology studies of SARS-CoV-2 and Middle Eastern respiratory syndrome coronavirus (MERS-CoV) have shown their ability to enter the brain and spread to specific areas such as the thalamus and brainstem, although the route of entry has yet to be elucidated.¹ Given this, it is likely that SARS-CoV-2 has similar neuro-invasive potential.¹ Multiple neurologic manifestations have been reported among patients hospitalized with COVID-19. In a case series of 214 patients with COVID-19 in Wuhan, China, neurological symptoms were present in 36.4% of patients, particularly with a preference for those with more severe infection as according to their respiratory status. The most common nervous system complications were dizziness and headache among those with central nervous system manifestations, and taste and smell impairment in those with peripheral nervous system impairment.² This case to our knowledge is the first case of tremors described in the COVID-19 pandemic. Similar neurologic manifestations, with postural and action tremors, have been

CPC-EM Capsule

What do we already know about this clinical entity?

Coronavirus disease 2019 (COVID-19) typically presents with symptoms of fever, cough, fatigue, and myalgias, but can rapidly progress to involve other organ systems.

What makes this presentation of disease reportable?

Although postural and action tremors have been seen with other viral infections, this is the first known presentation linking these symptoms with COVID-19.

What is the major learning point?

COVID-19 can present with various neurologic manifestations such as headache, dizziness, taste and smell impairments, ataxia, seizures and tremors.

How might this improve emergency medicine practice?

Unexplained tremors and gait abnormalities can be a rare presentation of COVID-19 infection, and should be suspected in patients presenting with viral syndrome.

reported with other viral infections. A case study involving a hepatitis C virus-positive patient reported these isolated symptoms despite normal MRI findings.³ In pediatric patients gait unsteadiness has been attributed to acute cerebellar ataxia secondary to numerous viral infections ranging from varicella to coxsackievirus.⁴

CONCLUSION

Considering the prevalence of neurologic manifestations occurring in this illness, physicians should consider SARS CoV-2 infection in patients presenting with unexplained neurologic symptoms to avoid delayed diagnosis and prevention of transmission.

The authors attest that their institution requires neither Institutional Review Board approval, nor patient consent for publication of this case report. Documentation on file.

Address for Correspondence: Nancy Kwon, MD, MPA, Long Island Jewish Medical Center, Department of Emergency Medicine, 270-05 76th Avenue, New Hyde Park, NY 11040. Email: nkwon@northwell.edu.

Conflicts of Interest: By the *CPC-EM* article submission agreement, all authors are required to disclose all affiliations, funding sources and financial or management relationships that could be perceived as potential sources of bias. The authors disclosed none.

Copyright: © 2020 Klein et al. This is an open access article distributed in accordance with the terms of the Creative Commons Attribution ([CC BY 4.0](https://creativecommons.org/licenses/by/4.0/)) License. See: <http://creativecommons.org/licenses/by/4.0/>

REFERENCES

1. Li YC, Bai WZ, Hashikawa T. [Ahead of Print]. The neuroinvasive potential of SARS-CoV2 may be at least partially responsible for the respiratory failure of COVID-19 patients. *J Med Virol*. February 27, 2020.
2. Mao L, Jin H, Wang M, et al. [Ahead of Print]. Neurologic manifestations of hospitalized patients with coronavirus disease 2019 in Wuhan, China. *JAMA Neurol*. April 10, 2020.
3. Orsucci D, Mancuso M, Ali G, et al. Inflammatory myopathy in a patient with postural and kinetic tremor. *Neurol Sci*. 2011;32(6):1175-8.
4. Salas AA and Nava A. Acute cerebellar ataxia in childhood: initial approach in the emergency department. *Emerg Med J*. 2010;27(12):956-7.

Optimizing Non-invasive Oxygenation for COVID-19 Patients Presenting to the Emergency Department with Acute Respiratory Distress: A Case Report

David Zodda, MD, FACEP*†
Allyson Hanson, DO†
Alyssa Berns, DO†

*Hackensack University Medical Center School of Medicine at Seton Hall, Nutley, New Jersey
†Hackensack University Medical Center, Department of Emergency Medicine, Hackensack, New Jersey

Section Editor: Rick A. McPheeters, DO

Submission history: Submitted May 28, 2020; Revision received June 11, 2020; Accepted June 11, 2020

Electronically published June 22, 2020

Full text available through open access at http://escholarship.org/uc/uciem_cpem

DOI: 10.5811/cpcem.2020.6.48456

Introduction: The novel coronavirus (COVID-19) pandemic has led to an increase in the number of patients presenting to the emergency department (ED) with severe hypoxia and acute respiratory distress. With limited resources and ventilators available, emergency physicians working at a hospital within the epicenter of the United States outbreak developed a stepwise, non-invasive oxygenation strategy for treating COVID-19 patients presenting with severe hypoxia and acute respiratory distress.

Case Report: A 72-year-old male suspected of having the COVID-19 virus presented to the ED with shortness of breath. He was found to be severely tachypneic, febrile, with rales in all lung fields. His initial oxygen saturation registered at SpO₂ (blood oxygenation saturation) 55% on room air. Emergency physicians employed a novel non-invasive oxygenation strategy using a nasal cannula, non-rebreather, and self-proning. This approach led to a reversal of the patient's respiratory distress and hypoxia (SpO₂ 88-95%) for the following 24 hours. This non-invasive intervention allowed providers time to obtain and initiate high-flow nasal cannula and discuss end-of-life wishes with the patient and his family.

Conclusion: Our case highlights a stepwise, organized approach to providing non-invasive oxygenation for COVID-19 patients presenting with severe hypoxia and acute respiratory distress. This approach primarily employs resources and equipment that are readily available to healthcare providers around the world. The intent of this strategy is to provide conventional alternatives to aid in the initial airway management of confirmed or suspected COVID-19 patients. [Clin Pract Cases Emerg Med. 2020;4(3):327–331.]

Keywords: COVID-19; Hypoxia; Non-invasive; Oxygenation; Airway.

INTRODUCTION

The novel coronavirus disease (COVID-19) pandemic, caused by the highly contagious severe acute respiratory syndrome-coronavirus-2 (SARS-CoV-2), is currently threatening the global human population.¹ We describe the case of a 72-year-old male presenting to the emergency department (ED) with acute respiratory distress. The case

described took place during the 2020 COVID-19 pandemic and occurred at an academic medical center with one of the highest rates of COVID-19 infections in the United States.

The COVID-19 pandemic has led to an increase in the number of patients presenting to the hospital with severe hypoxia and acute respiratory distress. We employed a novel non-invasive oxygenation strategy using a nasal cannula

(NC), non-rebreather (NRB), and self-proning. This technique led to an improvement in the patient's hypoxia and a 24-hour reversal in his acute respiratory failure, which allowed us time to obtain and initiate high-flow NC and discuss end-of-life wishes with the patient and his family.

Our case highlights a stepwise, organized approach to providing non-invasive oxygenation for hypoxic patients in acute respiratory distress. It was developed during the initial days of the COVID-19 pandemic at a frontline hospital at the epicenter of the US outbreak. This approach employs resources and equipment readily available to healthcare providers around the world. The intent of this strategy is to provide conventional alternatives to aid in the initial management of confirmed or suspected COVID-19 patients with acute hypoxic respiratory failure.

CASE REPORT

A 72-year-old male presented to the ED for shortness of breath that had progressed over the prior seven days. He was found to be tachypneic, febrile, and with rales in all lung fields. His blood pressure and heart rate were within acceptable limits. He was awake, alert and cooperative. However, his oxygen saturation upon presentation to the ED was abnormal and initially registered at 55% on room air. The patient was placed on a cardiac monitor with pulse oximetry, and we obtained a chest radiograph revealing multilobar pneumonia (Image).

We employed a non-invasive oxygenation strategy using a NC at 6 liters per minute (LPM) and a NRB mask at 15 LPM. In addition, the patient was assisted to the prone position on the stretcher. Within five minutes, his mental status and work of breathing improved, his oxygen saturation improved to 95%, and he remained between 88-95% for the next 16 hours. Approximately 16 hours after arrival, the patient became

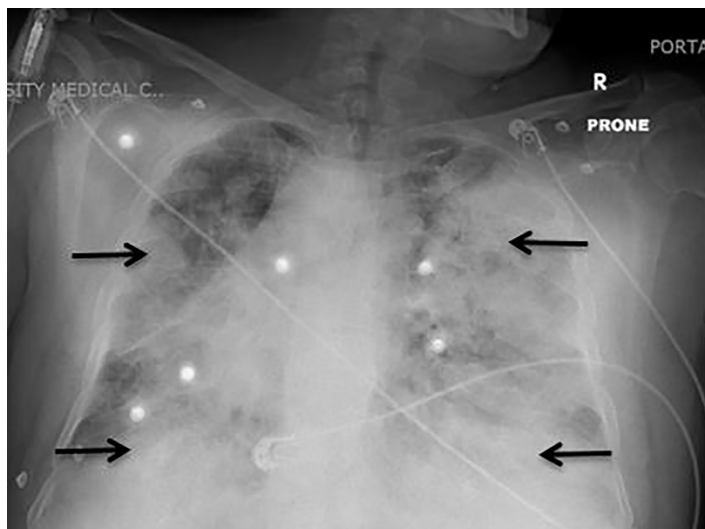


Image. Chest radiograph (prone position) demonstrating bilateral patchy opacities, most prominently at periphery of the lung concerning for multifocal pneumonia (arrow).

CPC-EM Capsule

What do we already know about this clinical entity?

A common presentation of symptomatic patients with coronavirus disease 2019 (COVID-19) is severe hypoxia and respiratory distress often requiring emergent intubation in the emergency department (ED) setting.

What makes this presentation of disease reportable?

We present a COVID-19 patient presenting to the ED with profound hypoxia and respiratory distress and rather than intubate, we employed a novel stepwise approach to non-invasive oxygenation.

What is the major learning point?

A stepwise approach to non-invasive oxygenation of COVID-19 patients can delay emergent intubation, allow time for additional ventilatory treatments to become available, and provide time for emergency providers to clarify goals of care with patients and their family.

How might this improve emergency medicine practice?

Resuscitating the hypoxic COVID-19 patient is uniquely challenging and necessitates a stepwise approach for both provider safety and patient care.

hypoxic with oxygen saturations dipping below 88%. The NC was removed and a high-flow nasal cannula (HFNC) 60 LPM was added. Using this strategy of a HFNC, NRB, and self-proning, the patient remained alert and his oxygen saturation remained between 88-95% for a total of 24 hours.

Eventually, his mental status waned, his work of breathing became labored, and his oxygen saturation further deteriorated. Discussions with the patient and his family regarding advance directives revealed that his wishes were to be full code. He was admitted to the intensive care unit (ICU) and soon placed on a ventilator. Ultimately, our non-invasive strategy did not reverse this patient's respiratory failure. However, it did allow us time (24 hours) to stabilize him, procure additional resuscitative resources, and discuss advance directives with him and his family.

DISCUSSION

We present a stepwise approach to providing non-invasive oxygenation to confirmed or suspected COVID-19 patients presenting to the ED with hypoxia and acute respiratory distress. This strategy was developed during the initial days of

the COVID-19 pandemic at a frontline hospital at the epicenter of the US outbreak. As in the case of our patient, this approach can be used to improve oxygen saturation, work of breathing, and may reduce the need for early mechanical ventilation.

Our pathway does not include non-invasive positive pressure ventilation (NIPPV). We did not have masks or helmets available that would have sufficiently protected staff from aerosolization of the COVID-19 virus during NIPPV. In addition, due to limited resources, we needed to repurpose all of our bi-level positive airway pressure machines into ventilators.

Step 1: Patient and Provider Safety

Patients presenting to the ED during the COVID-19 pandemic with symptoms such as fever, dyspnea, and hypoxia should be suspected of having the COVID-19 virus.² These patients should be provided with a surgical mask and placed in a single-occupancy, negative pressure room with a closed door.³

Contact and droplet precautions should be initiated for all patients suspected of having COVID-19, and providers should wear personal protective equipment (PPE) that includes a gown, gloves, eye protection, and a respirator (e.g., an N95 respirator).⁴ Healthcare providers should pay special attention to the appropriate sequence of putting on (donning) and taking off (doffing) of PPE to avoid contamination.

Step 2: Initial Assessment

Patients presenting to the ED with confirmed or suspected COVID-19 should receive an initial assessment that includes evaluation of their airway, breathing, and circulation. The patient should be placed on a cardiac monitor to evaluate blood pressure, heart rate, and breaths per minute. Continuous pulse oximetry should be obtained. However, the presence of hypoxemia alone should not trigger intubation, as hypoxemia is often remarkably well tolerated in patients with COVID-19.⁵

Patients with COVID-19 differ in some ways from other patients with acute respiratory failure. On presentation to the ED, most have significant hypoxia without other organ failures and without hypercapnia. The interventions described here as well as the inclusion/exclusion criteria (Figure) are built upon recommendations from the Intensive Care Society COVID-19 Guidance and Resource Library and designed specifically for patients with hypoxic respiratory failure.⁶

Supplemental oxygen is the mainstay of treatment of hypoxic patients, and for the majority of patients should begin with non-invasive maneuvers. If initial resuscitation strategies fail, if the patient becomes altered or shows continuing signs of respiratory failure, then he or she should be placed on mechanical ventilation. The remainder of this report describes our stepwise, non-invasive oxygen strategy for hypoxic patients with suspected or confirmed COVID-19.

Step 3: Nasal Cannula

Initiate non-invasive oxygenation using a NC at 6 LPM. At room air, the air we breathe consists of 21% oxygen. A NC at 6

Inclusion criteria:

- Acute hypoxic respiratory failure with saturation less than 92% on room air
- Able to communicate and follow instructions
- Able to change position independently

Exclusion criteria:

- Altered mental status
- Hemodynamic instability (dysrhythmia or systolic blood pressure <90 mmHg)
- Recent abdominal, chest or facial surgery
- Relative contraindications
 - Morbid obesity
 - Pregnancy (2nd / 3rd trimesters)
 - Anticipated anatomically difficult airway

Figure. Non-Invasive Oxygenation Strategy for COVID-19 Patients with Acute Respiratory Distress. Inclusion and exclusion criteria based upon the recommendations from the Intensive Care Society (United Kingdom) and designed specifically for patients with hypoxic respiratory failure.
mmHg, millimeters of mercury.

LPM equates to fraction of inspired oxygen (FIO₂) of 44%.⁷ At rates greater than 6 LPM the laminar flow becomes extremely turbulent and oxygen being delivered at that rate is only as effective as 6 LPM. The dispersal of exhaled air at this rate has been measured to be 40 centimeters (cm), roughly 1.5 feet.⁸ This can be significantly higher in a patient in respiratory distress. We recommend placing a surgical mask over the NC as it has been shown to significantly reduce the dispersion distance.⁹

Step 4: Nasal Cannula + Non-Rebreather

Should the patient continue to remain hypoxic or should their work of breathing increase as demonstrated by tachypnea, accessory muscle use, or change in mental status, the next step is to employ a NRB mask over the NC. The reservoir bag on the NRB should be at least two-thirds inflated before applying the mask to the patient. This will help to increase the amount of consistent FIO₂ delivered. Oxygen via the NRB should be delivered at a rate of 15 LPM constituting a FIO₂ of 70-80%.¹⁰

Air leak should be monitored and maintained, as these patients often have a minute ventilation far in excess of the 15 LPM from the NRB and the 6LPM of the NC combined; during respiratory distress, patients have a flow rate that varies widely between 30-120 LPM.¹¹

Step 5: Nasal Cannula + Non-Rebreather + Self-Prone

If the patient remains hypoxic or their work of breathing increases despite the NC and NRB, the next step in our non-invasive oxygenation strategy includes NC + NRB + self-prone. Prone patients has been shown to improve oxygenation, reduce respiratory effort, and decrease the need for intubation.¹²

Patients should rotate every 30-120 minutes from prone position to left-lateral decubitus, right-lateral decubitus, and

upright sitting positions. A recent observational cohort study revealed that patients presenting to the ED during the COVID-19 pandemic with moderate to severe hypoxemia, peripheral oxygen saturation (SpO₂) 80% at triage demonstrated an improved SpO₂ (94%) after five minutes of self-proning.¹³ In a case series of 15 awake patients with hypoxic respiratory failure, a series of short, two to four hour cycles of proning significantly improved oxygenation and was well tolerated by most patients.¹⁴

Step 6: High-Flow Nasal Cannula + Non-Rebreather + Self-Proning

The next step in our non-invasive oxygenation strategy includes employing a HFNC in conjunction with a NRB and self-proning. HFNC warms oxygen to 37° Celsius creating 100% humidity, and when set to high flow rates 60 LPM can achieve FIO₂ of nearly 100% and add about three to five cm H₂O of positive-end expiratory pressure.¹⁰ A recent meta-analysis evaluating HFNC for COVID-19 patients with acute respiratory failure found a reduction in intubation, ICU admission, and mortality.¹⁵ Our strategy includes a NRB over the HFNC to assist in entrainment of O₂ via oral inhalation. We also recommend self-proning of patients to improve O₂ delivery and reduce respiratory effort.

CONCLUSION

The novel coronavirus COVID-19 triggered a global pandemic leading to the infection of millions of individuals worldwide. Critically ill patients infected with COVID-19 often present to the ED with hypoxia and acute respiratory distress. The sheer scope and size of this pandemic has led to limited ventilator supplies and resources. Speaking with family members and determining wishes in patients who may not be good candidates for invasive ventilation is more time-consuming than ever before as most hospitals are limiting or banning visitors, and any procedure that can delay or prevent intubation has significant value.

With limited data and supplies during the COVID 19 pandemic, novel strategies have been stressed as a bridge therapy for the patients with hypoxemia and respiratory distress. Our case report describes a stepwise approach to providing non-invasive oxygenation for confirmed or suspected COVID-19 patients presenting to the ED with hypoxia and acute respiratory distress.

This strategy was developed during the initial days of the COVID-19 pandemic at a frontline hospital at the epicenter of the US outbreak. As in the case of our patient, this approach can be used to improve oxygen saturation, work of breathing, and reduce the need for early mechanical ventilation. Further evidence is needed to support causality and determine the effect this non-invasive has on disease severity and mortality.

The authors attest that their institution requires neither Institutional Review Board approval, nor patient consent for publication of this case report. Documentation on file.

Address for Correspondence: David Zodda, MD, Hackensack University Medical Center, Department of Emergency Medicine, 30 Prospect Avenue, Hackensack, NJ 07601. Email: David.Zodda@HackensackMeridian.org.

Conflicts of Interest: By the CPC-EM article submission agreement, all authors are required to disclose all affiliations, funding sources and financial or management relationships that could be perceived as potential sources of bias. The authors disclosed none.

Copyright: © 2020 Zodda et al. This is an open access article distributed in accordance with the terms of the Creative Commons Attribution (CC BY 4.0) License. See: <http://creativecommons.org/licenses/by/4.0/>

REFERENCES

1. Fauci AS, Lane HC, Redfield RR. Covid-19: navigating the uncharted. *N Engl J Med.* 2020;382(13):1268-9.
2. Wu Z and McGoogan JM. [Ahead of Print]. Characteristics of and important lessons from the coronavirus disease 2019 (COVID-19) outbreak in China: summary of a report of 72,314 cases from the Chinese Center for Disease Control and Prevention. *JAMA.* February 24, 2020.
3. Centers for Disease Control and Prevention. Interim Infection Prevention and Control Recommendations for Patients with Confirmed 2019 Novel Coronavirus (2019-nCoV) or Patients Under Investigation for 2019-nCoV in Healthcare Settings. 2020. Available at: <https://www.cdc.gov/coronavirus/2019-nCoV/hcp/infection-control.html>. Accessed April 21, 2020.
4. World Health Organization. Infection prevention and control during health care when novel coronavirus (nCoV) infection is suspected. Available at: [https://www.who.int/publications-detail/infection-prevention-and-control-during-health-care-when-novel-coronavirus-\(ncov\)-infection-is-suspected-20200125](https://www.who.int/publications-detail/infection-prevention-and-control-during-health-care-when-novel-coronavirus-(ncov)-infection-is-suspected-20200125). Accessed April 21, 2020.
5. Dondorp AM, Hayat M, Diptesh Aryal D, et al. Respiratory support in COVID-19 patients, with a focus on resource-limited settings. *Am J Trop Med Hyg.* 2020;102(6):1191-7.
6. Intensive Care Society. Intensive Care Society guidance for prone positioning for the conscious COVID patient 2020. 2020. Available at: <https://static1.squarespace.com/static/5e6613a1dc75b87df82b78e1/t/5e99e7f60755047b87934d6e/1587144697447/2020-04-12+Guidance+for+conscious+proning.pdf>. Accessed April 21, 2020.
7. O'Reilly NA, Kelly PT, Stanton J, et al. Measurement of oxygen concentration delivered via nasal cannulae by tracheal sampling. *Respirology.* 2014;19(4):538-43.
8. Whittle JS, Pavlov I, Sacchetti AD, et al. Respiratory support for adult patients with COVID-19. *JACEP Open.* 2020;1:95-101.
9. Kluge S, Janssens U, Welte T, et al. "Recommendations for critically ill patients with COVID 19." *Med Klin Intensivmed Notfmed.* 2020;115:175-7.
10. Garcia JA, Gardner D, Vines D, et al. The oxygen concentrations

- delivered by different oxygen therapy systems. *Chest*. 2005;128(4):389S-90.
11. Nishimura M. High-flow nasal cannula oxygen therapy in adults: physiological benefits, indication, clinical benefits and adverse effects. *Respir Care*. 2016;61(4): 529-41.
 12. Ding L, Wang L, Ma W, et al. Efficacy and safety of early prone positioning combined with HFNC or NIV in moderate to severe ARDS: a multi-center prospective cohort study. *Crit Care*. 2020;24(1):28.
 13. Caputo ND, Strayer RJ, Levitan R. Early self-proning in awake, non-intubated patients in the emergency department: a single ED's experience during the COVID-19 pandemic. *Acad Emerg Med*. 2020;27(5):375-8.
 14. Scaravilli V, Grasselli G, Castagna L, et al. Prone positioning improves oxygenation in spontaneously breathing nonintubated patients with hypoxemic acute respiratory failure: a retrospective study. *J Crit Care*. 2015;30(6):1390-4.
 15. Rochweg B, Granton D, Wang DX, et al. High-flow nasal cannula compared with conventional oxygen therapy for acute hypoxemic respiratory failure: a systematic review and meta-analysis. *Intensive Care Med*. 2019;45(5):563-72.

Cardioembolic Stroke in a Patient with Coronavirus Disease of 2019 (COVID-19) Myocarditis: A Case Report

James S. Ford, MD
James F. Holmes, MD, MPH
Russell F. Jones, MD

UC Davis Health, Department of Emergency Medicine, Sacramento, California

Section Editor: Rick A. McPheeters, DO

Submission history: Submitted April 23, 2020; Revision received June 3, 2020; Accepted June 3, 2020

Electronically published June 22, 2020

Full text available through open access at http://escholarship.org/uc/uciem_cpem

DOI: 10.5811/cpcem.2020.6.47856

Introduction: There is a growing body of literature detailing coronavirus 2019 (COVID-19) cardiovascular complications and hypercoagulability, although little has been published on venous or arterial thrombosis risk.

Case Report: In this report, we present a single case of cardioembolic stroke in the setting of COVID-19 related myocarditis, diagnosed via cardiac magnetic resonance imaging and echocardiography. COVID-19 infection was confirmed via a ribonucleic acid polymerase chain reaction assay.

Conclusion: Further research is needed to evaluate the hypercoagulable state of patients with COVID-19 to determine whether prophylactic anticoagulation may be warranted to prevent intracardiac thrombi and cardioembolic disease in patients with COVID-19 related myocarditis. [Clin Pract Cases Emerg Med. 2020;4(3):332–335.]

Keywords: COVID-19; SARS-CoV-2; myocarditis; thromboembolic stroke.

INTRODUCTION

The first cases of coronavirus of 2019 (COVID-19) were reported in Wuhan, China, in December 2019.¹ While the full spectrum of clinical disease that the virus can cause has yet to be elucidated, a growing body of literature is emerging detailing various cardiovascular complications, ranging from myocardial injury with mild troponin elevations to fulminant myocarditis.^{2,3} Elevations in cardiac biomarkers such as B-type natriuretic peptide (BNP, 27.5% of patients) and cardiac troponin (7-17%) are common, with the latter being associated with worsening disease severity, intensive care unit status, and mortality.⁴⁻⁶ Additionally, cardiac dysrhythmias from a variety of etiologies have been reported.² In a case series of 150 patients with confirmed COVID-19, 7% of all deaths were attributed to myocarditis with ensuing circulatory collapse.⁷

Derangements of coagulation laboratory studies have also been reported from COVID-19, including elevations of D-dimer, modulation of fibrinogen (high in early disease, low

in advanced disease), and modulation of prothrombin time and partial thromboplastin time, with over 70% of non-survivors in one study meeting criteria for disseminated intravascular coagulation.⁸ While rates of venous thromboembolism have not been reported for COVID-19, severe acute respiratory syndrome, coronavirus 1, (SARS-CoV-1)(2013) was associated with ischemic stroke, deep venous thrombosis and pulmonary embolism, making it probable that similar complications are possible with the 2019 novel virus.⁹ A recent case series identified seven cases of acro-ischemia in patients without evidence of shock and not on vasopressor support, providing early evidence of hypercoagulability in COVID-19 infection.¹⁰ In this report, we present a single case of cardioembolic stroke in the setting of COVID-19 related myocarditis.

CASE REPORT

A 53-year-old male with a past medical history significant only for hyperlipidemia, was brought in by ambulance to the

emergency department (ED) with a six-day history of malaise and fever (T_{\max} 101°Fahrenheit [F]), and one day of cough. The day before presentation, he was seen in an outside ED and discharged home with a diagnosis of viral upper respiratory syndrome. On presentation to our ED the next day, he reported a brief episode of chest pain with palpitations that resolved spontaneously after 30 minutes. He denied shortness of breath, nocturnal dyspnea or lower extremity swelling. Vitals at triage were notable for temperature of 100.2°F, heart rate 140 beats per minute, blood pressure 97/55 millimeters of mercury, respiratory rate 16 breaths per minute, and oxygen saturation of 100%.

Exam was notable for diaphoresis, with clear breath sounds bilaterally, tachycardia with irregular pulse with no murmurs, and no lower extremity edema. Electrocardiogram (ECG) demonstrated a wide-complex, irregular tachycardia with a left bundle branch block (LBBB) morphology not meeting modified Sgarbosa criteria (Concordant ST elevation > 1 millimeter [mm] in leads with a positive QRS complex; concordant ST depression > 1 mm in V1-V3; discordant ST elevation [or depression] relative to the preceding S-wave [or R-wave] with 1) at least 1 mm of ST elevation (or depression) AND 2) an ST/S(R) ratio \leq -0.25) that was favored to be atrial fibrillation with rapid ventricular response or sinus tachycardia with frequent premature atrial contractions, as well as a corrected QT interval (QTc) of 563 (Reference [Ref]: \leq 440, in males).¹¹ No comparison ECG was available. Laboratory work-up was significant for hypokalemia (K^+ 2.8 milliequivalents per liter [mEq/L] [Ref: 3.3-5.0 mEq/L]), normal creatinine, white blood cell count of 5.5 thousand per cubic millimeter [K/mm^3] [Ref: 4.5-11 K/mm^3] with lymphopenia (absolute lymphocyte count, 0.7 K/mm^3 [Ref: 1.0-4.8 K/mm^3]), mild transaminitis (aspartate aminotransferase 63 units/L [Ref: 15-43 units/L], alanine transaminase 72 /L [Ref: 6-63 units/L], negative serial high-sensitivity troponin T (< 99 percentile) and BNP 588 picogram (pg)/mL (Ref: 1-100pg/mL). Chest radiograph (CXR) showed a left lower lobe consolidation. His potassium was replaced, he was given an amiodarone load, started on ceftriaxone/azithromycin for presumed community-acquired pneumonia, and admitted to the cardiology service.

During his hospitalization, he converted to normal sinus rhythm with electrolyte replacement and amiodarone load, but LBBB morphology and prolonged QTc persisted. Azithromycin was changed to doxycycline due to concerns of potentially worsening QTc prolongation from azithromycin. Rapid flu test, respiratory viral panel (RVP), legionella urine antigen, and blood cultures were all negative. Transthoracic echocardiography (TTE) was performed which showed mild left ventricular (LV) dilation with hypokinesis (ejection fraction 15%). There was no comparison TTE available. Cardiac catheterization did not reveal significant coronary artery disease. Cardiac magnetic resonance imaging (MRI) with contrast confirmed LV dilation with global hypokinesis,

CPC-EM Capsule

What do we already know about this clinical entity?
Coronavirus disease 2019 (COVID-19) can cause cardiovascular complications, including myocarditis. New evidence is emerging describing the hypercoagulability of COVID-19 patients.

What makes this presentation of disease reportable?
COVID-19 myocarditis and left ventricular thrombus formation with cardioembolic stroke has not been previously reported.

What is the major learning point?
COVID-19 myocarditis with associated left-heart dilation and hypercoagulability may predispose patients to cardioembolic stroke, especially in patients with underlying cardiomyopathy.

How might this improve emergency medicine practice?
Understanding clinical sequelae related to COVID-19 will help tailor diagnostics and therapeutics related to cardiovascular complications of infection.

increased T2 signal, hyperemia, and edema consistent with viral myocarditis. In the setting of these MRI findings, the patient's CXR infiltrate, and the absence of an additional viral etiology for myocarditis (negative RVP), radiology recommended dedicated COVID-19 testing.

The patient was tested using a qualitative ribonucleic acid polymerase chain reaction assay (via nasopharyngeal swab) and resulted positive. However, since LV dilation (defined as LV end diastolic diameter [LVEDD] >3.3 centimeters per meter squared [cm/m^2]) is only present in approximately 50% of patients with acute myocarditis, and the range of LVEDD reported in one study of myocarditis patients with LV dilation was 3.4-6.1 cm/m^2 , the patient's initial LVEDD (5.96 cm/m^2) approached the upper range for LV dilation expected in myocarditis, leading the cardiology service to suspect a chronic undiagnosed cardiomyopathy.¹² The patient had no evidence of ischemic heart disease, history of alcohol or methamphetamine use, or any other obvious etiology of cardiomyopathy. Further investigation revealed that the patient had spent time in Mexico, so he was tested for Chagas disease. This was a send-out lab and would not result for several days. The patient was discharged in stable condition on hospital day four with new prescriptions for metoprolol succinate, losartan and spironolactone.

Three days later, the patient returned to the ED with acute expressive aphasia without other neurological deficits. MRI and MR angiography of the brain revealed an acute left middle cerebral artery stroke involving Broca's area. He was treated with tissue plasminogen activator and admitted to the neurology service. ECG demonstrated a stable LBBB with no acute ST-T wave changes. Troponin T was elevated at 66 nanograms per liter (ng/L) (Ref: <19ng/L), and peaked at 373ng/L, 11 hours later. Emergent computed tomography angiography of the neck, did not reveal any carotid lesions, but did show ground-glass infiltrates in bilateral lung apices, consistent with COVID-19 infection.⁴ CXR showed bilateral peripheral airspace opacities (left greater than right). Repeat TTE showed a new LV thrombus (not visualized on TTE or cardiac MRI from previous hospitalization) and worsening LV dilation (diastolic diameter increased from 5.96 cm to 6.53 cm, compared to previous echocardiography six days earlier). He was started on anticoagulation therapy with warfarin with a heparin bridge, and transferred to an outside hospital for continued care and rehabilitation.

The patient's *Trypanosoma cruzi* (T. cruzi) immunoglobulin G (IgG) was found to be positive at 1.8, suggesting active or past infection. The patient was notified of this finding, and infectious disease follow-up was arranged.

DISCUSSION

While the patient's presentation was consistent with acute viral myocarditis, the presence of *T. cruzi* IgG antibodies confounded the clinical picture. Since it is possible that the patient had undiagnosed Chagas cardiomyopathy, it is difficult to know whether the patient's presentation was truly related to COVID-19 myocarditis or simply was related to chronic pre-existing heart failure. However, myocardial fibrosis, a marker of Chagas cardiomyopathy that is detected as delayed gadolinium enhancement on cardiac MRI, was not seen in our patient, making Chagas cardiomyopathy less likely.¹³ Furthermore, acute worsening of LV dilation and rising troponin levels, suggested an acute, rather than chronic process, making viral (COVID-19) myocarditis more likely.

In the setting of a newly diagnosed LV thrombus, the most likely source of the patient's stroke was cardioembolic. Transesophageal echocardiography (TEE) is the gold standard for diagnosing intracardiac thrombi. However, cardiac MRI has been found to be both more sensitive and specific than TEE for detecting LV thrombus, making it unlikely that the LV thrombus was present during the initial hospitalization, and instead, more likely that the thrombus formed during the three days between discharge and re-hospitalization.¹⁴ While it is possible that the patient had undiagnosed paroxysmal atrial fibrillation that predisposed him toward forming a LV thrombus, this seems unlikely given that his irregular rhythm converted to sinus after electrolyte correction, and he did not re-enter an irregular rhythm during the same hospitalization, or during subsequent re-hospitalization. Furthermore, if he

indeed did have atrial fibrillation, his CHA₂DS₂-VASc score would have been one (one point for newly diagnosed heart failure, annual stroke risk 0.6%), making it unlikely that a ventricular thrombus could have formed and embolized in three days.¹⁵

The prevalence of LV thrombus in patients with dilated cardiomyopathy with reduced ejection fraction and sinus rhythm, is as high as 13%, with increasing LV size being independently associated with LV thrombus.^{16,17} Since complete coagulation parameters were not initially obtained, it is difficult to quantify his level of hypercoagulability. Nonetheless, it is likely that this hypercoagulable state, in conjunction with acute myocarditis and worsening LV dilation, predisposed the patient to LV thrombus formation and cardioembolic stroke.

CONCLUSION

Myocarditis is a serious complication of COVID-19 infection and may predispose patients to further cardiovascular injury, such as cardioembolic stroke. Further research is needed to evaluate the full scope of cardiovascular complications in order to better inform treatment. Prophylactic anticoagulation should be considered in high-risk patients at risk for venous and arterial thromboembolism.

The authors attest that their institution requires neither Institutional Review Board approval, nor patient consent for publication of this case report. Documentation on file.

Address for Correspondence: Russell Jones, MD, UC Davis Health, Department of Emergency Medicine, 4150 V. St., PSSB 2100, Sacramento, CA 95817. Email: rfjones@ucdavis.edu.

Conflicts of Interest: By the CPC-EM article submission agreement, all authors are required to disclose all affiliations, funding sources and financial or management relationships that could be perceived as potential sources of bias. The authors disclosed none.

Copyright: © 2020 Ford et al. This is an open access article distributed in accordance with the terms of the Creative Commons Attribution (CC BY 4.0) License. See: <http://creativecommons.org/licenses/by/4.0/>

REFERENCES

1. World Health Organization. Pneumonia of unknown cause — China. 2020. Available at: <https://www.who.int/csr/don/05-january-2020-pneumonia-of-unknown-cause-china/en/>. Accessed April 15, 2020.
2. Driggin E, Madhavan MV, Bikdeli B, et al. Cardiovascular considerations for patients, health care workers, and health systems

- during the coronavirus disease 2019 (COVID-19) Pandemic. *J Am Coll Cardiol*. 2020;75(18):2352-71.
3. Madjid M, Safavi-Naeini P, Solomon SD, et al. [Ahead of Print]. Potential effects of coronaviruses on the cardiovascular system: a review. *JAMA Cardiol*. March 27, 2020.
 4. Huang C, Wang Y, Li X, et al. Clinical features of patients infected with 2019 novel coronavirus in Wuhan, China. *Lancet*. 2020;395(10223):497-506.
 5. Zhou F, Yu T, Du R, et al. Clinical course and risk factors for mortality of adult inpatients with COVID-19 in Wuhan, China: a retrospective cohort study. *Lancet*. 2020;395(10229):1054-62.
 6. Wang D, Hu B, Hu C, et al. Clinical characteristics of 138 hospitalized patients with 2019 novel coronavirus-infected pneumonia in Wuhan, China. *JAMA*. 2020;323(11):1061-9.
 7. Ruan Q, Yang K, Wang W, et al. Clinical predictors of mortality due to COVID-19 based on an analysis of data of 150 patients from Wuhan, China. *Intensive Care Med*. 2020;46(5):846-8.
 8. Tang N, Li D, Wang X, et al. Abnormal coagulation parameters are associated with poor prognosis in patients with novel coronavirus pneumonia. *J Thromb Haemost*. 2020;18(4):844-7.
 9. Umapathi T, Kor AC, Venketasubramanian N, et al. Large artery ischaemic stroke in severe acute respiratory syndrome (SARS). *J Neurol*. 2004;251(10):1227-31.
 10. Zhang Y, Cao W, Xiao M, et al. [Clinical and coagulation characteristics of 7 patients with critical COVID-2019 pneumonia and acro-ischemia]. *Zhonghua Xue Ye Xue Za Zhi*. 2020;41(0):E006.
 11. Smith SW, Dodd KW, Henry TD, et al. Diagnosis of ST-elevation myocardial infarction in the presence of left bundle branch block with the ST-elevation to S-wave ratio in a modified Sgarbossa rule. *Ann Emerg Med*. 2012;60(6):766-76.
 12. Pinamonti B, Alberti E, Cigalotto A, et al. Echocardiographic findings in myocarditis. *Am J Cardiol*. 1988;62(4):285-91.
 13. Rochitte CE, Oliveira PF, Andrade JM, et al. Myocardial delayed enhancement by magnetic resonance imaging in patients with Chagas' disease: a marker of disease severity. *J Am Coll Cardiol*. 2005;46(8):1553-8.
 14. Srichai MB, Junor C, Rodriguez LL, et al. Clinical, imaging, and pathological characteristics of left ventricular thrombus: a comparison of contrast-enhanced magnetic resonance imaging, transthoracic echocardiography, and transesophageal echocardiography with surgical or pathological validation. *Am Heart J*. 2006;152(1):75-84.
 15. Lip GYH, Nieuwlaat R, Pisters R, et al. Refining clinical risk stratification for predicting stroke and thromboembolism in atrial fibrillation using a novel risk factor-based approach: the Euro Heart Survey on Atrial Fibrillation. *Chest*. 2010;137(2):263-72.
 16. Bakalli A, Georgievska-Ismail L, Koçinaj D, et al. Left ventricular and left atrial thrombi in sinus rhythm patients with dilated ischemic cardiomyopathy. *Med Arch*. 2012;66(3):155-8.
 17. Bakalli A, Georgievska-Ismail L, Koçinaj D, et al. Prevalence of left chamber cardiac thrombi in patients with dilated left ventricle at sinus rhythm: the role of transesophageal echocardiography. *J Clin Ultrasound*. 2013;41(1):38-45.

Case Report: Disposition of Symptomatic Probable COVID-19

Aleq Jaffery, MD, MPH*
John Slakey, MD*
David Zodda, MD†
Douglas Finefrock, DO†

*Hackensack University Medical Center, Department of Emergency Medicine, Hackensack, New Jersey
†Hackensack Meridian School of Medicine at Seton Hall University, Department of Emergency Medicine, Hackensack, New Jersey

Section Editor: Rick A. McPheeters, DO

Submission history: Submitted May 19, 2020; Revision received May 28, 2020; Accepted May 26, 2020

Electronically published June 5, 2020

Full text available through open access at http://escholarship.org/uc/uciem_cpchem

DOI: 10.5811/cpchem.2020.5.48318

Introduction: The novel coronavirus disease 2019 (COVID-19) presents a challenge for healthcare providers in terms of diagnosis, management, and triage of cases requiring admission.

Case Report: A 47-year-old male with symptoms suspicious for COVID-19, pulse oximetry of 93% on room air, and multifocal pneumonia was risk stratified and safely discharged from the emergency department (ED) despite having moderate risk of progression to acute respiratory distress syndrome. He had resolution of his symptoms verified by telephone follow-up.

Conclusion: Various risk-stratifying tools and techniques can aid clinicians in identifying COVID-19 patients who can be safely discharged from the ED. [Clin Pract Cases Emerg Med. 2020;4(3):336–339.]

Keywords: COVID-19; coronavirus; pneumonia; disposition; MulBSTA.

INTRODUCTION

An emerging challenge in the management of patients with coronavirus disease 2019 (COVID-19) symptoms involves the disposition of those with moderate risk for decompensation. Clinicians must grapple with the desire to be conservative with this novel disease entity and the bitter truth that hospital beds as well as life-saving resources are increasingly limited. A growing body of evidence has identified key clinical factors associated with increased morbidity for these patients (Table). There are in addition many clinical tools available to aid in the diagnosis and disposition of these patients. While data are still emerging and not all the tools are fully validated, the growing corpus of evidence as well as shared decision-making and ensuring follow-up are essential parts of safely dispositioning moderate-risk patients. Here we present a case of a 47-year-old male with symptoms suspicious for COVID-19 and with moderate risk of progression to acute respiratory distress syndrome (ARDS) who was discharged home from our emergency department (ED). We discuss which factors contributed to a favorable outcome and how to apply this to patients on a larger scale.

Table. Factors identified with morbidity and mortality in novel coronavirus disease 2019 patients.^{2,3,4,5}

- Age > 65
- Comorbid conditions, i.e., diabetes mellitus, hypertension
- Lymphopenia
- Elevated D-dimer
- Elevated lactate dehydrogenase
- Elevated C-reactive protein
- Elevated erythrocyte sedimentation rate
- Elevated ferritin
- Low albumin

CASE REPORT

In March 2020, a 47-year-old man presented to a suburban New Jersey hospital at the national epicenter of the COVID-19 pandemic. The patient had no past medical history of known illness. He presented with a chief complaint of persistent fever for 14 days as well as productive cough, scant hemoptysis, sore throat, generalized body aches, and worsening shortness of breath. He was seen by his primary

care provider and prescribed a five-day course of amoxicillin. His symptoms did not resolve, so he presented to the ED. He denied recent travel, exposure to positive COVID-19 patients, and any history of smoking.

The patient's vital signs included a temperature of 38.3° Celsius, a heart rate of 110 beats per minute, a blood pressure of 103/62 millimeters of mercury, and respiratory rate of 21 breaths per minute. His oxygen saturation was 93% on room air. He was overweight with a body mass index of 29.1 kilograms (kg) per meter (m)² (normal range 18.5-24.9 kg/m²). His physical exam was otherwise benign including a pulmonary exam with clear and equal breath sounds. Despite tachypnea, he showed no signs of respiratory distress. He additionally had no signs of dehydration, cardiovascular collapse, or rash.

The leading diagnosis was for COVID-19 or another respiratory virus given the geographical area and timing of his presentation, and the patient received a chest radiograph (CXR), a COVID-19 test, and a respiratory pathogen panel (RPP). His RPP was negative for a host of common viruses, and the COVID-19 test had a processing time of several days. His CXR showed multifocal, patchy, airspace opacities at the bilateral lower lobes concerning for multifocal infectious pneumonitis (Image).

Given his oxygen saturation and his CXR, the team discussed with the patient and his wife his risk factors and the likelihood of progression to ARDS. At this point, the patient

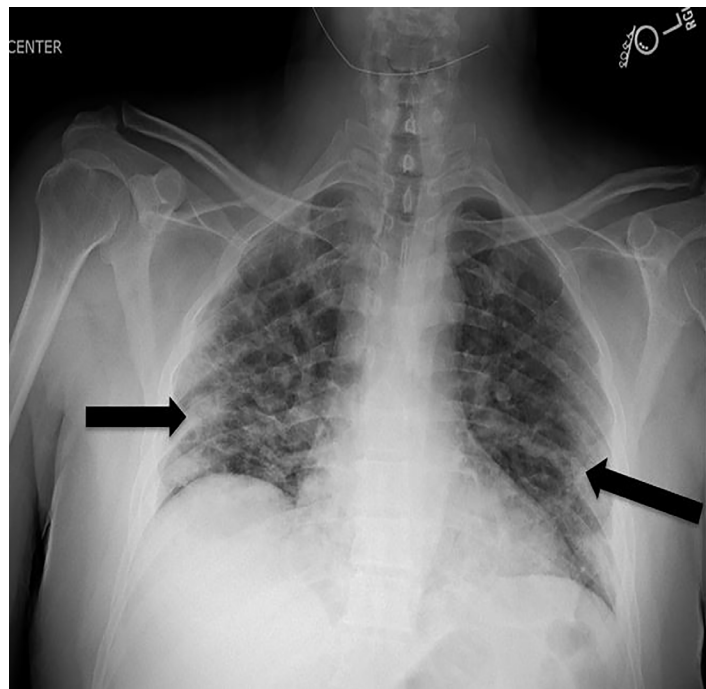


Image. Chest radiograph of the patient. Note bilateral patchy opacities, most prominently at periphery of the lung concerning for multifocal pneumonia (arrows).

CPC-EM Capsule

What do we already know about this clinical entity?

The novel coronavirus disease 2019 (COVID-19) is a rapidly evolving clinical entity that causes a variety of pulmonary and inflammatory conditions of varying severity.

What makes this presentation of disease reportable?

This case involves a patient suspicious for novel coronavirus and provides examples of clinical scoring systems and tools that assisted in a safe disposition.

What is the major learning point?

Not every suspected COVID-19 patient who may decompensate need be admitted. Clinicians have a variety of tools that can assist in decision-making.

How might this improve emergency medicine practice?

Clinicians should use both their acumen and gestalt as well as evidence-based clinical tools in their management and disposition of COVID-19 patients.

did not require supplemental oxygen. The team used shared decision-making and explained the risks of progression of his pneumonitis and the likelihood of COVID-19 infection, as well as the benefits of returning home and avoiding hospitalization. The patient and his wife were given strict return precautions for worsening symptoms, particularly worsening dyspnea, and quarantine instructions and precautions were reviewed at length.¹ He was discharged home that day with azithromycin and an albuterol metered-dose inhaler. Telephone follow-up was made by the same ED provider to check on the patient, who confirmed his symptoms had abated.

DISCUSSION

An important step for clinicians treating confirmed or suspected COVID-19 patients is to risk stratify them and generate a clinical picture with probability of illness progression. In terms of risk, this patient was under 65 years old with no medical comorbidities, two of the most important predictors of morbidity in COVID-19.^{2,4} Had his oxygen saturation been lower, or had there been signs of respiratory

distress on physical examination, more laboratory values may have been obtained. Laboratory values associated with increased morbidity and mortality from COVID-19 include lymphopenia and elevated acute phase reactants (Table).^{2,3,4,5} These, however, are not necessarily always indicated in the acute setting.

His RPP was of limited clinical utility given the possibility of coinfection;⁵ however, his CXR was concerning, given that bilateral interstitial infiltrates are a common finding in COVID-19 patients.^{3,4,5}

After information-gathering, clinicians can combine the clinical picture with a variety of clinical tools. In critically ill patients with COVID-19 pneumonia, the sequential organ failure assessment score has been shown to correlate with mortality.⁶ The pneumonia severity index (PSI) has traditionally been used to predict risk in patients with community-acquired pneumonia, although it has not been exclusively validated for COVID-19 pneumonia.⁷ Alternatively, a yet-to-be validated tool, initially developed for risk stratifying viral pneumonia in China, shows promise for application in COVID patients. It evaluates Multilobular infiltration, Lymphocytopenia, Bacterial coinfection, Smoking history, hyperTension, and Age greater than or equal to 60 into the MuLBSTA score, an acronym of its composing parts.⁸ It can also be calculated with less information than the more detailed PSI, although it still requires a complete blood count to evaluate for lymphopenia. Each individual point on the score corresponds to a different 90-day mortality value. The cutoff between low-risk patients and high-risk patients is a score of 12, which corresponds to a 90-day mortality of 16%. Had this patient had a normal white blood cell count, he would have received five points on his MuLBSTA score, corresponding to a 90-day mortality of 2.17%, which is rather high for a “low-risk” designation. Nevertheless, this tool may have helped reinforce what the physical exam, vital signs, and CXR already revealed: that this patient may yet deteriorate and require respiratory support.

Finally, what is the disposition? Should we admit or discharge? This often involves more gestalt than clinical science. The patient was a good candidate for discharge given his likelihood of convalescing and healing, his ability to understand the risks of discharge, his ability to return should symptoms progress, his social network which was capable of offering him support and, most importantly, the ability of the emergency physician to contact him and follow up. It is also essential that this decision be shared between the clinician and the patient and that the clinician stresses the risks and benefits of hospitalization. Ultimately, the shared conversation and education of the patient and the ability to follow-up are the most essential factors in discharging moderate risk patients.

CONCLUSION

The patient in our case had moderate-risk COVID-19 but had resolution of symptoms without the need for supplemental

oxygen therapy or hospital admission. Key contributing factors to positive outcomes include strict return precautions and a follow-up plan. However, not all cases of COVID-19 will resolve. Patients may return at the threshold of intubation, or with new, unpredicted clinical manifestations of this novel virus. Clinicians must be prepared to accept a degree of uncertainty with the risk of a bounceback return to the ED. These risks should be discussed with patients and their preferred support system. In the setting of a global pandemic where ventilators and beds are numbered, a bounceback should not be viewed as a failure of care. Instead, thoughtful disposition of moderate-risk COVID-19 discharges should be seen as temporizing measures to best use our resources. In a practical setting, this may mean the difference between life or death for a patient.

The authors attest that their institution requires neither Institutional Review Board approval, nor patient consent for publication of this case report. Documentation on file.

Address for Correspondence: Douglas Finefrock, DO, Hackensack Meridian School of Medicine at Seton Hall University, Department of Emergency Medicine, 30 Prospect Ave, Attn: Department of Emergency Medicine, Hackensack, NJ 07601. Email: douglas.finefrock@hackensackmeridian.org.

Conflicts of Interest: By the CPC-EM article submission agreement, all authors are required to disclose all affiliations, funding sources and financial or management relationships that could be perceived as potential sources of bias. The authors disclosed none.

Copyright: © 2020 Jaffery et al. This is an open access article distributed in accordance with the terms of the Creative Commons Attribution (CC BY 4.0) License. See: <http://creativecommons.org/licenses/by/4.0/>

REFERENCES

- Centers for Disease Control and Prevention. Disposition of Non-Hospitalized Patients with COVID-19. 2020. Available at: <https://www.cdc.gov/coronavirus/2019-ncov/hcp/disposition-in-home-patients.html>. Accessed May 18, 2020.
- Wu C, Chen X, Cai Y, et al. Acute respiratory distress syndrome and death in patients with COVID-19 in Wuhan, China. *JAMA Int Med*. 2020:E1-10.
- Tan L, Wang Q, Zhang D, et al. Lymphopenia predicts disease severity of COVID-19: a descriptive and predictive study. *Signal Transduct Target Ther*. 2020;5:33.
- Wang Y, Wang Y, Chen Y, et al. [Ahead of Print]. Unique epidemiological and clinical features of the emerging 2019 novel

- coronavirus pneumonia (COVID-19) implicate special control measures. *J Med Virol*. March 5, 2020.
5. Wang M, Wu Q, Xu W, et al. Clinical diagnosis of 8274 samples with 2019 novel coronavirus in Wuhan. *medRxiv*. 2020.
 6. Zhou F, Yu T, Du R, et al. Clinical course and risk factors for mortality of adult inpatients with COVID-19 in Wuhan, China: a retrospective cohort study. *Lancet*. 2020;395(10229):1054-62.
 7. Shah B, Ahmed W, Dhobi G, et. al. Validity of pneumonia severity index and CURB-65 severity scoring systems in community acquired pneumonia in an Indian setting. *Indian J Chest Dis Allied Sci*. 2009;52(1):9-17.
 8. Guo L, Wei D, Zhang X, et al. Clinical features predicting mortality risk in patients with viral pneumonia: the MuLBSTA score. *Front Microbiol*. 2019;10:2752.

A Case Report: Co-presenting COVID-19 Infection and Acute Drug Intoxication

Jeremy Riekema, MD
Irene Lee, BA
Anita Lui, DO
Marion-Vincent Mempin, MD

New York-Presbyterian Queens, Department of Emergency Medicine, Flushing, New York

Section Editor: Rick A. McPheeters, DO

Submission history: Submitted April 17, 2020; Revision received May 28, 2020; Accepted June 1, 2020

Electronically published July 1, 2020

Full text available through open access at http://escholarship.org/uc/uciem_cpem

DOI: 10.5811/cpcem.2020.6.47764

Background: Coronavirus disease 2019 (COVID-19) has spread throughout the world since late 2019. Symptoms appear after a two-week incubation period and commonly include fever, cough, myalgia or fatigue, and shortness of breath.

Case Report: A 32-year-old male with a history of opiate abuse presented to the emergency department with altered mental status. The patient was lethargic and hypoxic with improvement from naloxone. Official chest radiograph was read as normal; however, the treating clinicians noted bilateral interstitial opacities, raising concern for underlying infectious etiology. Opiates and cocaine were positive on drug screen, and an arterial blood gas on room air showed hypoxemia with respiratory acidosis. The patient was intubated during the treatment course due to persistent hypoxemia and for airway protection after resuscitation. The COVID-19 test was positive on admission, and later computed tomography showed ground-glass opacities. The patient was extubated and discharged after one week on the ventilator.

Conclusion: When screening patients at and during evaluation, physicians should consider a broad differential as patients with atypical presentations may be overlooked as candidates for COVID-19 testing. As screening and evaluation protocols evolve, we emphasize maintaining a high index of suspicion for COVID-19 in patients with atypical symptoms or presenting with other chief complaints in order to avoid spreading the disease. [Clin Pract Cases Emerg Med. 2020;4(3):340–343.]

Keywords: COVID-19; Anchoring bias; Opiates.

INTRODUCTION

The main objective in this case study was to promote a bottoms-up approach in tackling the coronavirus disease 2019 (COVID-19) pandemic, as it has a wide variety of presentations in different individuals across the globe. Throughout this case, we were able to use multiple points of re-evaluation to uncover COVID-19 induced hypoxemia initially presenting as an opiate overdose.

In December 2019, a cluster of patients who had been admitted to various hospitals in the eastern region of China were diagnosed with pneumonia of unknown etiology. After

undergoing a series of medical evaluations, it was concluded that these individuals were epidemiologically linked to a seafood and wet-animal wholesale market located in Wuhan, Hubei Province, China. Upon further review, it was determined that these patients had been infected with a novel variation of coronavirus.¹

Coronavirus is a major pathogen that predominantly targets the human respiratory system. Symptoms of this virus, on average, appear after an incubation period of approximately 5.2 days. Onset of symptoms to death varies between 6-41 days, with a median onset period of 14 days.

Mortality is predicated on various risk factors including the patient's age and comorbidities.

At the onset of illness in the setting of the COVID-19 pandemic, most common presentations in patients include fever (77-98%), cough (46-82%), myalgia or fatigue (11-52%), and shortness of breath (3-31%).² However, clinicians should not neglect other atypical symptoms that have been reported, including sore throat, headache, hemoptysis, diarrhea, and nausea. Research done by Xu et al showed that pathological features of COVID-19 greatly resemble those seen in severe acute respiratory syndrome (SARS)-associated coronavirus, as well as Middle Eastern respiratory syndrome coronavirus infection. Methods to identify various modes of transmission are crucial in the development of transmission mitigation strategies and creation of therapeutics to more effectively manage the disease.

Lab values that help identify COVID-19 have included leukopenia and lymphopenia, aspartate aminotransferase (AST) and alanine aminotransferase (ALT) elevation, increase in acute inflammatory markers, and low procalcitonin.³ Imaging findings include chest radiograph (CXR) with bilateral interstitial opacities. Numerous peripheral ground-glass opacities have been observed in subpleural areas of both lungs on computed tomography (CT), mediated by both general and localized immune responses that led to inflammation within the lungs. A limited number of reports describe identification of hypoxic COVID-19 patients with an absence of the most common respiratory or systemic symptoms.

CASE REPORT

A 32-year-old male presented to the emergency department (ED) with altered mental status secondary to drug overdose as reported by emergency medical services (EMS). EMS gave the patient one round of naloxone with reported improvement of the patient's respiratory status. Patient chart review was notable for a history of opiate dependence and enrollment in suboxone and methadone centers. History of presenting illness was limited due to the patient's presenting mental status.

Presenting vital signs were notable for a respiratory rate of 25 breaths per minute and oxygen saturation of 75% on room air, with improvement to 95% on a non-rebreather mask. The patient was lethargic but arousable and was able to move all four extremities spontaneously. Initial lab work was notable for a glucose of 87 milligrams per deciliter (mg/dL) (70-130 mg/dL) and a urine drug screen that was positive for opiates and cocaine. The official CXR read was as normal; however, the treating clinicians were concerned about the subtle appearance of bilateral interstitial opacities.

After a period of observation, the patient had multiple episodes of emesis. Additionally, he was noted to have no improvement in mental status or ability to oxygenate; therefore, crystalloid fluids, naloxone, ondansetron, and clonidine were given in an attempt to reverse the reported

CPC-EM Capsule

What do we already know about this clinical entity?
Coronavirus disease 2019 (COVID-19) is a world wide pathogen with a varied symptom course. Major health organizations recommend measures to prevent spread between asymptomatic individuals.

What makes this presentation of disease reportable?
Early in the COVID-19 pandemic and before routine testing, this patient was identified with COVID-19 infection in addition to opiate overdose with hypoxia.

What is the major learning point?
As the COVID-19 pandemic wanes, maintaining a high index of suspicion for asymptomatic or occult infection is important in disease control.

How might this improve emergency medicine practice?
This case highlights the importance of continuous re-evaluation for multiple disease processes underlying a pre-established diagnosis.

opiate overdose and prevent withdrawal symptoms. On re-assessment, physical exam revealed sonorous respiration and inspiratory stridor; thus, it became more apparent that an underlying pulmonary and metabolic pathology was contributing to the patient's hypoxemia and lethargy, rather than just opiate use.

Once the patient's family arrived at the hospital, they noted that he had recently traveled to Israel for drug rehabilitation approximately one week prior to his hospital visit. However, they believed that he continued to use intravenous drugs upon arrival home. At that time, Israel already had confirmed COVID-19 positive cases.⁴

The patient was moved into a negative pressure isolation after travel history correlated with the known abnormal CXR and hypoxemia because of a high degree of suspicion of COVID-19. Arterial blood gas on room air showed a pH of 7.26 (7.35-7.45), partial pressure carbon dioxide of 60 millimeters of mercury (mmHg) (35-45 mmHg), partial pressure oxygen of 47mmHg (80-100 mmHg), and bicarbonate of 27 milliequivalents per liter (mEq/L) (22-28 mEq/L), demonstrating hypercarbic hypoxemic respiratory failure, and the patient's oxygen saturation began to drop to 85% on a non-rebreather.

The decision was made to intubate the patient for hypoxemia and airway protection. A post-intubation CXR demonstrated progression of bibasilar opacities from initial CXR (Image 1), with later lung CT demonstrating extensive ground-glass opacities in bilateral lungs (Image 2).

During the patient's intensive care unit (ICU) course, the SARS-associated coronavirus ribonucleic acid assay sent from the ED came back positive, indicating COVID-19 pulmonary infection. Repeat lab work also showed characteristic COVID-19 findings of lymphopenia and elevated AST and ALT. After six days on a ventilator, the patient was successfully extubated. He was treated with hydroxychloroquine for COVID-19 and antibiotics for aspiration pneumonia. After a stable course on the general medical floor, he was discharged home with self-quarantining instructions to prevent the spread of COVID-19.

DISCUSSION

Anchoring bias is a common phenomenon in the field of medicine, and especially in emergency medicine. In the acute setting in the ED, a patient's history and ancillary information may be limited due to various reasons, such as the altered mental status presented in our patient. Because of these limitations, it is critical to maintain a broad and evolving differential diagnosis using thorough physical examinations and continuous re-evaluations.

Our 32-year-old patient presented as a drug overdose with agitation and was ultimately admitted to the medical ICU after intubation for profound hypoxemia and airway protection. While we were initially limited to information given by EMS, the lab results and imaging provided us with information that was compatible with patients who had tested positive for COVID-19. Variables such as oxygen saturation and abnormal CXR findings were the initial clues into the presenting viral illness. The fact that the patient's mental status did not improve, paired with the ancillary history after family arrived in the ED, made it clear that COVID-19 had to be considered underlying the patient's presentation. After definitive airway

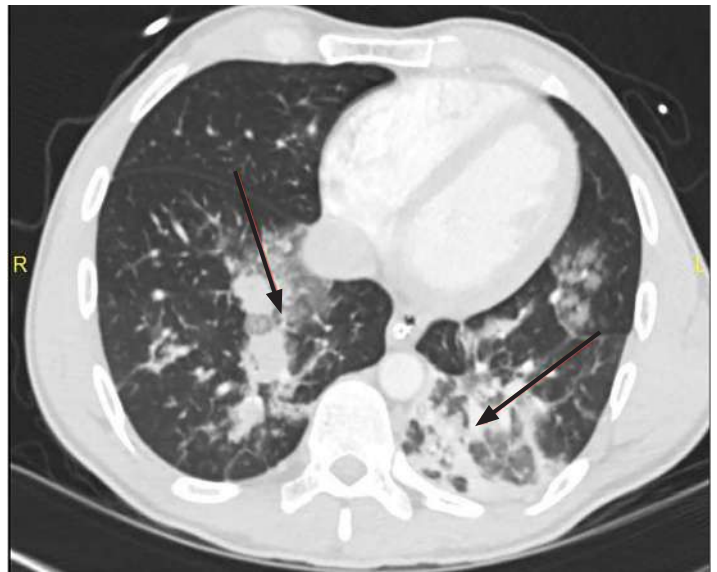


Image 2. Computed tomography showing extensive ground-glass opacities (arrows) in multiple lung fields concerning for inflammatory or infectious etiology.

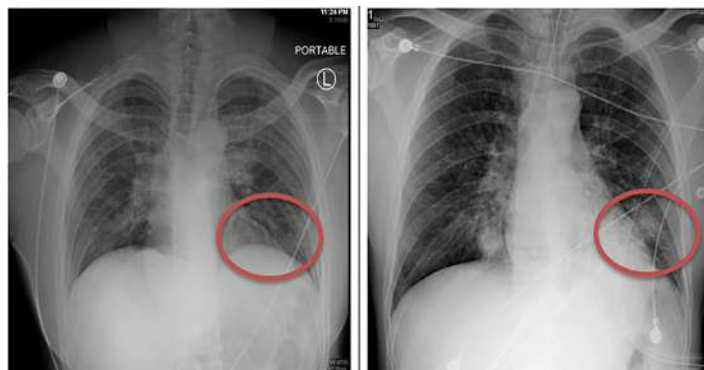


Image 1. Initial chest radiograph (left) and post-intubation chest radiograph (right) demonstrating interval progression of bibasilar opacities and interstitial opacities in several hours.

control and isolation, a contrast-enhanced CT of the lungs was performed, showing the ground-glass opacities prevalent with COVID-19 positive patients, indicating that the patient was an appropriate candidate for COVID-19 testing. COVID-19 primarily affects the respiratory system, thus directing the clinicians' focus to respiratory-related symptoms.

When screening patients at and during evaluation, clinicians should consider a broad differential because patients with atypical presentations may be overlooked as candidates for COVID-19 testing and treatment. Ramifications of neglecting certain signs and symptoms may include risks such as patients being brought to non-COVID-19 isolation areas and causing further spread of the disease to otherwise healthy individuals. By thoroughly considering all potential risk factors within variable presentations, the capture rate of COVID-19 infected patients should improve. Further discussion and studies should be encouraged as the rapid rise in COVID-19 patients may precipitate mistakes made while they are being triaged. Given the paucity of research on atypical presentations for COVID-19, it would prove beneficial to broaden the knowledge of this pandemic.

Hospital protocols are rapidly developing and evolving to account for the wide variety of patient presentations. These include patients with absence of all respiratory symptoms; incidental findings on CT or CXR while investigating other pathology; and exacerbation of chronic disease such as hyperglycemia in diabetic patients. No protocol, however, can effectively capture all patients who may fall out of normal protocol guidelines. In an effort to curb the spread of disease, physicians will need a high index of suspicion for identifying COVID-19 positive patients, especially as the incidence of the disease continues to rise.

CONCLUSION

Keeping a broad differential diagnosis while evaluating patients during the COVID-19 pandemic will aid physicians in controlling the spread of this pathogen. Appropriate use of imaging and labs may expedite diagnosis of COVID-19 in patients and ensure they are properly managed. Atypical manifestations of patients with COVID-19 should not be undermined as research is still limited on the pathophysiology of this virus.

The authors attest that their institution requires neither Institutional Review Board approval, nor patient consent for publication of this case report. Documentation on file.

REFERENCES

1. Rothan HA and Byrareddy SN. The epidemiology and pathogenesis of coronavirus disease (COVID-19) outbreak. *J Autoimmun.* 2020;109:102433.
2. Centers for Disease Control and Prevention. Management of patients with confirmed 2019-NCov. 2020 Available at: www.cdc.gov/coronavirus/2019-ncov/hcp/clinical-guidance-management-patients.html. Accessed April 10, 2020.
3. Xu Z, Shi L, Wang Y, et al. Pathological findings of COVID-19 associated with acute respiratory distress syndrome. *Lancet Respir Med.* 2020;8(4):420-2.
4. Staff T. COVID-19 Cases in Israel jump to 298; nearly 1/4 showed no symptoms. 2020. Available at: www.timesofisrael.com/covid-19-cases-in-israel-climb-to-277-nearly-1-4-showed-no-symptoms/. Accessed April 10, 2020.

Address for Correspondence: Jeremy Riekema, MD, New York-Presbyterian Queens, Department of Emergency Medicine, 5644 Main Street, Flushing, NY 11355. Email: jer9225@nyp.org.

Conflicts of Interest: By the *CPC-EM* article submission agreement, all authors are required to disclose all affiliations, funding sources and financial or management relationships that could be perceived as potential sources of bias. The authors disclosed none.

Copyright: © 2020 Riekema et al. This is an open access article distributed in accordance with the terms of the Creative Commons Attribution ([CC BY 4.0](http://creativecommons.org/licenses/by/4.0/)) License. See: <http://creativecommons.org/licenses/by/4.0/>

Acute Transverse Myelitis Secondary to Severe Acute Respiratory Syndrome Coronavirus 2 (SARS-CoV-2): A Case Report

Muhammad Durrani, DO, MS
Kevin Kucharski, DO
Zachary Smith, DO
Stephanie Fien, PA

Inspira Medical Center, Department of Emergency Medicine, Vineland, New Jersey

Section Editor: Rick A. McPheeters, DO

Submission history: Submitted May 28, 2020; Revision received June 12, 2020; Accepted June 10, 2020

Electronically published June 22, 2020

Full text available through open access at http://escholarship.org/uc/uciem_cpem

DOI: 10.5811/cpcem.2020.6.48462

Introduction: Respiratory viral illnesses are associated with diverse neurological complications, including acute transverse myelitis (ATM). Among the respiratory viral pathogens, the Coronaviridae family and its genera coronaviruses have been implicated as having neurotropic and neuroinvasive capabilities in human hosts.¹ Despite previous strains of coronaviruses exhibiting neurotropic and neuroinvasive capabilities, little is known about the novel severe acute respiratory syndrome coronavirus 2 (SARS-CoV-2) and its involvement with the central nervous system (CNS). The current pandemic has highlighted the diverse clinical presentation of SARS-CoV-2 including a possible link to CNS manifestation with disease processes such as Guillain-Barré syndrome and cerebrovascular disease. It is critical to shed light on the varied neurological manifestation of SARS-CoV-2 to ensure clinicians do not overlook at-risk patient populations and are able to provide targeted therapies appropriately.

Case Report: While there are currently no published reports on post-infectious ATM secondary to SARS-CoV-2, there is one report of parainfectious ATM attributed to SARS-CoV-2 in pre-print. Here, we present a case of infectious ATM attributed to SARS-CoV-2 in a 24-year-old male who presented with bilateral lower-extremity weakness and overflow urinary incontinence after confirmed SARS-CoV-2 infection. Magnetic resonance imaging revealed non-enhancing T2-weighted hyperintense signal abnormalities spanning from the seventh through the twelfth thoracic level consistent with acute myelitis.

Conclusion: The patient underwent further workup and treatment with intravenous corticosteroids with improvement of symptoms and a discharge diagnosis of ATM secondary to SARS-CoV-2. [Clin Pract Cases Emerg Med. 2020;4(3):344–348.]

Keywords: *Acute Transverse Myelitis; Severe Acute Respiratory Syndrome Coronavirus 2 (SARS-CoV-2); Para-infectious Acute Transverse Myelitis; Post-infectious Acute Transverse Myelitis.*

INTRODUCTION

Transverse myelitis is typified by an acute or subacute inflammatory myelopathy resulting in potentially disabling neurological deficits such as motor weakness and sensory deficits, as well as autonomic dysfunction. Acute transverse myelitis (ATM) has been associated with a variety of different etiologies, which have been subdivided into compressive and non-compressive myelopathies. Non-compressive etiologies

include infectious, autoimmune, ischemic, paraneoplastic, radiation effects, post-vaccination, and post-infectious, as well as idiopathic causes. The diagnosis of ATM, while challenging for the clinician, is important to recognize as it is associated with significant morbidity and mortality leaving two-thirds of infected patients with moderate to severe permanent disability.²⁻⁴

The incidence rate of ATM has been estimated to be between one and eight new cases per million annually,

but recent data show that it may be as high as 31 cases per million.⁵ While this disease entity can occur at any age, the mean age of onset ranges from 35-40.⁶ Most studies conclude that men and women are affected equally, although some studies do show a female predominance.⁶ Diagnosis is based upon uniform diagnostic criteria published by the Transverse Myelitis Consortium Working Group.⁷ These criteria rely on the exclusion of extra-axial compressive etiology by neuroimaging along with inclusion of sensory, motor, or autonomic dysfunction attributed to the spinal cord, bilateral signs/symptoms, as well as a clearly defined sensory level with demonstration of inflammation within the spinal cord through either cerebrospinal fluid (CSF) or magnetic resonance imaging (MRI) studies.⁶ Treatment is varied and depends on the accurate identification of etiology to guide treatment protocols.

CASE REPORT

A 24-year-old male with no significant medical history presented to the emergency department (ED) with complaint of fever and chills, along with nausea and non-bloody, non-bilious vomiting. He denied recent travel or sick contacts. He was febrile and tachypneic with findings of patchy airspace disease throughout both lungs compatible with multifocal pneumonia on computed tomography of the chest without contrast. He was subsequently admitted to the hospital for three days. Nasopharyngeal swabs were positive for severe acute respiratory syndrome coronavirus 2 (SARS-CoV-2) on reverse-transcriptase polymerase chain reaction (RT-PCR). He was treated with supportive care and demonstrated clinical improvement.

His respiratory pathogen panel did not reveal any coinfection and his legionella antigen, blood cultures, respiratory cultures, and human immunodeficiency virus (HIV) testing were also negative. He was discharged home but subsequently presented to the ED nine days later with symptoms of bilateral lower-extremity weakness in addition to developing overflow urinary incontinence. He denied any history of trauma, pain, or similar symptoms in the past. Upon arrival, his vitals revealed a blood pressure of 111/61 millimeters of mercury, pulse 97 beats per minute, respiratory rate 16 breaths per minute, 98% oxygen saturation on room air, and temperature of 37.3° Celsius.

His neurological examination revealed bilaterally absent knee and ankle reflexes with equivocal plantar reflexes, and flaccid, lower-extremity paraplegia bilaterally, in addition to evidence of overflow urinary incontinence. His lower-extremity sensory examination and anal tone were normal. His physical examination was otherwise normal. Laboratory workup included a complete blood count, complete metabolic panel, thyroid testing, inflammatory markers, repeat nasopharyngeal RT-PCR SARS-CoV-2 testing, and urinalysis, which were found to be unexceptional with a negative SARS-CoV-2 result on

CPC-EM Capsule

What do we already know about this clinical entity?
Transverse myelitis is a focal inflammatory myelopathy causing motor, sensory, and autonomic dysfunction. Diagnosis rests upon clinical findings as well as serologic, magnetic resonant imaging, and cerebral spinal fluid studies.

What makes this presentation of disease reportable?
Coronaviridae have been shown to have neurotropic and neuro-invasive capabilities, yet little is known about severe acute respiratory coronavirus 2 (SARS-CoV-2). We present the second case of acute myelitis attributed to SARS-CoV-2.

What is the major learning point?
SARS-CoV-2 is associated with a variety of neurological manifestations, including myelitis. Diagnosis should utilize established diagnostic criteria.

How might this improve emergency medicine practice?
Reinforcing the unique presentations of SARS-CoV-2 and myelitis yields a better understanding of the disease entities, allowing a focused investigation for accurate diagnosis and treatment.

hospital day one. The patient underwent MRI of the spine as well as a lumbar puncture (LP). The MRI showed a non-enhancing T2-weighted hyperintense signal abnormality spanning from the seventh through the twelfth thoracic level consistent with acute myelitis (Image).

CSF studies from the LP were consistent with a lymphocytic pleocytosis, normal glucose and protein levels, and electrophoresis. The patient underwent further workup to rule out other causes of transverse myelitis with CSF immunoglobulin G index, CSF-specific oligoclonal bands, aquaporin-4 antibodies, B-12 level, methylmalonic acid level, as well as a workup for HIV, other infectious diseases, autoimmune disease, connective tissue disease, and multiple sclerosis. He was diagnosed with post-infectious myelitis secondary to SARS-CoV-2 infection. Treatment was initiated with intravenous (IV) methylprednisolone and supportive care with noted improvement in bilateral lower-extremity strength. Interestingly, repeat SARS-CoV-2 testing was done on hospital day four, which returned positive. Hence, it is difficult to ascertain whether the patient demonstrated post-infectious ATM as opposed to parainfectious ATM secondary to SARS-CoV-2.

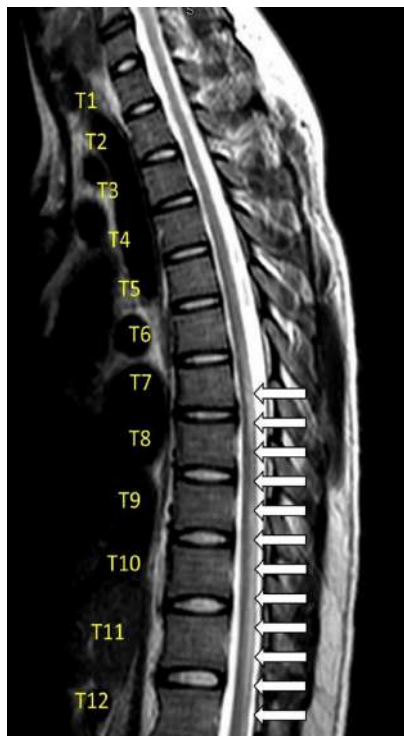


Image. T2 sagittal image of thoracic spine showing hyperintensity in the spinal cord from the seventh through the twelfth thoracic level suggestive of transverse myelitis (arrows).

DISCUSSION

ATM is characterized by focal inflammation of the spinal cord leading to varied severity of motor, sensory, and autonomic dysfunction. Although uncommon, it is paramount to distinguish it from other neurologic etiologies due to its potential for permanent disability. The diagnosis is based on characteristic clinical findings in addition to serologic, MRI, and CSF studies. As previously noted, the *Coronaviridae* family and its genera coronaviruses have been implicated as having neurotropic and neuroinvasive capabilities in human hosts.¹ They have been associated with the development of neuropsychiatric symptoms, seizure activity, encephalomyelitis, acute flaccid paralysis, and Guillain-Barré syndrome, as well as cerebrovascular disease.^{1,8}

Previous studies in mice have proposed that human coronavirus may reach the CNS via the olfactory bulbs, as viral antigens were initially detected there followed by propagation and detection in whole brain tissue days later.^{1,9} Subsequent viral infection of CNS glial and neuronal cells triggers demyelination as well as an inflammatory response.¹ Other pathways proposed for viral entry have implicated both hematogenous spread as well as a retrograde axonal transport pathway for entry into the CNS.^{10,11}

Recently, there has been a growing body of evidence supporting the association of SARS-CoV-2 with neurological abnormalities. A systematic review looking at the incidence

of secondary neurological disease in patients diagnosed with SARS-CoV-2 found rates to vary from 6-36.4%.¹¹ Additionally, the first case report of acute infectious myelitis associated with concurrent SARS-CoV-2 was only recently described.¹² Here, we present the second case of acute myelitis attributed to SARS-CoV-2 infection. Considering the chronological association of a confirmed positive SARS-CoV-2 infection and the development of signs and symptoms consistent with ATM nine days later, we speculate that SARS-CoV-2 may have played a role in the development of ATM in this patient.

During his workup for ATM, this patient tested negative on repeat SARS-CoV-2 testing on hospital day one but tested positive for SARS-CoV-2 on hospital day four. Hence, it is difficult to ascertain whether the patient demonstrated post-infectious ATM as opposed to parainfectious ATM secondary to SARS-CoV-2. The diagnosis of parainfectious or post-infectious ATM relies upon a stepwise approach to rule out compressive etiologies as well as other inflammatory and non-inflammatory etiologies of ATM (Figure).

Our patient met the inclusion criteria for diagnosis of ATM based on bilateral motor symptoms and autonomic dysfunction with bladder incontinence along with evidence of CSF lymphocytic pleocytosis and characteristic MRI findings while ruling out other infectious, autoimmune, and connective tissue etiologies. Treatment of ATM must be individualized to the patient and underlying etiology that may have caused ATM. There are currently no established regimens for treatment of SARS-CoV-2 post-infectious or parainfectious transverse myelitis. Treatment for other infectious-mediated ATM include antivirals, antibiotics, corticosteroids, and IV immunoglobulin, but their efficacy has yet to be completely defined. Overall, a single case report is not robust enough to suggest a definitive link between ATM and SARS-CoV-2. More research and case reports are necessary to support a causal relationship. Despite this, clinicians must be aware of the possibility of an association with SARS-CoV-2 and be aware of the salient features of ATM for early diagnosis, workup, and potential treatment to prevent permanent disability.

CONCLUSION

In summary, we hypothesize that this patient's ATM was precipitated by SARS-CoV-2 leading to a diagnosis of post-infectious or parainfectious ATM. ATM has a varied presentation and is associated with significant morbidity and mortality that necessitates increased awareness and vigilance on part of the clinician. This article is the second reported case of ATM attributed to SARS-CoV-2 infection, and should serve to reinforce the unique presentations of SARS-CoV-2 and ATM.

The authors attest that their institution requires neither Institutional Review Board approval, nor patient consent for publication of this case report. Documentation on file.

Acute Transverse Myelitis



1 Incidence and Gender

Estimated to be between one and eight cases per million annually

Males and females equally affected, although some studies show a female predominance

2 Age and Gender

May occur at any age but mean age of onset ranges from thirty-five to forty years of age

Bimodal peak from ten to nineteen and from thirty to thirty-nine years has also been published

3 Prognosis

Highly variable, one-third of patients recover over a period of three months, one-third of patients have a severe, rapidly progressive course

Inclusion Criteria

- Sensory, motor, or autonomic dysfunction attributable to the spinal cord
- Bilateral signs/symptoms (does not need to be symmetric)
- Clearly defined sensory level
- Extra-axial compressive etiology excluded by imaging
- Evidence of inflammation within spinal cord through cerebrospinal fluids (CSF) findings of pleocytosis, elevated immunoglobulin G (IgG) index, or magnetic resonance imaging (MRI) gadolinium enhancement
- Progression of sign/symptoms to start of improvement between four hours and twenty-one days after initial symptom onset

Exclusion Criteria

- Previous history of spinal radiation within ten years
- Deficits consistent with thrombosis of anterior spinal artery
- Evidence of spinal cord arteriovenous malformation
- *Evidence of connective tissue disease, autoimmune disease, optic neuritis, or multiple sclerosis
- *Central nervous system manifestation of primary infectious disease (Syphilis, Lyme disease, Human Immunodeficiency Virus, Human T-cell lymphotropic virus, viral infections, etc.)
- *Can still be present with disease-associated acute transverse myelitis

Proposed Diagnostic Algorithm For Post-Infectious and Para-Infectious Transverse Myelitis

Non-Compressive Etiologies:

- Acquired demyelinating disorders, systemic autoimmune disorders, paraneoplastic syndromes
- Vascular, arteriovenous malformation, para-infectious, drugs and toxins
- Idiopathic, post-infectious, post-vaccination

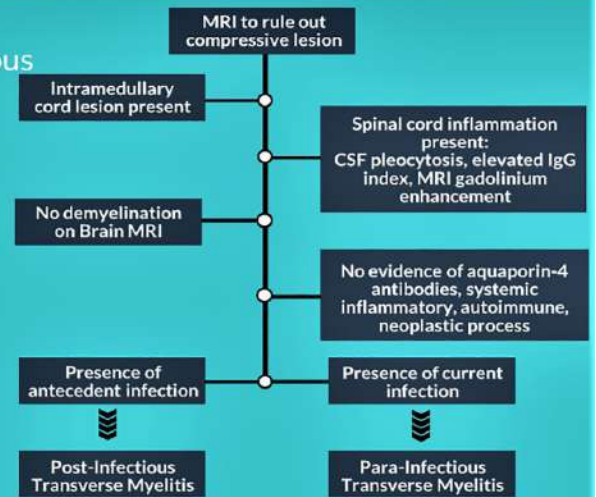


Figure. Summary of acute transverse myelitis and proposed diagnostic workup of post-infectious myelitis.

Address for Correspondence: Muhammad Durrani, DO, Inspira Medical Center, Department of Emergency Medicine, 1505 W. Sherman Ave, Vineland, NJ 08360. Email: durranim1@ihn.org.

Conflicts of Interest: By the CPC-EM article submission agreement, all authors are required to disclose all affiliations, funding sources and financial or management relationships that could be perceived as potential sources of bias. The authors disclosed none.

Copyright: © 2020 Durrani et al This is an open access article distributed in accordance with the terms of the Creative Commons Attribution (CC BY 4.0) License. See: <http://creativecommons.org/licenses/by/4.0/>

REFERENCE

1. Bohmwald K, Gálvez NMS, Ríos M, et al. Neurologic alterations due to respiratory virus infections. *Front Cell Neurosci.* 2018;12:386.
2. Altrocchi PH. Acute transverse myelopathy. *Trans Am Neurol Assoc.* 1963;88:186-8.
3. Misra UK, Kalita J, Kumar S. A Clinical, MRI and neurophysiological study of acute transverse myelitis. *J Neurol Sci.* 1996;138(1-2):150-6.
4. Klein N, Ray P, Carpenter D, et al. Rates of autoimmune diseases in Kaiser Permanente for use in vaccine adverse event safety studies. *Vaccine.* 2010;28(4):1062-8.
5. Borchers AT and Gershwin ME. Transverse myelitis. *Autoimmun Rev.* 2012;11(3):231-48.
6. Transverse Myelitis Consortium Working Group. Proposed diagnostic criteria and nosology of acute transverse myelitis. *Neurology.* 2002;59(4):499-505.
7. Turgay C, Emine T, Ozlem K, et al. A rare cause of acute flaccid paralysis: human coronaviruses. *J Pediatr Neurosci.* 2015;10(3):280-1.
8. St-Jean JR, Jacomy H, Desforges M, et al. Human respiratory coronavirus OC43: genetic stability and neuroinvasion. *J Virol.* 2004;78(16):8824-34.
9. Paniz-Mondolfi A, Bryce C, Grimes Z, et al. Central nervous system

- involvement by severe acute respiratory syndrome coronavirus-2 (SARS-CoV-2). *J Med Virol.* 2020;92(7):699-702.
10. Desforges M, Le Coupanec A, Dubeau P, et al. Human coronaviruses and other respiratory viruses: underestimated opportunistic pathogens of the central nervous system? *Viruses.* 2019;12(1):14.
 11. Herman C, Mayer K, Sarwal A. [Ahead of Print]. Scoping review of prevalence of neurologic comorbidities in patients hospitalized for COVID-19. *Neurology.* April 28, 2020.
 12. Zhao K, Huang J, Dai D, et al. Acute myelitis after SARS-CoV-2 infection: a case report. *medRxiv.* 2020. Available at: <https://www.medrxiv.org/content/10.1101/2020.03.16.20035105v1.full.pdf>. Accessed May 15, 2020.

Mixed Purpuric and Maculopapular Lesions in a Patient with COVID-19: A Case Report

Randall Beaupre II, MD
Cody Petrie, MD
Alexander Toledo, DO, Pharm D

Creighton University Arizona Health Education Alliance, Department of Emergency Medicine, Phoenix, Arizona

Section Editor: Rick A. McPheeters, DO

Submission history: Submitted June 8, 2020; Revision received June 10, 2020; Accepted June 17, 2020

Electronically published July 1, 2020

Full text available through open access at http://escholarship.org/uc/uciem_cpchem

DOI: 10.5811/cpcem.2020.6.48617

Introduction: The coronavirus disease of 2019 (COVID-19) caused by the novel severe acute respiratory syndrome coronavirus 2 is a global pandemic that expresses itself with a wide variety of presenting symptoms in patients. There is a paucity of literature describing the dermatologic manifestations of the virus, particularly in the United States.

Case Report: Here we present a case of COVID-19 that manifested with a purpuric rash on the lower extremities and a maculopapular eruption on the abdomen in a patient in acute diabetic ketoacidosis and normal platelet count.

Discussion: The reported presenting symptoms of patients with COVID-19 vary greatly. This is the first documented case of COVID-19 presenting with mixed cutaneous manifestations of a purpuric as well as maculopapular rash.

Conclusion: The cutaneous lesions associated with the COVID-19 infection may mimic or appear similar to other well-known conditions. We illustrate a case of COVID-19 infection presenting with purpuric rash on the lower extremities and a maculopapular rash on the abdomen. [Clin Pract Cases Emerg Med. 2020;4(3):349–351.]

Keywords: COVID-19; coronavirus; rash; dermatologic.

INTRODUCTION

The scant literature to date detailing the dermatologic manifestations of severe acute respiratory syndrome coronavirus 2 (SARS-CoV-2) (COVID-19) describes a presentation that can vary greatly. There have been case reports noting cutaneous lesions such as urticarial,^{1,2,3} a rash mistaken for dengue fever,⁴ and various plaques.⁵ The most comprehensive description of the cutaneous manifestations of COVID-19 to date has been reported by Galván Casas et al in a nationwide consensus study in Spain. This study describes five basic categories of rashes associated with COVID-19: erythema with vesicles or pustules; other vesicular eruptions; urticarial lesions; maculopapular eruptions; and livedo or necrosis.⁶ In our literature review we found a single case report published in April 2020 that described a patient presenting with COVID-19 and lower extremity purpura. Notably this patient was found to have thrombocytopenia (as low as

66,000 per cubic millimeter) and was diagnosed with concurrent immune thrombocytopenic purpura.² This study, and other case reports, have failed to describe the presence of purpuric lesions in conjunction with a maculopapular rash on the abdomen in a patient with COVID-19.

CASE REPORT

A 42-year-old Hispanic female with a history of insulin-dependent diabetes mellitus, hypertension, and asthma presented to the emergency department (ED) with four days of worsening abdominal pain, nausea with non-bloody, non-bilious vomiting and two days of rash. Abdominal pain was described as dull and burning in quality, constant in timing with brief periods of intensification, and generalized in location with notably worse pain in the epigastrium and suprapubic regions. The patient reported shortness of breath that she attributed to

the abdominal pain. With regard to her rash, she stated that it began on her lower extremities and had spread centrally to her abdomen and upper extremities. It was non-urticarial, painless, and spared the palms, feet and mucosal surfaces. She first noticed the rash approximately 12 hours prior to presentation.

History was also significant for diabetic medication non-compliance, as she stated she had not taken her medications for 2-3 months. Of note, the patient had finished a course of antibiotics the week prior for what she thinks may have been a urinary tract infection. However, further details regarding the antibiotic were unknown. The patient denied diarrhea, fever, chills, cough, and myalgias. She could not identify known sick contacts, and no one else in her family had similar symptoms at that time.

On initial evaluation in the ED, the patient's vital signs were notable for tachycardia to 120 beats per minute, tachypnea to 40 breaths per minute, and blood pressure elevated at 154/103 millimeters of mercury (mmHg). She was afebrile (36.5° Celsius), and oxygen saturation was 93% on room air. She looked ill appearing and was placed in a negative pressure room. Physical examination noted an obese, ill-appearing female who appeared to have Kussmaul respirations. Lungs were clear to auscultation, and cardiac exam was unremarkable. Her abdomen was soft, nondistended, and diffusely tender, most notably in the epigastrium and suprapubic regions but without rebound pain or guarding. Dermatologic examination was notable for a non-blanching purpuric rash on the distal lower extremities (Image 1), as well as a non-blanching maculopapular rash on the abdomen (Image 2).

Initial labs were notable for a platelet count of 660 thousand (K)/microliter (μL) (reference range 157-371 K/ μL), prothrombin time of 12.1 seconds (sec) (reference range 11.0-12.5 sec) and an international normalized ratio of 1.1 (reference range <1.1). The patient's chemistry profile showed a

severely decreased bicarbonate level of 7 millimoles (mmol)/liter (L) (reference range 22-26 mmol/L); glucose of 551 milligrams (mg)/deciliter (dL) (reference range 73-99 mg/dL); and an anion gap of 25 (reference range 3-10).

Based upon the patient's initial vital signs and presentation, we initiated a full sepsis workup. Chest radiograph was performed and demonstrated scattered, bilateral, hazy airspace opacities (Image 3). This was concerning for COVID-19 infection, and so the typical 30

CPC-EM Capsule

What do we already know about this clinical entity?

Five basic categories of rashes are associated with coronavirus disease of 2019 (COVID-19): erythema with vesicles or pustules; vesicular eruptions; urticarial lesions; maculopapular rash; and necrosis.

What makes this presentation of disease reportable?

In this case, COVID-19 infection presented with purpuric rash on the lower extremities and maculopapular rash on the abdomen.

What is the major learning point?

COVID-19 presentations may vary widely and mimic other diseases. The dermatologic manifestations may be more varied than previously thought.

How might this improve emergency medicine practice?

Early identification of COVID-19 cases based upon known clinical presentations is critical for appropriate patient care as well as public health outcomes.

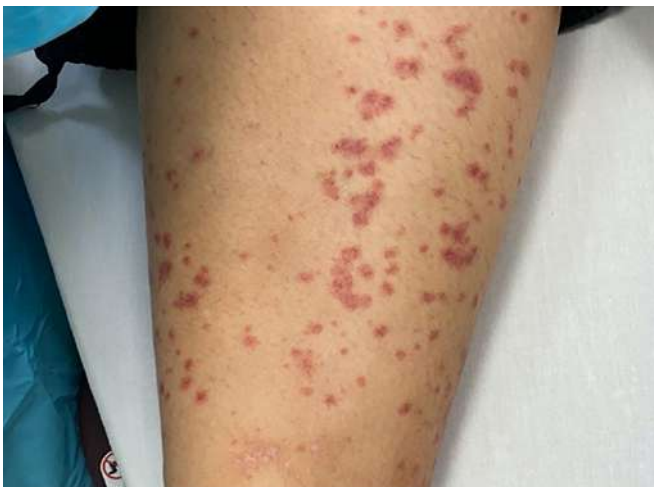

Image 1. Non-blanching purpuric rash on the bilateral lower extremities of a patient with COVID-19 with concurrent non-blanching maculopapular rash on the abdomen.

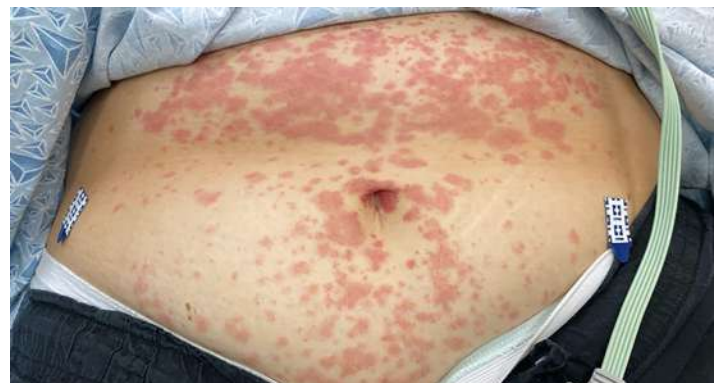

Image 2. Non-blanching maculopapular rash on the abdomen of a patient with COVID-19 with concurrent non-blanching purpuric rash on the bilateral lower extremities.

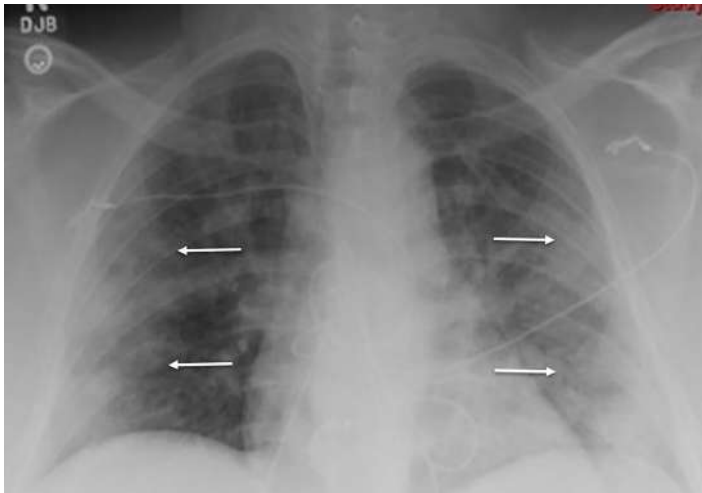


Image 3. Initial chest radiograph of a patient with COVID-19 showing scattered, bilateral, hazy airspace opacities (indicated by the arrows).

cubic centimeters per kilogram fluid bolus for sepsis was omitted. Initial laboratory values were consistent with diabetic ketoacidosis including a bicarbonate of 7.0 microequivalents/L (mEq/L), elevated anion gap of 25, and a blood glucose of 551mEq/L. Venous blood gas analysis demonstrated that the patient was acidotic with a pH of 7.216 (reference range 7.310 – 7.410). Additionally, her complete blood count revealed a leukocytosis of $13.3 \times 10^3/\mu\text{L}$ (reference range 4.5 – $11.0 \times 10^3/\mu\text{L}$), and an elevated lactic acid of 2.4 millimoles/L (reference range 0.5 – 2.0 mmol/L). Our institutional diabetic ketoacidosis protocol was initiated at this time including an insulin bolus followed by a regular insulin infusion along with maintenance intravenous fluids. The institutional nasopharyngeal COVID-19 rapid test resulted positive.

DISCUSSION

According to a study done in Wuhan, China, patients infected with COVID-19 occur in a male to female ratio of approximately 1:1 with a median age in the mid-50s.² The most common presenting symptoms of patients with test-confirmed COVID-19 were fever, cough, fatigue, and gastrointestinal symptoms. In this patient population, lymphopenia and eosinophilia were commonly found on laboratory testing. Early data has linked more severe infections with increased number of comorbidities; however, the presence of chronic obstructive pulmonary disease, asthma, and other allergic diseases were not risk factors for contracting the COVID-19 infection.³

An article based upon the Italian patient population showed that approximately 20% of patients with COVID-19 infections present with a rash.¹ This is the first documented case of COVID-19 presenting with mixed cutaneous manifestations of a purpuric as well as maculopapular rash. Further, unlike previous descriptions of patients with COVID-19 and a purpuric rash, this patient did not have thrombocytopenia or idiopathic

thrombocytopenic purpura.² Early identification of COVID-19 cases based upon known clinical presentations is critical for appropriate patient care as well as public health outcomes.

CONCLUSION

The presentation of patients with SARS-CoV-2 varies widely and is just now becoming more understood. The cutaneous lesions associated with this infection may mimic or appear similar to other well-known conditions. We illustrate a case of COVID-19 infection presenting with purpuric rash on the lower extremities and a maculopapular rash on the abdomen.

The authors attest that their institution requires neither Institutional Review Board approval, nor patient consent for publication of this case report. Documentation on file.

Address for Correspondence: Randall Beaupre II, MD, Valleywise Health Medical Center, Department of Emergency Medicine, Attn: Randall Beaupre, MD, 2601 E. Roosevelt St., Phoenix, AZ 85008. Email: randall.beaupre@valleywisehealth.org.

Conflicts of Interest: By the CPC-EM article submission agreement, all authors are required to disclose all affiliations, funding sources and financial or management relationships that could be perceived as potential sources of bias. The authors disclosed none.

Copyright: © 2020 Beaupre et al. This is an open access article distributed in accordance with the terms of the Creative Commons Attribution (CC BY 4.0) License. See: <http://creativecommons.org/licenses/by/4.0/>

REFERENCES

1. Recalcati S. Cutaneous manifestations in COVID-19: a first perspective. *J Eur Acad Dermatol Venereol.* 2020;34(5):e212.
2. Zhang JJ, Dong X, Cao YY, et al. [Ahead of Print]. Clinical characteristics of 140 patients infected with SARS-CoV-2 in Wuhan, China. *Allergy.* February 19, 2020.
3. Lu S, Lin J, Zhang Z, et al. [Ahead of Print]. Alert for non-respiratory symptoms of coronavirusdisease 2019 (COVID19) patients in epidemic period: a case report of familial cluster with three asymptomatic COVID-19 patients. *J Med Virol.* March 19, 2020.
4. Joob B and Wiwanitkit V. COVID-19 can present with a rash and be mistaken for dengue. *J Am Acad Dermatol.* 2020;82(5):e177.
5. Estebanez A, Perez-Santiago L, Silva E, et al. Cutaneous manifestations in COVID-19: a new contribution. *J Eur Acad Dermatol Venereol.* 2020;34(6):e250-1.
6. Galván Casas C, Català A, Carretero Hernández G, et al. [Ahead of Print] Classification of the cutaneous manifestations of COVID-19: a rapid prospective nationwide consensus study in Spain with 375 cases. *Br J Dermatol.* April 29, 2020.

A Case Report of Acute Motor and Sensory Polyneuropathy as the Presenting Symptom of SARS-CoV-2

Michael R. Kopscik, BS*
Barbra K. Giourgas, MD†
Bradley C. Presley, MD*

*Medical University of South Carolina, Department of Emergency Medicine, Charleston, South Carolina

†Medical University of South Carolina, Department of Neurology, Charleston, South Carolina

Section Editor: Rick A. McPheeters, DO

Submission history: Submitted June 12, 2020; Revision received June 15, 2020; Accepted June 17, 2020

Electronically published July 1, 2020

Full text available through open access at http://escholarship.org/uc/uciem_cpem

DOI: 10.5811/cpem.2020.6.48683

Introduction: Severe acute respiratory syndrome coronavirus 2 (SARS-CoV-2) typically presents with respiratory illness and fever, however some rare neurologic symptoms have been described as presenting complaints. We report a case of an acute motor and sensory polyneuropathy consistent with Miller-Fisher Syndrome (MFS) variant of Guillain Barre Syndrome (GBS) as the initial symptom.

Case Report: A 31-year old Spanish speaking male presents with two months of progressive weakness, numbness, and difficult walking. He had multiple cranial nerve abnormalities, dysmetria, ataxia, and absent lower extremity reflexes. An extensive workup including infectious, autoimmune, paraneoplastic, metabolic and neurologic testing was performed. Initially SARS-CoV-2 was not suspected based on a lack of respiratory symptoms. However, workup revealed a positive SARS-CoV-2 polymerase chain reaction test as well as presence of Anti-Ganglioside – GQ1b (Anti-GQ1b) immunoglobulin G antibodies.

Discussion: Miller Fisher syndrome (MFS) is a variant of Guillain-Barre syndrome (GBS) characterized by a triad of ophthalmoplegia, ataxia, and areflexia. The patient's exam and workup including Anti-GQ1b is consistent with MFS.

Conclusion: SARS-CoV-2 infection in patients can have atypical presentations similar to this neurologic presentation. Prompt recognition and diagnosis can minimize the risk of transmission to hospital staff and facilitate initiation of treatment. [Clin Pract Cases Emerg Med. 2020;4(3):352–354.]

Keywords: SARS-CoV-2; COVID; COVID-19; Miller Fisher syndrome; Guillain-Barré syndrome; motor and sensory polyneuropathy.

INTRODUCTION

Severe acute respiratory syndrome coronavirus 2 (SARS-CoV-2) typically presents with respiratory illness and fever; however, rare cases of isolated neurologic manifestations of this virus have been reported.¹ Here we report a case of an acute motor and sensory polyneuropathy consistent with Miller Fisher syndrome (MFS) variant of Guillain-Barré syndrome (GBS) as the presenting symptom of SARS-CoV-2.

CASE REPORT

A 31-year-old Spanish-speaking male with no significant past medical history presented to the emergency department (ED) with progressively worsening weakness, numbness, and difficulty walking. Approximately two months prior to presentation, he woke up and noticed some numbness in his right hand. One month later he noticed double vision. He started wearing an eye patch over one eye to help with symptoms of diplopia. He then started experiencing numbness in his right leg as well as

left facial weakness with dysarthria. About a week later, his symptoms progressed to numbness on the left upper and lower extremity, which prompted a visit to an outside hospital. His workup was reportedly normal including a magnetic resonance imaging (MRI) of the brain and lumbar puncture. His weakness and bilateral paresthesias progressed to the point that he was unable to ambulate, which prompted his current visit. The patient denied any trauma, headache, neck stiffness, loss of vision, fever, cough, or any other infectious symptoms. He denied any recent travel, sick contacts, or contacts with similar complaints.

On presentation to the ED his vital signs were within normal limits, and with the exception of a malar facial rash and abnormal neurologic exam, his physical exam was unremarkable. On neurologic exam, he was awake, alert, and oriented appropriately. On primary gaze there was left-eye adduction and cranial nerve VI palsy bilaterally with extraocular movements and vertical nystagmus. He had a unilateral, lower motor neuron cranial nerve VII palsy with left upper and lower hemifacial weakness, and also cranial nerve XII dysfunction with tongue deviation to the left. Overall his motor bulk was normal and strength was 5/5 in flexor and extensor groups of all four extremities. His sensation was intact to light touch and pinprick in all extremities. He had significant dysmetria with finger-nose-finger and heel-to-shin bilaterally, slightly worse on the left with decreased amplitude and discoordination on finger tapping and other rapidly alternating movements bilaterally. All upper extremity reflexes were intact; however, he had no patellar or Achilles reflexes; he had downgoing plantar reflex on the left. and mute plantar reflex on the right. He was unable to stand or test gait secondary to significant ataxia.

The patient was admitted and underwent an extensive workup including infectious, autoimmune, paraneoplastic, metabolic, and neurologic testing. MRI of his brain and lumbar spine were unremarkable. A computed tomography of his chest looking for neoplasm revealed a consolidation in his left lower lobe that prompted SARS-CoV-2 polymerase chain reaction testing and returned positive. Cerebrospinal fluid (CSF) studies revealed the presence of anti-ganglioside – GQ1b (Anti-GQ1b) immunoglobulin G antibodies (1:100), with lymphocytic predominance without albuminocytologic dissociation, and he subsequently was found to have positive immunoglobulin G (IgG) antibodies to COVID-19.

The patient was treated with convalescent plasma, tocilizumab, and intravenous immunoglobulin, in addition to extensive physical and occupational therapy. He had some mild subjective improvement in vision and coordination as well as return of patellar reflexes bilaterally; however, he required maximum assistance to ambulate on transfer to rehab facility.

DISCUSSION

MFS is a variant of GBS characterized by a triad of ophthalmoplegia, ataxia, and areflexia.² It was first recognized as a distinct clinical entity in 1956 and is observed in 1-5% of GBS cases in Western countries.^{2,3} While GBS

CPC-EM Capsule

What do we already know about this clinical entity?

Severe acute respiratory syndrome coronavirus 2 (SARS-CoV-2) is a novel coronavirus that has been found to have effects on multiple different systems throughout the body.

What makes this presentation of disease reportable?

Neurologic manifestations of SARS-CoV-2 have been reported, but this is the first case of acute motor and sensory polyneuropathy as the presenting complaint in emergency medicine literature.

What is the major learning point?

Maintaining a high suspicion and low threshold to test for SARS-CoV-2 is important to help minimize the spread of the disease.

How might this improve emergency medicine practice?

It is important to recognize the findings of neurologic syndromes and recognize their possible relationship to SARS-CoV-2.

is characterized by ascending flaccid paralysis, symptoms of cranial nerve dysfunction predominate in MFS. The majority of MFS cases present following viral or bacterial infections, although it has also been reported in conjunction with autoimmune and neoplastic disorders as well. One widely-cited study reported a median of eight days between the onset of infectious symptoms and neurologic symptoms.³ Sensory, motor, and autonomic nerve dysfunction in MFS patients reflect immune-mediated nerve damage, likely due to molecular mimicry between viral/bacterial antigens and ganglioside GQ1b. Anti-GQ1b antibodies are present in about 90% of patients with MFS and are absent in normal subjects, making this an ideal diagnostic marker.³ The overall clinical picture must be considered for accurate diagnosis, as 26% of GBS patients and 66% of Bickerstaff's brainstem encephalitis patients also test positive for these antibodies.

This patient's insidious onset of multiple cranial neuropathies, ataxia, and areflexia is suggestive of MFS, although his presentation was somewhat atypical. The presence of anti-GQ1b IgG antibodies (1:100) on CSF studies supports this diagnosis, despite the absence of expected albuminocytologic dissociation. Instead, lymphocytic predominance in this patient's CSF suggests a sustained immune response to viral

infection, SARS-CoV-2, within the CNS. This patient's tongue fasciculations and generalized muscle atrophy are also a clinical finding not typically associated with MFS. Electromyography nerve conduction studies will be helpful in understanding this physiology. Angiotensin-converting enzyme 2 has been identified as a receptor for SARS-CoV-2, which is present throughout the nervous system, likely a contributing mechanism of this patient's multiple neurologic manifestations.⁴

This patient lacked respiratory or infectious symptoms and presented exclusively with progressive neurologic deficits and an asymptomatic pulmonary infiltrate. In addition to the absence of expected symptoms, the extent of this patient's neurologic deficits is atypical in a previously healthy patient infected with SARS-CoV-2.^{1,5,6} Because of his unique presentation, the patient was not tested for SARS-CoV-2 until hospital day 3, and later for antibodies as part of an extensive workup.

CONCLUSION

Recognizing unique presentations of SARS-CoV-2 infection is especially pertinent for emergency physicians. This case highlights the importance of identifying SARS-CoV-2 infection in patients with atypical presentations, specifically multiple neurologic deficits, as this virus can exhibit multiple different neurologic manifestations. Prompt recognition and diagnosis of SARS-CoV-2 infection in the ED minimizes the risk of transmission to hospital staff and enables timely initiation of treatment to improve patient outcomes.

The authors attest that their institution requires neither Institutional Review Board approval, nor patient consent for publication of this case report. Documentation on file.

Address for Correspondence: Bradley C. Presley, Medical University of South Carolina, Department of Emergency Medicine, 169 Ashley Ave MSC 300, Charleston, SC 29425. Email: presley@musc.edu.

Conflicts of Interest: By the *CPC-EM* article submission agreement, all authors are required to disclose all affiliations, funding sources and financial or management relationships that could be perceived as potential sources of bias. The authors disclosed none.

Copyright: © 2020 Kopscik et al. This is an open access article distributed in accordance with the terms of the Creative Commons Attribution ([CC BY 4.0](http://creativecommons.org/licenses/by/4.0/)) License. See: <http://creativecommons.org/licenses/by/4.0/>

REFERENCES

1. Zhao H, Send D, Zhou H, et al. Guillain-Barré syndrome associated With SARS-CoV-2 infection: causality or coincidence? *Lancet Neurol.* 2020;19(5):383-4.
2. Fisher CM. An unusual variant of acute idiopathic polyneuritis (syndrome of ophthalmoplegia, ataxia and areflexia). *N Engl J Med.* 1956;255(2):57-65.
3. Mori M, Kuwabara S, Fukutake T, et al. Clinical features and prognosis of Miller Fisher syndrome. *Neurology.* 2001;56(8):1104-6.
4. Mao L, Jin H, Wang M, et al. [Ahead of Print]. Neurologic manifestations of hospitalized patients with coronavirus disease 2019 in Wuhan, China. *JAMA Neurol.* April 10, 2020.
5. Gutiérrez-Ortiz C, Méndez A, Rodrigo-Rey S, et al. [Ahead of Print]. Miller Fisher syndrome and polyneuritis cranialis in COVID-19. *Neurology.* April 17, 2020.
6. Fernández-Domínguez J, Ameijide-Sanluis E, García-Cabo C, et al. [Ahead of Print]. Miller-Fisher-like syndrome related to SARS-CoV-2 infection (COVID 19). *J Neurol.* May 26, 2020.

Point-of-care Ultrasound Detection of Cataract in a Patient with Vision Loss: A Case Report

Kyle Dornhofer, MD
Marawan Alkhattabi, MBBS
Shadi Lahham, MD, MS

University of California, Irvine Medical Center, Department of Emergency Medicine,
Orange, California

Section Editor: Scott Goldstein, MD

Submission history: Submitted January 18, 2020; Revision received April 26, 2020; Accepted April 30, 2020

Electronically published July 14, 2020

Full text available through open access at http://escholarship.org/uc/uciem_cpem

DOI: 10.5811/cpcem.2020.4.46597

Background: Point-of-care ocular ultrasound in the emergency department (ED) is an effective tool for promptly evaluating for several vision-threatening etiologies and can be used to identify more slowly progressing etiologies as well, such as cataract formation within the lens.

Case Report: A 62-year-old female presented to the ED with a two-day history of painless vision loss of the left eye as well as reduced vision for the prior 30 days.

Conclusion: Point-of-care ultrasound was performed and showed calcification of the lens consistent with cataract. [Clin Pract Cases Emerg Med. 2020;4(3):355–357.]

Keywords: *POCUS; ultrasonography; ocular; cataract; vision loss.*

INTRODUCTION

Vision loss is a common complaint encountered in the emergency department (ED) and frequently prompts further imaging or consultation. Point-of-care ultrasound (POCUS) is well suited for the rapid assessment of several potential etiologies ranging from acutely vision-threatening to slowly progressive or chronic. We present a case of an elderly female with vision loss who was evaluated with POCUS and found to have a cataract, a diagnosis rarely initially made in the ED. In this case, point-of-care ocular ultrasound rapidly guided further management and disposition.

CASE REPORT

A 62-year-old female presented to the ED with a two-day history of painless vision loss of the left eye. She reported gradual reduction in her vision over the prior 30 days, with a more dramatic reduction in her vision over the prior two days. She denied any eye pain, flashers, floaters, or diplopia. Past medical history was significant for cerebrovascular accident, hypertension, type 2 diabetes mellitus, and hypercholesterolemia. In the ED, physical exam was significant for chronic left facial droop with white

opacification of the left lens, a visual acuity of 20/30 in the right eye, and perception of light only in the left eye. Point-of-care ocular ultrasound using a linear probe (10 megahertz) in the ocular setting showed lens calcification consistent with cataract (Image).

Ophthalmology was consulted, and an anterior segment exam was performed. The right eye showed a diffuse grade 4 superficial punctate keratitis (SPK) with a grade 2 nuclear sclerotic cataract. In contrast, the left eye showed a grade 3 SPK with grade 4 mature cataract. The fundoscopic exam was normal in the right eye, while the left eye view was obscured due to the mature cataract. B-scan was performed by ophthalmology, again showing a significant cataract in the left eye. Outpatient follow-up with possible cataract extraction with intraocular lens implantation was recommended by ophthalmology.

DISCUSSION

Cataract is a clouding of the crystalline lens inside the eye. It is the leading cause of blindness and the most prevalent ocular disease worldwide.^{1,2} In the United States, it is the third leading cause of treatable blindness.^{3,4} Cataracts typically

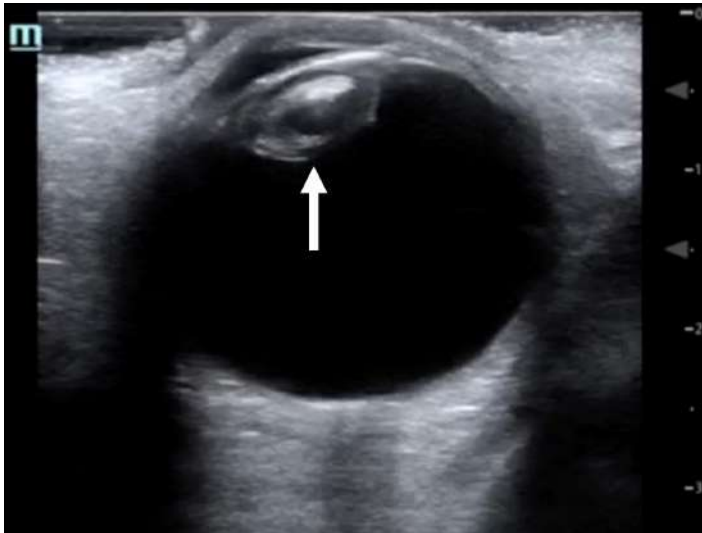


Image. Point-of-care ocular ultrasound image in the transverse plane, revealing lens calcification consistent with cataract (arrow).

occur gradually as a result of aging or secondary to trauma, inflammation, metabolic/nutritional disorders, or radiation, with age-related cataracts being the most common cause.^{5,6} Cataracts are considered one of the earliest complications of diabetes mellitus.⁷

Patients often present with gradually decreased vision and increased problems with glare. They may or may not experience changes in refractive error and loss of stereopsis (depth perception). In the ED the ocular exam should include pupil examination, assessment of extraocular muscles, measurement of visual acuity and intraocular pressure, and confrontational visual field testing.^{8,9} Measurement of visual acuity under both high and low illumination can be helpful. Definitive diagnosis is made with slit lamp examination and direct visualization of the cataract within the lens. Treatment consists of vision correction with lenses or surgery depending on the severity of the cataract.⁷

CONCLUSION

Point-of-care ocular ultrasound can be performed when there is concern for posterior globe pathology (i.e., retinal/vitreous detachment), but visualization of the back of the eye with the slit lamp is obscured due to an opaque lens or when eyelids are swollen shut following injury. Indications for ocular ultrasound include decreased vision/loss of vision, suspected foreign body, ocular pain, eye trauma, and head injury. POCUS provides a rapid and noninvasive evaluation for several vision-threatening ocular emergencies including globe perforation, retrobulbar hematoma, retinal detachment, lens subluxation, vitreous hemorrhage, and intraocular foreign body.¹⁰⁻¹² Occasionally, as in this case, cataract formation within the lens can be directly visualized with ultrasound.

CPC-EM Capsule

What do we already know about this clinical entity?

Cataract is the leading cause of blindness and the most prevalent ocular disease worldwide. Vision loss is a common complaint encountered in the emergency department.

What makes this presentation of disease reportable?

Point-of-care ultrasound (POCUS) was performed in a patient complaining of vision loss and showed findings consistent with cataract.

What is the major learning point?

POCUS is an effective tool for promptly evaluating a patient with complaints of vision loss.

How might this improve emergency medicine practice?

Ultrasound provides a rapid and noninvasive evaluation for several vision-threatening ocular emergencies.

The authors attest that their institution requires neither Institutional Review Board approval, nor patient consent for publication of this case report. Documentation on file.

Address for Correspondence: Shadi Lahham, MD, MS, University of California, Irvine Medical Center, Department of Emergency Medicine, 333 The City Boulevard West, Suite 640, Orange, CA 92668. Email: slahham@uci.edu.

Conflicts of Interest: By the CPC-EM article submission agreement, all authors are required to disclose all affiliations, funding sources and financial or management relationships that could be perceived as potential sources of bias. The authors disclosed none.

Copyright: © 2020 Dornhofer et al. This is an open access article distributed in accordance with the terms of the Creative Commons Attribution (CC BY 4.0) License. See: <http://creativecommons.org/licenses/by/4.0/>

REFERENCES

1. Thompson J and Lakhani N. Cataracts. *Prim Care*. 2015;42(3):409-23.
2. Foster A and Johnson GJ. Magnitude and causes of blindness in the developing world. *Int Ophthalmol*. 1990;14(3):135-40.
3. Dana MR, Tielsch JM, Enger C, et al. Visual impairment in a

- rural Appalachian community. Prevalence and causes. *JAMA*. 1990;264(18):2400-5.
4. Sommer A, Tielsch JM, Katz J, et al. Racial differences in the cause-specific prevalence of blindness in East Baltimore. *N Engl J Med*. 1991;325(20):1412-7.
 5. Datiles MB and Kinoshita JH. (1991). Pathogenesis of cataracts. In: Tasman W, Jaeger EA (eds). *Duane's Clinical Ophthalmology, Vol 1 (p. 1-14)*. Philadelphia, PA: JB Lippincott.
 6. Bunce GE. (1991). The role of nutrition in cataract. In: Tasman W, Jaeger EA (eds). *Duane's Clinical Ophthalmology, Vol 1 (p. 1-9)*. Philadelphia, PA: JB Lippincott.
 7. Klein BE, Klein R, Wang Q, et al. Older-onset diabetes and lens opacities. The Beaver Dam Eye Study. *Ophthalmic Epidemiol*. 1995;2(1):49-55.
 8. Juang PS and Rosen P. Ocular examination techniques for the emergency department. *J Emerg Med*. 1997;15(6):793-810.
 9. Gorovoy IR. Pearls in ophthalmology for the emergency nurse. *J Emerg Nurs*. 2015;41(1):19-22.
 10. Dewitz A. (2003). Soft tissue applications. In: Ma OJ, Mateer J (eds). *Emergency Ultrasound (p. 385)*. New York, NY: McGraw-Hill.
 11. Whitcomb MB. How to diagnose ocular abnormalities with ultrasound. *AAEP Proceedings*. 2002;48:272-5.
 12. Price DD, Simon BC, Park RS. Evolution of emergency ultrasound. *Cal J Emerg Med*. 2003;4(4):82-8.

A Case Report on Paget-Schroetter Syndrome Presenting as Acute Localized Rhabdomyolysis

Jonathan B. Lee, MD
Ami Kurzweil, MD
Shadi Lahham, MD, MS

University of California, Irvine Medical Center, Department of Emergency
Medicine, Orange, California

Section Editor: Steven Walsh, MD

Submission history: Submitted March 19, 2020; Revision received May 27, 2020; Accepted June 1, 2020

Electronically published July 14, 2020

Full text available through open access at http://escholarship.org/uc/uciem_cpem

DOI: 10.5811/cpcem.2020.6.47335

Introduction: The life- or limb-threatening differential diagnosis for upper extremity swelling can include deep vein thrombosis (DVT), infectious processes, and compartment syndrome. Chronic anatomic abnormalities such as axillary vein stenosis are rarely a consideration in the emergency department.

Case Report: We present a 26-year-old female with history of Chiari type 1 malformation who presented with acute left arm swelling. Initial workup, including point-of-care ultrasound, revealed the presence of significant soft tissue swelling without evidence of DVT.

Conclusion: Further workup revealed an early, localized rhabdomyolysis secondary to axillary vein stenosis or venous thoracic outlet syndrome, also known as Paget-Schroetter syndrome. [Clin Pract Cases Emerg Med. 2020;4(3):358–361.]

Keywords: *Paget-Schroetter syndrome; point-of-care ultrasound; axillary vein stenosis.*

INTRODUCTION

Venous stenosis can present with a number of clinical symptoms, including swelling, pain, numbness, discoloration, and paresthesias.¹ These non-specific symptoms can often lead physicians to consider more common life-threatening conditions such as venous thrombosis, lymphedema, or inflammatory processes. Notably, the upper extremities are more commonly affected by venous stenosis than the lower extremities, and among the most common vein to be affected is the axillary vein.² Venous strictures have been reported to be secondary to fibrosis from placement of central lines, prior radiation, trauma, or extrinsic compression from musculoskeletal structures. One known cause of axillary vein stenosis is venous thoracic outlet syndrome, also known as Paget-Schroetter syndrome.³ This condition typically presents in patients whose work or activities require prolonged repetitive motions of the arm, or in a patient with an acute traumatic injury to an upper extremity. Thoracic outlet syndrome has even been reported in patients with

cervicothoracic scoliosis and post spinal surgery patients,^{4,5} such as seen in this case report.

CASE REPORT

A 26-year-old female with history of Chiari type 1 malformation, status post intracranial shunt and scoliosis leading to cervical spinal fusion at age 10 presented with left upper arm swelling for seven hours. She stated there was mild, pressure-like sensation and endorsed associated radiating numbness to her fingertips. She denied any pain, but explained she had chronic baseline sensation deficits on the left side of her body as a sequelae from her cervical spinal fusion and thus had diminished ability to sense pain to her left upper extremity since the age of 10. She did not recall any inciting insult, repetitive movement during work or exercise, or trauma to the arm. The patient stated she had an etonogestrel/ethinyl estradiol vaginal ring placed approximately three months earlier and had not had any complications. Her only risk factor for venous thromboembolism was her contraception.

Upon arrival, her vital signs were all within normal limits. On physical exam she was calm and in no acute distress. Her left upper extremity was swollen circumferentially from the distal deltoid to the antecubital fossa, with the greatest area of swelling on the posterior-medial aspect of the left upper extremity overlying the triceps. Her left upper extremity had full passive and active range of motion without pain. Although she had decreased sensation, she reported no change from her baseline complications post cervical spinal fusion. She had 2+ distal radial and ulnar pulses. There was no increased warmth or erythema when compared to the right upper extremity, and she was without ecchymosis. She had five out of five grip strength bilaterally. Her left upper medial posterior compartment was moderately tense. The rest of her extremities had five out of five strength bilaterally.

Based on physical exam, the leading life-threatening diagnosis was upper extremity deep vein thrombosis (DVT). However, the patient had no other risk factors or clinical signs of DVT except for marked upper extremity swelling and etonogestrel/ethinyl estradiol vaginal ring. She was saturating well on room air, without any tachycardia or pleuritic chest pain, and thus initial suspicion for acute pulmonary embolism (PE) was low. Infection was thought to be unlikely given there was no overlying erythema, no warmth, and no systemic signs of infection. Compartment syndrome was considered but thought to be less likely given her compartments were mostly soft, and there was no history of trauma. Although, given the patient's baseline sensory deficits, occult trauma was still thought to be possible. Lymphedema was seen as less likely without any history of prior surgeries in the axilla that would place her at risk.

Initial work-up consisted of a complete blood count (CBC), basic metabolic panel (BMP), coagulation panel, a formal left upper extremity (LUE) DVT ultrasound performed by an ultrasound technician, and an electrocardiogram (ECG). The ECG was obtained to evaluate for any subtle signs of PE, given a diagnosis of DVT was in consideration. Her CBC and BMP were within normal limits. Her ECG revealed normal sinus rhythm, without evidence of right heart strain. Her formal LUE DVT ultrasound was negative for any venous thrombus (Image, panels 1 and 2).

This initial negative work-up prompted a point-of-care ultrasound (POCUS) to further evaluate the cause of swelling. Images were notable for soft tissue edema including pockets of interstitial fluid between the muscle bellies and perivascular fluid around veins of the upper arm, which upon review were also noticeable in images obtained by the ultrasound technician (Image, panel 3). These findings indicated a possible inflammatory process or a source of venous congestion from a more proximal source. Furthermore, POCUS revealed there were muscle fibers of mixed echogenicity along with notable disorganized muscle fibers, which upon review were also notable in images obtained from the ultrasound technician (Image, panel 4), which could have

CPC-EM Capsule

What do we already know about this clinical entity?

Venous thoracic outlet syndrome, also known as Paget's Schroetter's syndrome, can present acutely when mechanical compression of stenosed veins results in a subsequent effort thrombosis.

What makes this presentation of disease reportable?

In this case, the acute presentation was obscured by the patient's baseline sensory deficits to sensation and pain, resulting in the development of localized rhabdomyolysis.

What is the major learning point?

Ultrasound findings of interstitial edema and disorganized muscle fibers can point to a diagnosis of rhabdomyolysis or localized myositis.

How might this improve emergency medicine practice?

Performing point-of-care ultrasound or to reviewing images obtained by the technician may allow incorporation of clinical context and may lead to an expanded differential diagnosis.

been consistent with rhabdomyolysis.⁶ These findings prompted a D-dimer, which when resulted as abnormal, prompted both a computed tomography (CT) venography of the chest and upper extremities and CT angiogram of the chest. To assess for potential complications of venous congestion resulting in compressive ischemia such as rhabdomyolysis and early compartment syndrome, a serum creatinine kinase (CK) level was ordered.

Additional laboratory results revealed an elevated D-dimer 1860 milligrams per milliliter (mg/mL) (normal limit <500 mg/mL) and CK 7990 units per liter (U/L) (normal limit 30-223 U/L). With these results, the concern for complications such as rhabdomyolysis or compartment syndrome rose. The patient was started on intravenous fluids and aspirin. CT venogram revealed chronic severe luminal stricture of the left axillary vein. The rest of the veins of the chest and upper extremities were widely patent. CT angiogram was negative for PE or any arterial abnormality. The patient was admitted to the hospital with vascular surgery consultation.

During her inpatient stay, CK trended down from 7990 U/L to 1094 U/L over the next three days. The patient's arm

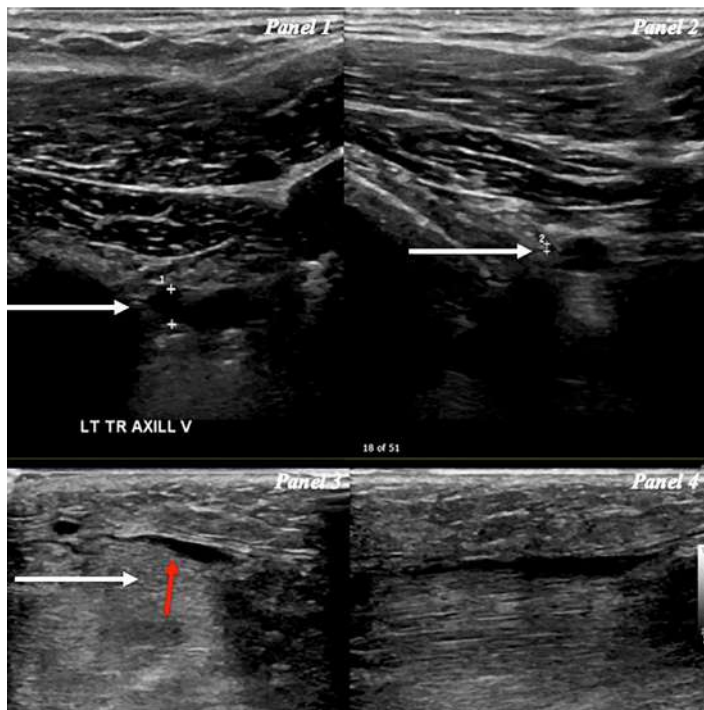


Image. Panel 1, Ultrasound Images obtained by radiology technician: Left axillary vein in the transverse plane (white arrow), showing full compressibility (panel 2) with overlaying soft tissue swelling. Panel 3 with left upper arm with diffuse soft tissue swelling (white arrow) and interstitial edema (red arrow). Panel 4 areas of mixed echogenicity along with disorganized muscle fibers, consistent with findings of rhabdomyolysis.

swelling improved throughout her hospitalization and remained well perfused without signs of worsening limb ischemia or compartment syndrome. Vascular surgery recommended no acute surgical intervention, discontinuation of use of the etonogestrel ethinyl estradiol vaginal ring, and a short course of aspirin. They arranged for close outpatient follow-up. Her case was discussed during vascular surgery case conference, a weekly educational conference in which attending and resident physicians discuss and provide recommendations for complex cases. Given her symptoms had resolved on re-evaluation two months after her admission, vascular surgery opted for continued conservative management and monitoring with repeat CT venograms.

DISCUSSION

Initially this patient presentation prompted concern for DVT of the upper extremity, which included a limited work up with CBC, BMP, coagulation panel, ECG, and LUE DVT ultrasound. When the work-up results were negative, reevaluation with POCUS allowed the physician to visualize abnormalities. Ultrasound findings revealed interstitial edema in the soft tissues, between muscle bellies and adjacent to vasculature. In addition, disorganized

muscle fibers with surrounding fluid were seen, raising the suspicion for rhabdomyolysis or, more rarely, a localized inflammatory myositis.⁷ It was suspected that a more proximal venous occlusion resulting in distal congestion was the cause, prompting additional lab tests with D-dimer and CK.

Given an elevated D-dimer at this point had resulted, the decision was made to add on both CT angiogram to assess for PE and CT venogram to assess for more proximal DVT that might have been missed on ultrasound. Furthermore, ultrasound is often technician-dependent and relies on radiological interpretation. Given upper extremity ultrasounds for DVT are less commonly performed compared to lower extremity ultrasound for DVT, there is a greater possibility of technical and interpretative error. The expanded work-up with CT venogram led to the diagnosis of an axillary vein stenosis, resulting in venous congestion of the upper extremity, and localized rhabdomyolysis.

Initial management included intravenous fluids, aspirin and surgical consultation. Had there been a definitive thrombosis identified on imaging, heparin could have been initiated. Other complications, just as with any thrombosis, may include phlegmasia alba dolens, venous gangrene, and embolization. The extent of the DVT may also indicate the need for further consultations with interventional radiology for thrombectomy vs catheter-directed thrombolysis.

Initially, venous thromboembolism was a consideration given the patient had recently started an estrogen-releasing vaginal ring lending to a hypercoagulable state. However, the cause of the patient's venous stenosis was likely attributable to anatomic compression in the form of venous thoracic outlet syndrome. Although there was no clearly defined association, the patient's scoliosis and history of cervical spinal fusion may have provided some rationale for the possibility of abnormal anatomy resulting in a compression or stenosis of her axillary vein. Furthermore, given her baseline sensory deficits, occult injury to the patient's upper extremity could have led to an anatomic deformity resulting in compression of the vein and acute occlusion within the thoracic outlet.

In this case, the patient attributed her left upper extremity sensory deficits to her cervical spinal fusion. However, chronic neurogenic thoracic outlet syndrome with an acute on chronic venous thoracic outlet syndrome was also considered. Neurogenic thoracic outlet syndrome accounts for 95-99% of all cases of thoracic outlet syndrome, while venous and arterial cases account for 3-5% and 1-2%, respectively.^{8,9} Furthermore, neurogenic thoracic outlet syndrome most commonly presents with symptoms such as upper extremity paresthesia (98%), neck pain (88%), trapezius pain (92%), and shoulder pain (88%), all of which the patient was found to have on subsequent interview in follow-up.¹⁰ However, given the patient did not have any evidence of brachial plexus compression on CT, this alternative diagnosis is less likely.

CONCLUSION

This patient likely had venous thoracic outlet syndrome, also known as Paget-Schroetter syndrome, which can present acutely when mechanical compression of stenosed veins from occult injury, repetitive movements of the arm, or stressful positioning results in stagnation of blood flow, and thus a subsequent “effort” thrombosis.¹ Although no definitive blood clot was identified on ultrasound or CT, it is postulated that the patient’s acute symptomatology was due to a short-lived effort thrombosis of a chronically strictured axillary vein. This is evidenced by the elevated D-dimer, but limited given the lack of specificity of D-dimer for thrombosis. Furthermore, given the patient’s symptoms resolved spontaneously without surgical intervention, a short-lived thrombosis seems the most likely explanation for her acute presentation. Although the patient denied any trauma, this was difficult to ascertain given her baseline sensory deficits. She may have been prone to occult trauma or even stressful positioning such as during sleep resulting in an acute compression to a chronically stenosed vein.

This case highlights the importance of maintaining a high clinical suspicion for rhabdomyolysis or compartment syndrome in patients with baseline sensory deficits. In addition, when imaging results are unremarkable and do not correlate with the clinical picture, have a low threshold to apply POCUS to further reveal specific concerns or expand the differential diagnosis. In this patient who presented with left upper extremity swelling, POCUS elucidated findings that led to further testing and treatment of rhabdomyolysis and diagnosis of Paget-Schroetter syndrome by CT venogram.

The authors attest that their institution requires neither Institutional Review Board approval, nor patient consent for publication of this case report. Documentation on file.

REFERENCES

1. Jones MR, Prabhakar A, Urits I, et al. Thoracic outlet syndrome: a comprehensive review of pathophysiology, diagnosis, and

Address for Correspondence: Jonathan B. Lee, MD, University of California, Irvine Medical Center, Department of Emergency Medicine, 333 The City Boulevard West, Suite 640, Orange, CA 92868. Email: jonathanbl@uci.edu.

Conflicts of Interest: By the CPC-EM article submission agreement, all authors are required to disclose all affiliations, funding sources and financial or management relationships that could be perceived as potential sources of bias. The authors disclosed none.

Copyright: © 2020 Lee et al. This is an open access article distributed in accordance with the terms of the Creative Commons Attribution (CC BY 4.0) License. See: <http://creativecommons.org/licenses/by/4.0/>

- treatment. *Pain Ther.* 2019;8(1):5-18.
2. Chan AW and Chi YW. Venous stenosis. *Guide to Peripheral and Cerebrovascular Intervention.* 2004. Available at: <https://www.ncbi.nlm.nih.gov/books/NBK27375/>. Accessed June 1, 2020.
3. Williams TK, Harthun N, Herbert I. (2013). *Vascular Medicine: A Companion to Braunwald’s Heart Disease (2nd ed).* Philadelphia, PA: Elsevier/Saunders.
4. Wang XT, Yao M, Zhong M, et al. Thoracic outlet syndrome in a postoperative cervical spondylotic myelopathy patient: a case report. *Medicine (Baltimore).* 2019;98(11):e14806.
5. Tomsick TA, Ahlstrand RA, Kiesel TM. Thoracic outlet syndrome associated with rib fusion and cervicothoracic scoliosis. *J Can Assoc Radiol.* 1974;25(3):211-3.
6. Nassar A, Talbot R, Grant A, et al. Rapid diagnosis of rhabdomyolysis with point-of-care ultrasound. *West J Emerg Med.* 2016;17(6):801-4.
7. Anand ŁS and Kosiak W. Sonographic appearance of rhabdomyolysis: a systematic review of the literature. *Med Ultrason.* 2020;22(1):92-6.
8. Freischlag J and Orion K. Understanding thoracic outlet syndrome. *Scientifica (Cairo).* 2014;2014:248163.
9. Stewman C, Vitanzo PC, Harwood MI. Neurologic thoracic outlet syndrome: summarizing a complex history and evolution. *Curr Sports Med Rep.* 2014;13(2):100-6.
10. Sanders RJ, Hammond SL, Rao NM. Diagnosis of thoracic outlet syndrome. *J Vasc Surg.* 2007;46(3):601-4.

Intracavernous Internal Carotid Artery Aneurysm Presenting as Acute Diplopia: A Case Report

Austin Brown, DO*
Heath Jolliff, DO*
Douglas Poe, DO*
Michael Weinstock, MD*†

*Adena Regional Medical Center, Department of Emergency Medicine, Chillicothe, Ohio

†Wexner Medical Center at The Ohio State University, Department of Emergency Medicine, Columbus, Ohio

Section Editor: Rick A. McPheeters, DO

Submission history: Submitted September 18, 2019; Revision received March 10, 2020; Accepted March 13, 2020

Electronically published July 20, 2020

Full text available through open access at http://escholarship.org/uc/uciem_cpem

DOI: 10.5811/cpcem.2020.3.45266

Introduction: Diplopia is an uncommon emergency department (ED) complaint representing only 0.1% of visits, but it has a large differential. One cause is a cranial nerve palsy, which may be from a benign or life-threatening process.

Case Report: A 69-year-old female presented to the ED with two days of diplopia and dizziness. The physical exam revealed a sixth cranial nerve palsy isolated to the left eye. Imaging demonstrated an intracavernous internal carotid artery aneurysm. The patient was treated with embolization by neurointerventional radiology.

Discussion: The evaluation of diplopia is initially divided into monocular, usually from a lens problem, or binocular, indicating an extraocular process. Microangiopathic disease is the most common cause of sixth nerve palsy; however, more serious etiologies may be present, such as an intracavernous internal carotid artery aneurysm, as in the patient described. Imaging modalities may include computed tomography or magnetic resonance imaging.

Conclusion: Some causes of sixth nerve palsy are benign, while others will require more urgent attention, such as consideration of an intracavernous internal carotid artery aneurysm. [Clin Pract Cases Emerg Med. 2020;4(3):362–365.]

Keywords: *Sixth cranial nerve palsy; diplopia; intracavernous internal carotid artery.*

INTRODUCTION

Dizziness, imbalance, vertigo, or lightheadedness account for over 4.3 million emergency department (ED) visits annually in the United States;^{1,2} vision changes, such as double vision or diplopia, represent 0.1% of ED visits.³ The initial differentiation of a “double vision” visit is to determine monocular vs binocular diplopia; this will help focus the urgency of imaging, diagnostic testing and disposition. The most common source of diplopia, accounting for 50% of diagnosis, is from an isolated cranial nerve palsy involving the sixth cranial nerve (abducens nerve).⁴ A diagnosis of sixth cranial nerve palsy can often be referred to neurology in an

urgent manner; however, with certain risk factors and associated symptoms further imaging in the ED may be warranted.

One pathology that may cause an isolated sixth cranial nerve palsy is an intracavernous internal carotid artery aneurysm, which is present in only 3% of cases of dizziness.⁵ We present a case where a 69-year-old female presented to the ED with dizziness secondary to diplopia. The only significant finding on physical exam was a left sixth cranial nerve palsy.

CASE REPORT

A 69-year-old female presented to the ED with two days of dizziness and double vision that was present only when both

eyes were open and resolved when she closed one or both eyes. She denied any concomitant symptoms such as headache, neck pain, paresthesia, numbness, or weakness. Approximately five days prior to ED evaluation the patient was diagnosed with otitis media and sinusitis at an urgent care and placed on cephalexin. The patient had no neurological symptoms present at that time.

On physical examination the patient was afebrile with pulse of 64 beats per minute, respiratory rate of 16 respirations per minute, blood pressure of 150/83 millimeters of mercury, and oxygen saturation of 96% on room air. The neck, lung, heart, and abdominal exams were normal. Visual acuity was 20/30 in the right eye and 20/25 in the left eye with correction. Ocular exam demonstrated a left lateral gaze palsy of the left eye (Image 1). No other extraocular deficits were identified. The neurologic exam revealed the patient to be alert and oriented to person, place, and time with a Glasgow Coma Scale of 15. No other cranial nerve or neurologic deficits were present. The differential diagnosis included direct sixth nerve compression due to intracranial pathology, intracranial ischemia, carotid artery aneurysm or dissection, and cavernous sinus vasculitis.

A computed tomography (CT) angiography of the head and neck were considered; however, because the patient was allergic to intravenous contrast, we obtained non-contrast magnetic resonance imaging (MRI) of the brain and MR angiography of the brain and neck that demonstrated a large, partially thrombosed left cavernous internal carotid artery aneurysm measuring up to 2.7centimeter (cm) x 2.0cm x 2.1 cm resulting in compression of the sixth cranial nerve (Image 2).

The neurointerventional radiologist was consulted and successfully pipeline embolized the thrombosis. On three-month follow-up the patient's vision was reported to be intact with

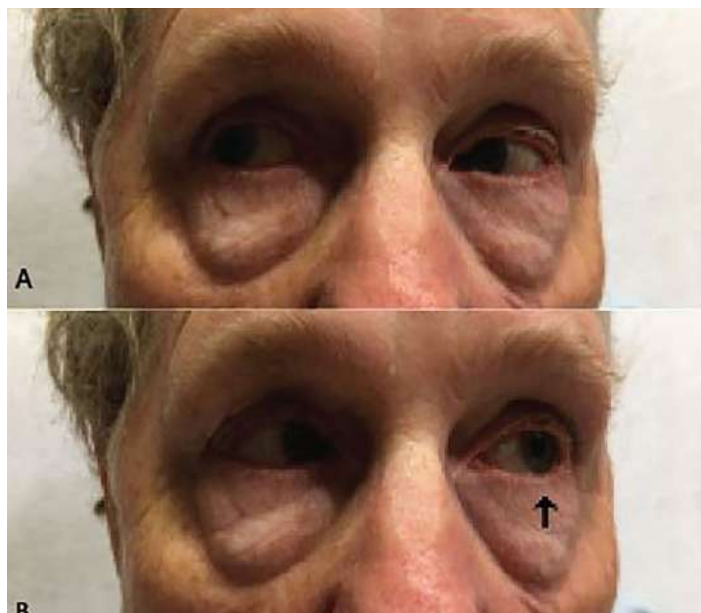

Image 1. Lateral gaze testing. (A) Right lateral gaze test normal. (B) Left lateral gaze demonstrating left ocular lateral gaze palsy (arrow).

CPC-EM Capsule

What do we already know about this clinical entity?

Sixth cranial nerve palsies are commonly benign but some findings may need further investigation and sometimes involving advanced imaging.

What makes this presentation of disease reportable?

Sixth cranial nerve palsies can be caused by an intracavernous internal carotid artery aneurysm, which needs urgent intervention.

What is the major learning point?

Dizziness is a common emergency department presentation where a full neurological exam including testing all cranial nerves must be done to rule out urgent pathology.

How might this improve emergency medicine practice?

Sixth cranial nerve palsies, although mostly benign, may need advanced imaging where urgent intervention is needed.

resolution of the diplopia and dizziness. The patient continued to have a slight residual left sixth nerve palsy on physical exam.

DISCUSSION

The differential for diplopia starts by determining whether the diplopia is monocular, which implicates an intraocular/lens abnormality, or binocular, which indicates an extraocular process. Binocular diplopia results from ocular misalignment, which can be secondary to impaired neuromuscular control of the medial rectus muscle, lateral rectus muscle, or both.⁶ Sixth nerve palsy can be differentiated into six syndromes based on where the nerve travels anatomically (summarized in the table).

Among patients presenting with an eye movement abnormality, a sixth cranial nerve palsy is the most common, representing 50% of cases.⁴ The most common cause of sixth cranial nerve palsy is microangiopathic disease with increased incidence in patients with hypertension and older age⁷; other etiologies include trauma, demyelination and, rarely, neoplasms.⁸ Most causes spontaneously resolve within 2-3 months.⁹ The decision of whether to image the head or neck in the non-traumatic, isolated sixth nerve palsy should be a case-by-case decision. The ophthalmology literature recommends that patients above the age of 50 with risk factors including diabetes or multiple sclerosis may be treated conservatively with

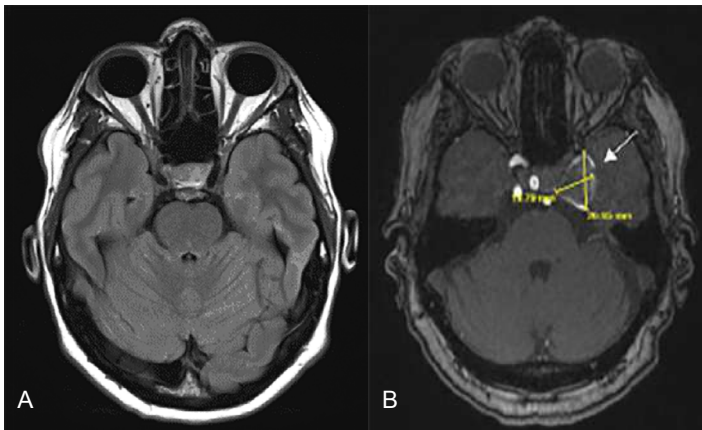


Image 2. Internal carotid artery aneurysm. (A) Normal brain magnetic resonance imaging (MRI) (image courtesy: Prof. Frank Gaillard, Radiopedia.org) (B) Patient's MRI showing thrombosed internal carotid artery aneurysm.

management focusing on underlying systemic conditions, and immediate neuroimaging may be delayed.¹⁰ However, contrast CT or MRI is indicated in patients with other neurological symptoms or signs, patients less than 50 years of age (older patients are more likely to have microangiopathic disease), symptoms that are present for longer than 2-3 months, or if there is diagnostic uncertainty.¹¹

The clinical course of an intracavernous carotid aneurysm can be variable and clinical progression can occur; however, symptomatic aneurysms can also improve spontaneously.¹¹ Cranial nerve palsies are among the most common complications of intracavernous internal carotid aneurysm.¹¹ Cranial nerves that transverse the cavernous sinus include the oculomotor (third cranial nerve), trochlear nerve (fourth cranial nerve), the ophthalmic and maxillary branches of the trigeminal nerve (fifth cranial nerve) and the abducens (sixth cranial nerve).¹² The diagnosis of an intracavernous carotid aneurysm in an isolated sixth nerve palsy presentation is rare, occurring in up to 3% of cases.⁵

Patients with intracavernous carotid artery aneurysms may be managed with coil embolization, balloon occlusion, or a new technique that involves pipeline diversion.¹³ This novel treatment is now becoming more popular. Three-year follow-up studies have shown that pipeline embolization is safe and effective in the treatment of complex large and giant aneurysms of the intracranial internal carotid artery.¹⁰

CONCLUSION

The isolated sixth nerve palsy although normally benign can be caused by an emergent pathology such as an intracavernous internal carotid artery aneurysm as presented in this case. When a patient with diplopia presents to the ED, the physician must use careful history-taking and physical exam skills to find even the most subtle findings to better diagnose and possibly treat a life-threatening pathology.

Table. Sixth nerve palsy differentiation.⁵

Sixth Nerve Palsy Syndromes	Description
1. Brain stem syndrome	Compressive, ischemic, inflammatory or degeneration within the brain stem
2. Elevated intracranial pressure syndrome	Increased pressures in subarachnoid space caused by hemorrhage, infections, or infiltrates
3. Petrous apex syndrome	Compression under petroclinoid ligament
4. Cavernous sinus syndrome	Pathologies involving the cavernous sinus include nasopharyngeal carcinoma, intracavernous internal carotid aneurysm, carotid cavernous fistula, Tolosa-Hunt syndrome, and meningioma
5. Orbital syndrome	Commonly seen with proptosis and is frequently accompanied by congestion of conjunctival vessels and conjunctival chemosis
6. Isolated 6th nerve palsy syndrome	Only lateral rectus weakness and no historical data to implicate a specific pathology

Documented patient informed consent and Institutional Review Board exemption has been obtained and filed for publication of this case report.

Address for Correspondence: Austin Brown, DO, Adena Regional Medical Center, Department of Emergency Medicine, 446 Hospital Road, Chillicothe, OH 45601. Email: austin.brown.do@gmail.com.

Conflicts of Interest: By the CPC-EM article submission agreement, all authors are required to disclose all affiliations, funding sources and financial or management relationships that could be perceived as potential sources of bias. The authors disclosed none.

Copyright: © 2020 Brown et al. This is an open access article distributed in accordance with the terms of the Creative Commons Attribution (CC BY 4.0) License. See: <http://creativecommons.org/licenses/by/4.0/>

REFERENCES

- Saber T, Coughlan D, Hsieh YH, et al. Rising annual costs of dizziness presentations to U.S. emergency departments. *Acad Emerg Med.* 2013;20(7):689-96.
- Newman-Toker DE, Hsieh YH, Camargo CA Jr, et al. Spectrum of dizziness visits in US emergency departments: cross-sectional analysis from a nationally representative sample. *Mayo Clin Proc.*

- 2008;83(7):765-75.
3. Nazerian P, Vanni S, Tarocchi C, et al. Causes of diplopia in the emergency department: diagnostic accuracy of clinical assessment and of head computed tomography. *Eur J Emerg Med.* 2014;21(2):118-24.
 4. Koskas P and Héran F. Towards understanding ocular motility: III, IV and VI. *Diagn Intervent Imaging.* 2013;94(10):1017-31.
 5. Azrmina M and Azarmina H. The six syndromes of the sixth cranial nerve. *J Ophthalmic Vis Res.* 2013;8(2):160-71.
 6. Rucker J and Tomsak R. Binocular diplopia: a practical approach. *Neurologist.* 2005;11(2):98-110.
 7. Okroglic S, Widmann CN, Urgach H, et al. Clinical symptoms and risk factors in cerebral microangiopathy patients. *PLoS One.* 2013;8(2):e53455.
 8. Margolin E and Lam C. Approach to a patient with diplopia in the emergency department. *J Emerg Med.* 2018;54(6):799-806.
 9. Elder C, Hainline C, Galetta S, et al. Isolated abducens nerve palsy: update on evaluation and diagnosis. *Curr Neurol Neurosci Rep.* 2016;16(8):69.
 10. Becske T, Potts M, Shapiro M, et al. Pipeline for uncoilable or failed aneurysms: 3-year follow-up results. *J Neurosurg.* 2018;127(1):81-8.
 11. Linskey ME, Sekhar LN, Hirsch W Jr, et al. Aneurysms of the intracavernous carotid artery: clinical presentation, radiographic features, and pathogenesis. *Neurosurgery.* 1990;26(1):71-9.
 12. Massa RN, Minutello K, Mesfin FB. (2020). Neuroanatomy, Cavernous Sinus. In: *StatPearls.* Treasure Island, FL: StatPearls Publishing.
 13. van Rooij WJ. Endovascular treatment of cavernous sinus aneurysms. *Am J Neurorad.* 2012;33(2):323-6.

Detection of Migrainous Infarction with Formal Visual Field Testing: A Case Report

William Bylund, MD*
Ross Patrick, DO†
Ann Macdonald, OD‡

*Naval Hospital Okinawa, Department of Emergency Medicine, Okinawa, Japan
†Naval Hospital Okinawa, Department of Internal Medicine, Okinawa, Japan
‡Naval Hospital Okinawa, Department of Optometry, Okinawa, Japan

Section Editor: Christopher Sampson, MD

Submission history: Submitted January 2, 2020; Revision received April 18, 2020; Accepted April 30, 2020

Electronically published July 9, 2020

Full text available through open access at http://escholarship.org/uc/uciem_cpem

DOI: 10.5811/cpcem.2020.4.46387

Introduction: Cerebrovascular accidents (CVA) of the posterior circulation are a rare complication of migraine, and present with atypical CVA symptomatology.

Case Report: A 49-year-old-male presented with complaint of persistent visual aura and resolved mild cephalgia. His exam corroborated his reported incomplete left inferior quadrantanopia, and was confirmed by immediate formal optometry evaluation. Occipital CVA was confirmed on admission.

Conclusion: Migrainous strokes of posterior circulation should be considered as a potential diagnosis in any headache patient with persistent visual aura. This case suggests that incorporation of formal visual field testing in the emergent setting can shorten the time required for diagnosis in certain circumstances. [Clin Pract Cases Emerg Med. 2020;4(3):366–370.]

Keywords: *cerebrovascular accident; homonymous hemianopsia; migraine.*

INTRODUCTION

Posterior circulation ischemic stroke syndromes comprise approximately 20% of stroke syndromes, and often present with atypical symptoms when compared to anterior or middle circulation ischemic strokes.¹ However, most strokes do affect the visual pathway, some causing oculomotor deficits, while up to 70% result in decreased visual acuity.² This high percentage is not surprising when one considers the multiple anatomic regions involved in visual processing, visuospatial reasoning, and oculomotor control. Information from the retina travels through the optic nerves, optic chiasm, optic tracts, lateral geniculate nuclei, and the optic radiations, before finally arriving to the visual cortex in the occipital lobes. Each of these structures is vulnerable to ischemia with variable clinical effects. Although the posterior circulation only supplies 20% of the brain, it is critical to consciousness, movement, and visual processing in the occipital cortex.^{1,3}

Acute ischemic strokes are considered an essential diagnosis to make quickly in the emergency department (ED),

in part because of their significant morbidity and mortality. There are nearly 800,000 strokes annually in the United States, and approximately 17% result in death.³⁻⁴ Given the magnitude of the problem, the American Heart Association has established multidisciplinary programs to improve outcomes.⁵ In the 1990s, the National Institutes of Health Stroke Scale (NIHSS) was developed to better assess cerebrovascular accident (CVA) severity, although the NIHSS does not well assess posterior circulation strokes.¹ Migrainous infarctions are a rare complication of migraines, representing only 0.2-0.5% of all ischemic strokes.⁶ According to the International Classification of Headache Disorders, migrainous infarction is defined as “One or more migraine aura symptoms occurring in association with an ischemic brain lesion in the appropriate territory demonstrated by neuroimaging, with onset during the course of a typical migraine with aura attack.”⁷ The following case demonstrates an unusual presentation of CVA that qualifies as a migrainous infarction. Visual field images demonstrate the diagnostic value of objective optometry evaluation.

CASE REPORT

A 49-year-old male with relevant medical history of migraines and hyperlipidemia (for which he was on 20 milligram [mg] daily atorvastatin) presented to our hospital after approximately 12 hours of decreased vision in his left lower visual field. Patient's history was notable for this quadrantanopia being consistent with prior migraines; however, he decided to present to the ED as this presentation was significantly different from his usual migraine duration. The headache had nearly resolved on presentation to the ED, but the patient still complained of decreased vision. The majority of the patient's exam was normal, including vital signs, cranial nerves II-XII, coordination, gait and balance. Confrontational visual fields were concerning for possible incomplete left inferior homonymous quadrantanopia. His electrocardiogram demonstrated normal sinus rhythm with no ischemic changes. Non-contrast computed tomography (CT) of the head was obtained and revealed no bleeding or mass. Magnetic resonance imaging (MRI) of the brain was ordered, but was not immediately available. Optometry service was consulted to confirm visual field defects and performed the Humphrey visual field 24-2 Swedish Interactive Threshold Algorithm Fast, which tests 54 visual field data points per eye and takes approximately five minutes to perform depending on the reliability of the test and size of the defect. Test reliability aids the provider in assigning diagnostic value. The optometrist's exam was reliable and consistent with left inferior incomplete homonymous quadrantanopia (Image 1). The patient was administered 324 mg of chewable aspirin but given his delayed presentation and low NIHSS, systemic thrombolytics were not administered. After consultation with internal medicine, the patient was admitted to a telemetry-capable ward for further evaluation and management.

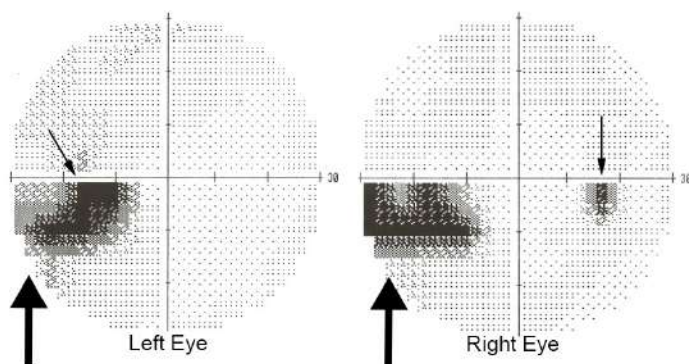


Image 1. Visual field tests via Humphrey visual field 24-2 Swedish Interactive Threshold Algorithm Fast algorithm: At left, the large arrow points to a clustered inferior temporal visual field defect adjacent and inferior to the anatomic blind spot (small arrow). At right, the large arrow points to a nasal inferior defect, while the clustered inferior temporal points correlate the anatomic blind spot (small arrow). Together, these images demonstrate a homonymous defect secondary to infarct.

CPC-EM Capsule

What do we already know about this clinical entity?

Migraines are associated with cerebrovascular accidents (CVA); isolated quadrantanopia leading to a stroke diagnosis has only been described once previously.

What makes this presentation of disease reportable?

This is the second case of migrainous infarction presenting with isolated visual field deficit and highlights the utility of formal visual field testing.

What is the major learning point?

Physicians should consider CVA in the setting of migraine, and use formal visual field testing to delineate a suspected homonymous defect when magnetic resonance imaging is unavailable.

How might this improve emergency medicine practice?

Improved recognition of acute CVA presentation and potential diagnostic modalities can improve timely diagnosis, enabling earlier treatment in certain instances.

A brain MRI with angiography was obtained the following day, which demonstrated acute cerebral infarction within the medial aspect of the right occipital lobe and small infarcts within the right cerebellum and the vermis (Image 2). There was also 50% luminal narrowing at the origin of the left vertebral artery, and scattered narrowing of less than 50% in the bilateral internal carotid arteries.

The following day, the patient reported no change in his visual symptoms. Neurology recommended increase of his aspirin to 325 mg daily as well as continuation of atorvastatin increased to 80 mg daily. Transthoracic echocardiogram was performed, and a two-day Holter (followed by 12-day cardiac event monitor) was initiated. The patient was discharged on ischemic secondary prevention therapy as noted above, pending cardioembolic etiology rule out.

Implanted loop recorder (ILR) was arranged by referral to a capable tertiary center in Okinawa, Japan. Transthoracic echocardiogram with bubble study interpretation resulted days later, revealing early positive agitated saline study consistent with patent foramen ovale (PFO). Additionally, neurology started a hypercoagulability workup to include assessment of

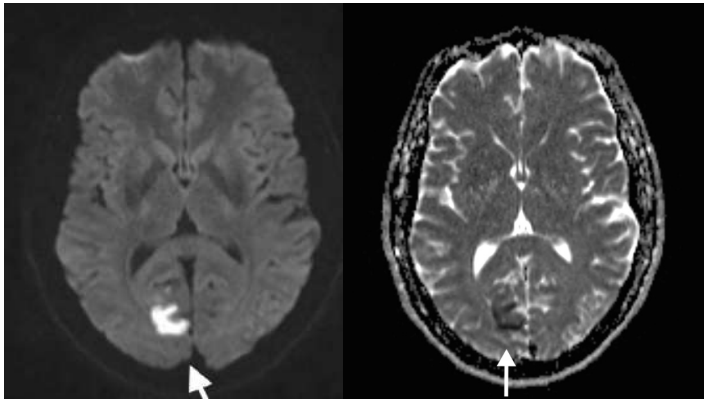


Image 2. Transverse brain magnetic resonance imaging at level of the basal ganglia: At left, an axial diffusion weighted image demonstrates hyperintense signal of right mesial occipital lobe. At right, the apparent diffusion coefficient illustrates corresponding hypointensity, which is consistent with acute brain ischemia.

lupus anticoagulant, protein C/S panel, factor V Leiden mutation, antithrombin III activity, and prothrombin mutation. Only the prothrombin workup was abnormal, revealing a heterozygous mutation (G-20210-A). However, in the absence of venous thromboembolism, prolonged antithrombotic therapy is generally not recommended for prothrombin G20210A heterozygotes.⁸

At the tertiary center, the patient underwent ILR placement, and a transesophageal echocardiogram was performed. The latter ruled out intracardiac thrombus, and demonstrated right to left shunting via his PFO. However, cardiology stated PFO closure was not indicated due to cryptogenic stroke etiology with unfavorable risk-benefit analysis. The ILR showed no cardiac dysrhythmias. In the first month after discharge, the patient had mild improvement in vision subjectively. At three-week ophthalmology follow-up, he had similar improvement on repeat visual field testing, and was cleared to return to driving. In an eight-month follow-up telephone consult, the patient stated he had no further improvement in vision, and had no recurrent strokes despite increased awareness of stroke symptoms. Repeat visual field testing performed at three and eight months showed no significant improvement or worsening.

DISCUSSION

This case highlights the importance of thorough visual field exam in diagnosing posterior CVA, which may have significant ramifications on immediate treatment. Additionally, this case meets criteria for migrainous infarction, although the exact pathophysiology of this case cannot be definitively proven and the etiology of migrainous infarctions at large remains debated.⁹⁻¹⁰ Symptoms of posterior circulation strokes can be subtle, go unnoticed by the patient, and result in delayed diagnosis.^{1,11} Our patient's presentation was delayed because he did not

recognize his symptoms were consistent with a stroke, only becoming suspicious that something was amiss when his usual symptoms failed to resolve. While homonymous hemianopia is well reported,¹³⁻¹⁴ to our knowledge, there is only one similar case of isolated homonymous quadrantanopia in the emergent setting that ultimately led to a diagnosis of CVA. Even then, the diagnosis was only made following an outpatient neuro-ophthalmology workup, leading the authors to recommend increased utilization of objective visual field tests.¹⁵

We found four ophthalmology case series related to isolated quadrantanopia or homonymous hemianopsia, including a combined total of 1050 patients. The studies show that approximately 80% of homonymous visual field defects are due to ischemic strokes, most often of the occipital lobe, in elderly patients, and without associated neurological findings. These case series are substantially different than our case report because the exam findings were made in a delayed setting by an eye specialist.¹¹⁻¹⁴ Based on the composition and number of reported cases, it is possible a significant number of isolated posterior strokes may be missed on initial presentation. The fact that no literature could be located on emergent formal visual field assessment may suggest less diagnostic utility in an era when rapid MRI acquisition is common. However, remote locations may occasionally find value in this less expensive, functional test.

Our case report and existing literature illustrate the diagnostic challenge of certain stroke subtypes and the utility of formal visual field testing by an eye specialist when there is suspicion of a posterior cerebral vascular event. The homonymous defect could have been missed, as it represented only 10% of the visual field. Small defects like these may explain the great variation in stroke patients with visual field loss (45-92%).² This wide range may also be secondary to the low sensitivity of confrontational visual fields and the difficulty in obtaining a more thorough visual field exam in a rapid manner. In many cases, the patient may not be stable to leave the ED for a detailed visual field evaluation, or doing so would delay care beyond the standard stroke treatment window. To further obfuscate matters, the current clinical scoring standard, the NIHSS, generally scores posterior circulation strokes lower than classic stroke presentations, as dizziness and visual fields generate minimal points in comparison to motor and language deficits.¹

Although posterior strokes and migrainous infarctions remain rare, literature suggests several associations. Patients with chronic migraines actually have twice the risk of stroke and other cardiovascular complications.¹⁰ The greater the frequency of migraine, the greater the risk of stroke.¹⁰ Consequently, some have suggested that migraine pathophysiology itself could be causal.¹⁰ Others have suggested that common risk factors could be the culprit.¹⁰ Hypothesized mechanisms for this relationship include genetic associations,

endothelial dysfunction, and defects in coagulation factors.¹⁰ While it is possible that our patient's heterozygous prothrombin mutation and PFO created risk factors for paradoxical embolic phenomenon, it is far more likely that the patient had migrainous vasospasm in the setting of pre-existing atherosclerotic disease, given the odds of a paradoxical emboli localizing to the same cerebral territory affected by his usual migraines is essentially nil. A PFO traditionally had been thought to predispose to migrainous infarction because the prevalence of PFO is twice as common in patients with migraines with aura.¹⁰ Interestingly, a randomized clinical trial of PFO closure found no effect on migraine symptoms.¹⁶

The treatment and prognosis for migraines and strokes generally remain two separate pathways. There are no additional recommendations to give antithrombotics to patients with chronic migraines. Calcium channel blockers and beta blockers have been used successfully for migraine prophylaxis, and further studies could possibly show a reduced cardiovascular risk in select migraine patients on these medications. Unfortunately, our patient met indications for few medications at time of presentation. His headache had resolved and his blood pressure was within normal limits. Aspirin was given, but he was not a candidate for thrombolytics based on the minor neurological deficit and the duration of symptoms. Patients with this presentation have variable prognosis. Some studies state that 44% of patients make complete visual recovery, usually within the first three months and unlikely after six months.¹⁷ Our patient reported similar recovery, with some recovery in the first month before a plateau in visual improvement.

CONCLUSION

Our case demonstrates isolated homonymous quadrantanopia as an uncommon presentation of a posterior stroke, which also met criteria for migrainous infarct. There is scant emergency medicine literature related to our case; more common is ophthalmologic literature discovering homonymous defect in delayed manner.^{11,13} The possibility of migraine precipitating infarction remains a viable mechanism in this case. Further studies are needed to understand this relationship. Indeed, emergency physicians must consider acute ischemic cerebrovascular event when a patient presents with visual complaints. Physicians must carefully examine for any potential homonymous deficit, as subtle stroke presentations such as this may be difficult to diagnose. When the exam is not definitive and advanced imaging is unavailable, rapid formal visual field testing is a useful adjunct as rapid diagnosis may enable expedited treatment and ultimately improve outcomes.

Patient consent has been obtained and filed for the publication of this case report.

Address for Correspondence: William Bylund, MD, Naval Medical Center Portsmouth, Department of Emergency Medicine, 620 John Paul Jones Circle, Portsmouth, VA 23708. Email: william.e.bylund@mail.mil.

Conflicts of Interest: By the CPC-EM article submission agreement, all authors are required to disclose all affiliations, funding sources and financial or management relationships that could be perceived as potential sources of bias. The authors disclosed none. The views expressed here are those of the authors and do not reflect the official policy of the Department of the Navy, the Department of Defense, or the U.S. Government.

Copyright: © 2020 Bylund et al. This is an open access article distributed in accordance with the terms of the Creative Commons Attribution (CC BY 4.0) License. See: <http://creativecommons.org/licenses/by/4.0/>

REFERENCES

1. Zürcher E, Richo B, Faouzi M, et al. Differences in ischemic anterior and posterior circulation strokes: a clinico-radiological and outcome analysis. *J Stroke Cerebrovasc Dis.* 2019;28(3):710-8.
2. Ghannam ASB and Subramanian PS. Neuro-ophthalmic manifestations of cerebrovascular accidents. *Curr Opin Ophthalmol.* 2017;28(6):564-72.
3. Marx J and Rosen P. (2014). Rosen's Emergency Medicine Concepts and Clinical Practice, 2 Volume Set. 8th ed. Philadelphia, PA: Elsevier Health Sciences.
4. Centers for Disease Control and Prevention. Stroke Fact Sheet Data & Statistics. 2017. Available at: https://www.cdc.gov/dhdsdp/data_statistics/fact_sheets/fs_stroke.htm. Accessed December 7, 2019.
5. Pare JR and Kahn JH. Basic neuroanatomy and stroke syndromes. *Emerg Med Clin North Am.* 2012;30(3):601-15.
6. Kreling GAD, de Almeida Neto NR, Santos Neto PJ. Migrainous infarction: a rare and often overlooked diagnosis. *Autops Case Rep.* 2017;7(2):61-8.
7. Headache Classification Committee of the International Headache Society (IHS). The International Classification of Headache Disorders, 3rd edition. *Cephalalgia.* 2018;38(1):1-211.
8. Kujovich JL. Prothrombin-related thrombophilia. 2014. Available at: <https://www.ncbi.nlm.nih.gov/books/NBK1148/>. Accessed March 15, 2020.
9. Vinciguerra L, Cantone M, Lanza G, et al. Migrainous infarction and cerebral vasospasm: case report and literature review. *J Pain Res.* 2019;12:2941-50.
10. Lee MJ, Lee C, Chung CS. The migraine-stroke connection. *J Stroke.* 2016;18(2):146-56.
11. Gilhotra JS, Mitchell P, Healey PR, et al. Homonymous visual field defects and stroke in an older population. *Stroke.* 2002;33(10):2417-20.
12. Jacobson DM. The localizing value of a quadrantanopia. *Arch Neurol.* 1997;54(4):401-4.
13. Zhang X, Kedar S, Lynn MJ, et al. Homonymous hemianopia in

- stroke. *J Neuroophthalmol*. 2006;26(3):180-3.
14. Trobe JD, Lorber ML, Schlezinger NS. Isolated homonymous hemianopia. A review of 104 cases. *Arch Ophthalmol*. 1973;89(5):377-81.
 15. Campagna G, Vickers A, Ponce CMP, et al. Homonymous hemianopsia as the presenting sign of migrainous infarction. *Can J Ophthalmol*. 2018;53(6):e229-32.
 16. Dowson A, Mullen MJ, Peatfield R, et al. Migraine Intervention with STARFlex Technology (MIST) trial: a prospective, multicenter, double-blind, sham-controlled trial to evaluate the effectiveness of patent foramen ovale closure with STARFlex septal repair implant to resolve refractory migraine headache. *Circulation*. 2008;117(11):1397-404.
 17. Rowe F, Wright D, Brand D, et al. Reading difficulty after stroke: ocular and non-ocular causes. *Int J Stroke*. 2011;6:404-11.

Ingestion of A Common Plant's Leaves Leads to Acute Respiratory Arrest and Paralysis: A Case Report

Breelan M. Kear, MD*
Richard W. Lee, MD†
Sanford B. Church, MD†
Fady A. Youssef, MD‡§
Anthony Arguija, DO, MBA**

*University of California, Irvine Medical Center, Department of Emergency Medicine, Orange, California

†University of California, Irvine Medical Center, Department of Internal Medicine, Orange, California

‡Memorial Care, Long Beach Medical Center, Department of Pulmonary and Critical Care Medicine, Long Beach, California

§University of California, Irvine Medical Center, Department of Pulmonary and Critical Care Medicine, Orange, California

**Memorial Care, Long Beach Medical Center, Department of Emergency Medicine, Long Beach, California

Section Editor: Steven Walsh, MD

Submission history: Submitted January 25, 2020; Revision received May 7, 2020; Accepted May 11, 2020

Electronically published July 9, 2020

Full text available through open access at http://escholarship.org/uc/uciem_cpccem

DOI: 10.5811/cpcem.2020.5.46703

Background: *Nicotiana glauca* is a plant known to cause acute toxicity upon ingestion or dermal exposure due to the nicotinic alkaloid, anabasine. Nicotinic alkaloids cause toxicity by acting as agonists on nicotinic-type acetylcholine receptors (nAChRs). Initial stimulation of these receptors leads to symptoms such as tachycardia, miosis, and tremors. The effects of high doses of nicotinic alkaloids are biphasic, and eventual persistent depolarization of nAChRs at the neuromuscular junction occurs. This causes apnea, paralysis, and cardiovascular collapse.

Case Report: In this report, we present a case of respiratory arrest due to nicotinic alkaloid poisoning from the ingestion of *Nicotiana glauca*. The diagnosis was suspected after the patient's family gave a history of the patient ingesting a plant prior to arrival. They were able to also provide a physical sample of the plant.

Conclusion: The phone application, "Plant Snap", determined the plant species and helped confirm the diagnosis. This case describes how modern technology and thorough history taking can combine to provide the best possible patient care. [Clin Pract Cases Emerg Med. 2020;4(3):371–374.]

Keywords: *Nicotiana glauca*; nicotinic alkaloids; respiratory arrest; toxicity.

INTRODUCTION

There are several classes of nicotinic and nicotinic-like alkaloid containing plants that can cause toxicological effects in humans.¹ The plant species in the genus *Nicotiana* contain these alkaloids. Nicotinic alkaloids exert their toxicity by acting as agonists on nicotinic-type acetylcholine receptors (nAChRs).¹ Examples of these alkaloids include nicotine, nornicotine, anabasine, and anatabine. In this case report we describe a case of acute toxicity due to the ingestion of the

plant, *Nicotiana glauca*, which primarily contains the nicotinic alkaloid, anabasine.²

CASE REPORT

A 65-year-old female was brought to the emergency department (ED) by emergency medical services (EMS) in respiratory arrest. Per EMS report, the patient had felt nauseous and vomited shortly after lunch. One hour later, she was found sitting in a chair complaining of weakness and then

suddenly became unresponsive. Her family began cardiopulmonary resuscitation with chest compressions and called 911. Upon arrival to the ED, she was receiving bag-valve-mask ventilation by EMS. She was found to be apneic with a strong pulse. Her initial vital signs were a temperature of 97.5° Fahrenheit, blood pressure of 163/82 millimeters of mercury, heart rate of 61 beats per minute, and 100% oxygen saturation. Her Glasgow Coma Score (GCS) was three, and she had sluggishly reactive mydriatic pupils. She had no signs of trauma. Exam was otherwise unremarkable. She was given intravenous naloxone without a response. The patient was immediately intubated.

The initial workup in the ED included laboratory studies and a computed tomography (CT) of the head. As this was being executed, the patient's family arrived with further history. Reportedly, the patient suffered from bipolar disorder; however, she had no history of suicide attempts and had been acting behaviorally normal prior to this episode. She was not prescribed any medications, but she did take homeopathic supplements and would occasionally pick dandelions found in her neighborhood for consumption. That morning, she had brought home a new plant "with yellow flowers" and boiled the leaves to eat them. This additional history put a toxicological cause of respiratory arrest higher on the differential; however, other etiologies had not been ruled out.

Laboratory results showed a normal pH on venous blood gas of 7.38, (reference range [Ref]: pH 7.35-7.45); normal electrolytes without anion gap; hyperglycemia of 305 milligrams per deciliter (mg/dL) (Ref: 65-99 mg/dL); mild leukocytosis of 12.5 thousand per microliter (k/ μ L) (Ref: 3.85k/ μ L-10.85k/ μ L); and mild anemia of 10.6 grams per deciliter (g/dL) (Ref: 13.2-17.1 g/dL). The urine drug screen was negative for amphetamines, barbiturates, benzodiazepines, cocaine, methadone, methamphetamines, opiates, phencyclidine, and cannabinoids. Lithium, salicylate, digoxin, cyanide, and acetaminophen were not detected in the serum. The electrocardiogram showed atrial fibrillation at 63 beats per minute with a normal axis. Chest radiograph and computed tomography (CT) of her head were normal.

Given that most of the findings were unremarkable at this point, a "code stroke" was called for fear of basilar cerebrovascular accident. The consulting neurologist noted that the patient had absent oculocephalic and gag reflexes. She had no dystonia or ankle clonus. CT brain perfusion and CT angiography of the head and neck were obtained and were negative. After alternative causes of coma were ruled out, there was increasing suspicion that the plant ingested earlier in the day could be the cause. The patient was admitted to the intensive care unit (ICU).

Later that evening, the family brought in the plant ingested by the patient to the ICU. A cell phone app, "Plant Snap," was used to identify the plant as *Nicotiana glauca*. A picture of the plant ingested was sent to Poison Control, which confirmed the identity of the plant (Image 1). Poison Control recommended

CPC-EM Capsule

What do we already know about this clinical entity?
The response to nicotinic alkaloids found in several plants is biphasic, with initial stimulation of nicotinic-type acetylcholine receptors causing tachycardia, miosis and tremors, and eventual persistent depolarization causing apnea and paralysis.

What makes this presentation of disease reportable?
This case discusses a severe toxic ingestion of a nicotinic alkaloid, anabasine, that led to apnea and paralysis. The phone app, "Plant Snap", helped to confirm the diagnosis through artificial intelligence and machine learning.

What is the major learning point?
The gold standard of diagnosis for nicotinic alkaloid poisoning are gas chromatography-mass spectrometry and high performance liquid chromatography, both of which were not readily available at the hospital. An easily accessible phone application helped clinch the diagnosis in this case.

How might this improve emergency medicine practice?
Phone applications and new technology can continue to assist us in clinical emergency medicine, but we must continue to perform detailed histories and physicals that lead us toward the correct diagnosis.



Image 1. Leaf brought in by the patient's family, later identified as *Nicotiana glauca*.

continuing supportive care. The inpatient team did not pursue confirmatory diagnosis by gas chromatography-mass spectrometry, as it was not readily available at the hospital.

She was initially sedated on a midazolam drip, but this was discontinued after only two hours. She was then started on 25-50 microgram per hour of fentanyl for pain control without any other form of sedation. The next morning, she opened her eyes and seemed to attempt to follow commands, but only exhibited fasciculations of her neck and forearms without true movement. She had an absent gag reflex per respiratory therapist evaluation. Later that afternoon, she began to regain her motor function by weakly moving her extremities. By evening, her gag reflex had returned and she was able to lift her legs off the bed. On day three, she was taking spontaneous breaths on the ventilator, scribbling down words to communicate and demonstrating four out of five upper and lower extremity motor strength. She was extubated on day three of mechanical ventilation and was discharged from the hospital the following day with full recovery. She explained that she had been fully cognizant of her surroundings, but was unable to move during the first two days of admission. She also confirmed that she had ingested several *Nicotiana glauca* leaves after microwaving them.

DISCUSSION

Nicotiana glauca, or tree tobacco, is a perennial shrub that is native to South America, particularly Bolivia and Argentina. It is now also found in the southwest United States, mainly in southern California, Arizona, and parts of Nevada. Its leaves are long and elliptical shaped, and its flowers are yellow and tubular (Image 2).³

Nicotiana glauca contains the nicotinic alkaloid,

anabasine. It is structurally similar to nicotine, but appears to be more potent.² This similarity allows anabasine to bind to nAChRs, which are located throughout the body, including the neuromuscular junction, as well as the central and autonomic nervous systems.¹ Anabasine primarily exerts its toxicity by acting as an agonist on these receptors, and the effects are significantly dose related.^{1,2} Initially, anabasine binds directly to the nAChRs throughout the body, causing stimulation of both central and autonomic nervous systems.^{1,4} Initial symptoms include tachycardia, vomiting, hypertension, and miosis. However, there is a threshold for which even higher doses of anabasine can lead to persistent depolarization of nAChRs at the neuromuscular junction.¹ This causes a biphasic effect of initial stimulation followed by persistent depolarization, leading to eventual skeletal muscle paralysis, central nervous system collapse, and coma.^{1,4,5}

Symptoms from nicotine and nicotinic-like alkaloid toxicity usually develop within 15-90 minutes of ingestion.^{1,2} These symptoms are broad as nAChRs are located throughout the body. Nicotinic alkaloid poisoning classically presents with exam finding of both sympathetic and parasympathetic stimulation due to their activity at both pre- and post-ganglionic nAChRs. Early-phase symptoms include nausea, vomiting, abdominal pain, hypertension, tachycardia, miosis, dizziness, tremors, seizures, and muscle fasciculations.¹ Delayed phase of toxicity typically occurs within 90 minutes of ingestion and includes respiratory depression, apnea, bradycardia, dysrhythmias, shock, mydriasis, coma, hypotonia, and muscle paralysis.^{1,2,5} Symptoms can last anywhere from one to two hours in mild toxicity to 24-72 hours in more severe toxicity.^{1,5} The patient in the case report experienced the early symptoms of nausea and vomiting after ingesting *Nicotiana glauca* leaves. She rapidly progressed to display the delayed symptoms, ultimately developing complete paralysis, apnea, dysrhythmia, and coma.

Diagnosis of nicotine alkaloid toxicity is typically clinical. In this case, a phone application, "Plant Snap," was used to identify the specific plant ingested. This application has a database with information on over 600,000 plants, and contains around 250 million images of plants. The user simply takes a picture of the plant, and the application identifies the plant using machine learning and artificial intelligence.⁶ The gold standards of diagnosis of *Nicotiana glauca* poisonings are diagnostic assays using gas chromatography, gas chromatography-mass spectrometry, and high performance liquid chromatography.^{7,8}

As demonstrated in this case report, the treatment for *Nicotiana glauca* poisoning is largely supportive. Securing the airway with endotracheal intubation followed by mechanical ventilation is paramount in poisonings that cause complete muscle paralysis and thereby respiratory failure. Additionally, seizure control and blood pressure support may be indicated. There is no role for activated charcoal in severe



Image 2. *Nicotiana glauca* including the flowers.

Source: Krysztof Ziarnik, Kenraiz. File:Nicotiana glauca kz3.JPG. Wikimedia Commons. <https://commons.wikimedia.org/w/index.php?curid=47830471>. Published March 28, 2016. Accessed May 2, 2020.

nicotinic alkaloid poisonings where the airway is compromised, but can be considered in mild poisonings that present within one hour. As to prognosis, patients are expected to make a full recovery if effective supportive care is initiated early in the patient's toxicity.¹

CONCLUSION

The differential diagnoses of this case were extremely broad. The initial management of this case included securing the airway as the patient was GCS 3 and apneic. The family's story about the plant ingestion was not initially presented to the ED team as the patient arrived with EMS. A broad workup was initiated, including studies looking for other toxicological, neurological, and cardiorespiratory causes. Once the common conditions such as cerebral hemorrhage, basilar cerebrovascular accident, opioid overdose, and hypoxic brain injury were ruled out, it became clear only from further history that this was a case of *Nicotiana glauca* poisoning.

Without the additional information from the family, the cause of this patient's respiratory arrest would not have been known.

The phone application, "Plant Snap," was paramount in helping us identify the plant as *Nicotiana glauca*. While the plant could likely have been identified by a botanist or using high-performance liquid chromatography, these methods of diagnosis are often not available in a reasonable timeframe. This phone application was free to download and results were available within seconds. There is a growing presence of artificial intelligence across the globe, and this case is an example demonstrating how technology was an aid in our diagnostic acumen in medicine. Nevertheless, in the age of advanced imaging, testing and technology, this case still highlighted the importance of history and physical, while keeping toxicological ingestion high on the differential.

The authors attest that their institution requires neither Institutional Review Board approval, nor patient consent for publication of this case report. Documentation on file.

Address for Correspondence: Breelan M. Kear, MD, University of California, Irvine Medical Center, Department of Emergency Medicine, 333 City Blvd. West, Suite 640, Orange, CA 92868. Email: breelankear@gmail.com.

Conflicts of Interest: By the CPC-EM article submission agreement, all authors are required to disclose all affiliations, funding sources and financial or management relationships that could be perceived as potential sources of bias. The authors disclosed none.

Copyright: © 2020 Kear et al. This is an open access article distributed in accordance with the terms of the Creative Commons Attribution (CC BY 4.0) License. See: <http://creativecommons.org/licenses/by/4.0/>

REFERENCES

1. Schep L, Slaughter R, Beasley D. Nicotinic plant poisoning. *Clin Toxicol*. 2009;47(8):771-81.
2. Furer V, Hersch M, Silvetzki N, et al. *Nicotiana glauca* (tree tobacco) intoxication-two cases in one family. *J Med Toxicol*. 2010;7(1):47-51.
3. Invasive Plant Atlas of the United States. Tree tobacco: *Nicotiana glauca* Graham. 2018. Available at <https://www.invasiveplantatlas.org/subject.html?sub=6083>. Accessed August 7, 2019.
4. Manoguerra A and Freeman D. Acute poisoning from the ingestion of *Nicotiana glauca*. *J Toxicol Clin Toxicol*. 1982;19(8):861-4.
5. Murphy N, Albin C, Tai W, et al. Anabasine toxicity from a topical folk remedy. *Clin Pediatr*. 2006;45(7):669-71.
6. PlantSnap. Who We Are. 2019. Available at: <http://www.plantsnap.com/who-we-are>. Accessed January 24, 2020.
7. Sercan Y and Selahattin K. Respiratory failure due to plant poisoning: *Nicotiana glauca* Graham. *J Emerg Med*. 2018;55(3):e61-3.
8. Steenkamp PA, Van heerden FR, Van wyk BE. Accidental fatal poisoning by *Nicotiana glauca*: identification of anabasine by high performance liquid chromatography/photodiode array/mass spectrometry. *Forensic Sci Int*. 2002;127(3):208-17.

A Case Report of Widely Disseminated Tuberculosis in Immunocompetent Adult Male

Samantha B. Esposito, BS
Joseph Levi, DO, DPT
Zachary M. Matuzsan, DO
Alexandra M. Amaducci, DO
David M. Richardson, MD

Lehigh Valley Health Network/USF Morsani College of Medicine, Department of Emergency and Hospital Medicine, Allentown, Pennsylvania

Section Editor: Anna McFarlin, MD

Submission history: Submitted December 13, 2019; Revision received March 17, 2020; Accepted March 20, 2020

Electronically published June 4, 2020

Full text available through open access at http://escholarship.org/uc/uciem_cpem

DOI: 10.5811/cpcem.2020.3.46183

Introduction: Disseminated tuberculosis (TB) is rare, affects any organ system, and presents mainly in immunocompromised populations. Typical presentation is non-specific, posing a challenge for diagnosis.

Case Report: This case presents an immunocompetent male presenting with severe headaches with meningeal signs. Lab and lumbar puncture results suggested bacterial meningitis, yet initial cerebral spinal fluid cultures and meningitis/encephalitis polymerase chain reaction were negative. A chest radiograph (CXR) provided the only evidence suggesting TB, leading to further tests showing dissemination to the brain, spinal cord, meninges, muscle, joint, and bone.

Discussion: This case stands to acknowledge the difficulty of diagnosis in the emergency department (ED), and the need for emergency physicians to maintain a broad differential including disseminated TB as a possibility from the beginning of assessment. In this case, emergency physicians should be aware of predisposing factors of disseminated TB in patients presenting with non-specific symptoms. They should also acknowledge that TB may present atypically in patients with minimal predisposing factors, rendering the need to further investigate abnormal CXR images despite lab results inconsistent with TB.

Conclusion: While this diagnosis is easily missed, early identification in the ED can lead to optimal treatment. [Clin Pract Cases Emerg Med. 2020;4(3):375–379.]

Keywords: *Disseminated tuberculosis; tuberculosis meningitis; miliary tuberculosis; immunocompetent adult; case report.*

INTRODUCTION

Tuberculosis (TB) stands as a global health problem caused by infection by *Mycobacterium tuberculosis*.¹ From 1993 to 2018, there was a constant decrease in TB cases in the United States with a national incidence of 2.8 cases per 100,000 persons.² At-risk populations include the elderly, immunocompromised individuals, the homeless, excessive alcohol use, and immigration from areas with high TB rates.¹⁻⁴ Despite this low incidence, detection remains important because if not recognized or treated the infection

can progress to disseminated TB, which can be fatal within a year.⁵⁻⁶

Disseminated, or miliary, TB is a progressive, life-threatening disease that results from lymphohematogenous dissemination of *M. tuberculosis* bacilli due to either primary dissemination or progression from years of untreated TB.^{1,6} Of all TB cases, only 1-2% are disseminated TB.^{1,4} Although rare, predisposing factors to disseminated TB include elderly patients, individuals with childhood infections, human immunodeficiency virus (HIV), alcohol abuse, diabetes, chronic liver or kidney

failure, organ transplant, pharmacological immunosuppressants, pregnancy, and symptoms lasting longer than 12 weeks.^{1,3,7}

TB can disseminate to any organ system of the body, 22% of which disseminate to the central nervous system (CNS) including meningitis, cerebral tuberculoma, tuberculoma abscess, and thoracic transverse myelopathy.^{1,6} TB meningitis accounts for 10-30% of CNS disseminations.¹ Because of disseminated TB's nonspecific clinical presentation such as weight loss, night sweats, cough, fever, anorexia, and weakness, it is increasingly difficult to diagnose despite the urgent need.^{4-5,7}

Because TB with dissemination to the CNS is rarely seen in the emergency department (ED), the current case stands to acknowledge the importance of early identification in the ED leading to optimal management and treatment. We report the case of an immunocompetent adult male presenting to the ED with severe headaches due to disseminated TB to the brain, spinal cord, meninges, muscle, joint, and bone.

CASE REPORT

A 30-year old male, who immigrated to the United States from Mexico three years prior, presented to the ED with complaints of a headache, weight loss, and vomiting. The patient reported the headache was localized to his bitemporal area without radiation, and progressively worsened over the two weeks prior to his arrival for evaluation. He also reported neck pain and stiffness associated with the headache. His neck pain increased with flexion and extension, and acetaminophen and nonsteroidal anti-inflammatory drugs did not provide relief. Additionally, the patient denied previous similar headaches, cough, congestion, sore throat, chest pain, shortness of breath, abdominal pain, back/hip pain, or changes in bowels or bladder.

His initial temperature was 37.5° Celsius. On exam he was noted to have an ill and sickly appearance. He had neck rigidity and decreased range of motion. Brudzinski's sign was noted; however, Kernig's sign was not present. The rest of the exam was normal.

Complete blood count, comprehensive metabolic panel, chest radiograph (CXR), head computed tomography (CT), and lumbar puncture (LP) were performed. The patient's labs revealed a white blood count of 4.0 per high power field, mild hyponatremia, but were otherwise unremarkable. His initial head CT revealed no acute abnormalities. However, the CXR showed reticulonodular diffuse lung pattern as typically seen with infection (Image 1). LP results (neutrophils 91% (normal 0-2%), protein 351 milligrams per deciliter (mg/dL) (normal 15-45 mg/dL), and glucose 14 mg/dL (normal 40-70 mg/dL) were concerning for bacterial meningitis; therefore, ceftriaxone and vancomycin were administered. The patient was then admitted for further evaluation and management pending further cerebral spinal fluid (CSF) study results.

An infectious disease physician (ID) was consulted by the hospital medicine team given concern for bacterial meningitis and worsening clinical symptoms. Initial cultures, meningitis/encephalitis CSF polymerase chain reaction (PCR), and HIV

CPC-EM Capsule

What do we already know about this clinical entity?
Disseminated tuberculosis (TB) is a rare progression of TB affecting many at risk populations, such as the immunocompromised and immigrants from areas with high TB rates.

What makes this presentation of disease reportable?
Disseminated TB to the meninges, spinal cord, bone, joint, and muscle is exceedingly rare, and it is important to have an early clinical suspicion in the emergency department to prevent delay in diagnosis and treatment.

What is the major learning point?
This case demonstrates that widely disseminated TB can present with vague, nonspecific symptoms with minimal risk factors and limited diagnostic evidence.

How might this improve emergency medicine practice?
This may improve emergency medicine practice by increasing awareness of TB and perhaps lower threshold for early testing for TB by serum or lumbar puncture analysis to prevent delay of diagnosis and treatment.

test results were negative, and so antibiotics were narrowed. On hospital day (HD) four, magnetic resonance imaging (MRI) was performed as no bacteria was yet identified to explain the abnormal CSF results. Brain and spine MRI

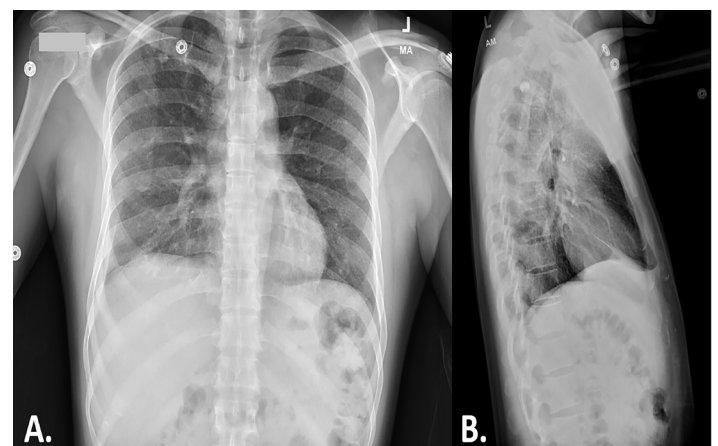


Image 1. Initial chest radiograph with reticulonodular diffuse lung pattern that can be seen in infection. A) anteroposterior view. B) lateral view.

showed multiple ring-enhancing foci in the brain parenchyma and diffuse enhancement along the thoracic spinal cord consistent with leptomeningitis (Image 2). Additionally, the MRI showed a large paraspinous abscess, a left epidural abscess compressing the thecal sac, and an abnormal signal enhancement in the left sacrum indicating sacral osteomyelitis with septic arthritis of the left sacroiliac joint (Image 3). However, they were again broadened given MRI findings. Following these results, ID recommended repeating the LP to specifically test for acid-fast bacilli (AFB) cultures and smear to determine whether mycobacterium was the source of the infection. Fluoroscopy-guided incision and drainage (I&D) of left paraspinous abscess drainage was also performed by interventional radiology to determine the source of the paraspinous abscess.

On HD seven, the cultures from both the LP and abscess drainage were positive for *M. tuberculosis* complex (MTC).

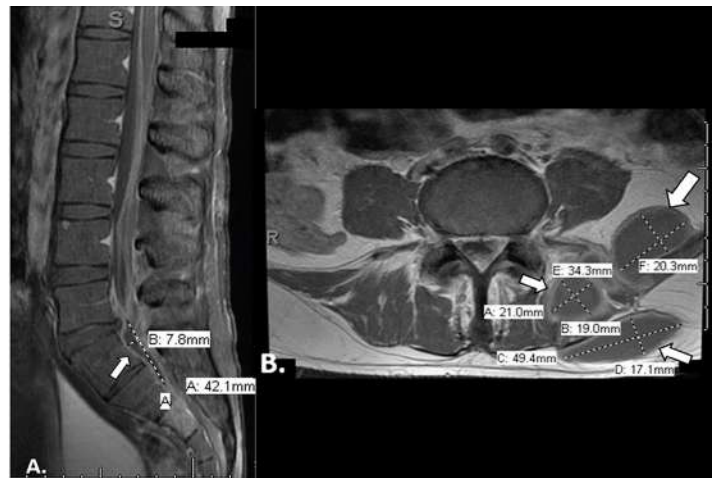


Image 3. Magnetic resonance imaging of the lumbar spine: A) sagittal view showing an epidural abscess measuring approximately 0.3 x 0.8 x 4.2 centimeters causing severe compression of the thecal sac (white arrows); B) axial view showing a paraspinous abscess at the fourth and fifth lumbar level contiguous with component extending to the subcutaneous soft tissue, and an additional abscess extending inferiorly into the left sacral paraspinous musculature (white arrows).

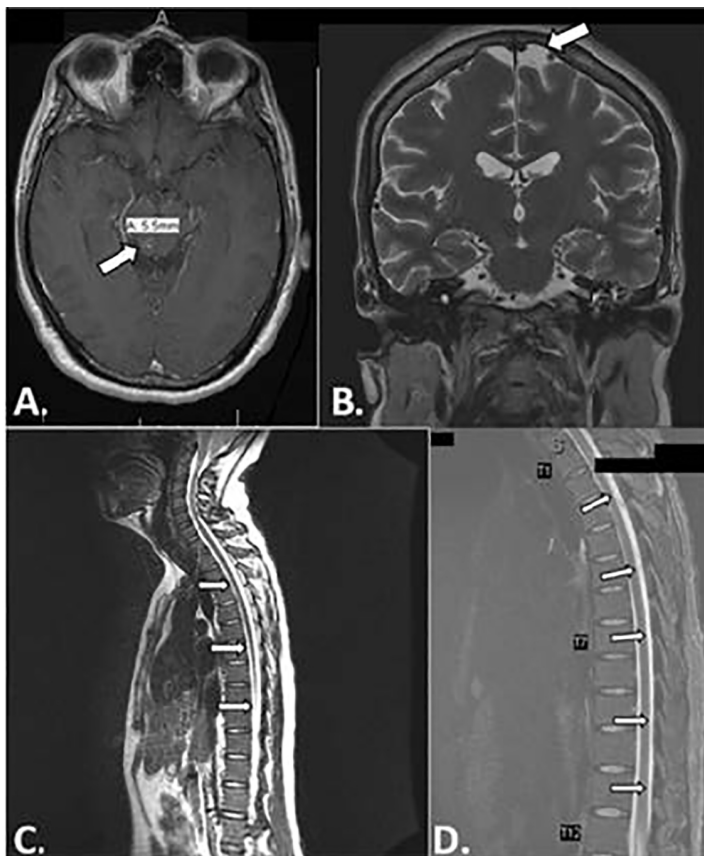


Image 2. Magnetic resonance imaging of the brain, cervical spine and thoracic spine: A) axial view of the brain showing 5.5 millimeter (mm) small ring-shaped enhancement in the posterior right side of the midbrain potentially indicating infection; B) coronal view of the brain showing 7.4 mm incidental arachnoid cyst of the left frontal lobe; C) sagittal view of the cervical and thoracic spine showing smooth enhancement along the pleural surface of the thoracic spinal cord; D) magnified sagittal view of the thoracic spine showing enhancement along leptomeninges potentially indicating meningitis.

The patient was diagnosed with disseminated TB to the meninges and spinal cord, with paraspinous abscesses, sacral osteomyelitis, and sacroiliac septic arthritis. A high sensitivity chest, abdomen, and pelvic CT confirmed this diagnosis as there was no evidence of active disease, but rather signs of disseminated TB. The patient was treated with rifampicin, isoniazid, pyrazinamide, and ethambutol (RIPE) therapy, pyridoxine, and dexamethasone taper, and he was confined to a negative pressure room until three negative sputum cultures were obtained. Vancomycin and cefepime were discontinued. On HD 12, per orthopedic surgery, an I&D of paraspinous abscesses and left sacroiliac joint was successfully completed. The specimen from this surgery grew AFB; therefore, the patient's RIPE therapy and steroids were continued. On HD 27, the patient was hemodynamically stable and discharged with RIPE, pyridoxine, and steroid prescriptions, and instructed to follow up with the Department of Health and Infectious Disease. The Department of Health was aware of the case and following it through the patient's hospital stay and follow-up.

DISCUSSION

This case presents a healthy 30-year-old male diagnosed with TB disseminated to the CNS, and highlights the need for early and accurate identification of disseminated TB for optimal patient outcomes. Despite previous reports of CNS dissemination of TB, this case stands to acknowledge the difficulty of diagnosis in the ED, and the need for emergency physicians (EP) to maintain a broad differential including disseminated TB as a possibility from the beginning of assessment.⁸⁻¹² In this case EPs should be aware of predisposing

factors of disseminated TB in patients presenting with non-specific symptoms. These predisposing factors include impaired cell-mediated immunity as seen in HIV/acquired immune deficiency syndrome patients, increased use of immunosuppressive drugs, diminished ability of the liver to clear bacteria from the bloodstream as seen in advanced liver disease among others, and recent immigration from areas with high rates of TB.^{1,2,7} Additionally, they should acknowledge that TB may present atypically in patients with minimal predisposing factors, rendering the need to further investigate abnormal CXR images despite laboratory results inconsistent with TB. EPs should also have a low threshold to order an AFB culture for the first CSF analysis with any suspicion for TB in a patient.

CXRs are pertinent for TB diagnosis by demonstrating discrete, uniform, pulmonary opacities measuring less than two millimeters in diameter.⁵ This was the only indication of TB in the present case, which expanded the differential diagnosis to include TB through AFB with CSF analysis to confirm TB. This led to a prompt diagnosis and management of the current patient. Although radiographs can be beneficial for TB diagnosis, approximately half of disseminated TB cases do not present with this typical lung pattern, rendering alternate means of imaging such as high-resolution CT or MRI.^{1,4,7} Despite robust therapeutic options, mortality rates are high as early diagnosis is hard to obtain because there is a lack of a gold standard for diagnosis.⁵ Currently, diagnosis requires presence of diffuse miliary infiltrate on CXR or high-resolution CT. Confirmation occurs with other methods such as isolation and PCR of sputum, body fluids, or biopsy specimen.¹ However, these confirmation methods may not produce positive results until late in the disease progression.¹

It has been suggested that close examination of organ systems can help determine TB dissemination.⁵ For example, in the present case the patient presented with signs of meningitis as well as hyponatremia, which serve as indications of TB meningitis.⁵ Contrast-enhanced, high-resolution CT and MRI of the brain and spine may be of increased use for TB meningitis as they can show the disease progression and miliary pattern.^{1,4,5} These additional images in the current case confirmed the dissemination of the disease to the meninges, paraspinal abscess, sacral osteomyelitis, and sacroiliac joint septic arthritis, which enabled further treatment for these specific disseminations.

Treatment regimens for disseminated TB vary in duration and require careful evaluation of the organ systems involved, especially in TB meningitis.⁴ Typical treatments for TB meningitis include RIPE therapy as initial treatment for two months, followed by 7-10 months of isoniazid and rifampicin therapy alone.¹³ Follow up of disseminated TB patients has showed 52% of patients improve with this treatment.⁶ Longer treatment duration occurs more often in men and dissemination with bone/joint involvement, which may also require surgery.^{4,13} Additionally, treating the inflammatory response in mycobacterial meningitis has been

seen to improve outcomes by reducing CSF inflammation.¹³ Therefore, dexamethasone tapers for 6-8 weeks are also recommended.¹³⁻¹⁴ Repeat LP should be used to monitor changes in CSF throughout treatment.¹³

CONCLUSION

Disseminating TB to the meninges, spinal cord, bone, joint, and muscle is exceedingly rare, and it is important to diagnose early in the ED. This case serves to demonstrate that TB disseminations can present with complaints typical of meningitis with the only indications suggesting TB being a miliary pattern on CXR, which needs to be further investigated despite limited risk factors and laboratory results not indicating TB. Additionally, this case shows successful treatment and outcome for the patient with early diagnosis and treatment management.

The authors attest that their institution requires neither Institutional Review Board approval, nor patient consent for publication of this case report. Documentation on file.

Address for Correspondence: Samantha Esposito, BS, Lehigh Valley Health Network, Department of Emergency Medicine, LVH-M 4th Floor (South Wing), 2545 Schoenersville Road, Bethlehem, PA 18017. Email: Samantha.Esposito@lvhn.org.

Conflicts of Interest: By the CPC-EM article submission agreement, all authors are required to disclose all affiliations, funding sources and financial or management relationships that could be perceived as potential sources of bias. The authors disclosed none.

Copyright: © 2020 Esposito et al. This is an open access article distributed in accordance with the terms of the Creative Commons Attribution (CC BY 4.0) License. See: <http://creativecommons.org/licenses/by/4.0/>

REFERENCES

1. Sharma SK, Mohan A, Sharma A, et al. Miliary tuberculosis: new insights into an old disease. *Lancet Infect Dis.* 2005;5(7):415-30.
2. Centers for Disease Control and Prevention. Trends in tuberculosis, 2018. 2019. Available at: <https://www.cdc.gov/tb/publications/factsheets/statistics/tbtrends.htm>. Accessed February 5, 2020.
3. Righi E, Siega RD, Merelli M, et al. Comparison of clinical characteristics of tuberculosis between two age groups at an Italian tertiary hospital. *Infection.* 2015;43(3):361-6.
4. Sharma SK, Mohan A, Sharma A. Miliary tuberculosis: a new look at an old foe. *J Clin Tuberc Other Mycobact Dis.* 2016;3:13-27.
5. Sharma SK, Mohan A, Sharma A. Challenges in the diagnosis & treatment of miliary tuberculosis. *Indian J Med Res.* 2012;135(5):703-30.

6. Garg RK, Sharma R, Kar AM, et al. Neurological complications of miliary tuberculosis. *Clin Neurol Neurosurg.* 2010;112(3):188-92.
7. Meira L, Chaves C, Araújo D, et al. Predictors and outcomes of disseminated tuberculosis in an intermediate burden setting. *Pulmonol.* 2019;25(6):320-7.
8. Medoza M and Sheele JM. An unusual presentation of disseminated *Mycobacterium tuberculosis* in the ED. *Am J Emerg Med.* 2016;34(9):1915e5-7.
9. Megarbane B, Lebrun L, Marchal P, et al. Fatal *Mycobacterium tuberculosis* brain abscess in an immunocompetent patient. *Scand J Infect Dis.* 2000;32(6):702-3.
10. Martins R, Casmiro C, Valverde A, et al. A rare presentation of invasive tuberculosis of the central nervous system in an immunocompetent patient in a nonendemic country. *Case Rep Neurol Med.* 2018;2940947.
11. Eshive C, Shahi F, Gordon N, et al. Rare and unusual case of hepatic and disseminated tuberculosis in an immunocompetent patient. *BMJ Case Rep.* 2019;12(6):22.
12. Madhyastha SP, Gopaldaswamy V, Acharya RV, et al. Disseminated tuberculosis in relatively asymptomatic young woman. *BMJ Case Rep.* 2017.
13. Nahid P, Dorman SE, Alipanah N, et al. Official American Thoracic Society/Centers for Disease Control and Prevention/Infectious Diseases Society of America Clinical Practice Guidelines: Treatment of Drug-Susceptible Tuberculosis. *CID.* 2016;63(7):e147-95.
14. Thwaites GE, Bang ND, Dung NH, et al. Dexamethasone for the treatment of tuberculosis meningitis in adolescents and adults. *N Engl J Med.* 2004;351(17):1741-51.

Medial Pontomedullary Stroke Mimicking Severe Bell's Palsy: A Case Report

Benjamin Boodaie, MD*
Manish Amin, DO*
Katayoun Sabetian, MD†
Daniel Quesada, MD*
Tyler Torrico, BIS‡

*Kern Medical, Department of Emergency Medicine, Bakersfield, California
†Kern Medical, Department of Neurology, Bakersfield, California
‡Ross University School of Medicine, Department of Medicine, Miramar, Florida

Section Editor: Austin Smith, MD

Submission history: Submitted February 14, 2020; Revision received April 22, 2020; Accepted May 5, 2020

Electronically published July 20, 2020

Full text available through open access at http://escholarship.org/uc/uciem_cpchem

DOI: 10.5811/cpcem.2020.5.46965

Introduction: Patients with acute unilateral upper and lower facial palsy frequently present to the emergency department fearing they have had a stroke, but many cases are benign Bell's palsy.

Case Report: We present a rare case of a medial pontomedullary junction stroke causing upper and lower hemifacial paralysis associated with severe dysphagia and contralateral face and arm numbness.

Conclusion: Although rare, pontine infarct must be considered in patients who present with both upper and lower facial weakness. Unusual neurologic symptoms (namely diplopia, vertigo, or dysphagia) and signs (namely gaze palsy, nystagmus, or contralateral motor or sensory deficits) should prompt evaluation for stroke. [Clin Pract Cases Emerg Med. 2020;4(3):380–383.]

Keywords: *Bell's Palsy; pontine stroke; MRI.*

INTRODUCTION

Acute facial palsy is a commonly encountered complaint in the emergency department (ED) setting. Bell's palsy represents approximately half of such cases.^{1,2} Bell's palsy is defined as an idiopathic peripheral facial nerve palsy, which is classically although controversially attributed to herpes simplex virus (HSV) infection.³ Bell's palsy is a diagnosis of exclusion. The differential diagnosis includes herpes zoster (Ramsey-Hunt syndrome), otitis media, Guillain-Barré syndrome, Lyme disease, sarcoidosis, amyloidosis, parotid gland tumor, temporal bone biopsy, trauma, acoustic neuroma, central nervous system (CNS) infection, and stroke.

The presentation of a peripheral type facial paresis with weakness of both upper and lower musculature is generally reassuring that the patient has not had a stroke. However, a rare but important subset of patients who present with complete hemifacial paresis has a stroke at the level of the lower pons.⁴ In fact, one percent of all new facial paralysis cases represent a pontine stroke.⁵ In a surveillance study of almost 44,000 diagnoses of Bell's palsy within California

EDs between 2005 and 2011, 0.8% received an alternative diagnosis after 90-day follow-up, of which 30% was found to be secondary to ischemic stroke or intracranial hemorrhage.⁴ By these numbers, approximately one in 400 ED diagnoses of Bell's palsy may be missed diagnoses of stroke.

In this report, we describe a rare presentation of medial pontomedullary junction (MPMJ) infarct that presented as unilateral peripheral type facial paresis, severe dysphagia, and contralateral face and arm numbness. We also review the literature on strokes causing peripheral facial nerve palsy and discuss important clinical flags that should raise suspicion for such pathology.

CASE REPORT

A 63-year-old Hispanic male with untreated hypertension presented to the ED with a chief complaint of facial droop. Three hours prior to presentation, the patient noticed his face "drooping to the right," with associated left-sided headache, left face and body numbness, chest pain radiating to his left arm, and shortness of breath. Upon arrival to the ED, the

patient's symptoms had self-resolved and facial asymmetry was absent on exam. Vitals were notable for a blood pressure of 212/123 millimeters of mercury. The National Institutes of Health Stroke Scale in the ED was calculated as one for mild, left-sided sensory deficit, which soon resolved. Computed tomography (CT) and magnetic resonance imaging (MRI) of the brain showed chronic periventricular ischemic changes but were negative for acute ischemia or hemorrhage. Laboratory studies were notable for an initial troponin of 0.09 nanograms per milliliter (ng/mL) (reference range: <0.05 ng/mL), which rose to 0.12 ng/mL four hours later. The patient was admitted for suspected acute coronary syndrome; he was started on dual antiplatelet therapy, enoxaparin, and antihypertensive therapy.

On day two of admission, the patient developed severe left upper and lower facial weakness and inability to swallow. Physical exam showed a complete paralysis of the left upper and lower face resembling severe Bell's palsy with mild to moderate dysarthria, and decreased sensation to pinprick and cold temperature of the right face and arm. Otherwise, the patient had no upper or lower extremity motor weakness, normal extraocular movements, symmetric pupils and palatal elevation, no ptosis, and no hoarseness. A tentative diagnosis of severe Bell's palsy was made, although stroke remained on the differential diagnosis. Repeat MRI was ultimately completed on day four of admission (approximately 2.5 days after onset of in-hospital symptoms) and was notable for a 1.5-centimeter area of increased signal intensity on diffusion-weighted imaging located at the left MPMJ consistent with an acute infarction (Image). CT angiography of the head and neck was negative for vertebrobasilar stenosis or dissection. Left heart catheterization showed mild-moderate multivessel coronary artery disease. Echocardiography showed an ejection fraction of 30%, which was believed to be secondary to long-standing uncontrolled hypertension.

The patient failed a swallow evaluation by speech therapy; the swallow response (when present) was severely weak and uncoordinated with delayed initiation and profoundly reduced laryngeal elevation, epiglottis inversion, pharyngeal constriction, and upper esophageal opening. Since significant aspiration was observed across all consistencies, the patient received a gastrostomy tube. Physical therapy evaluation revealed a new balance deficit requiring a front wheel walker.

DISCUSSION

In patients with unilateral facial palsy, if the facial weakness is limited to the lower face, stroke is an important diagnosis to consider. This is because the frontalis muscle receives bilateral supranuclear innervation and, thus, strokes that occur above the facial nucleus (i.e., cortical, subcortical, and upper pontine strokes) will spare the upper facial muscles. Strokes occurring at the level of the lower pons that involve the facial motor nucleus or the infranuclear facial nerve can result in complete facial paralysis on the ipsilateral side and thus can mimic Bell's palsy. Albeit rare, clinicians must be

CPC-EM Capsule

What do we already know about this clinical entity?
In rare cases, pontine stroke can present with both upper and lower unilateral facial weakness and mimic disease of the peripheral facial nerve (e.g., Bell's palsy).

What makes this presentation of disease reportable?
This patient suffered from a rare stroke (reported only one other time) that led to upper and lower hemifacial paralysis, dysphagia, and contralateral face and arm numbness.

What is the major learning point?
All patients with a peripheral-type facial paralysis should be evaluated with a full neurologic exam and review of systems to evaluate for stroke.

How might this improve emergency medicine practice?
Our report highlights this easy-to-miss but potentially debilitating presentation of stroke and the specific neurologic signs and symptoms to look out for.

vigilant for such presentations, which can have significant morbidity if misdiagnosed.

Pontine stroke syndromes affecting the facial nerve have been well described. They include Gasperini syndrome (facial palsy and abducens nerve palsy), Foville syndrome (facial palsy, conjugate gaze paralysis, and contralateral hemiparesis), and Millard-Gubler syndrome (facial palsy and contralateral hemiparesis). The neurologic signs that accompany these syndromes can be deduced from neuroanatomy. The facial motor nucleus is located in the lower third of the pons. This nucleus gives rise to facial motor nerve roots, which pass around the abducens nerve before they emerge from the brainstem. Thus, lower pontine strokes affecting the facial nerve commonly also affect the abducens nerve and cause abducens palsy with diplopia. Similarly, involvement of the corticospinal tract within the dorsal tegmentum can cause contralateral hemiplegia; and involvement of the paramedian pontine reticular formation can cause conjugate gaze palsy. Thus, in the context of a peripheral-type facial palsy, a lateral gaze defect and/or contralateral hemiplegia can clue providers into the possibility of a pontine infarct.

The patient reviewed in our case also had a stroke-induced facial palsy, but his clinical presentation was distinct from these aforementioned syndromes. Our patient had an acute MPMJ infarct presenting as ipsilateral complete facial

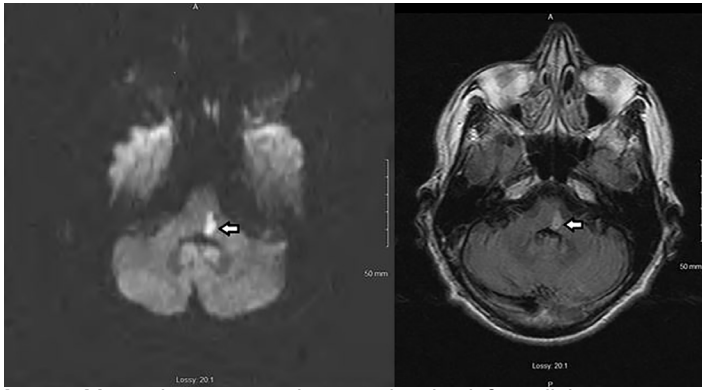


Image. Magnetic resonance images showing left medial pontomedullary junction infarction. Axial diffusion-weighted image (left) and fluid-attenuation inversion recovery image (right) demonstrate the acute ischemic lesion.

← Site of infarction.

hemiparesis, severe dysphagia, and a contralateral face and arm numbness. To the best of our knowledge, there is but one similar case report in the literature by Yoneoka et al in 2019.⁶ And to our knowledge, there are no reported cases in the emergency medicine literature. The infarct can be attributed to a branch occlusion of the anterior inferior cerebellar artery, as speculated by Yoneoka et al, or an occlusion of a paramedian perforating artery arising from the basilar artery.⁶

Bell's palsy is, by definition, an isolated peripheral facial nerve lesion; the presence of additional neurologic signs or symptoms, especially those associated with the above-mentioned pontine syndromes, should prompt evaluation for stroke. It should be noted, however, that a sensation of ipsilateral facial numbness in the paretic area with hypoesthesia to pinprick (possibly secondary to contiguous spread of HSV to the trigeminal nerve) is not an uncommon finding in Bell's palsy and should not be mistaken for stroke.^{7,8} Stroke and Bell's palsy can further be distinguished based on timing of onset; the manifestations of stroke tend to progress over seconds to minutes, whereas Bell's palsy tends to progress over hours to days. It is therefore possible for a patient to wake up with either Bell's palsy or pontine stroke. This evaluation for stroke as a mimic of Bell's palsy should of course be coupled with an assessment for other causes of unilateral facial paralysis, especially those for which misdiagnosis can lead to significant morbidity. These include herpes zoster (scabbing or vesicles on external ear exam); parotid gland lesions (history of facial twitching/spasms or palpable mass on exam); and Lyme disease (bilateral facial palsy or concerning history leading to serologic testing).

An additional challenge in the evaluation of pontine strokes lies in the limitations of imaging. Approximately 30% of vertebrobasilar ischemic strokes are missed on initial diffusion-weighted imaging (DWI) obtained in the first 24 hours after symptoms onset.⁹ Thus, vertebrobasilar strokes cannot be ruled out by an early negative DWI. In the patient described in this report, the initial MRI was negative in the setting of

resolved symptoms, and thus he initially suffered from a transient ischemic attack. Repeat imaging did not occur until approximately 2.5 days following in-hospital symptom onset, which likely improved yield. It is important for providers to be aware of the limitations of MRI in this acute window and to trust their clinical judgment if concerning neurologic signs and symptoms persist despite a negative MRI.

CONCLUSION

Emergency physicians must remain vigilant for acute pontine strokes presenting as complete hemifacial paresis mimicking Bell's palsy. Unusual clinical symptoms (namely diplopia, dysphagia, and vertigo) as well as abnormalities on neurologic examination apart from the facial nerve (namely gaze palsy, nystagmus, and contralateral motor or sensory deficits) should prompt evaluation for stroke. Moreover, given the unreliability of MRI in acute brainstem stroke diagnosis, emergency physicians should trust their clinical judgment even when opposed by radiographic data and consider admitting the patient for further workup.

Documented patient informed consent and Institutional Review Board approval has been obtained and filed for publication of this case report.

Address for Correspondence: Manish Amin, DO, Kern Medical, Department of Emergency Medicine, 1700 Mount Vernon Avenue, Bakersfield CA 93306. Email: manish.amin@kernmedical.com

Conflicts of Interest: By the CPC-EM article submission agreement, all authors are required to disclose all affiliations, funding sources and financial or management relationships that could be perceived as potential sources of bias. The authors disclosed none.

Copyright: © 2020 Boodaie et al. This is an open access article distributed in accordance with the terms of the Creative Commons Attribution (CC BY 4.0) License. See: <http://creativecommons.org/licenses/by/4.0/>

REFERENCES

1. May M and Klein SR. Differential diagnosis of facial nerve palsy. *Otolaryngol Clin North Am.* 1991;24(3):613-45.
2. Gilden DH. Clinical practice. Bell's palsy. *N Engl J Med.* 2004;351(13):1323-31.
3. Murakami S, Mizobuchi M, Nakashiro Y, et al. Bell palsy and herpes simplex virus: identification of viral DNA in endoneurial fluid and muscle. *Ann Intern Med.* 1996;124:27-30.
4. Fahimi J, Navi BB, Kamel H. Potential misdiagnosis of Bell's palsy in the emergency department. *Ann Emerg Med.* 2014;63(4):428-34.
5. Peitersen E. Bell's palsy: the spontaneous course of 2,500 peripheral

- facial nerve palsies and different etiologies. *Acta Oto-Laryngologica*. 2002;(549):4-30.
6. Yoneoka Y, Ikeda R, Aizawa N, et al. Medial Pontomedullary Junctional Infarction Presenting Vertigo, Ipsilateral Facial Paresis, Contralateral Thermal Hypoalgesia and Dysphagia Without Lateral Gaze Palsy, Curtain Sign and Hoarseness: A Case Presentation of a Novel Brain Stem Stroke Syndrome With Sensory Disturbance-Based Dysphagia and Review of the Literature. *Oxf Med Case Reports*. 2019;2019(1):omy121.
 7. Adour KK, Byl FM, Hilsinger RL, et al. The true nature of Bell's palsy: analysis of 1,000 consecutive patients. *Laryngoscope*. 1978;88(5):787-801.
 8. Vanopdenbosch LJ, Verhoeven K, Casselman JW. Bell's palsy with ipsilateral numbness. *J Neurol Neurosurg Psychiatry*. 2005;76(7):1017-8.
 9. Oppenheim C, Stanescu R, Dormont D, et al. False-negative Diffusion-Weighted MR Findings in Acute Ischemic Stroke. *AJNR AM J Neuroradiol*. 2000;21(8):1434-40.

A Case Report of Cake Frosting as a Source of Copper Toxicity in a Pediatric Patient

Hoi See Tsao, MD^{*†‡°}

Lauren Allister, MD^{*†°}

Takuyo Chiba, MD[§]

Jonathan Barkley, MPH[¶]

Rose H. Goldman, MD, MPH^{||****‡‡}

*Warren Alpert Medical School of Brown University, Department of Emergency Medicine, Providence, Rhode Island

†Warren Alpert Medical School of Brown University, Department of Pediatrics, Providence, Rhode Island

‡Brown University School of Public Health, Providence, Rhode Island

§Harvard Medical School, Boston Children's Hospital and the Beth Israel Deaconess Medical Center, Department of Toxicology, Boston, Massachusetts

¶Rhode Island Department of Health, Center for Acute Infectious Disease Epidemiology, Providence, Rhode Island

||Harvard Medical School, Department of Medicine, Boston, Massachusetts

****Harvard T.H. Chan School of Public Health, Department of Environmental Health, Boston, Massachusetts

‡‡Cambridge Health Alliance, Division of Occupational and Environmental Medicine, Cambridge, Massachusetts

‡‡New England Pediatric Environmental Health Specialty Unit, Boston, Massachusetts

°Co-first authors

Section Editor: Anna McFarlin, MD

Submission history: Submitted March 9, 2020; Revision received July 6, 2020; Accepted July 3, 2020

Electronically published August 2, 2020

Full text available through open access at http://escholarship.org/uc/uciem_cpchem

DOI: 10.5811/cpchem.2020.7.47267

Introduction: Copper is an uncommon source of metal toxicity in children that requires a high index of suspicion for diagnosis.

Case Report: We describe the unique presentation of a 12-month-old girl who developed acute onset of vomiting and diarrhea after ingestion of a copper-contaminated birthday cake.

Conclusion: This case highlights the presentation, evaluation, and management of the rare pediatric patient who presents with copper poisoning. This case also illuminates the public health implications of potential metal poisoning when using non-edible decorative products in homemade and commercially prepared baked goods. [Clin Pract Cases Emerg Med. 2020;4(3):384–388.]

Keywords: *copper; toxicology; ingestion; poison; pediatric.*

INTRODUCTION

Copper is an essential trace element in humans that is used as a cofactor in many redox reactions, including mitochondrial oxidative phosphorylation, free radical detoxification, neurotransmitter formation, pigment synthesis, connective tissue synthesis, and iron metabolism. Low amounts of copper are found in foods such as animal liver, crustaceans, shellfish, green vegetables, dried fruit, nuts, and chocolate. High levels of copper can cause toxicity, often secondary to exposure to pesticides,

fungicides, copper-contaminated pipe water and water treatment systems.¹⁻² We present a review of the literature on copper poisoning and a case report of a pediatric patient presenting to the emergency department (ED) following a known copper ingestion.

CASE REPORT

A 12-month-old female with no significant medical history presented to the ED with listlessness four days following one day of resolved gastrointestinal symptoms. Her

symptoms began after ingestion of birthday cake with rose-gold frosting from a local bakery (Images 1 and 2).

Within 20 minutes of cake consumption, the patient experienced six episodes of non-bloody, non-bilious vomiting and several episodes of non-bloody diarrhea. Multiple other guests developed similar symptoms that resolved after several hours.

The patient saw her pediatrician, who suspected a foodborne illness or other toxic exposure and called the regional poison control center, which in turn involved the Department of Health (DOH). The DOH found that only guests who ate frosted cake developed vomiting or diarrhea. Guests who did not eat the cake or ate cake without frosting had no symptoms. The DOH did not report the discovery of bacteria or other infectious agents. The DOH conducted an investigation into the bakery. The cake had been frosted with a rose-gold luster dust labeled “non-edible non-toxic for decoration only” (Image 3) that was mixed into a butter extract and painted onto the cake.

Based on the material safety data sheet provided by the supplier, the luster dust contained elemental copper. Chemical testing of the luster dust and leftover frosted birthday cake was performed by the state health laboratory. The cake frosting contained 21.1 milligrams (mg) of copper per gram. Each cake slice was estimated to contain 40 grams of frosting. Thus, each slice contained approximately 900 mg of copper.⁴ For comparison, beef liver, a copper-rich food, contains 0.157 mg of copper per gram, or 17 mg of copper for a 4-ounce portion.⁵ The DOH reported that the symptoms, timeline of illness, and laboratory evidence were consistent with copper poisoning from cake frosting.⁴

The investigation results were released four days after the patient’s exposure to the copper-contaminated cake. On the same day, she developed listlessness, poor oral intake, and what the parents thought was a facial droop. The pediatrician was concerned these symptoms could be due to ongoing



Image 1. Birthday cake with rose-gold luster dust frosting, the consumption of which led to copper toxicity.

CPC-EM Capsule

What do we already know about this clinical entity?

Copper poisoning is an uncommon metal toxicity that is often secondary to exposure to pesticides, fungicides, contaminated pipe water or water treatment systems.

What makes this presentation of disease reportable?

We describe the presentation, evaluation, and management of a pediatric patient with copper poisoning from a previously unreported source.

What is the major learning point?

Popular decorative products used in the commercial baking industry are a potential source of copper or other heavy metal poisoning.

How might this improve emergency medicine practice?

This newly recognized source of copper toxicity requires a high index of clinical suspicion from providers to ensure appropriate history-taking, evaluation, and management.

copper toxicity. After consultation with the regional poison control center, the patient was referred to the ED.

The patient’s ED vital signs were temporal temperature 36.9 degrees Celsius; heart rate 130 beats per minute; respiratory rate 40 breaths per minute; blood pressure 93/77 millimeters of mercury, and oxygen saturation 95% on room air. Physical exam showed a happy, interactive child with normal pulmonary, cardiac, abdominal, neurologic (no facial droop or focal neurologic symptoms), and skin examinations. The regional poison control center was contacted to discuss management given the concern for copper toxicity. A comprehensive metabolic panel and complete blood count were normal. A nasal swab was positive for rhinovirus/enterovirus. Copper and ceruloplasmin levels were sent. Given the patient’s well appearance, normal vital signs, normal laboratory results, and the unlikely possibility of copper-related delayed neurologic effects, no chelation was started pending copper studies. The patient was admitted to the hospital for observation.

On hospital day two, the patient’s total serum copper level resulted at 97 micrograms per deciliter (mcg/dL) (reference range 85-185 mcg/dL) and her ceruloplasmin level was 22 mg/dL (reference range 20-60 mg/dL). Her calculated non-



Image 2. Slice of birthday cake with rose-gold luster dust frosting, the consumption of which led to copper toxicity.

ceruloplasmin bound or free copper level was elevated at 31 mcg/dL (reference range 0-10 mcg/dL). Her physical exam remained normal. No chelation therapy or other interventions were initiated, and she was discharged home.

One month later, she was seen in the pediatric environmental health clinic. Her parents reported that the patient was back at her baseline. She had a normal physical examination and normal laboratory tests including total serum copper of 94 mcg/dL (reference range 70-150 mcg/dL) and free non-ceruloplasmin-bound copper <2.5 mcg/dL (reference range 0-10 mcg/dL).

The bakery was fined and prohibited from using the rose-gold luster dust and any other decoration unless specifically labeled as edible. The DOH visited additional establishments and issued guidance about these products to all bakeries in the state.

DISCUSSION

The mechanism of action of copper toxicity is through the creation of reactive oxygen species that cause oxidative cell damage and death.² Copper ingestion typically presents first with gastrointestinal symptoms including vomiting and abdominal pain, followed by gastroduodenal hemorrhage, ulceration or perforation in severe cases. Copper is then bound rapidly from the gastrointestinal tract by carrier proteins, ceruloplasmin and albumin, and transported to the liver and other tissues, where it can cause hepatotoxicity, methemoglobinemia and rhabdomyolysis. Hemolysis can occur within 24 hours from ingestion.^{1,6,7} The biological half-life of copper ranges from 13-33 days,⁸ and is predominantly eliminated via biliary excretion at an average rate of 2 mg per 24 hours.⁷

Prior studies on copper toxicity have focused on copper salt ingestions, such as copper sulfate. Elemental copper ingestions, such as in coin ingestions, usually do not cause toxicity unless in an acidic environment when elemental copper can transform into reactive copper ions. There have been prior copper toxicity cases in the setting of consuming beverages exposed to copper-contaminated bottle pourers, boilers, and cocktail shakers.⁹ The State of Iowa Alcoholic Beverages Division therefore recommends avoiding using unlined copper mugs for beverages

with a pH below 6.0, such as Moscow Mules.³ There are no published cases of copper powder ingestion causing toxicity. This patient case is therefore the first documented case of elemental copper powder ingestion causing toxicity in humans.

This case highlights the challenges in diagnosing and treating copper toxicity. If the patient had presented to the ED prior to the DOH investigation, given the simultaneous onset of gastrointestinal symptoms among the other guests, a foodborne microbial or toxin-mediated etiology may have been suspected instead of metal poisoning. However, it is important for clinicians to note that the onset of nausea and vomiting within 30 minutes of exposure is more consistent with metal or toxicant poisoning in contrast to foodborne illness, which typically takes several hours from exposure to symptom development. The patient's listlessness and poor oral intake during her ED visit four days after cake ingestion were also likely due to rhinovirus, as diagnosed by nasal swab, rather than ongoing copper toxicity.

Laboratory testing for copper toxicity, to confirm diagnosis or direct treatment, presents several challenges. Serum copper levels are not associated with copper toxicity severity.⁶ Additionally, no standardized serum copper reference range exists for infants, toddlers, or young school-age children. The youngest children for which a reference range is available are 6- to 11-year-old children, where the average serum copper concentration was 119 mcg/dL, and 95th percentile was 157 mcg/dL.¹⁰ We identified only one article in the literature that evaluated copper concentrations among healthy 6-month-old to 2-year-old children and showed an average serum copper concentration of 111 mcg/dL (standard deviation 26, range 72-178).¹¹

The lack of a standardized reference range for infants was reinforced when the two hospitals that tested the patient's serum copper level provided different reference ranges: 85-185 mcg/dL (Lifespan hospitals, all ages); and 70-150 mcg/dL (Boston Children's Hospital, with a note that mean levels are

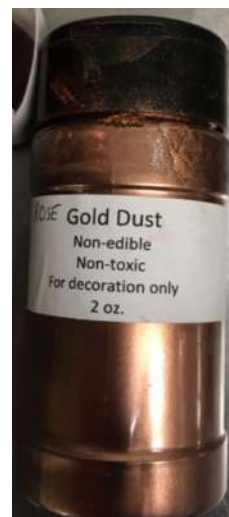

Image 3. Rose-gold luster dust vial used to provide decorative color to cake frosting, resulting in copper toxicity.

higher in women and children). While there is limited data on standardized serum copper level reference ranges for infants, our patient's serum copper level of 97 mcg/dL was within a similar normal reference range from available studies. However, the time from her exposure to copper level blood draw was four days, which may have allowed for normalization of her serum copper concentration.

Finally, even in the setting of normal total serum copper and ceruloplasmin levels, non-ceruloplasmin-bound or free copper levels can be elevated, which can suggest excessive copper ingestion. Based on Wilson's disease studies, routine serum copper levels performed in laboratories include both bound and unbound serum copper and may be falsely normal depending on ceruloplasmin levels.¹² To determine the form of copper that is free for deposition in tissues and toxic to cells, the non-ceruloplasmin-bound copper level should be calculated. The non-ceruloplasmin-bound copper level is calculated using the following equation: Non-ceruloplasmin-bound copper (mcg/dL) = serum copper (mcg/dL) – (3 x serum ceruloplasmin [mg/dL]).¹² In our patient, the calculated non-ceruloplasmin-bound copper level was elevated at 31 mcg/dL (reference range 0-10 mcg/dL).

The management of acute copper poisoning includes supportive care, fluid resuscitation for hemodynamic instability, replacement of gastrointestinal losses, and symptom management. Useful lab studies include those that evaluate for end-organ damage from copper deposition, dehydration, rhabdomyolysis, and methemoglobinemia in cyanotic patients. The interpretation of copper studies, especially in pediatric patients, can be difficult to reconcile with clinical symptoms. Normal values do not exclude exposure. The timing and type of copper biomonitoring are crucial given copper metabolism and non-standardized copper reference ranges. Regional poison control centers should be consulted to guide evaluation and management, including the decision for chelation. While there are limited studies regarding the efficacy of chelation, it should be considered when there are hepatic, hematologic, or other severe manifestations of toxicity.¹² Clinically available chelators include oral penicillamine, oral triethylenetetramine (Trientine), and intramuscular dimercaprol.⁷ If considering chelation, poison control center consultation is recommended to formulate individualized management plans, especially to engage in risk-benefit decision-making regarding chelation.

From a public health perspective, it is important for home and commercial bakers to be aware of the dangers of metal poisoning from decorative products. The DOH visited additional bakeries and found that one-third of the bakeries were using inedible luster dust on edible food products. The DOH issued guidance to bakeries, clarifying that the label "non-toxic" does not equate to being edible, and that edible luster dusts must have an ingredient list on the product label. The public health investigation into this particular case initiated other state investigations with similar findings of metals, such as lead, in decorative cakes.¹³ The United States Food and Drug

Administration has since released guidelines on how to use these decorative products appropriately and ways to determine whether decorative products are safe and edible.¹⁴

CONCLUSION

Copper poisoning in children is rare and may be difficult to diagnose but can have significant morbidities.^{1,2} When copper poisoning is suspected, laboratory studies that evaluate for end-organ damage, dehydration, rhabdomyolysis, and methemoglobinemia should be obtained. The utility of copper studies is limited. Treatment consists of predominantly supportive care, and the decision for chelation should be made in consultation with the regional poison control center. A new source of this uncommon metal poisoning is decorative products used in popular custom-made specialty baked goods, and requires a high index of clinical suspicion to ensure appropriate history-taking, evaluation, and management.

ACKNOWLEDGMENTS

The authors thank Evan Philo at the Rhode Island State Health Laboratories, Charles McGinnis at the Rhode Island Department of Health Center for Acute Infectious Disease Epidemiology, Brendalee Viveiros and Genevieve Caron at the Rhode Island Department of Health Center for Food Protection, and the New England Pediatric Environmental Health Specialty Unit for their help with this case.

The authors attest that their institution requires neither Institutional Review Board approval, nor patient consent for publication of this case report. Documentation on file.

Address for Correspondence: Hoi See Tsao, MD, Warren Alpert Medical School of Brown University, Department of Emergency Medicine, 55 Claverick St, Office 243, Providence, RI 02903. Email: hoi_see_tsao@brown.edu.

Conflicts of Interest: By the CPC-EM article submission agreement, all authors are required to disclose all affiliations, funding sources and financial or management relationships that could be perceived as potential sources of bias. The authors disclosed none.

Copyright: © 2020 Tsao et al. This is an open access article distributed in accordance with the terms of the Creative Commons Attribution (CC BY 4.0) License. See: <http://creativecommons.org/licenses/by/4.0/>

REFERENCES

1. Blundell S, Curtin J, Fitzgerald D. Blue lips, coma and haemolysis. *J Paediatr Child Health*. 2003;39(1):67-8.
2. Crisponi G, Nurchi VM, Fanni D, et al. Copper-related diseases:

- from chemistry to molecular pathology. *Coord Chem Rev.* 2010;254(7):876-89.
3. Advisory Bulletins - Iowa Alcoholic Beverages Division. Use of Copper Mugs in the Serving of Alcoholic Beverages. Available at: https://abd.iowa.gov/sites/default/files/advisory_bulletin_-_use_of_copper_mugs_in_the_serving_of_alcoholic_beverages_-_july_28_2017.pdf. Accessed July 5, 2020.
 4. Rhode Island Department of Health, Division of Preparedness, Response, Infectious Disease, and EMS, Center for Acute Infectious Disease Epidemiology. Copper Poisoning. 2018.
 5. Bost M, Houdart S, Oberli M, et al. Dietary copper and human health: current evidence and unresolved issues. *J Trace Elem Med Biol.* 2016;35:107-15.
 6. Saravu K, Jose J, Bhat MN, et al. Acute ingestion of copper sulphate: a review on its clinical manifestations and management. *Indian J Crit Care Med.* 2007;11(2):74.
 7. Nelson LS, Howland MA, Lewin NA, et al. (2019). Copper. In: Howland MA (Ed.). *Goldfrank's Toxicologic Emergencies, 11th Edition*. San Francisco, CA: McGraw-Hill Education.
 8. Johnson PE, Milne DB, Lykken GI. Effects of age and sex on copper absorption, biological half-life, and status in humans. *Am J Clin Nutr.* 1992;56(5):917-25.
 9. National Research Council (US) Committee on Copper in Drinking Water. (2000). Copper in Drinking Water. Chapter 5: Health Effects of Excess Copper. Table 5-1: Case Reports of Copper Toxicosis Following Oral Exposures of Humans to Copper Salts. Washington, DC: National Academy Press (US). Available at: https://www.ncbi.nlm.nih.gov/books/NBK225397/pdf/Bookshelf_NBK225397.pdf. Accessed June 10, 2020.
 10. Centers for Disease Control and Prevention. Fourth National Report on Human Exposure to Environmental Chemicals. 2019. Available at: https://www.cdc.gov/exposurereport/pdf/FourthReport_UpdatedTables_Volume1_Jan2019-508.pdf. Accessed June 10, 2020.
 11. Lin CN, Wilson A, Church BB, et al. Pediatric reference intervals for serum copper and zinc. *Clinica Chimica Acta.* 2012;413(5-6):612-5.
 12. Pfeiffer RF. Wilson's disease. *Semin Neurol.* 2007;27(2):123-32.
 13. Missouri Department of Health and Senior Services. Consumer Advisory Issued for Sunflower Sugar Art Products. 2019. Available at: <https://health.mo.gov/news/newsitem/uuid/7a575955-0c0c-4d70-a2ea-3b63f4c4f48c/consumer-advisory-issued-for-sunflower-sugar-art-products>. Accessed June 10, 2020.
 14. United States Food & Drug Administration. FDA advises home and commercial bakers to avoid use of non-edible food decorative products. 2018. Available at: <https://www.fda.gov/food/food-additives-petitions/fda-advises-home-and-commercial-bakers-avoid-use-non-edible-food-decorative-products>. Accessed June 10, 2020.

Euglycemic Diabetic Ketoacidosis Precipitated by SGLT-2 Inhibitor Use, Pericarditis, and Fasting: A Case Report

Rebecca A. Mendelsohn, MD
Anabelle N. Taveras, MD
Benjamin A. Mazer, MD
Lisa M. Clayton, DO, MBS

Florida Atlantic University Charles E. Schmidt College of Medicine, Department of
Emergency Medicine, Boca Raton, Florida

Section Editors: Austin Smith, MD

Submission history: Submitted December 3, 2019; Revision received April 1, 2020; Accepted April 3, 2020

Electronically published June 15, 2020

Full text available through open access at http://escholarship.org/uc/uciem_cpem

DOI: 10.5811/cpem.2020.4.46056

Introduction: Diabetic ketoacidosis (DKA) is a potentially life-threatening complication of diabetes mellitus. Less prevalent is euglycemic DKA (eDKA)—DKA with serum glucose less than 200 mg/dL; however, it is increasing in frequency with the introduction of sodium glucose cotransporter 2 (SGLT-2) inhibitors for treatment of type 2 diabetes.

Case Report: We report a case of SGLT-2 inhibitor-associated eDKA presenting with concurrent acute pericarditis.

Discussion: Our case suggests that the cause of eDKA can be multifactorial when decreased oral intake occurs in the setting of an acute cause of physiologic stress.

Conclusion: Prompt recognition of eDKA in the emergency department may allow earlier diagnosis and treatment directed at one or more of its underlying causes. [Clin Pract Cases. 2020;4(3):389–392.]

Keywords: *Euglycemic DKA; SGLT-2 Inhibitor; Pericarditis; Fasting.*

INTRODUCTION

Since their advent within the past decade, sodium glucose cotransporter 2 (SGLT-2) inhibitors, such as canagliflozin, empagliflozin, and dapagliflozin have gained considerable traction as a result of their highly favorable therapeutic indications. These medications have revolutionized diabetic treatment protocols by lowering patients' blood glucose, blood pressure, and uric acid, while also promoting weight loss, and improving patients' cardio-renal outcomes in patients with type 2 diabetes.^{1,2} The most dangerous complication of SGLT-2 inhibitors is possible precipitation of euglycemic DKA (eDKA), a state of DKA in which the serum glucose level is grossly normal (less than 200 mg/dL). While providers are becoming more and more aware of this clinical entity as of recently, many of these cases have gone undiagnosed or misdiagnosed.

In the past few years, reported cases of eDKA have risen sharply, in part due to increasing physician familiarity

with the diagnosis as well as the increased number of SGLT-2 inhibitors being prescribed. Other independent factors that predispose patients to eDKA are similar to risk factors for classic DKA and include decreased oral intake, insulin reduction/cessation, infections, hepatic, cardiac, or renal insults, pancreatitis, and alcohol intake.³ The presence of multiple risk factors for eDKA should raise the index of suspicion for this diagnosis in the emergency department (ED). eDKA is a diagnostic challenge because normal blood glucose levels may lead to a false reassurance of a patient's clinical stability, an inappropriately low triage priority, and even a delay in the initiation of critical treatment.⁵ Prompt recognition and workup of clinically significant acidosis with quantitative serum ketone measurement is crucial to the diagnosis and management of eDKA in the ED. We believe this to be the first reported case of pericarditis-associated eDKA in the setting of SGLT-2 inhibitor use.

CASE REPORT

A 39-year-old male with a history of hyperlipidemia and non-insulin-dependent type 2 diabetes mellitus managed with metformin and empagliflozin presented to our ED complaining of three days of substernal chest pain. He reported that the pain was constant, worsening on inspiration and while leaning forward, and associated with palpitations. The patient also disclosed that for the preceding 10 days he had been maintaining a strict daytime fast for the religious holiday of Ramadan. He denied radiation of his pain, infectious symptoms, neurological symptoms, shortness of breath, abdominal pain, or dysuria. He also denied any history of connective tissue disorder. He had no recent surgical history. His family history was significant for a father with type 2 diabetes, chronic kidney disease, and early coronary artery disease. The patient denied use of alcohol, tobacco, or illicit drugs of any kind. His only recent travel was a four-hour flight two weeks prior.

On initial evaluation, the patient was afebrile, tachycardic, and hypertensive (97.8° Fahrenheit, 116 beats per minute, 148/96 millimeters of mercury (mm Hg), 15 breaths per minute, oxygen saturation of 100% on 2 liters nasal cannula). His cardiac examination revealed tachycardia with normal first and second heart sounds, no murmurs, rubs, or gallops. He had normal capillary refill in his extremities and no peripheral edema. The rest of his physical examination was otherwise benign. Initial electrocardiogram revealed sinus tachycardia, significant ST-segment elevation in the precordial leads, minimal ST-segment elevation in the limb leads, ST depression in aVR, and widespread PR-segment depression. There was no evidence of ectopy, and the axis and intervals were otherwise normal. Additional workup included basic laboratory studies, cardiac enzymes, inflammatory markers, chest radiograph, and computed tomography angiography (CTA) of the chest.

Initial workup revealed leukocytosis of 13.1×10^9 per liter (L) ($5.0\text{--}10.0 \times 10^9$ /L), negative troponin, and elevated inflammatory markers with C-reactive protein of 30.43 milligrams per deciliter (mg/dL) (0-0.74 mg/dL) and erythrocyte sedimentation rate of 75 millimeters per hour (mm/h) (0-20 mm/h). CTA of the chest revealed tiny pericardial effusion with some inflammatory changes suspicious for pericarditis and no evidence of pulmonary emboli. These findings strongly supported the diagnosis of pericarditis, and he was given a dose of intravenous toradol with subsequent improvement in his chest pain. Critically, he also had a high anion-gap acidosis with bicarbonate of 12 millimoles per liter (mmol/L) (22-32 mmol/L), anion gap of 22 milliequivalents per liter (mEq/L) (5-15 mEq/L), serum glucose of 158 mg/dL (74-118 mg/dL) and an arterial blood gas showing a pH of 7.22 (7.35-7.45), partial pressure of carbon dioxide 20.5 mmHg (35-45 mmHg), partial pressure of oxygen 115.3 mmHg (75-100 mmHg), and bicarbonate of 8.3 mmol/L (22-27 mmol/L). His lactate was normal at 1.3 mmol/L (.5-2.2 mmol/L). Cognizant of recent reports of eDKA associated with

CPC-EM Capsule

What do we already know about this clinical entity?

Euglycemic diabetic ketoacidosis (eDKA) is a form of ketoacidosis most closely associated with use of sodium glucose cotransporter 2 (SGLT-2) inhibitors.

What makes this presentation of disease reportable?

This patient presented with eDKA in the setting of SGLT-2 inhibitor use, daytime fasting, and acute pericarditis.

What is the major learning point?

Patients taking SGLT-2 inhibitors can develop eDKA in the setting of even mildly decreased oral intake if another physiologic stressor is present.

How might this improve emergency medicine practice?

Prompt recognition of eDKA in the emergency department may allow earlier diagnosis and treatment directed at one or more of its underlying causes.

SGLT-2 inhibitors such as empagliflozin, we sent a serum beta-hydroxybutyrate level which returned at 116.1 mg/dl (0.21-2.8 mg/dL), confirming our suspicion for eDKA. His empagliflozin was stopped immediately, and he was admitted to the intensive care unit on intravenous (IV) drips of insulin and dextrose-containing maintenance fluid.

While being treated for eDKA, the patient's pericarditis was treated with oral colchicine. Over the next two days, his acidosis improved and his anion gap closed. However, he developed a large pericardial effusion, which required emergency pericardiocentesis with placement of a pigtail pericardial drain. Serum polymerase chain reaction was positive for multiple strains of coxsackievirus A and B. The patient was discharged home on hospital day five with his medication changed to metformin and glipizide.

DISCUSSION

There is abundant evidence that SGLT-2 inhibitors lower patients' overall risk of myocardial infarction and stroke.^{6,7} Unlike many other diabetic medications, they improve morbidity and mortality without posing a significant risk of hypoglycemia.⁸ The global prevalence of these medications will surely increase in the coming years, emphasizing

the importance of widespread emergency physician (EP) awareness of eDKA recognition and management.

A number of expert-written position papers argue that the ample benefits of SGLT-2 inhibitors outweigh the nominal risk of eDKA.⁵ However, in 2015 the US Food and Drug Administration released drug safety warnings about the risk of eDKA with the use of SGLT-2 inhibitors.⁹ Factors known to cause SGLT-2 inhibitor-associated eDKA include decreased oral intake, increased alcohol consumption, surgery, illness, glycogen storage disorders, and pregnancy.¹⁰ Specifically, decreased oral intake is the most frequently cited precipitant.⁵ However, our patient had managed to avoid any serious complications for a number of years despite taking an SGLT-2 inhibitor while fasting. It was not until he presented with acute pericarditis in the setting of fasting that he developed eDKA. This highlights the observation that similar to classic DKA, any physiologic stressor can serve as a precipitating factor for eDKA.⁵

SGLT-2 inhibitors block the reabsorption of 30-50% of filtered glucose in urine by competitive inhibition of the proximal convoluted tubule and thereby increasing urinary glucose excretion.¹¹ The hypoglycemic effect of this carbohydrate deficit renders a metabolic shift from glucose utilization to lipid utilization. The lower blood glucose causes a decrease in circulating insulin and an increase in glucagon, hence a downward shift in the insulin:glucagon ratio. This leads to relative hyperglucagonemia, thereby promoting lipolysis fatty acid metabolism and ketogenesis. Decreased urinary excretion of ketones also contributes to ketonemia. Diet restriction works in an analogous way to stimulate glucagon secretion leading to reduced glycogen reserves and increased free fatty acid metabolism and ketogenesis.¹² Diabetic patients taking SGLT-2 inhibitors already have decreased glycogen reserves. Any factor that further exacerbates this metabolic state can serve as a catalyst for eDKA.

Physiologic stressors such as illness/surgery increase the counter-regulatory hormones adrenaline and cortisol, thereby promoting increased insulin resistance and protein catabolism.¹³ In addition, physiologic stress causes increased stimulation of α 1- and β -adrenergic receptors on pancreatic α -cells, promoting glucagon secretion. The reduced insulin:glucagon ratio promotes lipolysis, hepatic fatty acid oxidation, and ketogenesis. In fact, hyperglucagonemia is widely considered a surrogate marker for physiological stress. In a mechanism similar to fasting, acute pericarditis, or any physiologic stressor for that matter, can potentially bring about clinically significant ketoacidosis.

The prognosis of ketoacidosis depends largely on how expediently it is recognized and treated. Increased use of SGLT-2 inhibitors has directly correlated with the increased incidence of eDKA. Therefore, the workup of diabetic patients presenting with nausea, vomiting, abdominal pain, dyspnea, lethargy, and unexplained acidosis should include quantitative serum ketone measurement, even in the setting of normal glucose levels. Urine ketone assessment is insufficient to screen for the diagnosis because it only measures acetoacetate when the

predominant ketone body in eDKA is B-hydroxybutyrate.¹⁴ After immediate cessation of SGLT-2 inhibitors, the treatment for eDKA is virtually identical to that of classic DKA, with the exception that dextrose-containing IV fluids must be initiated at the same time as insulin to prevent hypoglycemia.¹⁵

CONCLUSION

Prescriptions for oral SGLT-2 inhibitors have increased in recent years as a result of their favorable therapeutic profile. However, cases involving potentially lethal eDKA have increased throughout the United States. Providers need to be vigilant about prescribing SGLT-2 inhibitors to those who are at risk of physiologic stress such as fasting, dehydration, extreme temperature exposure, strenuous exercise, illness, surgery, or infection. Perhaps more importantly, EPs need to maintain a high index of suspicion when diabetics taking SGLT-2 inhibitors present with traditional DKA symptoms. Our case illustrates that once a diagnosis of eDKA is made, EPs still need to carefully assess for concurrent physiologic stressors that could affect overall morbidity and mortality.

The authors attest that their institution requires neither Institutional Review Board approval, nor patient consent for publication of this case report. Documentation on file.

Address for Correspondence: Lisa Clayton, DO, Florida Atlantic University, Department of Emergency Medicine, 2815 South Seacrest Blvd, Lower Level, Boynton Beach, FL 33435 Email: claytonl@health.fau.edu.

Conflicts of Interest: By the CPC-EM article submission agreement, all authors are required to disclose all affiliations, funding sources and financial or management relationships that could be perceived as potential sources of bias. The authors disclosed none.

Copyright: © 2020 Mendelsohn et al. This is an open access article distributed in accordance with the terms of the Creative Commons Attribution (CC BY 4.0) License. See: <http://creativecommons.org/licenses/by/4.0/>

REFERENCES

1. Wanner C, Inzucchi SE, Lachin JM, et al. Empagliflozin and progression of kidney disease in type 2 diabetes. *N Engl J Med*. 2016;375(4):323-34.
2. Peters AL, Buschur EO, Buse JB, et al. Euglycemic diabetic ketoacidosis: a potential complication of treatment with sodium-glucose cotransporter 2 inhibition. *Diabetes Care*. 2015;38(9):1687-93.
3. Rosenstock J and Ferrannini E. Euglycemic diabetic ketoacidosis: a predictable, detectable, and preventable safety concern with SGLT2

- inhibitors. *Diabetes Care*. 2015;38(9):1638-42.
4. Chou YM, Seak CJ, Goh ZN, et al. Euglycemic diabetic ketoacidosis caused by dapagliflozin: a case report. *Medicine (Baltimore)*. 2018;97(25):11056.
 5. Zinman B, Wanner C, Lachin JM, et al. Empagliflozin, cardiovascular outcomes, and mortality in type 2 diabetes. *N Engl J Med*. 2015;373(22):2117-28.
 6. Mahaffey KW, Neal B, Perkovic V, et al. Canagliflozin for primary and secondary prevention of cardiovascular events: results from the CANVAS program (Canagliflozin Cardiovascular Assessment Study). *Circulation*. 2018;37:323-34.
 7. Clar C, Gill JA, Court R, et al. Systematic review of SGLT2 receptor inhibitors in dual or triple therapy in type 2 diabetes. *BMJ Open*. 2012;2:e001007.
 8. U.S. Food and Drug Administration. Center for Drug Evaluation and Research. FDA Drug Safety Communication: FDA revises labels of SGLT2 inhibitors for diabetes to include warnings about too much acid in the blood and serious urinary tract infections. Available at: <https://www.fda.gov/drugs/drugsafety/ucm475463.htm>. September 6, 2019.
 9. Xiaofang Y, Saifei Z, Long Z. Newer perspectives of mechanisms for euglycemic diabetic ketoacidosis. *Int J Endocrinol*. 2018;2018(7074868):1-8.
 10. Fioretto P, Zambon A, Rossato M, et al. SGLT2 inhibitors and the diabetic kidney. *Diabetes Care*. 2016;39:165-71.
 11. Bonner C, Kerr-Conte J, Gmyr V, et al. Inhibition of the glucose transporter SGLT2 with dapagliflozin in pancreatic alpha cells triggers glucagon secretion. *Nat Med*. 2015;21(5):512-7.
 12. Thiruvankatarajan V, Meyer EJ, Nanjappa N, et al. Perioperative diabetic ketoacidosis associated with sodium-glucose co-transporter-2 inhibitors: a systematic review. *Br J Anaesth*. 2019;123(1):27-36.
 13. Rumbak MJ, Hughes TA, Kitabchi AE. Pseudonormoglycemia in diabetic ketoacidosis with elevated triglycerides. *Am J Emerg Med*. 1991;9(1):61-3.
 14. Kailash P, Weaver K, Shafer K. Euglycemic DKA secondary to SGLT2 inhibitors. emDOCs.net-Emergency Medicine Education. Available at: <http://www.emdocs.net/euglycemic-dka-secondary-sglt2-inhibitors/>. Accessed September 6, 2019.

Acute Acalculous Cholecystitis from Infection with Epstein–Barr Virus in a Previously Healthy Child: A Case Report

Robert Langenohl, DO
Scott Young, DO
Kyle Couperus, MD

Madigan Army Medical Center, Department of Emergency Medicine, Tacoma, Washington

Section Editor: Anna McFarlin, MD

Submission history: Submitted December 26, 2019; Revision received April 20, 2020; Accepted April 30, 2020

Electronically published June 15, 2020

Full text available through open access at http://escholarship.org/uc/uciem_cpem

DOI: 10.5811/cpcem.2020.4.46301

Background: Acute cholecystitis is the acute inflammation of the gallbladder. In adults it is most frequently caused by a gallstone(s) obstructing outflow from the cystic duct, leading to gallbladder distention and edema with eventual development of biliary stasis and bacterial overgrowth, often requiring operative management. However, in children acalculous cholecystitis is more common and is often the result of an infectious process.

Case Report: Here we present a case of acute acalculous cholecystitis caused by infection with Epstein-Barr virus in an otherwise healthy three-year-old male.

Conclusion: Acalculous cholecystitis is an uncommon but potentially significant complication of Epstein-Barr virus infection in the pediatric population. Emergency providers should consider this diagnosis in any child being evaluated for EBV with the complaint of abdominal pain. [Clin Pract Cases Emerg Med. 2020;4(3):393–396.]

Keywords: *Epstein-Barr; acalculous cholecystitis.*

INTRODUCTION

Acute cholecystitis is described as the acute inflammation of the gallbladder. Incidence rates of gallbladder disease in children are estimated at 1.3 cases for every 1000 adult cases, although these numbers have been increasing over the past decade.^{1,2} Cases in adults are classically associated with gallstones obstructing outflow from the cystic duct, leading to gallbladder distention and edema with eventual development of biliary stasis and bacterial overgrowth. This is often a surgical disorder and requires operative management for definitive treatment. In children, acalculous cholecystitis, or gallbladder inflammation in the absence of gallstones, is more common, occurring in up to 70% of pediatric cases, as opposed to 5-10% of adult cases.³ It has several proposed mechanisms and has been shown to be related to several infectious processes. Here we present a case of acute acalculous cholecystitis caused by infection with Epstein-Barr virus (EBV) in an otherwise healthy, immunocompetent three-year-old male.

CASE REPORT

A three-year-old male, without medical comorbidity, presented to his primary care physician's office with progressive night-time fevers for the previous three days. His parents also stated that he had developed abdominal pain and had several non-bloody loose stools. His mother reported that his bowel movements were painful, and that he had decreased urinary output and a poor appetite. His abdominal exam at that time demonstrated diffuse tenderness without localization. Labs were ordered, but after several unsuccessful attempts were unable to be obtained. The patient was ultimately diagnosed with a viral syndrome and sent home.

Approximately 10 days later the patient was brought to a local emergency department for continued fatigue, increased "whining," and persistent fevers. The physical exam revealed a fussy, but otherwise well-appearing male. He was alert, irritable, with slight conjunctival icterus and anterior/posterior cervical lymphadenopathy. Cardiovascular and pulmonary

exams were within normal limits. His abdomen was non-distended, soft, with diffuse abdominal tenderness and he was found to have 5 centimeters (cm) hepatomegaly and 4 cm splenomegaly. Labs were notable for a leukocytosis of 63×10^3 per microliter (μL) ($4\text{--}10 \times 10^3/\mu\text{L}$); platelets of $120 \times 10^3/\mu\text{L}$ ($150\text{--}450 \times 10^3/\mu\text{L}$); and a significant elevation in serum aspartate aminotransferase (AST) and alanine aminotransferase (ALT) of 314 units per liter (U/L) (10–40 U/L) and 274 U/L (10–40 U/L), respectively. A right lower quadrant (RLQ) ultrasound was obtained to evaluate for appendicitis. The appendix was not well visualized but revealed a thickened gallbladder. A dedicated right upper quadrant (RUQ) ultrasound was then obtained showing evidence of cholecystitis with gallbladder wall thickening and edema. The patient was transferred to our tertiary care center for further management.

Upon arrival the patient was slightly tachycardic with remaining vital signs being unremarkable. The family confirmed an absence of previous medical or surgical history and denied known drug allergies. Family history was notable for a father with a history of gallstones. The patient lived in Washington state with his parents and siblings with no recent travel or camping. No sick contacts were reported. Additional testing was performed with a negative respiratory viral panel, a continued leukocytosis of $52.9 \times 10^3/\mu\text{L}$ ($4\text{--}10 \times 10^3/\mu\text{L}$), with 6% lymphocytes of which 61% were atypical. Liver function tests remained elevated with an ALT of 247 U/L (10–40 U/L) and AST of 259 U/L (10–40 U/L), a total bilirubin of 4.3 milligrams (mg) per deciliter (mg/dL) (0.3–1.0 mg/dL) with a lipase of 16 U/L (10–140 U/L). A chest radiograph was ordered, which returned with a new moderate right pleural effusion with a hazy opacity of the right hemithorax and mild contralateral shift of the mediastinum. A computed tomography (CT) of the chest/abdomen/pelvis was then obtained, which revealed a thickened gallbladder with a common bile duct not well visualized, but which appeared mildly dilated for patient's age at 4 millimeters (mm). The CT also re-demonstrated the previously visualized large right pleural effusion and trace left pleural effusion with associated atelectasis and small volume ascites. The spleen and kidneys measured large for the patient's age but were without abnormal appearance. There was no discrete mass or lymphadenopathy identified.

The patient was ultimately evaluated by gastroenterology, general surgery, and hematology/oncology, in the setting of significant leukocytosis for evaluation of possible leukemic process. No surgical intervention was recommended, and the patient was started on broad-spectrum antibiotics. Testing for EBV was performed in the setting of hepatosplenomegaly and leukocytosis. Immunoglobulin-M antibodies were elevated, indicating an acute infection. Symptomatic treatment was continued, and broad-spectrum antibiotics were withdrawn in the setting of an identified viral etiology. After approximately two weeks the patient was discharged from the hospital.

CPC-EM Capsule

What do we already know about this clinical entity?

Acalculous cholecystitis is acute gallbladder inflammation in the absence of gallstones. It is frequently seen in adults and associated with significant mortality.

What makes this presentation of disease reportable?

Acute acalculous cholecystitis in the setting of Epstein-Barr virus (EBV) infection is a rare occurrence in otherwise healthy children.

What is the major learning point?

Acute acalculous cholecystitis is an uncommon but potentially significant complication of EBV infection in the pediatric population.

How might this improve emergency medicine practice?

Emergency providers should become more aware of this process and consider this diagnosis in any child being evaluated for EBV with the complaint of abdominal pain.

DISCUSSION

EBV belongs to the Herpesviridae family. It was first discovered in 1964 and was conclusively linked to being the causative agent of infectious mononucleosis in 1968.^{4,5} EBV is thought to be prevalent in the majority of the adult population with recent studies estimating that greater than 90% of the adult population are antibody positive, indicating a previous infection, thought to occur in childhood.⁶ EBV is primarily transmitted via oral secretions, although it has been reported through organ transplantation and blood transfusions.⁷ EBV initially infects epithelial cells and naïve B lymphocytes and then spreads, causing primary symptoms before it enters a latent phase when all viral proteins are no longer expressed on the cell surface. Symptoms of primary infection are generally non-specific but consist of malaise, low-grade fever, and headache. These symptoms eventually progress to include sore throat, increased fever, nausea, vomiting, and anorexia. Median symptom duration is 16 days with a gradual return to baseline, which may occur over several months.⁸

Reactivation is uncommon in the otherwise healthy patient but can cause serious, life-threatening symptoms in the immunocompromised.⁹ Treatment of EBV infection is

generally symptomatic. Rarely, infection has been associated with complications including meningoencephalitis, hemolytic anemia, thrombocytopenia, myocarditis, pancreatitis, pericarditis, splenic rupture, and cholecystitis.⁴

Acute acalculous cholecystitis is defined as inflammation of the gallbladder in the absence of gallstones. It has been a known disorder for greater than 150 years but remains an elusive diagnosis.¹⁰ In adults it is rare and commonly associated with elderly patients who have recently undergone major surgery and tends to have a significantly elevated mortality rate.⁹ In children, however, the prognosis is generally better. Acalculous cholecystitis in the pediatric population results secondary to several mechanisms. It was previously thought to be seen only in critically ill children, or burn patients, as a result of impaired gallbladder emptying from increased use of total parenteral nutrition, increased use of opioids, and prolonged fasting.³ Acalculous cholecystitis has also been shown to develop in patients with autoimmune disorders such as Kawasaki disease or lupus.¹¹ More recently, cases have been seen in association with infectious processes. These infections include yeasts, parasites, and several bacterial species, including *Brucella*, *Leptospira*, *Salmonella*, staphylococcus, and viruses such as hepatitis A, cytomegalovirus, influenza, and Epstein Barr.¹²

The diagnosis of acute acalculous cholecystitis secondary to EBV infection in the pediatric population is challenging given an unreliable, age-dependent exam. As such, it is important to have a broad differential when it comes to the febrile pediatric patient with undifferentiated abdominal pain. The most common associated risk factors include trauma, recent surgery, burns, and sepsis.¹³ Acute acalculous cholecystitis is clinically indistinguishable from classic calculous cholecystitis, and as such laboratory evaluation will have similar findings.¹⁴ These findings are often not specific but generally reveal a marked leukocytosis and abnormal liver function tests.¹⁵ Therefore, imaging is often required for diagnosis.

The appropriate imaging modality varies based on patient age, illness severity, and local protocols. Ultrasound is often the first line study, but CT may be more beneficial if the diagnosis is unclear. Ultrasound will reveal evidence of cholecystitis: gallbladder wall thickness greater than 3.5 mm, gallbladder distention, sludge, and pericholecystic fluid, in the absence of gallstones.¹⁴ Even in the setting of known EBV infection, imaging may be indicated. In a study by Kim et al, almost one quarter (24/94) of pediatric patients with primary EBV infection showed evidence of gallbladder abnormalities on ultrasound, specifically a thickened gallbladder wall.¹⁴ This suggests that gallbladder disease in the setting of an EBV infection is more common than previously thought.

Treatment options for acute acalculous cholecystitis include antibiotics, cholecystostomy, or cholecystectomy. Early studies recommend early operation for adult patients with acute acalculous cholecystitis but remains controversial in the pediatric population.¹⁶ More recent recommendations support a nonsurgical approach as pediatric cases are often the

result of infectious processes. Broad-spectrum antibiotics are frequently initiated to cover for a possible secondary infection of enteric pathogens.¹⁷ In general, treatment is supportive, and patients recover over a few days.

CONCLUSION

Acalculous cholecystitis is an uncommon but potentially significant complication of Epstein-Barr virus infection in the pediatric population. Emergency providers should consider this diagnosis in any child being evaluated for EBV with the complaint of abdominal pain. If abdominal pain or tenderness is present, it is important to consider associated biliary pathology, such as acalculous cholecystitis. Treatment is generally supportive and symptoms often resolve over several days without operative management.

The authors attest that their institution requires neither Institutional Review Board approval, nor patient consent for publication of this case report. Documentation on file.

Address for Correspondence: Robert Langenohl, DO, Madigan Army Medical Center, Department of Emergency Medicine, 9040A Jackson Ave., Joint Base Lewis-McChord, WA 98431. Email: Robert.R.Langenhohl.mil@mail.mil.

Conflicts of Interest: By the CPC-EM article submission agreement, all authors are required to disclose all affiliations, funding sources and financial or management relationships that could be perceived as potential sources of bias. The views expressed here are those of the authors and do not reflect the official policy of the Department of the Army, the Department of Defense, or the U.S. Government. The authors disclosed none.

Copyright: © 2020 Langenohl et al. This is an open access article distributed in accordance with the terms of the Creative Commons Attribution (CC BY 4.0) License. See: <http://creativecommons.org/licenses/by/4.0/>

REFERENCES

1. Neville HL. Pediatric gallbladder disease surgery treatment & management: approach considerations, medical therapy, surgical therapy. 2019. Available at: <https://emedicine.medscape.com/article/936591-treatment>. Accessed October 10, 2019.
2. Doniger SJ.(2015). *Pediatric Emergency and Critical Care Ultrasound* (pp. 160-77). Cambridge, United Kingdom: Cambridge University Press.
3. Poddighe D and Sazonov V. Acute acalculous cholecystitis in children. *World J Gastroenterol.* 2018;24(43):4870-9.
4. Odumade OA, Hogquist KA, Balfour HH. Progress and problems in understanding and managing primary Epstein-Barr virus infections. *Clin Microbiol Rev.* 2011;24(1):193-209.

5. Henle G, Henle W, Diehl V. Relation of Burkitts tumor-associated herpes-type virus to infectious mononucleosis. *Proc Natl Acad Sci.* 1968;59(1):94-101.
6. Smatti MK, Al-Sadeq DW, Ali NH et al. Epstein–Barr virus epidemiology, serology, and genetic variability of LMP-1 oncogene among healthy population: an update. *Front Oncol.* 2018;8.
7. Chan ALF and Wang HYL. Epstein-Barr virus-related post-transplant lymphoproliferative disorder in a renal transplant recipient treated with tacrolimus and antithymocyte globulin. *Clin Drug Investig.* 2003;23(4):281-3.
8. Rea TD, Russo JE, Katon W, et al. Prospective study of the natural history of infectious mononucleosis caused by Epstein-Barr virus. *J Am Board Fam Pract.* 2001;14(4):234-42.
9. Maurmann S, Fricke L, Wagner HJ, et al. Molecular parameters for precise diagnosis of asymptomatic Epstein-Barr virus reactivation in healthy carriers. *J Clin Microbiol.* 2003;41(12):5419-28.
10. Sellar W. (1845). Northern J Medicine Vol 2 (pp. 151-3). Edinburgh, United Kingdom: Oliver & Boyd.
11. Basiratnia M, Vasei M, Bahador A, et al. Acute acalculous cholecystitis in a child with systemic lupus erythematosus. *Pediatr Nephrol.* 2006;21(6):873-6.
12. Lu Y-A, Chiu C-H, Kong M-S, et al. Risk factors for poor outcomes of children with acute acalculous cholecystitis. *Pediatr Neonatol.* 2017;58(6):497-503.
13. Huffman JL and Schenker S. Acute acalculous cholecystitis: a review. *Clin Gastroenterol Hepatol.* 2010;8(1):15-22.
14. Yi DY, Kim JY, Yang HR. Ultrasonographic gallbladder abnormality of primary Epstein–Barr virus infection in children and its influence on clinical outcome. *Medicine.* 2015;94(27).
15. Owen C and Jain R. Acute acalculous cholecystitis. *Curr Treat Options Gastroenterol.* 2005;8(2):99-104.
16. Yasuda H, Takada T, Kawarada Y, et al. Unusual cases of acute cholecystitis and cholangitis: Tokyo Guidelines. *Ann Hepatobiliary Pancreat Surg.* 2007;14(1):98-113.
17. Kottanattu L, Lava SA, Helbling R, et al. Pancreatitis and cholecystitis in primary acute symptomatic Epstein-Barr virus infection: systematic review of the literature. *J Clin Virol.* 2016;82:51-5.

Pneumocephalus and Facial Droop on an Airplane: A Case Report

Irina Sanjeevan-Cabeza, MD
Morgan Oakland, MD

Thomas Jefferson University Hospital, Department of Emergency Medicine,
Philadelphia, Pennsylvania

Section Editor: Anna McFarlin, MD

Submission history: Submitted February 2, 2020; Revision received April 23, 2020; Accepted April 30, 2020

Electronically published June 10, 2020

Full text available through open access at http://escholarship.org/uc/uciem_cpem

DOI: 10.5811/cpcem.2020.4.46799

Introduction: Pneumocephalus (PNC) is most commonly associated with trauma or intracranial surgery, less commonly secondary to an infectious source, and is rarely caused by barotrauma.

Case report: A 32-year-old woman presented to the emergency department with complaint of resolved left-sided facial droop and a lingering paresthesia of her left upper extremity after a cross-country flight. Computed tomography demonstrated several foci of air in the subdural space consistent with PNC.

Conclusion: For PNC to occur there must be a persistent negative intracranial pressure gradient, with or without an extracranial pressure change. In this case the pressure change occurred due to cabin pressure. [Clin Pract Cases Emerg Med.2020;4(3):397–399.]

Keywords: *Pneumocephalus; facial droop; Barotrauma.*

INTRODUCTION

Pneumocephalus (PNC) is most commonly associated with trauma or intracranial surgery, less commonly secondary to an infectious source, and is rarely caused by barotrauma.^{1,2} We report a case of spontaneous atraumatic PNC in a previously healthy patient who presented with transient facial droop that had completely resolved by the time of presentation. Symptom onset was during a cross-country flight, making barotrauma from cabin pressure changes the suspected etiology.

CASE REPORT

A 32-year-old woman presented to the emergency department (ED) with complaint of resolved left-sided facial droop and a lingering paresthesia of her left upper extremity. Her medical history was relevant for recurrent otitis media infections; she was otherwise healthy and worked full time. She was not a frequent air traveller, nor did she have a history of scuba diving. Her symptoms began approximately six hours prior to arrival to the ED while she was aboard a flight across the country. She was not coughing, sneezing, or deliberately attempting a Valsalva maneuver when her symptoms started, but as the plane took off she experienced sudden, severe left ear pain and felt left-sided facial as well as left upper extremity numbness. She also felt that

her face was “drooping” and when she checked her reflection, she noticed that she had droop on the entire left side of her face: she could not lift her eyebrow, could not smile or frown, was unable to close her eye and was drooling out of the left side of her mouth. She was given a warm compress for her ear by airplane staff and the symptoms resolved within approximately 30 minutes, although her ear pain remained.

Neither her droop nor her numbness was present by the time the plane landed. Her only lingering complaint was that of a “strange sensation” she could not describe in her left upper extremity. She specifically denied sensations of numbness, weakness or paresthesias after the event. Strength and sensation were fully intact. She presented to the ED with these complaints. On exam in the ED, her initial vital signs were within normal limits, and her neurologic exam was completely normal. Her National Institutes of Health Stroke Scale was zero. Her tympanic membranes were intact bilaterally, with subtle bulging of the left concerning for otitis media without signs of rupture.

Routine laboratory data was unremarkable; however, computed tomography (CT) was notable for small foci of air in the subdural space scattered along the left aspect of the outside of the superior sagittal sinus (Image 1), as well as a focus along the left cerebellar tentorium. There was no

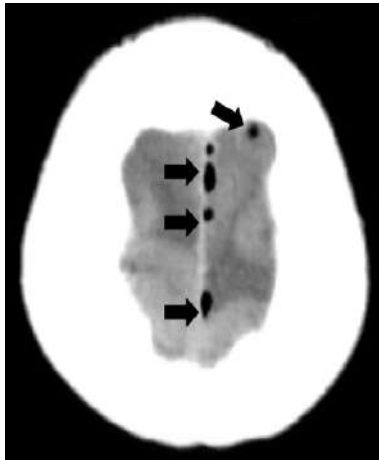


Image 1. Transverse section of a computed tomography brain where foci of air (black arrows) can be seen along the left aspect of the falx cerebri outside of the superior sagittal sinus.

midline shift or mass effect. Also noted was pneumatization of the squamosal portion of both temporal bones, and both petrous apices. A CT internal auditory canals was performed (Image 2). Neurology, neurosurgery, and otolaryngology were consulted for management.

Her transient facial droop was attributed to an air pocket near the facial nerve that would have expanded with cabin pressure change, but had since been reabsorbed and therefore was not captured on imaging at the time of the patient's presentation in the ED. A presumed defect in the dura was discussed by both neurosurgery and otolaryngology, although this defect was not identified on imaging. Otolaryngology recommended placement of a myringotomy tube after discharge from the ED. No acute surgical interventions were indicated as per neurosurgery.

The patient followed up with otolaryngology the following day and had uncomplicated placement of a myringotomy tube with aspiration of a thick mucoid effusion. She reported immediate resolution of her ear pain following placement. She was scheduled to fly back to her hometown and follow up with her local otolaryngology physician, as well as obtain repeat head imaging to confirm resolution of the PNC.

DISCUSSION

This is the first reported case of PNC and facial palsy from altitude barotrauma in emergency medicine (EM) literature. PNC is a rare condition that most commonly occurs as a consequence of trauma or surgical intervention.^{1,2} PNC after air travel has been described in isolated case reports where, again, patients had a history of neurosurgical intervention.^{3,4} Barotrauma as the etiology of spontaneous PNC is very rare and has been described in scuba diving-related pressure changes.⁵ These cases were identified through a literature search using the keywords “pneumocephalus,” “pneumocranium”,

CPC-EM Capsule

What do we already know about this clinical entity?

Atraumatic pneumocephalus (PNC) is associated with surgery or infection. It occurs through a fistula that requires a negative pressure gradient between the extracranial and intracranial spaces.

What makes this presentation of disease reportable?

The mechanism (barotrauma) by which this PNC occurred is extremely rare.

What is the major learning point?

Keep PNC in the differential for patients who present with neurological complaints after air travel.

How might this improve emergency medicine practice?

This case highlights the importance of obtaining a thorough travel history and keeping a broad differential diagnosis for patients with recent travel.

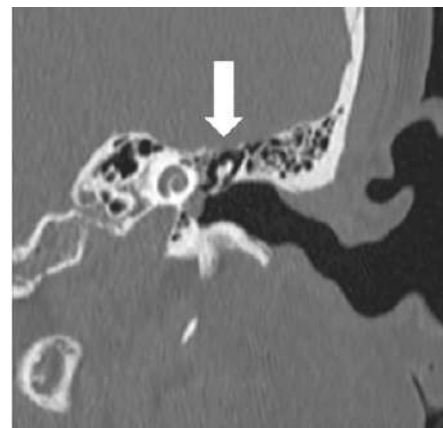


Image 2. Left coronal section of a computed tomography internal auditory canals demonstrating the patient's thinned tegmen tympani (white arrow).

“pneumocephalus,” or “intracranial pneumatocele” in PubMed and Cochrane Library databases, and are all published in neurosurgical literature, as were the vast majority of PNC case reports identified in our search. Thus, a case of spontaneous PNC after air travel in an otherwise

healthy young patient is rare and has not been described in EM literature before.

For PNC to occur there must be a persistent negative intracranial pressure gradient, with or without an extracranial source of positive pressure.⁶

There are two presumed mechanisms as described in neurosurgical literature.⁷ The first mechanism occurs in the setting of low intracranial pressure due to a dural leak or ventricular shunt. In this setting, cerebrospinal fluid is replaced by air. If a fistula exists across the dura to an aerated sinus, air may enter the intracranial space in response to that negative pressure gradient. Postoperative and postprocedure PNC most commonly occurs via this mechanism.

The second mechanism involves “air trapping” in a presumed ball-valve system where two pathologies must be present: a defect in the temporal bone that communicates air from the mastoid cells to the intracranial compartment and a gradient of pressure between the middle ear and the intracranial space. Pressure changes can be both internal (such as Valsalva) and external (ambient pressure). Once the air is inside the intracranial space it increases intracranial pressure again, collapsing or obliterating the fistula after equalization of pressures and trapping it inside as the negative gradient is terminated.

This patient demonstrates the second mechanism described, as the cabin pressure change and presumed temporal bony defect were both present. Cabin pressure decreases rapidly during ascent, causing gases to expand. The air in the patient’s left middle ear expanded in a fixed space, likely finding the path of least resistance internally, via the temporal bone defect and subsequent dural defect, instead of through the thick mucoid effusion and her tympanic membrane, externally. It was then trapped intracranially after the pressure gradient equalized.

The patient’s facial droop was left-sided and peripheral (involved upper and lower facial palsy) as per her description; therefore, this was likely caused by an air pocket near the facial nerve that would have expanded with cabin pressure change, causing ipsilateral symptoms. It is unclear why this resolved with a warm compress; however, heat lends gas particles kinetic energy and so the warmth could have caused the air pocket to dissipate. Her improvement with placement of the myringotomy tube one day later also correlates with this explanation.

CONCLUSION

Given the episodic nature of the facial palsy, the air pocket near the facial nerve was suggested as a likely etiology, but was not captured on imaging since that symptom resolved with the presumed resorption of the air. Unfortunately we

were unable to obtain records from the patient’s follow-up appointments, nor could we obtain follow-up imaging. This case report highlights the importance of keeping barotrauma in the differential diagnosis for patients who present with neurological and otologic complaints after air travel.

The authors attest that their institution requires neither Institutional Review Board approval, nor patient consent for publication of this case report. Documentation on file

Address for Correspondence: Irina Sanjeevan-Cabeza, MD, Thomas Jefferson University Hospital, Department of Emergency Medicine, 1020 Sansom Street, Thompson Building Suite 239, Philadelphia PA 19107. Email: irina.sanjeevan@jefferson.edu.

Conflicts of Interest: By the CPC-EM article submission agreement, all authors are required to disclose all affiliations, funding sources and financial or management relationships that could be perceived as potential sources of bias. The authors disclosed none.

Copyright: © 2020 Sanjeevan-Cabeza et al. This is an open access article distributed in accordance with the terms of the Creative Commons Attribution (CC BY 4.0) License. See: <http://creativecommons.org/licenses/by/4.0/>

REFERENCES

1. Das J and Bajaj J. Pneumocephalus. 2019. Available at: <https://www.ncbi.nlm.nih.gov/books/NBK535412>. Accessed December 17, 2019.
2. Schirmer CM, Heilman CB, Bhardwaj A. Pneumocephalus: Case Illustrations and Review. *Neurocrit Care*. 2010;13:152.
3. Matt BJ and Harold PA. Pneumocephalus After Air Travel. *Neurology*. 2004;63(2):400-1.
4. Huh J. Barotrauma-induced pneumocephalus experienced by a high risk patient after commercial air travel. *J Korean Neurosurg Soc*. 2013;54(2):142-4.
5. Goldmann RW. Pneumocephalus as a consequence of barotrauma. *JAMA*. 1986;255(22):3154-6.
6. Abbati SG and Torino RR. Spontaneous intraparenchymal otogenic pneumocephalus: a case report and review of literature. *Surg Neurol Int*. 2012;3:32.
7. Dowd GC, Molony TB, Voorhies RM. Spontaneous otogenic pneumocephalus. *J Neurosurg*. 1998;89(6):1036-9.

Respiratory Failure Due to a Large Mediastinal Mass in a 4-year-old Female with Blast Cell Crisis: A Case Report

Christian I. Wade, MD*

Cody J. Couperus-Mashewske, MD†

Mia E. Geurts, MD‡

Nicholas Derfler, MD‡

John Ngo, DO§

Kyle S. Couperus, MD‡

*Uniformed Services University of the Health Sciences, School of Medicine, Department of Emergency Medicine, Bethesda, Maryland

†University of Maryland Medical Center, Department of Emergency Medicine, Baltimore, Maryland

‡Madigan Army Medical Center, Department of Emergency Medicine, Tacoma, Washington

§Providence St. Peter Hospital Olympia, Department of Emergency Medicine, Olympia, Washington

Section Editor: Manish Amin, MD

Submission history: Submitted February 19, 2020; Revision received April 27, 2020; Accepted May 5, 2020

Electronically published June 19, 2020

Full text available through open access at http://escholarship.org/uc/uciem_cpccem

DOI: 10.5811/cpccem.2020.5.47016

Introduction: Symptomatic leukostasis is an exceptionally atypical presentation of blast crisis; and when coupled with an enlarged neoplastic mediastinal mass in a four-year-old female, an extremely rare and challenging pediatric emergency arises.

Case Report: We present a unique case of a four-year-old female who arrived via emergency medical services in cardiopulmonary arrest with clinical and radiographic evidence suggestive of bilateral pneumothoraces, prompting bilateral chest tube placement. Further evaluation revealed a large mediastinal mass and a concurrent white blood cell count of 428,400 per milliliter (/mL) (4,400-12,900/mL), with a 96% blast differential, consistent with complications of T-cell acute lymphoblastic leukemia.

Conclusion: This case highlights how pulmonary capillary hypoperfusion secondary to leukostasis, coupled with a ventilation/perfusion mismatch due to compression atelectasis by an enlarged thymus, resulted in this patient's respiratory arrest. Furthermore, the case highlights how mediastinal masses in pediatric patients present potential diagnostic challenges for which ultrasound may prove beneficial. [Clin Pract Cases Emerg Med. 2020;4(3):400–403.]

Keywords: *Blast Cell Crisis; Hyperleukocytosis with Leukostasis; Thymus; Mediastinal Mass; Acute Lymphoblastic Leukemia.*

INTRODUCTION

Acute and chronic leukemia can both present in blast crisis resulting in hyperleukocytosis and leukostasis – an uncommon but life-threatening condition characterized by blood hyperviscosity with reduction of the other cell lines.¹ This condition can lead up to a 40% mortality rate if not rapidly recognized and treated.² Although *symptomatic* leukostasis remains extremely rare, nearly every organ system has the potential to be damaged due to the microvascular aggregates of leukocytes.³ Additionally, approximately 50% of patients with T-cell acute lymphoblastic leukemia were also identified to have a thymic mass.⁴⁻⁶ An extremely rare and

challenging emergency therefore arises when pulmonary capillary hypoperfusion is coupled with compressive atelectasis by a large neoplastic mediastinal mass.

CASE REPORT

Emergency medical services (EMS) were called to the home of a four-year-old female with a history of intermittent asthma and recent outpatient diagnosis of pneumonia after found to be cyanotic, surrounded by emesis, and without apparent respirations. Cardiopulmonary resuscitation was initiated by EMS upon arrival for pulseless electrical activity, and after eight minutes the patient achieved return of spontaneous circulation.

She was subsequently intubated without the need for induction medications and transported to the emergency department (ED). Upon arrival to the ED, an initial physical exam revealed an intubated, unresponsive child with markedly diminished lung sounds bilaterally without wheezing, and an oxygen saturation of 60% on 100% fraction of inspired oxygen (FiO₂). Additionally, respiratory therapy reported extreme difficulty with ventilation. Initial bedside chest radiographs (CXR) (Image) were obtained and showed evidence suggestive of bilateral pneumothoraces, which in conjunction with the patient's clinical picture prompted bilateral chest tube placement. Both returned large volumes of serous fluid, although no blood or air.

Continuation of the primary survey revealed tachycardia at 132 beats per minute with strong and regular peripheral pulses in all extremities. There was no jugular venous distention. The abdomen was soft without masses. A limited neurologic exam revealed bilateral sluggish pupils, with the right pupil at 6 millimeters (mm) and the left pupil at 3 mm. There were no obvious signs of trauma, and no dermatologic findings.

After initial stabilization, collateral history was obtained from the mother who stated the patient had been feeling tired with intermittent fevers over the prior few days, which led to a diagnosis of mild viral pneumonia by her outpatient pediatrician. Per her electronic health record, this was based on the patient's age, gradual onset of symptoms with non-toxic appearance, and non-focal pulmonary findings on auscultation. Imaging and medications were therefore deferred, but return precautions were given should the patient's clinical presentation worsen. With regard to her asthma, the patient had only occasionally used an inhaler for night-time coughing but

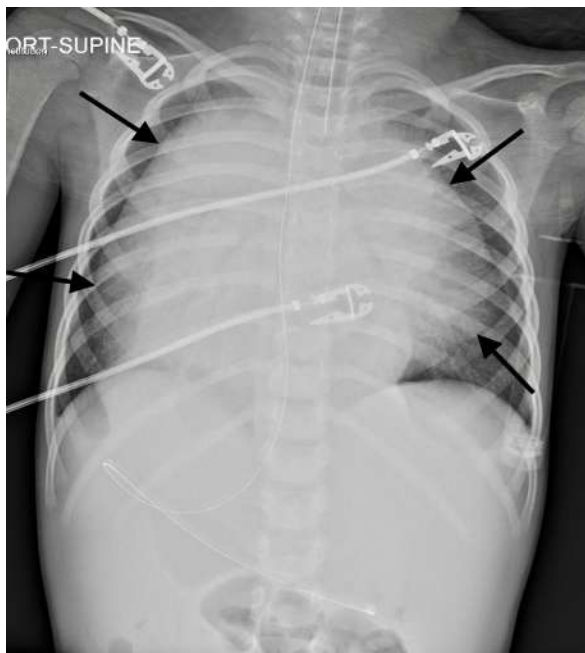


Image. Supine portable frontal chest radiograph with arrows pointing to what resembles bilateral pneumothoraces.

CPC-EM Capsule

What do we already know about this clinical entity?
Acute and chronic leukemia can both present in blast crisis resulting in hyperleukocytosis and leukostasis – an uncommon but life-threatening condition carrying a mortality rate as high as 40%.

What makes this presentation of disease reportable?
Symptomatic leukostasis, coupled with the presence of a large neoplastic mediastinal mass, is an exceptionally atypical, but potentially deadly, presentation of T-cell acute lymphoblastic leukemia (T-ALL).

What is the major learning point?
Pulmonary capillary hypoperfusion secondary to leukostasis, coupled with a ventilation/perfusion mismatch due to compression atelectasis by an enlarged thymus, led to this patient's respiratory arrest.

How might this improve emergency medicine practice?
In addition to reporting an extremely rare presentation of T-ALL, this case highlights how mediastinal masses present potential diagnostic challenges for which ultrasound may prove beneficial.

otherwise had never been admitted, intubated, or prescribed oral steroids. She additionally denied any other known medical conditions, surgical history, allergies, or red flags to suggest the potential for non-accidental trauma.

Shortly thereafter, initial laboratory values resulted in a white blood cell count of 428,000 per milliliter (/mL) (4,400-12,900/mL) with a 96% blast differential, hemoglobin of 6.7 grams per deciliter (g/dL) (11.4-14.3 g/dL), and platelet count of 27,000/mL (187,000-445,000/mL). An electrolyte panel was significant for a sodium of 131 milliequivalents per liter (mEq/L) (135-145 mEq/L), potassium of 8.7 mEq/L (3.6-5.2 mEq/L), chloride of 102 mEq/L (102-112 mEq/L), bicarbonate of 10 mEq/L (19-26 mEq/L), blood urea nitrogen of 16 milligram per deciliter (mg/dL) (7-20 mg/dL), creatinine of 0.61 mg/dL (0.19-0.49 mg/dL), and a glucose of 461 mg/dL (70-140 mg/dL). An arterial blood gas resulted in a pH of 6.75 (7.35-7.45), PaCO₂ of 60.6 mmHg (35-45 mmHg), PaO₂ of 59.7 millimeters of mercury (mm Hg) (75-100 mm Hg), lactate of 12.14 mEq/L (0.2-1.8 mEq/L), HCO₃ of 8.3 mEq/L (19-26 mEq/L), with the FiO₂ at 100%. An alveolar-arterial gradient was calculated to be in excess of 577 mmHg (estimated normal gradient for the age of this patient is 5 mmHg).

Non-contrasted computed tomography (CT) of the head showed no evidence of intracranial abnormalities. Following the patient's stabilization, the official read of the bedside CXR by pediatric radiology instead revealed a large mediastinal mass, manifesting features similar to that of bilateral pneumothoraces. Due to the patient's age and concern for radiation, the patient did not receive CT of the chest as part of her initial workup. The patient was subsequently admitted for hyperleukocytosis with leukostasis and, in conjunction with hematology oncology, was started on leukapheresis and, later, induction chemotherapy. Over the course of the week, the patient's clinical status continued to improve, and she was extubated and discharged home with a diagnosis of T-cell acute lymphoblastic leukemia.

DISCUSSION

Given the patient's respiratory status and what appeared to be evidence suggestive of bilateral pneumothoraces on the initial bedside CXR, bilateral chest tubes were placed. However, the official read by pediatric radiology later found the patient to have a large thymus that had features resembling what appeared to be bilateral pneumothoraces. A thymic mass is identified in 50% of patients with T-cell acute lymphoblastic leukemia, and can lead to airway obstruction.^{4,6} In our patient's case, and as evidenced by an extremely elevated alveolar-arterial gradient of 577 mm Hg, her mediastinal mass likely caused compression atelectasis leading to a ventilation/perfusion mismatch, which manifested as hypoxia and respiratory distress. The mass also likely contributed to the extreme difficulty in ventilating the patient and the need for high pressures.

The thymus, proportionally the largest at birth and rather difficult to see on chest radiography by age three, lies in the anterior superior mediastinum and begins the process of involution during puberty.⁷ It normally conforms to the surrounding structures without compression or displacement; however, diffuse infiltration can cause rigidity with subsequent compression of surrounding structures.⁸ Radiologic findings consistent with a normal thymus include the following: undulating or wavy lateral margins caused by impression of overlying ribs ("wave sign"); a triangular and slightly convex right lobe due to abutting minor fissure ("sail sign"); and inspiratory and expiratory respiratory variation.⁷ Ultrasound can be particularly useful in rapidly identifying a normal vs pathologic thymus.⁹ Specifically, it should appear as a homogeneous soft tissue with finely granular echotexture and some echogenic stranding.¹⁰ Ultrasound can also be useful to identify ectopic thymic tissue, evaluate for focal lesions, and to differentiate from pulmonary pathology – such as verifying the presence or absence of lung sliding to rule out pneumothoraces.

Although hyperleukocytosis with leukostasis can present in a number of ways, the most common presentation is neurologic dysfunction characterized by headache, vision changes, ataxia, cranial nerve palsy, confusion, somnolence, or even coma.^{3,11} Emergency management of leukostasis should focus on patient stabilization, respiratory support, aggressive intravenous fluid

resuscitation, prevention and treatment of disseminated intravascular coagulation, and treatment of tumor lysis syndrome should it arise. Extreme caution should be taken to avoid treatments that may increase blood viscosity, such as diuresis or red blood cell transfusions. Therapeutic leukapheresis may be indicated for patients with symptomatic hyperleukocytosis (a Grade 1B recommendation per the American Society for Apheresis), or when induction chemotherapy requires postponement. High rates of mortality are also associated with the treatment of hyperleukocytosis, and therefore immediate consultation with hematology oncology should be placed.^{2,3,11-13}

CONCLUSION

This case highlights the treatment of a relatively rare symptomatic hyperleukocytosis presenting with a large thymus causing mass effect and ultimately respiratory failure. We also identified potential diagnostic challenges associated with pediatric mediastinal masses, and how on review, point-of-care ultrasound may have proven more beneficial in our diagnostic approach. Specific ultrasound findings clinicians can use to identify the thymus include a homogeneous soft tissue with finely granular echotexture and echogenic stranding, and the evidence of pliability, i.e., an undulating lateral border and a triangular and slightly convex right lobe. Moreover, evidence of lung sliding can help differentiate between thymic pathology and potential pulmonary pathology such as pneumothoraces.

The authors attest that their institution requires neither Institutional Review Board approval, nor patient consent for publication of this case report. Documentation on file.

Address for Correspondence: Christian I. Wade, MD, F. Edward Hébert School of Medicine, Uniformed Services University of the Health Sciences, Department of Emergency Medicine, 4301 Jones Bridge Road, Bethesda, MD 20814. Email: christian.i.wade.mil@mail.mil.

Conflicts of Interest: By the CPC-EM article submission agreement, all authors are required to disclose all affiliations, funding sources and financial or management relationships that could be perceived as potential sources of bias. The view(s) expressed herein are those of the author(s) and do not reflect the official policy or position of Madigan Army Medical Center, the U.S. Army Medical Department, the U.S. Army Office of the Surgeon General, the Department of the Army, Department of Defense, the Uniformed Services University of the Health Sciences or any other agency of the U.S. Government. The investigators have adhered to the policies for the protection of human subjects as prescribed in 45 CFR 46. The authors disclosed no conflicts of interest.

Copyright: © 2020 Wade et al. This is an open access article distributed in accordance with the terms of the Creative Commons Attribution (CC BY 4.0) License. See: <http://creativecommons.org/licenses/by/4.0/>

REFERENCES

1. Morris CM. Blast crisis. *Encyclopedia of Cancer*. 2017;432-3.
2. Giammarco S. Hyperleukocytosis **and** leukostasis: management of a medical emergency. *Exp Rev Hematol*. 2017;10(2):147-54.
3. Ali AM, Mirrakhimov AE, Abboud CN, et al. Leukostasis in adult acute hyperleukocytic leukemia: a clinician's digest. *Hematol Oncol*. 2016;34:69-78.
4. Manchanda S, Bhalla AS, Jana M, et al. Imaging of the pediatric thymus: clinico-radiologic approach. *World J Clin Pediatr*. 2017;6(1):10-23.
5. Gupta R and Butler RH. Shortness of breath in an infant with history of acute lymphoblastic leukemia. *J Emerg Med*. 2005;28(1):79-81.
6. Heinz P and Dunne J. Wheeze and mediastinal mass: a challenging patient. *Emerg Med Australas*. 2004;16(3):241-3.
7. Francis IR, Glazer GM, Bookstein FL, et al. The thymus: reexamination of age-related changes in size and shape. *Am J Roentgenol*. 1985;145(2):249-54.
8. Nasser F and Eftekhari F. Clinical and radiologic review of the normal and abnormal thymus: pearls and pitfalls. *Radiographics*. 2010;30(2):413-28.
9. Gravel CA and Bachur RG. Point-of-care ultrasound differentiation of lung consolidation and normal thymus in pediatric patients: an educational case series. *J Emerg Med*. 2018;55:235-9.
10. Newman B. Ultrasound body applications in children. *Ped Rad*. 2011;41(2):555.
11. Porcu P, Farag S, Marcucci G, et al. Leukocytoreduction for acute leukemia. *Ther Apher*. 2002;6:15-23.
12. Stapczynski JS and Tintinalli JE. *Tintinalli's Emergency Medicine: A Comprehensive Study Guide*. 2016.
13. Shiber JR and Fines RE. Cerebral hemorrhage due to hyperleukocytosis. *J Emerg Med*. 2011;40(6):674-7.

Point-of-care Ultrasound Identification of Iliopsoas Abscess in Emergency Department: A Case Report

Nehal A. Al-Sadhan, MD*
Otto Liebmann, MD†
Kristin H. Dwyer, MD, MPH†

*King Fahad Medical City, Department of Emergency Medicine, Riyadh, Saudi Arabia
†Warren Alpert Medical School of Brown University, Department of Emergency Medicine, Division of Emergency Ultrasound, Providence, Rhode Island

Section Editor: Shadi Lahham, MD

Submission history: Submitted September 17, 2019; Revision received April 28, 2020; Accepted May 5, 2020

Electronically published July 20, 2020

Full text available through open access at http://escholarship.org/uc/uciem_cpccem

DOI: 10.5811/cpcem.2020.5.45255

Introduction: The iliopsoas muscle is a rare place for an abscess to collect. While these abscesses can have high mortality, they are often misdiagnosed. The use of point-of-care ultrasound (POCUS) can aid in earlier diagnosis.

Case Report: A 45-year-old male presented to the emergency department (ED) with severe lower back pain. The pain radiated to both of his legs and was associated with fever, weight loss, and malaise. The differential diagnosis for this patient was broad. A POCUS was performed at the bedside and revealed bilateral iliopsoas abscesses. This finding was then confirmed by computed tomography.

Conclusion: In this case report we will discuss how to identify an iliopsoas abscess using POCUS in ED patients, and the utility of POCUS to facilitate an expedited diagnosis. [Clin Pract Cases Emerg Med. 2020;4(3):404–406.]

Keywords: *abdominal pain; flank pain; psoas abscess; ultrasound; bedside ultrasound; POCUS.*

INTRODUCTION

The iliopsoas muscle is located in the retroperitoneal space arising from the thoracic and lumbar vertebrae and it serves as the flexor muscle for the hip.² It is rare for an abscess to collect in this space; however, males and younger individuals are more commonly affected.² Iliopsoas abscesses are categorized as either primary (idiopathic) or secondary to direct spread from nearby structures.³ These abscesses are most commonly caused by hematogenous spread of *Staphylococcus aureus*. Patients with Crohn's disease, acquired immunodeficiency syndrome, diabetes, immunosuppression, or intravenous drug abuse (IVDA) are at increased risk.² The mortality associated with iliopsoas abscesses is higher for those resulting from hematogenous spread (19%) than those that are categorized as primary (<5%).³ Patients are frequently misdiagnosed as they present with nonspecific symptoms and the diagnosis may not even be considered in the differential.^{2,3} The classic triad is back pain, fever, and a limp; however, many patients don't exhibit the

complete triad. Incorporating ultrasound at the bedside may aid in a more rapid diagnosis, enabling earlier treatment and potentially a decrease in mortality.⁴

CASE REPORT

A 45-year-old, ill-appearing male with no past medical or surgical history presented to the emergency department (ED) with a chief complaint of atraumatic low back pain that radiated down both of his legs. The pain started two weeks earlier and was associated with fevers and chills. Additional symptoms included difficulty with ambulation, generalized weakness, malaise, and 30 pound weight loss over several months. He denied any history of bowel or bladder incontinence, sensory deficits, or weakness. The patient denied IVDA or recent travel. On physical exam, he appeared pale and cachectic. He was febrile at 39.8° Celsius and his heart rate was 139 beats per minute. His other vital signs were normal. He had bilateral lower-back tenderness, but no bony midline pain. The skin over his back was normal appearing,

with no redness, rash, or evidence of trauma. His neurological examination was within normal limits.

Initial laboratory investigations revealed an elevated white blood cell count of 30,800 cells per cubic millimeter ($3.5-11.00 \times 10^9/L$), with 22% bands. In addition, he had a platelet count of 714×10^9 per liter ($/L$) ($150-400 \times 10^9/L$), C-reactive protein of 461.36 milligrams per liter (mg/L) (RR 0-8 mg/L), and an erythrocyte sedimentation rate of 130 millimeters per hour (mm/h) (0-30mm/hr). Blood cultures sent from the ED were negative for growth at five days. Urine analysis revealed pyuria, and was positive for nitrites and leukocyte esterase, but with a negative culture. The emergency physician performed a point-of-care ultrasound (POCUS) with a curvilinear probe (2-5 megahertz) to evaluate for hydronephrosis, given the fever and back pain. While no hydronephrosis was seen, an abnormal collection of mixed echogenicity was visualized posterior to the kidney within the iliopsoas muscle (Images 1 and 2). The patient had a computed tomography (CT) that confirmed bilateral iliopsoas abscesses (Image 3) and, in addition, identified a pulmonary abscess. IV antibiotics were initiated in the ED, and the patient was admitted to the hospital.

DISCUSSION

Iliopsoas abscesses were first described as psittacosis in 1881 and were defined as “a collection of pus in the iliopsoas compartment.”⁵ The majority of clinical exam findings and laboratory tests are not specific for the iliopsoas abscess diagnosis. Importantly, mortality reaches 100% in untreated patients, making it an important condition to recognize and treat early.¹ To assess for iliopsoas abscess on ultrasound, a curvilinear or phase array probe should be placed in the midaxillary line at the level of the xiphoid with the marker pointing to the patient’s head. Consider rotating the probe slightly oblique, parallel to the ribs, to decrease interference from rib shadow. The iliopsoas muscle will be seen as a striated structure between

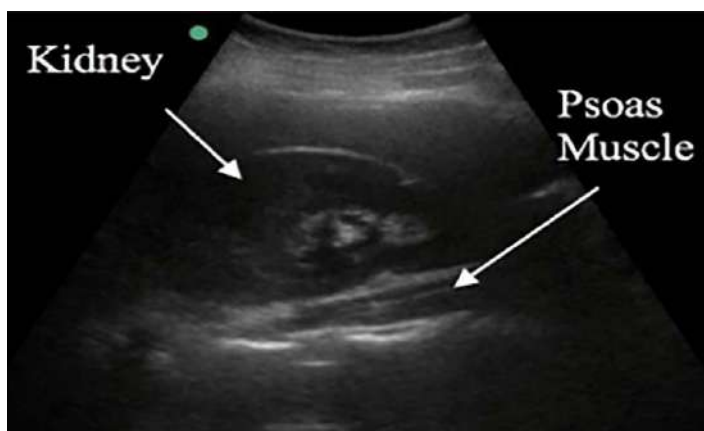


Image 1. Normal right upper quadrant sonoanatomy with the psoas muscle visible posterior to the kidney.

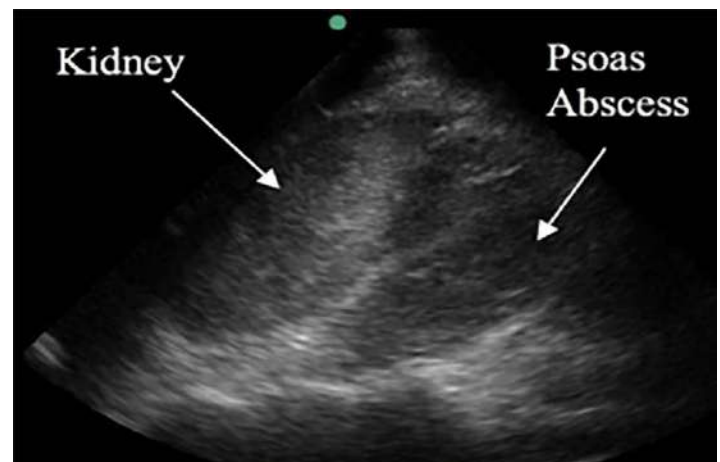


Image 2. Right upper quadrant ultrasound demonstrating heterogenous mass within the psoas musculature.

CPC-EM Capsule

What do we already know about this clinical entity?

Patients with iliopsoas abscesses are frequently misdiagnosed as they present with nonspecific symptoms. The classic triad is back pain, fever, and a limp; however, many patients don't exhibit the complete triad.

What makes this presentation of disease reportable?

Mortality of untreated iliopsoas abscesses is very high, making it an important condition to recognize and treat early. In this case, we were able to rapidly diagnose an iliopsoas abscess utilizing point-of-care ultrasound (POCUS), and confirm by computed tomography.

What is the major learning point?

Incorporating POCUS may aid in a more rapid diagnosis of iliopsoas abscesses, enabling earlier treatment and potentially a decrease in mortality.

How might this improve emergency medicine practice?

POCUS may be able to aid in earlier identification of this dangerous condition, which could limit the delay in diagnosis and management of these patients.

the kidney and the vertebral column.⁶ In this case report, a large heterogenous mass was visualized with loss of the normal muscle striation.

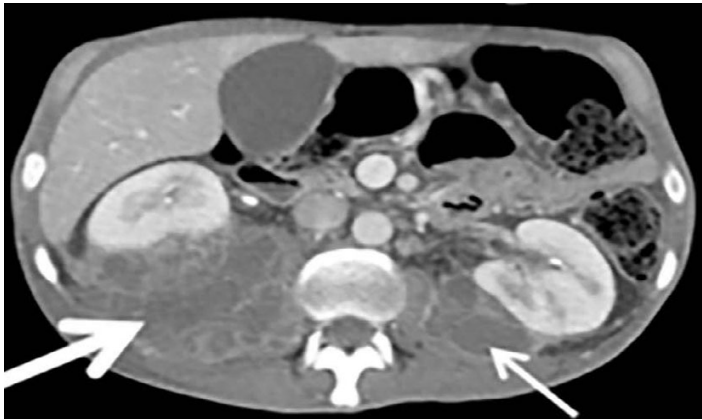


Image 3. Computed tomography with intravenous contrast demonstrates bilateral psoas abscesses. The right-sided abscess is much larger as indicated by the thicker arrow.

It can be difficult to differentiate hematoma from abscess or other masses on ultrasound. However, if there is an abnormal collection identified on ultrasound within the psoas in the setting of fever, back pain, and limp, clinical suspicion for an abscess should be high. Currently, CT remains the definitive diagnostic and is considered the “gold standard” for diagnosis.

CONCLUSION

The diagnosis of iliopsoas abscess is often delayed because of the non-specific presentation. For immunocompromised, febrile patients with back pain, maintain a high level of clinical suspicion. Those with Crohn’s disease are at particularly high risk. POCUS may be able to aid in earlier identification of this dangerous condition, which could limit the delay in diagnosis and management of these patients. Infected kidney stone will be on the differential diagnosis for many of these patients, so clinicians should be interrogating the kidney at the bedside already with POCUS.

The authors attest that their institution requires neither Institutional Review Board approval, nor patient consent for publication of this case report. Documentation on file.

Address for Correspondence: Nehal A. Al-Sadhan, MD, King Fahad Medical City, Department of Emergency Medicine, P.O. Box 59046, Riyadh 11525, Kingdom of Saudi Arabia. Email: nalsadhan@kfmc.med.sa.

Conflicts of Interest: By the CPC-EM article submission agreement, all authors are required to disclose all affiliations, funding sources and financial or management relationships that could be perceived as potential sources of bias. The authors disclosed none.

Copyright: © 2020 Al-Sadhan et al. This is an open access article distributed in accordance with the terms of the Creative Commons Attribution (CC BY 4.0) License. See: <http://creativecommons.org/licenses/by/4.0/>

REFERENCES

1. Ricci MA, Rose FB, Meyer KK. Pyogenic psoas abscess: worldwide variations in etiology. *World J Surg.* 1986;10(5):834-43.
2. Mallick IH, Thoufeeq MH, Rajendran TP. Iliopsoas abscesses. *Postgrad Med J.* 2004;80(946):459-62.
3. Qureshi NH, O'Brien DP, Allcutt DA. Psoas abscess secondary to discitis: a case report of conservative management. *J Spinal Disorder.* 2000;13(1):73-6.
4. Deanehan JK. Point-of-care ultrasound identification of psoas abscess in a child presenting with hip pain. *Pediatr Emerg Care.* 2017;33(6):437-9.
5. Mynter H. Acute psoitis. *Buffalo Med Surg J.* 1881;21:202-10.
6. King AD, Hine AI, McDonald C, et al. The ultrasound appearance of normal psoas muscle. *Clin Radiol.* 1993;48(5):316-8.

A Case Report: Point-of-care Ultrasound in the Diagnosis of Post-Myocardial Infarction Ventricular Septal Rupture

Andrew J. Portuguese, MD*
Khaled H. Abdulla, MD*
Michael Vornovitsky, MD†
John DeAngelis, MD‡

*University of Rochester Medical Center, Department of Medicine, Rochester, New York
†University of Rochester Medical Center, Department of Cardiology, Rochester, New York
‡University of Rochester Medical Center, Department of Emergency Medicine, Rochester, New York

Section Editor: Scott Goldstein, MD

Submission history: Submitted February 25, 2020; Revision received April 21, 2020; Accepted April 24, 2020

Electronically published June 15, 2020

Full text available through open access at http://escholarship.org/uc/uciem_cpem

DOI: 10.5811/cpcem.2020.4.47073

Introduction: Ventricular septal rupture (VSR) is a rare complication of ST-elevation myocardial infarction (STEMI), typically discovered post-revascularization.

Case report: We present the first case of VSR detected on point-of-care ultrasound (POCUS) in the emergency department immediately prior to emergent angiography, with management positively affected by this discovery. The VSR was quickly confirmed via right heart catheterization. Subsequently, hemodynamic stability was achieved using an intra-aortic balloon pump. A delayed surgical VSR repair, with concomitant coronary artery bypass grafting, was implemented for definitive management.

Conclusion: This case highlights the utility of POCUS in a STEMI patient with a suspected mechanical complication. [Clin Pract Cases Emerg Med. 2020;4(3):407–410.]

Keywords: *Coronary artery disease; mechanical circulatory support; ST-elevation myocardial infarction; ventricular septal rupture.*

INTRODUCTION

Ventricular septal rupture (VSR) is a serious complication of ST-elevation myocardial infarction (STEMI) associated with extremely high mortality. Development of VSR is thought to be mediated by the complete occlusion of a major vessel in the absence of spontaneous reperfusion or collateral circulation. In this regard, VSR is less likely to occur in a patient with a history of symptomatic coronary artery disease (CAD).¹ Risk factors shown to be independently associated with development of VSR include advanced age, female gender, and chronic kidney disease. Paradoxically, hypertension and diabetes mellitus appear to confer protection, possibly via concentric myocardial hypertrophy and increased collateral circulation, respectively.²

Diagnosis of VSR generally occurs within the first week post-MI, typically presenting as a clinical decompensation

in patients who received timely revascularization. Whereas the median time from symptom onset to diagnosis is approximately five days, earlier occurrence (\leq two days) has been associated with thrombolytic utilization. In roughly 50% of cases, VSR occurs with total occlusion of the infarct-related artery. Anterior and inferior-posterior infarcts occur with roughly equal frequency. Hemodynamic instability often accompanies VSR. Cardiogenic shock is present in 39% of cases, and cardiac arrest occurs in 6.1% of cases.² Current European Society of Cardiology guidelines recommend immediate echocardiographic assessment when mechanical complications are suspected.³ In many cases, particularly in the emergency department (ED) setting, point-of-care ultrasound (POCUS) may be the most rapidly available test to establish this diagnosis.

CASE REPORT

A 61-year-old man with a history of long-term cigarette smoking (45 pack-years) presented to the ED with acute dyspnea and one week of chest pain. Initial vital signs were as follows: temperature 36°C, heart rate 97 beats per minute, blood pressure 176/100 millimeters of mercury, respiratory rate 30 breaths per minute, and oxygen saturation (SpO₂) 89%. He required four liters per minute supplemental oxygen to maintain SpO₂ greater than 94%. An electrocardiogram revealed Q waves and ST-segment elevations in leads II, III, and aVF with reciprocal depressions in leads I, aVL, and V₂-V₅ (Image, Panel A), consistent with subacute inferior STEMI. His exam was notable for a harsh holosystolic murmur heard throughout the precordium. The patient's preliminary laboratory results revealed a lactic acidosis with arterial lactate of 9.2 millimoles per liter (mmol/L) (normal range 0.5-2.2 mmol/L), and a leukocytosis with a white blood cell count of 19.8 x 10⁹/L (normal range 4.2-9.1 x 10⁹/L). His high sensitivity troponin T was 5853 nanograms (ng)/L (normal range 0-21 ng/L).

On POCUS in the ED, parasternal long- (Image, Panel B) and short-axis (Image, Panel C) views revealed a large VSR, and a modified apical four-chamber view (Video) with color flow Doppler confirmed left-to-right flow across the defect (Image, Panel D and Video). Emergent coronary angiography demonstrated a chronically occluded proximal right coronary artery and an 80% proximal- to mid-left circumflex stenotic

CPC-EM Capsule

What do we already know about this clinical entity?

Ventricular septal rupture (VSR) is a devastating ST-elevation myocardial infarction (STEMI) complication that requires prompt diagnosis and management.

What makes this presentation of disease reportable?

Early discovery of a post-STEMI VSR on point-of-care ultrasound (POCUS) allowed for optimal management and led to a positive outcome.

What is the major learning point?

Immediate echocardiographic assessment should be performed whenever post-STEMI mechanical complications are suspected.

How might this improve emergency medicine practice?

Rapid screening of the unstable STEMI patient using POCUS can help diagnose VSR and facilitate appropriate management.

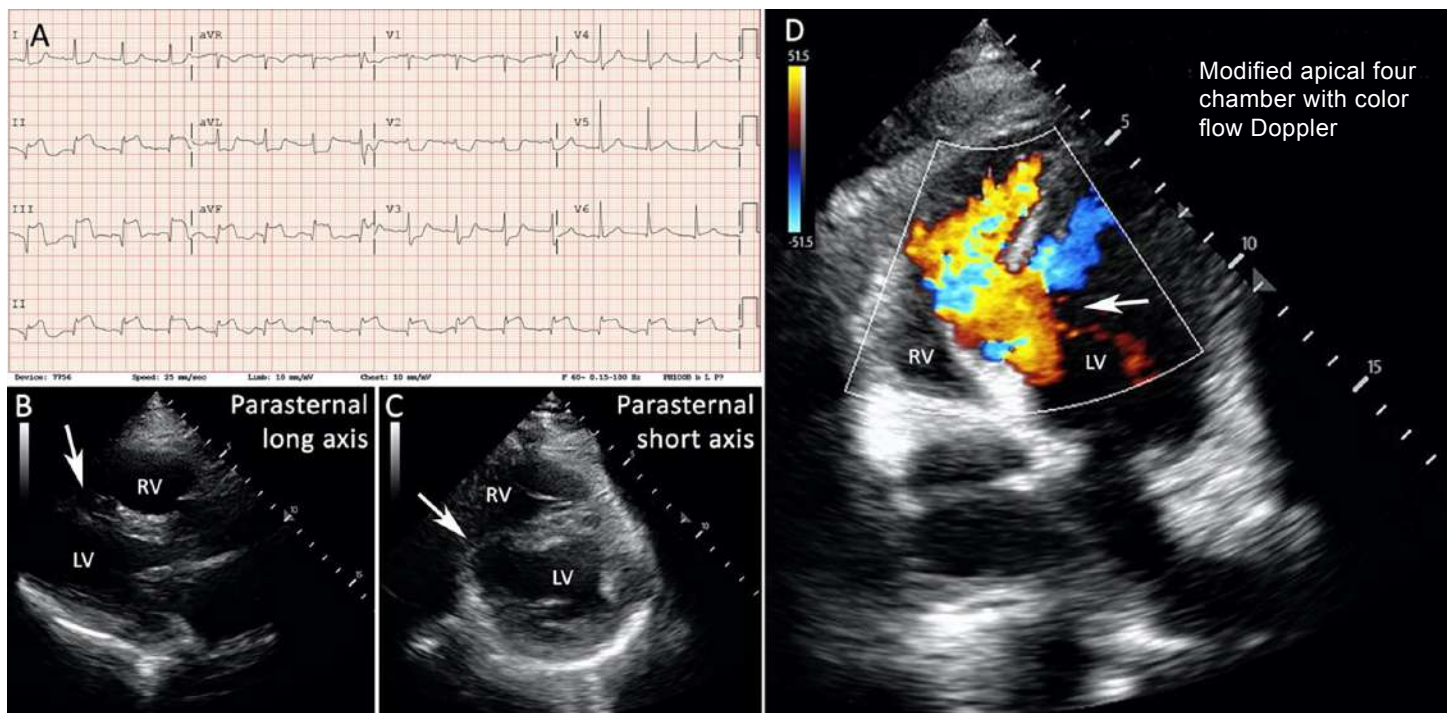


Image. Initial emergency department diagnostics: A) The initial electrocardiogram demonstrates a subacute inferior ST-elevation myocardial infarction; B) Parasternal long; and C) short-axis views reveal an interventricular septal defect; D) A modified apical four-chamber view with color flow Doppler demonstrates a left-to-right shunt across the defect. Arrows point to the interventricular septal defect. LV, left ventricle; RV, right ventricle.

lesion; no stents were placed. The cardiac index was 1.0 L/minute (min)/squared meter (m²) (normal range 2.5-4.2 L/min/m²) and the pulmonary-to-systemic flow ratio (Q_p:Q_s) was 7.8 (normal ratio of 1), consistent with an extremely large left-to-right intraventricular shunt. Oxygen saturation measurements collected during right heart catheterization (RHC) are shown in the table.

The coronary artery stenotic lesions were not amenable to stenting. Hemodynamic stabilization was achieved with placement of an intra-aortic balloon pump (IABP). On hospital day 10, single vessel coronary artery bypass grafting (CABG) and VSR repair were completed successfully. The IABP was removed the following day. Post-op transthoracic echocardiography (TTE) demonstrated moderately reduced left ventricular ejection fraction (30-39%; calculated at 35%; normal range 55-70%) and trivial left-to-right shunting. His post-op course was uncomplicated, and the patient was discharged home on hospital day 15.

At two-week post-discharge follow-up with his new cardiologist, the patient endorsed improving exertional fatigue and was otherwise asymptomatic. His recovery had been uneventful. He remained abstinent from cigarette smoking.

One month after discharge, repeat TTE and RHC were completed to rule out significant left-to-right shunting. TTE demonstrated an improvement in left ventricular ejection fraction, now only mildly reduced (40-49%; calculated at 44%), and a borderline increase in left-to-right shunting. RHC showed a mild step-up in oxygen saturation from the mixed venous to the right ventricle (53 to 65%, respectively), with a calculated Q_p:Q_s of 1.4, and cardiac index of 2.3 L/min/m² (Table).

DISCUSSION

Mechanical complications of STEMI are life-threatening and necessitate prompt diagnosis and management. Concerning findings (e.g., acute hypotension, recurrence of chest pain, a new cardiac murmur, pulmonary vascular congestion, or jugular vein distension) should raise suspicion and trigger immediate echocardiographic assessment.³ In the ED, POCUS shows promise as a rapid and easily accessible screening tool in the diagnosis of VSR, as well as other mechanical complications (e.g., RV wall rupture and aortic dissection).^{4,6} Key sonographic findings of VSR include direct visualization of the defect, blood flow across the interventricular septum, and RV dilation.⁷ Since the defect may not be visible in standard imaging planes, it is necessary to sweep through the interventricular

septum and obtain non-standard windows.⁵ Although standard echocardiographic evaluation is highly sensitive (90%) and specific (98%) for the diagnosis of VSR,⁸ the test characteristics of POCUS are unknown, and likely depend on the size and position of the VSR and the ultrasound operator's proficiency.

Correcting the VSR is essential, with surgical repair representing the gold standard approach. In medically treated patients, the prognosis is grave, with in-hospital mortality ranging from 94-100%.^{9,11} Although critical, the optimal timing of VSR repair is not clearly defined. In the immediate period, the fragile necrotic myocardium represents a problematic, technically challenging surgical substrate. Surgical delay is associated with improved 30-day and long-term survival, with an inverse relationship between 30-day mortality and time from diagnosis to repair.¹² Furthermore, patients who undergo early surgical repair (≤2 days after diagnosis) have markedly worse outcomes compared to those who undergo delayed surgery (>2 days after diagnosis; one-year survival rate 38% vs 64%, p <0.05).¹⁰ Unfortunately, delay of surgery is often limited by hemodynamic instability.^{10,13}

The advent and wide availability of mechanical circulatory support (MCS) devices has dramatically altered VSR management. The hemodynamic stabilization afforded by MCS allows for recovery of end-organ injury and serves as a bridge to definitive repair. Current MCS options include IABP, left ventricular assist devices (eg, Impella and TandemHeart), and extracorporeal membrane oxygenation. Currently, European Society of Cardiology and American College of Cardiology Foundation/American Heart Association guidelines suggest using IABP as a stabilizing measure.^{3,14} However, there is a paucity of clinical evidence demonstrating the superiority of any one approach. A recent publication by Pahuja et al examined the hemodynamic effects of the above MCS devices in VSR using a computer simulation model. In this model, although no percutaneous MCS completely normalized hemodynamics, pulmonary capillary wedge pressure and left-to-right shunting were worsened by extracorporeal membrane oxygenation and most improved by Impella.¹³

It is uncertain whether revascularization with concomitant CABG at the time of VSR repair improves outcomes. Some studies fail to demonstrate a benefit, instead finding an association between the number of anastomoses and worse mid- to long-term outcomes.⁷ However, it is plausible that the indication for CABG, namely extensive CAD, is the poor prognostic factor rather

Table. Initial and follow-up right heart catheterization results. Oxygen saturations were measured in the superior vena cava (SVC), high right atrium (hRA), middle right atrium (mRA), low right atrium (IRA), inferior vena cava (IVC), right ventricle (RV), main pulmonary artery (MPA), and arterial blood (SaO₂). The calculated Q_p:Q_s and cardiac index (CI) are listed.

RHC\Chamber	SVC	hRA	mRA	IRA	IVC	RV	MPA	SaO ₂	Qp:Qs	CI (L/min/m ²)
Initial	31%	39%		39%	13%	86%	88%	97%	7.8	1.0
Follow-up	50%		66%		62%	65%	65%	97%	1.4	2.3

RHC, right heart catheterization; Q_p:Q_s, pulmonary-to-systemic flow ratio; L, liters; min, minute; m², squared meter.

than CABG itself. By controlling for the severity of CAD using carefully matched cohorts, concomitant CABG at the time of VSR repair has been shown to be associated with improved long-term survival.¹⁵ This result lends support to the hypothesis that late revascularization is beneficial in this population.

CONCLUSION

VSR is a rare but devastating complication that typically occurs three to five days post-myocardial infarction and requires definitive surgical repair. When a post-STEMI VSR or other mechanical complication is suspected, immediate echocardiographic assessment should be performed. Our case highlights that this can be accomplished using POCUS. Immediate VSR repair carries a high mortality risk due to the fragility of necrotic tissue. When feasible, a delayed approach enables a more durable repair of scarred tissues, markedly improving outcomes. Performing concomitant CABG at the time of VSR repair is controversial but may improve long-term survival.

Video. Modified apical four-chamber view on point-of-care ultrasound. The ventricular septal rupture is directly visualized by sweeping the imaging plane through the interventricular septum. Color flow Doppler demonstrates left-to-right blood flow across the defect.

The authors attest that their institution requires neither Institutional Review Board approval, nor patient consent for publication of this case report. Documentation on file.

Address for Correspondence: Andrew J. Portuguese, MD, University of Rochester Medical Center, Department of Medicine, 601 Elmwood Ave., Box MED, Rochester, NY 14642. Email: aportugu@gmail.com.

Conflicts of Interest: By the CPC-EM article submission agreement, all authors are required to disclose all affiliations, funding sources and financial or management relationships that could be perceived as potential sources of bias. The authors disclosed none.

Copyright: © 2020 Portuguese et al. This is an open access article distributed in accordance with the terms of the Creative Commons Attribution (CC BY 4.0) License. See: <http://creativecommons.org/licenses/by/4.0/>

REFERENCES

- Pohjola-Sintonen S, Muller JE, Stone PH, et al. Ventricular septal and free wall rupture complicating acute myocardial infarction: experience in the Multicenter Investigation of Limitation of Infarct Size. *Am Heart J*. 1989;117(4):809-18.
- Moreyra AE, Huang MS, Wilson AC, et al. Trends in incidence and mortality rates of ventricular septal rupture during acute myocardial infarction. *Am J Cardiol*. 2010;106(8):1095-100.
- Ibanez B, James S, Agewall S, et al. 2017 ESC Guidelines for the management of acute myocardial infarction in patients presenting with ST-segment elevation: The Task Force for the Management of Acute Myocardial Infarction in Patients Presenting with ST-segment Elevation of the European Society of Cardiology (ESC). *Eur Heart J*. 2018;39(2):119-77.
- Chenkin J. Diagnosis of aortic dissection presenting as ST-elevation myocardial infarction using point-Of-care ultrasound. *J Emerg Med*. 2017;53(6):880-4.
- Mukherjee A and Fong J. Heartbreak: a case of post-infarction cardiogenic shock. *Australian Journal of Ultrasound in Medicine*. 2019;22(1):66-71.
- Miller J, Swarbrick L, Abdelhameed B, et al. Point-of-care ultrasound diagnosis of right ventricular rupture post cardiac arrest after thrombolysis in myocardial infarction. *Clin Pract Cases Emerg Med*. 2019;3(1):85-6.
- Mubarik A and Iqbal AM. (2020). Ventricular septal rupture. In: *StatPearls*. Treasure Island, FL: StatPearls Publishing.
- Stevenson JG, Kawabori I, Dooley T, et al. Diagnosis of ventricular septal defect by pulsed Doppler echocardiography. Sensitivity, specificity and limitations. *Circulation*. 1978;58(2):322-6.
- Crenshaw BS, Granger CB, Birnbaum Y, et al. Risk factors, angiographic patterns, and outcomes in patients with ventricular septal defect complicating acute myocardial infarction. GUSTO-I (Global Utilization of Streptokinase and TPA for Occluded Coronary Arteries) trial investigators. *Circulation*. 2000;101(1):27-32.
- Poulsen SH, Praestholm M, Munk K, et al. Ventricular septal rupture complicating acute myocardial infarction: clinical characteristics and contemporary outcome. *Ann Thorac Surg*. 2008;85(5):1591-6.
- Menon V, Webb JG, Hillis LD, et al. Outcome and profile of ventricular septal rupture with cardiogenic shock after myocardial infarction: a report from the SHOCK Trial Registry. Should we emergently revascularize Occluded Coronaries in cardiogenic shock? *J Am Coll Cardiol*. 2000;36(3 Suppl A):1110-6.
- Jeppsson A, Liden H, Johnsson P, et al. Surgical repair of post infarction ventricular septal defects: a national experience. *Eur J Cardiothorac Surg*. 2005;27(2):216-21.
- Pahuja M, Schrage B, Westermann D, et al. Hemodynamic effects of mechanical circulatory support devices in ventricular septal defect. *Circ Heart Fail*. 2019;12(7):e005981.
- O'Gara PT, Kushner FG, Ascheim DD, et al. 2013 ACCF/AHA guideline for the management of ST-elevation myocardial infarction: a report of the American College of Cardiology Foundation/American Heart Association Task Force on Practice Guidelines. *J Am Coll Cardiol*. 2013;61(4):e78-e140.
- Muehrcke DD, Daggett WM JR, Buckley MJ, et al. Postinfarct Ventricular Septal Defect Repair: Effect of Coronary Artery Bypass Grafting. *Ann Thorac Surg*. 1992;54(5):876-882; discussion 882-3.

Infected Recurrent Thyroglossal Duct Cyst: A Case Report

Jennifer Foti, DO
Felipe Grimaldo, MD

Naval Medical Center San Diego, Department of Emergency Medicine, San Diego, California

Section Editor: Anna McFarlin, MD

Submission history: Submitted February 6, 2020; Revision received May 12, 2020; Accepted April 24, 2020

Electronically published July 2, 2020

Full text available through open access at http://escholarship.org/uc/uciem_cpem

DOI: 10.5811/cpcem.2020.4.46863

Introduction: A thyroglossal duct cyst (TGDC) is a congenital malformation in the neck. Surgical management is often recommended due to risk of recurrent infections and rare possibility of malignancy.

Case Report: Herein, we describe the case of an adult presenting with tender neck mass and fever. She had a history of previous surgical excision of her TGDC as a child. On evaluation she was found to have a recurrent TGDC complicated by acute infection via computed tomography imaging.

Conclusion: In patients who have had previous surgical intervention to remove a TGDC, recurrence with infection should remain a diagnostic consideration. [Clin Pract Cases Emerg Med. 2020;4(3):411–413.]

Keywords: *Thyroglossal duct cyst.*

INTRODUCTION

Thyroglossal duct cysts (TGDC) are a common congenital malformation, typically presenting in the pediatric population. Predominant occurrence is in the first decade of life with physical exam findings of a midline mobile mass at the level of the hyoid.¹ Most cases are managed with surgical excision in childhood due to possibility of malignancy. While various surgical techniques aimed at removal have been previously described, risk of recurrence still remains high with an average of 11% of individuals experiencing this complication.² Exact risk factors that predispose an individual for recurrence or timing of recurrence are not yet clear.³ However, this common complication is important when considering the differential of a patient with acute onset neck mass in the emergency department (ED). Here, we describe a patient who presented to the ED with a tender neck mass who was found to have recurrence of TGDC complicated by acute infection.

CASE REPORT

A 24-year-old previously healthy female presented to the ED with four days of fever, sore throat, neck swelling, and voice change. She had been previously evaluated at an urgent care facility where she had a negative rapid antigen detection test for group A streptococcus, but was referred to the ED for suspected peritonsillar abscess. Her past medical history

was significant for tonsillectomy, adenoidectomy, and TGDC excision. On physical exam, she was appropriately managing her secretions, protecting her airway, and was able to lay supine without experiencing any respiratory distress. Her neck was diffusely swollen, with tender submandibular and anterior cervical lymphadenopathy. Her voice was notably muffled. No discrete fluctuant mass could be palpated or visibly appreciated. The remainder of her physical exam was unremarkable and her vital signs were within normal limits.

Computed tomography (CT) of the neck with contrast revealed a 1.0 x 1.3 x 2 centimeter midline lobulated fluid collection with mild rim enhancement immediately anterior to the lingual tonsils (Image). The otolaryngology service was consulted in the ED. Flexible fiberoptic laryngoscopy was performed at bedside, which revealed a patent airway with an edematous base of the tongue abutting the epiglottis and limited view of the vallecula. Given the history, exam, and radiographic findings, the diagnosis of recurrent, infected TGDC was made. The patient was started on intravenous ampicillin-sulbactam and admitted to the hospital. After resolution of the acute infection, the patient returned four weeks later for excision of the recurrent TGDC.

DISCUSSION

The differential diagnosis for neck swelling, and voice change includes infectious etiologies, oncologic processes, lymphadenopathy, and various cysts. As previously

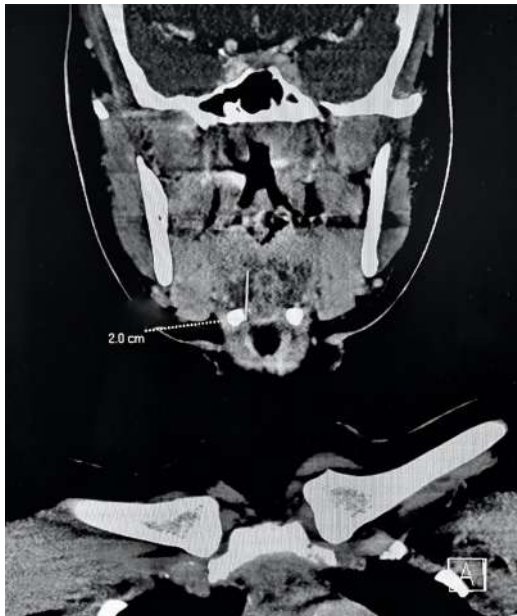


Image. 1.0 x 1.3 x 2 centimeter midline lobulated fluid collection in patient with infected, recurrent thyroglossal duct cyst.

mentioned, the majority of TGDCs will present in childhood, with 60% before age 20. While infrequent, primary occurrence can also present in adulthood, with an even distribution between males and females.¹ A majority of initial presentations are asymptomatic, but a TGDC may be complicated by infection or fistula formation. Patients who experience these complications usually present with dysphagia, throat pain, or tender neck swelling. Infections of a first-time TGDC occur in approximately 8% of patients. Regardless of presentation, definitive management remains surgical excision.³

Recurrence rate following excision remains uncommon. The earlier in childhood the excision is performed, the higher the rate of recurrence.³ However, in the adult population it is important to include recurrence of TGDC as part of the differential diagnosis despite removal in childhood as demonstrated in this case. From our review of the literature, the rate of recurrence complicated by infection is unknown and exceedingly uncommon. This is the first case report that describes recurrence of a TGDC that is also complicated by infection. Diagnosis can be challenging, and ultimately requires imaging to further characterize. CT imaging will demonstrate a midline cystic mass with ring enhancement.⁴ In the acute infectious stage, patients are at risk for airway compromise due to significant swelling and should be admitted to the hospital for intravenous antibiotics, close observation and otolaryngology consultation. Definitive management for TGDC remains surgical excision once the infection has cleared.¹

CONCLUSION

Although infection of a recurrent TGDC is rare, early recognition and diagnosis in the ED is key to appropriate dispositioning of patients, and avoidance of potential airway compromise.

CPC-EM Capsule

What do we already know about this clinical entity?

Thyroglossal duct cysts (TGDC) commonly present in childhood as benign midline neck masses, usually treated with surgical resection.

What makes this presentation of disease reportable?

This is the first case report detailing a recurrent TGDC complicated by acute infection.

What is the major learning point?

Acute infected TGDC should remain on the differential diagnosis for neck swelling regardless of history of previous excision.

How might this improve emergency medicine practice?

As emergency clinicians it is important to keep common childhood pathologies and their complications on the differential even into adulthood.

The authors attest that their institution requires neither Institutional Review Board approval, nor patient consent for publication of this case report. Documentation on file.

Address for Correspondence: Jennifer Foti, DO, Naval Medical Center San Diego, Department of Emergency Medicine, 34800 Bob Wilson Drive, San Diego, CA 92134. Email: fotijt@gmail.com.

Conflicts of Interest: By the CPC-EM article submission agreement, all authors are required to disclose all affiliations, funding sources and financial or management relationships that could be perceived as potential sources of bias. Disclaimer: I am a military service member or federal/contracted employee of the United States government. This work was prepared as part of my official duties. Title 17 U.S.C. 105 provides that 'copyright protection under this title is not available for any work of the United States Government.' Title 17 U.S.C. 101 defines a U.S. Government work as work prepared by a military service member or employee of the U.S. Government as part of that person's official duties. The views expressed in this article are those of the authors and do not necessarily reflect the official policy or position of the Department of the Navy, Department of Defense, nor the U.S. Government. The authors disclosed none..

Copyright: © 2020 Foti et al. This is an open access article distributed in accordance with the terms of the Creative Commons Attribution (CC BY 4.0) License. See: <http://creativecommons.org/licenses/by/4.0/>

REFERENCES

1. Al-Thani H, El-Menyar A, Sulaiti MA, et al. Presentation, management, and outcome of thyroglossal duct cysts in adult and pediatric populations: a 14-year single center experience. *Oman Med J.* 2016;31(4):276-83.
2. Gioacchini FM, Alicandri-Ciufelli M, Kaleci S, et al. Clinical presentation and treatment outcomes of thyroglossal duct cysts: a systematic review. *Int J Oral Maxillofac Surg.* 2015;44(1):119-26.
3. Rohof D, Honings J, Theunisse HJ, et al. Recurrences after thyroglossal duct cyst surgery: results in 207 consecutive cases and review of the literature. *Head Neck.* 2015;37(12):1699-704.
4. Woo E and Connor S. Computed tomography and magnetic resonance imaging appearances of cystic lesions in the suprahyoid neck: a pictorial review. *Dentomaxillofac Radiol.* 2007;36(8):451-8.

Spontaneous Isolated Celiac Artery Dissection: A Case Report

Clifford L. Freeman, MD*
Aaron J. Lacy, MD*
Aubrey Miner, MD*
Devin M. Rogers, MD*
Austin T. Smith, MD†
Karan S. Shah, MD‡

*Vanderbilt University Medical Center, Department of Emergency Medicine, Nashville, Tennessee
†Intermountain Healthcare, Park City Hospital, Department of Emergency Medicine, Park City, Utah
‡Indiana University School of Medicine, Department of Emergency Medicine, Indianapolis, Indiana

Section Editor: Christopher Sampson, MD

Submission history: Submitted February 10, 2020; Revision received May 7, 2020; Accepted May 11, 2020

Electronically published July 3, 2020

Full text available through open access at http://escholarship.org/uc/uciem_cpem

DOI: 10.5811/cpcem.2020.5.46906

Introduction: Abdominal pain is a common chief complaint that can represent a wide breadth of diagnoses, ranging from benign to life-threatening. As our diagnostic tools become more sophisticated, we are able to better identify more causes of potentially life-threatening diseases. One such disease that is relatively unfamiliar to clinicians is spontaneous isolated celiac artery dissection (SICAD).

Case Report: We describe a case of a 46-year-old man who presented to our emergency department with a chief complaint of abdominal pain and was found to have a SICAD and was successfully treated with anticoagulation, antihypertensives, and observation.

Conclusion: It is important for emergency physicians to keep this potentially life-threatening condition in mind and to know the appropriate first steps once identified. [Clin Pract Cases Emerg Med. 2020;4(3):414–416.]

Keywords: SICAD; spontaneous isolated celiac artery dissection; abdominal pain; imaging; computed tomography.

INTRODUCTION

Abdominal pain is one of the most common presenting chief complaints of patients in the emergency department (ED).¹ It is a general chief complaint that represents a wide breadth of diagnoses, ranging from benign to life-threatening, and it is critical that emergency physicians be able to differentiate the two. For this reason, abdominal pain can be a challenging chief complaint, as there is often overlap in symptoms and localization of intra-abdominal pathology can be unreliable on physical exam. A combination of labs, imaging, and physical exam is often needed to determine the diagnosis. The management of abdominal pain has changed over time, and recent trends show an increase in computed tomography (CT) being done to aid in the diagnosis.² While increased use of CT carries the risk of radiation exposure, potential of contrast-induced nephropathy, and higher hospital costs, it has led to more reports of diseases that previously could only be identified in the operating room

or on autopsy. One such potentially life-threatening diagnosis is spontaneous visceral artery dissection.^{3,4} We describe a case of a 46-year-old man who presented to the ED with a chief complaint of abdominal pain and was found to have a spontaneous isolated celiac artery dissection (SICAD) and was successfully treated with anticoagulation, antihypertensives, and observation.

CASE REPORT

A 46-year-old male with a past medical history of hypertension and Hodgkin's lymphoma presented to our ED for evaluation of abdominal pain. He reported that just prior to arrival he had sudden onset pain in his midepigastriac region. It was sharp, severe, radiating to his back and was associated with nausea and dyspnea. He was hypertensive with otherwise normal vital signs. On examination he was tender to light palpation in his epigastriac region without rebound, guarding, or tenderness elsewhere. He had a normal electrocardiogram

without any signs of ischemia. His labs were significant for a white blood cell count of 11.4×10^9 thousands (K) per microliter (mcL) (range 3.6-10.6 K/mcL), with a normal lipase, normal liver function tests, and negative troponin. Given the history and exam, a CT angiogram of the chest, abdomen, and pelvis was ordered, which revealed SICAD (Images 1 and 2) with extension into the common hepatic artery (Image 3).

DISCUSSION

SICAD is a rare but potentially life-threatening diagnosis.⁵ It is the second leading type of visceral artery dissection after spontaneous isolated superior mesenteric artery dissection.⁵ Visceral artery dissections were first described in 1947 and initially thought to be a fatal injury as all cases reported before 1975 were diagnosed at autopsy.^{5,6} However, the implementation of CT angiography has improved the ability to make the diagnosis.⁷ Symptoms can range from asymptomatic incidental findings to severe abdominal pain with bowel ischemia resulting in peritonitis; therefore, the diagnosis requires a high level of clinical suspicion.⁷ The most common profile of patients presenting with SICAD are male smokers with hypertension, although it will also present in those without these comorbidities.⁷ Conservative management is considered the initial treatment for most SICAD patients as long as they do not have bowel ischemia, although there is not a standardized consensus on the best medical therapy.⁷ Most medical treatments performed include a combination of fasting, parenteral nutrition support, pain control, and treatment of hypertension. Two large cohort studies to date have shown no benefit with antithrombotic therapy vs observation in clinical outcomes.^{4,8} Our patient was started on an esmolol infusion to control his hypertension along with a heparin infusion at the recommendation of the vascular surgery service. He was admitted and transitioned to

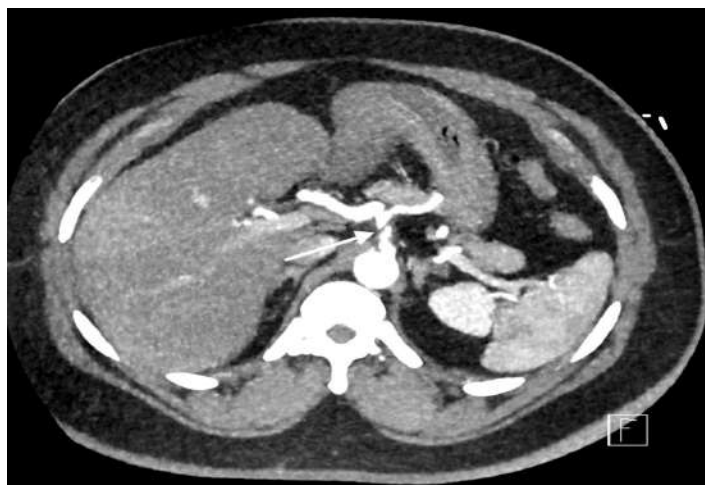

Image 1. An axial image of a contrast-enhanced computed tomography angiogram showing a dissection flap in the celiac trunk (arrow).

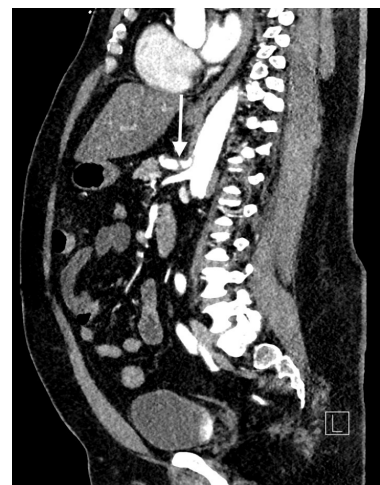


Image 2. A sagittal image of a contrast-enhanced computed tomography angiogram showing a dissection flap in the celiac trunk (arrow).

CPC-EM Capsule

What do we already know about this clinical entity?
Spontaneous isolated celiac artery dissection is a rare, but potentially life-threatening diagnosis. There is no consensus on treatment, which ranges from conservative therapy to surgical intervention.

What makes this presentation of disease reportable?
This is a disease process that previously was discovered by autopsy and therefore considered (at that time) to be universally fatal. With the increased utilization of computed tomography imaging, it is being detected more frequently.

What is the major learning point?
This rare, but potentially fatal condition should be considered in the differential diagnosis for abdominal pain; particularly in male smokers with a history of hypertension.

How might this improve emergency medicine practice?
It is important for emergency physicians to consider this potentially fatal diagnosis. Knowledge of this condition, risk factors and presentation will increase the likelihood of detection resulting in life-saving therapies.

oral anticoagulation and antihypertensive medications after his abdominal pain resolved. He did not require intervention and was discharged in good condition several days later.

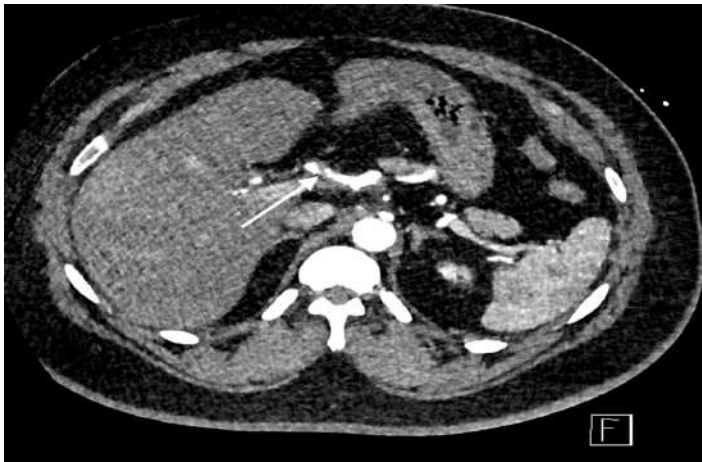

Image 3. An axial image of a contrast-enhanced computed tomography angiogram showing a dissection flap in the common hepatic artery (arrow).

CONCLUSION

Abdominal pain as a chief complaint can vary from benign to catastrophic. Spontaneous isolated celiac artery dissection is relatively rare, and can present from asymptomatic incidental finding to severe pain with bowel ischemia and peritonitis. Early diagnosis is critical to reduce morbidity and mortality and is typically detected on a contrast-enhanced CT. SICAD has a wide presentation range, but often resolves with conservative management. It is important for emergency physicians to keep this potentially life-threatening condition on their differential, and to know the appropriate first steps to take once identified.

The authors attest that their institution requires neither Institutional Review Board approval, nor patient consent for publication of this case report. Documentation on file.

REFERENCES

1. National Hospital Ambulatory Medical Care Surgery. 2015

Address for Correspondence: Austin T. Smith, MD, Intermountain Park City Hospital, Department of Emergency Medicine, 900 Round Valley Drive, Park City, UT 84060. Email: Austin.smith@imail.org.

Conflicts of Interest: By the CPC-EM article submission agreement, all authors are required to disclose all affiliations, funding sources and financial or management relationships that could be perceived as potential sources of bias. The authors disclosed none.

Copyright: © 2020 Freeman et al. This is an open access article distributed in accordance with the terms of the Creative Commons Attribution (CC BY 4.0) License. See: <http://creativecommons.org/licenses/by/4.0/>

- Emergency Department Summary Tables. 2015. Available at: https://www.cdc.gov/nchs/data/nhamcs/web_tables/2015_ed_web_tables.pdf. Accessed January 20, 2019.
2. Neychev V, Krol E, Dietzek A. Unusual presentation and treatment of spontaneous celiac artery dissection. *J Vasc Surg.* 2013;58(2):491-5.
3. Aisenberg GM and Grimes RM. Computed tomography in patients with abdominal pain and diarrhoea: Does the benefit outweigh the drawbacks? *Intern Med J.* 2013;43(10):1141-4.
4. Loeffler JW, Obara H, Fujimura N, et al. Medical therapy and intervention do not improve uncomplicated isolated mesenteric artery dissection outcomes over observation alone. *J Vasc Surg.* 2017;66(1):202-8.
5. Ko SH, Hye R, Frankel DA. Management of spontaneous isolated visceral artery dissection. *Ann Vasc Surg.* 2015;29(3):470-4.
6. Bauersfeld SR. Dissecting aneurysm of the aorta: a presentation of 15 cases and a review of the recent literature. *Ann Intern Med.* 1947;26(6):873-89.
7. Wang J, He Y, Zhao J, et al. Systematic review and meta-analysis of current evidence in spontaneous isolated celiac and superior mesenteric artery dissection. *J Vasc Surg.* 2018;68(4):1228-40.e9.
8. Heo SH, Kim YW, Woo SY, et al. Treatment strategy based on the natural course for patients with spontaneous isolated superior mesenteric artery dissection. *J Vasc Surg.* 2017;65(4):1142-51.

Spinal Arteriovenous Fistula, A Manifestation of Hereditary Hemorrhagic Telangiectasia: A Case Report

Jodi Spangler, BA
Bjorn Watsjold, MD, MPH
Jonathan S. Ilgen, MD, MCR

University of Washington School of Medicine, Department of Emergency Medicine,
Seattle, Washington

Section Editor: Austin Smith, MD

Submission history: Submitted February 26, 2020; Revision received May 3, 2020; Accepted May 11, 2020

Electronically published July 3, 2020

Full text available through open access at http://escholarship.org/uc/uciem_cpchem

DOI: 10.5811/cpcem.2020.5.47086

Introduction: Hereditary hemorrhagic telangiectasia (HHT) is an autosomal dominant disorder characterized by arteriovenous malformations (AVM). HHT can have neurological manifestations.

Case Report: A 32-year-old woman with a history of HHT presented to the emergency department with acute partial paralysis of the right leg, urinary retention, and right-sided back and hip pain. Magnetic resonance imaging of the spine demonstrated multiple, dilated blood vessels along the cervical spine, diffuse AVMs in the lumbar and thoracic spine, and a new arteriovenous fistula at the twelfth thoracic (T12) vertebral level. Her symptoms improved after endovascular embolization of the fistula.

Conclusion: Spinal AVMs are thought to be more prevalent in patients with HHT. Given the high morbidity of arteriovenous fistulas, early recognition and intervention are critical. [Clin Pract Cases Emerg Med. 2020;4(3):417–420.]

Keywords: *Hereditary hemorrhagic telangiectasia; arteriovenous fistula.*

INTRODUCTION

Hereditary hemorrhagic telangiectasia (HHT) is an autosomal dominant disorder occurring in approximately 1 in 10,000 people, characterized by arteriovenous malformations (AVM) in the gastrointestinal tract, central nervous system, and lungs, mucocutaneous telangiectasia, and recurrent epistaxis.^{1,2,3} HHT can have neurological manifestations, and, although rare, spinal AVMs are thought to be more prevalent in these patients.⁴ Arteriovenous fistulas (AVF) are direct communications between arteries and veins without a vascular nidus and have a high morbidity if untreated.^{5,6}

CASE REPORT

A 32-year-old woman with a history of HHT presented to the emergency department (ED) with acute right hip and flank pain with associated weakness in her right leg.

The patient, as a result of her HHT, had a history of persistent epistaxis requiring embolization and two prior spontaneous subdural hemorrhages that required decompressive craniotomies

five years prior to her visit. At that time, computed tomography (CT) and magnetic resonance imaging (MRI) imaging of her spine demonstrated diffusely dilated vessels that extended from her cervical spine to the base of her thoracic spine, causing compression and deformity of the spinal cord. These were suspected to be secondary to dural AVFs and an AVM at the seventh thoracic (T7) vertebral level. Neurosurgical consultants recommended surgical intervention to prevent myelopathy, but she elected not to undergo surgery because of the potential complications of the procedures.

She was otherwise healthy, did not smoke, drink alcohol, or take recreational drugs. She had emigrated from Ethiopia, and her father had had recurrent episodes of epistaxis that were thought to be secondary to HHT, although this was never formally diagnosed.

Two weeks prior to presentation, the patient had sought care in the ED for right hip and flank pain. At that time, her physical examination showed no definite motor weakness, and she was discharged to follow-up with her physician. She had two

subsequent ED visits at other hospitals and was documented to have increasing weakness of hip flexion (4/5), knee extension (4/5), and ankle dorsiflexion (3/5). She eventually needed crutches for mobility. Across these three visits, the patient had negative radiographs of the femur, normal CT imaging of the abdomen and pelvis, and normal MRI of the pelvis.

Her pain and weakness progressed until she lost sensation in her right leg, was unable to bear weight secondary to weakness, and was subsequently bedridden. Additionally, she developed increased urinary frequency and difficulty fully evacuating her bladder. Upon her return to the ED, she was noted to have profound (0/5) weakness of right hip flexion, knee flexion, and ankle plantar- and dorsiflexion, as well as significant (2/5) weakness of right knee extension. She had no sensation to pinprick throughout her right thigh, leg, and foot, and had hyporeflexia throughout her right lower extremity. Her plantar reflex in both feet was normal, as were her mental status and cranial nerves. She had intact rectal tone and perineal sensation.

Based on her presentation, her providers were concerned for spinal cord compression, dural compression syndrome, and spinal cord ischemia. Neurosurgery was consulted, and MRI of her entire spine was performed. MRI of her cervical, thoracic, and lumbar spine demonstrated diffuse, dilated vessels extending from her brainstem to T12, consistent with her known dural AVF (Image 1). In addition to multiple arterial feeder vessels contributing to the AVF, she had two areas of AVM at T7 and T11-12, and an area of subacute/chronic hemorrhage at T11-12 (Image 2). There was also diffuse abnormality of the spinal cord

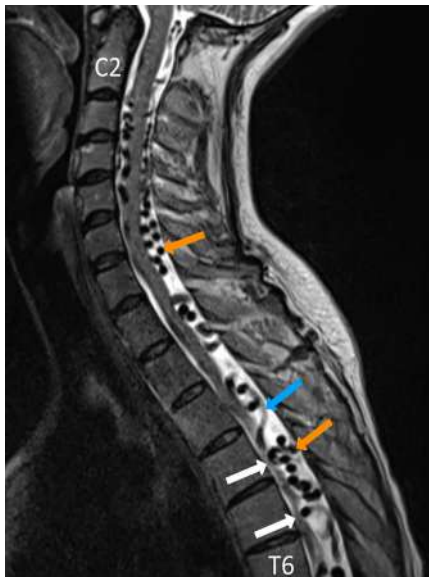

Image 1. Sagittal magnetic resonance imaging T2-weighted image of the cervical and thoracic spine. Flow voids appear black against white cerebrospinal fluid, and indicate extensive dilated vessels suggestive of dural arteriovenous fistulas. Orange arrows identify vessels perpendicular to the plane of the image, blue arrow identifies vessel at an angle to the plane with relatively increased signal. The white arrows highlight areas of spinal cord being compressed or deformed out of plane by dilated vessels.

CPC-EM Capsule

What do we already know about this clinical entity?

Hereditary Hemorrhagic Telangiectasia (HHT) is an autosomal dominant disorder characterized by arteriovenous malformations (AVMs).

What makes this presentation of disease reportable?

A rare case of spinal arteriovenous malformations and fistula in a patient with HHT who presented with neurological symptoms.

What is the major learning point?

HHT can have neurological manifestations, and, although rare, spinal AVMs are thought to be more prevalent in these patients.

How might this improve emergency medicine practice?

Given the high morbidity of arteriovenous fistulas, early recognition and intervention are critical.

signal extending from T6 to the conus medullaris that was concerning for multiple processes including edema and ischemia.

The patient underwent angiography and embolization of a feeder vessel to the dural AVF originating at T12 that connected to the AVM at T7, but this procedure incompletely treated the abnormal flow. After the procedure, she discussed further intervention with the neurosurgical service, and again declined surgical intervention. The patient spent four weeks in the hospital postoperatively and in rehabilitation, ultimately regaining normal bladder function and motor function in her right leg.

Two years after this visit, the patient developed left-sided radicular leg pain without loss of motor function. She continued to follow up with neurosurgery but postponed management of the residual AVM due to other complications of HHT, including anemia, recurrent epistaxis, and cardiomyopathy due to high-output heart failure. She developed progressive loss of function in the right leg, and eventually underwent successful embolization of the remaining fistula pouch nearly four years after the initial visit.

DISCUSSION

HHT is an autosomal dominant disorder characterized by AVMs in the gastrointestinal tract, central nervous system, and lungs, mucocutaneous telangiectasia, and recurrent epistaxis.^{1,2,3} Thought to be caused by changes in angiogenesis, HHT manifestations develop with increasing age and range from

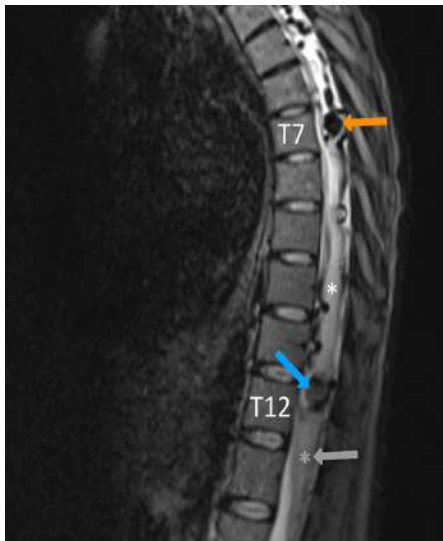

Image 2. Sagittal magnetic resonance imaging T2-weighted image of the thoracic and lumbar spine. The orange arrow points to a flow void suggestive of an arteriovenous malformation with dilated varix at seventh thoracic (T7). There is a similar dilated varix at T11 to the twelfth thoracic (T12), and the blue arrow shows an area of darker gray suggesting hemosiderin from subacute or chronic hemorrhage. The spinal cord in this image is hyperintense due to venous congestion and edema, possibly worsened by ischemia. For comparison of relative signal intensity, the gray asterisk and arrow at the conus show the same signal level as the cord at the tenth thoracic level surrounding the white asterisk.

being asymptomatic to life-threatening.⁸ Spontaneous recurrent epistaxis from telangiectasia of the nasal mucosa is the most common symptom and usually the earliest sign of the disease.¹

This patient's initial evaluations focused on hip, leg, and flank pain, with multiple unrevealing imaging studies. When she returned with muscle weakness, sensory deficits, and urinary retention, there was concern for acute pathology affecting the spinal cord or peripheral nerves. In an otherwise healthy patient, acute neurologic deficits such as these may have prompted consideration of cauda equina syndrome, inflammatory and autoimmune pathologies including acute transverse myelitis, multiple sclerosis, and Guillain-Barré syndrome, and infectious causes including epidural abscess. In a patient with HHT, one must take into consideration that their vascular abnormalities increase the risk for central and peripheral neurologic insults. Pulmonary AVMs can increase risk of embolic stroke, and cerebral and/or spinal AVMs can cause local ischemia and hemorrhage. Imaging and management should, therefore, correlate physical exam findings with the likely level of the injury.⁷

HHT has neurological involvement in up to 20% of patients, including cerebral and spinal AVMs.⁹ Cerebral AVMs can result in hemorrhage, such as in this patient's prior spontaneous subdural hematomas. Spinal AVMs are thought to be more prevalent in patients with HHT, although these lesions are rare

(estimated prevalence of less than 1% in patients with HHT) with the majority being perimedullary fistulae with complex high-flow angioarchitecture.^{3,4} Spinal vascular malformations are categorized as non-shunting lesions (aneurysms) and shunting lesions (AVM and fistulas).¹⁰ AVFs are a direct communication between arteries and veins without a vascular nidus, and spinal AVF in particular is an abnormal connection between an arterial feeder and a draining vein in the spinal cord dura or arachnoid.^{5,6}

Perimedullary AVFs commonly develop at the ventral portion of the spinal cord, while dural AVFs commonly develop at the dorsolateral portion of the dura mater.¹¹ Dorsal AVFs are typically low flow, and lead to congestive myelopathy that affects the caudal end of the cord regardless of the level of fistula.¹² The majority of AVFs are idiopathic and detected only when symptoms arise, with acute or subacute presentation, presenting as severe neurological deficits, progressive myelopathy, or subarachnoid hemorrhage.⁴ The most common presenting symptoms, such as in this case, are acute motor deficits.⁴

The diagnosis of spinal AVMs is often delayed and challenging, and significant morbidity can occur before surgical or endovascular intervention.⁸ Lesions detected early are reversible, and the preferred treatment modality for spinal vascular malformations in HHT is endovascular embolization, which also helps to decrease the risk of developing future vascular collaterals.^{13,14} If endovascular intervention is unsuccessful, surgery is also an option to interrupt the shunt.¹³ In general, early treatment has a high rate of clinical and angiographic improvement and complications are uncommon.^{13,15}

CONCLUSION

Although rare, vascular etiologies such as spinal arteriovenous fistula should be in the differential diagnosis for a patient with HHT presenting with neurological symptoms. Spinal AVF can cause significant morbidity, and given the effectiveness of embolization or surgical intervention, early recognition and treatment are critical.

Patient consent has been obtained and filed for the publication of this case report.

Address for Correspondence: Jodi Spangler, BA, University of Washington School of Medicine, 325 9th Avenue, Seattle, WA 90104. Email: jspang@uw.edu.

Conflicts of Interest: By the CPC-EM article submission agreement, all authors are required to disclose all affiliations, funding sources and financial or management relationships that could be perceived as potential sources of bias. The authors disclosed none.

Copyright: © 2020 Spangler et al. This is an open access article distributed in accordance with the terms of the Creative Commons Attribution (CC BY 4.0) License. See: <http://creativecommons.org/licenses/by/4.0/>

REFERENCES

1. Govani FS and Shovlin CL Hereditary haemorrhagic telangiectasia: a clinical and scientific review. *Eur J Hum Genet.* 2009;17(7):860-71.
2. Shovlin CL, Guttmacher AE, Buscarini E, et al. Diagnostic criteria for hereditary hemorrhagic telangiectasia (Rendu-Osler-Weber syndrome). *Am J Med Genet.* 2000;91(1):66-7.
3. Faughnan ME, Palda VA, Garcia-Tsao G, et al. International Guidelines for the Diagnosis and Management of Hereditary Haemorrhagic Telangiectasia. *J Med Genet.* 2011;48(2):73-87.
4. Brinjikji W, Nasr DM, Cloft HJ, et al. Spinal arteriovenous fistulae in patients with hereditary hemorrhagic telangiectasia: a case report and systematic review of the literature. *Interv Neuroradiol.* 2016;22(3):354-61.
5. Jahan R and Vinuela F. Vascular anatomy, pathophysiology, and classification of vascular malformations of the spinal cord. *Seminars Cerebrovasc Dis Stroke.* 2002;2(3):186-200.
6. Krings T and Geibprasert S. Spinal dural arteriovenous fistulas. *AJNR Am J Neuroradiol.* Apr 2009;30(4):639-48
7. Willemse RB, Mager JJ, Westermann CJ, et al. Bleeding risk of cerebrovascular malformations in hereditary hemorrhagic telangiectasia. *J Neurosurg.* 2000;92(5):779-84.
8. Gallitelli M, Pasculli G, Fiore T, et al. Emergencies in hereditary haemorrhagic telangiectasia. *QJM.* 2006;99(1):15-22.
9. Krings T, Chng SM, Ozanne A, et al. Hereditary haemorrhagic telangiectasia in children. endovascular treatment of neurovascular malformations. *Interv Neuroradiol.* 2005;11(1):13-23.
10. Morris JM. Imaging of dural arteriovenous fistula. *Radiol Clin North Am.* 2012;50(4):823-39.
11. Takai K. Spinal arteriovenous shunts: angioarchitecture and historical changes in classification. *Neurol Med Chir (Tokyo).* 2017;57(7):356-65.
12. Jellema K, Tijssen CC, van Gijn J. Spinal dural arteriovenous fistulas: a congestive myelopathy that initially mimics a peripheral nerve disorder. *Brain.* 2006;129(Pt 12):3150-64.
13. Gross BA and Du R. Spinal pial (Type IV) arteriovenous fistulae: a systematic pooled analysis of demographics, hemorrhage risk, and treatment results. *Neurosurgery.* 2013;73(1):141-51;discussion 151.
14. Berenstein A and Lasjaunias P. (1992). Endovascular treatment of spine and spinal cord lesions. *Surgical Neuroangiography (pp. 18-85).* Heidelberg, Germany: Springer-Verlag Berlin Heidelberg.
15. Ling JCM, Agid R, Nakano S, et al. Metachronous multiplicity of spinal cord arteriovenous fistula and spinal dural AVF in a patient with hereditary haemorrhagic telangiectasia. *Interv Neuroradiol.* 2005;11(1):79-82.

Tranexamic Acid in a Case Report of Life-threatening Nontraumatic Hemorrhage in Immune Thrombocytopenic Purpura

Melanie M. Randall, MD*
Jason Nurse†
Karan P. Singh, MD, MBA†

*Loma Linda University Medical Center and Children's Hospital, Department of Emergency Medicine, Loma Linda, California
†San Geronio Memorial Hospital, Department of Emergency Medicine, Banning, California

Section Editor: Steven Walsh, MD

Submission history: Submitted February 14, 2020; Revision received May 5, 2020; Accepted May 11, 2020

Electronically published July 9, 2020

Full text available through open access at http://escholarship.org/uc/uciem_cpem

DOI: 10.5811/cpem.2020.5.46955

Introduction: Immune thrombocytopenic purpura (ITP) is an autoimmune-mediated disorder in which the body produces antibodies that destroy platelets, causing an increased risk of bleeding and bruising. Tranexamic acid (TXA) is a medication that prevents clot breakdown and is used to treat uncontrolled bleeding.

Case Report: We present the case of an 11-year-old female with significant epistaxis and hypotension in the emergency department. Traditional therapies were initiated; however, the patient continued to have bleeding and remained hypotensive, so intravenous TXA was given. The patient's bleeding then resolved.

Conclusion: TXA may be a safe and effective adjunct to traditional therapies for the treatment of life-threatening hemorrhage in ITP patients. [Clin Pract Cases Emerg Med. 2020;4(3):421–423.]

Keywords: *immune thrombocytopenic purpura; tranexamic acid; epistaxis.*

INTRODUCTION

Immune thrombocytopenic purpura (ITP) is an autoimmune-mediated disorder in which antibodies to platelets cause a precipitous drop in platelet level. This increases bruising and risk of bleeding. It can be acute, chronic, or recurrent. While most patients do not experience severe consequences, ITP occasionally causes life-threatening hemorrhage.¹ Tranexamic acid (TXA) is a medication that prevents breakdown of formed clots and is commonly used for traumatic hemorrhage and perioperative bleeding. To date, it has not been described in the setting of life-threatening bleeding secondary to ITP in children. We present a novel case of an 11-year-old female with recurrent epistaxis, hematemesis, and hypotension who was given, along with standard ITP therapies, intravenous (IV) TXA in the emergency department (ED).

CASE REPORT

An 11-year-old female weighing 62 kilograms with no past medical history presented to the ED by ambulance after two syncopal episodes and recurrent epistaxis. The epistaxis had begun the night before and was associated with multiple episodes of hematemesis. Her measured vital signs by paramedics were a heart rate of 150 beats per minute and blood pressure 76 systolic over 41 diastolic millimeters of mercury. Her physical exam was a general appearance of alert and awake, warm and dry skin, dried blood in the nares, tachycardia with no murmur, clear lung sounds, and a petechial rash on bilateral lower extremities.

The patient was initially given a one liter bolus of lactated Ringer's solution. A type and crossmatch for packed red blood cell (PRBC) transfusion was sent to the laboratory along with a complete blood count, coagulation studies, and electrolytes.

The laboratory results showed a platelet count of 1000 per cubic millimeter (mm³) (reference range [Ref]: 150,000-450,000/mm³); hemoglobin of 7.3 grams per deciliter (g/dL) (Ref: 12.0-16.0 g/dL); hematocrit of 20.9% (Ref: 37.0-47.0%); partial thromboplastin time of 29.6 seconds (Ref: 22.0-34.0 seconds); prothrombin time of 12.1 seconds (Ref: 9.0-12.0 seconds); and international normalized ratio of 1.1 (Ref: 0.8-1.2).

Approximately two and half hours after arrival, the patient had another epistaxis episode with posterior bleeding and 400 milliliters of hematemesis. The patient was given IV dexamethasone 10 milligrams and IV immune globulin (IVIG) of 45 grams (g). The correct dose of IVIG would have been 62 g; however, the pharmacy had only 45 g available at the time. Despite these treatments, the patient remained hypotensive with a systolic blood pressure in the 60s and a heart rate in the 160s.

Nasal packing topically soaked with TXA was placed in the patient's left nare, and PRBC transfusion was begun; however, due to continued hypotension and instability of the patient, the decision was made to give TXA 1 gram intravenously. Ten minutes after the administration of TXA, the patient's hematemesis and epistaxis resolved. The patient's systolic blood pressure improved to the 80s, and her heart rate to the 110s. Platelet transfusion had been ordered but was not available readily, by which time the patient's vital signs had improved and bleeding had stopped. The patient's clinical course is noted in the table.

Patient was transferred to a nearby, contracted facility during which she received evaluation for new-onset ITP. She did well and was discharged home without further episodes of serious bleeding.

DISCUSSION

We report a case of life-threatening hemorrhage secondary to acute ITP treated with IV TXA. To our knowledge, this is the first case of this use of TXA reported in the literature. Acute ITP often presents to the ED with easy bruising and mucosal bleeding. In children it can develop suddenly and is often the result of an autoimmune antibody response to platelets.² The incidence of serious hemorrhage is rare, but is highest in patients with very low platelet counts and those who do not achieve remission.^{1,2} A standard treatment regimen for pediatric acute ITP includes corticosteroids and IVIG to increase platelet counts; however, another school of thought is to only provide supportive care as most patients will recover without treatment.¹ Cases refractory to standard treatments have been successfully treated with rituximab, a monoclonal antibody. Newer thrombopoietin receptor antagonists (TPO-RAs) such as eltrombopag and romiplostim, which stimulate bone marrow, have been used in treating chronic ITP.³ For acute cases of bleeding, high-dose IV steroids, IVIG, aminocaproic acid, recombinant factor VIIIa, and TPO-RAs have been studied.^{1,2} And while TXA has been studied in adults, with anecdotal evidence of its use in controlling mucosal bleeding, and a case

CPC-EM Capsule

What do we already know about this clinical entity?

Immune thrombocytopenic purpura (ITP) can develop acutely, with a risk of bleeding and requiring emergent treatment. Tranexamic acid (TXA) is a medication used to treat hemorrhage in a variety of settings.

What makes this presentation of disease reportable?

The use of intravenous TXA has not been previously described as a treatment for hypotension and hemorrhage control in ITP.

What is the major learning point?

TXA may be a safe and effective adjunct to traditional therapies for the treatment of life-threatening hemorrhage in patients with Immune thrombocytopenic purpura ITP.

How might this improve emergency medicine practice?

Emergency physicians can add this to the list of potential treatments for severe acute hemorrhage in the setting of ITP.

Table. Timeline of patient care.

Time	Patient course
0827	Patient arrived by ambulance VS: BP 76/41, HR 150, RR 18, SaO ₂ 93% on RA
0900	LR 1L IV bolus
1000	Dexamethasone 10mg IV VS: BP 84/52, HR 123, RR 22, SaO ₂ 99%
1100	IVIG 45gm
1115	Epistaxis resumes and draining posteriorly, Emesis 400mL blood VS: BP 70/40, HR 140, RR 20, SaO ₂ 100% Nasal tampon soaked in TXA inserted
1130	PRBC 1 unit IV started
1134	TXA 1gm IV
1145	Patient reports no further bleeding
1155	VS: BP 82/58, HR 110, RR 22, SaO ₂ 100%

VS, vital signs; BP, blood pressure; HR, heart rate; RR, respiratory rate; SaO₂, oxygen saturation; RA, room air; LR, lactated Ringer's; IV, intravenous; gm, gram; IVIG, intravenous immunoglobulin; TXA, tranexamic acid; PRBC, packed red blood cells.

series describing its use of TXA in chronic ITP-related bleeding, there are no studies in children.⁴⁻⁶

When reviewing the literature, we found that TXA has been studied and used in a wide range of settings, especially in the surgical fields including orthopedic procedures, otolaryngologic surgery, obstetric bleeding and heavy menstrual bleeding, pediatric cardiac surgery, and coronary artery surgery.^{2,8-11} A large meta-analysis evaluating TXA in surgical patients showed that TXA reduced the need for blood transfusion and resulted in fewer deaths.¹¹ It has also been studied for the treatment of epistaxis.^{10,12} TXA is quickly becoming a standard of care in the treatment of adult trauma patients, with studies ongoing in pediatric trauma patients.¹³ A few of these studies have shown a slightly higher risk for postoperative seizures; however, the majority of studies show that TXA has minimal side effects.^{2,9,11}

TXA, which is a synthetic derivative of lysine, acts as an antifibrinolytic by preventing plasminogen from being converted to plasmin. Plasmin breaks down fibrin of already-formed blood clots.¹⁴ The evidence for antifibrinolytics in hematology patients is limited, but it has been used to treat bleeding related to a variety of hematologic conditions including hemophilia and von Willebrand disease.^{2,15} While there is no evidence that shows TXA should be used in the absence of other traditional treatments for ITP, this case demonstrates its use as an adjunct for unstable bleeding and the need for further study and investigation of TXA use in patients with ITP.

CONCLUSION

TXA may be a safe and effective adjunct to traditional therapies for the treatment of life-threatening hemorrhage in ITP patients.

Patient informed consent has been obtained and filed for publication of this case report.

Address for Correspondence: Melanie Randall, MD, Loma Linda University Medical Center and Children's Hospital, Department of Emergency Medicine, 11234 Anderson st., Loma Linda, CA 92354. Email: mrandall@llu.edu.

Conflicts of Interest: By the CPC-EM article submission agreement, all authors are required to disclose all affiliations, funding sources and financial or management relationships that could be perceived as potential sources of bias. The authors disclosed none.

Copyright: © 2020 Randall et al. This is an open access article distributed in accordance with the terms of the Creative Commons Attribution (CC BY 4.0) License. See: <http://creativecommons.org/licenses/by/4.0/>

REFERENCES

1. Neunert CE, Buchanan GR, Imbach P, et al. Bleeding manifestations and management of children with persistent and chronic immune thrombocytopenia: data from the Intercontinental Cooperative ITP Study Group (ICIS). *Blood*. 2013;121(22):4457-62.
2. Cooper N. State of the art: how I manage immune thrombocytopenia. *Br J Haematol*. 2017;177(1):39-54.
3. Neunert C, Lim W, Crowther M, et al. The American Society of Hematology 2011 evidence-based practice guideline for immune thrombocytopenia. *Blood*. 2011;117(16):4190-207.
4. Bartholomew JR, Salgia R, Bell WR. Control of bleeding in patients with immune and nonimmune thrombocytopenia with aminocaproic acid. *Arch Intern Med*. 1989;149(9):1959-61.
5. Lakshmanan S and Cuker A. Contemporary management of primary immune thrombocytopenia in adults. *J Thromb Haemost*. 2012;10(10):1988-98.
6. Mayer B and Salama A. Successful treatment of bleeding with tranexamic acid in a series of 12 patients with immune thrombocytopenia. *Vox Sang*. 2017;112(8):767-72.
7. Karaaslan F, Karaoğlu S, Yurdakul E. Reducing intra-articular hemarthrosis after arthroscopic anterior cruciate ligament reconstruction by the administration of intravenous tranexamic acid: a prospective, randomized controlled Trial. *Am J Sports Med*. 2015;43(11):2720-6.
8. Arantes GC, Pereira RMR, de Melo DB, et al. Effectiveness of tranexamic acid for reducing intraoperative bleeding in palatoplasties: a randomized clinical trial. *J Craniomaxillofac Surg*. 2017;45(5):642-8.
9. WOMAN Trial Collaborators. Effect of early tranexamic acid administration on mortality, hysterectomy, and other morbidities in women with post-partum haemorrhage (WOMAN): an international, randomised, double-blind, placebo-controlled trial. *Lancet*. 2017;389(10084):2105-16.
10. Nishijima DK, Monuteaux MC, Faraoni D, et al. Tranexamic acid use in United States children's hospitals. *J Emerg Med*. 2016;50(6):868-74.
11. Zhang Y, Zhang X, Wang Y, et al. Efficacy and safety of tranexamic acid in pediatric patients undergoing cardiac surgery: a single-center experience. *Front Pediatr*. 2019;7:181.
12. Joseph J, Martinez-Devesa P, Bellorini J, et al. Tranexamic acid for patients with nasal haemorrhage (epistaxis). *Cochrane Database Syst Rev*. 2018;12:CD004328.
13. CRASH-2 trial collaborators. Effects of tranexamic acid on death, vascular occlusive events, and blood transfusion in trauma patients with significant haemorrhage (CRASH-2): a randomised, placebo-controlled trial. *Lancet*. 2010;376:23-32.
14. McCormack PL. Tranexamic acid: a review of its use in the treatment of hyperfibrinolysis. *Drugs*. 2012;72(5):585-617.
15. Estcourt LJ, Desborough M, Brunskill SJ, et al. Antifibrinolytics (lysine analogues) for the prevention of bleeding in people with haematological disorders. *Cochrane Database Syst Rev*. 2016;3:CD009733.

Point-of-care Echocardiogram as the Key to Rapid Diagnosis of a Unique Presentation of Dyspnea: A Case Report

Michael Moore, MD
Brian Dilcher, MD
Joseph Minardi, MD
Kimberly Quedado, PhD
Erica Shaver, MD

West Virginia University School of Medicine, Department of Emergency Medicine,
Morgantown, West Virginia

Section Editor: Manish Amin, DO

Submission history: Submitted February 21, 2020; Revision received May 6, 2020; Accepted May 11, 2020

Electronically published July 30, 2020

Full text available through open access at http://escholarship.org/uc/uciem_cpem

DOI: 10.5811/cpcem.2020.5.47012

Introduction: Dyspnea is commonly evaluated in the emergency department (ED). The differential diagnosis is broad. Due to the large volume of dyspneic patients evaluated, emergency physicians (EP) will encounter uncommon diagnoses. Early, liberal application of point-of-care ultrasound (POCUS) may decrease diagnostic error and improve care for these patients.

Case Report: We report a 48-year-old male presenting to the ED with cough and progressively worsening dyspnea for 11 months after multiple healthcare visits. Using POCUS, the EP was immediately able to diagnose a severe dilated cardiomyopathy (DCM) with left ventricular thrombus.

Conclusion: Given that non-ischemic DCM is one of the most common etiologies of heart failure, often presenting with respiratory symptoms, POCUS is key to rapid diagnosis and, along with modalities such as electrocardiography and chest radiograph, should be standard practice in the workup of dyspnea, regardless of age or comorbidities. [Clin Pract Cases Emerg Med. 2020;4(3):424–427.]

Keywords: *Emergency Medicine; Point of Care Ultrasound; Dyspnea.*

INTRODUCTION

In the emergency department (ED), healthcare providers are responsible for ruling out life-threatening causes of chief complaints. Of the more than 145 million ED visits in the United States in 2016, dyspnea accounted for 2.4%, or roughly 3.4 million visits.¹ The differential diagnosis of dyspnea is broad, including both life-threatening and less urgent etiologies. Clinching the final diagnosis is guided by the clinical history, physical exam, and ancillary testing, including point-of-care ultrasound (POCUS). We discuss a case that highlights the importance of early POCUS use, specifically echocardiogram, in the ED for a patient with dyspnea.

CASE REPORT

A 48-year-old male presented to the ED with complaint of cough and worsening dyspnea on exertion (DOE). Specifically,

he was told he had an elevated D-dimer and troponin that were confirmed the day before during outpatient laboratory testing. The patient had been seen the previous day by the pulmonology clinic due to chronic cough and DOE for 11 months. At that time, he had blood work (including D-dimer and troponin) and a computed tomographic pulmonary angiogram (CTPA), which was negative for pulmonary embolism or gross cardiac abnormality, but showed bilateral ground-glass opacities consistent with pulmonary edema or pneumonitis. Specifically, the patient's CTPA results indicated a normal heart size without pericardial effusion or evidence of right heart strain, without mention of cardiomegaly or visualized cardiac thrombus. Given the abnormal labs resulted after his discharge home from the pulmonology clinic, when his D-dimer and troponin were reported as abnormal, he was called by the pulmonologist who requested return to the ED for further evaluation.

On arrival to the ED, the patient stated he was experiencing worsening DOE and mild chest pressure. He denied any radiation, pleuritic, or positional components of the pressure. He also denied any lightheadedness, syncope, diaphoresis, nausea, pain or swelling in his lower extremities, orthopnea, or paroxysmal nocturnal dyspnea.

On chart review, we learned the patient had been seen in the lower acuity area of our ED six weeks prior for his chronic cough and reported DOE. His workup included a negative chest radiograph (CXR) and computed tomography of the chest with intravenous contrast. Given the patient's lack of chest pain and previous "clean" health history, with complaint of cough, no further evaluation was completed during the initial ED presentation. With a negative workup at that time, the patient was advised to take an antihistamine for chronic sinusitis and referred to the pulmonology clinic for further evaluation. Of note, the patient was also seen by otolaryngology during the course of his symptoms and had a negative nasopharyngeal scope.

The patient had no other significant past medical or surgical history and no known drug allergies. His medications included albuterol, cetirizine, ipratropium, montelukast, omeprazole, tiotropium, prednisone, and over-the-counter testosterone supplements. Of note, these respiratory, gastric reflux, and seasonal allergy medications had only been added in recent months in attempts to treat his ongoing symptoms of cough and DOE. He denied any smoking history or recreational drug use; he did admit to consumption of three to five alcoholic beverages per day. He was employed as a commercial airline pilot and, prior to the onset of these symptoms, he was quite active and exercising daily. His family history was negative for venous thromboembolism, early cardiac disease, pulmonary disease, or aortic disease.

The patient's vital signs were significant for an oxygen saturation of 88% on room air, heart rate 108 beats per minute, and blood pressure 138/90 millimeters of mercury. On physical exam, he was a healthy appearing, middle-aged male with conversational dyspnea. Head and neck exam were largely unremarkable. Chest exam revealed rales present in the mid and lower lung fields, bilaterally. Heart exam revealed a tachycardic rate with a regular rhythm and no murmurs or gallops. Lower extremities were symmetric, non-edematous, and non-tender bilaterally. Distal pulses were intact. Skin and neurological exams were normal. Given his hypoxia and conversational dyspnea, he was placed on supplemental oxygen and a point-of-care echocardiogram was performed by the emergency physicians (EP) (Image 1 and 2, Video). POCUS revealed a dilated, globally hypokinetic left ventricle with a significantly reduced ejection fraction (EF). There was also a large, mobile, left ventricular (LV) mass initially concerning for neoplasm or thrombus. No pericardial effusion was visualized. It was evident that the EF was significantly

CPC-EM Capsule

What do we already know about this clinical entity?

Patients with cardiomyopathy and acute heart failure often present with dyspnea, a common chief complaint with the potential for morbidity and mortality.

What makes this presentation of disease reportable?

Point-of-care ultrasound (POCUS) quickly clinched the diagnosis of acute heart failure in a patient with progressive dyspnea.

What is the major learning point?

POCUS, even in the most novice physician hands, can assist in the quick identification of normal vs abnormal cardiac findings and guide further workup and treatment.

How might this improve emergency medicine practice?

POCUS is a low-risk diagnostic tool with a potentially high yield that can be used in the emergent evaluation of patients with dyspnea.

reduced, estimated to be about 30%. Of note, the attending EP was a general EP without fellowship training or focused practice in POCUS who was supervising general emergency medicine residents.

Given these findings, we discussed the case with the cardiology service. Cardiology suspected thrombus more likely than mass due to the acute, decompensated heart failure. Medical management was initiated, including a heparin infusion. The patient was admitted to the cardiology service. Upon admission, transthoracic echocardiogram (TTE) revealed an EF of 29% with a large, mobile LV mural thrombus. Coronary catheterization revealed minimal coronary artery disease. Cardiac magnetic resonance imaging showed an EF of 16%, LV mural thrombus, and evidence of LV non-compaction. The patient was ultimately diagnosed with non-ischemic dilated cardiomyopathy (DCM), of uncertain etiology. He was discharged home with a life vest, optimal medical therapy, and was advised to stop using alcohol as well as testosterone supplements. At three months post discharge he remained on medical therapy, including anticoagulation. He was found to have a persistently diminished EF of 30% without signs of LV thrombus on repeat TTE.

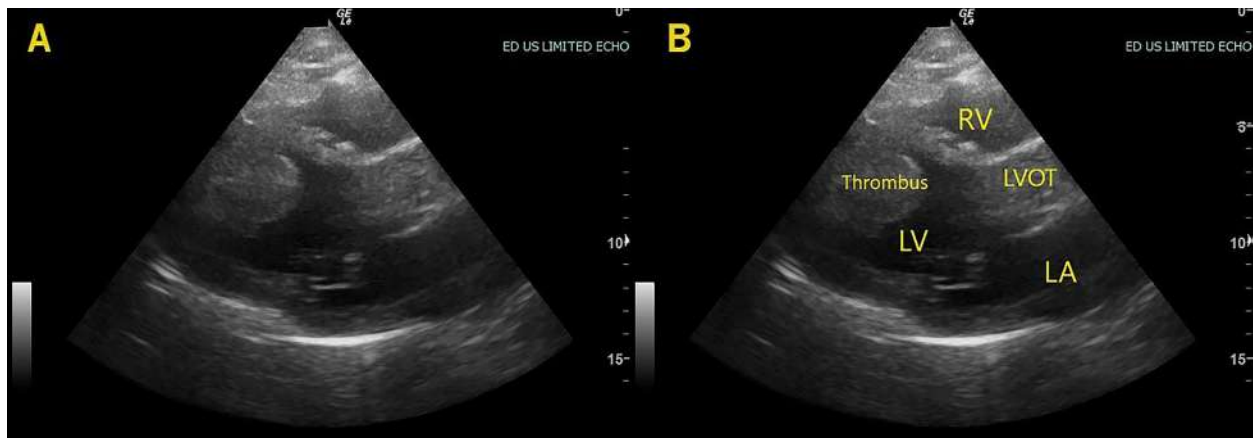


Image 1. Left ventricular thrombus, parasternal long axis. In this parasternal long-axis view, a rounded mass labeled “Thrombus” in frame B is seen in the apex of the left ventricle.

RV, right ventricle; LVOT, left ventricular outflow tract; LA, left atrium, LV, left ventricle.

DISCUSSION

This case serves to highlight the importance of the use of point-of-care echocardiography in the evaluation of dyspnea in the ED. This patient was evaluated multiple times over months by his primary care physician, emergency providers, otolaryngology, and pulmonology prior to his presentation to our ED for worsening cough and dyspnea. It was only then that he was accurately diagnosed with acute decompensated heart failure secondary to severe cardiomyopathy. Prior to his final diagnosis, his workup included CXRs, CTPA, nasopharyngeal laryngoscopy, and bronchoscopy. He had been treated for allergic rhinitis, asthma, gastroesophageal reflux disease, and chronic sinusitis with minimal to no improvement in his symptoms.

The diagnosis of heart failure in this patient, ultimately related to non-ischemic DCM, had likely not been strongly considered by previous providers. No echocardiogram had been performed and no documentation had suggested such a diagnosis on the differential. Providers were likely falsely reassured given the negative CTPA, his relatively young age, fit physical condition, and lack of other comorbidities. While he presented in acute decompensated heart failure on his second ED encounter, it is likely that he had a significantly reduced EF for some time. Had a point-of-care echocardiogram been performed earlier in his workup, it is likely there would have been a quicker final diagnosis. An earlier diagnosis may have led to earlier intervention and symptomatic improvement.^{2,3} There is some evidence that earlier recognition and initiation of therapy may slow progression of heart failure and reduce adverse events.

According to the American Heart Association, the incidence and prevalence of DCM has been challenging to predict based on multiple geographic and patient demographic variables. In most multicenter trials regarding heart failure, approximately 30-40% of patients have non-ischemic cardiomyopathy identified as the etiology.^{4,5}

Evidence continues to support that sudden cardiac death (SCD) is a leading cause of mortality worldwide, and in up to 20% of these SCD cases, non-ischemic cardiomyopathies are to blame.⁶ Therefore, physicians on the front lines caring for the undifferentiated patient must recognize the warning signs of DCM when present. While cardiomyopathy is a less common cause of DOE in younger, healthier populations, it is nonetheless essential to consider in the differential diagnosis of DOE and cough. The potential for delayed diagnosis, significant morbidity, and even mortality is significant and very impactful in otherwise young, healthy patients. Although the etiology of this patient’s cardiomyopathy was not clearly identified, risk factors seem to be moderate alcohol use and testosterone supplementation, which has been noted to be a potential impetus for cardiomyopathy.⁷

POCUS was the key to a quick diagnosis in this protracted case of dyspnea. Thus, POCUS should be an essential part of the ED workup for a patient with dyspnea, regardless of patient age or comorbidities.⁸ Previous studies have demonstrated that POCUS performed by emergency medicine residents is comparable to echocardiography performed by cardiologists.⁹ Even in the hands of a non-POCUS focused EP, it was evident upon first glance that the heart in this case was abnormal. We feel that any EP with the most basic emergency echocardiography education would have identified the “abnormal” large mass/thrombus visualized in this case. For this particular patient, point-of-care echocardiogram assisted in rapid diagnosis of a previously overlooked etiology of dyspnea and the quick development of a treatment plan.

CONCLUSION

This case emphasizes the vigilance EPs must maintain in all patients with cardiorespiratory symptoms. It is yet another illustration of the utility of POCUS to more thoroughly explore

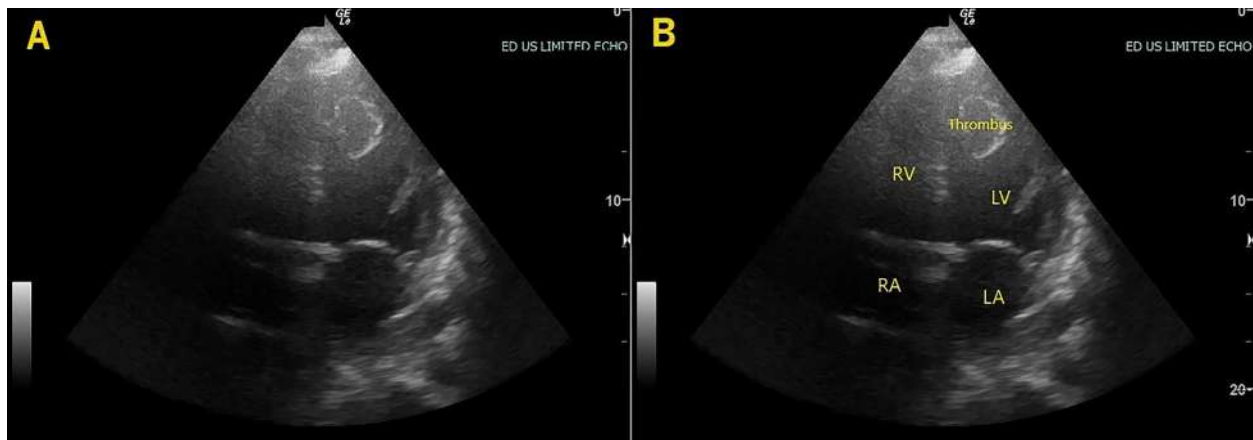


Image 2. Left ventricular thrombus, apical 4-chamber. In this apical 4-chamber view, a rounded mass labeled “Thrombus” in frame B is seen in the apex of the left ventricle (LV).
RV, right ventricle; RA, right atrium; LA, left atrium.

a broad, high-risk differential and provide a rapid, accurate diagnosis. Its early utilization in symptomatic patients should reduce diagnostic error and may lead to improved outcomes.

Video. Dilated cardiomyopathy (DCM) with left ventricular (LV) apical thrombus. In this brief, narrated video, the findings of a DCM are seen, including a dilated, globally hypokinetic LV, with poor mitral opening, as well as a rounded mobile mass in the LV apex consistent with thrombus.

The Institutional Review Board approval has been documented and filed for publication of this case report.

Address for Correspondence: Kimberly Quedado, PhD, West Virginia University, Robert C. Byrd Health Sciences Center School of Medicine, Department of Emergency Medicine, P.O. Box 9149, Morgantown, WV 26505. Email: Kimberly.quedado@hsc.wvu.edu.

Conflicts of Interest: By the CPC-EM article submission agreement, all authors are required to disclose all affiliations, funding sources and financial or management relationships that could be perceived as potential sources of bias. The authors disclosed none.

Copyright: © 2020 Moore et al. This is an open access article distributed in accordance with the terms of the Creative Commons Attribution (CC BY 4.0) License. See: <http://creativecommons.org/licenses/by/4.0/>

REFERENCES

1. Rui P, Kang K, Ashman JJ. National Hospital Ambulatory Medical Care Survey: 2016 Emergency Department Summary Tables. Available at: https://www.cdc.gov/nchs/data/ahcd/nhamcs_emergency/2016_ed_web_tables.pdf. Accessed May 6, 2020.
2. The Heart Outcomes Prevention Evaluation Study Investigators, Yusuf S, Sleight P, et al. Effects of an angiotensin-converting-enzyme inhibitor, ramipril, on cardiovascular events in high-risk patients. *N Engl J Med.* 2000;342(18):1376.
3. Vantrimpont P, Rouleau JL, Wun CC, et al. Additive Beneficial Effects of Beta-Blockers to Angiotensin-Converting Enzyme Inhibitors in the Survival and Ventricular Enlargement (SAVE) Study. SAVE Investigators. *J Am Coll Cardiol.* 1997;29(2):229-36.
4. Bozkurt B, Colvin M, Cook J, et al. Current Diagnostic and Treatment Strategies for Specific Dilated Cardiomyopathies: a scientific statement from the American Heart Association. *Circulation.* 2016;134(23):e579-646.
5. Japp AG, Gulati A, Cook SA, et al. The diagnosis and evaluation of dilated cardiomyopathy. *J Am Coll Cardiol.* 2016;67(25):2996-3010.
6. Betensky BP and Dixit S. Sudden cardiac death in patients with nonischemic cardiomyopathy. *Indian Heart J.* 2014;66(Suppl 1):S35-45.
7. Doleeb S, Kratz A, Salter M, et al. Strong Muscles, Weak Heart: Testosterone-Induced Cardiomyopathy. *ESC Heart Fail.* 2019;6(5):1000-4.
8. Minardi J, Marshall T, Massey G, et al. Focused cardiac ultrasound: uncommon but critical diagnoses made at the point of care. *J Ultrasound Med.* 2015;34(4):727-36.
9. Farsi D, Hajsadeghi S, Hajighanbari MJ, et al. Focused cardiac ultrasound (FOCUS) by emergency medicine residents in patients with suspected cardiovascular diseases. *J Ultrasound.* 2017;20(2):133-8.

A Case Report: The Challenging Diagnosis of Spontaneous Cervical Epidural Hematoma

Francis L. Counselman, MD*†
Julie M. Tondt, MD*
Harry Lustig, MD*†

*Eastern Virginia Medical School, Department of Emergency Medicine, Norfolk, Virginia
†Emergency Physicians of Tidewater, Norfolk, Virginia

Section Editor: Melanie Heniff, MD

Submission history: Submitted February 28, 2020; Revision received May 5, 2020; Accepted May 11, 2020

Electronically published July 13, 2020

Full text available through open access at http://escholarship.org/uc/uciem_cpccem

DOI: 10.5811/cpcem.2020.5.47107

Introduction: We present the case of a patient with a spontaneous cervical epidural hematoma that presented with neck pain and mild, left arm parasthesia.

Case Report: A 59-year old man presented with sudden onset of severe neck pain, without history of injury or trauma. The patient also complained of associated left arm paresthesias that progressed to left arm and leg weakness while in the emergency department. Multiple diagnoses were considered and worked up; eventually the correct diagnosis was made with magnetic resonance imaging of the cervical spine.

Conclusion: Spontaneous cervical epidural hematoma typically presents with neck pain, and variable neurologic complaints. This case illustrates the challenge in making this uncommon but serious diagnosis. [Clin Pract Cases Emerg Med. 2020;4(3):428–431.]

Keywords: *Spontaneous cervical epidural hematoma; neck pain; epidural hematoma.*

INTRODUCTION

Cervical spinal epidural hematomas can be either spontaneous or secondary to trauma, with the latter much more common. Spontaneous cervical epidural hematomas (SCEH) have been associated with bleeding disorders, vascular abnormalities, or the use of antiplatelet and anticoagulant medications. Typically, these patients present initially with neck pain, which can then progress to parasthesia and weakness as the hematoma expands and compresses the spinal cord. The presentation can easily be confused with a stroke, transient ischemic attack (TIA) or an arterial dissection. Magnetic resonance imaging (MRI) is the study of choice to identify this disease process. Our case is interesting because the only risk factor was daily aspirin 81 milligrams (mg), and the initial presentation was confusing and included a wide differential diagnosis. Only after the development of left-sided weakness was a cervical MRI ordered and the correct diagnosis made.

CASE PRESENTATION

A 59-year-old man presented to our freestanding emergency department (ED) with abrupt onset of severe, upper

back and neck pain. The patient stated he experienced sudden, severe, upper back and neck pain in the shower as he raised his arms over his head to wash his hair. He stated the pain increased with arm movement. He also complained of mild paresthesia in the left arm. He denied weakness, and there was no history of trauma, injury, or overuse. He denied fevers, chills, chest pain, shortness of breath, or headache. Past medical history was significant for hypertension, type 2 diabetes mellitus, peripheral vascular disease, and coronary artery disease. Medications included metformin 1000 mg twice each day, rosuvastatin 20 mg daily, telmisartan-hydrochlorothiazide 80-25mg daily, fenofibrate 145 mg each day, and aspirin 81mg daily. The patient stated he had quit smoking five years prior and consumed alcohol only on occasion.

The patient appeared uncomfortable secondary to pain. Physical exam revealed a pulse of 76 beats per minute, respiratory rate of 15 breaths per minute, blood pressure 156/82 millimeters of mercury, 97% oxygen saturation on room air, and he was afebrile.

The head, eyes, ears, nose, and throat exam was normal. The heart exam was normal, and auscultation of the lungs

revealed clear, bilateral breath sounds. The abdomen was soft, nontender, and without guarding or rebound. The patient exhibited tenderness in the lower cervical and upper thoracic region posteriorly, both in the midline and paraspinal region bilaterally. He described increased pain when he lowered his left arm from the abducted position. On initial neurologic examination, the patient exhibited normal strength, without sensory deficits, in all four extremities. He did complain of left arm paresthesia.

An intravenous (IV) line was established, and the patient was administered hydromorphone 0.5 mg and ondansetron 4mg IV for pain. A stat electrocardiogram revealed normal sinus rhythm, normal axis, and no evidence of ischemia or injury. Laboratory studies were sent for a complete blood count (CBC), basic metabolic profile (BMP), urinalysis, and a troponin T.

The emergency physician (EP) was concerned the patient was experiencing a dissecting thoracic aortic aneurysm and ordered a computed tomography angiography (CTA) scan of the chest, abdomen, and pelvis. The CBC was normal, and the BMP was remarkable only for a serum glucose of 355 mg per deciliter (mg/dL) (Reference: 70-99 mg/dL), with a normal serum bicarbonate. The urinalysis and troponin T were normal.

The patient returned from radiology after his chest CTA, complaining of continued pain. He received an additional hydromorphone 0.5 mg IV. While the CT was waiting to be read, change of shift occurred, and the case was turned over to the oncoming EP.

The chest CTA was interpreted as no active aortic pathology, severe coronary arteriosclerosis, and mild to moderate hepatic steatosis. Given the lack of an identifiable cause of the patient's severe pain, the oncoming EP performed his own history and physical exam. The patient now complained of new left arm and leg weakness, in addition to the left arm paresthesia. On exam, the patient had 2/5 motor strength in the left leg, and 4/5 motor strength in the left arm. He had strong pulses in all four extremities. The oncoming EP expanded the differential diagnosis to include carotid artery dissection, cerebrovascular accident, and TIA. After discussion with radiology, a low-dose CTA of the head and neck was ordered.

The CTA of the head and neck was interpreted as "no acute arterial disease identified, and no dissection of carotid artery (or any other artery). There is no acute thromboembolism or flow limiting stenosis identified." Given the negative CTA and abnormal neurologic exam, an MRI of the cervical spine, with and without contrast, was ordered. The patient required two more additional doses of hydromorphone 0.5 mg IV for pain, and was administered IV normal saline at 125 cubic centimeter per hour.

Radiology called the ED immediately after reviewing the MRI. They described a "moderate sized T1 isointense T2 hyperintense left posterolateral epidural collection, extending from the second and third cervical (C2/C3) through mid C7 level, without internal or thick peripheral enhancement." See Image. Given the history, this was

CPC-EM Capsule

What do we already know about this clinical entity?

Spontaneous cervical epidural hematoma is a rare disease process, much less common than traumatic spinal epidural hematoma. While associated with antithrombotic medications, bleeding disorders and vascular abnormalities, in a significant number of cases, the cause remains unknown.

What makes this presentation of disease reportable?

The only risk factor for our patient was the daily use of aspirin 81mg. In addition, while initially complaining only of associated parasthesias, his neurologic exam rapidly deteriorated.

What is the major learning point?

For patients complaining of neck pain and any associated neurologic symptoms, spontaneous cervical epidural hematoma should be included in the differential diagnosis. Magnetic resonance imaging is the study of choice.

How might this improve emergency medicine practice?

Timely diagnosis and appropriate treatment can help prevent devastating neurological injuries.

thought to reflect a hyperacute (less than 12 hours old) cervical epidural hematoma.

The EP immediately consulted neurosurgery at a nearby hospital for transfer and admission. The patient was accepted by neurosurgery and transported via air ambulance to the receiving hospital. The patient's neurologic exam remained unchanged, with the noted left-sided weakness. Coagulation studies were ordered prior to taking the patient to the operating room (OR). The protime, international normalized ratio and partial thromboplastin time were all normal. However, the platelet function assay was elevated, thought to be secondary to the patient's daily aspirin use. The patient was transfused one unit of platelets IV and taken to the OR where he underwent a left C3-C6 hemilaminectomy for evacuation and drainage of the epidural hematoma. During the surgery, they found a sizable, left epidural hematoma causing spinal cord and nerve root compression from C3 through C6, on the left side only.

The postoperative course was uneventful. The paresthesia resolved, and the patient gradually regained his strength. He was

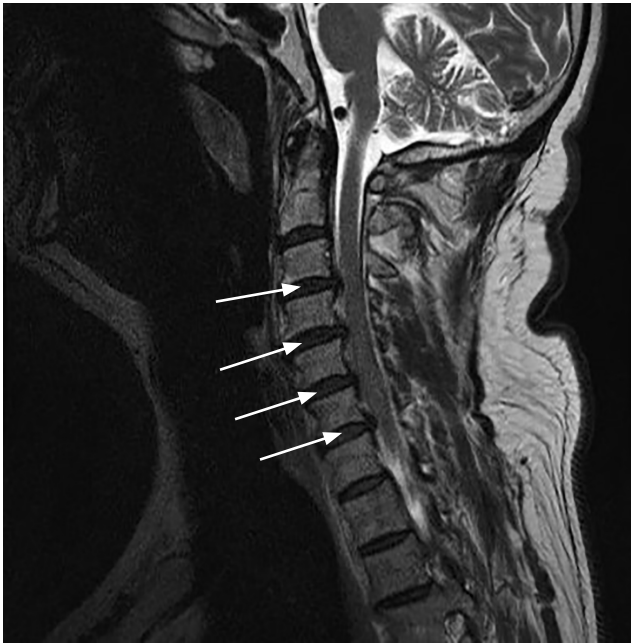

Image. Epidural hematoma in left posterolateral spinal canal extending from mid C3 to mid C7 level (arrows). The fluid displaces the cord anteromedially and there is multilevel deformity.

discharged on postop day six, with a hard cervical collar. He was seen in follow-up eight days later with a completely normal neurologic exam.

DISCUSSION

Cervical spinal epidural hematomas are an uncommon neurologic emergency that can broadly be categorized as either spontaneous or traumatic. Spontaneous spinal epidural hematomas were first described in the literature in 1869 by Jackson, and have since been reported to have an incidence of 1 per 100,000 people per year and represents 0.3-0.9% of all spinal cord lesions.^{1,2} In comparison, traumatic spinal epidural hematomas have been reported to occur in 0.5-1.7% of all spinal injuries.³ Spinal epidural hematomas occur within the epidural space, similarly to those occurring within the cranium, and cause compression on the vasculature and cord within the spinal canal.

SCEH have been attributed to various causes, including bleeding disorders, antithrombotic medications, or vascular abnormalities.^{4,5} Aspirin, warfarin, rivaroxaban, and dabigatran are a few of the antithrombotic (antiplatelet, anticoagulant) medications reported to have been used by patients ultimately diagnosed with SCEH. Emamhadi et al described a case of a 77-year-old woman on aspirin and antihypertensive medications (similar to our patient) who presented with left hemiparesis and was subsequently found to have a SCEH at the level of C3 through first thoracic (T1).⁶ Approximately, 25-70% of patients diagnosed with spontaneous spinal epidural hematomas have been reported to be taking an anticoagulant medication.⁷ In contrast to the cases

discussed above, Salehpour et al reported a case in 2018 of a 31-year-old male diagnosed with SCEH who was without significant past medical history or use of antithrombotic medications.⁸ Although various causes have been attributed to SCEH, including the use of antithrombotic medications, in as many as 40-50% of the cases the exact cause remains unknown.^{2,9} It is likely that the daily low-dose aspirin played a role in our patient.

SCEH are a dynamic process that often begin with localized neck pain as blood collects in the epidural space, and can progress to paresthesia, paraplegia, quadriplegia, or hemiparesis as the hematoma expands and subsequently compresses the spinal cord.^{2,9} This is the same progression we witnessed in our patient. Taha et al described a 41-year-old man diagnosed with SCEH who presented with six days of neck pain radiating to both upper extremities that subsequently progressed to quadriparesis and urinary urgency.⁴ Further complicating the clinical picture of SCEH, Hongo et al described two case reports of elderly Japanese men diagnosed with SCEH who presented with sudden onset of ataxic gait, rather than the more commonly described neck pain and associated progressive neurologic deficits.¹⁰

EPs are often challenged to identify patients with a SCEH who have a presentation that may mimic other, more common diagnoses, such as TIA or acute ischemic stroke.^{9,11,12} The misdiagnosis of a SCEH as a TIA or ischemic stroke could lead to the patient receiving antithrombotic medications, which could worsen the hematoma expansion and, ultimately, adversely affect the patient's morbidity and mortality. In just such a situation, Morimoto et al described 71-year-old male who presented with sudden onset of neck pain and left hemiparesis, who received tissue plasminogen activator for suspected ischemic stroke, with subsequent worsening in neurologic function. The patient was ultimately diagnosed with SCEH on further work-up and imaging.¹³

MRI of the spine is the imaging modality of choice for identifying a SCEH.^{6,14} According to Matsumura et al, the hematoma appears on MRI as an isointense signal on T1-weighted images within 24 hours of symptom onset and as a hyperintense signal on T2-weighted images after 36 hours.¹⁴ Obtaining a stat MRI of the cervical spine shortly after patient arrival to the ED may prove to be difficult depending on resource availability; however, the information provided is invaluable for the diagnosis and guidance of surgical intervention.

Emergency surgical intervention is recommended as the primary treatment for SCEH, given concern for possible irreversible and permanent neurologic damage.^{12,15} A retrospective review of 35 cases of spontaneous spinal epidural hematoma by Liao et al reported that patients who presented with less severity or duration of neurologic deficits had better neurologic outcomes after surgical intervention.¹⁵ Our patient did extremely well, with no residual neurologic deficits following surgical intervention.

CONCLUSION

Spontaneous cervical epidural hematoma is an uncommon yet “cannot miss” neurologic emergency that EPs should consider in the differential diagnosis for patients presenting with acute neck pain, with or without signs of cord compression.

The authors attest that their institution requires neither Institutional Review Board approval, nor patient consent for publication of this case report. Documentation on file.

Address for Correspondence: Francis L. Counselman, MD, Eastern Virginia Medical School, Department of Emergency Medicine, 600 Gresham Drive, Raleigh Building, Room 304, Norfolk, VA 23507. Email: counselfl@evms.edu.

Conflicts of Interest: By the CPC-EM article submission agreement, all authors are required to disclose all affiliations, funding sources and financial or management relationships that could be perceived as potential sources of bias. The authors disclosed none.

Copyright: © 2020 Counselman et al. This is an open access article distributed in accordance with the terms of the Creative Commons Attribution (CC BY 4.0) License. See: <http://creativecommons.org/licenses/by/4.0/>

REFERENCES

- Baek BS, Hur JW, Kwon KY, et al. Spontaneous spinal epidural hematoma. *J Korean Neurosurg Soc.* 2008;44(1):40-2.
- Gomes PA, Cernadas E, Sá J, et al. Spontaneous spinal haemorrhage as a complication of oral anticoagulant therapy: a case report and literature review. *Eur J Case Rep Intern Med.* 2018;5(12):000887.
- Brichko L, Giddey B, Tee J, et al. Cervical spine traumatic epidural haematomas: incidence and characteristics. *Emerg Med Australasia.* 2018;30(3):359-65.
- Taha MM, Elsharkawy AM, Al Menshawy HA, et al. Spontaneous cervical epidural hematoma: a case report and review of literature. *Surg Neurol Int.* 2019;10(247):1-3.
- Tawk C, El Hajj Moussa M, Zgheib R, et al. Spontaneous epidural hematoma of the spine associated with oral anticoagulants: 3 case studies. *Int J Surg Case Rep.* 2015;13:8-11.
- Emamhadi M, Ghadarjani S, Alijani B, et al. Spontaneous cervical epidural hematoma with stroke manifestations. *Asian J Neurosurg.* 2019;14(1):286-8.
- Kirazli Y, Akkoc Y, Kanyilmaz S. Spinal epidural hematoma associated with oral anticoagulation therapy. *Am J Physical Med Rehabil.* 2004;83(3):220-3.
- Salehpour F, Mirzaei F, Kazemzadeh M, et al. Spontaneous epidural hematoma of cervical spine. *Int J Spine Surg.* 2018;12(1):26-9.
- Tiryaki M, Basaran R, Aydin SO, et al. Spontaneous cervical epidural hematoma with hemiparesis mimicking cerebral stroke. *Case Rep Emerg Med.* 2014;2014:210146.
- Hongo T, Iseda K, Tsuchiya M, et al. Two cases of spontaneous cervical epidural hematoma without back or neck pain in elderly Japanese men. *Acute Med Surg.* 2017;5(2):181-4.
- Pavličević G, Lepić M, Lepić T, et al. A spontaneous cervical epidural hematoma mimicking a stroke: a challenging case. *J Emerg Med.* 2019;57(1):70-3.
- Li C, He R, Li X, et al. Spontaneous spinal epidural hematoma mimicking transient ischemic attack. *Medicine (Baltimore).* 2017;96(49):e9007.
- Morimoto T, Yoshihara T, Yakushiji Y, et al. Worsening cervical epidural hematoma after tissue plasminogen activator administration for stroke-like symptoms. *Spine.* 2016;41(7):E437-40.
- Matsumura A, Namikawa T, Hashimoto R, et al. Clinical management for spontaneous spinal epidural hematoma: diagnosis and treatment. *The Spine Journal.* 2008;8(3):534-7.
- Liao CC, Lee ST, Hsu WC, et al. Experience in the surgical management of spontaneous spinal epidural hematoma. *J Neurosurg Spine.* 2004;100(1):38-45.

Atypical Cause of Sepsis from Bilateral Iliopsoas Abscesses Seeded from Self-mutilation: A Case Report

Sam Langberg, MD*†
Shayan Azizi, MS-IV*

*University of Queensland School of Medicine, Ochsner Clinical School, Department of Emergency Medicine, New Orleans, Louisiana
†Ochsner Health System, Department of Emergency Medicine, Division of Emergency Ultrasound, New Orleans, Louisiana

Section Editor: Scott Goldstein, MD

Submission history: Submitted February 19, 2020; Revision received May 6, 2020; Accepted May 7, 2020

Electronically published July 7, 2020

Full text available through open access at http://escholarship.org/uc/uciem_cpccem

DOI: 10.5811/cpcem.2020.5.47020

Introduction: An iliopsoas abscess (IPA) is an abscess located adjacent to the iliopsoas and iliacus muscles. Although rare, their variable clinical presentations often lead to a delay in diagnosis.

Case report: We present a case of sepsis secondary to multiple IPAs that was missed despite multiple healthcare encounters. The patient had no classical risk factors for an IPA, and the abscesses were found to be seeded via hematogenous spread from self-inflicted cutting.

Conclusion: This case illustrates the importance of obtaining a complete history, including psychiatric screen, and performing a thorough examination when evaluating patients with low back pain to rule out overlooked sources of bacteremia. [Clin Pract Cases Emerg Med. 2020;4(3):432–435.]

Keywords: *abscess; sepsis; iliopsoas abscess; self-mutilation.*

INTRODUCTION

An iliopsoas abscess (IPA) is an abscess located adjacent to the iliopsoas and iliacus muscles. An IPA can be classified as a primary abscess resulting from hematogenous spread of bacteria via the blood supply of the iliopsoas musculature, or a secondary abscess formed directly by adjacent infectious processes.¹ It is a rare condition, with an annual incidence rate of 0.4 cases per 100,000 persons, but its true incidence is felt to be underdiagnosed and under-reported due to its vague presentation leading to delays in diagnosis and resulting increases in morbidity and mortality.^{2,3}

The classic triad of fever, flank pain, and limitation of hip movement are only present in 30% of cases, and diagnosis remains a challenge because iliopsoas abscesses more commonly present with low-grade pyrexia, body aches, malaise, or non-specific abdominal or hip pain.³ Due to the complexity and variability in presentation, diagnosis typically depends on having a high clinical index of suspicion. If suspected, it is imperative to investigate in order to avoid mortality rates of 2.4% and 18.9% of primary and secondary

IPAs, respectively.¹ IPAs should be investigated with blood cultures and inflammatory markers, along with ruling out other sites of infection; however, laboratory studies are non-specific, and diagnosis ultimately relies on imaging with ultrasound, computed tomography (CT), or magnetic resonance imaging (MRI). Once diagnosed, treatment typically begins with empiric antibiotics, followed by percutaneous drainage.^{1,4}

CASE REPORT

A 19-year-old woman with a past medical history of schizoaffective disorder presented to the emergency department (ED) with a one-week history of left hip pain and chills. Pain was worsened with hip flexion and described as “searing” while sitting. She saw an orthopedic surgeon at the onset of the hip pain and was diagnosed with left hip bursitis. She was prescribed a course of prednisone and cyclobenzaprine. Despite use of the prednisone, she reported no improvement in symptoms. She also reported low-grade fever, poor appetite, polydipsia, fatigue, diarrhea, and insomnia. The patient had a history of cutting, but it

had been over two months since she had last cut her forearms. This history was affirmed by the patient's mother at bedside.

On initial ED presentation, the patient had a temperature of 36.8° Celsius, blood pressure of 115/59 millimeters of mercury (mm Hg), heart rate of 119 beats per minute (bpm), respiratory rate of 18 breaths per minute (breaths/min), and pulse oximetry measured 98% on room air. Physical examination was remarkable for left lumbar paraspinal tenderness. There was good range of motion of the left hip, with minimal pain on internal rotation and extension. There were multiple, self-inflicted, superficial lacerations in various stages of healing on her bilateral wrists. Serum laboratory studies were significant for a leukocytosis of 21.32 thousands per microliter (K/uL) (Reference [Ref]: 3.90-12.80 K/uL) and hyponatremia of 130 millimoles per liter (mmol/L) (Ref: 136-145 mmol/L), otherwise without significant abnormalities. A urinalysis was clear. Abdominal radiographs were normal. The leukocytosis and insomnia were attributed to the recent course of prednisone. She received a non-steroidal anti-inflammatory medication and was discharged home.

Three days later, she returned to her primary care doctor with worsening hip pain, fever, and lightheadedness. She was noted to be hypotensive with a blood pressure of 78/45 mm Hg. She was referred back to the ED. On her second ED visit, and fourth healthcare encounter since the onset of symptoms, she was noted to be febrile, with a temperature of 39.4° C, tachycardic, with a heart rate of 118 bpm, a blood pressure of 104/57 mm Hg, a respiratory rate of 18 breaths/min, and pulse oximetry measured 99% on room air. Examination revealed persistent left lumbar paraspinal tenderness with no midline spinal tenderness, and no rigidity to range of motion of hip. Laboratory studies revealed a worsening leukocytosis of 22.2 K/uL (Ref: 3.90-12.80 K/uL), an erythrocyte sedimentation rate (ESR) of >120 millimeters per hour (mm/hr) (Ref: 0-36 mm/hr), and a C-reactive protein (CRP) of 478.2 milligrams per liter (mg/L) (Ref: 0.0-8.2 mg/L).

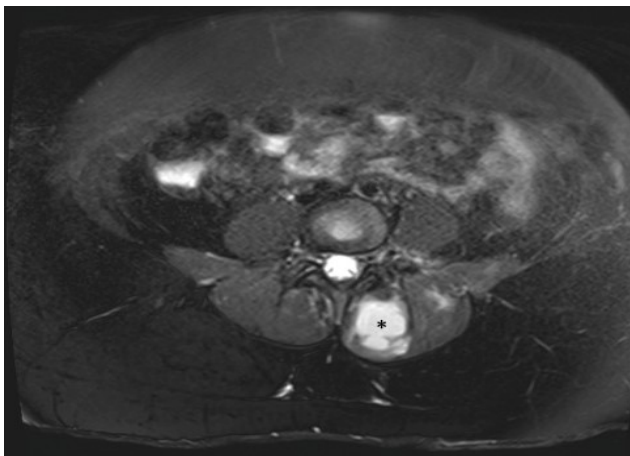


Image 1. Axial T-2 weighted magnetic resonance imaging pelvis revealing a 3.4 x 3.2 x 7.9 centimeter abscess involving the left paraspinal muscle (*).

CPC-EM Capsule

What do we already know about this clinical entity?

An iliopsoas abscess (IPA) is a rare pathologic entity with significant morbidity. The varied clinical presentations often lead to a delay in diagnosis.

What makes this presentation of disease reportable?

We present a case of sepsis secondary to IPAs seeded from self-mutilation that was missed on multiple health care encounters because the patient had none of the classic risk factors for IPAs.

What is the major learning point?

Providers should be suspicious for bacteremia or IPA in patients with a psychiatric history, or a history of self-mutilation, if presenting with fevers and pain in the back, abdomen, or hip.

How might this improve emergency medicine practice?

Given their variable presentation, providers may suspect and recognize an IPA earlier in a patient without classical risk factors for this disease process.

Pelvic MRI was obtained, which revealed multiple bilateral IPAs (Image 1). A 3.6 x 8.5 x 10.6 centimeter (cm) abscess on her left iliacus involving her sacroiliac joint, a 3.4 x 3.2 x 7.9 cm abscess involving her left paraspinal muscle, and a right iliac abscess measuring 1.5 x 2.4 x 3.6 cm. She received broad-spectrum antibiotic coverage with vancomycin and piperacillin-tazobactam. Interventional radiology performed CT-guided aspiration with drain placement of the two larger, left-sided abscesses. Both blood and abscess cultures returned positive with methicillin-resistant *Staphylococcus aureus* (MRSA). Throughout her hospitalization, her white blood cell count continued to trend upward, and a CT revealed enlargement of the right iliacus abscess (Image 2). Interventional radiology subsequently performed a percutaneous aspiration of the abscess. She was discharged on hospital day 10 on parenteral vancomycin via a peripherally inserted central catheter line.

One month after discharge, the patient returned to the ED, reporting worsening back pain. Repeat MRI revealed persistence of left iliopsoas abscess measuring 3.2 x 1.3 cm, which now extended into the left iliac bone consistent with sacroiliitis/osteomyelitis (Image 3). She was evaluated by both interventional radiology and orthopedics consults who felt that the fluid collection was too small for aspiration or drain placement. Infectious diseases consult evaluated the

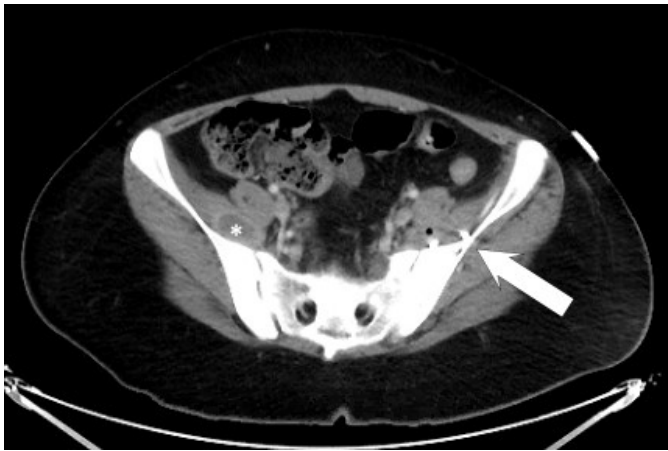


Image 2. Computed tomography of the abdomen and pelvis with intravenous contrast revealing a 2.7 centimeter (cm) abscess of right iliacus muscle (*). This had increased in size from 1.6 cm on initial magnetic resonance imaging. Note pigtail catheter (arrow) from drainage of left-sided iliopsoas abscess.

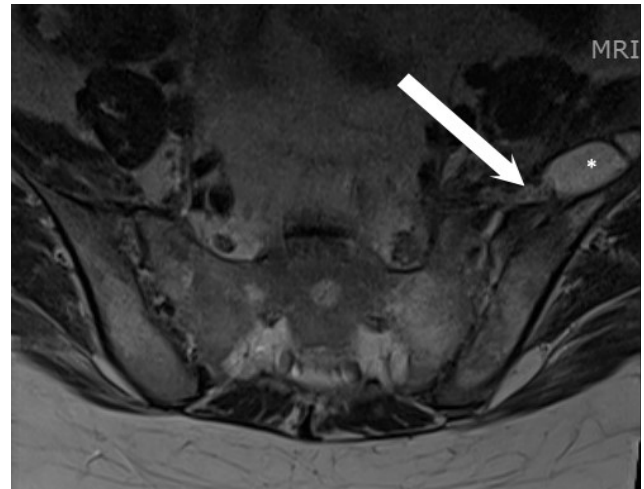


Image 3. Axial T-2 weighted magnetic resonance imaging of lumbar spine after four weeks showing a recurrent abscess (*) measuring 3.2 x 1.3 centimeters. The lateral aspect of this collection extends beyond the field of view. The medial aspect of this collection appears continuous with the left sacroiliac joint (arrow), concerning for sacroiliitis and possible involvement of the left iliac bone, although incompletely characterized on this study.

patient and recommended a six-week course of intravenous (IV) daptomycin. As an outpatient, antibiotics were adjusted to oral doxycycline. Follow-up MRI two months after discharge revealed resolution of abscess with residual inflammatory edema.

DISCUSSION

This case illustrates the high degree of morbidity from the misdiagnosis of a case of a primary IPA. This patient unfortunately experienced 93 days between her first ED visit to the resolution of her infection. Primary IPAs exist in the setting of bacteremia, whereas secondary IPAs may progress to bacteremia and sepsis. The high vascularity within the iliopsoas musculature, predisposes to the seeding of an abscess. This case may have been initially misdiagnosed because the patient had none of the classic risk factors for IPAs, such as IV drug use, immunodeficiencies, or inflammatory bowel disease where the risk of hematogenous seeding of bacteria is higher. The most common cause of a secondary IPA is Crohn's disease, followed by appendicitis, diverticulitis, ulcerative colitis, osteomyelitis, neoplasm, disk infections, renal infections, and trauma.⁵ With none of the traditional risk factors for iliopsoas abscess, obtaining a focused psychiatric history to screen for self-harm could have given clues to the source of bacteremia and abscess formation.

Staphylococcus aureus is the most predominant organism cultured from IPAs.¹ Other common pathogens cultured are species found on the skin or in the gastrointestinal tract, such as *Staphylococcus*, *Streptococcus*, *Escherichia coli*, and enterococcus, but often are polymicrobial.¹ An IPA enlarges and creates mass effect on the adjacent iliopsoas and iliacus muscles. This will typically present with pain and swelling in the region irritating the hip extensors, leading to a limp and a

positive psoas sign. However, the classic triad of decreased hip movement, flank pain, and fever may only be present in 30% of patients.⁶ There are cases in the literature of IPA presenting as exclusively fever and thigh pain.^{1,7}

If there is suspicion for an IPA, serum laboratory studies such as an elevated white blood cell count, ESR, or CRP, are non-specific, and diagnosis requires imaging. IPAs may be identified on ultrasound, CT, or MRI. CT with contrast is frequently the initial imaging study given the feasibility and speed of CTs, but MRI is considered superior because of better discrimination of the soft tissues and the ability to visualize the abscess wall and surrounding structures without the need of an IV contrast medium.⁸

Even with treatment, primary and secondary IPAs have a mortality rate of 2.4% and 19%, respectively.¹ Literature suggests that an untreated IPA may reach a mortality rate of up to 100%.¹ Treatment and management of an IPA begins with empiric, broad-spectrum antibiotics for polymicrobial coverage, followed by percutaneous drainage.^{1,4} Open surgical drainage may be required for IPAs in the setting of Crohn's disease because of the potential for abscesses to be connected via a fistula to the intestine, or in abscesses with multiple septae.⁹ Antibiotics are eventually tailored toward culture results. There is some literature suggesting that antibiotics alone may be adequate in abscesses smaller than 3 cm in greatest diameter.¹⁰

The literature describes a number of other unorthodox etiologies of IPAs. Tuberculosis has been known to seed as IPAs and may be suspected in patients with human immunodeficiency virus.¹¹ In a case in India, the rare gram-negative organism, melioidosis, was cultured from an IPA.¹² There have been cases of MRSA retroperitoneal infections

attributed to infected skin lesions as a port of entry.¹³ However, on our review of the literature, this is the first case that describes an IPA as a result of self-mutilation.

CONCLUSION

This case describes an atypical etiology of an IPA in a young patient with no classic risk factors, leading to a delay in diagnosis and treatment. Bacteremia is not exclusive to patients with a history of diabetes, immunosuppression, or IV drug use. In patients with a psychiatric history or a history of self-mutilation, providers should keep a level of suspicion for bacteremia or IPA in patients presenting with fevers and pain in the back, abdomen, or hip.

The authors attest that their institution requires neither Institutional Review Board approval, nor patient consent for publication of this case report. Documentation on file.

Address for Correspondence: Sam Langberg, MD, University of Queensland School of Medicine, Department of Emergency Medicine, 1401 Jefferson Highway, New Orleans, LA 70121. Email: Sam.Langberg@ochsner.org.

Conflicts of Interest: By the *CPC-EM* article submission agreement, all authors are required to disclose all affiliations, funding sources and financial or management relationships that could be perceived as potential sources of bias. The authors disclosed none.

Copyright: © 2020 Langberg et al. This is an open access article distributed in accordance with the terms of the Creative Commons Attribution ([CC BY 4.0](http://creativecommons.org/licenses/by/4.0/)) License. See: <http://creativecommons.org/licenses/by/4.0/>

REFERENCES

1. Ricci MA, Rose FB, Meyer KK. Pyogenic psoas abscess: worldwide variations in etiology. *World J Surg.* 1986;10(5):834-42.
2. Bartolo DC, Ebbs SR, Cooper MJ. Psoas abscess in Bristol: a 10-year review. *Int J Colorectal Dis.* 1987;2(2):72-6.
3. Garner JP, Meiring PD, Ravi K, et al. Psoas abscess – not as rare as we think? *Colorectal Dis.* 2007;9(3):269-74.
4. Dinç H, Onder C, Turhan AU, et al. Percutaneous catheter drainage of tuberculous and nontuberculous psoas abscesses. *Eur J Radiol.* 1996;23(2):130-4.
5. Agrawal SN, Dwivedi AJ, Khan M. Primary psoas abscess. *Dig Dis Sci.* 2002;47(9):2103-5.
6. Chern CH, Hu SC, Kao WF. Psoas abscess: making an early diagnosis in the ED. *Am J Emerg Med.* 1997;15(1):83-8.
7. Xu BY, Vasanwala FF, Low SG. A case report of an atypical presentations of pyogenic iliopsoas abscess. *BMC Infect Dis.* 2019;19(1):58.
8. Mallick IH, Thoufeeq MH, Rajendran TP. Iliopsoas abscesses. *Postgrad Med J.* 2004;80(946):459-62.
9. Navarro López V, Ramos JM, Meseguer V, et al. Microbiology and outcome of iliopsoas abscess in 124 patients. *Medicine (Baltimore).* 2009;88(2):120-30.
10. Yacoub WN, Sohn HJ, Chan S. Psoas abscess rarely requires surgical intervention. *Am J Surg.* 2008;196(2):223-7.
11. Wong-Taylor L, Scott AJ, Burgen J. Massive TB psoas abscess. *BMJ Case Rep.* 2013;2013:1-2.
12. Janardanan P, Easaw PC, Rahiman A. An unusual case of melioidosis with psoas abscess. *Glob J Medical Clin Case Rep.* 2017;4(1):015-7.
13. Abreu DA, Osorio F, Guido LG, et al. Retroperitoneal infectious by community acquired methicillin resistant *Staphylococcus aureus*. *J Urol.* 2008;179(1):172-6.

A Case Report of a Migrated Pelvic Coil Causing Pulmonary Infarct in an Adult Female

Angel Guerrero, MD
Rebecca G. Theophanous, MD

Duke University Medical Center, Department of Surgery, Division of Emergency Medicine, Durham, North Carolina

Section Editor: Christopher Sampson, MD

Submission history: Submitted March 28, 2020; Revision received May 14, 2020; Accepted May 20, 2020

Electronically published July 9, 2020

Full text available through open access at http://escholarship.org/uc/uciem_cpchem

DOI: 10.5811/cpchem.2020.5.47463

Introduction: It is possible but rare for a pelvic coil to migrate to the pulmonary vasculature, which can cause cardiac damage, arrhythmias, pulmonary infarct, and thrombophlebitis. The few cases reported typically do not describe removal of the coils, as patients were asymptomatic.

Case report: A 39-year-old female with recent coil embolization of her left internal iliac and ovarian veins for pelvic congestion syndrome presented with one month of right-sided chest pain and dyspnea. Imaging revealed a migrated pelvic coil in the patient's right main pulmonary artery with pulmonary infarcts and a pleural effusion.

Conclusion: Interventional radiology successfully removed the coil endovascularly, with significant symptom improvement. This prevented a more-invasive open surgical procedure and resolved symptoms without requiring long-term anticoagulation or monitoring. [Clin Pract Cases Emerg Med. 2020;4(3):436–439.]

Keywords: *Migrated coil; pelvic congestion syndrome; pulmonary infarct.*

INTRODUCTION

Pelvic congestion syndrome is chronic pelvic pain caused by gonadal vein varicosities, worsened by prolonged standing, sexual intercourse, menstruation, or pregnancy. Multiparous women of reproductive age are at increased risk, and the overall prevalence is about 30%.¹ Venogram is the diagnostic gold standard, and potential treatments include hormone therapy, vasoconstrictive medications, or pelvic coil embolization.^{1,2} It is possible but rare for a pelvic coil to migrate to the pulmonary vasculature, and the few cases reported typically do not describe removal of the coils, as patients were asymptomatic.^{3,4} We present an adult female with pelvic congestion syndrome status post coil embolization with chest pain and dyspnea, found to have a migrated pelvic coil in her right pulmonary artery.

CASE REPORT

A 39-year-old female with pelvic congestion syndrome had undergone coil embolization of the left internal iliac

and ovarian veins three months earlier. For the prior month, the patient endorsed right-sided pleuritic chest pain and dyspnea with orthopnea. Differential diagnosis included a viral or bacterial pulmonary infection, pulmonary embolism, acute coronary syndrome, pericarditis, and less likely pneumothorax, aortic dissection, or congestive heart failure. Outpatient chest radiograph (CXR) demonstrated an ectopic coil in the right pulmonary vasculature, with a second coil still in place in the left ovarian vein on subsequent abdominal radiograph.

On emergency department evaluation, the patient had normal vitals including 100% oxygen saturation on room air with a respiratory rate of 18 breaths per minute, clear breath sounds, and no leg edema. Labs were unremarkable. Electrocardiogram demonstrated normal sinus rhythm at 84 beats per minute. CXR and computed tomography (CT) imaging revealed an ectopic pelvic coil in the right main pulmonary artery extending into multiple upper and lower lobe segmental branches (Image 1).

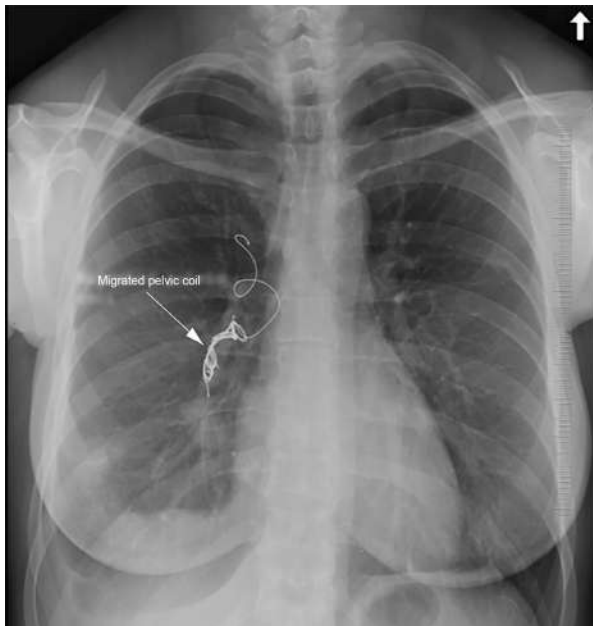

Image 1. Posteroanterior chest radiography showing a migrated pelvic coil (arrow) in the right pulmonary artery extending into segmental branches.

Coil artifact somewhat limited the identification of thrombus, but there were peripheral wedge-shaped opacities in the right middle and lower lobes concerning for infarcts and a small right pleural effusion (Image 2). There was no evidence of right heart strain on CT.

Following consultation with vascular surgery, it was decided that vascular interventional radiology (VIR) would be the least invasive yet most likely successful method for coil retrieval when compared to an open surgical approach. The patient was consented and transported directly to VIR, where the groin was prepped in standard fashion. The right common femoral vein was accessed with a micropuncture kit using ultrasound guidance. A pulmonary angiography catheter was advanced over a guidewire into the right main pulmonary artery via a 7 French sheath. Contrast phase did not show significant clot within the artery.

The sheath was exchanged for a long 7 French sheath with the tip in the right pulmonary artery. Multiple snares were passed through the sheath to engage the 20-millimeter (mm) Nester coil pack (Cook Medical, Bloomington, IN); however, the coil unraveled into small pieces, until eventually a large piece was snared and retracted to the right femoral vein. Interventional radiology then performed en bloc removal through the right groin access site given the coil was too large to pass through the sheath; however, a piece of coil remained in the right femoral vein (Image 3). Multiple attempts to snare the coil via an upsized 11 French sheath were still unsuccessful.

Similarly, the left femoral vein was accessed and upsized to a 9 French sheath, which finally allowed for successful snare removal of the remaining coil. Repeat imaging showed a small

CPC-EM Capsule

What do we already know about this clinical entity?
The migration of endovascular coils is a relatively rare complication, with few cases reported in patients with pelvic congestion syndrome.

What makes this presentation of disease reportable?
Endovascular retrieval is a less invasive treatment modality compared to surgery with fewer risks and decreased recovery time.

What is the major learning point?
Emergency clinicians should be able to recognize, stabilize, and initiate treatment for complications of surgical procedures including coil embolization.

How might this improve emergency medicine practice?
Endovascular retrieval can be a safe intervention, resulting in symptom resolution without the requirement of long-term anticoagulation or monitoring.

residual coil fragment in the right mid-lung that was deemed not to cause increased injury, thus was left in situ. An intact, 16mm Nester coil pack was noted in the left gonadal vein.

The patient was observed in the hospital overnight and went home the following day without anticoagulation or other

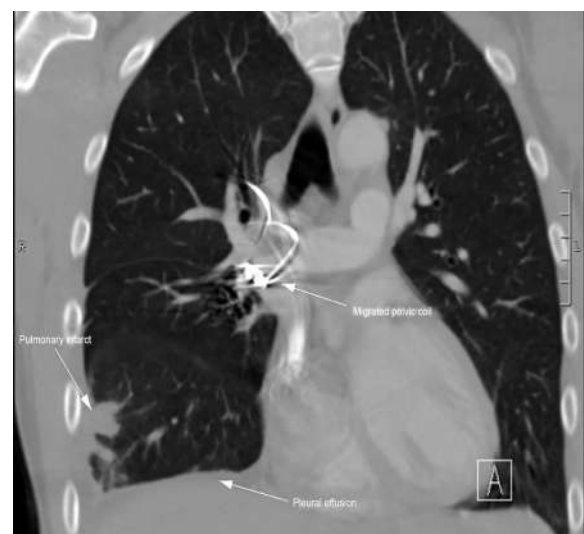

Image 2. Computed tomography imaging showing a migrated pelvic coil (mid-image arrow) in the right pulmonary artery with areas of pulmonary infarct in the right middle and lower lobes and a small right pleural effusion (left and lower arrows).

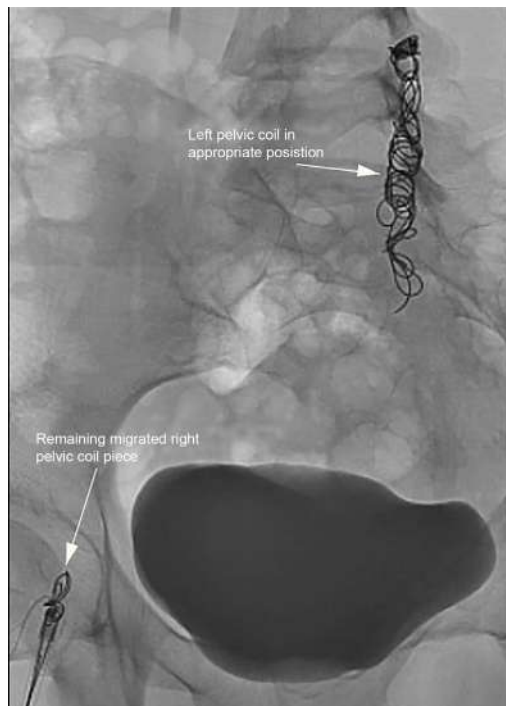


Image 3. Fluoroscopy demonstrating a piece of migrated pelvic coil from the right lung now in the right femoral vein (lower arrow), as well as the remaining pelvic coil in place in the left ovarian vein (upper arrow).

acute complications. The patient followed up with vascular surgery clinic several months later for recommendations on her remaining gonadal vein coil with no additional interventions.

DISCUSSION

Coil embolization has been used since demonstrating efficacy in arterial occlusion in 1975 and in the treatment of pelvic congestion syndrome since first described by Edwards et al in 1993.^{2,3} Current literature reports high symptomatic improvement rates of 70-85% for percutaneous vein embolization, whereas pharmacotherapy has had poor success in achieving pain relief.³ Surgical ligation is another effective treatment but is much more invasive.¹

Complications of pelvic embolization include vein perforation and coil migration (either immediate or delayed) causing cardiac damage, arrhythmias, pulmonary infarct, and thrombophlebitis, with rates ranging from 4-8%.⁴⁻⁶ Few cases have been reported regarding migration of pelvic coils to the pulmonary vasculature, and rarely with symptomatic patients requiring endovascular retrieval of the coils.^{7,8}

Yamasaki et al described migration of nine internal iliac vein coils to the pulmonary artery, but the coils were not removed as the patient was asymptomatic. They, along with other studies, postulated that coils should be at least 30-50% the diameter of the target vessel in order to decrease migration risk. They also describe using coils with a stronger radial force, for example measuring 0.035 inch, as veins have lower frictional

resistance (increased elasticity) between the vessel wall and the coils. Furthermore, larger vessels with a high-flow state (such as the internal iliac, as in our patient), are at higher risk for coil migration, especially when the varices are relieved and flow is increased.⁹ Tonkin et al described two cases of coil migration to the tricuspid valve and pulmonary arteries with a coil fragment in the right ventricle, which were asymptomatic and conservatively managed.¹⁰

None of these cases include removal of the coils nor the methods behind the retrieval process. Our patient developed pulmonary infarcts and a pleural effusion, which has not been previously reported, and thus necessitated urgent removal of the migrated coil, as we have described above. Although there were difficulties with VIR removal of the coil, this still prevented the patient from undergoing an open surgical procedure, which could have led to prolonged recovery time, longer hospital stay, and other post-operative complications such as non-healing wounds, infection, hemorrhage, pulmonary embolism, etc. Our patient had complete resolution of her symptoms and no additional complications on follow-up.

CONCLUSION

The migration of endovascular coils is a relatively rare complication, with few cases reported in patients with pelvic congestion syndrome. Additionally, the coil retrieval process has not been well described. Careful history should be obtained in patients presenting with chest pain or shortness of breath, including recent procedures. Plain film imaging is a rapid and useful tool to easily assess for coil migration. Endovascular retrieval of the migrated coil was a successful and safe intervention in this patient, resulting in symptom resolution without the requirement of long-term anticoagulation or monitoring.

The authors attest that their institution requires neither Institutional Review Board approval, nor patient consent for publication of this case report. Documentation on file.

Address for Correspondence: Rebecca G. Theophanous, MD, Duke University Medical Center, Department of Surgery, Division of Emergency Medicine, 2301 Erwin Road, Durham, NC 27710. Email: rebecca.theophanous@duke.edu.

Conflicts of Interest: By the CPC-EM article submission agreement, all authors are required to disclose all affiliations, funding sources and financial or management relationships that could be perceived as potential sources of bias. The authors disclosed none.

Copyright: © 2020 Guerrero et al. This is an open access article distributed in accordance with the terms of the Creative Commons Attribution (CC BY 4.0) License. See: <http://creativecommons.org/licenses/by/4.0/>

REFERENCES

1. Ignacio EA, Dua R, Sarin S, et al. Pelvic congestion syndrome: diagnosis and treatment. *Semin Interv Radiol*. 2008;25(4):361-8.
2. Gianturco C, Anderson JH, Wallace S. Mechanical devices for arterial occlusion. *Am J Roentgenol*. 1975;124(3):428-35.
3. Edwards RD, Robertson IR, MacLean AB, et al. Case report: pelvic pain syndrome--successful treatment of a case by ovarian vein embolization. *Clin Radiol*. 1993;47(6):429-31.
4. Maleux G, Stockx L, Wilms G, et al. Ovarian vein embolization for the treatment of pelvic congestion syndrome: long-term technical and clinical results. *J Vasc Interv Radiol*. 2000;11(7):859-64.
5. Ganeshan A, Upponi S, Hon LQ, et al. Chronic pelvic pain due to pelvic congestion syndrome: the role of diagnostic and interventional radiology. *Cardiovasc Intervent Radiol*. 2007;30(6):1105-11.
6. Coil embolization to the right side of the heart after elective hypogastric vein embolization requiring open-heart surgery | *Cath Lab Digest*. <https://www.cathlabdigest.com/article/Coil-Embolization-Right-Side-Heart-After-Elective-Hypogastric-Vein-Embolization-Requiring>. Accessed October 14, 2019.
7. D'Amato R, Figueira Gonçalves JM, Palmero Tejera JM. Pulmonary embolism due to metal coil migration after treatment of pelvic varices. *Arch Bronconeumol Engl Ed*. 2017;53(2):72.
8. León FX, Alba B, Arribas A, et al. A rare case of pulmonary embolism due to endovascular coil embolization and review of literature. *Int J Respir Pulm Med*. 5:094.
9. Yamasaki W, Kakizawa H, Ishikawa M, et al. Migration to the pulmonary artery of nine metallic coils placed in the internal iliac vein for treatment of giant rectal varices. *Acta Radiol Short Rep*. 2012;1(6):arsr.2012.120024
10. Tonkin J and Madden B. From ovarian coils to pulmonary emboli | B58. Who's bad: case reports in pulmonary vascular medicine I. 2018. Available at: https://www.atsjournals.org/doi/pdf/10.1164/ajrccm-conference.2018.197.1_MeetingAbstracts.A3700. Accessed October 20, 2019.

A Missed Celiac Artery Aneurysm Leading to Rupture: A Case Report

Jason Della Vecchia, DO*
Eric Blazar, MD†

*Clovis Community Medical Center, Department of Emergency Medicine,
Clovis, California

†Inspira Medical Center, Department of Emergency Medicine, Vineland, New Jersey

Section Editor: Anna McFarlin, MD

Submission history: Submitted January 13, 2020; Revision received June 2, 2020; Accepted June 10, 2020

Electronically published July 14, 2020

Full text available through open access at http://escholarship.org/uc/uciem_cpccem

DOI: 10.5811/cpcem.2020.6.46513

Introduction: Abdominal pain is a common complaint seen in the emergency department (ED). We report a case of celiac artery aneurysm (CAA) in a male patient presenting with abdominal pain to the ED on two separate occasions, approximately 24 hours apart.

Case Report: On the initial visit the patient was discharged with undifferentiated abdominal pain after computed tomography imaging and laboratory investigations. On the repeat visit he was found to have a rapidly expanding CAA with rupture. He became unstable requiring intubation, blood transfusions, and emergent transfer to a tertiary care center for surgical management where, unfortunately, he died hours after failed operative management.

Conclusion: Although rare, abdominal pain caused by CAAs can rapidly progress to rupture and have a high mortality. [Clin Pract Cases Emerg Med. 2020;4(3):440–442.]

Keywords: *celiac artery aneurysm; abdominal pain; neurofibromatosis.*

INTRODUCTION

Abdominal pain is a common presenting complaint in the emergency department (ED) with a large differential diagnosis list ranging from non-emergent to emergent life-threatening diagnoses. We present a case of a 41-year-old male who initially presented to the ED with abdominal pain and a stable-appearing neurofibroma adjacent to the celiac artery on work-up. On a repeat visit the next day, the patient was found to have a rapidly expanding celiac artery aneurysm (CAA) with rupture.

CASE REPORT

Initial Visit

A 41-year-old male presented to the ED for worsening abdominal pain over the prior three days. The patient described the pain as intermittent, sharp, and crampy in the upper quadrants. He reported constipation but denied fevers, nausea, vomiting, or diarrhea. He reported a past medical history of hypertension and neurofibromatosis. He

denied prior surgeries, smoking, alcohol abuse, or illicit drug use.

The vital signs were heart rate 94 beats per minute (bpm); respiratory rate 18 breaths per minute; blood pressure 159/90 millimeters of mercury (mmHg); temperature 36.5 degrees Celsius; and oxygen saturation 98% on room air. The patient appeared comfortable, but his physical exam was remarkable for tenderness in the upper abdomen without rebound or guarding. Murphy's sign was negative, and no masses were palpated. The remainder of his physical exam was unremarkable. The emergency physician ordered a complete blood count (CBC), comprehensive metabolic panel (CMP), lipase, urinalysis (UA), and computed tomography (CT) of the abdomen and pelvis with intravenous (IV) contrast. CBC, CMP, lipase and UA were within normal limits.

The CT revealed no acute intra-abdominal process but revealed a stable, round focus of low attenuation adjacent to the celiac artery. This was thought to be a neurofibroma given the patient's history and stable appearance from a CT performed nine

years prior. The diameter of the opacified celiac artery was also similar to the prior study at 1.2 centimeters (cm). The patient was treated with one liter normal saline bolus and famotidine. On re-evaluation he was symptom free and informed of the results of the work-up that was performed. He was diagnosed with undifferentiated abdominal pain and counseled to return to the ED for worsening pain, the development of fever, uncontrollable vomiting, or any new concerns.

Repeat Visit

The patient returned to the ED the next day for acute worsening of his pain that became diffuse and constant. He reported several episodes of non-bloody vomiting and several episodes of non-bloody diarrhea after taking milk of magnesia and a Fleet enema for his constipation. The vital signs were heart rate 75 bpm; respiratory rate 18 breaths per minute; blood pressure 170/95 mmHg; temperature 36.2 degrees Celsius; and oxygen saturation 100% on room air. The patient appeared very uncomfortable and was writhing in pain. He had diffuse tenderness on abdominal exam, but no palpable pulsatile masses or auscultated abdominal bruits. He had good distal perfusion to his extremities with distal pulses equal. Otherwise, his physical exam was unremarkable.

CBC, CMP, lipase, lactic acid, and a CT angiogram of the abdomen and pelvis were ordered, along with IV opioid and fluids. The patient received multiple doses of opiate analgesia, including hydromorphone, without relief. CBC was remarkable for leukocytosis of 17.3×10^9 per liter (L) (normal range: 4.5 to $11.0 \times 10^9/L$), and lactic acid was 2.0 millimoles per liter (mmol/L) (normal range: 0.5 to 2.0 mmol/L). CMP and lipase were unremarkable. The

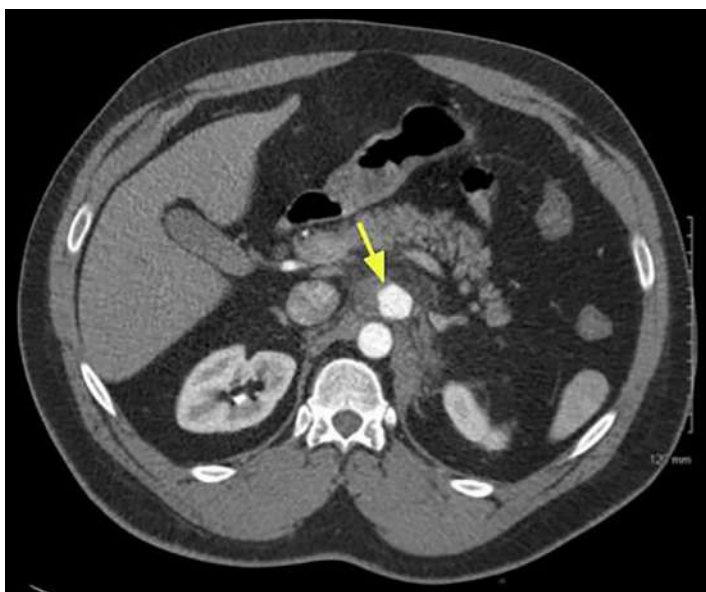


Image 1. Axial view of computed tomography angiogram of abdomen and pelvis showing a proximal celiac artery aneurysm (arrow) with surrounding inflammation and trace hemorrhage.

CPC-EM Capsule

What do we already know about this clinical entity?

Celiac artery aneurysm (CAA) is an uncommon vascular lesion that can rapidly expand and rupture.

What makes this presentation of disease reportable?

Symptomatic CAA can present with non-specific abdominal pain and be missed on initial imaging.

What is the major learning point?

Failure to consider a diagnosis of CAA in a differential can lead to a failure to diagnose this potentially life-threatening condition.

How might this improve emergency medicine practice?

Emergency physicians should consider this rare life-threatening diagnosis and be skeptical of all diagnostic tests.

CT angiogram of the abdomen and pelvis (Images 1 and 2) revealed a 3.2 x 2.4 cm proximal CAA with surrounding inflammatory change and trace hemorrhage. The remaining vasculature was unremarkable.

Upon return from CT, the patient's status deteriorated. He became diaphoretic, tachycardic, and hypotensive. Point-of-care ultrasound revealed fluid in Morrison's pouch. Central venous access was obtained and the patient was stabilized with four units of blood. He was transferred to a tertiary care facility for emergent surgical repair. The patient was brought to the operating room emergently at the tertiary care facility and underwent exploratory laparotomy. He was found to have a large retroperitoneal hematoma from a bleeding CAA. Both proximal and distal control was obtained, and the CAA was ligated.

Intraoperatively he had an estimated blood loss of eight liters and received 20 units of blood by massive transfusion protocol. He developed a coagulopathy, and the bleeding could not be controlled. The area of bleeding was packed and the patient transferred to the post-anesthesia care unit with an open abdomen, vacuum-assisted wound closure for continued resuscitation. The patient had a do-not-resuscitate order placed by family and expired a few hours after surgery.

DISCUSSION

CAAs are uncommon vascular lesions, accounting for 5.1% of all splanchnic artery aneurysms, which have an incidence

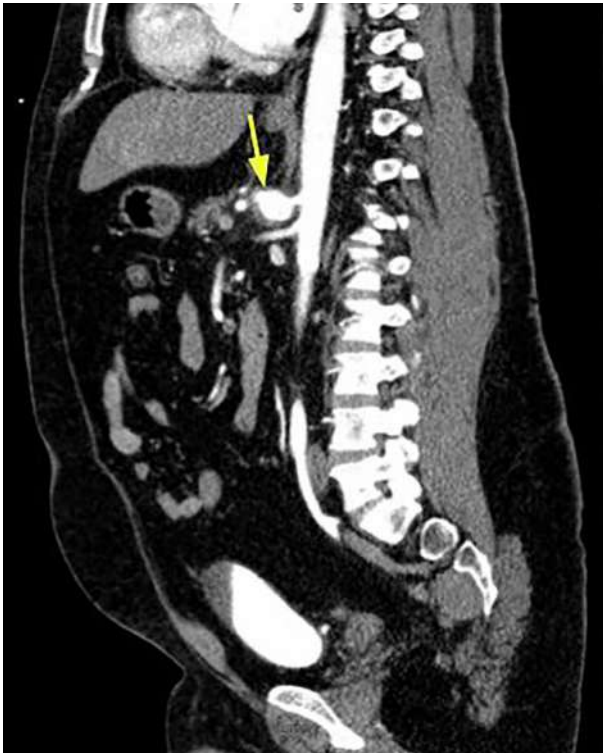


Image 2. Sagittal view of computed tomography angiogram of abdomen and pelvis showing a proximal celiac artery aneurysm (arrow) with surrounding inflammation and trace hemorrhage.

ranging from 0.1-2% in the adult population.¹ The etiology of CAA includes infectious diseases, atherosclerosis, trauma, or congenital diseases. While infectious diseases such as syphilis and tuberculosis were once the most common causes, today atherosclerosis is more common.² Patients can present with vague abdominal or back pain representing an expanding hematoma that may eventually rupture into the peritoneum, retroperitoneum, or the thorax, leading to an unstable patient. However, the majority of patients will be asymptomatic and the aneurysm is found incidentally on imaging or angiography in search or treatment of other diagnoses. Unlike abdominal aortic aneurysms (AAA), the natural history and management of CAAs is fairly unknown given their low prevalence compared to AAAs; however, like AAAs the rupture carries a high rate of mortality.¹ In the largest known case series with 18 patients, the two patients with rupture died.³

With the increase in CT imaging in the ED, it can be expected that incidental CAAs will be found. Although there are no clear consensus guidelines, it is recommended that surgical repair be done on aneurysms that are symptomatic, greater in size than two cm, those that expand greater than 0.5 cm per year, or those found in asymptomatic women who are either pregnant or of childbearing age.⁴ The treatment approach varies

depending on the preference of the vascular surgeon, but it can involve an open procedure with celiac artery ligation with or without revascularization, or endovascular approaches with stenting and embolization. On the initial visit for our patient a vascular origin of his pain was not considered given the stable CT findings and no report to suggest an aneurysm in the radiologist's differential for the abnormality seen adjacent to the celiac artery. Unfortunately, this misdiagnosis led to a delay in diagnosis and likely contributed to the patient's mortality on his repeat visit.

CONCLUSION

Celiac artery aneurysms can be asymptomatic but have the potential to be life-threatening if presenting with rupture. Although rare, it is important for emergency physicians to be aware of this diagnosis and refer patients for early treatment if found on imaging.

The authors attest that their institution requires neither Institutional Review Board approval, nor patient consent for publication of this case report. Documentation on file.

Address for Correspondence: Jason Della Vecchia, DO, Clovis Community Medical Center, Department of Emergency Medicine, 2755 Herndon Ave, Clovis, CA 93611. Email: jasondellavecchia@vituity.com.

Conflicts of Interest: By the CPC-EM article submission agreement, all authors are required to disclose all affiliations, funding sources and financial or management relationships that could be perceived as potential sources of bias. The authors disclosed none.

Copyright: © 2020 Vecchia et al. This is an open access article distributed in accordance with the terms of the Creative Commons Attribution (CC BY 4.0) License. See: <http://creativecommons.org/licenses/by/4.0/>

REFERENCES

1. Pulli R, Dorigo W, Troisi N, et al. Surgical treatment of visceral artery aneurysms: a 25-year experience. *J Vasc Surg.* 2008;48(2):334-42.
2. Takeuchi N, Soneda J, Naito H, et al. Successfully-treated asymptomatic celiac artery aneurysm: a case report. *Int J Surg Case Rep.* 2017;33:115-8.
3. Stone W, Abbas M, Gloviczki P, et al. Celiac arterial aneurysms. *Archives of Surg.* 2002;137(6).
4. Azimi-Ghomi O, Khan K, Ulloa K. Celiac artery aneurysm diagnosis and repair in the postpartum female. *J Surg Case Rep.* 2017;2017(2):rjx010.

A Case Report of Nebulized Tranexamic Acid for Post-tonsillectomy Hemorrhage in an Adult

Michael Poppe, MD
Felipe Grimaldo, MD

Naval Medical Center San Diego, Department of Emergency Medicine, San Diego, California

Section Editor: Rick A. McPheeters, DO

Submission history: Submitted April 13, 2020; Revision received June 1, 2020; Accepted June 10, 2020

Electronically published July 14, 2020

Full text available through open access at http://escholarship.org/uc/uciem_cpccem

DOI: 10.5811/cpcem.2020.6.47676

Introduction: Post-tonsillectomy hemorrhage is a potentially life-threatening, postoperative complication that is commonly encountered in the emergency department (ED).

Case Report: Herein, we describe the case of a 22-year-old male who presented to the ED with an active post-tonsillectomy hemorrhage. He rapidly became hypotensive and experienced an episode of syncope. Immediate interventions included intravenous fluids, emergency release blood and nebulized tranexamic acid (TXA). After completion of the nebulized TXA, the patient's bleeding was controlled.

Conclusion: To our knowledge, this is the first case in the emergency medicine literature that describes the use of nebulized TXA in an adult to achieve hemostasis in post-tonsillectomy hemorrhage. [Clin Pract Cases Emerg Med. 2020;4(3):443–445.]

Keywords: *Tranexamic acid; TXA; post-tonsillectomy hemorrhage.*

INTRODUCTION

Postoperative hemorrhage is the leading cause of death associated with tonsillectomy, most commonly occurring on postoperative days five to seven.¹ It is often a therapeutic challenge for emergency physicians, many times requiring management without surgical assistance. The American Academy of Otolaryngology-Head and Neck Surgery Foundation guidelines offer little assistance, as there is no report on the best way to control post-tonsillectomy hemorrhage. Management strategies in the adult population have not been extensively studied.

Management strategies in the pediatric population include intravenous (IV) fluids, direct pressure, clot suction, silver nitrate, vasoconstrictor-soaked pledgets, epinephrine injections, topical epinephrine, thrombin powder, and labs.² Tranexamic acid (TXA) is an antifibrinolytic, which has been studied extensively in many different settings for its procoagulant properties. There is a limited body of published literature describing inhaled TXA use, as well as oral TXA, for post-tonsillectomy hemorrhage in the pediatric population.³

Here, we present the first case report of inhaled TXA use in the setting of adult post-tonsillectomy hemorrhage.

CASE REPORT

A 22-year-old male presented to the emergency department (ED) with active post-tonsillectomy hemorrhage. He was post-operative day five from tonsillectomy performed for recurrent tonsillitis. Approximately one hour prior to arrival, he had been eating pizza rolls when he felt a “scratch in his throat.” He began bleeding profusely, unable to speak more than one to two words at a time before his mouth would fill with blood. By the time he arrived to the ED, he had filled an emesis basin with approximately 500 milliliters (mL) of blood. He was found to have a tachycardia of 104 beats per minute (bpm) with a blood pressure of 131/94 millimeters of mercury (mmHg). Due to the large volume of blood in the basin, continued bleeding, and tachycardia, one unit of uncrossmatched packed red blood cells (PRBC) was transfused. Both TXA (1000 milligrams [mg] per 10 mL) five mL and normal saline five mL were added to a nebulizer and administered to the patient.

Approximately 20 minutes into his ED evaluation, the patient became pale and diaphoretic. His heart rate increased to 122 bpm and blood pressure significantly decreased to 75/40 mmHg. Massive transfusion protocol was initiated, and the patient required a total of two units of PRBCs before his blood pressure and heart rate normalized. Upon completing the nebulizer treatment, the patient's rate of bleeding slowed and he could then speak full sentences. Examination of the oropharynx revealed a left fossa with postsurgical exudate without any active bleeding and a right fossa filled with clot and a steady, small-volume flow of bright red blood. Otolaryngology arrived at bedside and performed bedside coagulation cautery, after which bleeding was completely controlled. He was admitted to the hospital for further observation and discharged the following day.

DISCUSSION

TXA is an analog of the amino acid lysine. It functions as an antifibrinolytic by binding to plasminogen, inhibiting its transformation into plasmin, which in turn results in decreased fibrin breakdown. TXA has been studied for a variety of bleeding conditions in the adult and pediatric populations. Initially designed to assist in postpartum hemorrhage, its uses have been broadened in the interim.⁴ In the trauma setting it has also been shown to have a mortality benefit when given in the first three hours from injury.⁵

While generally considered a benign medication, it is not without risks. IV administration has been associated with increased risk of pulmonary embolism and deep venous thrombosis. This risk seems to increase if given after the first three hours of bleeding onset.⁶ That being said, these effects have not been studied in patients given TXA via a nebulized route. It has been studied in the setting of intracranial hemorrhage as well, with some evidence showing no statistical mortality benefit with increased risk of thromboembolic events.⁷ Areas of ongoing study where the inhaled route has been evaluated include diffuse alveolar hemorrhage (DAH) and hemoptysis.⁸⁻¹² In diffuse alveolar hemorrhage models, doses of 250 milligrams (mg) for less than 25 kilogram (kg) patients and 500 mg for greater than 25kg patients were able to control intractable DAH in 10 out of 18 patients.¹² As for hemoptysis patients, nebulized TXA has been shown to decrease the rate of bleed, decrease length of disease course, and decrease the need for invasive procedures when compared to placebo.¹³

In the pediatric population, there are case reports of nebulized TXA for post-tonsillectomy bleeding that have demonstrated feasibility in terms of ease of access to materials including TXA and nebulizers, as well as patient compliance and potential positive benefit.¹⁴ Cases described, as mentioned above, typically use doses of 250-500 mg nebulizer treatment, and most often efficacy is based on cessation of bleeding. Many of these involve co-treatment with nebulized epinephrine as well, which makes drawing conclusions as to

CPC-EM Capsule

What do we already know about this clinical entity?

Post-tonsillectomy hemorrhage is a common, potentially life-threatening complication seen frequently in the emergency department.

What makes this presentation of disease reportable?

There is weak evidence supporting the use of tranexamic acid (TXA) for pediatric post-tonsillectomy hemorrhage, but no evidence as to its effect on adults.

What is the major learning point?

TXA appears safe and with potential benefit in the setting of post-tonsillectomy hemorrhage in an adult.

How might this improve emergency medicine practice?

This novel treatment modality for post-tonsillectomy hemorrhage in an adult adds a tool to the emergency provider's arsenal.

efficacy from TXA alone more difficult. In this case, TXA and blood transfusion were the sole interventions, which resulted in clinical improvement and stabilization prior to the arrival of the otolaryngologist.

While a single case is not sufficient for determining causative relationships, the pharmacology of TXA and time course do support its efficacy in this case. The estimated onset of effect for TXA is one to two minutes, with an expected clinical effect to occur at 10-30 minutes.¹⁵ This seems consistent with the timing of this patient's clinical course, as bleeding had slowed down significantly to the point that he could speak and be fully examined approximately 25 minutes after administration. Some concern may be raised as to whether therapeutic concentrations may be obtained via a nebulized route. In vitro studies have shown a plasma concentration of 16 micrograms/mL to be the threshold for ceasing fibrinolysis. This patient received a total of 1000 mg of TXA. Even allowing for incomplete dosing due to frequent spitting, the patient would need to have absorbed a fraction of the initial 100 mg/mL dose to achieve effective concentration. In addition, it has been hypothesized that topical oral administration may be especially effective, given there is a relatively high concentration of plasminogen and low concentration of plasmin inhibitors in the oral cavity.⁹ In pediatric studies of DAH, TXA has not

been linked to any adverse effects (seizures, thromboembolic events, worsening of gas exchange).¹² Thus there is minimal risk in attempting treatment. This is in contrast to IV or oral TXA, which has at times been linked to increased risk of thromboembolism, renal injury, or hypotension if administered too quickly although the evidence remains inconclusive.⁹

CONCLUSION

Massive post-tonsillectomy bleeds can leave physicians feeling helpless due to limited treatment modalities, the potential for extremely difficult-to-control airway scenarios, and possibly prolonged duration of care before operative intervention becomes available. In the pediatric population both inhaled epinephrine and inhaled TXA have proven efficacious and safe. A well-documented risk factor for post-tonsillectomy bleeding is increased age, putting adults at potentially higher risk. In adult patients, this case demonstrated inhaled TXA to be a safe and effective management technique in addition to resuscitative care while waiting for surgical intervention.

The authors attest that their institution requires neither Institutional Review Board approval, nor patient consent for publication of this case report. Documentation on file.

Address for Correspondence: Felipe Grimaldo, MD, Naval Medical Center San Diego, Department of Emergency Medicine, 34800 Bob Wilson Drive, San Diego, CA 92134. Email: felipegrimaldojr@gmail.com.

Conflicts of Interest: By the CPC-EM article submission agreement, all authors are required to disclose all affiliations, funding sources and financial or management relationships that could be perceived as potential sources of bias. I am a military service member or federal/contracted employee of the United States government. This work was prepared as part of my official duties. Title 17 U.S.C. 105 provides that 'copyright protection under this title is not available for any work of the United States Government.' Title 17 U.S.C. 101 defines a U.S. Government work as work prepared by a military service member or employee of the U.S. Government as part of that person's official duties. The views expressed in this article are those of the authors and do not necessarily reflect the official policy or position of the Department of the Navy, Department of Defense, nor the U.S. Government. The authors disclosed none.

Copyright: © 2020 Poppe et al. This is an open access article distributed in accordance with the terms of the Creative Commons Attribution (CC BY 4.0) License. See: <http://creativecommons.org/licenses/by/4.0/>

REFERENCES

1. Wall JJ and Tay K. Postoperative tonsillectomy hemorrhage. *Emerg Med Clin N Am.* 2018;36(2):415-26.
2. Baugh RF, Archer SM, Mitchell RB, et al. Clinical practice guideline: tonsillectomy in children. *Otolaryngol Head Neck Surg.* 2011;144(1 Suppl):S1-30.
3. Chan CC, Chan YY, Tanweer F. Systematic review and meta-analysis of the use of tranexamic acid in tonsillectomy. *Eur Arch Otorhinolaryngol.* 2013;270(2):735-48.
4. WOMAN Trial Collaborators. Effect of early tranexamic acid administration on mortality, hysterectomy, and other morbidities in women with post-partum haemorrhage (WOMAN): an international, randomised, double-blind, placebo-controlled trial. *Lancet.* 2017;389(10084):2105-16.
5. CRASH-2 trial collaborators, Shakur H, Roberts I, et al. Effects of Tranexamic Acid on Death, Vascular Occlusive Events, and Blood Transfusion in Trauma Patients With Significant Haemorrhage (CRASH-2): a randomised, placebo-controlled trial. *Lancet.* 2010;376(9734):23-32.
6. Roberts I, Shakur H, Coats T, et al. The CRASH-2 trial: a randomised controlled trial and economic evaluation of the effects of tranexamic acid on death, vascular occlusive events and transfusion requirement in bleeding trauma patients. *Health Technol Assess.* 2013;17(10):1-79.
7. Hu W, Xin Y, Chen X, et al. Tranexamic acid in cerebral hemorrhage: a meta-analysis and systematic review. *CNS Drugs.* 2019;33(4):327-36.
8. Hunt BJ. The current place of tranexamic acid in the management of bleeding. *Anaesthesia.* 2015;70(Suppl 1):50-3,e18.
9. Robb PJ. Tranexamic acid: a useful drug in ENT surgery? *J Laryngol Otol.* 2014;128(7):574-9.
10. Urban D, Dehaeck R, Lorenzetti D, et al. Safety and efficacy of tranexamic acid in bleeding paediatric trauma patients: a systematic review protocol. *BMJ Open.* 2016;6(9):e012947.
11. Komura S, Rodriguez RM, Peabody CR. Hemoptysis? Try inhaled tranexamic acid. *J Emerg Med.* 2018;5(5)4:e97-9.
12. Bafaqih H, Chehab M, Almohaimeed S, et al. Pilot trial of a novel two-step therapy protocol using nebulized tranexamic acid and recombinant factor VIIa in children with intractable diffuse alveolar hemorrhage. *Ann Saudi Med.* 2015;35(3):231-9.
13. Wand O, Guber E, Guber A, et al. Inhaled tranexamic acid for hemoptysis treatment: a randomized controlled trial. *Chest.* 2018;154(6):1379-84.
14. Schwarz W, Ruttan T, Bundick K. Nebulized tranexamic acid use for pediatric secondary post-tonsillectomy hemorrhage. *Ann Emerg Med.* 2019;73(3):269-71.
15. Wolters Kluwer. Clinical Drug Information, Inc. 2018. Available at: <https://www.wolterskluwerdi.com/>. Accessed February 10, 2020.

An Unusual Presentation of Retinal Detachment and Conjunctivitis: A Case Report

Bailey Pierce, BS*
Scott M. Alter, MD, MBA*
Kyle Gerakopoulos, MD, MBA*
Jeniell Parmar, MD, PhD*†

*Florida Atlantic University Charles E. Schmidt College of Medicine, Division of
Emergency Medicine, Boca Raton, Florida
†Boca Raton Regional Hospital, Department of Emergency Medicine, Boca Raton, Florida

Section Editor: Rick A. McPheeters, DO

Submission history: Submitted May 18, 2020; Revision received June 20, 2020; Accepted July 1, 2020

Electronically published July 30, 2020

Full text available through open access at http://escholarship.org/uc/uciem_cpem

DOI: 10.5811/cpcem.2020.7.48292

Introduction: Vision loss is an ophthalmologic emergency with broad differential requiring prompt medical attention.

Case Report: We describe a 55-year-old male presenting to the emergency department (ED) with unilateral, painless visual field deficit with ipsilateral conjunctivitis induced by a presumed foreign body. The patient described a foreign body sensation nine days prior to developing visual changes. In the ED, the patient was diagnosed with a retinal detachment using point-of-care ultrasonography, and emergent ophthalmologic consultation was obtained.

Conclusion: Concurrent retinal detachment and conjunctivitis in a patient is extremely rare. Healthcare providers should be aware that foreign body-induced conjunctivitis could lead to retinal detachment. [Clin Pract Cases Emerg Med. 2020;4(3):446–449.]

Keywords: *Conjunctivitis; retinal detachment; foreign body; corneal abrasion.*

INTRODUCTION

A total of 11.9 million visits to emergency departments (ED) from 2006–2011 were for eye-related issues.¹ Among these visits, acute vision loss is an ophthalmologic emergency with a large differential. Retinal detachment (RD) is one cause of painless acute vision loss that affects one in 10,000 annually.² Although RD is associated with a number of risk factors, RD following corneal abrasion or conjunctivitis is not well documented. We describe a case of a 55-year-old man who presented to the ED with acute retinal detachment following eye injury and subsequent symptoms of conjunctivitis. Physicians should be aware that minor eye injury and ocular inflammation may present with delayed RD.

CASE REPORT

A 55-year-old man with no significant past medical history presented to the ED for evaluation of right eye conjunctival injection, irritation, and painless visual field

loss over the lower half of his vision in the ipsilateral eye. The patient stated that nine days prior a foreign body may have penetrated his right eye, for which he did not seek medical attention at that time. In the affected eye, he subsequently developed erythema, edema, purulent crusty drainage, itching, and a foreign body sensation. On day eight after the initial eye injury, the patient developed sudden-onset painless vision loss over the lower aspect of the right visual field. The following day, he presented to the ED with these symptoms. The patient denied blurry vision, floaters, or any past ophthalmological history.

On physical exam of the right eye, the patient had minimal conjunctival injection. Visual field deficits were appreciated over the lower temporal and lower nasal sides of the right eye. All remaining visual fields and visual acuity were intact. Fluorescein staining and Wood's lamp exam did not reveal any foreign body, with negative Seidel sign. Point-of-care ocular ultrasonography showed retinal detachment of

the right eye. The case was discussed with an ophthalmologist, who came to the ED, evaluated the patient, and arranged for next day follow-up and outpatient retinal repair.

DISCUSSION

Retinal detachment is the separation of the neurosensory retina from the retinal pigment epithelium and results in retinal ischemia with progressive photoreceptor degeneration. Rhegmatogenous RD, the most common type, is caused by breaks in the retina.³ Patients with RD will endorse a sudden loss of vision that begins peripherally. Permanent vision loss, even with surgical repair, is likely when detachment progresses across the fovea with central vision loss.² Larger retinal breaks can progress to central vision loss over days while smaller breaks may progress over weeks to months.⁴ Rhegmatogenous RD has several risk factors, or detachment may be secondary to ocular trauma.³ Minor eye injuries causing corneal abrasion or conjunctivitis are not well-documented risk factors for any type of RD.

The patient we present had symptoms of conjunctivitis preceding his RD. Although our patient described classic signs and symptoms of conjunctivitis, other ocular conditions may present similarly. Our first diagnostic challenge was attempting to determine an accurate diagnosis for the patient's initial symptoms to better understand the pathogenesis of his RD. We first considered whether these symptoms were secondary to his presumed eye injury, a corneal abrasion, or from an infectious etiology.

In our patient, the initial eye injury could have led to a retained foreign body causing subsequent conjunctivitis. A retained foreign body could have caused continued eye irritation and inflammation until it fell out, coinciding with improvement of his symptoms the night prior to presentation. It is also possible the foreign body caused a corneal abrasion with subsequent inflammation and foreign body sensation. Corneal abrasions typically heal within 24-48 hours, accounting for the negative Wood's lamp exam at the time of presentation.⁵ Alternatively, these symptoms could have been caused by an infectious etiology. Bacterial conjunctivitis often presents with a unilateral conjunctival injection with increased discharge and purulence, symptoms that our patient endorsed. The pathogen was likely introduced by the foreign body itself or by the patient attempting to remove the presumed foreign body.

Although not likely, we considered other infectious etiologies for our patient's initial symptoms that also present with conjunctival injection and have more documented associations with RD. Corneal abrasions can become secondarily infected and cause keratitis. Keratitis may similarly present with conjunctival injection, foreign body sensation, and discharge, but often presents with pain and corneal opacity, which were not appreciated on our patient's exam. Keratitis may rarely progress to endophthalmitis, which typically develops following cataract surgery, ocular trauma, or hematogenous spread.⁶ However, our patient's eye injury was minor, he denied

CPC-EM Capsule

What do we already know about this clinical entity?

The well-described risk factors for retinal detachment include older age, myopia, ocular trauma, and previous eye surgery.

What makes this presentation of disease reportable?

Though common complaints, conjunctivitis and corneal abrasions have not been previously reported as precursors to retinal detachment.

What is the major learning point?

Delayed presentation of retinal detachment may occur after minor eye injury and ocular inflammation.

How might this improve emergency medicine practice?

Blindness due to retinal detachment may be prevented if physicians consider this devastating disorder in patients presenting with conjunctivitis or corneal abrasion.

cataract surgery, and endophthalmitis is not self-limited and would be apparent on exam. Another disease process that can present with conjunctival injection is anterior uveitis. This could then develop into a panuveitis with involvement of the retina, and later progress to RD. While uveitis may have an infectious etiology, it is more commonly associated with systemic disorders that would be revealed in the history.⁷ As symptoms of these conditions overlap, and because our patient did not seek medical attention for his prior symptoms, we were unable to confirm his initial diagnosis. However, given the lack of risk factors and self-limited nature of our patient's symptoms, it was more likely to be continued irritation from a foreign body, corneal abrasion, or conjunctivitis.

Next, we considered whether our patient's initial eye injury, the foreign body, or conjunctivitis played a role in the development of RD. Ocular injury is a well-documented cause of RD but usually follows significant ocular trauma, including open-globe injuries and blunt trauma severe enough to cause contusion. Although RD may occur at the time of injury, it may also be delayed. One study found that for both open- and closed-globe injuries, roughly half the participants had a delayed presentation to RD, ranging from four days to nine years.⁸ While it is possible our patient's initial eye injury caused a delayed RD, his description of the injury, if an injury at all, did not seem severe enough to have caused RD. Conversely,

minor ocular injuries that cause corneal abrasions are not well documented to cause RD. It is possible though that the initial eye injury caused an abrasion that healed with formation of fibrous bands that acted as a nidus for delayed tractional RD.

Alternatively, a retained intraocular foreign body (IOFB) itself may have caused a RD through continued inflammation, direct toxicity, or secondary infection. Retained IOFB usually occurs following penetrating open-globe trauma. Risk factors for subsequent RD include delayed IOFB removal and foreign body located in the posterior segment.⁹ While our patient did not have an open-globe injury, there are cases in which an occult IOFB after minimal or no reported trauma caused RD. In a case series of three, patients initially presented with uveitis and were found to have a secondary RD. Initial ultrasound did not reveal IOFB, but later was discovered one to three weeks after onset of symptoms during surgical exploration. Unlike our patient whose symptoms nearly resolved prior to presentation, all three cases had progressively worsened until treatment.¹⁰

It is also possible that development of conjunctivitis led to our patient's RD. There has been little published in the literature regarding RD acutely following conjunctivitis. *Chlamydia trachomatis* can cause a self-limited hyperpurulent conjunctivitis and has been associated with the development of RD. One case report described a patient presenting with decreased visual acuity and RD with subretinal fluid and conjunctival scrapings positive for chlamydia. However, this patient did not present with conjunctivitis symptoms, and the RD associated with chlamydia usually occurs after repeated or persistent exposure with development of conjunctival scarring and Herbert's pits.¹¹ These findings were not visualized in our patient, and RD has not been reported to acutely follow chlamydial conjunctivitis.

Another case report describes a patient who had an episode of conjunctival injection, epiphora, and no pain. The patient's symptoms worsened, and a serous RD was found on exam. After a thorough history and extensive lab testing, he was diagnosed with idiopathic orbital inflammatory syndrome (IOIS).¹² While this report is similar to our patient's, IOIS is a diagnosis of exclusion requiring an extensive workup that would not be completed in the ED. In our patient, IOIS was also less likely in the setting of more obvious risk factors.

Finally, it is possible our patient's RD was coincidental and not related to either his eye injury or conjunctivitis. Rhegmatogenous RD is more common in the fourth through sixth decades of life, and risk factors include myopia, cataract surgery, previous RD in the contralateral eye, lattice degeneration, and some hereditary disorders.³ In non-traumatic RD, one study found that posterior vitreous detachment occurs prior to RD in 87.6% of cases. This typically presents with flashers and floaters one-half to three weeks prior to visual field loss.¹³ Our patient did not have many of the previously stated risk factors, and he denied flashers and floaters.

CONCLUSION

Our case is unusual because RD does not usually develop after conjunctivitis-like symptoms. Healthcare providers should be vigilant during their assessment of patients with ocular complaints. We have described concomitant presentation of conjunctivitis and retinal detachment.

The authors attest that their institution requires neither Institutional Review Board approval, nor patient consent for publication of this case report. Documentation on file.

Address for Correspondence: Jeniel Parmar, MD, PhD, Boca Raton Regional Hospital, Department of Emergency Medicine, 800 Meadows Rd., Boca Raton, FL 33486. Email: jenielparmar@gmail.com.

Conflicts of Interest: By the CPC-EM article submission agreement, all authors are required to disclose all affiliations, funding sources and financial or management relationships that could be perceived as potential sources of bias. The authors disclosed none.

Copyright: © 2020 Pierce et al. This is an open access article distributed in accordance with the terms of the Creative Commons Attribution (CC BY 4.0) License. See: <http://creativecommons.org/licenses/by/4.0/>

REFERENCES

1. Channa R, Zafar SN, Canner JK, et al. Epidemiology of eye-related emergency department visits. *JAMA Ophthalmol.* 2016;134(3):312-9.
2. Kang HK and Luff AJ. Management of retinal detachment: a guide for non-ophthalmologists. *BMJ.* 2008;336(7655):1235-40.
3. Ghazi NG and Green WR. Pathology and pathogenesis of retinal detachment. *Eye.* 2002;16:411-21.
4. Byer NE. Natural history of posterior vitreous detachment with early management as the premier line of defense against retinal detachment. *Ophthalmology.* 1994;101(9):1503-14.
5. Wipperman JL and Dorsch JN. Evaluation and management of corneal abrasions. *Am Fam Physician.* 2013;87(2):114-20.
6. Gao Y, Chen N, Dong XG, et al. Surgical management of fungal endophthalmitis resulting from fungal keratitis. *Int J Ophthalmol.* 2016;9(6):848-53.
7. De Hoog J, Ten Berge JC, Groen F, et al. Rhegmatogenous retinal detachment in uveitis. *J Ophthalmic Inflamm Infect.* 2017;7(1):22.
8. Sarrazin L, Averbukh E, Halpert M, et al. Traumatic pediatric retinal detachment: a comparison between open and closed globe injuries. *Am J Ophthalmol.* 2004;137(6):1042-9.
9. Parke DW, Pathengay A, Flynn HW, et al. Risk factors for

- endophthalmitis and retinal detachment with retained intraocular foreign bodies. *J Ophthalmol.* 2012;2012:758526.
10. Sychev YV, Verner-Cole EA, Suhler EB, et al. Occult nonmetallic intraocular foreign bodies presenting as fulminant uveitis: a case series and review of the literature. *Clin Ophthalmol.* 2013;7:1747-51.
 11. Ghaffariyeh A, Honarpisheh N, Lari AR. Detection of *Chlamydia trachomatis* in the subretinal fluid of a patient with rhegmatogenous retinal detachment. *Clin Exp Optom.* 2011;94(5):488-9.
 12. Slagle WS, Boothe KH, Musick AN, et al. Idiopathic orbital inflammatory syndrome without pain: a case report. *Optometry.* 2010;81(3):146-52.
 13. Mitry D, Singh J, Yorston D, et al. The predisposing pathology and clinical characteristics in the Scottish retinal detachment study. *Ophthalmology.* 2011;118(7):1429-34.

Rectal Foreign Body Removal in the Emergency Department: A Case Report

Samuel Nesemann, MD*

Kimberly A. Hubbard, BS†

Mehdi I. Siddiqui, BS†

William G. Fernandez MD, MPH, MS*

*University of Texas Health San Antonio, Department of Emergency Medicine, San Antonio, Texas

†University of Texas Health San Antonio Long School of Medicine, Department of Emergency Medicine, San Antonio, Texas

Section Editor: Scott Goldstein, MD

Submission history: Submitted March 5, 2020; Revision received June 28, 2020; Accepted July 3, 2020

Electronically published July 30, 2020

Full text available through open access at http://escholarship.org/uc/uciem_cpem

DOI: 10.5811/cpem.2020.7.47237

Introduction: Rectal foreign bodies (RFB) pose a challenge to emergency physicians. Patients are not often forthcoming, which can lead to delays to intervention. Thus, RFBs require a heightened clinical suspicion. In the emergency department (ED), extraction may require creative methods to prevent need for surgical intervention.

Case Report: The authors present a case of a successful extraction of a RFB in the ED and review of the literature.

Conclusion: Retained RFBs are an unusually problematic reason for an ED visit. Thus, it is important for emergency physicians to be comfortable managing such cases appropriately. [Clin Pract Cases Emerg Med. 2020;4(3):450–453.]

Keywords: *Rectal foreign body; emergency department.*

INTRODUCTION

Abdominal pain due to a retained rectal foreign body (RFB) is an unusually problematic complaint in the emergency department (ED) setting.¹⁻³ The true incidence of retained RFB in the community is not currently known.¹ A study done using two large hospitals in Southern California had an incidence of nearly one episode per month over nine years. This presentation is not a recent phenomenon; in fact, the earliest reports date back to the 16th century.² Most RFBs are inserted for the purpose of autoerotic sexual gratification.^{3,4} Naturally, having a retained RFB often leads to some degree of embarrassment for the patient, which may result in reticence in providing a full account of the situation, which may impede the physician from obtaining an accurate history.⁵ Typically, patients with retained RFB present to the ED several hours after insertion following failed attempts at self-removal.⁵ In such cases, radiographic imaging is a key diagnostic modality. Successful management of RFB in the ED involves early diagnosis and triage for extraction. In this

report, we describe an approach to extracting a retained RFB in the ED setting.

CASE REPORT

A Hispanic female in her 40s presented to the ED approximately six hours after inserting a cylindrical deodorant container into her rectum. After discussing anal sex with friends, she became curious and inserted the deodorant canister into her rectum. The patient became distressed by her inability to remove the object and developed dull, diffuse lower abdominal pain that radiated to her rectum. Upon ED presentation, she was in moderate discomfort, lying in the lateral decubitus position.

On physical exam, the patient's vital signs were normal; additionally, there was diffuse tenderness to palpation of the lower abdomen. On inspection of the perineal area, there were no signs of external trauma or other abnormalities noted. A hard, cylindrical structure was palpable approximately five centimeters (cm) into the rectum on digital rectal exam,

posteriorly displaced from the anal orifice. The patient was given morphine four milligrams (mg) intravenously, and then an abdominal kidney-ureter-bladder (KUB) radiograph was ordered for evaluation of RFB. The key findings of the KUB included “a cylindrical lucency projecting over the rectum consistent with inserted foreign object” (Image).

Based on the patient’s presentation and radiographic findings, extraction of the canister in the ED was attempted. Prior to the procedure, the patient was placed on a cardiac monitor with pulse oximetry, and given supplemental oxygen before receiving lorazepam 2 mg for anxiety, and later 4 mg morphine sulfate for pain, to facilitate the procedure. To extract the canister, three successive methods were used. The patient was placed in a lateral decubitus position, and a lubricated finger was inserted into the rectum to locate the canister (manual extraction method). Once located, a second finger on the opposite hand was inserted into the anus to gain traction with one finger on each side of the canister and pull the object out of the anus. Unfortunately, the anal orifice did not allow enough space for two fingers to be inserted far enough to obtain traction sufficient for removal.

Next, a lubricated finger was used to guide a coudé catheter past the canister, using the first finger for guidance (coudé catheter method). Then, the catheter balloon was inflated with saline and traction applied to dislodge the canister. This was unsuccessful, likely because the catheter was not rigid enough to apply the necessary pressure for extraction. Finally, a lubricated finger was used to guide a set of ring forceps around the canister. Traction was applied to the forceps while squeezing to maintain contact with the canister (forceps method). This was attempted three times, but the forceps dislodged each time. On a fourth attempt, we maneuvered the canister from its posteriorly displaced position to a position in line with the anal orifice using the forceps. Once in this position, we applied gentle traction to remove the

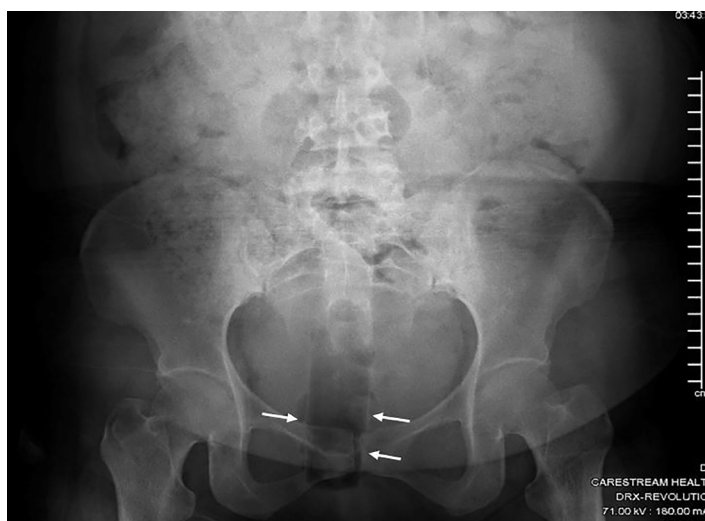

Image. Kidney-ureter-bladder radiograph demonstrating retained rectal foreign body as lucency in rectum (arrows).

CPC-EM Capsule

What do we already know about this clinical entity?

Despite careful emergency department (ED) management, certain factors reduce the odds of rectal foreign body (RFB) extraction. In such cases, endoscopic or surgical removal is necessary.

What makes this presentation of disease reportable?

This case highlights the challenge of RFB removal in the ED. In some cases, several attempts may be required to avoid the need for endoscopic or surgical extraction.

What is the major learning point?

In addition to detailed history-taking and adequate patient preparation, making time to allow for an unhurried extraction is critical to success in RFB cases.

How might this improve emergency medicine practice?

We highlight some best practices as well as key challenges to the safe removal of RFB in the ED. Also, we list conditions where additional computed tomography imaging is advised.

RFB; the deodorant canister measured approximately 11.5 cm in length by 3.5 cm in diameter.

Following the extraction, the patient had complained of persistent abdominal discomfort. Therefore, an intravenous contrast-enhanced computed tomography (CT) of the abdomen and pelvis was ordered to evaluate for perforation or damage to the bowel. Only mild rectal wall thickening without free air or signs of perforation was seen on CT.

DISCUSSION

Patient Evaluation

The first step in patient evaluation requires a focused history with an emphasis on the nature of the RFB and manner of insertion. Although not so in the present case, the majority of patients presenting with RFB are white males in their 40s.^{6,14-15} While many RFBs are smooth and egg-shaped, which facilitates insertion, some may have sharp edges or are easily fragmented.⁶ Thus, some recommend abdominal radiographic imaging prior to digital rectal exam (DRE) in order to identify sharp edges on the RFB that could result in provider injury.⁶ Additionally, imaging may identify free air, and help to assess the size and

depth of the RFB.⁶ RFBs that contain sharp edges, are over 10 cm, have entered the sigmoid colon, or that have been retained for two or more days are less likely to be extracted in the ED, and may require endoscopic or surgical removal.^{6-7, 14-15} Importantly, “body-packers” – those who conceal illicit drugs by swallowing latex balloons filled with such illegal substances in smuggling attempts – will require close monitoring in the event that such balloons break during transit through the bowels, as extraction should not be attempted in these patients.¹ Additionally, the risk of perforation is not limited to sharp or easily fragmented RFBs; it also is related to the force of insertion.⁸ Obtaining detailed information about the size and shape of the RFB, as well as the manner and circumstances with which it was introduced is imperative, as most failures of manual extraction in the ED can be predicted preoperatively.⁹

Next, imaging should be obtained. It is important to first assess for perforation both clinically and via imaging, such as an upright chest radiograph. RFB perforation is a potential surgical emergency and should result in immediate surgical intervention.^{2, 6-8, 13-15} In addition to assessing perforation, imaging can also determine the general location of the RFB within the abdomen, which affects disposition. For instance, if the RFB is proximal to the rectosigmoid junction, endoscopic removal is recommended.¹ However, if it is distal to this point, a DRE should be performed. If the RFB cannot be palpated on DRE, manual extraction should not be attempted, and a surgeon should instead be consulted for either endoscopic or operative removal.^{2, 7, 10, 14-15}

Techniques

There are several key principles of managing RFBs within the ED to optimize successful extraction. These include minimizing cross-sectional area, employing visualization during extraction, overcoming suction, and limiting procedure time.⁸ First, it is important to grasp the RFB securely. Broadly, the literature describes the use of forceps, Foley catheters, and bimanual manipulation for extraction.¹¹ Several reports mention the use of obstetric forceps as grasping tools,^{1, 6-9, 11} while others suggest the use of endoscopic snares to grasp the object.^{1-4, 6} While there is little consensus in the literature regarding specific techniques within each category of grasping tools, the vast majority of reports suggest first attempting bimanual manipulation, and then proceeding to the use of forceps before involving endoscopy. If the object is difficult to remove with simple grasping, it is likely that the suction effect must be overcome. This is accomplished in several different ways, including the use of a Foley catheter, endotracheal tube, or air insufflation during endoscopy.^{7, 12}

Additionally, to increase the success of RFB removal during an extraction attempt, it is important to keep the patient calm, and to control their pain. If they can tolerate the procedure without being sedated, they can actively aid in removal by performing the Valsalva maneuver at a specific time.⁷ However, given the discomfort in the removal process, sedative agents are often necessary, and may include procedural sedation or

perianal local anesthesia,⁵⁻⁶ although this may be beyond the scope of ED management.⁷ Additionally, the generous use of lubricant¹ and placing the patient in the lithotomy position may also be used to facilitate extraction.⁵ Regardless of the outcome of the RFB extraction attempt, the patient should be observed for several hours with repeated abdominal exams for signs of peritonitis from perforation.^{6, 14-15} Any evolving changes in the abdominal exam or other concerning findings (e.g., vital sign changes, vomiting) should warrant abdominal CT imaging and urgent surgical consultation.^{6, 14-15} Finally, after discharge, patients should have close follow-up for any subsequent post-extraction complications.

CONCLUSION

Retained RFBs are an unusual reason for ED presentation. However, it is important for emergency physicians to be comfortable managing these patients appropriately. Most cases can be successfully managed in the ED via forceps-assisted manual extraction, effectively removing the object with minimal long-term complication. Some cases will require referral for endoscopic or operative extraction.

The authors attest that their institution requires neither Institutional Review Board approval, nor patient consent for publication of this case report. Documentation on file.

Address for Correspondence: William G. Fernandez, MD, MPH, MS, University of Texas Health San Antonio, Department of Emergency Medicine, 7703 Floyd Curl Drive, San Antonio, TX 78229. Email: fernandezw@uthscsa.edu.

Conflicts of Interest: By the CPC-EM article submission agreement, all authors are required to disclose all affiliations, funding sources and financial or management relationships that could be perceived as potential sources of bias. The authors disclosed none.

Copyright: © 2020 Nesemann et al. This is an open access article distributed in accordance with the terms of the Creative Commons Attribution (CC BY 4.0) License. See: <http://creativecommons.org/licenses/by/4.0/>

REFERENCES

1. Cologne K and Ault G. Rectal foreign bodies: What is the current standard? *Clin Colon Rectal Surg.* 2012;25(4):214-8.
2. Kasotakis G, Roediger L, Mittal S. Rectal foreign bodies: a case report and review of the literature. *Int J Surg Case Rep.* 2012;3(3):111-5.
3. Bak Y, Merriam M, Neff M, et al. Novel approach to rectal foreign body extraction. *JSL.S.* 2013;17(2):342-5.
4. Lim KJ, Kim JS, Kim BG, et al. Removal of rectal foreign bodies using tenaculum forceps under endoscopic assistance. *Intest Res.*

- 2015;13(4):355-9.
5. Ologun GO, Stevenson Y, Cagir B, et al. Successful retrieval of a retained rectal foreign body in the emergency department. *Cureus*. 2018;10(1):e2025
 6. Barrineau T, Davee D, Mosley C. Rectal foreign bodies: not always a simple ED diagnosis. 2019. Available at: <http://www.emdocs.net/rectal-foreign-bodies-not-always-a-simple-ed-diagnosis/>. Accessed May 12, 2020.
 7. Desai B. Visual diagnosis: rectal foreign body: a primer for emergency physicians. *Int J Emerg Med*. 2011;4(1):73.
 8. Wigle RL. Emergency department management of retained rectal foreign bodies. *Am J Emerg Med*. 1988;6(4):385-9.
 9. Ayantunde AA and Unluer Z. Increasing trend in retained rectal foreign bodies. *World J Gastrointest Surg*. 2016;8(10):679-84.
 10. Humes D and Lobo DN. Removal of a rectal foreign body by using a Foley catheter passed through a rigid sigmoidoscope. *Gastrointest Endosc*. 2005;62(4):610.
 11. Cawich SO, Thomas DA, Mohammed F, et al. A management algorithm for retained rectal foreign bodies. *Am J Mens Health*. 2017;11(3):68492.
 12. Mikami H, Ishimura N, Oka A, et al. Successful transanal removal of a rectal foreign body by abdominal compression under endoscopic and X-ray fluoroscopic observation: a case report. *Case Rep Gastroenterol*. 2016;10(3):64-52.
 13. Lake JP, Essani R, Kaiser A, et al. Management of retained rectal foreign bodies: predictors of operative extraction. *Gastroenterol*. 2013;124(4 Supp1):A816.
 14. Shaban Y, Elkbuli A, Ovakimyan V, et al. Rectal foreign body causing perforation: case report and literature review. *Ann Med Surg*. 2019;47:66-9.
 15. Schellenberg M, Brown CVF, Trust MD, et al. Rectal injury after foreign body insertion: secondary analysis from the AAST contemporary management of rectal injuries study group. *J Surg Res*. 2020;247:541-6.

A Rare Case Report of Lemierre Syndrome from the Anterior Jugular Vein

Nima Rejali, DO*
Marissa Heyer, BA†
Doug Finefrock, DO*†

*Hackensack University Medical Center, Department of Emergency Medicine, Hackensack, New Jersey

†Hackensack Meridian School of Medicine, Department of Emergency Medicine, Hackensack, New Jersey

Section Editor: Rick A. McPheeters, DO

Submission history: Submitted March 27, 2020; Revision received June 14, 2020; Accepted July 3, 2020

Electronically published August 3, 2020

Full text available through open access at http://escholarship.org/uc/uciem_cpem

DOI: 10.5811/cpcem.2020.7.47442

Introduction: Lemierre syndrome is a rare, potentially fatal, septic thrombophlebitis of the internal jugular vein. Treatment includes intravenous antibiotics for *Fusobacterium necrophorum*, the most common pathogen, as well as consideration for anticoagulation therapy.

Case Report: A 27-year-old female presented with left-sided neck swelling and erythema. Computed tomography noted left anterior jugular vein thrombophlebitis and multiple cavitating foci, consistent with septic emboli. We report a rare case of Lemierre syndrome in which the thrombus was found in the anterior jugular vein, as opposed to the much larger internal jugular vein more traditionally associated with creating septic emboli.

Conclusion: Based on an individual's clinical symptoms, history, and radiologic findings, it is important for physicians to consider Lemierre syndrome in the differential diagnosis, as the condition may rapidly progress to septic shock and death if not treated promptly. The use of anticoagulation therapy remains controversial, and there is a lack of established standard care because the syndrome is so rare. [Clin Pract Cases Emerg Med. 2020;4(3):454–457.]

Keywords: Sepsis; septic emboli; thrombophlebitis; case report; Lemierre.

INTRODUCTION

Lemierre syndrome is a rare septic thrombophlebitis of the internal jugular vein that will almost certainly result in mortality if proper treatment is not established quickly.¹ It is commonly preceded by an oropharyngeal infection, such as pharyngitis, and is complicated by bacteremia with primarily anaerobic organisms of the oral flora.¹ The most common pathogen associated with Lemierre syndrome is *Fusobacterium necrophorum*, a Gram-negative, anaerobic bacillus that inhabits the oropharynx.² While the mechanism of how this generally noninvasive organism infiltrates mucosal surfaces is unknown, some research has pointed to viral or bacterial infections altering the pharyngeal mucosa, allowing the bacteria to invade parapharyngeal and carotid spaces via direct or venolymphatic route.³ Affected individuals are often

young (age 16-30 years) and initially present with sore throat, followed by neck pain and a neck mass.⁴ Patients require hospital admission for intravenous (IV) antibiotic administration to eradicate the infection.

CASE REPORT

A 27-year-old female presented to the emergency department (ED) for swelling and redness of the left neck. She noted having a “pimple on her chin” two weeks prior, which she popped. A few days later, she developed swelling to her left neck and jaw. The swelling progressed and required emergent intubation and an intensive care unit admission at a nearby hospital for one week. Her treatment included IV antibiotics and steroids without surgical drainage. After extubation, she exhibited concern for proper

treatment and left against medical advice (AMA). The next day she presented to our ED. The patient stated that she was also treated for a “lung infection,” but was unclear of the diagnosis. She noted that over the prior few days her “neck infection,” which initially improved, had increased swelling and redness. She denied any difficulty swallowing or speaking, fever, nausea, or vomiting. She was unsure of her diagnosis or specific antibiotic treatment and could not recall whether any cultures were obtained.

Upon arrival to the ED, the patient’s blood pressure was 107/68 milligrams of mercury with a pulse of 99 beats per minute and temperature of 98.2°Fahrenheit (36.8°Celsius). Her respiratory rate was 20 breaths per minute, and oxygen saturation on room air was 98%. Her height was 1.575 meters (5’2”) and weight was 83 kilogram (kg) (183 pounds) with a body mass index of 33.47 kg per meters squared (m²) (reference range 18.5-24.9 kg/m²).

On physical exam, the patient was oriented to person, place, and time; however, she appeared visibly dyspneic ambulating from the waiting area to exam room. She had a pressure ulcer on the lower lip (likely from endotracheal tube), and fluctuance, erythema, and tenderness to teeth numbered 18 and 19. There was a large area of erythema, induration, and warmth on the left mandible, approximately 10 x 6 centimeters (cm), with no central fluctuance. Exam was negative for elevation of the tongue, uvular deviation, pharyngeal edema or erythema, and brawny edema of the anterior neck. Patient’s pupils were equal, round, and reactive to light with extraocular motions intact.

Pulmonary/chest exam was notable for mild tachypnea with cough, as well as bilateral rales (right > left). She had no stridor, drooling, voice changes, or other concerning symptoms requiring emergent airway stabilization. The patient had normal rate and regular rhythm on cardiac exam, with no murmurs heard. She had a soft, non-tender abdomen with normal bowel sounds. There were no abnormal findings on neurological exam, and the patient’s skin was warm, dry, and non-diaphoretic.

Overall, suspicion for a serious medical illness upon initial presentation was high: the patient had recently been intubated for respiratory distress and follow-up management was challenged by the lack of a proper transition of care. Medical records were not available for review during her ED presentation, and she had left another hospital AMA the day prior. In addition to the patient’s obvious discomfort and fatigue, a detailed head, eyes, ears, nose, and throat exam revealed many abnormalities, most notably an intraoral abscess and significant redness and swelling to the neck concerning for large abscess vs cellulitis.

The diagnostic evaluation included laboratory testing with blood cultures (Table). The patient was started on broad spectrum IV antibiotics: ampicillin/sulbactam and vancomycin, as methicillin-resistant *Staphylococcus aureus* was also considered given her recent hospital admission. A

CPC-EM Capsule

What do we already know about this clinical entity?
Lemierre syndrome is a rare clinical diagnosis that carries high morbidity and mortality if not identified early.

What makes this presentation of disease reportable?
The disease usually presents with thrombus in the internal jugular vein. In our case, disease pathology was observed via the much smaller anterior jugular vein.

What is the major learning point?
If a patient presents with an active or recent neck infection and shortness of breath, Lemierre syndrome should be on the differential diagnosis.

How might this improve emergency medicine practice?
Early recognition and antibiotics, as well as early consultation with appropriate consultants, can improve patient outcomes with Lemierre syndrome.

dental consultation was obtained and an incision and drainage of an abscess at tooth 19 was performed prior to computed tomography (CT) imaging. A CT soft tissue neck with IV

Table. Complete blood count and complete metabolic panel of patient with Lemierre syndrome.

	Result	Reference range
White blood cells	18.0x10 ³ /mcL	4.5-13.5x10 ³ /mcL
Hemoglobin	11.9 gm/dL	12.0-15.0 gm/dL
Hematocrit	36.7%	34.0-43.0%
Platelets	396x10 ³ /mcL	135-430x10 ³ /mcL
Neutrophil %	94.1%	40.0-75.0%
Sodium (Na ⁺)	140 mmol/L	138-145 mmol/L
Potassium (K ⁺)	4.5 mmol/L	3.4-4.7 mmol/L
Chloride (Cl ⁻)	103 mmol/L	96-109 mmol/L
Carbon dioxide (CO ₂)	26 mmol/L	20-28 mmol/L
Blood urea nitrogen	10 mg/dL	7.0-16.8 mg/dL
Creatinine	0.5 mg/dL	0.5-1.1 mg/dL
Glucose	166 mg/dL	60-100 mg/dL
Lactic acid	1.9 mmol/L	< 2.0 mmol/L

mcL, microliters; *gm*, gram; *dL*, deciliter; *mmol*, millimole; *L*, liter; *mg*, milligram.

contrast was ordered. A CT chest was also ordered to further evaluate her recent history of “lung infection,” fatigue with ambulation, and rales on pulmonary exam. Care coordination occurred with the radiologist to consider both pneumonia and pulmonary septic emboli. The radiologist recommended a traditional pulmonary embolus protocol study.

CT findings were consistent with a diagnosis of Lemierre syndrome. CT neck images revealed a 3.2 cm area of ill-defined low density and gas in the left buccal perimandibular soft tissues, concerning for site of reported abscess status-post incision and drainage. There were numerous small areas of low attenuation overlying thickening in the left submandibular soft tissues, raising concern for possible cellulitis or thrombophlebitis sequelae (Image 1). Finally, thrombus of the left anterior jugular vein was visualized, as well as suspected thrombus of the superficial facial vein branches and left perimandibular regions. CT chest study revealed numerous cavitating nodular consolidations concerning for septic emboli given the patient’s history, in addition to a small right pleural effusion (Image 2). Pulmonology, vascular surgery, and infectious disease were consulted by the ED, and care was transitioned to the admitting hospitalist.

The patient was continued on IV antibiotics as an inpatient. Blood cultures remained negative throughout inpatient stay. Given a concern for endocarditis, a transthoracic echocardiogram was performed followed by a transesophageal echocardiogram. Both were negative for any signs of endocarditis or structural heart abnormalities. Vascular surgery did not recommend anticoagulation. The patient remained stable, transitioned to oral antibiotics, and

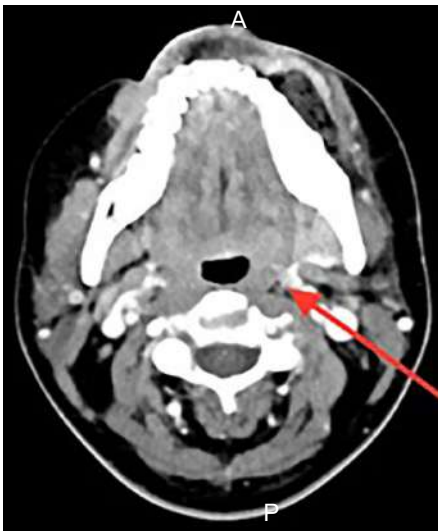


Image 1. Computed tomography soft tissue neck with intravenous contrast demonstrating thickening in the left submandibular soft tissues concerning for cellulitis or the sequela of thrombophlebitis (arrow), with thrombus of the left anterior jugular vein and suspected thrombus of the superficial branches of the superficial facial vein branches and left perimandibular region.

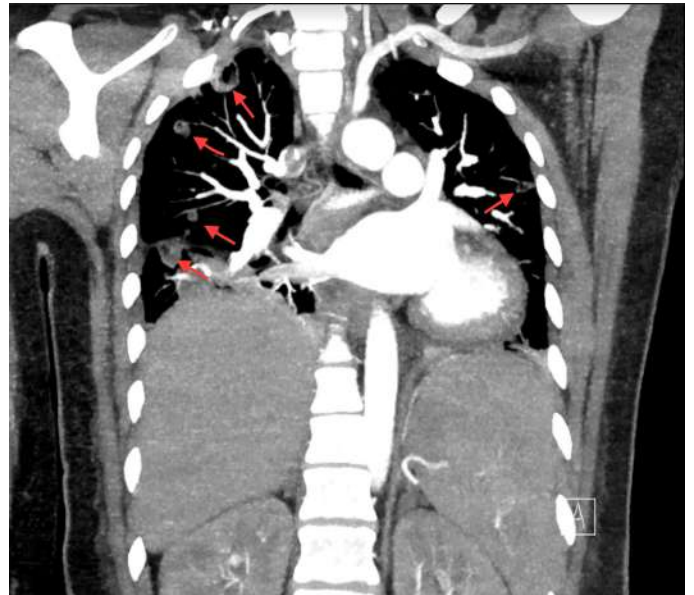

Image 2. Computed tomography chest pulmonary embolism protocol, demonstrating numerous cavitating nodular consolidations (arrows), concerning for septic emboli.

was discharged home on a two-week course of sulfamethoxazole/trimethoprim and amoxicillin/clavulanic acid. During a follow-up appointment in primary care clinic one week after discharge, she remained afebrile without any new complaints. The plan was made to finish her oral antibiotic course and follow up with pulmonology in the clinic for a repeat CT chest study and re-evaluation.

DISCUSSION

As documented in the literature, Lemierre syndrome is classically associated with thrombus of the internal jugular vein; however, there are only limited case reports demonstrating involvement of the smaller anterior jugular vein.⁵ Although otherwise healthy, these patients may appear acutely ill with tachycardia, tachypnea, hypotension, and oxygen saturation less than 95%.⁶ Typical lab findings of Lemierre syndrome are notable for neutrophilic leukocytosis and signs of organ insult to the affected organs.⁶ CT soft tissue neck with IV contrast best confirms septic thrombophlebitis, while CT chest may show multiple necrotic cavitory lesions, characteristic of Lemierre syndrome.^{2,3} Septic emboli have been reported in the lungs, kidneys, liver, joints, peritoneum, and brain.³

F. necrophorum is usually susceptible to beta-lactam antibiotics, such as penicillin, as well as protein and deoxyribonucleic acid synthesis inhibitors, such as clindamycin, and metronidazole, respectively, but is resistant to macrolides.⁷ Additionally, some *F. necrophorum* are capable of producing beta-lactamase, and develop resistance to beta-lactam antibiotics.⁸ As a result, patients are generally treated with metronidazole, carbapenem, or a penicillin/

beta-lactamase inhibitor combination. Although the overall incidence is about 0.6–3.6 cases per million, incidence rates appear to be increasing likely because of antibiotic resistance.⁷ Decisions on pharmacological treatment are case-dependent.^{2,9}

The use of anticoagulation therapy has been controversial and varies on an individual basis. Since Lemierre syndrome is rare, it is essentially impossible to collect direct outcome measures based on anticoagulation therapy.¹⁰ Anticoagulation therapy, in the case of Lemierre syndrome, is aimed at preventing possible life-threatening consequences of septic thromboembolism, such as respiratory failure, septic arthritis, and retrograde thrombophlebitis extending to intracranial sinuses.¹⁰ Because the disease is an inflammatory process, there is a possibility that resolution of inflammation could cause spontaneous improvement of the thrombosis.¹¹ Recanalization of the internal jugular vein has been observed in some patients; however, other authors have reported that recanalization is generally uncommon.^{11,12}

Successful management depends on an initial high index of suspicion and a multidisciplinary-team treatment approach.⁴

CONCLUSION

Lemierre syndrome is typically characterized as a septic thrombophlebitis of the internal jugular vein, or less commonly the anterior jugular vein. The condition is frequently attributed to infection with *F. necrophorum* and may progress to septic shock if left untreated. Since the syndrome is so rare, there is no established standard of care with regard to antibiotic treatment. Implementation of anticoagulation therapy continues to remain a controversial topic that varies on an individual basis. Due to the high risk of mortality associated with the disease, it is important for physicians to consider Lemierre syndrome as part of a differential diagnosis based on the presentation of the patient's clinical symptoms, history, and radiologic findings.

The Institutional Review Board approval has been documented and filed for publication of this case report.

REFERENCES

1. Ferri FF. (2020). Lemierre syndrome. *Ferri's Clinical Advisor 2020: 5 Books in 1* (828.e5-6). Philadelphia, PA: Elsevier.

Address for Correspondence: Nima Rejali, DO, Hackensack University Medical Center, Department of Emergency Medicine, 30 Prospect Ave, Room 3620, Hackensack, NJ 07601. Email: Nima.rejali@hackensackmeridian.org.

Conflicts of Interest: By the CPC-EM article submission agreement, all authors are required to disclose all affiliations, funding sources and financial or management relationships that could be perceived as potential sources of bias. The authors disclosed none.

Copyright: © 2020 Rejali et al. This is an open access article distributed in accordance with the terms of the Creative Commons Attribution (CC BY 4.0) License. See: <http://creativecommons.org/licenses/by/4.0/>

2. Riordan T. Human Infection with *Fusobacterium necrophorum* (necrobacillosis), with a focus on Lemierre's syndrome. *Clin Microbiol Rev.* 2007;20(4):622-59.
3. Kuppalli K, Livorsi D, Talati NJ, et al. Lemierre's syndrome due to *Fusobacterium necrophorum*. *Lancet Infect Dis.* 2012;12(10):808-15.
4. Karkos PD, Asrani S, Karkos CD, et al. Lemierre's syndrome: a systematic review. *Laryngoscope.* 2009;119(8):1552-9.
5. Risoud M, Mortuaire G, Chevalier D, et al. Atypical Lemierre syndrome. *Eur Ann Otorhinolaryngol Head Neck Dis.* 2016;133(2):123-4.
6. Johannesen KM and Bodtger U. Lemierre's syndrome: current perspectives on diagnosis and management. *Infect Drug Resist.* 2016;9:221-7.
7. Dalen CT and Mekhail AM. Lemierre syndrome: early recognition and management. *CMAJ Can Med Assoc J.* 2015;187(16):1229-31.
8. Golpe R, Marín B, Alonso M. Lemierre's syndrome (necrobacillosis). *Postgrad Med J.* 1999;75(881):141-4.
9. Osowicki J, Kapur S, Phuong LK, et al. The long shadow of Lemierre's syndrome. *J Infect.* 2017;74:S47-53.
10. Bondy P and Grant T. Lemierre's Syndrome: What are the roles for anticoagulation and long-term antibiotic therapy? *Ann Otol Rhinol Laryngol.* 2008;117(9):679-83.
11. Agrafiotis M, Moulara E, Chloros D, et al. Lemierre syndrome and the role of modern antibiotics and therapeutic anticoagulation in its treatment. *Am J Emerg Med.* 2015;33(5):733.e3-4.
12. Lustig LR, Cusick BC, Cheung SW, et al. Lemierre's syndrome: two cases of postanginal sepsis. *Otolaryngol Neck Surg.* 1995;112(6):767-72.

COVID-19 with Hypoxic Respiratory Failure

Miguel A. Martinez-Romo, MD
Shahram Lotfipour, MD, MPH
C. Eric McCoy, MD, MPH

University of California, Irvine Medical Center, Department of Emergency Medicine,
Orange, California

Section Editor: Rick A. McPheeters, DO

Submission history: Submitted June 16, 2020; Revision received June 26, 2020; Accepted July 3, 2020

Electronically published July 16, 2020

Full text available through open access at http://escholarship.org/uc/uciem_cpchem

DOI: 10.5811/cpchem.2020.7.48793

Case Presentation: We describe an elderly male presenting to the emergency department with shortness of breath that progressed to hypoxic respiratory failure. Radiography and computed tomography findings were suggestive of coronavirus disease 2019 (COVID-19).

Discussion: We review the clinical presentation of COVID-19 and its complications. We also describe the characteristic presentation of COVID-19 on imaging. Our case illustrates the hallmark findings of bilateral and peripheral ground-glass opacities of COVID-19. [Clin Pract Cases Emerg Med. 2020;4(3):458–460.]

Keywords: *Coronavirus Disease 2019; Coronavirus; COVID-19; ground-glass opacities; chest computed tomography.*

CASE PRESENTATION

A 70-year-old male with a history of hypertension and chronic kidney disease presented to the emergency department (ED) with cough, fevers, and worsening shortness of breath for two weeks. He saw his primary-care physician a week prior and received azithromycin and oseltamivir and was also tested for coronavirus disease 2019 (COVID-19), which was negative. Initial vitals were temperature 38.7°Celsius, blood pressure 176/87 millimeters of mercury, respirations of 22 breaths per minute, and oxygen saturation of 86% on room air. His exam was significant for tachypnea and diffuse crackles bilaterally. Despite non-invasive oxygenation, he progressed to hypoxic respiratory failure and required intubation. Chest imaging revealed multifocal peripheral bilateral ground-glass opacities suggestive of COVID-19. (Images 1-3) He was admitted to the intensive-care unit and subsequently tested positive for COVID-19.

DISCUSSION

Severe acute respiratory syndrome coronavirus 2 causes COVID-19.¹ The virus was first described in China in 2019 as the cause of a cluster of severe cases of viral pneumonia.² The disease spread globally and was declared a pandemic on March 11, 2020.³ The clinical presentation of COVID-19

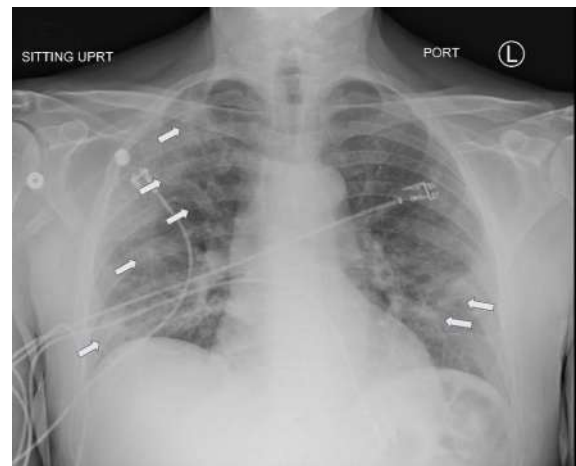

Image 1. Radiograph demonstrating multifocal patchy ill-defined opacities (arrows) in bilateral lung fields, suggestive of atypical/viral pneumonia.

is non-specific and includes fever, cough, fatigue, myalgias, shortness of breath, sore throat, and gastrointestinal symptoms.⁴ Complications include acute respiratory distress syndrome, septic shock, respiratory failure, and death.⁴ In a study from China, computed tomography (CT) was 86.2% sensitive for

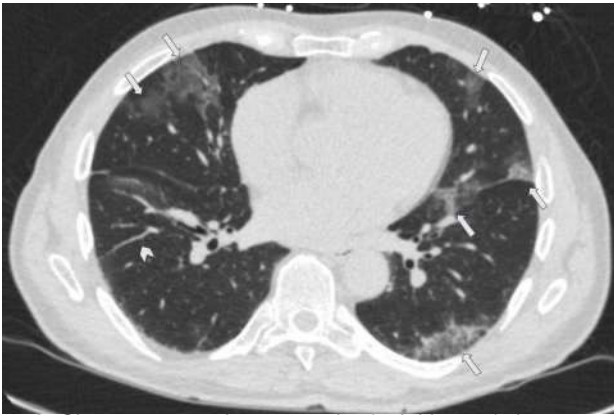

Image 2. Chest computed tomography (axial image) demonstrating multifocal peripheral bilateral ground glass opacities (arrows) with interlobular septal thickening (arrowhead) and mild peribronchial thickening, suggestive of infectious/inflammatory airway disease which can be seen in the setting of COVID-19.

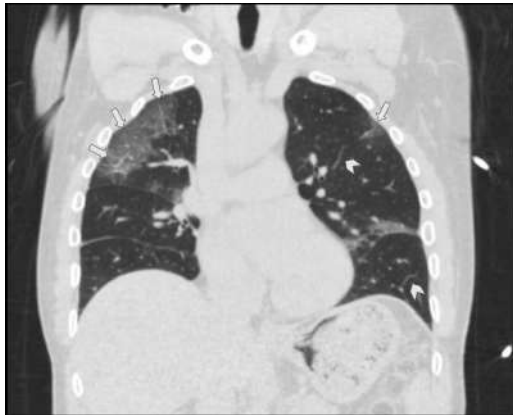


Image 3. Chest computed tomography (coronal image) demonstrating multifocal peripheral bilateral ground glass opacities (arrows) with interlobular septal thickening (arrowheads) and mild peribronchial thickening, suggestive of infectious/inflammatory airway disease which can be seen in the setting of COVID-19.

COVID-19, while radiograph was 59.1% sensitive.⁴ The hallmark findings of COVID-19 on CT are bilateral and peripheral ground-glass and consolidative pulmonary opacities,⁵ which this patient had. Other findings include linear opacities, “crazy-paving” pattern (area of ground-glass opacification with interlobular septal thickening and intralobular lines), the “reverse halo” sign (area of ground-glass opacification with a ring of dense consolidation), local patchy shadowing, bilateral patchy shadowing, and interstitial abnormalities.^{4,5}

The authors attest that their institution requires neither Institutional Review Board approval, nor patient consent for publication of this image in emergency medicine. Documentation on file.

CPC-EM Capsule

What do we already know about this clinical entity?

Coronavirus disease 2019 (COVID-19) has a spectrum of clinical presentations, from asymptomatic or mild viral symptoms, to respiratory distress, respiratory failure, severe disease, and death.

What is the major impact of the image(s)?

We present the classic presentation of COVID-19 on chest radiography and computed tomography, which can assist providers in making a diagnosis.

How might this improve emergency medicine practice?

Recognizing COVID-19 on imaging studies can help providers increase their index of suspicion, given the variable speed and availability of confirmatory testing.

Address for Correspondence: C. Eric McCoy, MD, MPH, University of California, Irvine Medical Center, Department of Emergency Medicine, 333 City Boulevard West, Suite 640, Orange, CA 92868. Email: cmccoy@hs.uci.edu.

Conflicts of Interest: By the CPC-EM article submission agreement, all authors are required to disclose all affiliations, funding sources and financial or management relationships that could be perceived as potential sources of bias. The authors disclosed none.

Copyright: © 2020 Martinez-Romo et al. This is an open access article distributed in accordance with the terms of the Creative Commons Attribution (CC BY 4.0) License. See: <http://creativecommons.org/licenses/by/4.0/>

REFERENCES

1. World Health Organization. Naming the coronavirus disease (COVID-19) and the virus that causes it. 2020. Available at: [https://www.who.int/emergencies/diseases/novel-coronavirus-2019/technical-guidance/naming-the-coronavirus-disease-\(covid-2019\)-and-the-virus-that-causes-it](https://www.who.int/emergencies/diseases/novel-coronavirus-2019/technical-guidance/naming-the-coronavirus-disease-(covid-2019)-and-the-virus-that-causes-it). Accessed April 3, 2020.
2. Wang D, Hu B, Hu C, et al. Clinical characteristics of 138 hospitalized patients with 2019 novel Coronavirus–Infected pneumonia in wuhan, china. *JAMA*. 2020;323(11):1061-9.
3. World Health Organization. WHO timeline - COVID-19. 2020. Available at: <https://www.who.int/news-room/detail/08-04-2020-who->

- timeline---covid-19. Accessed April 9, 2020.
4. Guan W, Ni Z, Hu Y, et al. Clinical characteristics of coronavirus disease 2019 in china. *N Engl J Med.* 2020;382(18):1708-20.
 5. Bernheim A, Mei X, Huang M, et al. Chest CT findings in coronavirus disease-19 (COVID-19): Relationship to duration of infection. *Radiology.* 2020;295(3):200463.

Crazy-Paving: A Computed Tomographic Finding of Coronavirus Disease 2019

Megan Gillespie, DO*
Patrick Flannery, DO*
Jessica A. Schumann, DO*
Nathan Dincher, DO*†
Rebecca Mills, MD*
Argun Can, MD†

*Jefferson Health - Northeast, Department of Emergency Medicine, Philadelphia, Pennsylvania

†Jefferson Health - Northeast, Department of Critical Care, Philadelphia, Pennsylvania

Section Editor: Rick A. McPheeters, DO

Submission history: Submitted May 1, 2020; Revision received May 11, 2020; Accepted May 11, 2020

Electronically published May 18, 2020

Full text available through open access at http://escholarship.org/uc/uciem_cpцем

DOI: 10.5811/cpcm.2020.5.47998

Introduction: Coronavirus disease 2019 (COVID-19) is caused by severe acute respiratory syndrome coronavirus 2.¹ COVID-19 first occurred in Wuhan, China, in December 2019, and by March 2020 COVID-19 was declared a global pandemic.¹

Case Presentation: We describe a case of a 52-year-old female with past medical history of asthma, type 2 diabetes, and previous tobacco use who presented to the emergency department with dyspnea and was found to be positive for COVID-19. We discuss the computed tomographic finding of “crazy-paving” pattern in the patient’s lungs and the significance of this finding in COVID-19 patients.

Discussion: Emergency providers need to be aware of the different imaging characteristics of various stages of COVID-19 to appropriately treat, isolate, and determine disposition of COVID-19 infected patients. Ground-glass opacities are the earliest and most common imaging finding for COVID-19.²⁻⁴ Crazy-paving pattern is defined as thickened interlobular septa and intralobular lines superimposed on diffuse ground-glass opacities and should be recognized by emergency providers as a radiographic finding of progressive COVID-19.²⁻⁴ [Clin Pract Cases Emerg Med. 2020;4(3):461–463.]

Keywords: *Coronavirus disease 2019; COVID-19; crazy-paving.*

CASE PRESENTATION

A 52-year-old female with past medical history of asthma, type 2 diabetes, and previous tobacco use presented to the emergency department with dyspnea. The patient denied fever/chills, congestion, or gastrointestinal symptoms. She denied recent travel or exposure to known sick contacts. She presented afebrile, tachycardic, tachypneic, hypoxic with pulse oximetry measuring 79% on room air, and had mild conversational dyspnea with diminished auscultated breath sounds bilaterally. The patient had imaging findings as below (Images 1, 2, and 3) and laboratory abnormalities of elevated D-dimer, fibrinogen, lactate dehydrogenase, ferritin,

C-reactive protein, lactic acid, glucose, aspartate aminotransferase, and alanine aminotransferase, in conjunction with a positive severe acute respiratory syndrome coronavirus 2 (SARS-CoV-2) reverse transcriptase polymerase chain reaction assay.

The patient was started on mid-flow supplemental nasal cannula oxygen at 15 liters per minute, enoxaparin, azithromycin, and ceftriaxone, and was admitted to the hospital.

DISCUSSION

Coronavirus disease 2019 (COVID-19) is caused by SARS-CoV-2.¹ The COVID-19 outbreak first occurred in Wuhan,

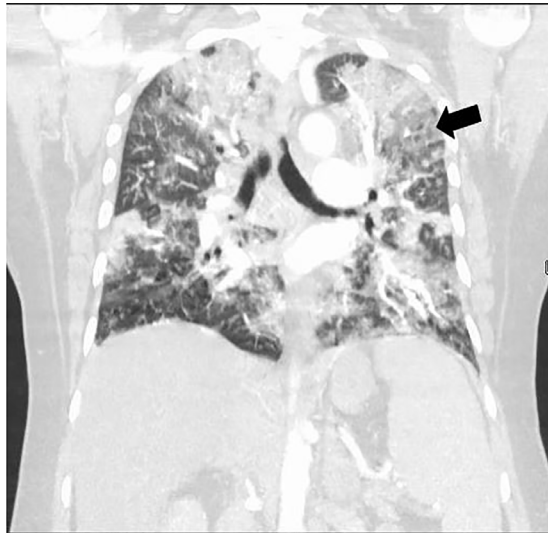


Image 1. Crazy-paving pattern noted on computed tomography chest of coronavirus disease 2019 patient as manifested by multiple, patchy ground-glass opacities with reticular and interlobular septal thickening and intralobular lines in the coronal plane. Crazy-paving pattern can be seen in both lung fields, but the tile-like or stone pavement resemblance pattern is best noted in the left upper lung (arrow).

China, in December 2019, and by March 2020, COVID-19 was declared a global pandemic.¹ Emergency physicians are on the front line to diagnose and treat this global health emergency. These images are intended to present the “crazy-paving”

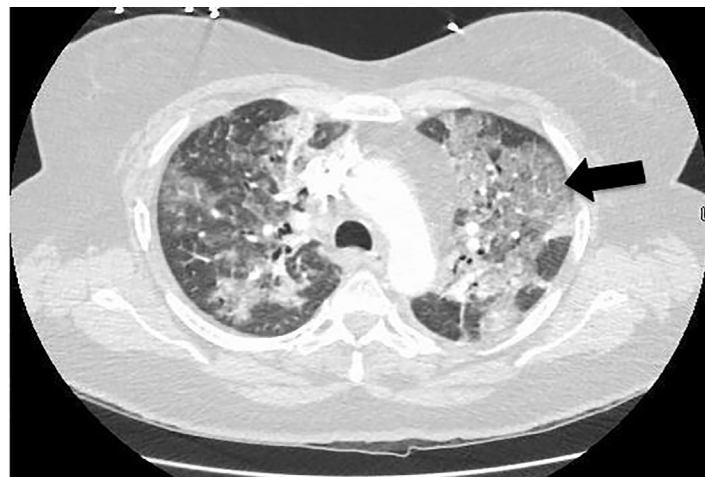

Image 2. Crazy-paving pattern noted on computed tomography chest of coronavirus disease 2019 patient as manifested by multiple, patchy ground-glass opacities with reticular and interlobular septal thickening and intralobular lines in the axial plane. Crazy-paving pattern can be seen in both lung fields, but the tile-like or stone pavement resemblance pattern is best noted in the left lung (arrow).

CPC-EM Capsule

What do we already know about this clinical entity?
Ground-glass opacities are the most common and frequently noted radiographic abnormality of corona virus disease 2019 (COVID-19).

What is the major impact of the image(s)?
Crazy-paving pattern – thickened interlobular septa and intralobular lines superimposed on diffuse ground-glass attenuation – is an imaging finding suggestive of progressive COVID-19.

How might this improve emergency medicine practice?
Awareness of imaging findings of COVID-19 will help providers appropriately treat, isolate, and determine the disposition of infected patients promptly.

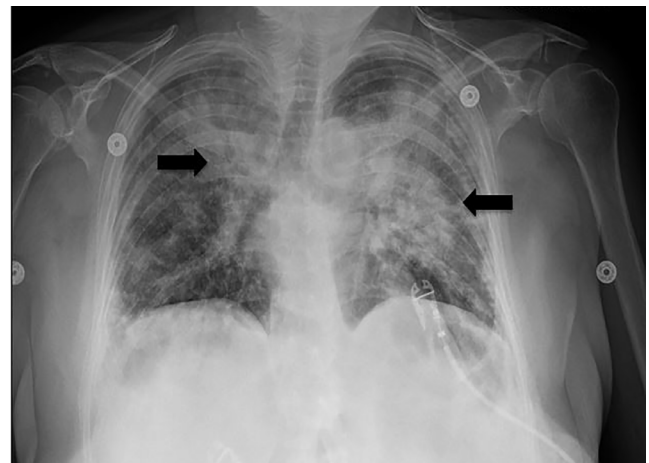


Image 3. Radiograph of this patient with coronavirus disease 2019 demonstrates dense patchy airspace disease bilaterally (arrows).

pattern, which is a computed tomographic (CT) finding of progressive COVID-19.

Ground-glass opacities, defined as hazy opacities compared to healthy lung, are the earliest and most commonly noted finding on CT for COVID-19.²⁻⁴ As COVID-19 progresses, a pattern known as “crazy-paving” can be noted on CT.³⁻⁴ Crazy-paving is

defined by the Fleischner Society as thickened interlobular septa and intralobular lines superimposed on diffuse ground-glass attenuation, and is named for its resemblance to stone pavement streets.²⁻⁵ Crazy-paving pattern is classically noted as a finding of pulmonary alveolar proteinosis, a rare lung disease, but this pattern is also caused by *Pneumocystis jiroveci* pneumonia, sarcoidosis, bronchioloalveolar carcinoma, amiodarone-induced nonspecific interstitial pneumonia, lipoid pneumonia, organizing pneumonia, acute respiratory distress syndrome, pulmonary hemorrhage syndromes, and, now, COVID-19.³⁻⁵

The authors attest that their institution requires neither Institutional Review Board approval, nor patient consent for publication of this image in emergency medicine. Documentation on file.

REFERENCES

1. The World Health Organization. 2020. Coronavirus disease 2019 (COVID-19) pandemic. Available at: <https://www.who.int/emergencies/diseases/novel-coronavirus-2019>. Accessed May 1, 2020.
2. Hansell DM, Bankier AA, MacMahon H, et al. Fleischner Society: glossary of terms for thoracic imaging. *Radiology*. 2008;246(3):697-722.
3. Ye Z, Zhang Y, Wang Y, et al. [Ahead of Print]. Chest CT manifestations of new coronavirus disease 2019 (COVID-19): a pictorial review. *Eur Radiol*. March 19, 2020.
4. Salehi S, Abedi A, Balakrishnan S, et al. [Ahead of Print]. Coronavirus disease 2019 (COVID-19): a systematic review of imaging findings in 919 patients. *AJR Am J Roentgenol*. Accessed March 14, 2020.
5. Rossi SE, Erasmus JJ, Volpacchio M, et al. "Crazy-paving" pattern at thin-section CT of the lungs: radiologic-pathologic overview. *RadioGraphics*. 2003;23(6):1509-19.

Address for Correspondence: Megan Gillespie, DO, Jefferson Health - Northeast, Department of Emergency Medicine, Graduate Medical Education Office, % Mary Allegrini, 10800 Knights Road, Philadelphia, PA 19114. Email: megan.gillespie@jefferson.edu.

Conflicts of Interest: By the CPC-EM article submission agreement, all authors are required to disclose all affiliations, funding sources and financial or management relationships that could be perceived as potential sources of bias. The authors disclosed none.

Copyright: © 2020 Gillespie et al. This is an open access article distributed in accordance with the terms of the Creative Commons Attribution (CC BY 4.0) License. See: <http://creativecommons.org/licenses/by/4.0/>

48-year-old with Coronavirus Disease 2019

Holly Gil, MD*
Ryan M. Finn, MD†
Neha P. Raukar, MD, MS†

*Brown University, Department of Radiology, Providence, Rhode Island
†Mayo Clinic, Department of Emergency Medicine, Rochester, Minnesota

Section Editor: Rick A. McPheeters, DO

Submission history: Submitted April 11, 2020; Revision received April 28, 2020; Accepted April 28, 2020

Electronically published May 7, 2020

Full text available through open access at http://escholarship.org/uc/uciem_cpem

DOI: 10.5811/cpem.2020.4.47648

Case Presentation: A 48-year-old male who presented with signs and symptoms suggestive of an upper respiratory infection was seen at an urgent care, he had a negative chest radiograph and was discharged. With no other cases of coronavirus disease 2019 (COVID-19) in the state, the patient presented to the emergency department two days later with worsening shortness of breath.

Discussion: There are a variety of findings on both chest radiograph and computed tomography of the chest that suggests COVID-19. [Clin Pract Cases Emerg Med. 2020;4(3):464–465.]

Keywords: COVID-19; imaging; Xray (radiograph); CT (computed tomography).

CASE PRESENTATION

A 48-year-old man with a history of asthma and reflux presented to the emergency department (ED) with a dry cough, sore throat, pleuritic chest pain, and dyspnea on exertion a week after serving as a tour guide in Europe and sharing equipment with other tour guides. He had been seen at an urgent care two days prior where he had a normal chest radiograph (CXR) and was discharged. On arrival to the ED, he was hemodynamically stable but had an oxygen saturation of 87% on room air, was tachypneic, using accessory muscles, and was febrile to 103.2° Fahrenheit. He was intubated secondary to respiratory distress. CXR and computed tomography (CT) were done in the ED, and it was later confirmed he was infected by severe acute respiratory syndrome coronavirus 2 (SARS-CoV-2),¹ which causes coronavirus disease 2019 (COVID-19).²

The primary finding on CXR is airspace opacities that are often bilateral or peripheral and found typically in the lower zones (Image 1).^{3,4}

While there are over a dozen non-specific findings suggestive of COVID-19 on CT, those with the highest discriminatory values were ground-glass opacities (GGO), and GGO that are bilateral and/or peripheral in distribution (Image 2).⁵

DISCUSSION

Given the infectious nature of SARS-CoV-2, a portable, single-view CXR is preferred to limit contamination.⁶ Of those hospitalized, CXR is abnormal 69% of the time and findings are most prominent 10–12 days after symptom onset.⁴

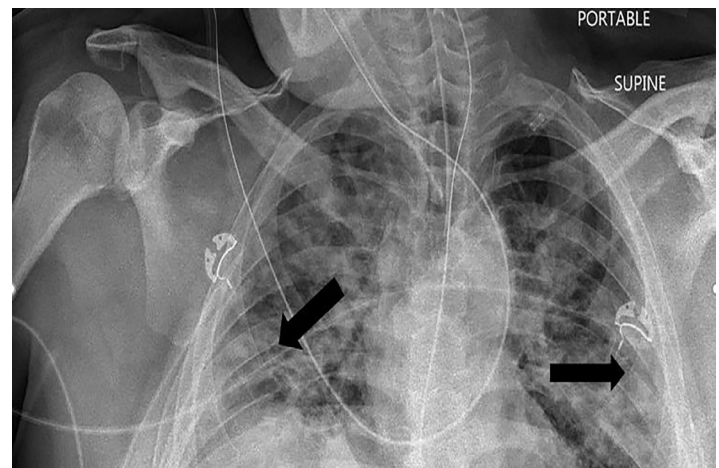


Image 1. Chest radiograph with peripheral airspace opacities (arrows).

Within the first two days of symptom onset, CT is normal 56% of the time, and after day three of symptoms is abnormal in at least 90% of patients.⁷ Despite the non-specific nature of these findings, radiologists are able to distinguish between COVID-19 and viral pneumonia with high specificity and moderate sensitivity.⁵ Although not diagnostic, imaging can suggest the presence of COVID-19 disease, and the American College of Radiology has adopted standardized language to reduce reporting variability.⁸

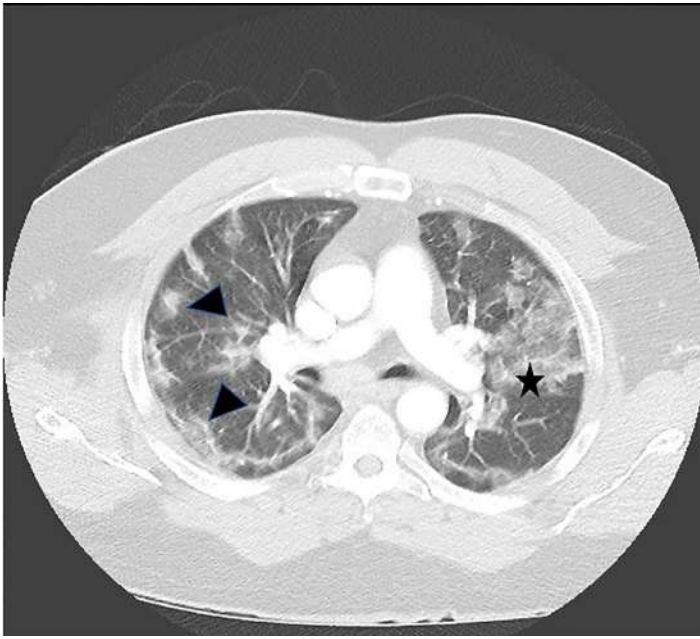


Image 2. Computed tomography of the chest with contrast that demonstrates peripheral, ground-glass opacities (GGO) (arrowheads) in the periphery and a large area of GGO (star).

The authors attest that their institution requires neither institutional review board approval nor patient consent for publication of this image in emergency medicine. Documentation on file.

Address for Correspondence: Neha Raukar, MD, MS, Mayo Clinic, Department of Emergency Medicine, 200 First Street, Rochester, MN 55905. Email: raukar.neha@mayo.edu.

Conflicts of Interest: By the CPC-EM article submission agreement, all authors are required to disclose all affiliations, funding sources and financial or management relationships that could be perceived as potential sources of bias. The authors disclosed none.

Copyright: © 2020 Gil et al. This is an open access article distributed in accordance with the terms of the Creative Commons Attribution (CC BY 4.0) License. See: <http://creativecommons.org/licenses/by/4.0/>

REFERENCES

1. Gorbalenya AE, Baker SC, Baric RS, et al. Severe acute respiratory syndrome-related coronavirus: the species and its viruses – a statement of the Coronavirus Study Group. 2020. Available at: <https://www.biorxiv.org/content/10.1101/2020.02.07.937862v1>. Accessed February 26, 2020.
2. World Health Organization. Naming the coronavirus disease

CPC-EM Capsule

What do we already know about this clinical entity?

The high infectious state, especially when asymptomatic, and increased mortality seen with severe acute respiratory syndrome coronavirus 2 has led to a global pandemic.

What is the major impact of the image(s)?

Bilateral and/or peripheral airspace opacities on radiographs and computed tomography can help suggest infection before testing results are available.

How might this improve emergency medicine practice?

Early identification of potentially positive cases can help the healthcare team maintain vigilance in protecting themselves and when indicated and available, start treatment early.

(COVID-19) and the virus that causes it. Available at: [https://www.who.int/emergencies/diseases/novel-coronavirus-2019/technical-guidance/naming-the-coronavirus-disease-\(covid-2019\)-and-the-virus-that-causes-it](https://www.who.int/emergencies/diseases/novel-coronavirus-2019/technical-guidance/naming-the-coronavirus-disease-(covid-2019)-and-the-virus-that-causes-it). Accessed April 1, 2020.

3. Rodrigues JCL, Hare SS, Edey A, et al. An update on COVID-19 for the radiologist: A British Society of Thoracic Imaging statement. *Clin Radiol*. 2020;75(5):323-5.
4. Wong HYF, Lam HYS, Fong AH, et al. [Ahead of Print]. Frequency and distribution of chest radiographic findings in COVID-19 positive patients. *Radiology*. March 27, 2019.
5. Bai HX, Hsieh B, Xiong Z, et al. [Ahead of Print]. Performance of radiologists in differentiating COVID-19 from viral pneumonia on chest CT. *Radiology* March 10, 2020.
6. American College of Radiology. ACR recommendations for the use of chest radiography and computer tomography (CT) for suspected COVID-19 infection. 2020. Available at: <https://www.acr.org/Clinical-Resources/COVID-19-Radiology-Resources>. Accessed April 2, 2020.
7. Bernheim A, Mei X, Huang M, et al. [Ahead of Print]. Chest CT findings in coronavirus disease-19 (COVID-19): relationship to duration of infection. *Radiology*. February 20, 2020.
8. Simpson S, Kay FU, Abbara S, et al. [Ahead of Print]. Special Report: Radiological Society of North America Expert Consensus Statement on Reporting Chest CT Findings Related to COVID-19. Endorsed by the Society of Thoracic Radiology, the American College of Radiology, and RSNA. *J Thorac Imaging*. April 28, 2020.

Pulmonary Artery Dissection Post-blunt Thoracoabdominal Trauma

Daniel Quesada, MD*
Larissa A. Morsky, MD*
Amber Jones, DO†
Allan L. Capote, MD†

*Kern Medical, Department of Emergency Medicine, Bakersfield, California
†Kern Medical, Department of Surgery, Bakersfield, California
‡LAC+USC Medical Center, Department of Emergency Medicine, Los Angeles, California

Section Editor: Austin Smith, MD

Submission history: Submitted July 25, 2019; Revision received February 15, 2020; Accepted December 19, 2019

Electronically published June 2, 2020

Full text available through open access at http://escholarship.org/uc/uciem_cpem

DOI: 10.5811/cpcem.2019.12.44649

Background: Pulmonary artery dissection is a rare condition that is usually diagnosed in patients exhibiting chronic pulmonary arterial hypertension, congenital heart abnormalities or secondary to iatrogenic injury. Diagnosis is often made at autopsy as many patients experience sudden death when the pulmonary artery dissection progresses rapidly and ruptures into the pericardium, resulting in acute cardiac tamponade.

Case Presentation: We report a case of pulmonary artery dissection, which resulted from blunt thoracic trauma diagnosed in the emergency department. [Clin Pract Cases Emerg Med. 2020;4(3):466–467.]

Keywords: pulmonary artery dissection; blunt thoracic trauma.

CASE PRESENTATION

A 43-year-old restrained female with an unremarkable past medical history was involved in a frontal impact high-speed motor vehicle accident and presented to our emergency department with a deceleration injury. Upon arrival, she was alert and fully oriented with vital signs within normal limits. She reported vehicle airbag deployment, loss of consciousness on impact and noted sternal and abdominal pain. On physical examination, secondary trauma survey was positive for diffuse sternal and abdominal tenderness with a large seatbelt sign across the chest and abdomen. Focused assessment with sonography for trauma was positive in Morrison's pouch, consistent with significant thoracoabdominal trauma. A chest radiograph revealed mediastinal widening (Image 1) and a left-sided pneumothorax. Given concern for intrathoracic injury, a computed tomography (CT) angiography of the chest was performed and displayed a post-traumatic pulmonary artery dissection (PAD) with classic findings of true and false lumens (Image 2). Other CT findings included Cervical(C) 5, C6 and C7 transverse process fractures and a linear laceration at the inferior and posterior portion of

the right lobe of the liver with minimal amount of free fluid surrounding the liver.

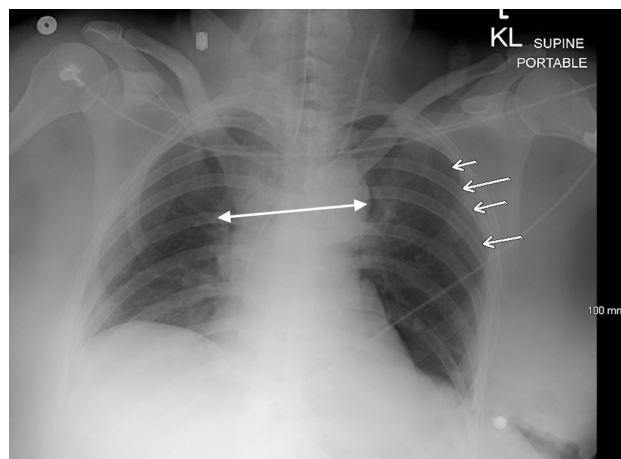


Image 1. Anteroposterior supine chest radiograph revealing slight mediastinal widening (double-headed arrow), pneumothorax (arrows), and multiple left-sided rib fractures.

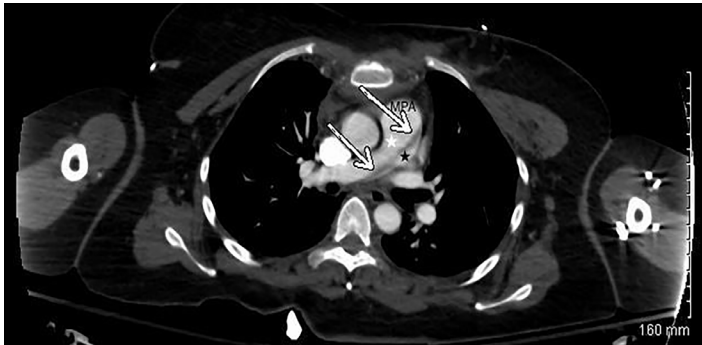

Image 2. Computed tomography angiography of the chest with intravenous contrast in axial view showing displacement of the left atrium (arrows). True (white star) and false (black star) lumens can also be visualized.

Since the PAD was deemed stable, an exploratory laparotomy was performed for clinical as well as radiographic findings, revealing 3 areas of mesenteric avulsion resulting in small bowel resection and control of hemorrhage. A damage control procedure was done with temporary abdominal closure, remained intubated and was transferred to an outside facility where she was lost to follow-up.

DISCUSSION

This report describes a case of traumatic PAD. Most reported traumatic injuries of the pulmonary artery have occurred secondary to blunt or penetrating chest trauma and result in rupture, pseudoaneurysm or both.^{1,2} The majority of patients with PAD are diagnosed post-mortem due to the condition manifesting as cardiogenic shock or sudden death when the dissection progresses rapidly and results in rupture.³ However, a recent review of the literature has noted over 90% of traumatic, non-iatrogenic pulmonary artery injuries of 50 reported since 1990 have resulted in survival of the patient.² Diagnosis in living patients has been made based on intraoperative findings or pulmonary arteriography.³ Clinical suspicion for a PAD should include: chest pain, cyanosis, pulmonary arterial hypertension and dyspnea.^{4,5}

Although there is no consensus on management due to the variation of mechanism of injury and rarity of the condition, the mainstay of treatment for traumatic PADs is a surgical or interventional approach.²

Documented Institutional Review Board approval has been obtained and filed for publication of this image in emergency medicine.

REFERENCES

1. Collins MP and Robinson GC. Traumatic Rupture of the Pulmonary

CPC-EM Capsule

What do we already know about this clinical entity?

The majority of reported pulmonary artery dissections are diagnosed post-mortem. Most of the reported dissections rupture, causing cardiogenic shock or sudden death.

What is the major impact of the image(s)?

A case of traumatic pulmonary artery dissection diagnosed in a living patient, displaying clear displacement of the left atrium.

How might this improve emergency medicine practice?

This case reminds emergency physicians to maintain pulmonary artery dissection in the differential when encountering high speed frontal impact deceleration injuries or other major traumatic injuries to the chest.

Address for Correspondence: Daniel Quesada, MD, Kern Medical Center, Department of Emergency Medicine, 1700 Mount Vernon Avenue, Bakersfield, CA 93306. Email: Rhabdo77k@gmail.com.

Conflicts of Interest: By the CPC-EM article submission agreement, all authors are required to disclose all affiliations, funding sources and financial or management relationships that could be perceived as potential sources of bias. The authors disclosed none.

Copyright: © 2020 Quesada et al. This is an open access article distributed in accordance with the terms of the Creative Commons Attribution (CC BY 4.0) License. See: <http://creativecommons.org/licenses/by/4.0/>

Artery. *Ann Thorac Surg.* 1989;47(4):612-3.

2. Yanagawa Y, Ishikawa K, Nagasawa H, et al. Traumatic pulmonary artery injury: a review of the recent literature. *Vessel Plus.* 2018;2:1.
3. Graham JK and Shehata B. Sudden death due to dissecting pulmonary artery aneurysm: a case report and review of the literature. *Am J Forensic Med Pathol.* 2007;28(4):342-4.
4. Jung LY. Is pulmonary artery dissection predictable? *Heart Lung.* 2016;45(1):79-80.
5. Khattar RS, Fox DJ, Alty JE, et al. Pulmonary artery dissection: an emerging cardiovascular complication in surviving patients with chronic pulmonary hypertension. *Heart.* 2005;91(2):142-5.

Chest Wall Pain after Minor Trauma

Deepak Chandwani, MD*†

Jeff Arnold‡

John Terrusa, MS, NRP, DMT, CCP‡

*California Task Force 6 - Urban Search and Rescue, Riverside, California

†Arrowhead Regional Medical Center, Department of Emergency Medicine, Colton, California

‡California Task Force 1 - Urban Search and Rescue, Los Angeles City Fire Department, Los Angeles, California

Section Editor: Rick A. McPheeters, DO

Submission history: Submitted February 14, 2020; Revision received May 26, 2020; Accepted June 1, 2020

Electronically published July 20, 2020

Full text available through open access at http://escholarship.org/uc/uciem_cpccem

DOI: 10.5811/cpcem.2020.6.46961

Case Presentation: A 30-year-old healthy male presented with a complaint of chest pain after mild thoracic trauma sustained while rescuing stranded flood victims during Hurricane Harvey. Careful physical examination revealed a tender palpable cord along the lateral aspect of his chest consistent with a superficial thrombophlebitis.

Discussion: Mondor's disease is a superficial thrombophlebitis with myriad underlying causes that can involve the thoracic wall. Although Mondor's disease has been well described in the literature, this case describes a unique presentation in an austere environment with blunt trauma as the underlying cause. [Clin Pract Cases Emerg Med. 2020;4(3):468–469.]

Keywords: *Mondor's disease; superficial thrombophlebitis; chest pain.*

CASE PRESENTATION

While deployed during Hurricane Harvey with a Federal Emergency Management Agency Task Force, a 30-year-old male presented to the medical team for left-sided chest pain. He had been leaning over the rail of a military truck during search and rescue operations and developed pain and a “pulling sensation” when moving his left upper extremity. He had no significant past medical history and was well appearing with normal vital signs. Examination of the chest revealed a tender palpable cord along the left anterolateral chest wall without overlying erythema or warmth (Image).

DISCUSSION

This case highlights a presentation of Mondor's disease secondary to blunt trauma in a unique, austere environment. Mondor's disease is a superficial thrombophlebitis first described by Charles Fagge in 1870 and later described by French surgeon Henri Mondor in 1939.^{1,2,3} Initially, the diagnosis referred specifically to superficial thrombophlebitis of the lateral thoracic, thoracoepigastric, or superior epigastric veins of the thoracoabdominal wall. Currently, the diagnosis has expanded to include thrombosis of the dorsal penile vein.^{2,4}

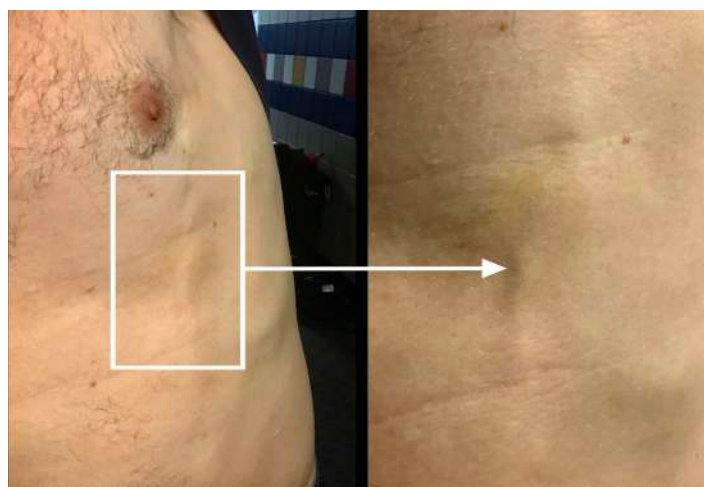


Image. Subcutaneous cord along the anterolateral thoracoabdominal wall.

The underlying etiology of Mondor's disease is varied and in many cases unknown. It can be related to trauma, physical activity, breast surgery, and rarely breast carcinoma.⁵ It is

thought that an initial injury to the vein leads to inflammation, thrombosis, and fibrosis, although some cases are believed to be related to lymphangitis.^{1,2} Symptoms typically last 4-8 weeks with spontaneous resolution. Treatment consists of non-steroidal anti-inflammatory drugs and warm compresses. It is imperative that possible underlying causes are considered such as disease processes that result in a hypercoagulable state, vasculitis/vascular diseases, carcinoma and, in the case of penile Mondor's disease, sexually transmitted diseases.² Diagnosis is generally based on clinical presentation; however, it can be confirmed with ultrasound.

Institutional Review Board approval has been obtained and filed for publication of this image in emergency medicine.

Address for Correspondence: Deepak Chandwani, MD, Arrowhead Regional Medical Center, Department of Emergency Medicine, 400 N. Pepper Ave, MOB Ste 107, Colton, CA 92324. Email: deepak.chandwani@vituity.com.

Conflicts of Interest: By the CPC-EM article submission agreement, all authors are required to disclose all affiliations, funding sources and financial or management relationships that could be perceived as potential sources of bias. The authors disclosed none.

Copyright: © 2020 Chandwani et al. This is an open access article distributed in accordance with the terms of the Creative Commons Attribution (CC BY 4.0) License. See: <http://creativecommons.org/licenses/by/4.0/>

REFERENCES

1. Yordanov Y. Trauma on a recently augmented breast as a trigger for

CPC-EM Capsule

What do we already know about this clinical entity?

Mondor's disease is a superficial thrombophlebitis that can involve the chest wall, causing pain and discomfort.

What is the major impact of the image(s)?

This case highlights the importance of careful physical examination in a patient with chest pain.

How might this improve emergency medicine practice?

Increased awareness of Mondor's disease may lead to accurate diagnosis and appropriate therapeutic intervention, potentially minimizing unnecessary testing.

Mondor's disease. *Aesth Plast Surg.* 2019;43(4):927-9.

2. Amano A and Shimizu T. Mondor's disease: a review of the literature. *Intern Med.* 2018;57(18):2607-12.
3. Tröbinger C and Wiedermann C. Bodybuilding-induced Mondor's disease of the chest wall. *Phys Ther Sport.* 2017;23:133-5.
4. Hamilton J, Mossanen M, Strote J. Mondor's disease of the penis. *West J Emerg Med.* 2013;14(2):180.
5. Vijayalakshmi A and Anand S. Mondor's disease. *N Engl J Med.* 2017;376(23):e47.

Abdominal Computed Tomography with a Twist: The ‘Whirl Sign’ for Mesenteric Volvulus

Jodi Spangler, BA
Jonathan Ilgen, MD

University of Washington, School of Medicine, Department of Emergency Medicine,
Seattle, Washington

Section Editor: Scott Goldstein, MD

Submission history: Submitted January 23, 2020; Revision received none; Accepted March 7, 2020

Electronically published May 18, 2020

Full text available through open access at http://escholarship.org/uc/uciem_cpccem

DOI: 10.5811/cpcem.2020.3.46682

Case Presentation: A 55-year-old woman with a history of end-stage renal disease, peripheral vascular disease, and multiple prior abdominal surgeries presented to the emergency department with three days of diffuse, severe, abdominal pain with accompanying nausea, emesis, and food intolerance. A computed tomography (CT) of her abdomen demonstrated a “whirl” of small bowel and mesenteric vessels, raising suspicion for mesenteric volvulus and resultant small bowel obstruction.

Discussion: Mesenteric volvulus is a low incidence, high mortality condition; therefore, early recognition and operative intervention are critical. Patients with a “whirl sign” on CT are more likely to require surgical intervention for their small bowel obstruction. [Clin Pract Cases Emerg Med. 2020;4(3):470–471.]

Keywords: *Volvulus; whirl sign; bowel obstruction.*

CASE PRESENTATION

A 55-year-old woman with a history of end-stage renal disease, peripheral vascular disease, and multiple prior abdominal surgeries presented to the emergency department with three days of diffuse, severe, abdominal pain with accompanying nausea, emesis, and food intolerance. Her physical examination was remarkable for a soft, slightly distended abdomen with diffuse tenderness to palpation. She had no guarding or rebound. A computed tomography (CT) of her abdomen demonstrated a “whirl” of small bowel and mesenteric vessels (Video), raising suspicion for mesenteric volvulus and resultant small bowel obstruction.^{1,2}

In this patient, an exploratory laparotomy was performed amid concern for small bowel ischemia, and a mesenteric volvulus was confirmed intraoperatively. A small bowel resection with extensive adhesiolysis was performed, and multiple mesenteric lymph nodes were excised. The patient had an unremarkable postoperative course and was discharged home.

DISCUSSION

Mesenteric volvuli occur when bowel twists around its mesenteric root.¹ This results in bowel wall and vascular compression, with subsequent intestinal obstruction and ischemia. Mesenteric volvuli are classified as “primary” when occurring in the setting of an otherwise normal abdominal cavity, and

“secondary” when occurring in the setting of pre-existing lesions such as adhesions or malrotation.³ Abdominal pain is the typical presenting symptom, and despite its low incidence, mortality rates from mesenteric volvuli are high; thus, early recognition and operative intervention are critical.³ The “whirl sign” on CT imaging (Images 1 and 2) is a highly specific finding for intestinal

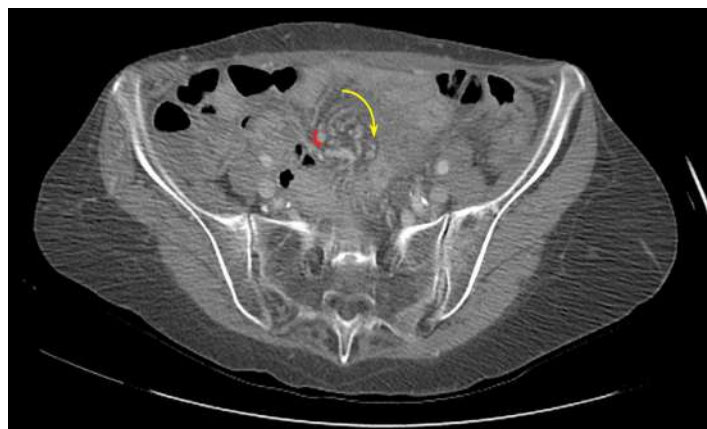


Image 1. Mesenteric whirl sign visualized on computed tomography (yellow arrow).

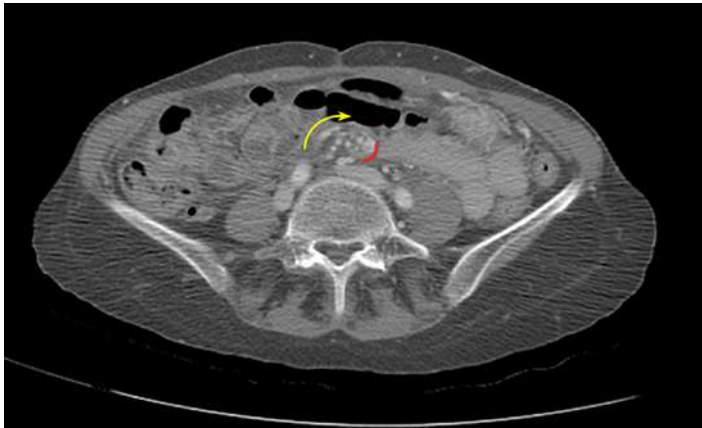

Image 2. Still images: Sequential computed tomography images demonstrate small bowel and mesenteric vessels rotating in mass with soft tissue and fat attenuation. Hash mark highlights the position of a specific piece of mesentery as it revolves; arrow indicates movement of the mass.

volvulus (albeit poorly sensitive), and should raise suspicion for a closed loop obstruction.⁴ Presence of the whirl sign is helpful for guiding management of patients with clinical and radiologic signs of small bowel obstruction, as patients with this finding are 25 times more likely to require surgery than those without this finding on imaging.⁴

Video. Mesenteric whirl sign. Computed tomography of the abdomen demonstrates a swirling mass (see arrow) of soft-tissue and fat attenuation indicative of twisted loops of small bowel and mesenteric vessels.

Patient consent has been obtained and filed for the publication of this image in emergency medicine.

REFERENCES

1. Fisher JK. Computed tomographic diagnosis of volvulus in intestinal malrotation. *Radiology*. 1981;140(1):145-6.
2. Khurana B. The whirl sign. *Radiology*. 2003;226(1):69-70.
3. Anton R and Leslie WO. Acute small bowel volvulus in adults: sporadic form of strangulating intestinal obstruction. *Ann Surg*. 1992;216(2):135-41.
4. Duda JB, Bhatt S, Dogra VS. Utility of CT whirl sign in guiding management of small-bowel obstruction. *AJR Am J Roentgenol*. 2008;191(3):743-7.

CPC-EM Capsule

What do we already know about this clinical entity?

Mesenteric volvulus occurs when bowels twists around its mesenteric root and can result in bowel wall and vascular compression, intestinal obstruction and ischemia.

What is the major impact of the image(s)?

Mesenteric volvulus is a low incidence, high mortality condition. Therefore, early recognition and operative intervention are critical.

How might this improve emergency medicine practice?

Whirl sign is helpful for guiding management of patients with signs of small bowel obstruction, as patients with this finding are more likely to require surgery.

Address for Correspondence: Jodi Spangler, BA, University of Washington School of Medicine, Department of Emergency Medicine, Harborview Medical Center, 325 9th Ave., Box 359702, Seattle, WA 98104. Email: jspang@uw.edu.

Conflicts of Interest: By the CPC-EM article submission agreement, all authors are required to disclose all affiliations, funding sources and financial or management relationships that could be perceived as potential sources of bias. The authors disclosed none.

Copyright: © 2020 Spangler et al. This is an open access article distributed in accordance with the terms of the Creative Commons Attribution ([CC BY 4.0](https://creativecommons.org/licenses/by/4.0/)) License. See: <http://creativecommons.org/licenses/by/4.0/>

Keratolysis Associated with Methamphetamine Use – Incidental Diagnosis of Corneal Melt in a Patient with Acute Methamphetamine Intoxication

Jagdipak S. Heer, MD*

Sean Heavey, MD*

Daniel Quesada, MD*†

Phillip Aguiñiga-Navarrete, RA*

Madison B. Garrett, RA*

Kieron Barkataki, DO*

*Kern Medical Center, Department of Emergency Medicine, Bakersfield, California

†LAC+ USC Medical Center, Department of Emergency Medicine, Los Angeles, California

Section Editors: Shadi Lahham, MD, MS

Submission history: Submitted August 15, 2019; Revision received February 13, 2020; Accepted March 10, 2020

Electronically published June 15, 2020

Full text available through open access at http://escholarship.org/uc/uciem_cpccem

DOI: 10.5811/cpcem.2020.3.43981

Case Presentation: A 38-year-old male presented to the emergency department with methamphetamine-induced agitation. Physical exam showed clouding of the left cornea, with gelatinous appearance and associated conjunctivitis, consistent with corneal melt, or keratolysis.

Discussion: Keratolysis is dissolution of the corneal stroma that can lead to corneal ulceration and vision loss. Smoking stimulants has been shown to be associated with this pattern of ocular injury, although this is a relatively rare presentation. Acute keratolysis is a unique complication of methamphetamine preparation and ingestion via smoking that can lead to corneal ulceration and loss of vision. [Clin Pract Cases Emerg Med. 2020;4(3):472–473.]

Keywords: *corneal ulceration; keratolysis; methamphetamine.*

CASE PRESENTATION

A 38-year-old male with a history of drug use was brought to the emergency department (ED) by law enforcement for evaluation of chest pain and acute agitation. The patient had a known history of methamphetamine use, and a urine drug screen in the ED was positive for methamphetamines. Complete medical history and initial physical exam were unable to be performed due to patient's agitation. Cardiac work-up, including chest radiograph, electrocardiograph, and troponin, was unremarkable. The patient was found to have elevated creatine kinase, concerning for rhabdomyolysis, but otherwise normal chemistries. He received benzodiazepines for his agitation and combativeness and was started on intravenous fluids for rhabdomyolysis.

Once he was calm, further physical examination was notable for clouding of the left cornea, with a gelatinous appearance overlying the left pupil and associated conjunctivitis (Image). The right pupil was normal. Formal visual acuity was not

performed as patient was unable to cooperate with the exam. After consulting with ophthalmology, it was determined the patient had keratolysis, likely associated with methamphetamine use. He was started on maxitrol and prednisone acetate drops with subsequent admission to internal medicine for management of methamphetamine-induced rhabdomyolysis.

DISCUSSION

Ocular injuries including corneal ulceration and ocular foreign bodies account for 1-2% of all ED visits.¹ Corneal ulceration is a feared complication of missed ocular injuries and can result in visual impairment. Keratolysis, or “corneal melting,” is a phenomenon well described in ophthalmology literature. It is defined as progressive dissolution of the corneal stroma, which if untreated can cause corneal perforation and vision loss. It is most commonly caused by autoimmune destruction, infection, or inflammation.² In rare cases, aerosolized and inhaled stimulant use, including crack cocaine and methamphetamine,

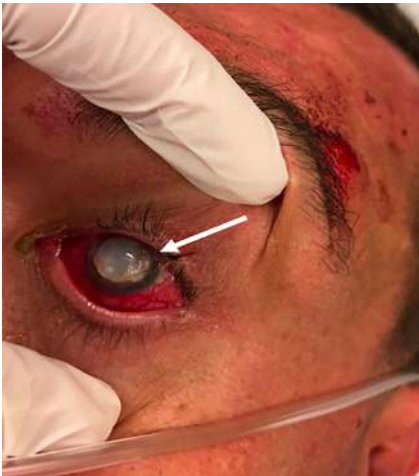

Image. Left eye showing clouding of the cornea, consistent with the diagnosis of corneal melting (arrow).

has been associated with keratitis and keratolysis.^{3,4} Although the exact mechanism of ocular injury is unknown, there are a number of factors related to drug use that may cause direct ocular injury including preparation of methamphetamine, smoking and thermal injuries, exposure to caustic chemicals used to produce methamphetamine, or exposure to impurities or additives used to dilute, or “cut” the methamphetamine.

Acute methamphetamine intoxication is a common problem seen in EDs, particularly in western states where methamphetamine use is highest.⁵ Acutely intoxicated patients may be aggressive toward staff, unable to communicate symptoms, or unable to participate with physical examination. Because of these challenges, missed diagnoses resulting in incomplete or delayed care are common.^{6,7} This case re-emphasizes the importance of careful and complete physical examinations in acutely agitated patients or patients presenting with clinical intoxication.

The Institutional Review Board approval has been documented and filed for publication of this image in emergency medicine.

REFERENCES

1. Nash EA and Margo CE. Patterns of emergency department visits for disorders of the eye and ocular adnexa. *Arch Ophthalmol.* 1998;116(9):1222-6.
2. Hossain P. The corneal melting point. *Eye (Lond).* 2012;26(8):1029-30.
3. Poulsen EJ, Mannis MJ, Chang SD. Keratitis in methamphetamine abusers. *Cornea.* 1996;15(5):477-82.
4. Ghosheh FR, Ehlers JP, Ayres BD, et al. Corneal ulcers associated with aerosolized crack cocaine use. *Cornea.* 2007;26(8):966-9.
5. Artigiani EE, Hsu MH, McCandlish D, et al. (2018). Methamphetamine: A Regional Drug Crisis. College Park, MD: National Drug Early Warning System.
6. Tucci V, Siever K, Matorin A, et al. Down the rabbit hole: emergency department medical clearance of patients with psychiatric or behavioral emergencies. *Emerg Med Clin North Am.* 2015;33(4):721-37.
7. Klein LR, Cole JB, Driver BE, et al. Unsuspected critical illness among emergency department patients presenting for acute alcohol intoxication. *Ann Emerg Med.* 2018;71(3):279-88.

CPC-EM Capsule

What do we already know about this clinical entity?

Corneal keratolysis is progressive dissolution of the corneal stroma, causing corneal ulceration and vision loss caused by infection, inflammation, or chemical injury.

What is the major impact of the image(s)?

Keratolysis is an uncommon ocular injury. Recognition and prompt treatment may help prevent further damage and vision loss.

How might this improve emergency medicine practice?

This image will aid in identification of corneal keratolysis and serve as a reminder of its possible association with smoking and manufacturing methamphetamine.

Address for Correspondence: Sean Heavey, MD, Kern Medical Center, Department of Emergency Medicine, 1700 Mount Vernon Ave., Bakersfield, CA 93306. Email: Sean.Heavey@kernmedical.com

Conflicts of Interest: By the *CPC-EM* article submission agreement, all authors are required to disclose all affiliations, funding sources and financial or management relationships that could be perceived as potential sources of bias. The authors disclosed none.

Copyright: © 2020 Heer et al. This is an open access article distributed in accordance with the terms of the Creative Commons Attribution ([CC BY 4.0](http://creativecommons.org/licenses/by/4.0/)) License. See: <http://creativecommons.org/licenses/by/4.0/>

Symptomatic Aortic Endograft Occlusion in a 70-year-old Male

Jose Cardenas, MD
Babak Khazaeni, MD

Desert Regional Medical Center, Department of Emergency Medicine, Palm Springs, California

Section Editor: Christopher Sampson, MD

Submission history: Submitted January 27, 2020; Revision received May 12, 2020; Accepted May 19, 2020

Electronically published July 9, 2020

Full text available through open access at http://escholarship.org/uc/uciem_cpccem

DOI: 10.5811/cpccem.2020.5.46734

Case Presentation: A 70-year-old male with prior aorta endovascular aneurysm repair presented with progressive lower extremity weakness over the course of several hours. There was noted loss of palpable bilateral femoral pulses in the emergency department. Computed tomography angiography revealed a kinked and occluded aortic endograft. He subsequently underwent successful axillobifemoral bypass revascularization.

Discussion: Kinking of endograft limbs and occlusion has been reported in a small percentage of patients. Bilateral leg ischemia due to aortic endograft occlusion is rare. [Clin Pract Cases Emerg Med. 2020;4(3):474–475.]

Keywords: *Emergency medicine; aortic endograft occlusion; leg ischemia; EVAR.*

CASE PRESENTATION

A 70-year-old male with a history of abdominal aorta endovascular aneurysm repair (EVAR) presented to the emergency department (ED) as a trauma activation after a fall and subsequent lower extremity weakness. The patient reported a near-syncopal episode the night preceding the fall and progressive lower extremity weakness over the course of the morning. On arrival to the ED, he complained of lower extremity weakness with noted initial 2+ palpable, bilateral femoral and dorsalis pedis pulses. Shortly thereafter, he lost palpable femoral pulses bilaterally and had noted cool lower extremities. Computed tomography angiography (CTA) was remarkable for kinking and occlusion of the abdominal aorta endograft below the renal vessels (Images 1-3). The patient was taken to the operating room emergently with successful axillobifemoral bypass revascularization.

DISCUSSION

The patient had undergone EVAR approximately three years prior and had been taking aspirin and clopidogrel but, per the patient, clopidogrel was recently discontinued by his primary care physician to decrease endoleak at aneurysm

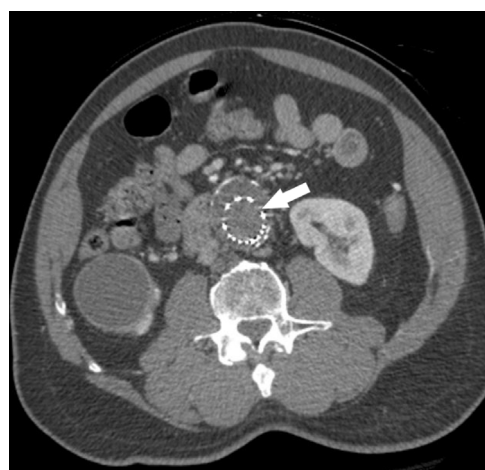


Image 1. Axial view of abdominal computed tomography angiography demonstrating absence of contrast within the aortic endograft, an indication of occlusion (arrow).

repair. CTA demonstrated a kinked endograft and thrombus within the graft into the iliac arteries. Kinking of endograft limbs and occlusion has been reported in 2-4% of patients,

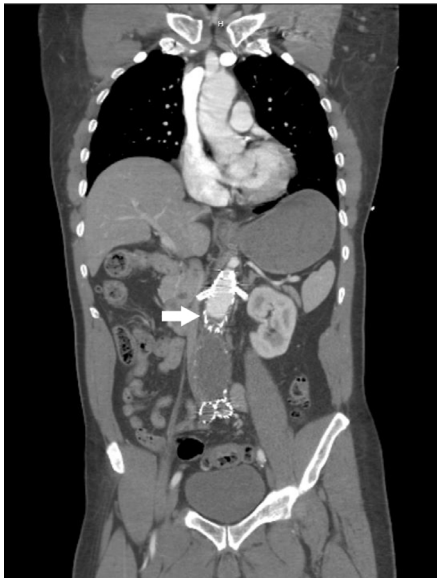

Image 2. Coronal view of abdominal computed tomography angiography demonstrating contrast reaching but not flowing past the site of occlusion at the aortic endograft (arrow).

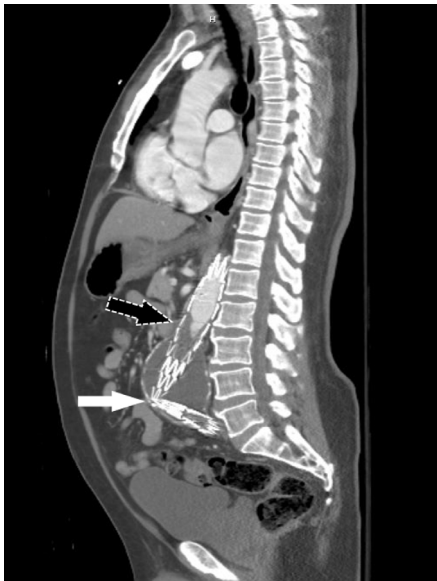

Image 3. Sagittal view of abdominal computed tomography angiography demonstrating kinking of the aortic endograft (white arrow) and the presence of contrast having reached the location of the thrombus (black arrow) within the endograft.

which can result in acute limb ischemia.^{1,2} Bilateral leg ischemia due to endograft occlusion is rare with a reported incidence ranging from 0%-0.6%.³

The authors attest that their institution requires neither Institutional Review Board approval, nor patient consent for publication of this image in emergency medicine. Documentation on file.

CPC-EM Capsule

What do we already know about this clinical entity?

Kinking and occlusion has been reported as a complication in 2-4% of patients who underwent endovascular aneurysm repair (EVAR) of the abdominal aorta.

What is the major impact of the image(s)?
These images demonstrate kinking and occlusion of the abdominal aorta EVAR endograft with resulting bilateral leg ischemia, which is very rare.

How might this improve emergency medicine practice?

Emergency physicians should consider endograft complications in patients with a history of EVAR presenting with lower extremity neurovascular complaints.

Address for Correspondence: Jose Cardenas, MD, Desert Regional Medical Center, Department of Emergency Medicine, 1150 N. Indian Canyon Drive, Palm Springs, CA 92262. Email: Jose3.Cardenas@tenethealth.com.

Conflicts of Interest: By the CPC-EM article submission agreement, all authors are required to disclose all affiliations, funding sources and financial or management relationships that could be perceived as potential sources of bias. The authors disclosed none.

Copyright: © 2020 Cardenas et al. This is an open access article distributed in accordance with the terms of the Creative Commons Attribution (CC BY 4.0) License. See: <http://creativecommons.org/licenses/by/4.0/>

REFERENCES

1. Daye D and Walker TG. Complications of endovascular aneurysm repair of the thoracic and abdominal aorta: evaluation and management. *Cardiovasc Diagn Ther.* 2018;8(Supple 1):S138-56.
2. EVAR Trial Participants. Endovascular Aneurysm Repair Versus Open Repair in Patients With Abdominal Aortic Aneurysm (EVAR Trial 1): randomised controlled trial. *Lancet.* 2005;365(9478):2179-86.
3. Moulakakis KG, Antonopoulos CN, Klonaris C, et al. Bilateral endograft limb occlusion after endovascular aortic repair: predictive factors of occurrence. *Ann Vasc Surg.* 2018;46:299-306.

De Winter T-wave Pattern in Proximal Left Anterior Descending Artery Occlusion

David Gregory, MD
Bryan Wexler, MD
Brent Becker, MD

Wellspring York Hospital, Department of Emergency Medicine, York, Pennsylvania

Section Editor: Christopher Sampson, MD

Submission history: Submitted March 18, 2020; Revision received May 14, 2020; Accepted May 20, 2020

Electronically published July 15, 2020

Full text available through open access at http://escholarship.org/uc/uciem_cpccem

DOI: 10.5811/cpcem.2020.5.47322

Case Presentation: We describe a case of an acute myocardial infarction with an atypical electrocardiogram showing a de Winter T-wave pattern suggesting the 100% proximal left anterior descending artery occlusion seen on emergent cardiac catheterization.

Discussion: Timely recognition of acute myocardial ischemia is paramount for emergency providers. As highlighted in this case, It is important to be mindful of atypical electrocardiogram findings, such as de Winter T-waves, which suggest acute myocardial ischemia. [Clin Pract Cases Emerg Med. 2020;4(3):476–477.]

Keywords: ECG; de Winter; T-wave; STEMI; AMI.

CASE PRESENTATION

A 56-year old male with a history of hypertension presented to the emergency department with one hour of crushing chest pain radiating to the left arm and neck. The symptoms began following exertion, but failed to alleviate with rest. Initial electrocardiogram (ECG) demonstrated hyperacute T-waves

with associated ST-segment depression in the precordial leads, consistent with a de Winter T-wave pattern¹ (Image 1). Due to concern for acute myocardial infarction (AMI), cardiology was consulted for possible percutaneous intervention (PCI).

Emergent cardiac catheterization was performed and revealed a 100% occlusion of the proximal left anterior

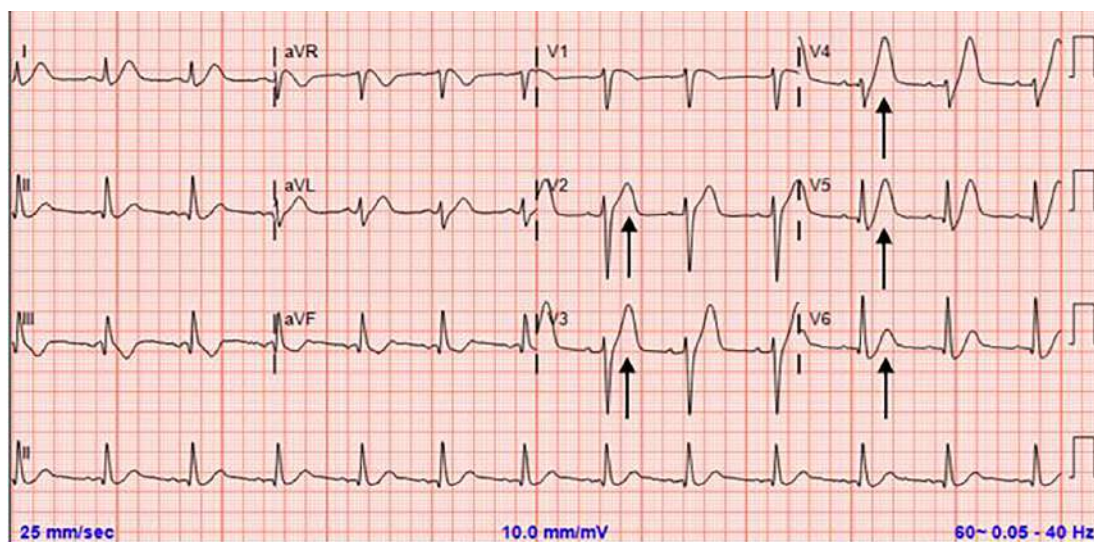


Image 1. Tall, prominent, symmetric T-waves with associated ST-segment depression in precordial leads (arrows).

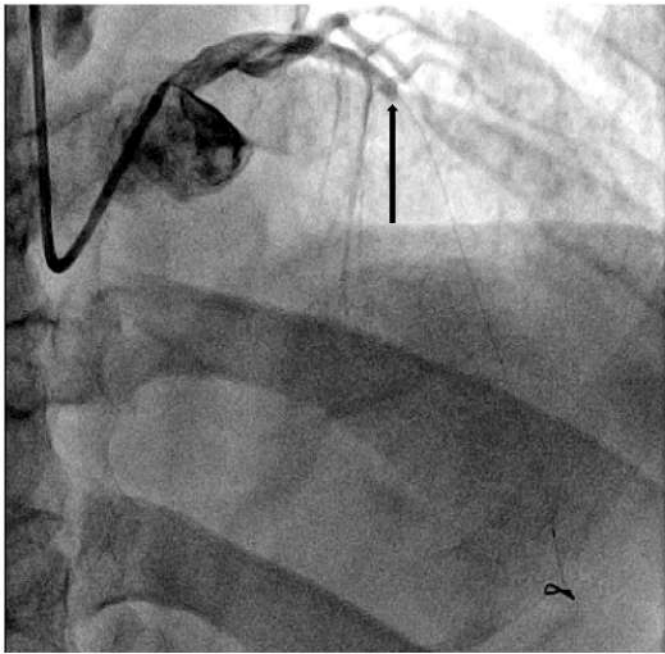


Image 2. Coronary angiography demonstrating occlusion of the proximal left anterior descending artery (arrow).

descending artery (Image 2). After successful PCI, the patient experienced no further complications and was subsequently discharged on appropriate medical management.

DISCUSSION

De Winter T-waves are characteristic prominent, symmetric precordial T-waves with associated upsloping ST-segment depression at the J-point.¹ This ECG pattern lacks traditional ST-segment elevations but is indicative of acute anterior ischemia.² Prior studies suggest approximately 2% of left anterior descending artery occlusions present with de Winter T-waves.³

Diagnosis of AMI can be challenging. Emergency physicians are well trained to recognize the pattern of contiguous ST-segment elevations with reciprocal depressions that define traditional criteria for an ST-elevated myocardial infarction (STEMI)²; however, clinicians must also be cognizant of atypical ECG findings that suggest acute myocardial ischemia, such as Wellens syndrome, patterns that meet modified Sgarbossa criteria, and as in this case, de Winter T-waves. These less common ECG nuances must be recognized and approached as a STEMI equivalent.

The authors attest that their institution requires neither Institutional Review Board approval, nor patient consent for publication of this image in emergency medicine. Documentation on file.

CPC-EM Capsule

What do we already know about this clinical entity?

De Winter T-waves are hyperacute precordial T-waves with associated upsloping ST-segment depressions that indicate acute anterior myocardial infarction (MI).

What is the major impact of the image(s)?

The electrocardiogram (ECG) demonstrates the de Winter T-wave pattern that emergency physicians must recognize as a ST-segment elevated MI equivalent.

How might this improve emergency medicine practice?

Recognition of atypical ECG patterns consistent with acute MI can facilitate prompt coronary intervention and salvage at-risk myocardium.

Address for Correspondence: David Gregory, MD, Wellspan York Hospital, Department of Emergency Medicine, 1001 S. George Street, York, PA 17403. Email: dave.l.gregory@gmail.com.

Conflicts of Interest: By the CPC-EM article submission agreement, all authors are required to disclose all affiliations, funding sources and financial or management relationships that could be perceived as potential sources of bias. The authors disclosed none.

Copyright: © 2020 Gregory et al. This is an open access article distributed in accordance with the terms of the Creative Commons Attribution ([CC BY 4.0](http://creativecommons.org/licenses/by/4.0/)) License. See: <http://creativecommons.org/licenses/by/4.0/>

REFERENCES

1. de Winter RJ, Verouden NJ, Wellens HJ, et al. A new ECG sign of proximal LAD occlusion. *NEJM*. 2008;359:2071-3.
2. Thygesen K, Alpert J, Jaffe A, et al. Fourth universal definition of myocardial infarction (2018). *Circulation*. 2018;138:e618-51.
3. Verouden NJ, Koch KT, Peters RJ, et al. Persistent precordial "hyperacute" T-waves signify proximal left anterior descending artery occlusion. *Heart*. 2009;95(20):1701-6.

Rare Cause of Syncope in a Gravid Female

Andrew Bellino, MD*
Katherine Staats, MD†
Jessica Ngo, MD†

*Stanford University School of Medicine, Emergency Medicine Residency Program, Stanford, California
†Stanford University School of Medicine, Department of Emergency Medicine, Stanford, California

Section Editor: Rick A. McPheeters, DO

Submission history: Submitted February 13, 2020; Revision received May 14, 2020; Accepted May 26, 2020

Electronically published July 14, 2020

Full text available through open access at http://escholarship.org/uc/uciem_cpem

DOI: 10.5811/cpem.2020.5.46948

Case Presentation: A 33-year-old gravid female was brought to the emergency department after she collapsed in the street. Point-of-care ultrasound showed free fluid in the abdomen and confirmed an intrauterine pregnancy. Surgical teams were consulted, and cross-sectional imaging revealed a spontaneously ruptured splenic artery aneurysm (SAA). The patient was taken expeditiously to the operating room for splenic artery ligation and subsequent splenectomy.

Discussion: Ruptured SAA in pregnant patients is associated with significant mortality for both mother and fetus. Maintaining a high index of suspicion in the correct population is crucial to avoid diagnostic errors and provide definitive care with operative repair. [Clin Pract Cases Emerg Med. 2020;4(3):478–479.]

Keywords: *splenic artery aneurysm; aneurysm rupture; pregnancy; syncope.*

CASE PRESENTATION

A 33-year-old gravida 1 para 0 at 18 weeks gestational age presented to the emergency department for syncope. The patient had passed out while crossing the street and emergency medical services were activated. She reported severe abdominal pain after arrival and vitals showed a heart rate of 120 beats per minute and a blood pressure of 88/52 millimeters of mercury. Point-of-care ultrasound showed free fluid in the left upper quadrant and confirmed an intrauterine pregnancy with good cardiac activity. Obstetrics and general surgery teams were consulted. Following improvement of the patient's vital signs with a crystalloid bolus, a computed tomography was performed, which revealed a spontaneously ruptured and previously undiagnosed 2.6-centimeter splenic artery aneurysm (SAA) (Images 1 and 2).

The patient was taken emergently to the operating room where surgeons evacuated six liters of blood that originated from her splenic artery rupture. Splenectomy was successful in stabilization; however, post-operatively no fetal heart rate was found and a dilation and evacuation was subsequently performed. The patient was discharged home on day 14.

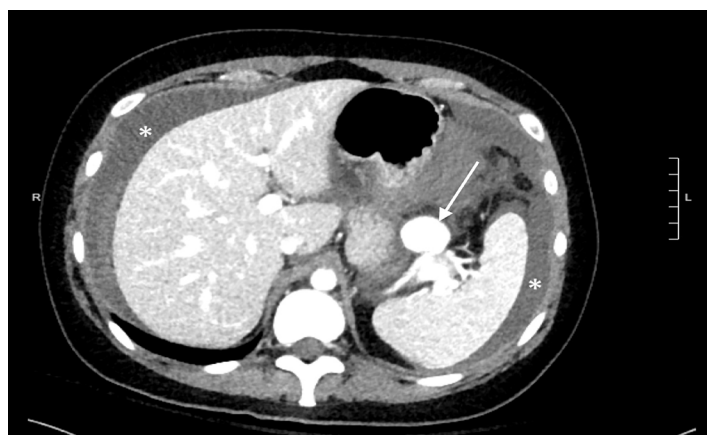

Image 1. Computed tomography axial section showing a large splenic artery aneurysm (arrow). There is also significant hemoperitoneum surrounding the liver and spleen (asterisks).

DISCUSSION

The true incidence of SAA is unknown; however, estimates range from 0.02-10.4%.^{1,2} Of those diagnosed, ruptured aneurysm is only seen in 5% of cases, and it is

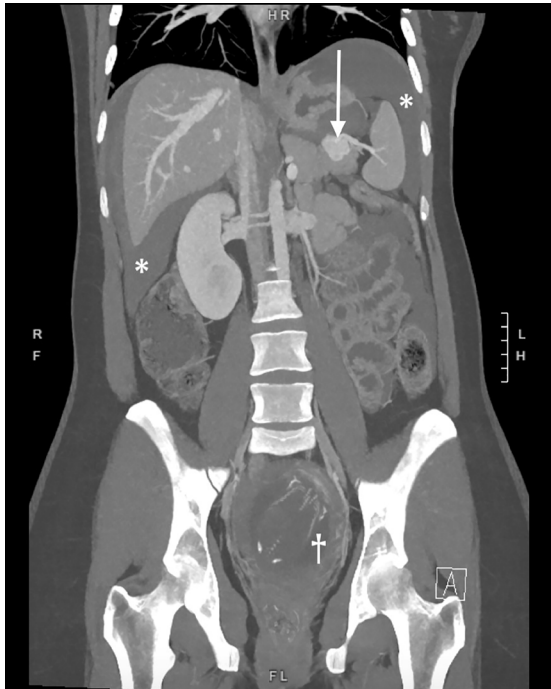

Image 2. Computed tomography coronal reformat showing the ruptured splenic artery aneurysm (arrow) and significant hemoperitoneum around the liver and spleen (asterisks). The gravid uterus with developing fetus is also noted within the pelvis (dagger), a combination rarely seen on imaging due to the high mortality of this disease.

associated with high mortality.^{2,3} SAA is more common in females (4:1) and is associated with pregnancy, hypertension, connective tissue disease, portal hypertension, and atherosclerosis.¹ Prophylactic treatment of unruptured aneurysm is recommended for women of childbearing age due to increased risk of rupture in pregnancy.^{2,4} Unfortunately, given its low incidence, ruptured aneurysm is often mistaken for more common pregnancy-related pathologies such as ruptured ectopic pregnancy, placental abruption, uterine rupture, pulmonary embolism, and perforated peptic ulcer.⁴ Prompt diagnosis and treatment with endovascular or open technique is crucial for maternal and fetal survival as mortality rates approach 70% and 90%, respectively.⁵

The authors attest that their institution requires neither Institutional Review Board approval, nor patient consent for publication of this image in emergency medicine. Documentation on file.

REFERENCES

1. Berceli S. Hepatic and Splenic artery aneurysms. *Semin Vasc Surg.* 2005;18(4):196-201.

CPC-EM Capsule

What do we already know about this clinical entity?

Splenic artery aneurysms are usually asymptomatic until ruptured at which point they are associated with high mortality. Pregnant women are at increased risk.

What is the major impact of the image(s)?

Images show ruptured aneurysm in conjunction with the developing fetus. These images are uncommon as such patients are often too unstable for advanced imaging.

How might this improve emergency medicine practice?

Understanding this deadly disease can improve emergency physicians' ability to quickly make the diagnosis and initiate effective treatment.

Address for Correspondence: Andrew Bellino, MD, Stanford University School of Medicine, Department of Emergency Medicine, 900 Welch Road, Palo Alto, CA 94304. Email: bellino@stanford.edu.

Conflicts of Interest: By the CPC-EM article submission agreement, all authors are required to disclose all affiliations, funding sources and financial or management relationships that could be perceived as potential sources of bias. The authors disclosed none.

Copyright: © 2020 Bellino et al. This is an open access article distributed in accordance with the terms of the Creative Commons Attribution (CC BY 4.0) License. See: <http://creativecommons.org/licenses/by/4.0/>

2. Abbas MA, Stone WM, Fowl RJ, et al. Splenic artery aneurysm: two decades experience at Mayo Clinic. *Ann Vasc Surg.* 2002;16(4):442-9.
3. Hogendoorn W, Lavidia A, Hunink MGM, et al. Open repair, endovascular repair, and conservative management of true splenic artery aneurysms. *J Vasc Surg.* 2014;60(6):1667-76.
4. Ha JF, Phillips M, Faulkner K. Splenic artery aneurysm rupture in pregnancy. *Euro J Obstetrics & Gyn Reprod Bio.* 2009;146(2):133-7.
5. Hillemanns P, Knitza R, Müller-Höcker J. Rupture of splenic artery aneurysm in a pregnant patient with portal hypertension. *Am J Obstet Gynecol.* 1996;174(5):1665-6.

Hirschsprung's Disease: A Rare Adult Diagnosis

Kaitlyn Schmutz, PA-C*
Gaea McGaig, PA-C†
B. Jason Theiling, MD‡

*Duke University Hospital, Department of Emergency Medicine, Durham, North Carolina
†Rex Hospital, Department of Emergency Medicine, Raleigh, North Carolina
‡Duke University School of Medicine, Department of Surgery, Division of Emergency Medicine, Durham, North Carolina

Section Editor: Manish Amin, DO

Submission history: Submitted January 10, 2020; Revision received May 28, 2020; Accepted June 1, 2020

Electronically published July 30, 2020

Full text available through open access at http://escholarship.org/uc/uciem_cpem

DOI: 10.5811/cpcem.2020.6.46492

Case Presentation: Approximately 94% of patients with Hirschsprung's disease (HD) are diagnosed before the age of five. In our case, a young adult with years of constipation presented to the emergency department with significant abdominal distention. He was ultimately diagnosed with HD, which was identified using computed tomography (CT).

Discussion: In HD, we find defects in gastric motility due to improper gut colonization. Without childhood recognition, HD often leads to chronic constipation and failure to thrive in adulthood. CT is a key step in identifying this rare adult diagnosis that should be considered in all patients with a history of chronic constipation. [Clin Pract Cases Emerg Med. 2020;4(3):480–481.]

Keywords: *Hirschsprung's disease; chronic constipation.*

CASE PRESENTATION

An 18-year-old male with history of chronic constipation (CC) presented to the emergency department complaining of left lower extremity (LLE) swelling and abdominal distention. Despite a daily polyethylene glycol regimen, he had previously required both manual and procedural disimpactions. He was tolerating both solids and liquids without vomiting. He denied infectious symptoms and was afebrile. On examination, his abdomen was distended without tenderness. The LLE had circumferential pitting edema without erythema or tenderness. He underwent computed tomography (CT) of the abdomen and pelvis with intravenous contrast that demonstrated a high degree of colonic distention (Image 1) with mass effect causing hydronephrosis, intrahepatic biliary ductal dilatation, and mesenteric venous engorgement (Image 2).

There was also CT evidence of iliac vein compression (left greater than right) that caused his LLE edema. He ultimately underwent colonic decompression followed by colonoscopy and rectal biopsy, which confirmed his diagnosis of Hirschsprung's disease (HD).

DISCUSSION

HD occurs in 1:5000 births, but in adults it is rarely considered and often undiagnosed. The pathophysiology of HD is

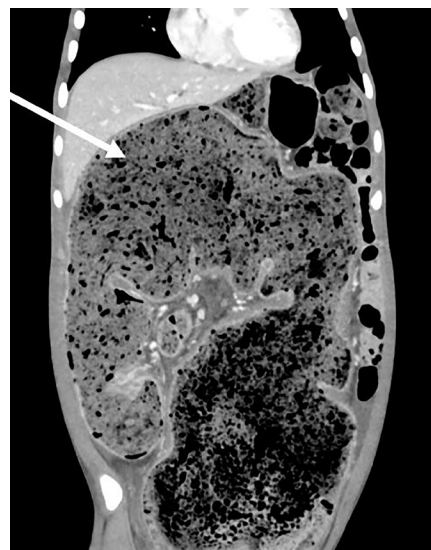


Image 1. Sagittal computed tomography with intravenous contrast demonstrating marked colonic distention with large stool burden.

an absence of intramural ganglion cells of the submucosal (Meissner's) and myenteric (Auerbach's) neural plexuses, which are situated between smooth muscle layers in the affected bowel

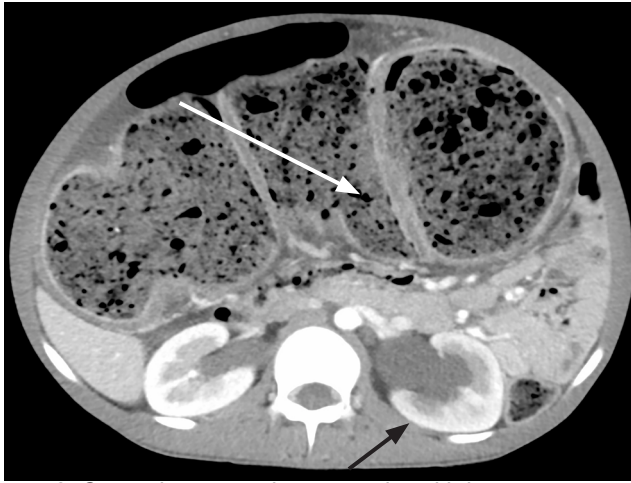

Image 2. Coronal computed tomography with intravenous contrast demonstrating marked colonic distention (white arrow) and hydronephrosis (black arrow).

segment.^{1,2} While it is likely that the colonic region proximal to the distal obstructed segment assumes a compensatory role in function for undiagnosed adults, these patients will often still suffer from CC.³ CC has prevalence estimates from 1%-8% in North America with significant impact on quality of life.⁴ A CT suggestive of HD could lead to complete eradication or significant improvement in CC by confirmational biopsy and definitive surgical management.⁵ For these reasons, Hirschsprung's disease should be considered in all adults with refractory constipation.

The authors attest that their institution requires neither Institutional Review Board approval, nor patient consent for publication of this image in emergency medicine. Documentation on file.

REFERENCES

1. Qiu JF, Shi YJ, Hu L, et al. Adult Hirschsprung's disease: report of four cases. *Int J Clin Exp Pathol.* 2013;6(8):1624-30.
2. Heanue TA and Pachnis V. Prospective identification and isolation of enteric nervous system progenitors using Sox2. *Stem Cells.* 2011;29(1):128-40.
3. Hye JK, Ah YK, Choong WL, et al. Hirschsprung disease and hypoganglionosis in adults: radiologic findings and differentiation. *Radiology.* 2008;247(2):428-34.
4. Sanchez MI and Bercik P. Epidemiology and burden of chronic constipation. *Can J Gastroenterol.* 2011;25(Suppl B):11B-5.
5. Chen F, Winston JH III, Jain SK, et al. Hirschsprung's disease in a young adult: report of a case and review of the literature. *Ann Diagn Pathol.* 2006;10(6):347-51.

CPC-EM Capsule

What do we already know about this clinical entity?

Hirschsprung's disease (HD) is characterized by gastric dysmotility and is associated with neonates.

What is the major impact of the image(s)?

This computed tomography of a young adult patient demonstrates colonic distention with significant mass effect, which was highly suspicious for undiagnosed HD.

How might this improve emergency medicine practice?

While it is a congenital condition, HD can present later in life as chronic constipation and should prompt an expansion of the differential diagnosis.

Address for Correspondence: B. Jason Theiling, MD, Duke University, Department of Surgery, Division of Emergency Medicine, Box 3096 DUMC, Durham, NC 27710. Email: Jason.theiling@duke.edu.

Conflicts of Interest: By the CPC-EM article submission agreement, all authors are required to disclose all affiliations, funding sources and financial or management relationships that could be perceived as potential sources of bias. The authors disclosed none.

Copyright: © 2020 Schmutz et al. This is an open access article distributed in accordance with the terms of the Creative Commons Attribution (CC BY 4.0) License. See: <http://creativecommons.org/licenses/by/4.0/>

Tubelight Adrenals in Diabetic Ketoacidosis

Prakrati Yadav, MBBS
Akhilesh Kumar, PH, MBBS
Rohit Mathur, MD
Pawan Garg, MD
Maya Gopalakrishnan, MD
Mahendra Kumar Garg, MD

All India Institute of Medical Sciences, Department of internal Medicine, Jodhpur, India

Section Editor: Christopher Sampson, MD

Submission history: Submitted April 14, 2020; Revision received May 21, 2020; Accepted June 1, 2020

Electronically published July 20, 2020

Full text available through open access at http://escholarship.org/uc/uciem_cpem

DOI: 10.5811/cpem.2020.6.47617

Case Presentation: We report a patient with the triad of diabetic ketoacidosis, hypertriglyceridemia, and acute pancreatitis associated with computed tomography hypoperfusion complex and adrenal hyperdensity on abdominal imaging – an association not previously reported in diabetic ketoacidosis.

Discussion: Presence of computed tomography hypoperfusion complex with hyperdense ‘Tubelight adrenals’ in a patient with diabetic ketoacidosis is associated with poor prognosis and thus serves to guide clinicians towards early and aggressive management. [Clin Pract Cases Emerg Med. 2020;4(3):482–484.]

Keywords: *Diabetic ketoacidosis; acute pancreatitis; hypertriglyceridemia; CT hypoperfusion; tubelight adrenal.*

CASE PRESENTATION

A 27-year-old male with type 1 diabetes who was poorly compliant with insulin therapy presented to our emergency department (ED) with severe abdominal pain. His records revealed

repeated ED visits for abdominal pain over the prior month. Based on laboratory findings the patient was diagnosed with diabetic ketoacidosis (DKA) (Table). Further evaluation demonstrated hypertriglyceridemia, elevated serum amylase, and elevated lipase.

Table. Laboratory values of patient with poorly controlled diabetes type 1 at presentation.

Lab parameter	Value	Reference range
Blood glucose	442 mg/dl (25.08 mmol/L)	Below 200 mg/dl (Below 11.1 mmol/L)
Glycated hemoglobin (HbA1C)	11.4%	4.0-6.2%
Total leukocyte count with differentials	17.37 x 10 ³ /μL (N:79%, L:17 % M:3.2%)	< 11.0 x 10 ³ / μL
Serum amylase	440 U/L	28-100 U/L
Serum lipase	1520 U/L	< 67 U/L
Serum cholesterol	770 mg/dl	Desirable: <200 mg/dL
Serum triglyceride	8210 mg/dl.	Normal: <150 mg/dL
Blood urea	20 mg/dL (7.14 mmol/L)	17–43 mg/dL
Serum creatinine	1.0 mg/dL (88.4μmol/L)	Male : 0.67–1.17 mg/dL Female : 0.51-0.95 mg/dL
pH	6.67	7.350- 7.450
Serum bicarbonate	7.8 mmol/L	22-29 mmol/L
Anion gap	14	12 + 4
Urinary ketones	4+	Negative
Serum calcium	6.3 mg/dL (1.58 mmol/L)	8.8-10.6 mg/dL

mg, milligram; dL, deciliter; mmol, millimole; L, liter; μL, microliter; N, neutrophils; L, lymphocytes; M, monocytes; U, units; μmol, micromole.

Computed tomography (CT) with intravenous contrast showed findings consistent with acute pancreatitis as well as enhancing bilateral adrenal glands with mucosal hyperenhancement of bowel loops and narrow caliber of abdominal aorta with imperceptible inferior vena cava, suggesting hypoperfusion complex (Image). Despite aggressive management, the patient developed hypovolemic shock, metabolic acidosis worsened, and sensorium deteriorated. An abdominal drain was placed and he was intubated, mechanically ventilated, and subsequently managed in the intensive care setting. The patient expired the next day.

DISCUSSION

The triad of diabetic ketoacidosis, hyperlipidaemia, and acute pancreatitis is important as it leads to profound hypovolemia comparable to post-traumatic shock, which leads to characteristic hypoperfusion complex on CT.¹ In 1987 Taylor et al first described CT hypoperfusion complex in three children with post-traumatic shock with dilated bowel, enhancing bowel walls, pancreas, kidneys, aorta and inferior vena cava.² Hyperdensity of normal-sized adrenal gland was later added to this complex by Sivit et al in paediatric patients who had sustained blunt abdominal trauma.³

The finding of adrenal hyperdensity, which we describe as “tubelight adrenal sign” [fluorescent-tube shaped] in our patient as a part of CT hypoperfusion complex is unique as it has not been reported in the setting of DKA and is associated with increased mortality. Early imaging for diagnosis of pancreatitis

CPC-EM Capsule

What do we already know about this clinical entity?

Diabetic ketoacidosis when associated with acute pancreatitis and hypertriglyceridemia results in profound hypovolemic shock. Computed tomography (CT) finding in such patients corresponds to post-traumatic shock known as ‘CT hypoperfusion complex.’

What is the major impact of the image(s)?

Profound hypovolemia may result in CT hypoperfusion complex and hyperdense adrenal, or “tubelight” (fluorescent tube-shaped) adrenals.” This CT finding indicates poor prognosis.

How might this improve emergency medicine practice?

Presence of this finding may guide physicians toward early and aggressive fluid management in these patients.

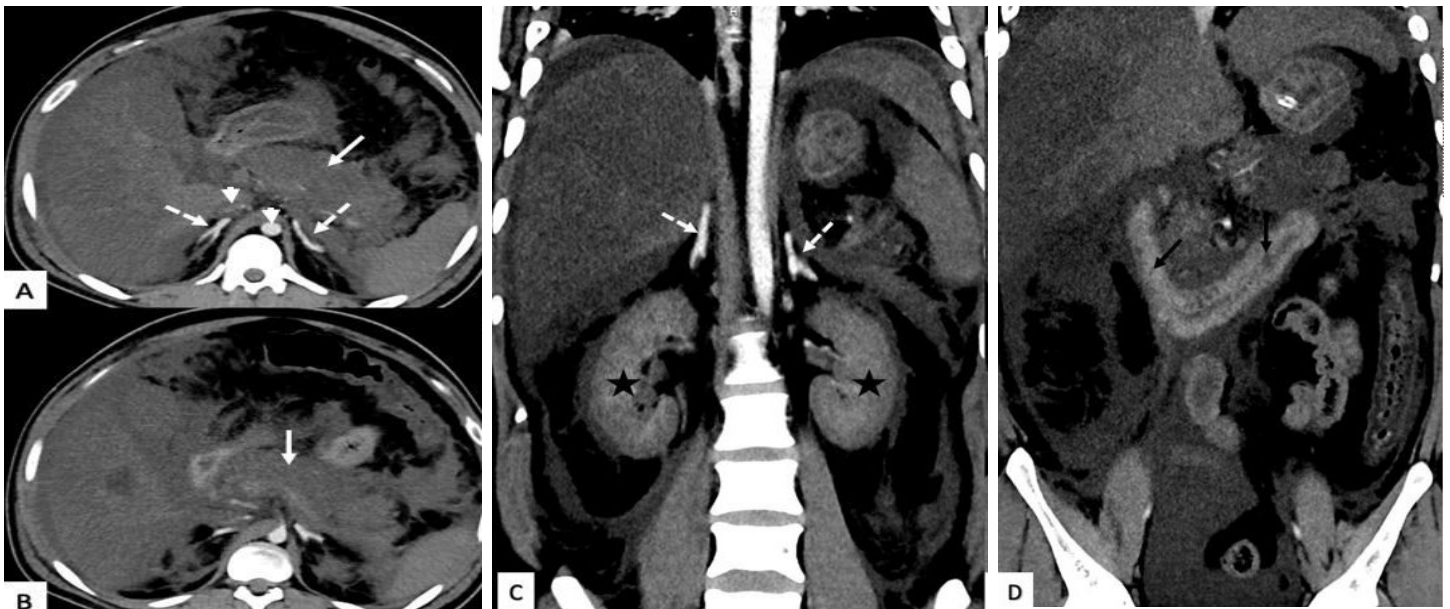


Image. Contrast-enhanced computed tomography abdomen axial (A, B) and coronal (C, D) images showing diffuse pancreatic necrosis (white arrow) with significant peripancreatic inflammation. Intense enhancing bilateral adrenal glands (dashed arrow) with mucosal hyperenhancement of small bowel loops (black arrow) and gross ascites are visible. The short white arrow indicates narrow caliber of abdominal aorta with imperceptible inferior vena cava. Bilateral kidneys (asterisks) are heterogeneously enhancing with perinephric fat stranding likely due to diabetic nephropathy.

and associated CT hypoperfusion complex with hyperdense tubelight adrenals can aid in guiding treatment and prognosis in these patients. Presence of tubelight adrenal sign on CT must alert the clinicians to possible adverse outcome and these patients should be initiated with early and aggressive fluid therapy.

The authors attest that their institution requires neither Institutional Review Board approval, nor patient consent for publication of this image in emergency medicine. Documentation on file.

REFERENCES

1. Simons-Linares CR, Jang S, Sanaka M, et al. The triad of diabetes ketoacidosis, hypertriglyceridemia and acute pancreatitis. How does it affect mortality and morbidity? A 10-year analysis of the National Inpatient Sample. *Medicine (Baltimore)*. 2019;98(7):e14378.
2. Taylor GA, Fallat ME, Eichelberger MR. Hypovolemic shock in children: abdominal CT manifestations. *Radiology*. 1987;164(2):479-81.
3. Sivit CJ, Taylor GA, Bulas DI, et al. Posttraumatic shock in children: CT findings associated with hemodynamic instability. *Radiology*. 1992;182(3):723-6.

Address for Correspondence: Prakrati Yadav, MBBS, All India Institute of Medical Sciences, Department of Medicine, AIIMS Jodhpur, Rajasathan, India 342005. Email: prakrati.yadav.2@gmail.com.

Conflicts of Interest: By the CPC-EM article submission agreement, all authors are required to disclose all affiliations, funding sources and financial or management relationships that could be perceived as potential sources of bias. The authors disclosed none.

Copyright: © 2020 Yadav et al. This is an open access article distributed in accordance with the terms of the Creative Commons Attribution (CC BY 4.0) License. See: <http://creativecommons.org/licenses/by/4.0/>

Use of Point-of-care Ultrasound for the Seizing Infant: An Adjunct for Detection of Abusive Head Trauma

Jonathan Rowland, MD
Dean Fouchia, MD
Mark Favot, MD

Wayne State University School of Medicine, Department of Emergency Medicine,
Detroit, Michigan

Section Editor: Rick McPheeters, DO

Submission history: Submitted May 14, 2020; Revision received June 10, 2020; Accepted June 17, 2020

Electronically published July 14, 2020

Full text available through open access at http://escholarship.org/uc/uciem_cpccem

DOI: 10.5811/cpcem.2020.6.48207

Case Presentation: An eight-week-old infant presented to the emergency department in cardiac arrest. Return of spontaneous circulation was obtained and the patient subsequently began seizing. Point-of-care ultrasound of the anterior fontanelle revealed an extra-axial fluid collection consistent with subdural hematoma (SDH).

Discussion: Abusive head trauma is still frequently missed on initial presentation. In addition to validated screening clinical prediction rules, point-of-care cranial ultrasound can be used as a noninvasive adjunct for detection of SDH related to abusive head trauma in infants with an open fontanelle. [Clin Pract Cases Emerg Med. 2020;4(3):485–486.]

Keywords: *Ultrasound; abusive head trauma; subdural hematoma.*

CASE PRESENTATION

An eight-week-old male with a history of laryngomalacia and prematurity born at 36 weeks presented to the emergency department (ED) in cardiac arrest after being found unresponsive at home. Cardiopulmonary resuscitation was initiated on arrival to the ED, intraosseous access was established, and the patient was intubated with subsequent return of spontaneous circulation. Ten minutes later, he had a generalized tonic-clonic seizure, and the anterior fontanelle was noted to be tense. Point-of-care ultrasound (POCUS) of the anterior fontanelle revealed an echogenic extra-axial fluid collection suspected to represent subdural hematoma (SDH) (Image 1).

The patient was successfully stabilized, then transferred to a tertiary center where a computed tomography (CT) of the brain confirmed the presence of an SDH, intraparenchymal hemorrhages of the hypothalamus and brainstem, and an anterior neck hematoma concerning for non-accidental trauma (Image 2).

DISCUSSION

Diagnosis: Acute Subdural Hematoma in Setting of Non-accidental Trauma

Abusive head trauma (AHT) is the leading cause of fatal head injuries in children under two years, with SDH being the most frequently identified lesion (up to 90%) located most

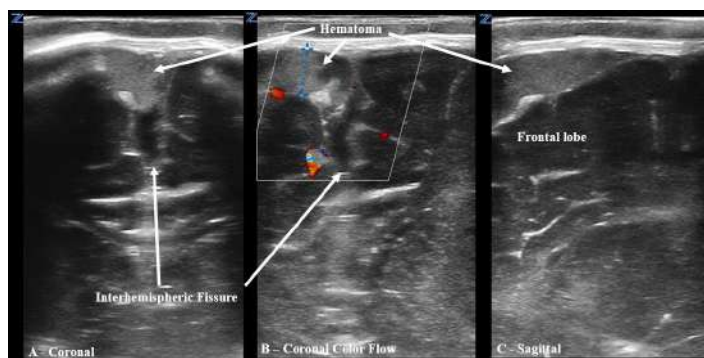


Image 1. Point-of-care ultrasound using 10-5 megahertz linear probe at the anterior fontanelle demonstrating an 8-millimeter subdural hematoma in both coronal (A) and sagittal (C) orientation; and color Doppler demonstrating lack of flow (B).

commonly in the parafalcine space along the superior sagittal sinus.¹ The rate of missed AHT remains largely unchanged for the last 20 years at roughly 30%.² Best practice recommendation is to *avoid* applying PECARN head CT rule³ to any suspected victims of AHT, and to instead use the validated “TEN-4 FACESp”²⁴ clinical prediction tool to maximize sensitivity in detection of sentinel injuries predictive of abuse.² Emergency physicians

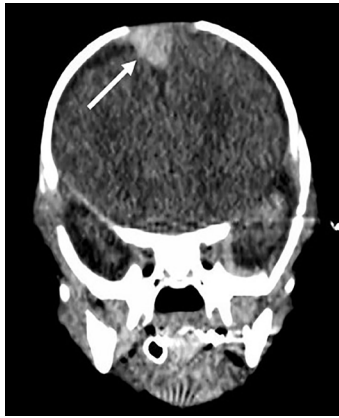


Image 2. Non-contrast computed tomography demonstrating a 1.2 x 1.3 centimeter subdural hematoma (arrow).

have been demonstrated as capable of identifying intracerebral hemorrhage using POCUS.^{5,6} POCUS should be considered when evaluating infants with suspected AHT or new-onset seizures and is easily performed with brief examination of the parafalcine space through the anterior fontanelle window using a high-frequency linear probe.

Video 1. Coronal sweep of the anterior fontanelle with a high-frequency linear 10-5 MHz probe utilizing color doppler to evaluate flow around the subdural hematoma within the interhemispheric fissure/parafalcine space.

Video 2. Coronal sweep of the anterior fontanelle at the interhemispheric fissure/parafalcine space with a high-frequency linear 10-5 MHz probe with B-mode imaging, demonstrating a subdural hematoma to the right of midline with associated widening of the interhemispheric fissure.

Video 3. Sagittal sweep of the anterior fontanelle at the frontal lobe with a high-frequency linear 10-5 MHz probe with B-mode imaging, demonstrating an echogenic subdural hematoma.

The authors attest that their institution requires neither Institutional Review Board approval, nor patient consent for publication of this image in emergency medicine. Documentation on file.

REFERENCES

1. Choudhary A, Servaes S, Slovis T, et al. Consensus Statement on Abusive Head Trauma in Infants and Young Children. *Pediatr Radiol*. 2018;48(8):1048-65.
2. Berger RP and Lindberg DM. Early recognition of physical abuse: bridging the gap between knowledge and practice. *J Pediatr*.

CPC-EM Capsule

What do we already know about this clinical entity?

Subdural hematoma is the most commonly identified lesion in fatal cases of abusive head trauma (AHT). The rate of missed AHT remains largely unchanged (~30%) for the last twenty years.

What is the major impact of the image(s)?

Point-of-care ultrasound (POCUS) can be utilized in infants with open fontanelles and should be considered in evaluation of suspected AHT and/or undifferentiated new-onset seizures.

How might this improve emergency medicine practice?

POCUS can be utilized as a noninvasive adjunct, in addition to validated clinical prediction tools, to improve our detection of AHT.

Address for Correspondence: Jonathan Rowland, MD, Wayne State University School of Medicine, Department of Emergency Medicine, 6071 W. Outer Dr., Lourdes 447-D, Detroit, MI 48235. Email: jrowland@dmc.org.

Conflicts of Interest: By the CPC-EM article submission agreement, all authors are required to disclose all affiliations, funding sources and financial or management relationships that could be perceived as potential sources of bias. The authors disclosed none.

Copyright: © 2020 Rowland et al. This is an open access article distributed in accordance with the terms of the Creative Commons Attribution (CC BY 4.0) License. See: <http://creativecommons.org/licenses/by/4.0/>

2019;204:16-23.

3. Kuppermann N, Holmes J, Dayan P, et al. Identification of children at very low risk of clinically-important brain injuries after head trauma: a prospective cohort study. *Lancet*. 2009;374(9696):1160-70.
4. Pierce M, Kaczor K, Lorenz D, et al. Bruising Clinical Decision Rule (BCDR) discriminates physical child abuse from accidental trauma in young children. Pediatric Academic Societies' Annual Meeting. 2017; San Francisco, CA.
5. McCormick T, Chilstrom M, Childs J, et al. Point-of-care ultrasound for the detection of traumatic intracranial hemorrhage in infants. *Pediatr Emer Care*. 2017;33(1):18-20.
6. Lee S, Bellamkonda Athmaram VR, Anderson JL. Infant with limpness; subdural hemorrhage from suspected abusive head trauma. *Ann Emerg Med*. 2013;61(1):18-36.

A Case of a Missing Proximal Humerus

Jessica Lynn Williams, MD
Steven M. Hochman, MD

Saint Joseph's University Medical Center, Emergency Department, Paterson,
New Jersey

Section Editor: Rick A. McPheeters, DO

Submission history: Submitted May 23, 2020; Revision received June 3, 2020; Accepted June 18, 2020

Electronically published July 30, 2020

Full text available through open access at http://escholarship.org/uc/uciem_cpem

DOI: 10.5811/cpem.2020.6.48396

Case Presentation: In this case, we demonstrate how a small radiolucency in the proximal humerus can progress to an even larger problem within a few months in a patient without follow-up. Our patient's ultimate diagnosis was renal cell carcinoma with metastasis to the right proximal humerus, completely obliterating the affected bone.

Discussion: In many underserved communities, patients have limited access to medical care, particularly specialty care. These patients often present to the emergency department and are unable to acquire appropriate follow-up. This situation illustrates the social issues that our patients face every day affecting their access to healthcare and ultimately necessary medical treatment. [Clin Pract Cases Emerg Med. 2020;4(3):487–488.]

Keywords: *proximal humerus; metastatic bone lesions; renal cell carcinoma.*

CASE PRESENTATION

A 56-year-old male with a history of alcoholic liver cirrhosis presented to the emergency department (ED) for worsening atraumatic right proximal arm pain. His examination was remarkable for limited active and passive range of motion of the right shoulder. He had presented to an affiliated ED three months prior for similar complaints. At that time, radiographs demonstrated a radiolucency in the right proximal humerus (Image 1). Computed tomography on the same date demonstrated a metastatic or a primary bone lesion.

The patient was discharged and instructed to follow up as an outpatient, but was unable to do so. The radiograph of the right humerus on the current visit demonstrated a large, soft tissue lytic mass (Image 2). The patient was admitted to the hospital and diagnosed with renal cell carcinoma (RCC) of the right kidney with metastasis to the humerus. Magnetic resonance imaging of the right humerus four days after admission can be seen in Image 3. The patient underwent right radical resection of the right proximal humerus mass, reverse total shoulder arthroplasty and rotator cuff repair at another institution. Pathology reports confirmed the humeral mass was metastatic RCC. The patient was started on infusion therapy.

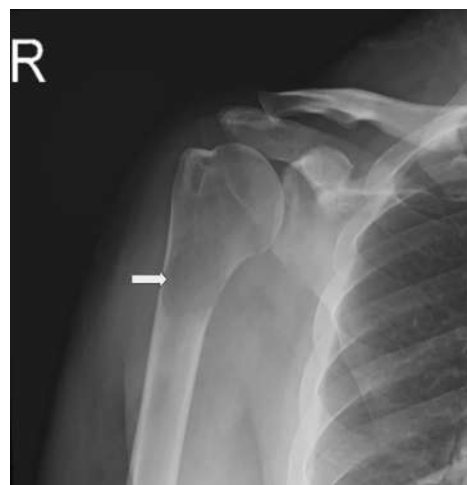


Image 1. Right shoulder radiograph demonstrates a radiolucency (arrow) in the right proximal humerus on the initial visit.

DISCUSSION

RCC is responsible for 3% of all cancers.¹ Bone metastasis is most commonly from breast, prostate, and lungs.² However, 25-30% of RCC tumors metastasize to bone.¹ Emergency physicians should have a low threshold for

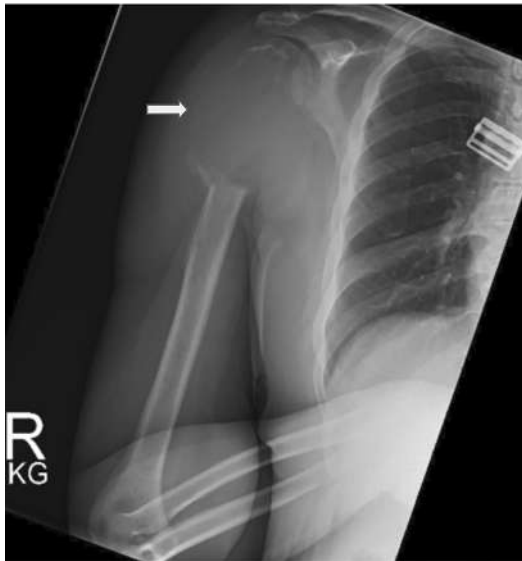

Image 2. Right humerus radiograph demonstrates an area of presumed soft-tissue mass causing bony destruction of the right proximal humerus (arrow) three months later.

obtaining radiographs in patients with atraumatic pain to rule out pathologic lesions. With a five-year RCC survival rate of less than 50%, early detection and initiation of treatment are essential, as earlier stages of cancer have better survival rates and treatment options. If patients lack follow-up or insurance, emergency providers must be diligent to provide patient education and assist in arranging follow-up for a better chance of survival.

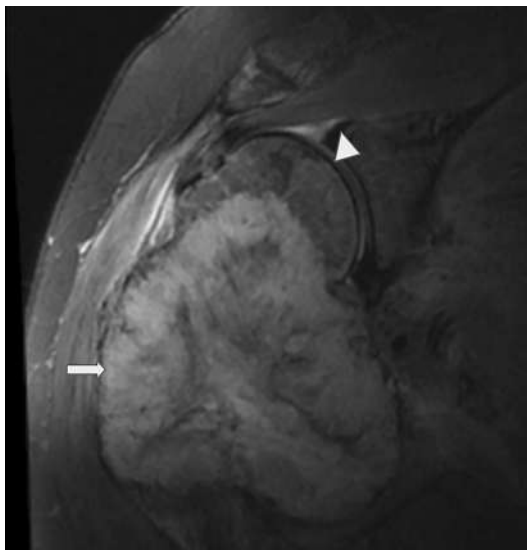


Image 3. Magnetic resonance imaging of the right humerus demonstrates a large, heterogeneous mass (arrow) adjacent to the right humeral neck and head, which extends peripherally into the soft tissues, representing malignancy. Arrowhead denotes the normal humeral head.

CPC-EM Capsule

What do we already know about this clinical entity?

Once cancer becomes stages 3 or 4 with metastasis, there are fewer treatment options and lower survival rates.

What is the major impact of the image(s)?

Subtle nonspecific findings on plain films can be early indications of pathology that can progress rapidly, reinforcing the importance of early diagnosis and treatment.

How might this improve emergency medicine practice?

Imaging should be obtained for atraumatic pain in patients with limited access to follow-up care who present with insidious onset or whose pain occurs at night or is not relieved by conservative treatment.

The authors attest that their institution requires neither Institutional Review Board approval, nor patient consent for publication of this image in emergency medicine. Documentation on file.

Address for Correspondence: Jessica L. Williams, MD, Saint Joseph's University Medical Center, Department of Emergency Medicine, 703 Main Street, Paterson, NJ 07503. Email: jlwilliams4@geisinger.edu.

Conflicts of Interest: By the CPC-EM article submission agreement, all authors are required to disclose all affiliations, funding sources and financial or management relationships that could be perceived as potential sources of bias. The authors disclosed none.

Copyright: © 2020 Williams et al. This is an open access article distributed in accordance with the terms of the Creative Commons Attribution ([CC BY 4.0](http://creativecommons.org/licenses/by/4.0/)) License. See: <http://creativecommons.org/licenses/by/4.0/>

REFERENCES

1. Umer M, Mohib Y, Atif M, et al. Skeletal metastasis in renal cell carcinoma: A review. *Ann Med Surg (Lond)*. 2018;27:9-16.
2. Nielsen OS, Munro AJ, Tannock IF. Bone metastases: pathophysiology and management policy. *J Clin Oncol*. 1991;9(3):509-24.

Carotid Artery Dissection as a Result of Penetrating Ear Trauma

Nicholas Peairs, MD
Joel Stillings, DO

Desert Regional Medical Center, Department of Emergency Medicine, Palm Springs, California

Section Editor: Rick A. McPheeters, DO

Submission history: Submitted April 2, 2020; Revision received May 17, 2020; Accepted June 8, 2020

Electronically published July 30, 2020

Full text available through open access at http://escholarship.org/uc/uciem_cpem

DOI: 10.5811/cpcem.2020.6.47537

Case Presentation: Here we present the case of a previously healthy 67-year-old female with carotid artery dissection as a result of penetrating ear trauma.

Discussion: Carotid artery dissection can result from unusual mechanisms of injury and present without typical symptoms or exam findings. If left untreated, devastating neurologic sequela can occur. Physicians must have a low threshold to obtain vascular imaging to appropriately manage such cases. [Clin Pract Cases Emerg Med. 2020;4(3):489–490.]

Keywords: *Ear trauma; Carotid Artery Dissection.*

CASE PRESENTATION

A 67-year-old female presented with headache after a four-foot mechanical fall that occurred while hiking. The patient removed a stick from her left ear after a brief loss of consciousness. In the emergency department, the patient had left tongue deviation, a macerated left external acoustic meatus, and hoarse voice. Computed tomography angiography of the head and neck demonstrated soft tissue injury extending inferiorly into the carotid space (Image 1).

Internal carotid artery dissection and occlusion were observed just superior to the carotid bifurcation. Both crescent sign and flame occlusion (Images 2 and 3) are pathognomonic findings on computed tomography angiography neck for carotid dissection and were identified as a result of this trauma. The patient was admitted to the neurological intensive care unit and later discharged with aspirin for stroke prophylaxis and percutaneous endoscopy gastrostomy placement to manage dysphagia from vocal cord paralysis secondary to microvascular injury to the left recurrent laryngeal and hypoglossal nerves.

DISCUSSION

Classic symptoms of carotid artery dissection include headache, neck pain, and Horner's syndrome without anhidrosis.¹ Cerebral ischemia was identified in 67% of

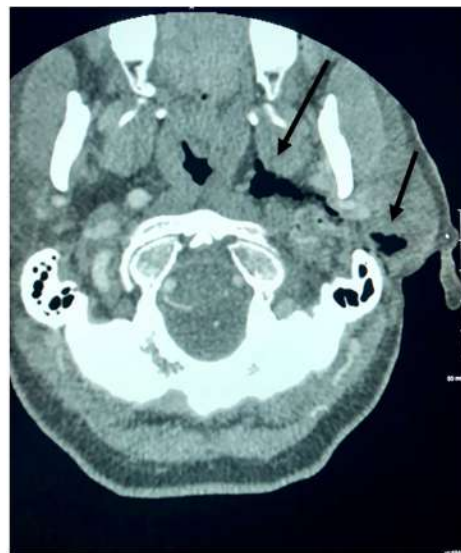


Image 1. Computed tomography demonstrating soft tissue injury with subcutaneous air extending from the external acoustic meatus to the carotid space (arrows).

patients with carotid artery dissection.² With early detection, antiplatelet prophylaxis can be started to prevent embolism and loss of brain tissue.³ Medical providers must consider carotid artery dissection in patients lacking common

exam findings and with unusual mechanisms of injury. Rapid diagnostics and intervention are essential to avoid debilitating sequela.

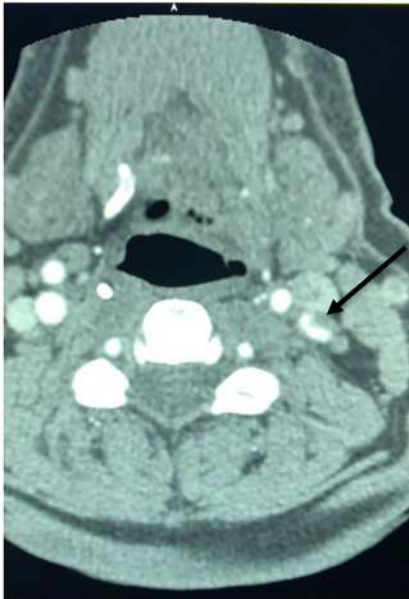


Image 2. Computed tomography demonstrating dissection of the left internal carotid artery depicting “crescent sign” (arrow).

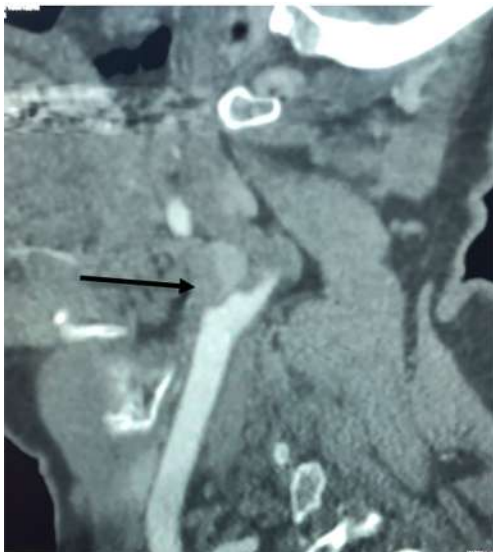

Image 3. Computed tomography demonstrating complete occlusion of the left internal carotid artery depicting “flame occlusion” (arrow).

The authors attest that their institution requires neither Institutional Review Board approval, nor patient consent for publication of this image in emergency medicine. Documentation on file.

CPC-EM Capsule

What do we already know about this clinical entity?

Carotid artery dissection can occur spontaneously or as the result of minor trauma.

What is the major impact of the image(s)?
Penetrating trauma to the external acoustic meatus and disruption of the carotid space has resulted in carotid artery dissection.

How might this improve emergency medicine practice?

Emergency medicine providers must consider carotid artery dissection despite unusual mechanisms of injury and in the absence of common exam findings.

Address for Correspondence: Joel Stillings, DO, Desert Regional Medical Center, Department of Emergency Medicine, 1180 N Indian Canyon Drive Suite E 418, Palm Springs, CA 92262. Email: joel.stillings@vituity.com.

Conflicts of Interest: By the CPC-EM article submission agreement, all authors are required to disclose all affiliations, funding sources and financial or management relationships that could be perceived as potential sources of bias. The authors disclosed none.

Copyright: © 2020 Peairs et al. This is an open access article distributed in accordance with the terms of the Creative Commons Attribution (CC BY 4.0) License. See: <http://creativecommons.org/licenses/by/4.0/>

REFERENCES

1. Silbert PL, Mokri B, Schievink WI, et al. Headache and neck pain in spontaneous internal carotid artery and vertebral artery dissections. *Neurology*. 1995;45(8):1517-22.
2. Lee VH, Brown RD Jr, Mandrekar JN, et al. Incidence and outcome of cervical artery dissection: a population-based study. *Neurology*. 2006;67(10):1809-12.
3. Imray CH and Pattinson KT. Potential role for TCD-directed antiplatelet agents in symptomatic carotid artery dissection. *Stroke*. 2006;37(3):767.

Bilateral Foot Skin Eruption in a Hepatitis C Patient

Shane Davis, MD
Angela Creditt, DO

Virginia Commonwealth University Health Systems, Department of Emergency Medicine,
Richmond, Virginia

Section Editor: Austin Smith, MD

Submission history: Submitted January 9, 2020; Revision received June 27, 2020; Accepted July 3, 2020

Electronically published August 3, 2020

Full text available through open access at http://escholarship.org/uc/uciem_cpem

DOI: 10.5811/cpcem.2020.7.46490

Case Presentation: A 58-year-old female with history of hepatitis C virus presented to the emergency department with a bilateral skin eruption to her feet for one year. Following skin biopsy, the patient was diagnosed with Necrolytic acral erythema (NAE). She was treated with clobetasol ointment, zinc supplementation, and mupirocin, which resulted in improvement in her symptoms.

Discussion: NAE is a rash described as sharply demarcated, lichenified plaques on the dorsal foot and is a rare extra-hepatic manifestation of hepatitis C. This case details a patient with a skin eruption consistent with NAE. [Clin Pract Cases Emerg Med. 2020;4(3):491–492.]

Keywords: *Hepatitis C; foot rash; necrolytic acral erythema.*

CASE PRESENTATION

A 58-year-old female with history of hepatitis C virus (HCV) presented to the emergency department with a bilateral skin eruption to her feet for one year. She described it as intermittent and severely painful causing her difficulty with ambulation. Physical exam revealed sharply demarcated, hyperpigmented, lichenified plaques on the dorsa of the feet extending circumferentially around her ankles, as seen in Images 1-3, with areas of fissuring and purulent drainage

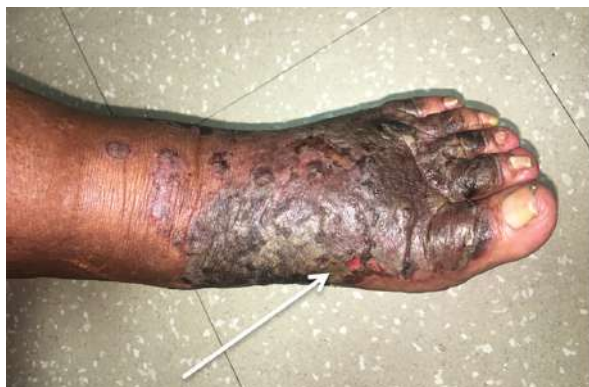

Image 1. A 58-year-old female with hepatitis C demonstrating a rash on the dorsal aspect of her foot consistent with necrolytic acral erythema.

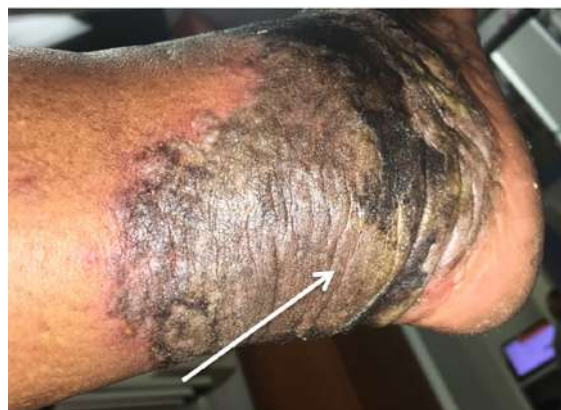

Image 2. A 58-year-old female with hepatitis C demonstrating a circumferential rash that extends from the dorsum of the foot around the ankle from necrolytic acral erythema.

consistent with superinfection. The patient was started on clindamycin and referred to dermatology. Following skin biopsy, the patient was diagnosed with NAE. She was treated with clobetasol ointment, zinc supplementation, and mupirocin, which resulted in improvement in her symptoms. However, symptoms returned once medications were stopped. The patient was restarted on zinc and clobetasol and referred to hepatology for treatment of her HCV.

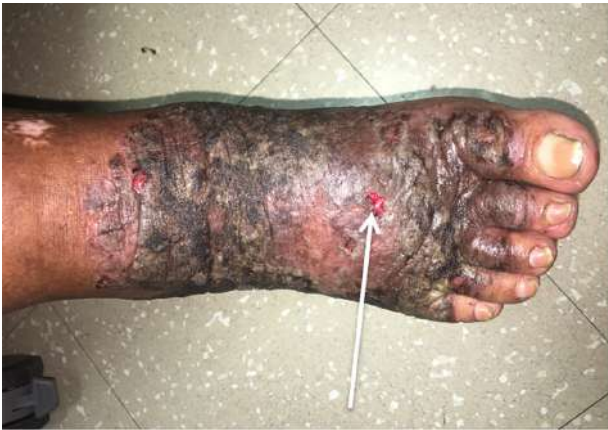

Image 3. A 58-year-old female with hepatitis C demonstrating fissures with purulent drainage consistent with superinfection from necrolytic acral erythema.

DISCUSSION

Necrolytic acral erythema (NAE) is a cutaneous manifestation of hepatitis C virus (HCV) with a prevalence of 1.7% among this patient population.¹ NAE is a well-defined, erythematous, tender plaque that typically appears on the dorsa of the feet but can also spread to the posterior ankle. With progression of disease, the appearance becomes thickened and velvety with a surrounding rim of erythema and fissures within the plaque.² The pathophysiology of NAE remains unclear and the low prevalence rate makes it difficult to determine risk factors. There is speculation that serum or skin zinc deficiency may play a role in this cutaneous manifestation in HCV patients;² however, there is variable responsiveness of NAE to zinc supplementation, and the only definitive treatment thus far is hepatitis C antivirals.³

The authors attest that their institution requires neither Institutional Review Board approval, nor patient consent for publication of this image in emergency medicine. Documentation on file.

REFERENCES

1. Raphael BA, Dorey-Stein ZL, Lott J, et al. Low prevalence of necrolytic acral erythema in patients with chronic hepatitis C virus infection. *J Am Acad Dermatol*. 2012;67(5):962-8.
2. Abdallah MA, Hull C, Horn TD. Necrolytic acral erythema: a patient from the United States successfully treated with oral zinc. *Arch*

1. *Dermatol*. 2005;141(1):85-7.
3. Fernandes Botelho LF, E Silva Enokihara MM, Enokihara MY. Necrolytic acral erythema: a rare skin disease associated with hepatitis C virus infection. *Anais Brasileiros de Dermatologia*. 2016;91(5):649-51.

CPC-EM Capsule

What do we already know about this clinical entity?

This rash that is an extra-hepatic manifestation of hepatitis C, called necrolytic acral erythema. Although the association is known, the pathophysiology behind the rash is incompletely understood.

What is the major impact of the image(s)?

This rare but characteristic rash that is an extra-hepatic manifestation of hepatitis C virus.

How might this improve emergency medicine practice?

This patient was initially mismanaged due to the rarity of this diagnosis. These images in the emergency medicine literature may potentially aid in proper diagnosis and treatment.

Address for Correspondence: Angela Creditt, DO, Virginia Commonwealth University Health Systems, Department of Emergency Medicine, 401 N 12th Street, Richmond, VA 23298. Email: angela.creditt@vcuhealth.org.

Conflicts of Interest: By the CPC-EM article submission agreement, all authors are required to disclose all affiliations, funding sources and financial or management relationships that could be perceived as potential sources of bias. The authors disclosed none.

Copyright: © 2020 Davis et al. This is an open access article distributed in accordance with the terms of the Creative Commons Attribution (CC BY 4.0) License. See: <http://creativecommons.org/licenses/by/4.0/>

Point-of-care Ultrasound for Long Head of the Biceps Tendon Rupture

Browning S. Wayman, MD, DTM&H
Ryan Joseph, DO, DTM&H

University of Texas Health Science Center at San Antonio, Department of
Emergency Medicine, San Antonio, Texas

Section Editor: Shaddi Lahham, MD, MS

Submission history: Submitted April 18, 2020; Revision received June 25, 2020; Accepted July 3, 2020

Electronically published July 20, 2020

Full text available through open access at http://escholarship.org/uc/uciem_cpccem

DOI: 10.5811/cpcem.2020.7.47777

Case Presentation: We present a case of a 59-year-old male who presented to the emergency department with left upper arm pain that started suddenly after lifting some plywood a few days prior. Point-of-care ultrasound (POCUS) was performed, which revealed a rupture of the long head of the biceps tendon.

Discussion: Biceps tendon rupture is a relatively rare occurrence; however, rupture of the long head is more common than the short head. Being competent in bedside musculoskeletal POCUS is important for the emergency physician and can help expedite care in cases such as the one presented here. [Clin Pract Cases Emerg Med. 2020;4(3):493–494.]

Keywords: *Biceps tendon rupture; ultrasound; musculoskeletal.*

CASE PRESENTATION

A 59-year-old male presented to the emergency department with left upper arm pain, which began abruptly while lifting some plywood about six days prior. On examination, he had significant tenderness at the proximal biceps and significant pain with passive range of motion as well as three out of five strength. There was also a large, soft tissue defect at his proximal bicep with ecchymosis. Point-of-care ultrasound (POCUS) revealed a proximal rupture of the long head of the biceps tendon (LHBT) (Images 1-3).

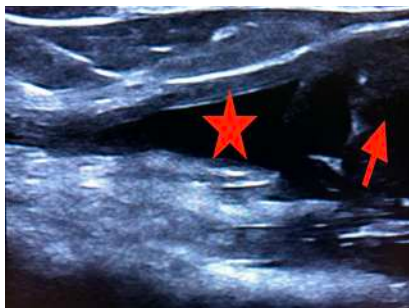

Image 1. Point-of-care ultrasound in the longitudinal view. The star indicates fluid collection, where the proximal long head biceps tendon (LHBT) is normally seen. The arrow indicates the retracted portion of the LHBT indicating rupture.

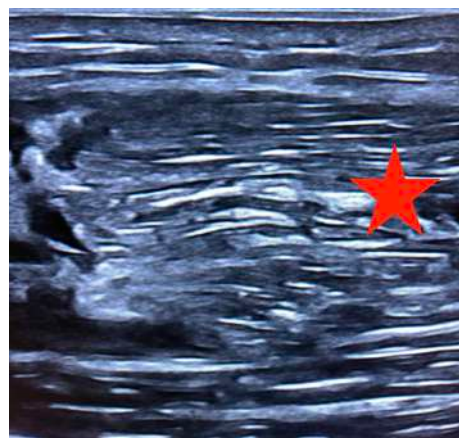

Image 2. Point-of-care ultrasound in the longitudinal view of the mid long head biceps tendon (LHBT). The star indicates the fluid-filled area where the LHBT should be located with small, echogenic blood clots throughout, indicating a tendon rupture.

DISCUSSION

Biceps tendon rupture is a relatively rare occurrence with a reported incidence rate of 0.53/100,000 over a period of five years, with a male to female ratio of 3:1.¹ These injuries are more likely to occur in middle age, and associated risk factors include smoking, corticosteroids, overuse, and diabetes.

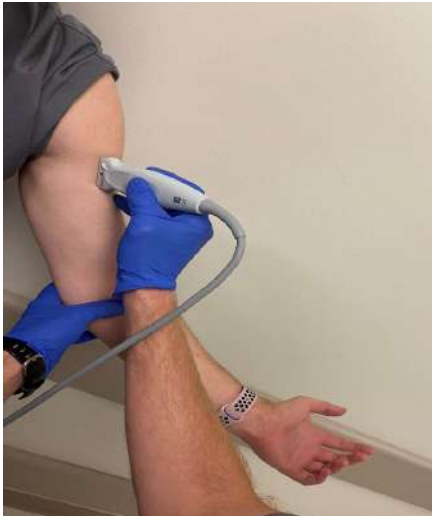

Image 3. This is the proper transducer orientation for the longitudinal view of the biceps tendon.

Proximal biceps tendon rupture is more common than distal and usually occurs at the tendon labral junction or the bony attachment.² Also, rupture of the LHBT is far more common than rupture of the short head.³

Musculoskeletal ultrasound enables the clinician to perform a dynamic exam at bedside and has a sensitivity and specificity of 88% and 98%, respectively.⁴ In this case, the emergency physician was able to diagnose a complete proximal LHBT rupture via clinical exam and confirmation with POCUS.

The authors attest that their institution requires neither Institutional Review Board approval, nor patient consent for publication of this image in emergency medicine. Documentation on file.

REFERENCES

1. Clayton RA and Court-Brown CM. The epidemiology of musculoskeletal tendinous and ligamentous injuries. *Injury*. 2008;39(12):1338.
2. Hsu D, Anand P, Chang KV. (2020). Biceps tendon rupture. Treasure Island, FL: StatPearls Publishing.
3. Shah AK and Pruzansky ME. Ruptured biceps brachii short head muscle belly: a case report. *J Shoulder Elbow Surg*. 2004;13(5):562-5.
4. Skendzel JG, Jacobson JA, Carpenter JE, et al. Long head of biceps brachii tendon evaluation: accuracy of preoperative ultrasound. *AJR Am J Roentgenol*. 2011;197(4):942-8.

CPC-EM Capsule

What do we already know about this clinical entity?

Biceps tendon rupture is an uncommon injury that usually occurs when the long head biceps tendon is torn. It has traditionally been a clinical diagnosis.

What is the major impact of the image(s)?

These ultrasound images will aid in identifying the anatomy of a ruptured long head of the biceps tendon.

How might this improve emergency medicine?

Familiarity with musculoskeletal ultrasound can hasten diagnosis in the emergency department and appropriate follow-up.

Address for Correspondence: Ryan Joseph, DO, DTM&H, University of Texas Health Science Center at San Antonio, Department of Emergency Medicine, 7703 Floyd Curl Dr. MC 7736, San Antonio, TX 78229. Email: josephr1@uthscsa.edu.

Conflicts of Interest: By the CPC-EM article submission agreement, all authors are required to disclose all affiliations, funding sources and financial or management relationships that could be perceived as potential sources of bias. The authors disclosed none.

Copyright: © 2020 Wayman et al. This is an open access article distributed in accordance with the terms of the Creative Commons Attribution (CC BY 4.0) License. See: <http://creativecommons.org/licenses/by/4.0/>

Point-of-care Ultrasound in the Diagnosis of Calciphylaxis

Natasha Tobarran, DO
Mark Collin, MD

Wellspring York Hospital, Department of Emergency Medicine, York, Pennsylvania

Section Editor: Rick A. McPheeters, DO

Submission history: Submitted April 25, 2020; Revision received June 12, 2020; Accepted July 3, 2020

Electronically published July 30, 2020

Full text available through open access at http://escholarship.org/uc/uciem_cpem

DOI: 10.5811/cpem.2020.7.47886

Case Presentation: A 63-year-old male with a past medical history of end stage renal disease presented to the emergency department with painful, lower-extremity necrotic ulcerations. Ultrasound and computed tomography imaging showed concerns for calcium deposits. Biopsy confirmed the diagnosis of calciphylaxis, a rare lethal disease.

Discussion: Emergency physicians should keep this disease on their differential due to the high mortality rate. [Clin Pract Cases Emerg Med. 2020;4(3):495–496.]

Keywords: *Point-of-care ultrasound; calciphylaxis; necrotic skin ulcer.*

CASE PRESENTATION

A 63-year-old male with end-stage renal disease (ESRD) presented to the emergency department with severe, bilateral lower-extremity pain with black necrotic ulcerations (Image 1). The symptoms began five weeks prior, and review of systems was negative for fevers or trauma. The patient was previously treated with antibiotics, prednisone, and oxycodone without improvement. Further evaluation via point-of-care ultrasound

focusing on the necrotic areas revealed calcium deposits and shadowing (Image 2). Computed tomography confirmed soft tissue calcifications (Image 3).

DISCUSSION

The findings were concerning for calciphylaxis. Punch biopsy showed extensive skin necrosis and calcifications confirming the diagnosis. The patient was treated with sodium thiosulfate and was discharged home but ultimately was transitioned to hospice care.

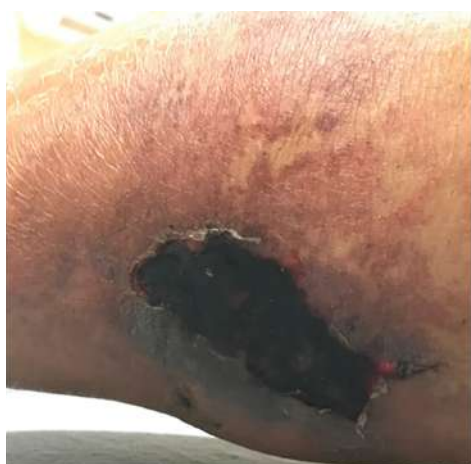

Image 1. Physical examination revealing lower extremity skin necrosis due to calciphylaxis in the setting of end-stage renal disease.

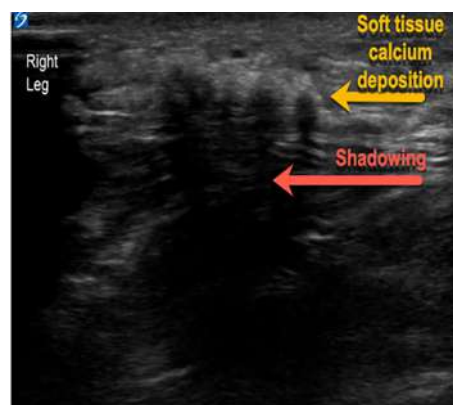


Image 2. Soft tissue point-of-care ultrasound identifying soft tissue calcium deposits with shadowing diagnostic of calciphylaxis in a patient with end-stage renal disease.

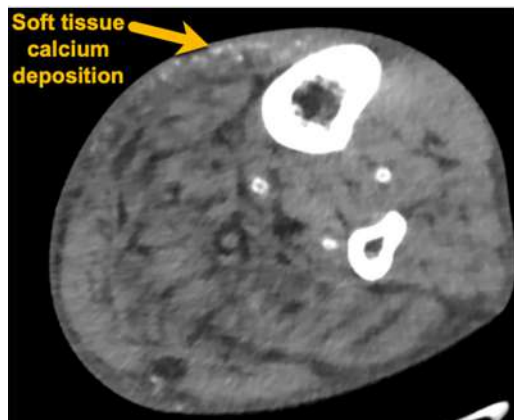


Image 3. Computed tomography with axial view demonstrating soft tissue calcium deposits diagnostic of calciphylaxis in a patient with end-stage renal disease.

Calciphylaxis is rare and lethal disease, presenting with skin ischemia and necrosis caused by total occlusion of blood vessels secondary to calcification of arterioles and capillaries in the dermis and adipose tissue.¹ The estimated six-month survival rate is 50%.² It has been linked to ESRD, hyperparathyroidism, hypercalcemia, and hyperphosphatemia.³ Patients present with non-healing, painful necrotic skin lesions in areas with increased adiposity such as distal lower extremities.² The diagnosis is clinical; however, biopsy can be used for confirmation. The treatment involves wound care, pain management, and correcting electrolyte abnormalities.¹ Wound infection is a common complication. A trial of sodium thiosulfate, which blocks the calcification of vascular smooth muscle, may be implemented.¹ It is important for emergency physicians to keep calciphylaxis on their differential for non-healing painful wounds, especially in high-risk patient populations. Point-of-care ultrasound is a useful tool in aiding with diagnosis.

The authors attest that their institution requires neither Institutional Review Board approval, nor patient consent for publication of this image in emergency medicine. Documentation on file.

REFERENCES

1. Chang JJ. Calciphylaxis: diagnosis, pathogenesis, and treatment. *Adv Skin Wound Care*. 2019;32(5):205-5.
2. Nigwekar SU, Thadani R, Brandenburg VM. Calciphylaxis. *N Engl J*

CPC-EM Capsule

What do we already know about this clinical *Calciphylaxis is a rare disease with high morbidity and mortality presenting with painful necrotic lesions due to calcium deposits in the fat and skin.*

What is the major impact of the image(s)? *Soft tissue calcium deposits with associated shadowing can be seen with ultrasound of the necrotic lesions, aiding in diagnosis of calciphylaxis.*

How might this improve emergency medicine practice? *Point-of-care ultrasound may be useful for an astute clinician in the diagnosis of calciphylaxis, which should be considered when evaluating painful skin lesions.*

Address for Correspondence: Natasha Tobarran, DO, Wellspan York Hospital, Department of Emergency Medicine, 1001 S. George Street, York, PA 17403. Email: Natasha.tobarran@gmail.com.

Conflicts of Interest: By the *CPC-EM* article submission agreement, all authors are required to disclose all affiliations, funding sources and financial or management relationships that could be perceived as potential sources of bias. The authors disclosed none.

Copyright: © 2020 Tobarran et al. This is an open access article distributed in accordance with the terms of the Creative Commons Attribution ([CC BY 4.0](http://creativecommons.org/licenses/by/4.0/)) License. See: <http://creativecommons.org/licenses/by/4.0/>

Med. 2018;378(18):1704-14

3. Udomkarnjananum S, Kongnatthasate K, Praditpornsilpa K, et al. Treatment of calciphylaxis in CKD: a systematic review and meta-analysis. *Kidney Int Rep*. 2018;4(2):231-44.

Man with Penile Pain

Jesse Wray, MD
Rachel E. Bridwell, MD
Michael J. Yoo, MD
Christopher N. Belcher, MD
Joshua J. Oliver, MD

San Antonio Uniformed Services Health Education Consortium, Department of
Emergency Medicine, Fort Sam Houston, Texas

Section Editor: Rick A. McPheeters, DO

Submission history: Submitted April 26, 2020; Revision received June 15, 2020; Accepted July 3, 2020

Electronically published July 20, 2020

Full text available through open access at http://escholarship.org/uc/uciem_cpem

DOI: 10.5811/cpcem.2020.7.47903

Case Presentation: We describe a case of spontaneous partial segmental thrombosis of the corpus cavernosum (PSTCC).

Discussion: PSTCC is a rare condition in which thrombus formation occurs in the corpus cavernosum. This condition is managed in conjunction with a urologist, and management typically includes anticoagulation and pain control. [Clin Pract Cases Emerg Med. 2020;4(3):497–498.]

Keywords: *Thrombosis of corpus cavernosum; partial priapism; penile thrombus.*

CASE PRESENTATION

A 39-year-old man presented to the emergency department for two days of worsening pain and swelling to the base of his penis. The patient denied trauma or a history of coagulopathy, had a non-contributory sexual history, and no recent use of erectile dysfunction medications. Examination demonstrated mild swelling to the penile base without evidence of hernia, infection, or shaft injury.

Computed tomography (CT) revealed penile asymmetry (Image 1). Ultrasound demonstrated asymmetric fullness

of the right corpus cavernosum. Pelvis magnetic resonance imaging (MRI) revealed an enlarged appearance of the right corpus cavernosum with hypointense T2 signal (Image 2) and hyperintense T1 signal (Image 3). These findings were consistent with a partial segmental thrombosis of the right corpus cavernosum (PSTCC). The patient was admitted for pain control and discharged after symptom resolution with

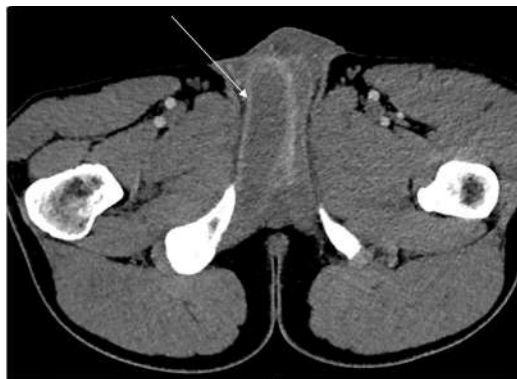

Image 1. Non-contrasted computed tomography of the pelvis demonstrating asymmetry of the right and left corpus cavernosum.

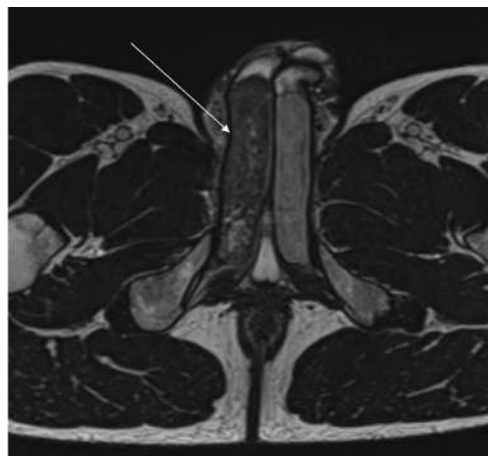


Image 2. Axial T2-weighted magnetic resonance imaging of the pelvis revealing a hypointense signal of the right corpus cavernosum.

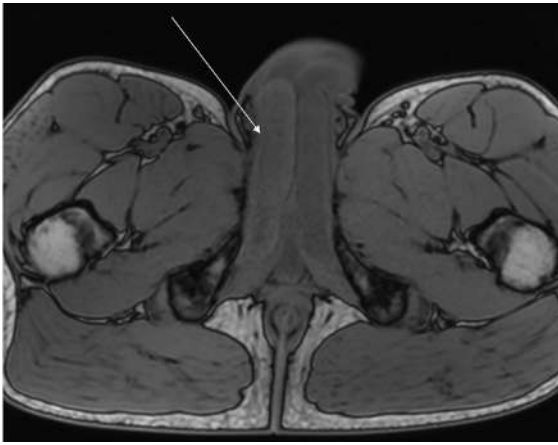


Image 3. Axial T1-weighted magnetic resonance imaging of the pelvis with hyperintense signal of the right corpus cavernosum.

anticoagulation therapy. Upon outpatient follow-up, the patient had no persistent complications.

DISCUSSION

PSTCC is a rare condition that manifests as penile or perineal pain and swelling. Thrombus formation likely arises secondary to microtrauma, thrombophilia, hemoglobinopathies and, rarely, medication side effect.^{1,2} Ultrasonography or MRI are recommended diagnostic modalities, while CT is reportedly suboptimal due to decreased sensitivity for this condition.³ Our case departs from the literature as CT and MRI were most useful. Additionally, because CT clearly demonstrates the pathology in this case, it may be a better diagnostic modality than previously reported in this rare phenomenon and serve as a rapid diagnostic tool in some cases. Early urologic consultation is recommended, with typical management consisting of anticoagulation and pain control.² PSTCC has an overall favorable prognosis rarely incurring long-term complications.³

The authors attest that their institution requires neither Institutional Review Board approval, nor patient consent for publication of this image in emergency medicine. Documentation on file.

REFERENCES

1. Christodoulidou M, Parnham A, Ramachandran N, et al. Partial segmental thrombosis of the corpus cavernosum presenting with perineal pain. *BMJ Case Rep.* 2016;2016:bcr2016217748.
2. Hoyerup PH and Azawi NH. Partial priapism. *BMJ Case Reports* 2013;2013:bcr2013200031.
3. Smetana A, Driver B, Gajic S, et al. Partial segmental thrombosis of the corpus cavernosum presenting to the ED. *Am J Emerg Med.* 2016;34(6):1182.e3-5.

CPC-EM Capsule

What do we already know about this clinical entity?

Partial segmental thrombosis of the corpus cavernosum (PSTCC) is a rare condition classically diagnosed with ultrasound or magnetic resonance imaging.

What is the major impact of the image(s)?

Although computed tomography (CT) has not been previously recommended for identifying this pathology, our case demonstrates that PSTCC can be clearly identified with CT.

How might this improve emergency medicine practice?

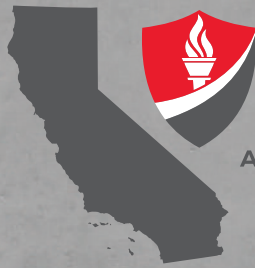This example of a rare pathology that may go unrecognized by emergency providers demonstrates the use of CT to aid in diagnosis.

Address for Correspondence: Jesse Wray, MD, San Antonio Uniformed Services Health Education Consortium, Department of Emergency Medicine, 3551 Roger Brooke Dr, Fort Sam Houston, TX 78234. Email: jesse.p.wray.mil@mail.mil.

Conflicts of Interest: By the CPC-EM article submission agreement, all authors are required to disclose all affiliations, funding sources and financial or management relationships that could be perceived as potential sources of bias. The view(s) expressed herein are those of the author(s) and do not reflect the official policy or position of Brooke Army Medical Center, the U.S. Army Medical Department, the U.S. Army Office of the Surgeon General, the Department of the Army, the Department of the Air Force and Department of Defense or the U.S. Government. The authors disclosed none.

Copyright: © 2020 Wray et al. This is an open access article distributed in accordance with the terms of the Creative Commons Attribution (CC BY 4.0) License. See: <http://creativecommons.org/licenses/by/4.0/>

**JOIN
CAL/AAEM!**



CALAAEM

CALIFORNIA CHAPTER DIVISION OF THE
AMERICAN ACADEMY OF EMERGENCY MEDICINE

*Championing
individual physician rights
and workplace fairness*

BENEFITS

- *Western Journal of Emergency Medicine* Subscription
- CAL/AAEM News Service email updates
- Discounted AAEM pre-conference fees
- And more!

CAL/AAEM NEWS SERVICE

- Healthcare industry news
- Public policy
- Government issues
- Legal cases and court decisions

In collaboration with our official journal

WestJEM Integrating Emergency Care
with Population Health



FACEBOOK.COM/CALAAEM



FOLLOW US @CALAAEM

[HTTP://WWW.CALAAEM.ORG](http://www.calaaem.org)



ADVANCED >

INSPIRED

> CALIFORNIA ACEP'S ANNUAL CONFERENCE 2020

Education is targeted to Medical Students and Residents, but all are welcome to attend.

Friday, September 25, 2020

Westin San Diego Gaslamp Quarter



CALIFORNIA ACEP
AMERICAN COLLEGE OF EMERGENCY PHYSICIANS