

# UC Irvine

## Clinical Practice and Cases in Emergency Medicine

### Title

CPC-EM Full-Text Issue

### Permalink

<https://escholarship.org/uc/item/6xq0d84c>

### Journal

Clinical Practice and Cases in Emergency Medicine, 5(4)

### Author

Nguyen, Trina

### Publication Date

2021

### DOI

10.5811/cpcem.2021.11.55343

### Copyright Information

Copyright 2021 by the author(s). This work is made available under the terms of a Creative Commons Attribution License, available at <https://creativecommons.org/licenses/by/4.0/>

Peer reviewed

# CPC Emergency Medicine

Volume V, Number 4, November 2021

Open Access at [www.cpcem.org](http://www.cpcem.org)

ISSN: 2474-252X

## *Clinical Practice and Cases in Emergency Medicine*

In Collaboration with the *Western Journal of Emergency Medicine*

### Clinicopathological Cases from the University of Maryland

- 369** 73-year-old Female with Syncope and Motor Vehicle Collision  
*Flanagan K, Dezman ZDW, Dachroeden KJ, Bontempo LJ*

### Case Series

- 377** Timely Diagnosis of Pneumoperitoneum by Point-of-care Ultrasound in the Emergency Department: A Case Series  
*Yum J, Hoffman T, Naraghi L*
- 381** Case Series of Three Patients with Disseminated Gonococcal Infection and Endocarditis  
*Moschella P, Shull H, Pittman M, Gleason A, Roth P*
- 385** Kinetic Projectile Injuries Treated During Civil Protests in Los Angeles: A Case Series  
*Pearl RC, Torbati S, Geiderman JM*
- 390** Push-Dose Pressors During Peri-intubation Hypotensions in the Emergency Department: A Case Series  
*Bakhsh A, Alotaibi L*

### Case Reports

- 394** Pheochromocytoma Leading to Multiorgan Failure in a Pregnant Patient: A Case Report  
*Myatt T, Barker M*
- 399** Thyroid Storm-induced Takotsubo Cardiomyopathy Presenting as Acute Chest Pain: A Case Report  
*Ashdown B, Hynes EC*
- 403** Point-of-care Ultrasound Diagnosis of Pulmonary Hydatid Cyst Disease Causing Shock: A Case Report  
*Hill A, Guillén M, Martin D, Dreyfuss A*
- 407** Rat-bite Fever: A Rare Diagnosis for a Common Pediatric Presentation: A Case Report  
*Edholm A, Heyer M, Nemetski SM*

Contents continued on page iii



**UC Irvine Health**





**ACOEP stands with all emergency  
physicians and providers on the  
front line. We thank you for your  
tireless work and effort.**



[www.acoep.org](http://www.acoep.org)

# Clinical Practice and Cases in Emergency Medicine

Indexed in PubMed and full text in PubMed Central

**Rick A. McPheeters, DO, Editor-in-Chief**  
Kern Medical/UCLA- Bakersfield, California

**Mark I. Langdorf, MD, MHPE, Senior Associate Editor**  
University of California, Irvine School of Medicine- Irvine, California

**Shahram Lotfipour, MD, MPH, Senior Associate Editor**  
University of California, Irvine School of Medicine- Irvine, California

**Shadi Lahham, MD, MS, Associate Editor**  
University of California, Irvine School of Medicine- Irvine, California

**Manish Amin, DO, Associate Editor**  
Kern Medical/UCLA- Bakersfield, California

**John Ashurst, DO, Decision Editor/ ACOEP Guest Editor**  
Kingman Regional Health Network, Arizona

**Anna McFarlin, MD, Decision Editor**  
Louisiana State University Health Science Center- New Orleans, Louisiana

**Austin Smith, MD, Decision Editor**  
Vanderbilt University Medical Center-Nashville, Tennessee

**Christopher Sampson, MD, Decision Editor**  
University of Missouri- Columbia, Missouri

**Joel Moll, MD, Decision Editor**  
Virginia Commonwealth University School of Medicine- Richmond, Virginia

**Scott Goldstein, DO, Decision Editor**  
Sidney Kimmel College of Medicine- Philadelphia, Pennsylvania

**Steven Walsh, MD, Decision Editor**  
Einstein Medical Center Philadelphia-Philadelphia, Pennsylvania

**Melanie Heniff, MD, Decision Editor**  
University of Indiana School of Medicine- Indianapolis, Indiana

**Gentry Wilkerson, MD, Decision Editor**  
University of Maryland School of Medicine

**Rachel A. Lindor, MD, JD, Decision Editor**  
Mayo Clinic College of Medicine and Science

**Jacqueline K. Le, MD, Decision Editor**  
Desert Regional Medical Center

**Christopher San Miguel, MD, Decision Editor**  
Ohio State University Wexner Medical Center

## Editorial Board

Amin A. Kazzi, MD, MAAEM  
The American University of Beirut, Beirut,  
Lebanon

Anwar Al-Awadhi, MD  
Mubarak Al-Kabeer Hospital, Jabriya,  
Kuwait

Arif A. Cevik, MD  
United Arab Emirates University  
College of Medicine and Health Sciences, Al  
Ain, United Arab Emirates

Abhinandan A. Desai, MD  
University of Bombay Grant Medical  
College, Bombay, India

Bandr Mzahir, MD  
King Fahad Medical City, Riyadh, Saudi  
Arabia

Barry E. Brenner, MD, MPH  
Case Western Reserve University

Brent King, MD, MMM  
University of Texas, Houston

Daniel J. Dire, MD  
University of Texas Health Sciences Center  
San Antonio

David F.M. Brown, MD  
Massachusetts General Hospital/Harvard  
Medical School

Edward Michelson, MD  
Texas Tech University

Edward Panacek, MD, MPH  
University of South Alabama

Erik D. Barton, MD, MBA  
Icahn School of Medicine, Mount Sinai,  
New York

Francesco Dellacorte, MD  
Azienda Ospedaliera Universitaria "Maggiore  
della Carità," Novara, Italy

Francis Counselman, MD  
Eastern Virginia Medical School

Gayle Galletta, MD  
Sørlandet Sykehus HF, Akershus  
Universitetssykehus, Lorenskog, Norway

Hjalti Björnsson, MD  
Icelandic Society of Emergency Medicine

Jacob (Kobi) Peleg, PhD, MPH  
Tel-Aviv University, Tel-Aviv, Israel

Jonathan Olshaker, MD  
Boston University

Katsuhiko Kanemaru, MD  
University of Miyazaki Hospital, Miyazaki, Japan

Khrongwong Musikataworn, MD  
King Chulalongkorn Memorial Hospital,  
Chulalongkorn University, Bangkok, Thailand

Leslie Zun, MD, MBA  
Chicago Medical School

Linda S. Murphy, MLIS  
University of California, Irvine School of  
Medicine Librarian

Nadeem Qureshi, MD  
St. Louis University, USA  
Emirates Society of Emergency Medicine,  
United Arab Emirates

Niels K. Rathlev, MD  
Tufts University School of Medicine

Pablo Aguilera Fuenzalida, MD  
Pontificia Universidad Católica de Chile,  
Región Metropolitana, Chile

Peter A. Bell, DO, MBA  
Liberty University  
College of Osteopathic Medicine

Peter Sokolove, MD  
University of California, San Francisco

Robert M. Rodriguez, MD  
University of California, San Francisco

Robert Suter, DO, MHA  
UT Southwestern Medical Center

Robert W. Derlet, MD  
University of California, Davis

Rosidah Ibrahim, MD  
Hospital Serdang, Selangor, Malaysia

Samuel J. Stratton, MD, MPH  
Orange County, CA, EMS Agency

Scott Rudkin, MD, MBA  
University of California, Irvine

Scott Zeller, MD  
University of California, Riverside

Steven Gabaeff, MD  
Clinical Forensic Medicine

Steven H. Lim, MD  
Changi General Hospital, Simei, Singapore

Terry Mulligan, DO, MPH, FIFEM  
ACEP Ambassador to the Netherlands Society of  
Emergency Physicians

Vijay Gautam, MBBS  
University of London, London, England

Wirachin Hoonpongmanont, MD, MSBATS  
Siriraj Hospital, Mahidol University, Bangkok,  
Thailand

## Advisory Board

Amal Khalil, MBA  
UC Irvine Health School of Medicine

Elena Lopez-Gusman, JD  
California ACEP  
American College of Emergency Physicians

Adam Levy, BS  
American College of Osteopathic Emergency  
Physicians

John B. Christensen, MD  
California Chapter Division of AAEM

Lori Winston, MD  
California ACEP  
American College of Emergency Physicians  
Kaweah Delta Healthcare District

Mark I. Langdorf, MD, MHPE  
UC Irvine Health School of Medicine

Jorge Fernandez, MD  
California ACEP  
American College of Emergency Physicians  
University of California, San Diego

Peter A. Bell, DO, MBA  
American College of Osteopathic Emergency  
Physicians  
Liberty University, College of Osteopathic Medicine

Robert Suter, DO, MHA  
American College of Osteopathic Emergency  
Physicians  
UT Southwestern Medical Center

Shahram Lotfipour, MD, MPH  
UC Irvine Health School of Medicine

Brian Potts, MD, MBA  
California Chapter Division of AAEM  
Alta Bates Summit-Berkeley Campus

## Editorial Staff

Isabelle Nepomuceno, BS  
Executive Editorial Director

Shreya Gupta, BS  
WestJEM Editorial Director  
Associate Marketing Director

Sohrab Kharabaf, BS  
CPC-EM Editorial Director  
Associate Marketing Director

Stephanie Burmeister, MLIS  
WestJEM Staff Liaison

June Casey, BA  
Copy Editor

Cassandra Saucedo, BS  
Executive Publishing Director

Nathan Do, BS  
WestJEM Publishing Director

Trina Nguyen, BS  
CPC-EM Publishing Director

Paul Abdo, BS  
WestJEM Associate Publishing Director  
Associate Marketing Director

Official Journal of the California Chapter of the American College of Emergency Physicians, the American College of Osteopathic Emergency Physicians, and the California Chapter of the American Academy of Emergency Medicine



Available in MEDLINE, PubMed, PubMed Central, Google Scholar, eScholarship, DOAJ, and OASPA.

Editorial and Publishing Office: WestJEM/Department of Emergency Medicine, UC Irvine Health, 333 City Blvd, West, Rt 128-01, Orange, CA 92866, USA

Office: 1-714-456-6389; Email: Editor@westjem.org



# Clinical Practice and Cases in Emergency Medicine

Indexed in PubMed and full text in PubMed Central

This open access publication would not be possible without the generous and continual financial support of our society sponsors, department and chapter subscribers.

## Professional Society Sponsors

AMERICAN COLLEGE OF OSTEOPATHIC EMERGENCY PHYSICIANS  
CALIFORNIA ACEP

CALIFORNIA CHAPTER DIVISION OF  
AMERICAN ACADEMY OF EMERGENCY MEDICINE

## Academic Department of Emergency Medicine Subscribers

|  |  |   |   |
|--|--|---|---|
| Albany Medical College<br>Albany, NY                     | INTEGRIS Health<br>Oklahoma City, OK                                 | Robert Wood Johnson University Hospital<br>New Brunswick, NJ            | University of Florida, Jacksonville<br>Jacksonville, FL                         |
| American University of Beirut<br>Beirut, Lebanon         | Kaweah Delta Health Care District<br>Visalia, CA                     | Rush University Medical Center<br>Chicago, IL                           | University of Illinois at Chicago<br>Chicago, IL                                |
| Arrowhead Regional Medical Center<br>Colton, CA          | Kennedy University Hospitals<br>Turnersville, NJ                     | Southern Illinois University<br>Carbondale, IL                          | University of Illinois College of<br>Medicine<br>Peoria, IL                     |
| Augusta University<br>Augusta GA                         | Kern Medical<br>Bakersfield, CA                                      | St. Luke's University Health Network<br>Bethlehem, PA                   | University of Iowa<br>Iowa City, IA   |
| Baystate Medical Center<br>Springfield, MA               | Lakeland HealthCare<br>St. Joseph, MI                                | Stanford/Kaiser Emergency Medicine<br>Residency Program<br>Stanford, CA | University of Louisville<br>Louisville, KY                                      |
| Beaumont Hospital<br>Royal Oak, MI                       | Lehigh Valley Hospital and Health Network<br>Allentown, PA           | Staten Island University Hospital<br>Staten Island, NY                  | University of Maryland<br>Baltimore, MD   |
| Beth Israel Deaconess Medical Center<br>Boston, MA       | Loma Linda University Medical Center<br>Loma Linda, CA               | SUNY Upstate Medical University<br>Syracuse, NY                         | University of Michigan<br>Ann Arbor, MI   |
| Boston Medical Center<br>Boston, MA                      | Louisiana State University Health Sciences Center<br>New Orleans, LA | Temple University<br>Philadelphia, PA                                   | University of Missouri, Columbia<br>Columbia, MO                                |
| Brigham and Women's Hospital<br>Boston, MA               | Madigan Army Medical Center<br>Tacoma, WA                            | Texas Tech University Health Sciences Center<br>El Paso, TX             | University of Nebraska Medical Center<br>Omaha, NE                              |
| Brown University<br>Providence, RI                       | Maimonides Medical Center<br>Brooklyn, NY                            | University of Alabama, Birmingham<br>Birmingham, AL                     | University of South Alabama<br>Mobile, AL                                       |
| Carl R. Damall Army Medical Center<br>Fort Hood, TX      | Maricopa Medical Center<br>Phoenix, AZ                               | University of Arkansas for Medical Sciences<br>Little Rock, AR          | University of Southern California/Keck<br>School of Medicine<br>Los Angeles, CA |
| Conemaugh Memorial Medical Center<br>Johnstown, PA       | Massachusetts General Hospital<br>Boston, MA                         | University of California, Davis Medical Center<br>Sacramento, CA        | University of Tennessee, Memphis<br>Memphis, TN                                 |
| Desert Regional Medical Center<br>Palm Springs, CA       | Mayo Clinic College of Medicine<br>Rochester, MN                     | University of California Irvine<br>Orange, CA                           | University of Texas, Houston<br>Houston, TX                                     |
| Doctors Hospital/Ohio Health<br>Columbus, OH             | Mt. Sinai Medical Center<br>Miami Beach, FL                          | University of California, Los Angeles<br>Los Angeles, CA                | University of Texas Health<br>San Antonio, TX                                   |
| Eastern Virginia Medical School<br>Norfolk, VA           | North Shore University Hospital<br>Manhasset, NY                     | University of California, San Diego<br>La Jolla, CA                     | University of Warwick Library<br>Coventry, United Kingdom                       |
| Einstein Healthcare Network<br>Philadelphia, PA          | Northwestern Medical Group<br>Chicago, IL                            | University of California, San Francisco<br>San Francisco, CA            | University of Washington<br>Seattle, WA   |
| Emory University<br>Atlanta, GA                          | Ohio State University Medical Center<br>Columbus, OH                 | UCSF Fresno Center<br>Fresno, CA  | University of Wisconsin Hospitals<br>and Clinics<br>Madison, WI                 |
| Genesys Regional Medical Center<br>Grand Blanc, Michigan | Ohio Valley Medical Center<br>Wheeling, WV                           | University of Chicago,<br>Chicago, IL                                   | Wake Forest University<br>Winston-Salem, NC                                     |
| Hartford Hospital<br>Hartford, CT                        | Oregon Health and Science University<br>Portland, OR                 | University of Colorado, Denver<br>Denver, CO                            | Wright State University<br>Dayton, OH   |
| Hennepin County Medical Center<br>Minneapolis, MN        | Penn State Milton S. Hershey Medical Center<br>Hershey, PA           | University of Florida<br>Gainesville, FL                                |   |
| Henry Ford Hospital<br>Detroit, MI                       | Presence Resurrection Medical Center<br>Chicago, IL                  |   |   |

## State Chapter Subscribers

ARIZONA CHAPTER DIVISION OF THE  
AMERICAN ACADEMY OF EMERGENCY MEDICINE  
CALIFORNIA CHAPTER DIVISION OF THE  
AMERICAN ACADEMY OF EMERGENCY MEDICINE  
FLORIDA CHAPTER DIVISION OF THE  
AMERICAN ACADEMY OF EMERGENCY MEDICINE

GREAT LAKES CHAPTER DIVISION OF THE  
AMERICAN ACADEMY OF EMERGENCY MEDICINE  
TENNESSEE CHAPTER DIVISION OF THE  
AMERICAN ACADEMY OF EMERGENCY MEDICINE

UNIFORMED SERVICES CHAPTER DIVISION OF THE  
AMERICAN ACADEMY OF EMERGENCY MEDICINE  
VIRGINIA CHAPTER DIVISION OF THE  
AMERICAN ACADEMY OF EMERGENCY MEDICINE

## International Society Partners

EMERGENCY MEDICINE ASSOCIATION OF TURKEY  
LEBANESE ACADEMY OF EMERGENCY MEDICINE  
MEDITERRANEAN ACADEMY OF EMERGENCY MEDICINE

NORWEGIAN SOCIETY FOR EMERGENCY MEDICINE  
SOCIEDAD ARGENTINA DE EMERGENCIAS

SOCIEDAD CHILENO MEDICINA URGENCIA  
THAI ASSOCIATION FOR EMERGENCY MEDICINE

To become a *WestJEM* departmental sponsor, waive article processing fee, receive print and copies for all faculty and electronic for faculty/residents, and free CME and faculty/fellow position advertisement space, please go to <http://westjem.com/subscribe> or contact:

Alissa Fiorentino  
*WestJEM* Staff Liaison  
Phone: 1-800-884-2236  
Email: [sales@westjem.org](mailto:sales@westjem.org)

## JOURNAL FOCUS

*Clinical Practice and Cases in Emergency Medicine* (CPC-EM) is a MEDLINE-indexed internationally recognized journal affiliated with the *Western Journal of Emergency Medicine* (WestJEM). It offers the latest in patient care case reports, images in the field of emergency medicine and state of the art clinicopathological and medicolegal cases. CPC-EM is fully open-access, peer reviewed, well indexed and available anywhere with an internet connection. CPC-EM encourages submissions from junior authors, established faculty, and residents of established and developing emergency medicine programs throughout the world.

## Table of Contents *continued*

- 412 **COVID-19 Associated Thyroid Storm: A Case Report**  
*K Sullivan, J Helgeson, A McGowan*
- 415 **Nutcracker Syndrome Masquerading as Renal Colic in an Adolescent Athlete: A Case Report**  
*RD Waldrop, P Henning*
- 419 **Gastric Pneumatosis After Accidental Ingestion of Concentrated Hydrogen Peroxide: A Case Report**  
*CXQ Pham, C Graves, M Uttaburanont, KP Singh, M Witkos*
- 422 **The Use of Point-of-care Ultrasound in the Diagnosis of Pott's Puffy Tumor: A Case Report**  
*J Acuña, D Shockey, S Adhikari*
- 425 **Early Extracorporeal Membrane Oxygenation in COVID-19 with Bullous Lung Disease on Mechanical Ventilation: A Case Report**  
*J Unold, B Marshal, T Sonuyi*
- 429 **A Case Report of Opisthotonos Associated with Administration of Intramuscular Ketamine**  
*MW Morgan, E Dore*
- 432 **A Chemist with a Strange Etiology of Rhabdomyolysis: A Case Report of a Rare Toxicological Emergency**  
*R Meenakshisundaram, JV Joseph, P Perumal, A Areeb, P Pancheti, DK Sampath, EM Jared*
- 436 **A Case Report of Acute Prostatitis Secondary to Use of P-valve Condom Catheter During Cave Diving**  
*A Barash, E Stern, R Hoelle*
- 440 **Atypical Presentation of Aseptic Meningitis Due to Varicella Zoster: A Case Report**  
*S Jia, T Luong*
- 443 **Bilateral Acute Angle-Closure Glaucoma: A Case Report of an Unusual Cause of Acute Headache in a Child**  
*B Kear, CR Gold, R Bhola*
- 447 **Didelphys Uterus in Pregnancy, an Uncommon Mullerian Duct Anomaly: A Case Report**  
*C Jorgensen, M Lusiak*
- 450 **An Uncommon Presentation of Cryptococcal Meningitis in an Immunocompetent Patient: A Case Report**  
*K Correa, S Craver, A Sandhu*

Policies for peer review, author instructions, conflicts of interest and human and animal subjects protections can be found online at [www.cpcem.org](http://www.cpcem.org).

## Table of Contents *continued*

- 455 **Small Bowel Volvulus as Delayed Presentation of Undiagnosed Crohn's Disease: A Case Report**  
*MTT Nguyen, A Ali, RP Bodkin*
- 459 **Atypical Presentation of *Haemophilus influenzae* Septic Arthritis: A Case Report**  
*AS Tadych, DE Catano, AL Brill*
- 463 **Whirlpool No More: A Case of Misdiagnosed Malrotation with Midgut Volvulus**  
*M Fogam, N Leigh, T She*

### Images in Emergency Medicine

- 466 **Diagnosis of Bladder Diverticula with Point-of-Care Ultrasound**  
*S Lahham, S Gutierrez*
- 468 **Computed Tomography Appearance of the "Whirlpool Sign" in Ovarian Torsion**  
*JK Livingston, S Gonzales, M Langdorf*
- 470 **Enterocutaneous Fistula and Abscess Diagnosed with Point-of-care Ultrasound**  
*S McCuskee, KL Anderson*
- 473 **Gastric Pneumatosis: An Atypical Presentation of Desmoid Tumor**  
*C Jorge, M Varela, JR Soares, H Uribe, L Flores, J Moreno*
- 476 **SAPHO Syndrome: An Unusual Cause of Dysphagia**  
*M Hoffer, M Salvo, S Batra*
- 479 **Pacemaker Lead Migration and Ventricular Perforation in a Patient Presenting with Chest Pain**  
*MC Cañizares-Otero, M Danckers*
- 482 **Adrenocortical Carcinoma Discovered with Point-of-care Ultrasound**  
*M McIntyre, MI Prats*
- 485 **Traumatic Anterior Dislocation of Ocular Cataract Lens**  
*T Shirke, K Wilcox, T Luong*
- 488 **Carpometacarpal Dislocation with Third Metacarpal Fracture**  
*C Jorgensen, SC Christos*
- 491 **Disseminated Kaposi Sarcoma**  
*LE Goyack, MA Heimann*

### ACOEP Clinicopathological Case

- 494 **The Tired Pregnant Woman**  
*K VanNatta, N Yuzuk, D Trotter, B Wisinski*

*Clinical Practice and Cases in Emergency Medicine* (CPC-EM) is a open-access Medline-indexed internationally recognized journal affiliated with the *Western Journal of Emergency Medicine* (WestJEM). CPC-EM is distributed electronically to 19,000 emergency medicine scholars. This includes our sponsors California ACEP, the American College of Osteopathic Emergency Physicians, California Chapter of AAEM, and over 83 academic department of emergency medicine subscribers and 8 AAEM State Chapters.

## Table of Contents *continued*

### **ACOEP Case Report**

- 499 Splenic Injury Following Colonoscopy: A Case Report**  
*J Wang, H Choi, J Ashurst*
- 502 48-year-old with Altered Mental Status and Respiratory Failure: A Case Report**  
*JE Pile, J Truong*
- 507 Acute Myocardial Infarction in a Patient with Twin Pregnancy: A Case Report**  
*T Michaelis, S Gunaga, T McKechnie, Q Shafiq*
- 511 Needle Decompression of Tension Pneumoperitoneum: A Case Report**  
*J Ray, N Exantus*
- 515 Bilateral Cranial Nerve VI Palsies in Cryptococcal Meningitis, HIV, and Syphilis: A Case Report**  
*G Rival, O Okorji, R Kern, P Patel, K Fradeneck, D Cullen*

*Clinical Practice and Cases in Emergency Medicine* (CPC-EM) is a open-access Medline-indexed internationally recognized journal affiliated with the *Western Journal of Emergency Medicine* (WestJEM). CPC-EM is distributed electronically to 19,000 emergency medicine scholars. This includes our sponsors California ACEP, the American College of Osteopathic Emergency Physicians, California Chapter of AAEM, and over 83 academic department of emergency medicine subscribers and 8 AAEM State Chapters.

# CPC**EM** Clinical Practice & Cases

## CALL FOR SUBMISSIONS

-Patient Care Case Reports

-Images in Emergency Medicine

Fully open-access, peer reviewed, well indexed: CPC-EM is available anywhere with an internet connection at **CPCEM.org**

*Clinical Practice and Cases in Emergency Medicine* is an internationally recognized journal affiliated with the MEDLINE-indexed **Western Journal of Emergency Medicine**

CPC-EM encourages submissions from junior authors and countries with developing emergency medicine programs

## IS NO DISABILITY INSURANCE A RISK YOU'RE WILLING TO TAKE?

COVID-19 HAS INCREASED THE RISKS OF PRACTICING EMERGENCY MEDICINE

## LET US PROTECT YOUR LIFESTYLE

- EMERGENCY MEDICINE SPECIFIC POLICIES
- MAJOR DISABILITY & LIFE INSURANCE COMPANIES
- DISCOUNTS AVAILABLE INCLUDING MILITARY & FEDERAL
- NO MEDICAL EXAM REQUIRED
- CURRENT POLICY CHECKUP

 **DI 4 MDS**  
DISABILITY INSURANCE SPECIALISTS  
30+ YEARS OF EXPERIENCE

**CONTACT NOW**



**Congratulations to WestJEM's and CPC-EM's  
Decision Editor and Section Editors of the Year!**

WestJEM's Section Editor

John Ashurst, DO  
Kingman Regional Health  
Network

WestJEM's Decision Editor

Andrew Phillips, MD, MEd  
Washington Hospital, Fremont, CA

CPC-EM's Section Editor

Austin Smith, MD  
Vanderbilt University

**Congratulations to WestJEM's and CPC-EM's  
Top Reviewers of the Year!**

Top 2 Reviewers

Aaron Dora-Laskey, MD      Ryan Misek, DO  
Michigan State University      Midwestern University

Top 20 Reviewers

<https://bit.ly/3woXV5C>

**Congratulations to ACEP President Elect, Dr. Christopher Kang!**

Christopher Kang, MD  
Madigan Army Medical Center  
WestJEM Disaster Medicine Section Editor

**Congratulations to ACEP's 2021 "25 Influencers Under 45 to Watch"!**

WestJEM Editorial Board Members

Chadd Kraus, DO, PhD  
Michael Gottlieb, MD  
Abra Fant, MD, MS



## 73-year-old Female with Syncope and Motor Vehicle Collision

Kevin Flanagan, DO\*

Zachary D.W. Dezman, MD, MS\*\*

Karl J. Dachroeden MD†

Laura J. Bontempo, MD, MEd\*

\*University of Maryland School of Medicine, Department of Emergency Medicine, Baltimore, Maryland

†University of Maryland, Department of Epidemiology and Public Health, Baltimore, Maryland

\*\*University of Maryland Medical Center, Department of Emergency Medicine, Baltimore, Maryland

Section Editor: Joel Moll, MD

Submission History: Submitted May 25, 2021; Revision received July 16, 2021; Accepted July 27, 2021

Electronically published November 1, 2021

Full text available through open access at [http://escholarship.org/uc/uciem\\_cpccem](http://escholarship.org/uc/uciem_cpccem)

DOI: 10.5811/cpcem.2021.7.53384

**Introduction:** Patients with traumatic injuries can be difficult to assess, and their evaluation often evolves in the emergency department (ED). We describe how an ED attending physician member developed a differential diagnosis for this presentation, arrived at a suspected diagnosis, and what test he proposed to prove his hypothesis.

**Case Presentation:** This clinicopathological case presentation details the initial assessment and management of a 73-year-old female who presented to the ED following a motor vehicle collision precipitated by a syncopal episode.

**Conclusion:** The final surprising diagnosis is then revealed. [Clin Pract Cases Emerg Med. 2021;5(4):369-376.]

**Keywords:** *syncope, takotsubo, CPC.*

### CASE PRESENTATION (DR. DACHROEDEN)

A 73-year-old female was brought by emergency medical services (EMS) to the emergency department (ED) after a motor vehicle collision (MVC). She was driving when her car crashed into a streetlamp at 40 miles per hour. The EMS team reported that the pole intruded into the passenger compartment and the patient required a prolonged extrication. She had a Glasgow Coma Scale score (GCS) of 11 when EMS arrived at the scene, which improved to a 15 after repeated evaluations. She was conscious, alert, and oriented at the scene and during transport.

The patient had difficulty recalling the events before the collision. She remembered feeling “like I was having a panic attack” just before the crash, and she did not recall the car impacting the streetlamp. In the ED, she complained of substernal chest pressure. The patient’s history was limited due to her continued difficulty recalling the events of the accident. The patient’s son was contacted and he stated that she lives alone and is active and independent. He stated that she had experienced syncopal episodes over the last several

years, all associated with paroxysms of panic when driving, and she had undergone extensive workups without any clear etiology identified. She had magnetic resonance imaging (MRI) of her brain with and without contrast four years prior for stroke-like symptoms after a syncopal event. Per his report, no abnormalities were found.

The patient had a past medical history of anxiety, migraines, Hashimoto thyroiditis, and hyperlipidemia. She had been diagnosed with breast cancer in 2012, which was treated with a left mastectomy followed by five years of tamoxifen and letrozole treatment. She had a family history of dementia, diabetes, and heart disease. She denied using tobacco, alcohol, or illicit substances. She was prescribed, and was taking, the following medications: levothyroxine 25 micrograms daily; atorvastatin 20 milligrams (mg) nightly; rizatriptan 10 mg as needed for headaches; and multivitamins.

On physical exam, the patient’s temperature was 36.5° Celsius, her heart rate was 92 beats per minute, and her blood pressure was 142/72 millimeters of mercury. She was

breathing at a rate of 21 breaths per minute with an oxygen saturation of 98% on room air. She weighed 125 pounds and was 5 feet, 3 inches tall, with a body mass index of 22.1 kilograms per meter squared. She did not appear to be in any acute distress, was healthy appearing, and was oriented to her name, date, and location. Her head was normocephalic and atraumatic; she had no Battle sign, raccoon eyes, or other signs of trauma. She had hearing aids in place bilaterally. She had normal extraocular movements with equal pupils that were reactive to light. She had a cervical collar in place. Later, when it was safe to remove her collar, her neck had a normal range of motion without rigidity or pain.

On auscultation, her heart had a regular S1 and S2 at a normal rate and was without murmurs. She had normal pulses bilaterally. Her lungs were clear without wheezing or rhonchi, and she was noted to have normal effort without respiratory distress. Her abdomen was soft and flat, without tenderness or guarding. Her musculoskeletal exam showed an overall normal range of motion without deformities. She had no step-offs of the spinous processes or tenderness along the midline spine. The remainder of her skeletal exam only revealed tenderness over the left wrist. She had a capillary refill of less than two seconds. On her skin exam, she had minor contusions to the left upper chest near the axilla with superficial abrasions along the left wrist. She was not diaphoretic. Neurologically she had no cranial nerve deficits, with no motor weakness or sensory deficits peripherally. She had a normal gait and normal coordination as well. She could not recall her birth date and had slow verbalization with some word-finding difficulty. Psychiatrically, she was normal in mood and behavior.

Point-of-care-ultrasound did not find evidence of free fluid within the abdominal or thoracic cavities and was negative for a pericardial effusion. Point-of-care ultrasound examination of her chest revealed normal lung sliding bilaterally. Chest radiograph showed no acute abnormalities. A radiograph of her pelvis showed no fracture or malalignment of the bones. A computed tomography (CT) of her head and brain showed no intracranial injury. A CT of the cervical spine and chest with contrast in the arterial phase was performed, which showed normal vertebral body height and alignment without fracture. The CT did show some mild atherosclerosis of the carotid and vertebral arteries, but no vascular injury and no obvious narrowing. Her trachea and mainstem bronchi were patent, she had no mediastinal abnormalities, the thoracic aorta was normal in appearance, and she had no pericardial effusion or pneumothorax (Image 1).

A CT of her abdomen and pelvis with contrast in the venous phase was also performed, which showed patent vasculature including a normal caliber aorta and inferior vena cava, normal appearing spleen, pancreas, adrenal glands and kidneys/ureters, a small hiatal hernia but otherwise normal appearing bowel, and no ascites or pneumoperitoneum. The radiologist did not find any fractures on her imaging or any soft

tissue injuries. Initial laboratory studies (Table 1), laboratory studies after administration of intravenous fluids (Table 2), and the patient's electrocardiograms (ECG) (Images 2) are shown. A test was then performed and a diagnosis was made.

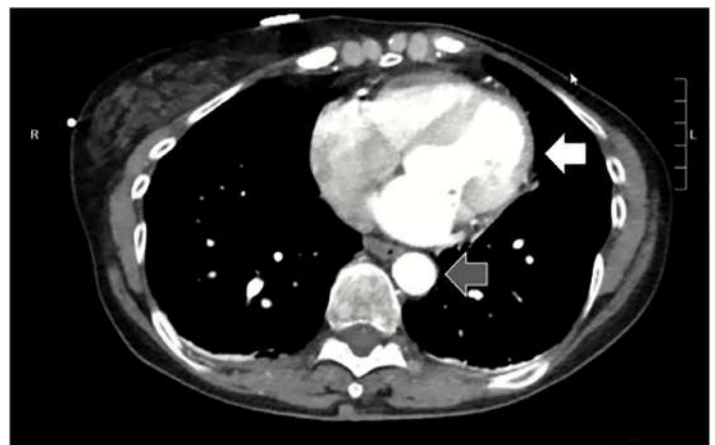### CASE DISCUSSION (DR. FLANAGAN)

Patients with traumatic injuries can be difficult to assess and their evaluation often evolves in the emergency department (ED). This case highlights how a meaningful history of present illness can be a priceless asset in the evaluation of a complicated trauma patient.

This case focuses on a 73-year-old female, restrained driver with confusion after being in a MVC. She later develops respiratory symptoms and chest pain while in the ED. While the history-taking is limited by her ongoing confusion, she describes a preceding syncopal event with a prodrome of anxiety.

This patient must be first evaluated through the lens of acute injury; so I applied the principles of Advanced Trauma Life Support. Her initial assessment was reassuring because there were no injuries identified that require immediate intervention. I calculated a GCS of 15 from the physical exam provided. Her vital signs were within normal limits and she is in no acute distress. This completes the primary trauma survey (airway, breathing, circulation and disability), but the mechanism of injury and several features of this case worry me.

My primary concern is her cardiopulmonary symptoms, which could be caused by an occult diaphragmatic, aortic, myocardial, or pulmonary injury, even though her vital signs are currently normal. Secondly, her disorientation, dysphasia, and lethargy are alarming. Despite a reassuring GCS, these findings could be a sign of an intracranial hemorrhage or due to an injury elsewhere causing poor cerebral perfusion.



**Image 1.** Transverse view of heart (white arrow) and descending aorta (gray arrow) taken from the computed tomography angiogram of the chest of a 73-year-old female with syncope and subsequent motor vehicle collision.

This patient clearly requires a rapid and thorough evaluation. The case presenter states the patient underwent an extended focused abdominal sonography in trauma (eFAST) examination, which did not show any free fluid. But the diagnostic capability of the eFAST exam is limited in hemodynamically stable patients; therefore, this patient needed to undergo CT and computed tomography angiography (CTA) imaging.<sup>1</sup> No traumatic injuries were identified on imaging, and her laboratory evaluation shows no evidence of anemia, severe metabolic derangement, or end organ damage.

The combination of physical examination and advanced imaging studies excludes acute traumatic injuries from my diagnosis. Her preceding symptoms of anxiety and the resulting

loss of consciousness now begs attention. Her son also noted multiple previous similar episodes of syncope, all while driving, with similar prodromal symptoms described as a “panic attack.” This sudden and transient loss of consciousness brings into question several etiologies including new-onset epilepsy and vascular and cardiogenic causes of syncope.

Her loss of consciousness could represent a seizure. Her symptoms of confusion, lethargy, and word-finding difficulty may represent a postictal state. Lactate can be elevated briefly after a seizure. Her prodrome of anxiety could represent a seizure with aura. But neither the patient nor her son reported a history of tonic-clonic like activity, and the patient did not experience any loss of bowel or bladder continence. Her brain imaging did not identify any significant ischemia, masses, or

**Table 1.** Initial laboratory results of 73-year-old female with syncope and subsequent motor vehicle collision.

| Test Name                      | Result       | Reference Range   |
|--------------------------------|--------------|-------------------|
| Complete blood cell count      |              |                   |
| White blood cells              | 10.2 K/mcL   | 4.5 - 11 K/mcL    |
| Hemoglobin                     | 13.2 g/dL    | 11.9 - 15.7 g/dL  |
| Hematocrit                     | 41.2%        | 35.0 - 45.0%      |
| Platelets                      | 200 K/mcL    | 153 – 367 K/mcL   |
| Complete metabolic panel       |              |                   |
| Sodium                         | 131 mmol/L   | 136 - 145 mmol/L  |
| Potassium                      | hemolyzed    | 3.5 - 5.1 mmol/L  |
| Chloride                       | 97 mmol/L    | 98 – 107 mmol/L   |
| Carbon dioxide                 | 18 mmol/L    | 21 -30 mmol/L     |
| Blood urea nitrogen            | 14 mg/dL     | 7 – 17 mg/dL      |
| Creatinine                     | 0.7 mg/dL    | 0.52 - 1.04 mg/dL |
| Glucose                        | 195 mg/dL    | 70 – 99 mg/dL     |
| Calcium                        | 10.3 mg/dL   | 8.6 - 10.2 mg/dL  |
| Magnesium                      | 2.4 mg/dL    | 1.6 - 2.6 mg/dL   |
| Phosphorus                     | 4.0 mg/dL    | 2.5 - 4.5 mg/dL   |
| Total protein                  | 7.4 g/dL     | 6.3 - 8.2 g/dL    |
| Albumin                        | 4.3 g/dL     | 3.2 - 4.6 g/dL    |
| Aspartate aminotransferase     | 46 units/L   | 14 - 36 units/L   |
| Alanine aminotransferase       | 24 units/L   | 0 - 34 units/L    |
| Total bilirubin                | 0.8 mg/dL    | 0.3 - 1.2 mg/dL   |
| Alkaline phosphatase           | 73 units/L   | 38 - 126 units/L  |
| Additional labs                |              |                   |
| Lactate                        | 8.6 mmol/L   | 0.5 - 1.6 mmol/L  |
| Troponin                       | 0.02 ng/mL   | <=0.06 ng/mL      |
| Partial thromboplastin time    | 21 seconds   | 25 – 38 seconds   |
| Prothrombin time               | 12.3 seconds | 12.1-15.0 seconds |
| International normalized ratio | 0.9          | unknown           |
| Fibrinogen                     | 354mg/dL     | 216 – 438 mg/dL   |
| Thyroid stimulating hormone    | 1.08 mIU/L   | 0.47-4.68 mIU/L   |

K, thousand; mcL, microliter; g, gram; dL, deciliter; mmol, millimoles; L, liter; mg, milligram; ng, nanogram; mIU, milli-international units; hpf, high powered field.

**Table 1 (continued).** Initial laboratory results of 73-year-old female with syncope and subsequent motor vehicle collision.

|                           |              |               |
|---------------------------|--------------|---------------|
| Urinalysis                |              |               |
| Color                     | Yellow       |               |
| Appearance                | Clear        |               |
| Specific gravity          | >1.040       | 1.002 - 1.030 |
| pH                        | 5.0          | 5.0 - 8.0     |
| Glucose                   | Negative     | Negative      |
| Bilirubin                 | Negative     | Negative      |
| Urobilinogen              | Negative     | Negative      |
| Ketones                   | Trace        | Negative      |
| Blood                     | Negative     | Negative      |
| Protein                   | Negative     | Negative      |
| Nitrite                   | Negative     | Negative      |
| Leukocyte esterase        | 1+           | Negative      |
| White blood cells         | 6 – 10 / hpf | 0 – 5 /hpf    |
| Red blood cells           | 6 – 10 /hpf  | 0 – 2/hpf     |
| Squamous epithelial cells | Negative     | Negative      |
| Bacteria                  | Negative     | Negative      |

K, thousand; *mCL*, microliter; *g*, gram; *dL*, deciliter; *mmol*, millimoles; *L*, liter; *mg*, milligram; *ng*, nanogram; *miU*, milli-international units; *hpf*, high powered field.

other parenchymal abnormalities, which are the most common causes of new-onset epilepsy in the elderly. Seizure, therefore, is lower on my differential diagnosis.

Vascular causes of syncope include aortic or carotid dissection, vertebrobasilar insufficiency, pulmonary embolism, and posterior strokes. However, none of these causes fit clinically with the presentation or the patient's recurrent prodrome. Furthermore, the patient's physical examination, radiology studies and prior brain MRI would have identified these conditions.

Cardiogenic causes of syncope are best summarized by three possibilities: arrhythmia, structural heart disease, and ischemia.

These are all best initially evaluated via electrocardiogram (ECG). Looking at the patient's first ECG, I do not see any of the following findings suggesting an arrhythmia:

- Arrhythmogenic intervals, such as a prolonged QT or high-degree atrioventricular blocks;
- Waveform morphologies concerning for pre-excitation pathways, Brugada syndrome, or arrhythmogenic right ventricular dysplasia.

There are no features on the ECG concerning for common structural heart diseases such as right or left ventricular hypertrophy. There is non-specific ST-segment depression inferiorly in leads II, III and aVF along with concave J-point elevations in V4 and V5. Her repeat ECG has similar features, but the ST-segment depression along the inferior leads is more pronounced and there are some dynamic changes along the precordium (lower amplitude T-waves V5 and V6), which is concerning for ischemia (Image 2).

I examined the patient's lab work for clues as to arrhythmogenic causes of syncope. There is no evidence of abnormalities of her serum potassium, calcium, or magnesium, which would place the patient at risk for an arrhythmia. Her troponins were not elevated on her initial lab results, making cardiac ischemia a less likely cause, but given the short interval since symptoms onset, these tests will need to be repeated.

While the patient's CTA imaging is limited because it captures a single moment in time, findings on CTA imaging are consistent with an underlying cardiac cause of the patient's presentation. The inferior vena cava, right heart, and pulmonary vascular circuit all appear prominent in the imaging and suggest some degree of left heart dysfunction. There are no overt masses that would represent a dynamic obstruction such as a left atrial myxoma, and I see no thickening of the left ventricular myocardium as would be found in patients with diastolic dysfunction. The shape of the left ventricle does appear abnormal, however. Normally, the left ventricle is conical in shape and tapers in diameter along the long axis. The luminal contour of the left ventricle in our patient's CTA appears dilated along the apical portion with no identifiable obstruction along the outflow tract.

In summary, this is a 73-year-old female with cardiopulmonary complaints following a MVC that was preceded by an anxiety-provoked syncopal event. Her evaluation shows no traumatic injuries but demonstrates dynamic ECG changes and abnormal cardiovascular findings on CTA imaging. Piecing together the clinical features of this presentation with her completed evaluation, I am concerned



**Table 2.** Repeat laboratory results taken two hours after arrival of a 73-year-old female with syncope and subsequent motor vehicle collision.

| Test Name                      | Result       | Reference range   |
|--------------------------------|--------------|-------------------|
| Complete metabolic panel       |              |                   |
| Sodium                         | 132 mmol/L   | 136 - 145 mmol/L  |
| Potassium                      | 3.4 mmol/L   | 3.5 - 5.1 mmol/L  |
| Chloride                       | 97 mmol/L    | 98 - 107 mmol/L   |
| Carbon dioxide                 | 23 mmol/L    | 21 -30 mmol/L     |
| Blood urea nitrogen            | 15 mg/dL     | 7 - 17 mg/dL      |
| Creatinine                     | 0.7 mg/dL    | 0.52 - 1.04 mg/dL |
| Glucose                        | 183 mg/dL    | 70 - 99 mg/dL     |
| Calcium                        | 9.3 mg/dL    | 8.6 - 10.2 mg/dL  |
| Total protein                  | 5.9 g/dL     | 6.3 - 8.2 g/dL    |
| Albumin                        | 3.3 g/dL     | 3.2 - 4.6 g/dL    |
| Aspartate aminotransferase     | 32 units/L   | 14 - 36 units/L   |
| Alanine aminotransferase       | 20 units/L   | 0 - 34 units/L    |
| Total bilirubin                | 0.4 mg/dL    | 0.3 - 1.2 mg/dL   |
| Alkaline phosphatase           | 62 units/L   | 38 - 126 units/L  |
| Additional labs                |              |                   |
| Lactate                        | 3.6 mmol/L   | 0.5 - 1.6 mmol/L  |
| Partial thromboplastin time    | 25 seconds   | 25 - 38 seconds   |
| Prothrombin time               | 13.5 seconds | 12.1-15.0 seconds |
| International normalized ratio | 1.0          | 0.9 - 1.1         |
| Fibrinogen                     | 296 mg/dL    | 216 - 438 mg/dL   |

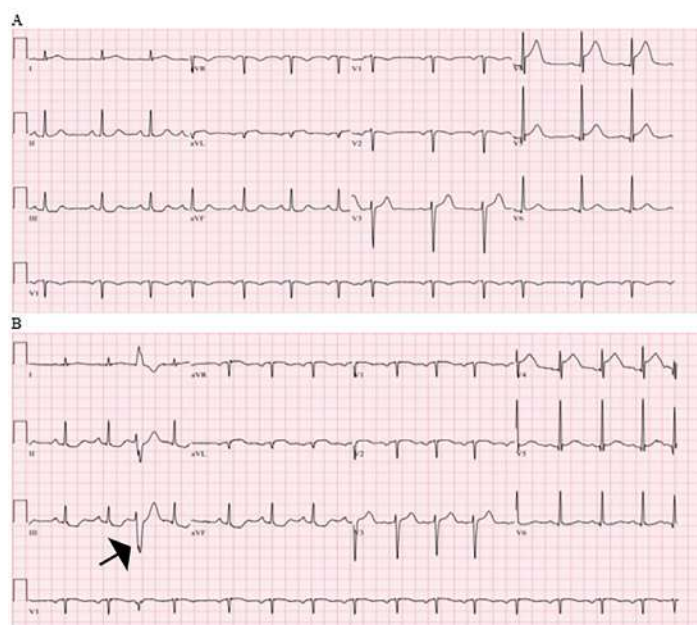
*Mmol*, millimoles; *L*, liter; *mg*, milligram; *dL*, deciliter; *g*, gram.

that there is an underlying cardiogenic etiology of her symptoms. Laboratory evaluation shows no current evidence of myocardial damage. The CTA imaging infers an underlying cardiac dysfunction with obvious prominence of the pulmonary and right-sided vasculature. Together with the abnormal shape of the left ventricle, these findings suggest a non-ischemic cardiomyopathy. The recurrence of these syncopal events, each time with prodromal anxiety is particularly interesting and suggests that her anxiety may be a causal factor of her symptoms.

When considered alongside her cardiopulmonary symptoms, her dynamic ECG changes, and the anatomical abnormalities identified along the apical portion of her left ventricle; I conclude that her diagnosis is takotsubo cardiomyopathy. This diagnosis would be confirmed by an echocardiogram.

#### CASE OUTCOME (DR. DACHROEDEN)

The study that led to the diagnosis was an echocardiogram (Image 3), which showed an ejection fraction (EF) of 40% with apical ballooning. These findings, plus the lack of any significant coronary artery disease found on emergent percutaneous coronary angiography, led to a diagnosis of



**Image 2.** Initial (A) and repeat (B) electrocardiogram of a 73-year-old female with syncope and subsequent motor vehicle collision. Noted is a premature ventricular complex (arrow) and ST-segment depression in the inferior leads

takotsubo cardiomyopathy. In the ED, the patient received 500 milliliters of normal saline for her lactic acidosis and she was started on aspirin, a beta-blocker, and an angiotensin-converting enzyme inhibitor. On her second hospital day, a cardiac MRI confirmed the diagnosis. She was seen by psychiatry who started her on buspirone, and after one week of hospitalization she was discharged. At her five-month follow-up visit she had complete return of her cardiac function.

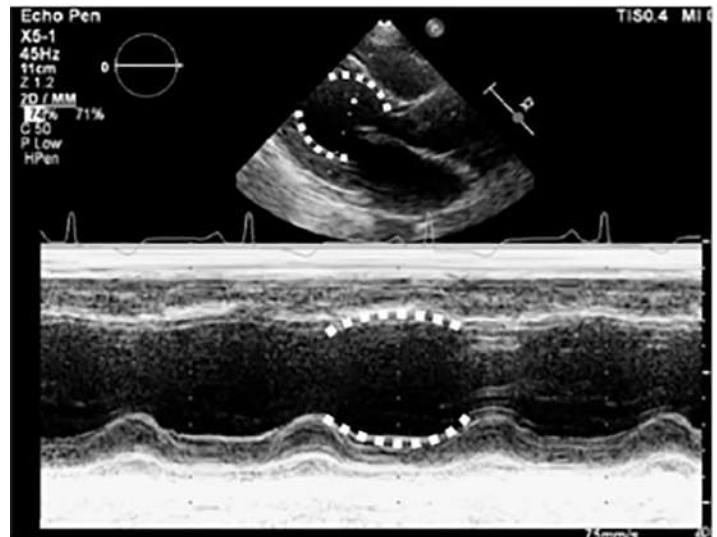
### RESIDENT DISCUSSION (DR. DACHROEDEN)

Takotsubo cardiomyopathy, or apical ballooning syndrome (ABS), is characterized by regional systolic dysfunction of the left ventricle (LV). It was first described in Japan in 1990.<sup>2,3</sup> The true incidence is still unknown, although it does appear to have greater incidence in women, the elderly, and those with thyroid disorders.<sup>4</sup> It is estimated to occur in 1-2% of cases of suspected acute coronary syndrome (ACS) or ST-elevation myocardial infarction (STEMI),<sup>5,6</sup> as well as in a significant percentage of critically ill patients.<sup>7</sup>

The most accepted pathophysiology of ABS is an excess of catecholamines leading to coronary artery spasm and myocardial stunning.<sup>8</sup> While an acute emotional stress is the classic trigger associated with ABS, causing it to also be referred to as “broken heart syndrome,” it is most commonly triggered by a severe medical illness.<sup>4,9</sup> The Mayo Clinic has proposed four criteria, all of which must be present to make the diagnosis of ABS: 1) transient left ventricular systolic dysfunction that involves more than the distribution of a single coronary artery; 2) absence of obstructive coronary disease/angiographic evidence of plaque rupture OR vessel disease that is not in the distribution of the wall motion abnormalities; 3) new ECG changes or modest elevation in troponin; and 4) absence of pheochromocytoma or myocarditis.<sup>12</sup> Note that the diagnosis can be made without a trigger being identified.

Cardiac dysfunction is usually documented using a combination of echocardiography, angiography, and cardiac MRI. A STEMI is present 43% of the time and is typically located in the anterior leads.<sup>4,11</sup> Cardiac biomarker testing is typically elevated to a significant degree in these patients, including troponin and brain natriuretic peptide levels.<sup>4</sup> The degree of ECG change or troponin elevation unfortunately has not been sufficient to differentiate between ACS and ABS but, interestingly, the brain natriuretic peptide levels do appear to exceed the levels found in their ACS-matched counterparts.

Treatment of this disease is primarily focused on supportive therapy with conservative management; most cases resolve in one to four weeks.<sup>13</sup> The most common complications are the development of cardiogenic shock, heart failure and thromboembolism. Interestingly, the development of shock does not appear to be related to a patient’s level of systolic dysfunction<sup>4,14</sup> but may be related to the presence of LV outflow tract (LVOT) obstruction.<sup>15</sup> An LVOT obstruction is important to identify to optimize management, as it changes



**Image 3.** Transthoracic echocardiogram of 73-year-old female at the left sternal border showing apical ballooning (white dotted line) in the long axis (top) and m-mode (bottom).

the expected treatment. Again, given the relatively recent discovery of this disease there are few trials comparing treatment in LVOT obstruction, however, based on knowledge of hypertrophic cardiomyopathy treatment, it does appear that a similar approach should be pursued. This includes using beta-blockers to improve filling and decrease obstruction, the avoidance of preload reduction<sup>16</sup> and balloon pump therapy in severe shock states that are refractory to initial management.

No formal studies have been performed to identify ideal heart failure management strategies in ABS. It is therefore recommended that patients be managed by standard protocols including diuresis<sup>17</sup> except when LVOT obstruction is present, as previously discussed. Given that the pathophysiology of this disease is suspected to be catecholamine related, inotropic agents that act through sympathetic mechanisms are thought to potentially worsen the disease, although they are recommended for temporization. Finally, there is a risk of intraventricular thrombus formation that may embolize; therefore, despite limited data, there are recommendations for anticoagulant therapy. If a thrombus is seen, then anticoagulation should continue for three months or until cardiac function returns and the thrombus resolves. If a thrombus is not seen, then the recommendation is anticoagulation for three months or until the significant cardiac dysfunction improves, whichever is shortest.

While ABS is primarily thought of as a transient disease, there are associated risks of in-hospital complications and morbidity after discharge, both of which more commonly occur in males. When compared to their ACS-matched



counterparts, ABS patients had similar or increased rates of serious in-hospital complication such as cardiogenic shock, need for vasopressors, ventilation (invasive and noninvasive), and cardiopulmonary resuscitation.<sup>4</sup> These events do appear to be more common in younger patients and those with a physical trigger, as well as those with underlying psychiatric disease, or a baseline EF of under 45%.<sup>4</sup> There is a 7.1% risk of major adverse cardiac or cerebrovascular events such as death, stroke, or transient ischemic attack in the first 30 days after admission, and again men are more affected than women.<sup>4</sup> Long-term follow-up of these patients demonstrates an all-cause mortality of 5.6% per patient-year and a rate of major adverse cardiac and cerebrovascular events of 9.9% per patient-year and, once again, men have worse outcomes than women.<sup>4</sup> Unfortunately, beta-blocker therapy has not been shown to improve survival rates at one year, although angiotensin-converting enzyme inhibitors were associated with improved survival.<sup>4</sup>

## FINAL DIAGNOSIS

Takotsubo cardiomyopathy (apical ballooning syndrome).

## KEY TEACHING POINTS

Takotsubo cardiomyopathy is also referred to as apical ballooning syndrome (ABS) and, more colloquially, as broken heart syndrome.

In ABS, an excess of catecholamines is thought to lead to coronary artery spasm and myocardial stunning, which can present as syncope and/or a STEMI.

A severe medical illness or emotional stress can trigger ABS.

If ABS is suspected, look for left ventricular outflow tract obstruction on echocardiogram, as this finding alters management.

In the absence of left ventricular outflow obstruction, treatment is supportive and the workup follows normal care patterns for suspected acute coronary syndrome.

The authors attest that their institution requires neither Institutional Review Board approval nor patient consent for publication of this case report. Documentation on file.

**Address for Correspondence:** Laura J Bontempo, MD, MEd, University of Maryland, Department of Emergency Medicine, 110 S Paca Street, 6<sup>th</sup> floor, Suite 200, Baltimore, Maryland 21201. Email: [lbontempo@som.umaryland.edu](mailto:lbontempo@som.umaryland.edu).

**Conflicts of Interest:** By the CPC-EM article submission agreement, all authors are required to disclose all affiliations, funding sources and financial or management relationships that could be perceived as potential sources of bias. The authors disclosed none.

**Copyright:** © 2021 Flanagan. This is an open access article distributed in accordance with the terms of the Creative Commons

Attribution (CC BY 4.0) License. See: <http://creativecommons.org/licenses/by/4.0/>

## REFERENCES

- Natarajan B, Gupta PK, Cemaj S, et al. FAST scan: Is it worth doing in hemodynamically stable blunt trauma patients? *Surgery*. 2010;148(4):695-700.
- Satoh H. Takotsubo-like left ventricular dysfunction due to multivessel coronary spasm. In: Kodama KK, Hori HM (Eds.), *Clinical Aspect of Myocardial Injury: From Ischemia to Heart Failure*. Kagaku Hyoronsha Publishing Co, 1990:56-64.
- Dote K, Sato H, Tateishi H, et al. Myocardial stunning due to simultaneous multivessel coronary spasms: a review of 5 cases. *J Cardiol*. 1991;21(2):203-14.
- Templin C, Ghadri JR, Diekmann J, et al. Clinical features and outcomes of takotsubo (stress) cardiomyopathy. *N Engl J Med*. 2015;373(10):929-38.
- Kurowski V, Kaiser A, von Hof K, et al. Apical and midventricular transient left ventricular dysfunction syndrome (Takotsubo cardiomyopathy): frequency, mechanisms, and prognosis. *Chest*. 2007;132(3):809-16.
- Gianni M, Dentali F, Grandi AM, et al. Apical ballooning syndrome or takotsubo cardiomyopathy: a systematic review. *Eur Heart J*. 2006;27(13):1523-9.
- Park JH, Kang SJ, Song JK, et al. Left ventricular apical ballooning due to severe physical stress in patients admitted to the medical ICU. *Chest*. 2005;128(1):296-302.
- Nef HM, Möllmann H, Kostin S, et al. Takotsubo cardiomyopathy: intraindividual structural analysis in the acute phase and after functional recovery. *Eur Heart J*. 2007;28(20):2456-64.
- Richard, C. Stress-related cardiomyopathies. *Ann Intensive Care*. 2011;1(1):39.
- Lyon AR, Rees PS, Prasad S, et al. Stress (takotsubo) cardiomyopathy: a novel pathophysiological hypothesis to explain catecholamine-induced acute myocardial stunning. *Nat Clin Pract Cardiovasc Med*. 2008;5(1):22-9.
- Parkkonen O, Allonen J, Vaara S, et al. Differences in ST-elevation and T-wave amplitudes do not reliably differentiate takotsubo cardiomyopathy from acute anterior myocardial infarction. *J Electrocardiol*. 2014;47(5):692-9.
- Prasad A, Lerman A, Rihal CS. Apical ballooning syndrome (takotsubo or stress cardiomyopathy): a mimic of acute myocardial infarction. *Am Heart J*. 2008;155(3):408-17.
- Wittstein IS, Thiemann DR, Lima JA, et al. Neurohumoral features of myocardial stunning due to sudden emotional stress. *N Engl J Med*. 2005;352(6):539-48.
- Singh K, Neil CJ, Nguyen TH, et al. Dissociation of early shock in takotsubo cardiomyopathy from either right or left ventricular systolic dysfunction. *Heart Lung Circ*. 2014;23(12):1141-8.
- De Backer O, Debonnaire P, Gevaert S, et al. Prevalence, associated

- factors and management implications of left ventricular outflow tract obstruction in takotsubo cardiomyopathy: a two-year, two-center experience. *BMC Cardiovasc Disord.* 2014;14:147.
16. Sharkey SW, Lesser JR, Zenovich AG, et al. Acute and reversible cardiomyopathy provoked by stress in women from the United States. *Circulation.* 2005;111(4):472-9.
17. Bybee KA, Kara T, Prasad A, et al. Systematic review: transient left ventricular apical ballooning: a syndrome that mimics ST-segment elevation myocardial infarction. *Ann Intern Med.* 2004;141(11):858-65.

# Timely Diagnosis of Pneumoperitoneum by Point-of-care Ultrasound in the Emergency Department: A Case Series

Jung Yum, MD  
Taryn Hoffman, MD, MS  
Leily Naraghi, MD

Maimonides Medical Center, Department of Emergency Medicine, Brooklyn, New York

Section Editor: Shadi Lahham, MD

Submission history: Submitted February 12, 2021; Revision received April 8, 2021; Accepted April 21, 2021

Electronically published July 27, 2021

Full text available through open access at [http://escholarship.org/uc/uciem\\_cpccm](http://escholarship.org/uc/uciem_cpccm)

DOI: 10.5811/cpcem.2021.4.52139

**Introduction:** Pneumoperitoneum is a life-threatening diagnosis that requires timely diagnosis and action. We present a case series of patients with perforated hollow viscus who were accurately diagnosed by emergency physicians using point-of-care ultrasound (POCUS) while in the emergency department (ED).

**Case Series:** Three elderly patients presented to the ED with the complaints of syncope, abdominal pain with constipation, and unresponsiveness. The emergency physicians used POCUS to diagnose and then expedite the necessary treatment.

**Conclusion:** Point-of-care ultrasound can be used by emergency physicians to diagnose pneumoperitoneum in the ED. [Clin Pract Cases Emerg Med. 2021;5(4):377–380.]

**Keywords:** *Emergency medicine; point of care ultrasound; pneumoperitoneum; free intraperitoneal air; enhanced peritoneal stripe sign; case series.*

---

## INTRODUCTION

Perforation of a hollow organ such as stomach or intestine is an acutely life-threatening condition. It requires urgent surgical intervention in up to 90% of patients and carries a high rate of associated peritonitis, sepsis, and death.<sup>1</sup> Despite advances in diagnostic and surgical technologies, morbidity and mortality associated with perforated viscus remains as high as 20-36%.<sup>2</sup> As a result, rapid diagnosis and early management is critical for positive patient outcomes.

The diagnosis of pneumoperitoneum has traditionally been made by upright chest radiograph (CXR) and/or computed tomography (CT). However, there are many factors in the emergency department (ED) that make it difficult to get these studies done in a timely manner. Ultrasound is more readily accessible and can be used to rapidly diagnose pneumoperitoneum and expedite management in the ED.

Sonographic diagnosis of pneumoperitoneum is made by first scanning the patient in supine position in both the right upper quadrant and midline of the patient's abdomen. These

areas are ideal as there is the least amount of bowel, especially in the right upper quadrant view between the anterior abdominal wall and liver. Next, the patient is scanned in the left lateral decubitus position for better visualization as air will collect in the least dependent area, the right upper quadrant.<sup>3</sup>

There are three main sonographic signs that indicate the presence of pneumoperitoneum. The first is referred to as the enhanced peritoneal stripe sign (EPSS).<sup>1</sup> As free air rises anteriorly in a supine patient, it makes contact with the peritoneal lining, creating a characteristic thick hyperechoic line.<sup>1,3,4</sup> Second is the shifting phenomenon. As the patient moves from one position to another, air will rise to the least dependent position. This results in shifting of the EPSS with movement, most notably from the anterior abdomen to the lateral aspect of the liver when the patient moves from supine to left lateral decubitus position.<sup>4</sup> The final sign is the ring-down artifact. In some cases, the presence of air can cause echoes at the air-to-soft tissue interface, causing posterior reverberation artifacts.<sup>3,4</sup>

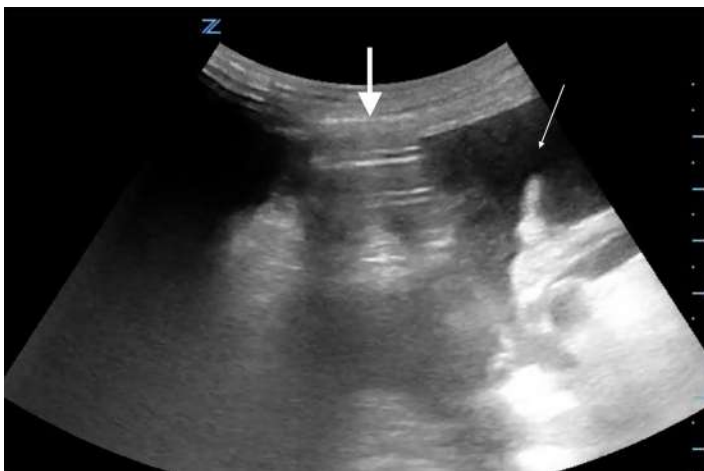Most studies evaluating the role of ultrasound in diagnosing pneumoperitoneum have been performed by radiologists. There is limited data available to demonstrate the role of point-of-care ultrasound (POCUS) in diagnosing pneumoperitoneum in the ED.<sup>4</sup> In this case series, we present three patients who had pneumoperitoneum diagnosed by an emergency physician using POCUS, which helped expedite further care in the ED.

## CASE SERIES

### Case 1

A 79-year-old male presented to the ED with a chief complaint of syncope. He had a past medical/surgical history of bladder cancer with prior neoadjuvant chemotherapy and subsequent consolidative cystoprostatectomy with ileal conduit and left nephrectomy. Prior to the syncopal episode, the patient had been complaining of abdominal pain associated with nausea and vomiting for two days. He was afebrile (98.6°F) with a heart rate of 135 beats per minute, blood pressure of 85/60 millimeters mercury (mm Hg), respiratory rate of 36 breaths per minute, and oxygen saturation of 94% on nasal cannula. On examination, the patient had an ileal conduit without active signs of infection; however, there was severe diffuse abdominal tenderness to palpation, which raised concern for peritonitis.

Point-of-care ultrasound showed a positive FAST exam (focused assessment with sonography for trauma) with free fluid in the abdomen (Image 1). It also showed a thick peritoneal stripe with posterior reverberation artifacts consistent with pneumoperitoneum and perforated viscus. Computed tomography of the abdomen/pelvis was expedited, which confirmed the diagnosis of pneumoperitoneum with viscus perforation. Meanwhile, the patient was given intravenous (IV)



**Image 1.** Abdominal ultrasound from Case 1 showing free intraperitoneal fluid (thin arrow) as well as free intraperitoneal air (thick arrow) as demonstrated by the enhanced peritoneal stripe sign and reverberation artifact.

### CPC-EM Capsule

What do we already know about this clinical entity?  
*Pneumoperitoneum caused by perforation of hollow viscus is a life-threatening diagnosis, requiring rapid diagnosis and surgical evaluation.*

What makes this presentation of disease reportable?  
*We present a case series in which point-of-care ultrasound (POCUS) was used to expedite diagnosis and management in three patients who presented to the emergency department (ED) with hollow viscus perforation and free intraperitoneal air.*

What is the major learning point?  
*When concerned about significant pathology such as hollow viscus perforation, ED providers should consider reaching for POCUS during their initial workup of the patient.*

How might this improve emergency medicine practice?  
*Understanding and utilizing POCUS during workup can help providers quickly make a diagnosis, thus expediting the definitive management the patient receives and improving their overall care.*

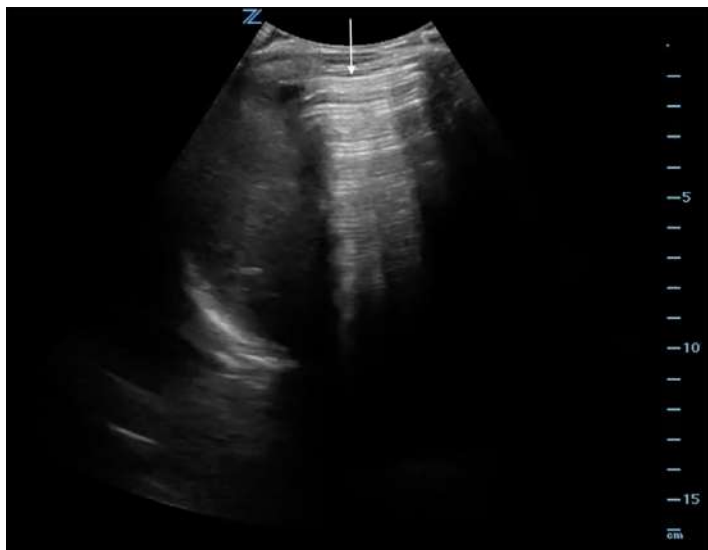
fluids, broad spectrum antibiotics, and pain control, and was started on vasopressors. Urology and general surgery were consulted immediately, and the patient was taken to the operating room (OR) emergently for exploratory laparotomy.

### Case 2

An 80-year-old male was brought into the ED from a nursing home for apparent abdominal pain and two weeks without having a bowel movement. The patient had a medical history of diabetes, hypertension, and dementia. He was unable to provide history due to his dementia. On exam, he was afebrile (97.3°F) with a blood pressure of 110/70 mm Hg, heart rate of 112 beats per minute and respiratory rate of 24 breaths per minute. His abdomen was nondistended, but it was diffusely tender with voluntary guarding.

Point-of-care ultrasound showed a positive FAST with free fluid in the abdomen. It also showed an EPSS suspicious for a perforation (Image 2). He was given IV fluids, analgesia, and broad-spectrum antibiotics. Computed tomography of the abdomen/pelvis confirmed free air and free fluid in the abdomen associated with ischemic jejunum with pneumatosis



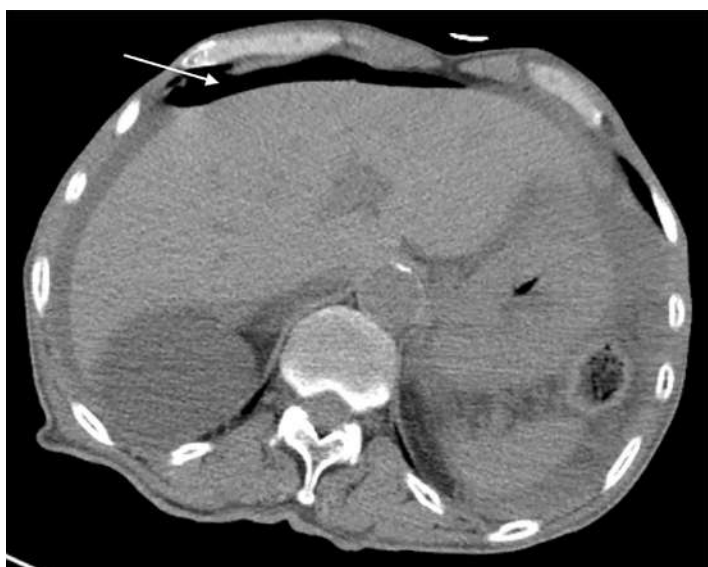

**Image 2.** Ultrasound image from Case 2 showing enhanced peritoneal stripe sign in the right upper quadrant, indicative of free intraperitoneal air (arrow).

intestinalis (Image 3). Surgery was consulted, and the patient was taken to the OR for emergent exploratory laparotomy.

### Case 3

An 88-year-old female was brought into the ED after she was found to be unresponsive at home. She had a medical history of hypertension and diabetes. Family reported that the patient had been lethargic for two days associated with poor oral intake. She also had an episode of nausea and bloody vomiting earlier that day. Upon arrival, she was hypoxic to 82% with respiratory rate of 30 breaths per minute even with non-rebreather mask. Heart



**Image 3.** Computed tomography image from Case 2 depicting free intraperitoneal air (arrow).

rate was 88 beats per minute. She was also hypotensive (74/39 mm Hg) with a mean arterial pressure of 50 mm Hg (reference range: 70-100 mm Hg). She was emergently intubated and was started on IV fluids, antibiotics, and vasopressors. Initial abdominal exam was limited due to her mental status, but her abdomen was noted to be distended.

Ultrasound showed EPSS with free air. The patient was started on broad spectrum antibiotics, and the expedited abdominal CT showed large volume pneumoperitoneum with perforation at the distal stomach. Surgery was consulted emergently; after further discussion her family decided against any surgical intervention and requested comfort care in the ED. The patient was subsequently admitted to the hospital for end-of-life care.

### DISCUSSION

Our case series reports the benefits of point-of-care sonographic detection of pneumoperitoneum in the ED. The diagnosis of pneumoperitoneum is usually identified by radiograph and/or CT. On radiographs, pneumoperitoneum is identified by the presence of subdiaphragmatic free air either in the upright or lateral decubitus position. It has been reported that plain radiographs can identify free air as little as one milliliter (mL) of intraperitoneal gas. However, the sensitivity is only 30-59%. Radiography is a reliable diagnostic test only when there are large volumes of free air (sensitivity approaches 100% when there is large volume pneumoperitoneum). In contrast, the sensitivity of CT in detecting free air is 96-100%; In addition, CT is able to identify the specific sites of perforation in 80-90% of cases.<sup>2</sup>

Nonetheless, there are circumstances that delay these imaging modalities significantly. Examples include patient's inability to stand or sit upright for an upright CXR, limited staffing/transport for CT, and hospital protocols that prioritize CT scanners for time-critical illnesses (eg, code strokes). As seen in two of our cases, there are also instances in which patients are obtunded or unresponsive, making physical exam less reliable even though they may, in fact, have significant underlying pathology. In these three cases, POCUS proved to be an excellent diagnostic tool to use at bedside. Studies have reported that as little as 1-2 mL of intraperitoneal free air can be detected by ultrasound.<sup>3,5</sup> Investigators have also reported a sensitivity of 93% and specificity of 64% for sonographic diagnosis of pneumoperitoneum and an even higher accuracy (sensitivity of 100% and specificity of 99%) when EPSS is present.<sup>2</sup>

While ultrasound is an accessible, cost-effective, and safe diagnostic tool, it comes with its own limitations. It is highly operator dependent with many factors that can prevent good quality images, including rib shadowing, bowel gas, obesity, and subcutaneous emphysema.<sup>3,5</sup> In addition, some critically ill or agitated patients may not tolerate the ultrasound probe on various regions of the abdomens.<sup>3</sup> Finally, ultrasound cannot identify the exact location of perforation.<sup>2</sup>

This case series highlights the benefits of using POCUS for the timely diagnosis of pneumoperitoneum in the ED to expedite management.

## CONCLUSION

In this case series, POCUS was used to identify signs of pneumoperitoneum, which helped expedite the CT and appropriate treatments and expert consultation in the ED. Thus, POCUS can be used as an extension to the physical examination for earlier detection and management of perforated bowel, especially in patients with concerning or limited abdominal exams. Further studies are required to investigate the effect of performing POCUS on the time to CT and definitive management in patients with abdominal emergencies.

The authors attest that their institution requires neither Institutional Review Board approval, nor patient consent for publication of this case report. Documentation on file.

## REFERENCES

1. Muradali D, Wilson S, Burns PN, et al. A specific sign of pneumoperitoneum on sonography: enhancement of the peritoneal stripe. *AJR Am J Roentgenol*. 1999;173(5):1257-62.

*Address for Correspondence:* Taryn Hoffman, MD, MS, Maimonides Medical Center, Department of Emergency Medicine, 965 48<sup>th</sup> St. Brooklyn, NY 11219. Email: [tarynhoffmanmd@gmail.com](mailto:tarynhoffmanmd@gmail.com).

*Conflicts of Interest:* By the *CPC-EM* article submission agreement, all authors are required to disclose all affiliations, funding sources and financial or management relationships that could be perceived as potential sources of bias. The authors disclosed none.

*Copyright:* © 2021 Yum et al. This is an open access article distributed in accordance with the terms of the Creative Commons Attribution ([CC BY 4.0](http://creativecommons.org/licenses/by/4.0/)) License. See: <http://creativecommons.org/licenses/by/4.0/>

2. Kumar A, Muir MT, Cohn SM, et al. The etiology of pneumoperitoneum in the 21st century. *J Trauma Acute Care Surg*. 2012;73(3):542-8.
3. Hefny AF and Abu-Zidan FM. Sonographic diagnosis of intraperitoneal free air. *J Emerg Trauma Shock*. 2011;4(4):511-3.
4. Shokoohi H, Boniface KS, Abell BM, et al. Ultrasound and perforated viscus; dirty fluid, dirty shadows, and peritoneal enhancement. *Emerg (Tehran)*. 2016;4(2):101-5.
5. Grechenig W, Peicha G, Clement HG, et al. Detection of pneumoperitoneum by ultrasound examination: an experimental and clinical study. *Injury*. 1999;30(3):173-8.



## Case Series of Three Patients with Disseminated Gonococcal Infection and Endocarditis

Phillip Moschella, MD, PhD\*

Hannah Shull, MD\*

Mark Pittman, MD\*

Alex Gleason, MD\*

Prerana Roth, MD, MPH†

\*Prisma Health-Upstate, Department of Emergency Medicine, Greenville, South Carolina

†Prisma Health-Upstate, Department of Infectious Diseases, Greenville, South Carolina

Section Editor: Steven Walsh, MD

Submission History: Submitted May 27, 2021; Revision received June 21, 2021; Accepted July 14, 2021

Electronically published October 26, 2021

Full text available through open access at [http://escholarship.org/uc/uciem\\_cpem](http://escholarship.org/uc/uciem_cpem)

DOI: 10.5811/cpcem.2021.7.53404

**Introduction:** The increasing incidence of *Neisseria gonorrhoeae* infections and emergence of cephalosporin-resistant strains means the threat of disseminated gonococcal infection and endocarditis needs to be reimagined into the differential diagnosis for patients treated in the emergency department (ED) for sexually transmitted infections and for endocarditis itself. Only 70 cases of disseminated gonococcal infection (DGI) with endocarditis had been reported through 2014.<sup>1-4</sup> In 2019, however, an outbreak of DGI with one case of endocarditis was reported.<sup>5</sup> This case series of three patients with DGI and endocarditis, in addition to the recent outbreak, may represent a warning sign for reemergence of this threat.

**Case Report:** We describe three cases within a recent three-year period of gonococcal endocarditis as seen and treated at our institution. These cases show divergent presentations of this insidious disease with both classical and atypical features. One case displayed a classic migratory rash with positive urine testing and a remote history of sexually transmitted infections, while another patient developed isolated culture-confirmed endocarditis with negative cervical testing and imaging, and the final case was a male patient who presented to the ED with fulminant endocarditis as the first ED presentation of infection.

**Conclusion:** Secondary to an overall rise in incidence and possibly due to increasing antibiotic-resistance patterns, gonococcal endocarditis should be included in the differential diagnosis of any case of endocarditis. Reciprocally, increased vigilance should surround the evaluation of any patient for sexually transmitted diseases while in the ED for both the development of DGI and endocarditis. [Clin Pract Cases Emerg Med. 2021;5(4):381-384.]

**Keywords:** *Neisseria gonorrhoeae*; gonococcal endocarditis; disseminated gonococcal infection; case report; case series.

---

### INTRODUCTION

*Neisseria gonorrhoeae*, a Gram-negative diplococcus, primarily infects the mucous membranes of the urethra and cervix. Disseminated gonococcal infection (DGI) occurs in 0.5-3% of patients with development of endocarditis in up to 1-2% of DGI patients. Before 1938, *N. gonorrhoeae* was responsible for up to 26% of all bacterial endocarditis and was uniformly fatal. With the advent of effective antibiotic

therapy, gonococcal endocarditis has become rare, yet mortality even with appropriate treatment remains high (19-20%).<sup>1-3</sup> It is important to re-emphasize the pathogenic capacity of *N. gonorrhoeae* given the following: 1) the increasing overall incidence of gonorrhea infections in the United States (US); 2) the emergence of new treatment-resistant strains; and 3) the high mortality rate associated with gonococcal endocarditis. A recent literature review

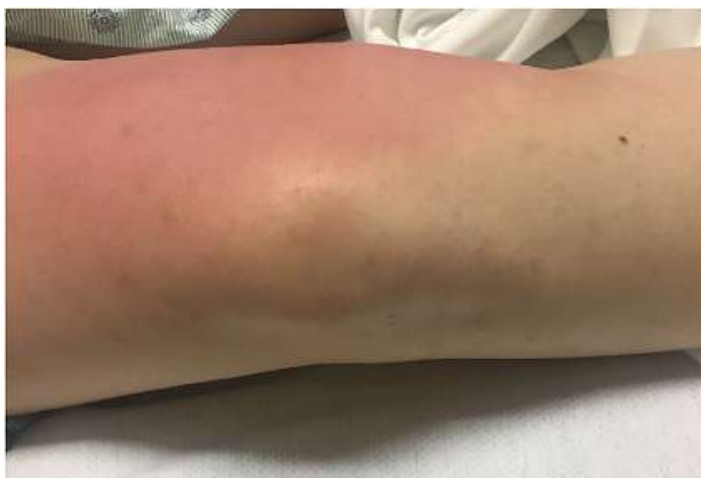found only 70 cases of gonococcal endocarditis had been reported in the literature after 1939.<sup>4</sup> Since then, a recent outbreak of DGI with one case of endocarditis was reported.<sup>5</sup> This report describes three additional separate cases of gonococcal endocarditis as seen within our emergency departments (ED) between 2017–2020. These patient presentations represent several ways in which this insidious disease may present and how gonococcal endocarditis was diagnosed and successfully treated. The comparative rarity of reporting on gonococcal endocarditis prior to 2014 and the fact that our single institution has had three such patients within a three-year period should serve as a warning for increased awareness and surveillance in the ED.

## CASE SERIES

### Case 1

A 26-year-old female presented to the ED in 2017 with a chief complaint of several days of nausea, abdominal pain, and a newly painful right knee associated with a migratory erythematous rash. The patient stated that one day prior, the same rash and pain were present on her contralateral knee but resolved with no treatment. Her past medical history (PMH) was significant for bipolar disorder and a chlamydia infection, successfully treated the prior year. Her social history was significant for tobacco and alcohol use, and no reported drug use. Her triage vital signs were temperature 36.7° Celsius, heart rate 87 beats per minute, blood pressure of 137/87 millimeters mercury (mm Hg), respiratory rate of 26 breaths per minute, and pulse oximetry of 99% on room air. Her physical exam (PE) was notable only for a large circular erythematous rash over the proximal aspect of her right knee and leg with full range of motion with minimal to no pain and no murmur on cardiac auscultation (Image).

She refused a vaginal exam. Significant laboratory results were as follows: white blood cell count 12.2 thousand per cubic millimeter ( $k/mm^3$ ) (reference range 4.5–11.5  $K/mm^3$ ;



**Image.** Erythematous rash of right knee.

### CPC-EM Capsule

What do we already know about this clinical entity?

*Gonococcal endocarditis following disseminated infection, although rare, has a high degree of mortality (~20%) even despite modern therapies.*

What makes this presentation of disease reportable?

*This case series highlights three separate cases in three years at one institution of this historically rare disease.*

What is the major learning point?

*The emergence of treatment resistant gonorrhea and increasing overall incidence may herald an unfortunate rise of gonococcal endocarditis.*

How might this improve emergency medicine practice?

*The differential for endocarditis should include gonorrhea with added vigilance during evaluation and treatment for emergency department patients with sexually transmitted infections.*

$mm^3$ ; C-reactive protein 3.5 milligrams per liter (mg/L) (reference less than 3.0mg/L); erythrocyte sedimentation rate 16 mm per hour (hr) (0–20 mm/hr); procalcitonin less than 0.05 nanograms per milliliter (ng/mL) (less than 0.1 ng/mL); rapid plasmin reagent was negative; urinalysis showed greater than 182 white blood cells per high-power field (HPF); greater than 182 red blood cells per HPF, and 5 squamous epithelial cells per HPF; urine pregnancy test was negative; and urine gonorrhea polymerase chain reaction was positive. A computed tomography (CT) of the abdomen and pelvis with intravenous (IV) contrast showed cholelithiasis without acute cholecystitis. Given her prior history of chlamydia infection, the migratory rash and joint pain, DGI was presumed, and blood cultures were obtained with initiation of IV ceftriaxone. Arthrocentesis was deferred. Several additional labs were ordered to evaluate for autoimmune disorders upon admission. Throughout her admission, the patient manifested several fevers across numerous nursing shifts with several sets of blood cultures (four total sets including the set obtained upon admission) obtained. All eventually showed no growth. A transthoracic

echocardiogram (TTE) was performed on hospital day four, which showed an abnormally thickened aortic valve. Transesophageal echocardiogram confirmed a mobile vegetation presumed to be gonococcal endocarditis, which was successfully treated with four weeks of IV ceftriaxone.

### Case 2

A 25-year-old female presented to the ED in 2018 with chief complaint of fever for one day and three weeks of cough, chest tightness, shortness of breath, abdominal pain, nausea, vomiting, fatigue, and an unintentional 10-pound weight loss. She had a PMH significant for mild asthma treated with a rescue inhaler and a remote history of chlamydia. She denied any alcohol, tobacco, or recreational drug use. Her triage vital signs were temperature 36.7°C, heart rate 87 beats per minute, blood pressure of 137/87 mm Hg, respiratory rate of 26 breaths per minute, and pulse oximetry of 99% on room air. Her PE was significant for a grade IV/VI systolic ejection murmur heard upon cardiac auscultation at the base of the heart. Significant laboratory results were as follows: white blood cell count 14.3 K/mm<sup>3</sup>; C-reactive protein 118.4 mg/L; erythrocyte sedimentation rate 83 mm/hr, procalcitonin 0.74 ng/mL, D-dimer 2.72 micrograms (µg)/mL (reference range <0.42 µg/mL), and a negative urine pregnancy. A CT angiogram of the chest was obtained and negative for pulmonary embolism but did show patchy infiltrates in the left lower lobe.

Blood cultures were drawn in the ED, and the patient was initially started on IV vancomycin and piperacillin-tazobactam and admitted to the hospital. A TTE was obtained upon admission and showed severe mitral regurgitation, concern for a ruptured chordae tendinea, and thickening/vegetations on the leaflets concerning for endocarditis. On hospital day two, both sets of blood cultures grew aerobic Gram-negative diplococci, which were identified as *N. gonorrhoeae* using a VITEK analyzer (bioMérieux, Inc. USA, Durham, NC). The isolate was sensitive to ceftriaxone. A pelvic exam found no discharge or cervical motion tenderness, and cervical gonococcal and chlamydia deoxyribonucleic acid probes were negative. A transvaginal ultrasound showed no abscess or signs of pelvic inflammatory disease. The patient underwent mitral valve replacement on hospital day five, and successfully completed six weeks of IV ceftriaxone.

### Case 3

A 20-year-old male presented to the ED in 2020 with a chief complaint of one month of worsening shortness of breath and malaise. He had no significant past medical history and denied any alcohol, tobacco, or recreational drug use. His triage vital signs were temperature 39.5°C, heart rate 117 beats per minute, blood pressure of 122/67 mm Hg, respiratory rate of 30 breaths per minute, and pulse oximetry of 99% on room air. Significant laboratory results were as follows: white blood cell count 16.4 K/mm<sup>3</sup>; C-reactive protein 129.3 mg/L; ferritin 333 ng/mL (reference range 22.0-275 ng/mL); and

procalcitonin 4.76 ng/mL (0.15 ng/mL). His initial PE was significant for a new IV/VI grade systolic ejection murmur heard at the base of the heart.

Initial blood cultures were obtained in the ED. He had negative screening tests for both severe acute respiratory syndrome coronavirus 2 and human immunodeficiency virus. A point-of-care TTE in the ED showed severe mitral regurgitation and concern for endocarditis. The patient was started on IV vancomycin and piperacillin-tazobactam. On hospital day two, admission blood cultures grew aerobic Gram-negative diplococci, and the patient was transitioned to ceftriaxone and ciprofloxacin. The organisms identified were *N. gonorrhoeae*, again using the VITEK analyzer. The isolate was sensitive to ceftriaxone. Further urine testing discovered only chlamydia, which was treated with azithromycin. The patient underwent mitral valve repair on hospital day 10, and he completed six weeks of IV ceftriaxone.

### DISCUSSION

This case series of three separate cases of DGI with development of endocarditis within a three-year period at a single institution has not been reported previously. Evidence suggests that asymptomatic infection may increase the risk of DGI, as it may lead to delay in diagnosis and subsequent antibiotic treatment. Thus, a lack of genital symptoms should not remove this from the differential.<sup>10</sup>

This case series shows some important atypical features that should serve to help increase awareness on the varied ways that DGI can present in the ED. Previous literature describes an increased prevalence of DGI and endocarditis in males<sup>1</sup>; however, our case series contains two women and one man. This series displays the insidious nature of this disease: one patient, despite multiple blood cultures obtained, was never able to culture the organism, yet she displayed a classic migratory rash that can accompany DGI and developed endocarditis on the aortic valve. Another patient was able to have the organism identified directly from blood cultures but had negative cervical swabs for infection and a history of previous chlamydia infection. Lastly, the male patient had no prior recorded sexually transmitted infection and no reported genital symptoms. He ultimately presented to the ED for his “initial” infection with fulminant endocarditis with positive blood cultures, but his urine was positive for chlamydia alone.

Several factors may be contributing to an overall increase in DGI and endocarditis. *N. gonorrhoeae* has been increasing in incidence across all races/ethnicities and is currently the second most commonly reported sexually transmitted infection in the US.<sup>6</sup> Along with this overall increasing incidence, there has also been emergence of cephalosporin-resistant strains, which has prompted the US Centers for Disease Control and Prevention to update recommendations for treatment, including an increase in the dose of intramuscular ceftriaxone from 250 mg to 500 mg.

Patients weighing more than 150 kilograms should be given 1 g of ceftriaxone.<sup>7-9</sup>

Evaluation in the ED for sexually transmitted infections should thus include a full skin and joint exam and a full cardiac exam. There should also be a low threshold to obtain an echocardiogram if any abnormalities are discerned. Overall, emergency physicians should consider DGI in all patients presenting with oligoarthritis, polyarthralgia, flu-like symptoms, dermatitis, tenosynovitis and, as noted in this case series, endocarditis. The constellation of arthritis and dermatitis with or without tenosynovitis may occur 2-3 weeks after the primary infection. Vesicular and/or pustular lesions are often painless; so a thorough physical examination of their common sites, the distal upper and lower extremities, is warranted. Tenosynovitis classically involves multiple tendons, also of the distal upper and lower extremities. Arthritis is more often migratory in nature and asymmetric.

## CONCLUSION

This case series highlights three divergent and atypical cases at one hospital system over a recent three-year period. The insidious nature of disseminated gonococcal infection and the atypical presentation of endocarditis in two women and one man within this series should serve as a warning sign for all emergency physicians to become more aware of this dangerous and deadly complication of possible untreated, or under-treated, gonorrhea. Increased surveillance for *N. gonorrhoeae* should be implemented across the US with rapid and widespread notification of all new cases of DGI/endocarditis to alert emergency physicians to either overall increasing incidence or penitance of antibiotic-resistant strains.

The authors attest that their institution requires neither Institutional Review Board approval nor patient consent for publication of this case series. Documentation on file.

*Address for Correspondence:* Phillip Moschella, MD, PhD, Prisma Health-Upstate, Department of Emergency Medicine, 701 Grove Road, Greenville, South Carolina 29605. Email: [phillip.moschella@prismahealth.org](mailto:phillip.moschella@prismahealth.org).

*Conflicts of Interest:* By the CPC-EM article submission agreement, all authors are required to disclose all affiliations, funding sources and financial or management relationships that could be perceived as potential sources of bias. The authors disclosed none.

*Copyright:* © 2021 Moschella. This is an open access article distributed in accordance with the terms of the Creative Commons Attribution (CC BY 4.0) License. See: <http://creativecommons.org/licenses/by/4.0/>

## REFERENCES

1. Nie S, Wu Y, Huang L, et al. Gonococcal endocarditis: a case report and literature review. *Eur J Clin Microbiol Infect Dis*. 2014;33(1):23-25.
2. Olayemi G, Oferczak M, Elagizi A, et al. Gonococcal endocarditis: the gift that stops giving! An uncommon presentation of a common disease. *J La State Med Soc*. 2017;169(2):47.
3. De Campos FP, Kawabata VS, Bittencourt MS, et al. Gonococcal endocarditis: an ever-present threat. *Autops Case Rep*. 2016;6(2):19-25.
4. Jackman J and Glamman B. Gonococcal endocarditis: twenty-five year experience. *The Am J Med Sci*. 1991;301(3):221-30.
5. Nettleton WD, Kent JB, Macomber K, et al. Notes from the field: ongoing cluster of highly related disseminated gonococcal infections—Southwest Michigan, 2019. *MMWR Morb Mortal Wkly Rep*. 2020;69(12):353-4.
6. Centers for Disease Control and Prevention. Sexually Transmitted Disease Surveillance 2018. 2018. Available at: <https://www.cdc.gov/std/stats18/gonorrhea.htm>. Accessed: 8/5/2020.
7. St Cyr S, Barbee L, Workowski KA, et al. Update to CDC's treatment guidelines for gonococcal infection, 2020. *MMWR Morb Mortal Wkly Rep*. 2020;69(50):1911-6.
8. Chen SC, Han Y, Yuan LF, et al. Identification of internationally disseminated ceftriaxone-resistant *Neisseria gonorrhoeae* strain FC428, China. *Emerg Infect Dis*. 2019;25(7):1427-9.
9. Lefebvre B, Martin I, Demczuk W, et al. Ceftriaxone-resistant *Neisseria gonorrhoeae*, Canada, 2017. *Emerg Infect Dis*. 2018;24(2):381-3.
10. O'Brien JP, Goldenberg DL, Rice PA. Disseminated gonococcal infection: a prospective analysis of 49 patients and a review of pathophysiology and immune mechanisms. *Medicine (Baltimore)*. 1983;62(6):395-406.



# Kinetic Projectile Injuries Treated During Civil Protests in Los Angeles: A Case Series

Rachel C. Pearl, MD  
Sam Torbati, MD  
Joel M. Geiderman, MD

Cedars-Sinai Medical Center, Department of Emergency Medicine, Los Angeles, California

Section Editor: Scott Goldstein, MD

Submission history: Submitted April 20, 2021; Revision received July 29, 2021; Accepted July 27, 2021

Electronically published October 19, 2021

Full text available through open access at [http://escholarship.org/uc/uciem\\_cpem](http://escholarship.org/uc/uciem_cpem)

DOI: 10.5811/cpcem.2021.7.52885

**Introduction:** During protests following the death of George Floyd, kinetic impact projectiles (KIP) were used by law enforcement as a method of crowd control. We describe the injuries seen at a single Level 1 trauma center in Los Angeles over a two-day period of protests to add to the collective understanding of the public health ramifications of crowd-control weapons used in the setting of protests.

**Case Series:** We reviewed the emergency department visits of 14 patients who presented to our facility due to injuries sustained from KIPs over a 48-hour period during civil protests after the death of George Floyd.

**Conclusion:** Less lethal weapons can cause significant injuries and may not be appropriate for the purposes of crowd control, especially when used outside of established guidelines. [Clin Pract Cases Emerg Med. 2021;5(4):385–389.]

**Keywords:** *case series, kinetic projectile, crowd control, less lethal weapons, protests.*

---

## INTRODUCTION

The United States saw a surge in the number of civil protests across the country following the death of George Floyd while in police custody. Law enforcement officers responded to these protests with crowd control measures, including in some instances the use of kinetic impact projectiles (KIP). As a result, protesters and bystanders alike suffered bodily injury ranging from superficial wounds to severe blunt and penetrating trauma resulting in injuries with potential for permanent disability. While protests are constitutionally protected and will always be part of our society, injuries associated with peaceful protests should not be. Thus, there is a need for further data regarding how crowd-control weapons (CCW) are used and the type and severity of injuries they cause, as well as appropriate recognition and management of these injuries by emergency physicians. We culled data from our institution to contribute to a collective understanding of the public health ramifications of CCW use in the setting of peaceful protests.

## CASE SERIES

We reviewed all emergency department (ED) visits at a Level I trauma center in Los Angeles, California, with proximity to the initial protests over the weekend of May 31–June 1, 2020, following the death of George Floyd on May 25. We searched for keywords suggesting traumatic injury either in the presenting complaint or final diagnosis. Upon review of those records captured by the criteria mentioned above, we further narrowed our search based on history and exam findings suggestive of traumatic injury inflicted by KIPs. Once cases were identified, we carefully reviewed each case, rating them for severity.

We defined minor injuries as those that were present on examination but did not require advanced professional medical care. These included contusions, abrasions, and sprains. Moderate injuries were defined as those requiring medical intervention, such as wounds and lacerations requiring suture repair and/or debridement, although the patients were safe for discharge from the ED with low

potential for long-term disability. We defined severe injuries as those requiring operative management and/or hospitalization. A final category would include patients with injuries resulting in permanent disability or death.

We identified 14 patients who presented to our ED with injuries sustained from KIPs at protests in Los Angeles over the weekend of May 31–June 1, 2020. The average age of the cohort was 31 years (range 21–62). Five patients were women (36%), and nine were men. Two of the patients had injuries categorized as minor, while four patients had injuries considered to be moderate, and the remaining eight had injuries that were categorized as severe. Except for one patient with possible permanent vision loss who was subsequently lost to follow-up, none of our patients were permanently disabled and none of the injuries were lethal. Patient characteristics, injuries, and treatments are summarized in the table below.

The preponderance of our patients (78%) across all severity categories were treated for injuries sustained to the face and head. One patient in the severe category was treated for injury to the groin, while another in the severe category was treated for injury to the upper extremity. We were unable to confirm the exact type of projectile causing injury in any given case, although based on the pattern of injury, we suspect the majority to have been rubber bullets, with pellet rounds in three cases.

An unanticipated finding among three of our patients with soft tissue injuries was the presence of embedded, high-density (metal) foreign bodies in facial wounds noted on computed tomography imaging (Patients d, f, and j). These injuries are suspected to have been caused by “pellet rounds.” These CCWs are metal cartridge projectiles filled with pellets composed of lead, steel, or plastic/rubber that disperse on impact. A representative image is shown to the right.

## DISCUSSION

Crowd-control weapons including KIPs have traditionally been described as “less lethal” munitions, intended to incapacitate individuals posing immediate threat with pain or nonlethal injury when compared with live, or *lethal*, ammunition. There has been ongoing scrutiny and criticism over the use of KIPs, particularly in the setting of crowd control regarding their potential for disproportionate and indiscriminate use. More than 75 types of KIPs are available, among them both single-projectile weapons (rubber and plastic bullets), and scatter projectiles (bean bag, flash, or pellet rounds), all of which are sold to police, military, and private security operations around the world.<sup>6</sup> Meanwhile, there is minimal discernible regulation when it comes to the manufacturing, marketing, and sales of these weapons.

Training for law enforcement on CCWs is unclear. A recent report found that while 40-millimeter rounds appeared

### CPC-EM Capsule

What do we already know about this clinical entity?

*The use of kinetic impact projectiles (KIP) as “less lethal” weapons can result in serious bodily harm. The most significant injuries involve the head and neck.*

What makes this presentation of disease reportable?

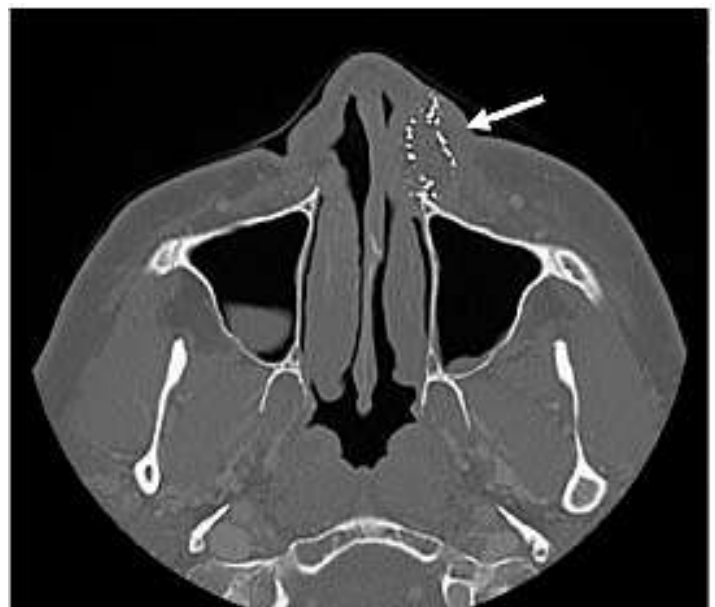*With the rise in number and frequency of protests worldwide, emergency physicians will likely see a rise in patients with injuries due to KIPs.*

What is the major learning point?

*The use of KIPs for crowd control may be inappropriate and unsafe from a public health perspective.*

How might this improve emergency medicine practice?

*Emergency physicians should become familiar with crowd-control weapons and the common injury patterns associated with their use.*



**Image.** Computed tomography image of multiple embedded, high-density foreign bodies within left facial wound (arrow).



**Table.** Patient characteristics, injuries, and disposition from kinetic impact projectiles.

| Patient | Age (yrs) | Gender | Purported Projectile | Injuries  | Severity | Intervention  | Hospitalized |
|---------|-----------|--------|----------------------|---|----------|---|--------------|
| a       | 24        | Male   | rubber bullet        | Subarachnoid hemorrhage, subdural hematoma, parenchymal hemorrhagic contusions, facial laceration/contusion | severe   | Intensive care unit stay, reversal of anticoagulation and suture repair | Yes          |
| b       | 21        | Male   | rubber bullet        | Open distal ulna fracture   | severe   | Surgical fixation   | Yes          |
| c       | 49        | Male   | rubber bullet        | Testicular rupture  | severe   | Surgical repair   | Yes          |
| d       | 26        | Female | pellet round         | Maxillary fracture, facial laceration, soft tissue foreign body   | severe   | Complex wound repair  | Yes          |
| e       | 31        | Female | rubber bullet        | Nasal bone fractures, facial laceration   | severe   | Complex wound repair, nasal fracture reduction                          | No           |
| f       | 27        | Female | Pellet round         | Complex facial lacerations, nasal fractures, soft tissue foreign body                                       | severe   | Complex wound repair  | No           |
| g       | 22        | Female | rubber bullet/fall   | Mandible fracture, lip laceration   | severe   | Surgical fixation, laceration repair                                    | Yes          |
| h       | 32        | Female | rubber bullet        | Orbital blowout fracture, hyphema, facial lacerations, corneal contusion                                    | moderate | Visual loss (lost to follow up)   | No           |
| i       | 28        | Male   | rubber bullet        | Facial bone fractures, facial laceration  | moderate | Suture repair   | No           |
| j       | 62        | Male   | pellet round         | Facial laceration, soft tissue foreign body, concussion   | moderate | Suture repair   | No           |
| K       | 30        | Male   | rubber bullet        | Scalp laceration, contusion of chest and neck   | moderate | Suture repair   | No           |
| l       | 23        | Male   | rubber bullet        | Face and arm lacerations, contusions  | moderate | Suture repair   | No           |
| m       | 28        | Male   | rubber bullet        | Dental fracture, facial contusion   | minor    | Dental referral   | No           |
| n       | 36        | Male   | rubber bullet        | Contusions & abrasions to abdomen and lower extremity   | minor    | Wound care  | No           |

to be responsible for most injuries sustained in Los Angeles during the George Floyd protests, Los Angeles Police Department (LAPD) officers were given only a one-time, two-hour training on the deployment of these munitions last in 2018. The report concludes that this level of training is woefully inadequate when considering the degree of skill and marksmanship required to use these weapons safely.<sup>7</sup> While some guidelines on CCW use exist at the international level, federal and local guidelines are limited and there is evidence that even those are not well adhered to. There is no governing body or process of formal data collection regarding the injuries they have caused, and thus no procedures are in place for accountability on behalf of the companies that produce these weapons and the individuals who wield them.<sup>5</sup> Most available data are limited to sparse case reports and case series in the medical literature,<sup>6</sup> as well as coverage in the media and posts on social media accounts.

A 2017 review found that among 1984 KIP injuries reported in the literature over a period of 27 years from around the world, 30% were characterized as “minor,” while 70% were characterized as “severe,” and 3% resulted in death.<sup>6</sup> These weapons have tremendous and unanticipated capacity for harm. Variables such as weapon shape and material, muzzle velocity, flight path, firing distance, and site of bodily impact influence not only injury severity, but target accuracy. Projectiles composed of dense materials such as metal will impart more force on impact. Others, designed with larger surface areas, have less predictable flight paths, especially when aimed from a distance. Inadequate understanding of these ballistic principles, including munition materials and their launching devices, by operators can lead to excessive harm to targeted individuals, as well as unintentional harm to bystanders. Much of the data previously reported suggest that injuries to the head and neck by KIPs tend to cause more harm than those to the limbs, leading

to a recommendation by the United Nations Human Rights Council and some manufacturers that the face and neck should be avoided when aiming these weapons.<sup>8</sup> The head, neck, spine, chest, groin, and kidneys are to be avoided according to LAPD policy guidelines as well. Our data reflect the importance of these guidelines.

## LIMITATIONS

There are several limitations in analyzing the data we collected. For one, our sample represents just a fraction of the injuries that were sustained across Los Angeles during the protests that weekend. Protests occurred in at least 49 cities in Los Angeles County, the nation's largest county. Some individuals may have sought care at other nearby medical facilities, while many may never have sought care at all. According to a report that pooled social media posts from across the US, there were at least 12 KIP-inflicted head injuries in the Los Angeles area that weekend, and at least 115 people nationwide who were shot in the neck or head between May 26–July 27 at protests following George Floyd's death in 2020.<sup>9</sup> At least one patient in our series initially attributed her injuries to a fall, to conceal her participation in the protests from her parents at the bedside. We may have missed other, likely minor or moderate injuries in our review from patients who did not disclose accurate details regarding the mechanism of traumatic injury.

It is important to note that we were unable to ascertain the circumstances surrounding the injuries we treated, including whether KIPs were fired indiscriminately, at what range, aim, and with what degree of real and/or perceived threat from protesters claiming to be peaceful. To what degree these injuries correlate with significance of threat from protesters is unclear. Furthermore, we could neither verify what type of personnel (law enforcement, military officials and/or civilians) were wielding these weapons nor how many times such weapons were used that weekend. The release of reports from a formal investigation commissioned by the Los Angeles City Council is concomitant with the submission of this article and should shed more light on these areas of uncertainty.

## CONCLUSION

Based on the limited data obtained from patients seen at our facility treated for injuries sustained from KIPs during the George Floyd protests in Los Angeles, there is concern that these weapons can result in significant injuries and may not be appropriate for the purpose of crowd control. While some guidelines exist to use these weapons in a "less lethal" manner, there are limitations in how those guidelines are disseminated or followed by law enforcement. These data and their implications have been echoed in similar reports from other major cities in the US and worldwide. Since protests are a fixture of our society, these observations should be carefully

considered by both the medical community and policymakers for the purpose of minimizing harm as law enforcement institutes crowd control measures.

The Institutional Review Board approval has been documented and filed for publication of this case report.

The authors would like to acknowledge Dr. Rohini Haar and Randy Olivera for their contributions to the production of this manuscript.

---

*Address for Correspondence:* Rachel C. Pearl, MD, Cedars-Sinai Medical Center, Department of Emergency Medicine, 8700 Beverly Blvd, Los Angeles, CA 90048. Email: Rachel.Pearl@cshs.com.

*Conflicts of Interest:* By the CPC-EM article submission agreement, all authors are required to disclose all affiliations, funding sources and financial or management relationships that could be perceived as potential sources of bias. The authors disclosed none.

*Copyright:* © 2021 Pearl. This is an open access article distributed in accordance with the terms of the Creative Commons Attribution (CC BY 4.0) License. See: <http://creativecommons.org/licenses/by/4.0/>

---

## REFERENCES

1. Buchanan L, Bui Q, Patel JK. Black Lives Matter may be the largest movement in U.S. history. *New York Times* 2020. Available at: <https://www.nytimes.com/interactive/2020/07/03/usgeorge-floyd-protests-crowd-size.html>. Accessed December 14, 2020.
2. Ifantides C, Christopher KL, Deitz GA, et al. Ophthalmic injuries by less-lethal kinetic weapons during the US George Floyd protests in Spring 2020. *JAMA Ophthalmol.* 2021;139(2):242-4.
3. Olson KA, Haselden LE, Zaunbrecher RD, et al. Penetrating injuries from "less lethal" bean bag munitions. *N Engl J Med.* 2020;383(11):1081-3.
4. Kaske E, Cramer S, Pino I, et al. Injuries from less-lethal weapons during the George Floyd protests in Minneapolis. *N Engl J Med.* 2021;384(8): 774-5.
5. Omega Research Foundation, Amnesty International. The human rights impact of less lethal weapons and other law enforcement equipment. 2015. Available at: <https://www.amnestyusa.org/reports/the-human-rights-impact-of-less-lethal-weapons-and-other-law-enforcement-equipment/>. Accessed December 14, 2020.
6. Haar RJ, Iacopino V, Ranadive N, et al. Death, injury and disability from kinetic impact projectiles in crowd control settings: a systematic review. *BMJ Open.* 2017;7(12):e018154.
7. Chaleff, G. An independent examination of the Los Angeles Police Department 2020 protest response. *New York Times* 2021. Available at: <https://www.nytimes.com/interactive/2021/03/11/us/lapd-george-floyd-protests-report.html>. Accessed March 13, 2021.

8. Office of the United Nations High Commissioner for Human Rights. Guidance on less-lethal weapons in law enforcement. 2020. Available at: [https://www.ohchr.org/Documents/HRBodies/CCPR/LLW\\_Guidance.pdf](https://www.ohchr.org/Documents/HRBodies/CCPR/LLW_Guidance.pdf). Accessed December 14, 2020.
9. Physicians for Human Rights. Shot in the head: crowd-control weapons have caused at least 115 head injuries across the United States during protests following the killing of George Floyd. 2020. Available at: <https://storymaps.arcgis.com/stories/29cbf2e87b914dbaabdec2f3d350839e>. Accessed December 14, 2020.
10. Culver, J. 'It seems systematic': Doctors group finds 115 cases of head injuries from crowd control weapons during nationwide protests. USA Today 2020. Available at: <https://www.usatoday.com/story/news/nation/2020/09/14/analysis-115-head-injuries-rubber-bullets-less-lethal-weapons/3468771001/>. Accessed December 14, 2020.
11. Los Angeles Police Department. Use of Force-Tactics Directive. 2018. Available at: [Lapd-assets.lapdonline.org/assets/pdf/td\\_11\\_crowd\\_mgmt.6.2011.pdf](https://assets.lapdonline.org/assets/pdf/td_11_crowd_mgmt.6.2011.pdf). Accessed December 15, 2020.
12. Wikipedia. George Floyd protests in California. 2020. Available at: [https://en.wikipedia.org/wiki/George\\_Floyd\\_protests\\_in\\_California#Los\\_Angeles\\_County](https://en.wikipedia.org/wiki/George_Floyd_protests_in_California#Los_Angeles_County). Accessed December 15, 2021.

# Push-Dose Pressors During Peri-intubation Hypotension in the Emergency Department: A Case Series

Abdullah Bakhsh, MBBS\*  
Leena Alotaibi, MBBS†

\*The King Abdulaziz University, Department of Emergency Medicine, Jeddah, Saudi Arabia

†The King Abdulaziz University, Faculty of Medicine, Jeddah, Saudi Arabia

Section Editor: Steven Walsh, MD

Submission history: Submitted December 14, 2020; Revision received April 8, 2021; Accepted April 21, 2021

Electronically published October 28, 2021

Full text available through open access at [http://escholarship.org/uc/uciem\\_cpccem](http://escholarship.org/uc/uciem_cpccem)

DOI: 10.5811/cpcem.2021.4.51161

**Introduction:** Emergency physicians frequently encounter critically ill patients in circulatory shock requiring definitive airway procedures. Performing rapid sequence intubation in these patients without blood pressure correction has lethal complications. Questioning the efficacy and fearing side effects of push-dose pressors (PDP) has created an obstacle for their use in the emergency department (ED) setting. In this case series we describe the efficacy and side effects of PDP use during peri-intubation hypotension in the ED.

**Case series:** We included 11 patients receiving PDPs in this case series. The mean increase in systolic blood pressure was 41.3%, in diastolic blood pressure 44.3%, and in mean arterial pressure 35.1%. No adverse events were documented in this case series.

**Conclusion:** The use of push-dose pressors during peri-intubation hypotension may potentially improve hemodynamic status when used carefully in the ED. [Clin Pract Cases Emerg Med. 2021;5(4):390–393.]

**Keywords:** *Push-dose pressors; peri-intubation hypotension; push-dose epinephrine; push-dose phenylephrine.*

## INTRODUCTION

Rapid sequence intubation (RSI) is the cornerstone of emergency airway management. Nonetheless, if not executed carefully the complications can be deadly.<sup>1</sup> In one study, patients with systolic hypotension (<90 millimeters of mercury [mmHg]) during RSI were more likely to sustain post-intubation cardiac arrest. The multivariate analysis showed that systolic hypotension was independently associated with post-intubation cardiac arrest (3.7 [95% confidence interval (CI), 1.6–8.6];  $P = 0.01$ ).<sup>2,3</sup> For many years, push-dose pressors (PDP) have been used in the operating room for rapid blood pressure correction.<sup>4,5</sup> This practice, however, has yet to be translated into standard emergency medicine practice.<sup>6</sup>

The emergency department (ED) environment poses unique challenges in ensuring seamless and safe administration; treatment of unfamiliar patients, crowding, reliance on verbal orders, dispensing and administering

medications without verification by a pharmacist, and understaffing.<sup>7</sup> A major reason for discouraging the use of such medications is that they add additional patient safety risks in addition to the complex, multistep process of using bolus-dose pressors.<sup>7,8</sup> Risks include the need for dose calculation, drug dilution, and incremental push-dose administration. These are all areas in which errors are common and potentially fatal.<sup>9,10</sup> In this case series we assessed the effect of PDP on blood pressure during RSI (defined as blood pressure change of at least 20%). We additionally assessed for any side effects including tachyarrhythmias, local tissue injury, and errors.

## CASE SERIES

The use of PDP during peri-intubation hypotension was part of a quality improvement program within the ED. We implemented a RSI bundle; this included instructions for PDP mixing (Supplementary). These instructions were

permanently attached to each intubation cart in the department, allowing immediate access. Additionally, an endotracheal intubation procedure note was completed for every patient requiring intubation by the emergency physician. We collected data retrospectively from intubation procedure notes. The notes included the following: patient information; diagnosis; indication for intubation; pre- and post-intubation vital signs; pre- and post-intubation drugs (with dose and time); number of intubation attempts; device used; operator level; and complications.

Push-dose pressors are prepared (following mixing instructions) and administered via large bore (14-18 gauge) peripheral intravenous (IV) access over one minute by the primary nurse. Vital signs were documented in the note at five minutes before and after the procedure. Adverse effects including extravasation and dysrhythmias were monitored for 30 minutes of PDP administration; standard procedure for nursing staff is to monitor for these adverse effects and document in the electronic health record if they do occur. Study investigators raised awareness of the new RSI bundle and PDP mixing instructions via departmental educational activities, bedside clinical demonstration, didactic lectures, and procedure note review. The bundle was approved by the department's chair and clinical practice committee.

We included patients undergoing the following: 1) RSI in the ED; or 2) receiving PDPs for a systolic blood pressure less than or equal to 100 mm Hg and/or diastolic blood pressure less than or equal to 60 mm Hg. During the one-year study period (January 2019–January 2020), a total of 86 patients underwent RSI by emergency physicians. Of those, only 11 patients received PDP for hypotension (defined as blood pressure less than or equal to 100/60 mm Hg within five minutes prior to the procedure). Table 1 describes the general characteristics of these patients. Table 2 describes the change in hemodynamic parameters in relation to PDP.

### CPC-EM Capsule

What do we already know about this clinical entity?

*Push-dose pressor (PDP) is common practice for rapid hemodynamic correction in the operating room. However, there is scant research examining the use of PDP in the emergency department.*

What makes this presentation of disease reportable?

*Understanding the effects of PDPs during peri-intubation hypotension will aid emergency physicians in clinical practice.*

What is the major learning point?

*Consider careful use of PDP for peri-intubation hypotension in the ED.*

How might this improve emergency medicine practice?

*Rapid correction of hemodynamic parameters prior to rapid sequence intubation, is crucial to lower deadly complications such as peri-intubation cardiac arrest.*

### Efficacy

We assessed the efficacy based on pre- and post-PDP vital signs in 11 patients (Table 3). The overall mean change in systolic blood pressure was 33.5 mm Hg (41.3% increase from baseline), the change in diastolic blood pressure was 21.4 mm Hg (44.3%

**Table 1.** General characteristics of patients undergoing rapid sequence intubation.

| Patient No. | Age/Gender | Indication for intubation   | Medications     |                        |
|-------------|------------|-----------------------------|-----------------|------------------------|
|             |            |                             | Induction       | Paralytic              |
| 1           | 57 F       | Anticipated clinical course | 100 mg ketamine | 50 mg rocuronium       |
| 2           | 59 F       | Hypoxic respiratory failure | 20 mg etomidate | 40 mg rocuronium       |
| 3           | 78 M       | Anticipated clinical course | 20 mg etomidate | 100 mg succinylcholine |
| 4           | 42 M       | Anticipated clinical course | 30 mg etomidate | 100 mg succinylcholine |
| 5           | 61 F       | Hypoxic respiratory failure | 20 mg etomidate | 100 mg succinylcholine |
| 6           | 62 M       | Airway protection           | 20 mg etomidate | 100 mg succinylcholine |
| 7           | 63 M       | Anticipated clinical course | 20 mg etomidate | 100 mg succinylcholine |
| 8           | 66 F       | Anticipated clinical course | 20 mg etomidate | 100 mg succinylcholine |
| 9           | 60 M       | Airway protection           | 20 mg etomidate | 100 mg succinylcholine |
| 10          | 51 M       | Airway protection           | 20 mg etomidate | 100 mg succinylcholine |
| 11          | 71 F       | Anticipated clinical course | 20 mg etomidate | 100 mg succinylcholine |

M, male; F, female; mg, milligrams.



**Table 2.** Change in hemodynamic parameters in relation to push-dose pressors.

| Patient no. | Pre-Push Dose Hemodynamics |     |     |     | PDP                   | Post-Push Dose Hemodynamics |     |     |     |
|-------------|----------------------------|-----|-----|-----|-----------------------|-----------------------------|-----|-----|-----|
|             | SBP                        | DBP | MAP | HR  |                       | SBP                         | DBP | MAP | HR  |
| 1           | 81                         | 51  | 51  | 81  | 10 mcg epinephrine    | 174                         | 94  | 121 | 128 |
| 2           | 70                         | 50  | 50  | 70  | 10 mcg epinephrine    | 84                          | 62  | 69  | 146 |
| 3           | 90                         | 62  | 71  | 95  | 20 mcg epinephrine    | 108                         | 85  | 93  | 98  |
| 4           | 93                         | 50  | 64  | 62  | 40 mcg epinephrine    | 104                         | 55  | 71  | 62  |
| 5           | 76                         | 35  | 49  | 106 | 10 mcg epinephrine    | 72                          | 36  | 48  | 110 |
| 6           | 82                         | 51  | 61  | 130 | 20 mcg epinephrine    | 106                         | 68  | 81  | 114 |
| 7           | 83                         | 46  | 58  | 63  | 200 mcg phenylephrine | 120                         | 57  | 78  | 84  |
| 8           | 87                         | 52  | 64  | 52  | 10 mcg epinephrine    | 97                          | 76  | 83  | 130 |
| 9           | 81                         | 48  | 59  | 91  | 10 mcg epinephrine    | 153                         | 76  | 102 | 87  |
| 10          | 65                         | 40  | 48  | 120 | 10 mcg epinephrine    | 146                         | 97  | 113 | 86  |
| 11          | 84                         | 46  | 59  | 100 | 10 mcg epinephrine    | 96                          | 60  | 72  | 89  |

*PDP*, push-dose pressor; *SBP*, systolic blood pressure (millimeters of mercury [mm Hg]); *DBP*, diastolic blood pressure (mm Hg); *MAP*, mean arterial pressure (mm Hg); *HR*, heart rate (beats per minute); *mcg*, micrograms.

increase from baseline), and in mean arterial pressure the change was 21.5 mm Hg (35.1% increase from baseline).

**Safety**

It is standard procedure to document any side effects from medication administration given intravenously. This is especially true for high-risk medications such as peripheral vasopressors. No events of extravasation or local tissue injury were documented in patients receiving PDP via peripheral IV route. Additionally, no documented cardiac dysrhythmias were found.

**DISCUSSION**

Significant data exist on the utilization and benefit of phenylephrine for hypotension induced by spinal anesthesia and neurologic emergencies.<sup>11,12</sup> However, only scant scientific evidence

examines the use of PDP for peri-intubation hypotension in the ED.<sup>6</sup> This case series describes a one-year cohort of patients receiving PDP for peri-intubation hypotension. We found a mean increase from baseline in all hemodynamic parameters with the use of PDP: systolic blood pressure increased by 41.3%; diastolic blood pressure increased by 44.3%; and mean arterial pressure increased by 35.1%. Rotando et al<sup>13</sup> evaluated PDP practice patterns and sought to determine the efficacy in hospitalized hypotensive patients outside of the operating room. Results show a mean increase in systolic blood pressure of 32.5% and a mean increase in diastolic blood pressure of 27.2%. Our series shows a larger mean increase in hemodynamic parameters. This is explained by the different agents used in both studies. The most frequently used PDP in this series is epinephrine (10 out of 11 patients). Previous reports, including those by Rotando et al, mostly used phenylephrine and ephedrine.<sup>6,13</sup>

**Table 3.** Overall mean hemodynamic parameters (before and after PDP\*) with mean percent change.

| Hemodynamic parameter | Blood pressure value and percent change with push-dose pressor |
|-----------------------|--|
| Pre-SBP               | 81.1 mm Hg   |
| Post-SBP              | 114.5 mm Hg  |
| Percent change        | 41.3%  |
| Pre-DBP               | 48.3 mm Hg   |
| Post-DBP              | 69.6 mm Hg   |
| Percent change        | 44.3%  |
| Pre-MAP               | 61.2 mm Hg   |
| Post-MAP              | 82.6 mm Hg   |
| Percent change        | 35.1%  |

*PDP*, push-dose pressor; *SBP*, systolic blood pressure; *DBP*, diastolic blood pressure; *MAP*, mean arterial pressure.

**LIMITATIONS**

First, this is a small sample size without comparison and therefore results are not generalizable. Second, the most commonly used PDP was epinephrine in 10 patients, while phenylephrine was only used in 1 patient. Third, this case series lacks data on patients requiring continuous vasopressor infusion after PDP. Fourth, dysrhythmias and extravasation was only monitored for 30-minutes post administration. While these PDPs are short-acting it is unclear if side effects may develop after the 3-minute time point.

**CONCLUSION**

Based on this small case series we conclude that the use of push-dose pressors causes a significant increase in systolic, diastolic, and mean arterial blood pressure (defined as >20% change). Therefore, if implemented with strict monitoring guidelines and appropriate education, we do not anticipate significant adverse events.

The authors attest that their institution requires neither Institutional Review Board approval, nor patient consent for publication of this case report. Documentation on file.

**Address for Correspondence:** Abdullah Bakhsh, The King Abdulaziz University, Department of Emergency Medicine, P.O. Box 80215, Jeddah, Saudi Arabia, 21589. Email: aarbakhsh@kau.edu.sa.

**Conflicts of Interest:** By the CPC-EM article submission agreement, all authors are required to disclose all affiliations, funding sources and financial or management relationships that could be perceived as potential sources of bias. The authors disclosed none.

**Copyright:** © 2021 Bakhsh et al. This is an open access article distributed in accordance with the terms of the Creative Commons Attribution (CC BY 4.0) License. See: <http://creativecommons.org/licenses/by/4.0/>

## REFERENCES

- Holler JG, Bech CN, Henriksen DP, et al. Nontraumatic hypotension and shock in the emergency department and the prehospital setting, prevalence, etiology, and mortality: a systematic review. *PLoS One*. 2015;10(3):e0119331.
- Marchick MR, Kline JA, Jones AE. The significance of non-sustained hypotension in emergency department patients with sepsis. *Intensive Care Med*. 2009;35(7):1261-4.
- Jones AE, Yiannibas V, Johnson C, et al. Emergency department hypotension predicts sudden unexpected in-hospital mortality: a prospective cohort study. *Chest*. 2006;130(4):941-6.
- Siddik-Sayyid SM, Taha SK, Kanazi GE, et al. A randomized controlled trial of variable rate phenylephrine infusion with rescue phenylephrine boluses versus rescue boluses alone on physician interventions during spinal anesthesia for elective cesarean delivery. *Anesth Analg*. 2014;118(3):611-8.
- Heesen M, Stewart A, Fernando R. Vasopressors for the treatment of maternal hypotension following spinal anaesthesia for elective caesarean section: past, present and future. *Anaesthesia*. 2015;70(3):252-7.
- Panchal AR, Satyanarayan A, Bahadir JD, et al. Efficacy of bolus-dose phenylephrine for peri-intubation hypotension. *J Emerg Med*. 2015;49(4):488-94.
- Weant KA, Bailey AM, Baker SN. Strategies for reducing medication errors in the emergency department. *Open Access Emerg Med*. 2014;6:45-55.
- Holden D, Ramich J, Timm E, et al. Safety considerations and guideline-based safe use recommendations for "bolus-dose" vasopressors in the emergency department. *Ann Emerg Med*. 2018;71(1):83-92.
- Kanwar M, Irvin CB, Frank JJ, et al. Confusion about epinephrine dosing leading to iatrogenic overdose: a life-threatening problem with a potential solution [published correction appears in *Ann Emerg Med*. 2010 Jul;56(1):23. Dosage error in article text]. *Ann Emerg Med*. 2010;55(4):341-4.
- Campbell RL, Bellolio MF, Knutson BD, et al. Epinephrine in anaphylaxis: higher risk of cardiovascular complications and overdose after administration of intravenous bolus epinephrine compared with intramuscular epinephrine. *J Allergy Clin Immunol Pract*. 2015;3(1):76-80.
- Habib A. A Review of the impact of phenylephrine administration on maternal hemodynamics and maternal and neonatal outcomes in women undergoing cesarean delivery under spinal anesthesia, anesthesia & analgesia. *Anesth Analg*. 2012;114(2):377-90
- Lee A, Ngan Kee W, Gin T. Quantitative, systematic review of randomized controlled trials of ephedrine versus phenylephrine for the management of hypotension during spinal anesthesia for cesarean delivery. *Anesth Analg*. 2002;94(4):920-6.
- Rotando A, Picard L, Delibert S, et al. Push dose pressors: experience in critically ill patients outside of the operating room. *Am J Emerg Med*. 2019;37(3):494-8.

# Pheochromocytoma Leading to Multiorgan Failure in a Pregnant Patient: A Case Report

Toby Myatt, MD  
Margot Barker, BS

University of California, Irvine, Department of Emergency Medicine, Irvine, California

Section Editor: Joel Moll, MD

Submission history: Submitted April 8, 2021; Revision received June 15, 2021; Accepted June 22, 2021

Electronically published August 31, 2021

Full text available through open access at [http://escholarship.org/uc/uciem\\_cpccm](http://escholarship.org/uc/uciem_cpccm)

DOI: 10.5811/cpcem.2021.6.52727

**Introduction:** Pheochromocytoma, a neuroendocrine tumor that secretes catecholamines, can present with episodic sweating, diaphoresis, headaches, and hypertension, as well as cardiac and pulmonary involvement. In a pregnant patient, it must be differentiated from preeclampsia, a leading cause of maternal mortality in the developed world, which can similarly present with hypertension and multiorgan involvement. Both conditions require early diagnosis and treatment to reduce maternal and fetal morbidity and mortality.

**Case Report:** We discuss the case of a pregnant patient at approximately 24 weeks' gestation presenting with chest pain and shortness of breath who was found to have a left adrenal mass and hypertensive urgency. The patient acutely decompensated during the course of evaluation. She ultimately suffered pregnancy loss and multiorgan failure requiring percutaneous heart pump placement and extracorporeal membrane oxygenation therapy for support before fully recovering. The adrenal mass was confirmed to be a pheochromocytoma after excision and contributed to the development of hypertensive emergency with multiorgan failure.

**Conclusion:** Pheochromocytoma during pregnancy is a rare condition but must remain on the differential until ruled out to improve patient outcomes as much as possible. Obtaining blood pressure control is imperative to reducing maternal and fetal mortality. Preeclampsia is similarly serious, and early diagnosis is essential for adequate management of the condition until delivery can occur. [Clin Pract Cases Emerg Med. 2021;5(4):394–398.]

**Keywords:** *medicine; pheochromocytoma; pregnancy; case report.*

---

## INTRODUCTION

Pheochromocytoma is a neuroendocrine tumor that secretes catecholamines, derived from chromaffin cells of the adrenal medulla or extra-adrenal paraganglia.<sup>1</sup> Typically, patients present with episodic sweating, diaphoresis, headaches, and hypertension, although presentations can be varied and multiple organ systems can be involved.<sup>1,2</sup> Cardiovascular and pulmonary involvement can also be associated with pheochromocytoma, including coronary spasm, arrhythmias, myocardial infarction, hemodynamic collapse, heart failure, pulmonary edema, and even cardiac arrest.<sup>3-5</sup> Diagnosis requires biochemical confirmation with urine or plasma fractionated metanephrines.<sup>6</sup> This is followed by radiologic studies to

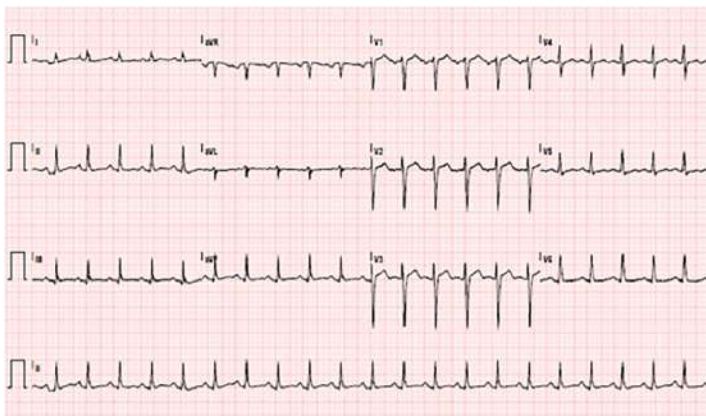
locate the tumor and resect if anatomically feasible.<sup>6</sup> It must be differentiated from preeclampsia, a condition with a very different etiology, that can also lead to multiorgan system involvement and is a leading cause of maternal mortality in the developed world.<sup>7</sup> It is defined as new-onset hypertension after 20 weeks' gestation with evidence of maternal organ dysfunction, proteinuria, or uteroplacental dysfunction.<sup>8</sup> Early diagnosis and treatment with a multidisciplinary approach are imperative, particularly in the case of a pregnant patient.

## CASE REPORT

A 36-year-old pregnant female (self-reported 24 weeks and 1 day gestation, with history of two prior pregnancies

resulting in one pre-term delivery and one full-term delivery) with a history of type 2 diabetes mellitus presented to the emergency department (ED) with a history of unprovoked, pressure-like chest pain for 3.5 hours. It was associated with shortness of breath, cough and nausea, and was worse when lying down. The patient had discovered she was pregnant two weeks previously and denied prior prenatal care or ultrasound. Additionally, she had recently been diagnosed with hypertension and started taking 100 milligrams (mg) labetalol twice daily one day before presenting. She had not taken labetalol on the day of her admission. In the ED, the patient was found to be severely hypertensive with systolic blood pressures (BP) in the 180s millimeters of mercury (mm Hg) and diastolic BP in the 120s mm Hg. She was also hypoxic with peripheral capillary oxygen saturation in the mid-80s percent on room air. An electrocardiogram (ECG) revealed sinus tachycardia at 129 beats per minute (Image 1).

Initial differential diagnosis included preeclampsia due to the recent diagnosis of hypertension, as well as pulmonary embolism, peripartum cardiomyopathy, and cardiac ischemia. The patient continued to experience worsening dyspnea and hypoxia despite trials on non-rebreather and bilevel positive airway pressure, and she was intubated. She was given 40 milligrams (mg) intravenous (IV) furosemide due to concern for flash pulmonary edema. She was then started on IV nitroglycerin and nicardipine as her BP remained consistently elevated to greater than 200/110 mm Hg. Laboratory studies revealed a pH of 6.9 (reference range: 7.35-7.45); bicarbonate of 11 milliequivalents per liter (mEq/L) (22-28 mEq/L); potassium of 7.9 mEq/L (3.5-5.0 mEq/L); and cardiac troponin that trended upward from 0.14 nanograms per milliliter (ng/mL) to 1.4 ng/mL (reference range: less than 0.04 ng/mL). Plasma-free normetanephrine was elevated at 273 nanomoles per liter (nmol/L) (reference range: less than 0.9 nmol/L), and free metanephrine was elevated at 4.8 nmol/L (less than 0.5 nmol/L).



**Image 1.** Electrocardiogram showing sinus tachycardia at 129 beats per minute.

### *CPC-EM Capsule*

What do we already know about this clinical entity?

*Pheochromocytoma is a rare condition that can present with varied symptoms and multisystem involvement that can present severely in the emergent setting.*

What makes this presentation of disease reportable?

*Early diagnosis and treatment of pheochromocytoma is necessary to reduce maternal and fetal morbidity and mortality.*

What is the major learning point?

*Reinforces the importance of a broad and comprehensive differential when evaluating patients in the emergency setting.*

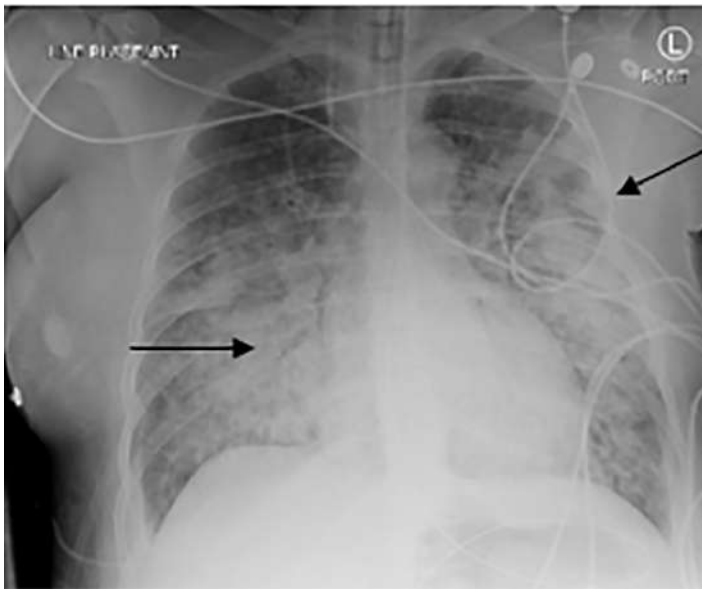
How might this improve emergency medicine practice?

*By adding to the body of knowledge regarding diagnosis and management of pregnant patients presenting with chest pain and shortness of breath in the emergency setting.*

Point-of-care ultrasound (POCUS) revealed B-lines consistent with severe pulmonary edema, an enlarged heart with depressed ejection fraction, and a live intrauterine pregnancy with fetal heart tones in the 120s-140s beats per minute. Computed tomography (CT) angiography of the chest was negative for pulmonary embolism. Both CT and chest radiograph showed diffuse pulmonary edema (Image 2). Computed tomography also revealed a suprarenal mass (Image 3). A repeat POCUS performed on day of presentation revealed intrauterine fetal demise.

The patient was given bicarbonate and insulin and glucose for profound acidosis and hyperkalemia, and she was transferred to the medical intensive care unit (MICU). She then experienced several convulsive episodes, which were initially thought to be eclamptic in etiology. She was first treated with 4 mg IV lorazepam rather than magnesium due to concern for potential exacerbation of pulmonary edema, but eventually required 2 mg magnesium to resolve seizures. The patient then became hypotensive and hypoglycemic and was treated with two ampules of 50% dextrose in water and started on vasopressors before undergoing emergent, uncomplicated

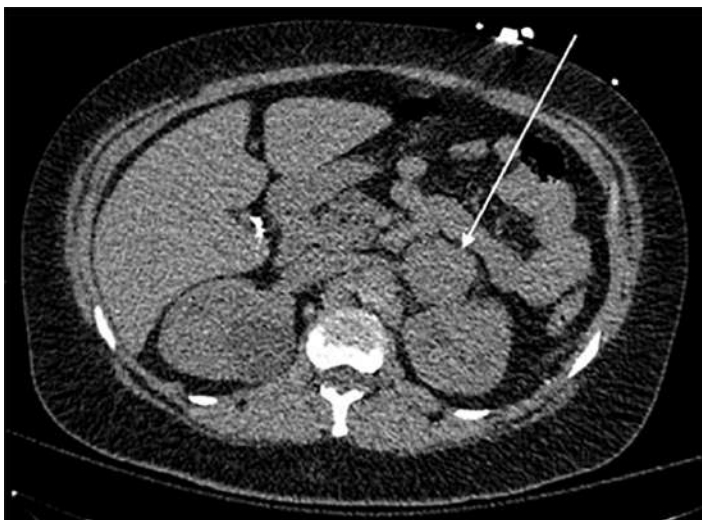



**Image 2.** Chest radiograph of patient with arrows showing diffuse pulmonary edema

cesarean section due to the presence of a large lower segment/cervical fibroid blocking access from the cervix.

The patient was returned to the MICU where she remained persistently hypotensive on milrinone, dobutamine, epinephrine, vasopressin, and norepinephrine. She was intermittently in ventricular tachyarrhythmia, with associated worsening of hypotension. A repeat ECG showed peaked T-waves with right bundle branch block and widened QRS complexes, suggestive of hyperkalemia. The ECG changes resolved with administration of calcium chloride. Nephrology



**Image 3.** Computed tomography showing soft tissue density lesion measuring approximately 4 centimeters (cm) x 4.5 cm in the left suprarenal region.

recommended initiation of continuous renal replacement therapy, which improved her hyperkalemia and resolved her ventricular tachyarrhythmia. However, the patient continued to be hypotensive despite maximal vasopressor support. A formal echocardiogram revealed an ejection fraction of 15%, prompting placement of a ventricular assist device for circulatory support.

At this point, the patient was suffering from multiorgan failure including renal failure, shock liver, acute heart failure, respiratory failure, and disseminated intravascular coagulation. She was still requiring the maximum dose of five vasopressors at that time. Her blood pressure remained stable until the next morning, when her mean arterial pressure (MAP) dropped to the 40s mm Hg. Continuous renal replacement therapy was stopped with improvement in her MAP improved to the 60s mm Hg. The patient was transferred to an outside facility for extracorporeal membrane oxygenation therapy. She was stabilized after several days and tolerated removal of the ventricular assist device. After continued supportive therapy, her organ function began to improve, with recovery of her heart, lung, liver, and kidney function. The patient subsequently underwent excision of the adrenal mass, which was confirmed to be a pheochromocytoma.

## DISCUSSION

Pheochromocytoma can be difficult to diagnose, as it can present with varied symptoms and lead to multisystem organ involvement. However, it is imperative to consider because it can lead to severe cardiovascular complications because of excessive catecholamine release and can be fatal if left untreated.<sup>3,4,9</sup> Preeclampsia is a condition that must be treated with a similar level of caution. While its etiology is unclear, it is theorized that it develops due to defective spiral artery formation and remodeling, which then leads to cellular ischemia in the placenta.<sup>10,11</sup> This causes a release of pro-inflammatory, anti-angiogenic factors, leading to widespread endothelial dysfunction affecting all maternal organ systems.<sup>10,11</sup> These alterations in vascular function contribute to the development of hypertension as well as multiorgan dysfunction, which is more severe with early-onset preeclampsia.<sup>10,12</sup> Additionally, women with diabetes and women with chronic hypertension are more likely to develop preeclampsia, both risk factors that were present in our patient.<sup>8,13</sup>

Early diagnosis and management of both conditions is essential to reducing patient morbidity and mortality. Our patient had no previous obstetric care, likely secondary to her lack of awareness of her pregnancy. This, coupled with her atypical and severe presentation, made diagnosis especially difficult. Suspicion was raised for pheochromocytoma due to the patient's refractory hypertension and incidentally observed suprarenal mass on imaging, which prompted diagnostic confirmation with plasma metanephrines and eventual surgical pathology. In addition, there was significant cardiac involvement, as well as pulmonary edema and multiorgan



dysfunction. Excessive catecholamine exposure, such as that caused by a pheochromocytoma, can cause cardiac dysfunction by inducing intracellular calcium overload in cardiomyocytes.<sup>3</sup> This can cause a variety of pathological cardiac symptoms, including coronary spasm, arrhythmias, myocardial infarction, hemodynamic collapse, heart failure, pulmonary edema, and even cardiac arrest.<sup>3,4</sup> Preeclampsia was also included in the differential due to her elevated BP on presentation, seizure activity, and significant reduction in BP following delivery.

Pheochromocytoma can be especially disastrous during pregnancy, occurring in approximately 1 in 54,000 pregnancies.<sup>14,15</sup> In addition to hypertension, pheochromocytoma can cause altered renal function and proteinuria as a result of catecholamine-induced renovascular abnormalities.<sup>15</sup> Because it is so rare, pheochromocytoma is often initially misdiagnosed as preeclampsia.<sup>15</sup> Diagnosis requires biochemical confirmation of elevated catecholamine levels: either 24-hour urine fractionated metanephrines and catecholamines or plasma fractionated metanephrines followed by radiologic studies to locate the tumor.<sup>6</sup> It is imperative to obtain BP control as soon as possible for all patients with pheochromocytoma, but especially in pregnant patients to prevent fetal demise, typically with alpha-blockers, beta-blockers, and magnesium sulfate.<sup>15</sup> Fetal loss associated with maternal pheochromocytoma is reported to be 11%.<sup>14</sup> Unfortunately, our patient presented with hypertensive crisis and fetal demise could not be prevented.

Definitive treatment of pheochromocytoma is surgical resection, and the timing during pregnancy is controversial.<sup>15</sup> For first trimester cases, surgical resection is not recommended due to high rates of miscarriage, while adrenalectomy is typically performed for patients presenting in their second trimester.<sup>15</sup> For patients presenting in the third trimester, surgical resection is often delayed until delivery and then performed concurrently with C-section.<sup>14,15</sup> Medical management, performed until surgical intervention can occur, consists of alpha-blockers, beta-blockers, and magnesium sulfate.<sup>15</sup> The alpha-blocker should be started before the beta-blocker to prevent unopposed alpha receptor stimulation.<sup>15</sup>

Magnesium sulfate is used in the treatment of both pheochromocytoma and preeclampsia because it reduces BP, inhibits catecholamine release, blocks peripheral catecholamine receptors, and causes vasodilation.<sup>15</sup> Definitive treatment of preeclampsia is delivery of both the baby and the placenta.<sup>8</sup> In the case of our patient, the fetus did not survive the patient's hypertensive crisis, and surgical resection of the adrenal mass was deferred until after stabilization and discharge to an outside facility. Pheochromocytoma was later confirmed on surgical pathology. Although preeclampsia was initially on the differential, given the presence of the suprarenal mass and elevated catecholamines, the patient was diagnosed with pheochromocytoma leading to the development multiorgan failure.

Early diagnosis of both pheochromocytoma and preeclampsia, especially with atypical presentation, remains difficult. In this case, the patient's shortness of breath and chest pain led to imaging that showed diffuse pulmonary edema and suprarenal mass. These findings, combined with her persistent hypertension, raised suspicion for both pheochromocytoma and preeclampsia. Unfortunately, pheochromocytoma often goes undiagnosed, especially when presenting with atypical symptoms. In patients without prenatal care, preeclampsia can also go undiagnosed until it becomes severely symptomatic. Given the life-threatening complications that can occur because of both conditions, diagnosis and multidisciplinary management are essential for reducing maternal and fetal mortality.

## CONCLUSION

Pheochromocytoma during pregnancy is a rare condition but must remain on the differential until ruled out to improve patient outcomes as much as possible. Obtaining blood pressure control is imperative to reducing maternal and fetal mortality. Preeclampsia is similarly serious and early diagnosis is essential for adequate management of the condition until delivery can occur.

The authors attest that their institution requires neither Institutional Review Board approval, nor patient consent for publication of this case report. Documentation on file.

---

*Address for Correspondence:* Toby Myatt, MD, University of California, Irvine, Department of Emergency Medicine, 333 City Blvd. West Suite 640, Orange, California 92868. [Email: myatt@hs.uci.edu](mailto:myatt@hs.uci.edu).

*Conflicts of Interest:* By the *CPC-EM* article submission agreement, all authors are required to disclose all affiliations, funding sources and financial or management relationships that could be perceived as potential sources of bias. The authors disclosed none.

*Copyright:* © 2021 Myatt. This is an open access article distributed in accordance with the terms of the Creative Commons Attribution ([CC BY 4.0](https://creativecommons.org/licenses/by/4.0/)) License. See: <http://creativecommons.org/licenses/by/4.0/>

---

## REFERENCES

1. Lenders JW, Eisenhofer G, Mannelli M, et al. Pheochromocytoma. *Lancet*. 2005;366(9486):665-75.
2. Gifford, Jr RW, Bravo EL, et al. Diagnosis and management of pheochromocytoma. *Cardiology*. 1985;72(1):126-30.
3. Adameova A, Abdellatif Y, Dhalla NS. Role of the excessive amounts of circulating catecholamines and glucocorticoids in stress-induced heart disease. *Can J Physiol Pharmacol*. 2009;87(7):493-514.
4. Berra E, Gonzalez MC, Scavée C, et al. High prevalence of cardiac

- electric abnormalities in patients with phaeochromocytomas. *J Hypertens*. 2017;35(4):899-901.
5. Solorzano CC, Parks J, Prinz RA. Pheochromocytoma presenting with multiple organ failure. *Am Surg*. 2008;74(11):1119-21.
  6. Lenders JWM, Pacak K, Walther MM, et al. Biochemical diagnosis of pheochromocytoma: Which test is best? *J Am Med Assoc*. 2002;287(11):1427-34.
  7. Orabona R, Sciatti E, Prefumo F, et al. Pre-eclampsia and heart failure: a close relationship. *Ultrasound Obstet Gynecol*. 2018;52(3):297-301.
  8. Fox R, Kitt J, Leeson P, et al. Preeclampsia: risk factors, diagnosis, management, and the cardiovascular impact on the offspring. *J Clin Med*. 2019;8(10):1625.
  9. Meseeha MG and Sattur S. Acute systolic heart failure and uncontrolled hypertension: What is the missing link? *Postgrad Med*. 2016;128(7):722-4.
  10. Gathiram P and Moodley J. Pre-eclampsia: its pathogenesis and pathophysiology. *Cardiovasc J Afr*. 2016;27(2):71-8.
  11. Palei AC, Spradley FT, Warrington JP, et al. Pathophysiology of hypertension in preeclampsia: a lesson in integrative physiology. *Acta Physiol (Oxf)*. 2013;208(3):224-33.
  12. LaMarca B. The role of immune activation in contributing to vascular dysfunction and the pathophysiology of hypertension during preeclampsia. *Minerva Ginecol*. 2010;62(2):105-20.
  13. Weissgerber TL and Mudd LM. Preeclampsia and diabetes. *Curr Diab Rep*. 2015;15(3):579.
  14. Ahlawat SK, Jain S, Kumari S, et al. Pheochromocytoma associated with pregnancy: case report and review of the literature. *Obstet Gynecol Surv*. 1999;54(11):728-37.
  15. Mohamed Ismail NA, Abd Rahman R, Abd Wahab N, et al. Pheochromocytoma and pregnancy: a difficult and dangerous ordeal. *Malays J Med Sci*. 2012;19(1):65-8.

# Thyroid Storm-induced Takotsubo Cardiomyopathy Presenting as Acute Chest Pain: A Case Report

Brayden Ashdown, MD, MSc\*

Emilie Calvello Hynes, MD, MPH†

\* Denver Health, Department of Emergency Medicine, Denver, Colorado

† University of Colorado School of Medicine, UC Health, Department of Emergency Medicine, Aurora, Colorado

Section Editor: Austin Smith, MD

Submission history: Submitted February 1, 2021; Revision received May 3, 2021; Accepted April 30, 2021

Electronically published October 5, 2021

Full text available through open access at [http://escholarship.org/uc/uciem\\_cpem](http://escholarship.org/uc/uciem_cpem)

DOI: 10.5811/cpcem.2021.4.52005

**Introduction:** Stress-induced cardiomyopathy is a rare but serious cause of chest pain, which in recent studies has been shown to carry a similar in-hospital mortality to acute ST-elevation myocardial infarction. The pathophysiology of the disease is thought to be secondary to dysregulated catecholamine effects on myocardium.

**Case Report:** We present a case of a previously healthy female without known thyroid disease who presented to the emergency department for acute chest pain and was found to have thyroid storm-induced cardiomyopathy in a typical stress-induced cardiomyopathy pattern without evidence of coronary disease on catheterization.

**Conclusion:** Thyrotoxicosis can cause dysregulation of catecholamines and is a rare cause of stress-induced cardiomyopathy. It requires distinct therapies and should be considered by emergency physicians in the workup of acute chest pain with concern for stress-induced cardiomyopathy. [Clin Pract Cases Emerg Med. 2021;5(4):399-402.]

**Keywords:** *Thyroid storm; Takotsubo; cardiomyopathy; chest pain; case report.*

## INTRODUCTION

Stress-induced cardiomyopathy (also known as Takotsubo cardiomyopathy) is an acute onset cardiomyopathy of unclear etiology.<sup>1-4</sup> There are many proposed mechanisms; however, despite significant research the underlying pathophysiology has not yet been clearly established. The diagnosis is made largely based on clinical history and imaging studies.<sup>2,5</sup> This disease is most commonly seen in post-menopausal women after an acute psychosocial stressor, but case reports exist for a variety of preceding medical conditions, including anaphylaxis, pancreatitis, pheochromocytoma, tricyclic overdose, and even lightning strike.<sup>4</sup> Although the condition is rarely seen, the pathophysiologic basis for hyperthyroid-induced stress cardiomyopathy aligns with current understanding of the disease process.<sup>1,2</sup>

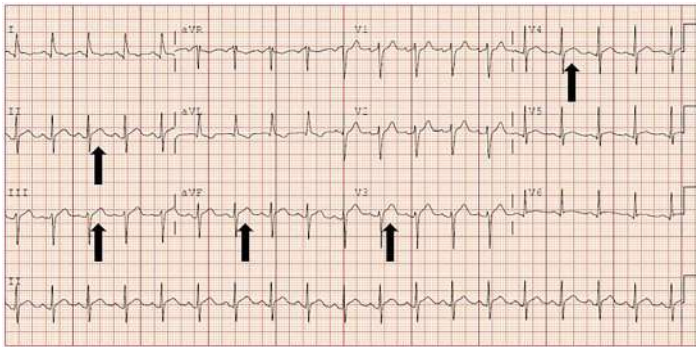
The etiology of heart failure in this case is fundamentally different from high output failure more commonly seen in thyrotoxic states, which is driven primarily by decreased

systemic vascular resistance.<sup>4</sup> Thyrotoxicosis as an etiology of stress-induced cardiomyopathy is important to recognize because it is easily treated; however, the therapies are distinct from what are typically used in stress-induced cardiomyopathy. Lack of prompt treatment may portend a worse prognosis.<sup>6</sup>

## CASE REPORT

A 61-year-old female with history of pulmonary embolism (PE), not on anti-coagulation, presented to the emergency department (ED) with pressure-like chest pain and associated dyspnea starting approximately eight hours prior to presentation. Her electrocardiogram on arrival had one-millimeter ST elevations in anterior and inferior leads, and the triage physician activated the cardiac alert system (Image 1).

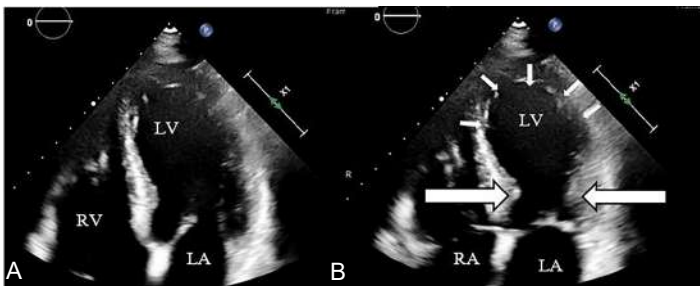
On arrival to the resuscitation room in the ED, she was afebrile, had a normal oxygen saturation on room air, a blood pressure of 151/85 millimeters of mercury and a heart rate of



**Image 1.** Presenting electrocardiogram, read by physician as 1 millimeter of ST elevation, most prominent in inferior and anterior leads (arrows).

142 beats per minute. The patient reported ongoing chest pain. She was given 325 milligrams of aspirin, and the interventional cardiologist was consulted. The patient was awake and alert and was answering questions appropriately. She reported that her prior PE had been provoked in the setting of childbirth over 20 years earlier but remained anticoagulated until four years prior to her current presentation when she discontinued, after a discussion of risks and benefits with her primary care physician. She had no other significant medical history and was not taking any medications regularly. Review of systems was notable only for a recent diagnosis of shingles, currently on antiviral medications.

Point-of-care ultrasound was performed, which demonstrated markedly reduced ejection fraction with apical hypokinesis, no pericardial effusion, no evidence of right ventricular strain, no aortic flap or dilation, and no evidence of deep vein thrombosis in bilateral lower extremities (Video). Due to the apical predominant dysfunction, the patient was asked about recent psychosocial life-stressors, which she denied (Image 2). She had a single view chest radiograph which showed no mediastinal widening, evidence of pulmonary edema, or pneumonia. Initial laboratory data were



**Image 2.** Point-of-care ultrasound images in the apical four-chamber view: A) diastole and B) systole demonstrating normal to hypercontraction of the base of the left ventricle (large arrows) and a hypodynamic apex (small arrows). LV, left ventricle; RV, right ventricle; LA, left atrium; RA, right atrium.

### CPC-EM Capsule

What do we already know about this clinical entity?

*Stress-induced cardiomyopathy is an uncommon cause of chest pain that can present with ST-segment elevation mimicking myocardial infarction.*

What makes this presentation of disease reportable?

*This patient had thyroid storm, a rare cause of stress-induced cardiomyopathy, requiring distinct therapies for management of hyperthyroidism and heart failure.*

What is the major learning point?

*Severe hyperthyroidism is a rare cause of stress-induced cardiomyopathy.*

How might this improve emergency medicine practice?

*In evaluation of stress-induced cardiomyopathy, consider hyperthyroidism as a possible etiology. Ultrasound is a rapid means to narrow the differential in chest pain.*

unremarkable with the exception of a potassium of 3.4 millimoles (mmol) per liter (L) (reference range: 3.5-5.1 mmol/L), a brain natriuretic peptide level of 227 picograms per milliliter (pg/mL) (0-100 pg/mL), and a troponin of 6.0 nanograms (ng/mL) ( $\leq 0.04$  ng/mL). Given ongoing chest pain and electrocardiographic findings, the decision was then made in conjunction with the interventional cardiology team to take the patient to the cardiac catheterization lab to rule out an ischemic etiology, although stress-induced cardiomyopathy was a leading diagnosis on the differential.

Coronary angiography showed no evidence of coronary artery disease. The patient was subsequently transferred to the cardiac intensive care unit (CICU) for ongoing management of acute cardiomyopathy. At time of admission to the CICU, the patient's dyspnea had worsened, and she had a three to four liter oxygen requirement. While in the catheterization lab, thyroid studies resulted with an undetectable thyroid stimulating hormone and a free thyroxine (T4) level of 5.75 ng/dL (0.89 - 1.76 ng/dL). Endocrinology was consulted to assist in management of a presumed thyroid storm. Further history revealed no prior history of known thyroid disease, but mild symptoms of thyrotoxicosis including weight loss (22



pounds in the prior month) and new intermittent tremor over the preceding several months.

Due to concerns that thyroid storm was contributing to heart failure symptoms, the inpatient team started propylthiouracil at 400 milligrams (mg) every six hours, potassium iodide oral solution (SSKI) five drops every six hours, hydrocortisone 100 mg intravenously every eight hours, and an esmolol infusion (to allow careful titration given reduced ejection fraction). Heart rate, palpitations, and dyspnea improved with treatment of thyroid storm. During hospitalization, thyroid stimulating hormone receptor antibody, thyroglobulin antibody, and thyroid peroxidase antibody levels were found to be elevated, consistent with Graves' disease.<sup>6</sup>

## DISCUSSION

Stress-induced cardiomyopathy was traditionally thought to be a relatively benign condition in which appropriately treated patients rarely die and typically completely recover cardiac function in 6-8 weeks. Unfortunately, more recent studies have demonstrated an early in-hospital mortality of around 4-5%, a figure "comparable to that of ST-segment elevation myocardial infarction [STEMI] in the era of primary percutaneous coronary interventions."<sup>2</sup> These findings highlight the importance of early recognition and treatment, as well as a more complete understanding of the underlying pathophysiology. Although many mechanisms have been proposed, the leading theories surround the dysfunctional effects of catecholamines on cardiac myocytes.<sup>1-2,5</sup> There is evidence of not only pathologic upregulation of catecholamine and neuropeptide levels in patients with stress-induced cardiomyopathy when compared to patients with STEMI but also abnormal, apex-predominate, sympathetic innervation. The proposed mechanisms include direct toxic effects on cardiac myocytes, cyclic adenosine monophosphate mediated calcium toxicity, and cytokine mediated inflammation.<sup>1,2</sup> These mechanisms underpin the rationale for beta-blocker therapy, which has been shown to be very effective in recovery of function in stress-induced cardiomyopathy.

By similar mechanistic pathways, hyperthyroidism can affect a similar physiologic state to catecholamine excess and, therefore, lead to stress-induced cardiomyopathy. Thyroid hormone can both directly upregulate beta-adrenergic receptors on myocardial tissue and sensitize those receptors to an exaggerated response to endogenous catecholamines.<sup>1,7</sup> Thyroid hormones likely also have a direct effect on myocytes based on animal data showing cardiovascular response to hyperthyroid states in knockout mice lacking all beta receptors.<sup>1,8</sup> Although the condition is rare, a review in *Thyroid* found 14 case reports of hyperthyroid-induced stress cardiomyopathy. Prompt treatment of hyperthyroid states led to complete recovery in the cases that those authors were able to follow.<sup>1</sup>

A second, more generally applicable learning point from this case is the utility of point-of-care echocardiography in

undifferentiated patients with chest pain. Chest pain is the second most common chief complaint among patients presenting to EDs in the United States.<sup>5</sup> While most patients who present with chest pain are ultimately diagnosed with benign etiologies of their pain,<sup>4,5</sup> there are several life-threatening causes, which require time-consuming, expensive, and potentially harmful diagnostic tests. Narrowing the differential diagnosis, which includes aortic dissection, acute coronary syndrome, pericardial effusion and tamponade, massive PE and acute decompensated heart failure, can pose a diagnostic challenge where time to therapy can make a difference in morbidity and mortality. This case demonstrates the utility of point-of-care ultrasound in quickly and efficiently narrowing that differential.

In this case, PE was a significant concern given the patient's tachycardia, dyspnea and history of prior PE, not currently on anticoagulation. Point-of-care echocardiogram and deep vein thrombosis ultrasound not only indicated PE was less likely but also showed reduced likelihood of dissection (normal appearing aortic root), pericardial effusion/tamponade (no effusion), and acute decompensated heart failure (no B-lines).<sup>9</sup> Although cardiac catheterization is still standard of care for patients presenting with more clear cases of stress-induced cardiomyopathy to rule out ischemic disease, characteristic point-of-care echocardiography can also impact the timing and subsequent resource utilization as well as urgency of transfer to a cardiac catheterization center. In this case the interventional team was already on site; so the patient was taken directly to the catheterization suite for what was already determined to be a non-emergent evaluation of her coronary arteries.

## CONCLUSION

Stress-induced cardiomyopathy is an uncommon cause of acute chest pain presenting to the ED, but a cause that carries an in-hospital mortality similar to acute ST-elevation myocardial infarction. The dysfunctional catecholamine regulation seen in thyroid storm can lead to a similar physiologic state as acute stress from medical illness or psychosocial stressors and lead to stress-induced cardiomyopathy. The prompt identification and treatment of this unique cause of chest pain allows for interventions that may prevent ongoing damage to the myocardium and provide the best chance at recovery for patients. Point-of-care ultrasound can assist in early identification due to the characteristic findings seen in stress-induced cardiomyopathy and the absence of findings consistent with alternative etiologies of chest pain.

**Video.** Point-of-care ultrasound video throughout the cardiac cycle in the apical four chamber view, demonstrating normal to hypercontraction of the base of the left ventricle and a hypo dynamic apex.



The authors attest that their institution requires neither Institutional Review Board approval, nor patient consent for publication of this case report. Documentation on file.

*Address for Correspondence:* Brayden Ashdown, MD, MSc  
Denver Health, Department of Emergency Medicine, 777 Bannock St., Denver, CO 80204. Email:brayden.ashdown@denverem.org.

*Conflicts of Interest:* By the CPC-EM article submission agreement, all authors are required to disclose all affiliations, funding sources and financial or management relationships that could be perceived as potential sources of bias. The authors disclosed none.

*Copyright:* © 2021 Ashdown et al. This is an open access article distributed in accordance with the terms of the Creative Commons Attribution (CC BY 4.0) License. See: <http://creativecommons.org/licenses/by/4.0/>

## REFERENCES

1. Eliades M, El-Maouche D, Choudhary C, et al. Takotsubo cardiomyopathy associated with thyrotoxicosis: a case report and review of the literature. *Thyroid*. 2014;24(2):383-9.
2. Khalid N, Ahmad SA, Shlofmitz E, et al. (2021). Pathophysiology of Takotsubo syndrome. [Updated 2021 Mar 3]. In: *StatPearls* [Internet]. Treasure Island (FL): StatPearls Publishing.
3. Lakdawala NK. (2015). Cardiomyopathy and myocarditis. In: Kasper DL, Fauci AS, Hauser SL, eds. *Harrison's Principles of Internal Medicine 19/E (Vol.1 & Vol.2) 19th ed (p. 1565)*. New York, NY: McGraw-Hill Professional.
4. Jouriles NJ. (2013). Pericardial and myocardial disease. In: Marx J, Walls R, Hockberger R, eds. *Rosen's Emergency Medicine - Concepts and Clinical Practice (p.1104)*. Amsterdam, Netherlands: Elsevier Health Sciences.
5. Emergency department visits. CDC.gov. 2021. Available at: <https://www.cdc.gov/nchs/fastats/emergency-department.htm>. Accessed February 2, 2021.
6. Wu WT, Hsu PC, Huang HL, et al. A case of Takotsubo cardiomyopathy precipitated by thyroid storm and diabetic ketoacidosis with poor prognosis. *Acta Cardiol Sin*. 2014;30(6):574-7.
7. Silva JE and Bianco SD. Thyroid-adrenergic interactions: physiological and clinical implications. *Thyroid*. 2008;18(2):157-65.
8. Bachman ES, Hampton TG, Dhillon H, et al. The metabolic and cardiovascular effects of hyperthyroidism are largely independent of beta-adrenergic stimulation. *Endocrinology*. 2004;145(6):2767-74.
9. Pomero F, Dentali F, Borretta V, et al. Accuracy of emergency physician-performed ultrasonography in the diagnosis of deep-vein thrombosis: a systematic review and meta-analysis. *Thromb Haemost*. 2013;109(1):137-45.
10. Pelliccia F, Kaski JC, Crea F, et al. Pathophysiology of Takotsubo syndrome. *Circulation*. 2017;135(24):2426-41.

# Point-of-care Ultrasound Diagnosis of Pulmonary Hydatid Cyst Disease Causing Shock: A Case Report

Alexandra Hill, MD, MDEV\*  
 Marco Guillén, MD†  
 David Martin, MD\*  
 Andrea Dreyfuss, MD, MPH\*

\*Highland Hospital - Alameda Health System, Department of Emergency Medicine, Oakland, California  
 †Hospital Nacional Adolfo Guevara Velasco, Department of Emergency Medicine, Cusco, Peru

Section Editor: Rachel Lindor, MD, JD

Submission history: Submitted February 25, 2021; Revision received May 27, 2021; Accepted May 28, 2021

Electronically published August 27, 2021

Full text available through open access at [http://escholarship.org/uc/uciem\\_cpem](http://escholarship.org/uc/uciem_cpem)

DOI: 10.5811/cpem.2021.5.52264

**Introduction:** Point-of-care ultrasound (POCUS) is accepted as an important tool for evaluating patients presenting to the emergency department (ED) with dyspnea<sup>1</sup> and undifferentiated shock.<sup>2</sup> Identifying the etiology and type of shock is time-critical since treatments vary based on this information. Clinicians typically rely on the history, exam, and diagnostics tests to identify the etiology of shock. In resource-limited settings where there is reduced access to timely laboratory and diagnostic studies. The use of POCUS enables rapid classification and directed treatment of shock. Additionally, POCUS can aid in the diagnosis of rarer tropical diseases that can be important causes of shock in resource-limited settings.

**Case Report:** We discuss a case of a pediatric patient who presented to an ED in Cusco, Peru, with acute dyspnea and shock. Point-of-care ultrasound was used to expedite the diagnosis of a ruptured pulmonary hydatid cyst, guide proper management of septic and anaphylactic shock, and expedite definitive surgical intervention.

**Conclusion:** In resource-limited settings where there is reduced access to timely laboratory and diagnostic studies, the use of POCUS enables rapid classification and directed treatment of shock. [Clin Pract Cases Emerg Med. 2021;5(4):403–406.]

**Keywords:** *Point-of-care ultrasound; POCUS; shock; dyspnea; hydatid cyst; case report.*

## INTRODUCTION

Hydatid cysts caused by infection with *Echinococcus granulosus* are recognized as a neglected tropical disease causing significant morbidity worldwide.<sup>3</sup> Humans and other intermediate hosts such as sheep are infected after ingesting eggs in the feces of the definitive host, dogs.<sup>4</sup> Patients from endemic regions, including South America, the Middle East, China, Australia, and Africa, are at risk for hydatid cysts.<sup>5</sup> There have also been cases of local infection reported in the southwest United States.<sup>4</sup> Adults most commonly develop hydatid cysts in the liver (75%) and the lungs (15%).<sup>4</sup> By contrast, children primarily develop pulmonary hydatid infections possibly because cysts grow best in compressible organs.<sup>5,6</sup>

Pulmonary hydatid cysts may present with symptoms related to mass effect, vascular communication, and rupture.<sup>5,7</sup> Patients with ruptured pulmonary hydatid cysts may develop anaphylaxis, pulmonary embolism, pleural effusions, or superimposed bacterial infection.<sup>5,7-10</sup> Ultrasound is the cornerstone of diagnosis of hydatid cysts in the liver<sup>4,11</sup> and is favored over computed tomography (CT) due to its superior ability to identify “membranes, septae, and hydatid sand” within the abdomen.<sup>6</sup> By contrast, the diagnosis of pulmonary hydatid cysts is more challenging and traditionally relies on a combination of chest radiograph (CXR), CT, serology, percutaneous aspiration, bronchoscopy, and/or surgical pathology.<sup>7,12</sup> Ultrasound has been thought to be of limited utility due acoustic shadowing from the air-filled lungs.<sup>12,13</sup>

Point-of-care ultrasound (POCUS) is known to be useful in evaluating critically ill patients presenting with acute dyspnea<sup>1</sup> and shock<sup>2</sup> in the emergency department (ED). It can aid in the diagnosis and management of multiple etiologies of acute dyspnea, including pneumonia, heart failure, pleural effusion, pulmonary embolism, pericardial effusion, and pneumothorax.<sup>1,14</sup> Similarly, POCUS has been shown to be helpful in differentiating types of shock, especially obstructive, cardiogenic, and hypovolemic, in resource-limited settings.<sup>2</sup> Here, we describe a case of a five-year-old male who presented to an ED in Cusco, Peru, with acute dyspnea and shock. We demonstrate how the use of POCUS led to the unusual diagnosis of a ruptured hydatid cyst and helped to guide proper management of the patient's respiratory failure and shock.

### CASE REPORT

A five-year-old previously healthy male was brought to the ED in Cusco, Peru, by his parents, who reported two days of fever, cough, rhinorrhea, pruritus, and decreased appetite. His temperature was 38.3° Celsius, heart rate was 150 beats per minute, respiratory rate was 52 breaths per minute, oxygen saturation was 77% on room air, and blood pressure was 100/60 millimeters of mercury (mm Hg). He appeared lethargic, and his capillary refill was less than two seconds. He was using accessory respiratory muscles and had wheezing and diminished vesicular breath sounds in the left hemithorax.

His labs were notable for white blood cell count of  $4.35 \times 10^3$  per cubic millimeter ( $\text{mm}^3$ ) (reference range:  $5 \times 10^3 - 10 \times 10^3 / \text{mm}^3$ ) with 84.8% polymorphonuclear leukocytes, hemoglobin of 9.5 grams per deciliter (g/dL) (reference range: 14-17 g/dL), platelets of 474,000 per microliter ( $\mu\text{L}$ ) (reference range: 140,000-500,000/ $\mu\text{L}$ ), and a creatinine of 0.24 milligrams (mg)/dL (reference range: 0-0.5 mg/dL). His arterial blood gas demonstrated metabolic acidosis with hypoxemia. The CXR showed radiopacity of the entire left hemithorax consistent with a massive pleural effusion (Image 1).

Based on the patient's overall presentation and CXR findings, the pediatrician suspected the patient was presenting with acute hypoxemic respiratory failure and septic shock from pneumonia complicated by a large parapneumonic effusion. Given the patient's tachypnea, hypoxia, flash capillary refill, and severe tachycardia, there was concern for impending respiratory failure and warm shock. The pediatrician consulted the emergency physician to perform an ultrasound-guided diagnostic and therapeutic thoracentesis.

The emergency physician began his POCUS examination by performing a "triple scan," which includes cardiac, inferior vena cava, and pulmonary ultrasound windows to evaluate for potential causes of the patient's acute dyspnea and shock.<sup>1</sup> The POCUS revealed a preserved ejection fraction on the parasternal long view and a collapsing inferior vena cava on the subxiphoid view consistent with the pediatrician's concern for septic shock. Point-of-care ultrasound of the right hemithorax

### CPC-EM Capsule

What do we already know about this clinical entity?

*Hydatid cyst disease can lead to complications including sepsis and anaphylaxis. Diagnosis of pulmonary involvement often requires a multimodal approach.*

What makes this presentation of disease reportable?

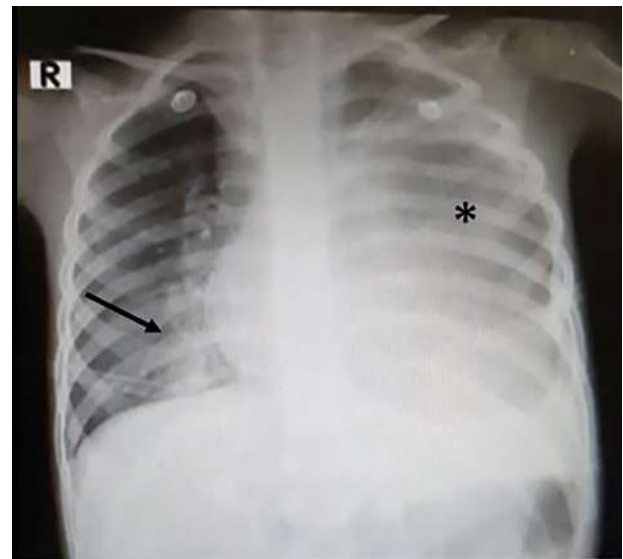
*Emergency providers used point-of-care ultrasound (POCUS) to diagnose and guide management of a pediatric patient with shock due to a ruptured pulmonary hydatid cyst.*

What is the major learning point?

*Point-of-care ultrasound can identify ruptured or multivesicular pulmonary hydatid cysts due to their unique ultrasonographic appearance.*

How might this improve emergency medicine practice?

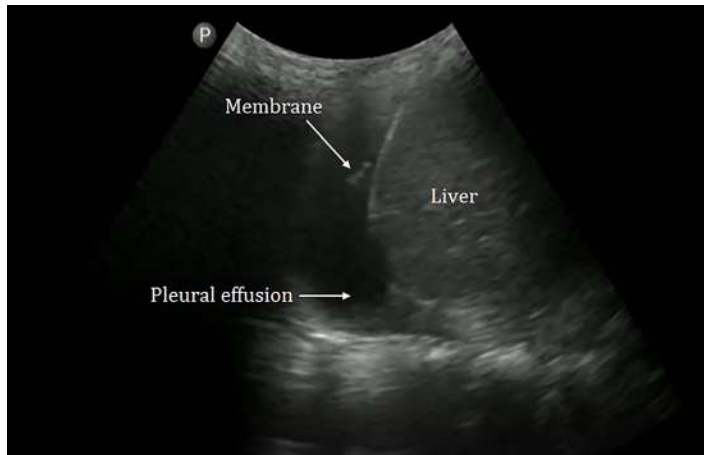*In undifferentiated shock, POCUS is an excellent tool for evaluating critically ill patients, including those who may be suffering from rare tropical diseases.*



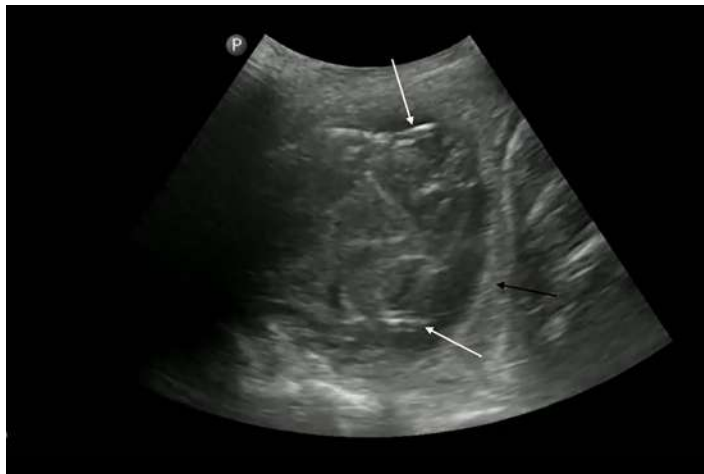
**Image 1.** Chest radiograph of five-year-old patient obtained in the emergency department. The left hemithorax is radiopaque, concerning for a possible large pleural effusion (asterisk). There is a normal cardiac silhouette and hazy interstitial opacities concerning for an infectious process present in the right hemithorax (arrow).

revealed a pleural effusion, a hyperechoic structure suggestive of a membrane in the pleural cavity, multiple B-lines, and a subpleural consolidation (Image 2, Video 1).

In the left hemithorax, a complex, double-layered structure was noted on POCUS (Image 3, Video 2). This was consistent with a “wall sign” and was thought to represent a cyst occupying the entire pleural cavity. This structure contained hypo- and hyperechoic regions (suggestive of multiple membranes), floating in heterogeneous fluid, which



**Image 2.** Point-of-care ultrasound of the right hemithorax showing a hyperechoic linear structure (suggestive of a membrane) floating in anechoic fluid (a pleural effusion).



**Image 3.** Point-of-care ultrasound of the left hemithorax showing the “honeycomb” appearance of a multivesicular cyst with double echogenic lines<sup>6</sup> (white arrows) known as the “wall sign”<sup>5</sup> and internal “serpentine” linear structures delineating the daughter cysts.<sup>6</sup> This cyst occupies nearly the entire volume of the left hemithorax (black arrow indicates the diaphragm).

appeared to be pus.

Based on these ultrasound images and the endemic nature

of *E. granulosus* in Cusco, a ruptured hydatid cyst was suspected to be the culprit. Due to these unexpected findings, the emergency physician aborted the planned thoracentesis since disrupting the cysts further could prove fatal to the patient by releasing “highly antigenic fluid” into the pleural space.<sup>10</sup> A chest CT corroborated the diagnosis of a ruptured hydatid cyst in the left lung. No abnormal CT findings were noted in the radiologist’s read of the right hemithorax, despite the abnormal findings seen on POCUS.

The patient was subsequently intubated for respiratory failure. He became hypotensive to 80/50 mm Hg and was started on an epinephrine infusion for treatment of septic and anaphylactic shock. Both were a concern since the patient had fever, cough, and evidence of purulent pleural fluid on POCUS, which suggested infection, in addition to wheezing, pruritus, and hypotension, which was concerning for anaphylaxis. The patient was also given hydrocortisone, vancomycin, ceftriaxone, meropenem and albendazole. Cardiothoracic surgery took him to the operating room for a thoracotomy where they removed a giant, multivesicular hydatid cyst containing purulent material that comprised the entire lower lobe and part of the upper lobe of the left bronchus. Their findings were consistent with superinfection of the hydatid cyst as well as rupture. Surgical pathology later confirmed the diagnosis: anhistic membranes of a hydatid cyst with active microorganisms.

Post-operatively, the patient improved gradually. On hospital day 12, he was transferred out of the intensive care unit, and on hospital day 25 he was discharged home with albendazole.

## DISCUSSION

This case highlights why POCUS is such a powerful diagnostic tool for the emergency physician, especially in resource-limited settings. Not only is POCUS a highly versatile and relatively low-cost technology, but it is also portable and readily available at the bedside of a critically ill ED patient, which can expedite care when there is lack of access to rapid CT in overburdened EDs or when the patient is too unstable for transportation. Our case also demonstrates how POCUS averted a potentially harmful procedure (thoracentesis) and guided fluid management, antibiotic and steroid initiation, vasopressor selection, and consultation.

Point-of-care ultrasound has been shown to be effective in helping emergency physicians differentiate between many etiologies of shock<sup>2</sup> and dyspnea,<sup>1</sup> and our case shows that it can even identify etiologies as unusual as a ruptured pulmonary hydatid cyst. As mentioned previously, the diagnosis of pulmonary hydatid cysts typically relies on a multimodal approach because the appearance of pulmonary hydatid cysts on CXR and CT is nonspecific with a few exceptions.<sup>4,6,12,13</sup> Ultrasound has a limited ability to evaluate structures that are deep to air-filled structures, thereby limiting its use in evaluating univesicular and centrally located pulmonary hydatid cysts.<sup>12,13</sup> However,



for multivesicular cysts and cysts surrounded by a pleural effusion, such as in ruptured hydatid cysts, ultrasound can have a higher specificity than other imaging modalities due to the acoustic window provided by the fluid-filled daughter cysts or effusion, respectively, which makes it easier to see cystic walls.<sup>13</sup> One study of nine cases of pulmonary hydatid cysts inside of large pleural effusions showed that the cysts were very well visualized on ultrasound but could not be seen on CT.<sup>13</sup>

Various sonographic findings should lead physicians to consider pulmonary hydatid cyst disease. Sometimes it is possible to see a “wall sign,” which is created by the cyst and the surrounding pericyst in univesicular cysts or by neighboring walls of the daughter cysts in multivesicular cysts.<sup>5,13</sup> Multivesicular cysts have a characteristic “honeycomb” appearance due to the presence of daughter cysts.<sup>6</sup> Broken daughter cysts may appear as “serpentine” linear structures.<sup>6</sup> When a membrane detaches within a cyst, it can create a “water lily sign.”<sup>4,6</sup> Additionally, hydatid sand falling to the most dependent part of the cyst appears as the “snowstorm sign.”<sup>4,6</sup> Emergency physicians should familiarize themselves with these unique sonographic findings when caring for patients living in or traveling from regions with endemic *E granulosus* infection.

## CONCLUSION

Point-of-care ultrasound should be considered an essential instrument for the evaluation and management of critically ill patients presenting to the ED, particularly in resource-limited settings, as it can change management and expedite definitive care. Furthermore, POCUS can be an important tool for diagnosing less common etiologies of shock and dyspnea, such as pulmonary hydatid cysts that may be endemic in resource-limited settings. Larger studies should be performed to evaluate the sensitivity and specificity of sonographic signs mentioned above for the diagnosis of pulmonary hydatid cysts as the studies cited were small, a common weakness of studies on neglected tropical diseases.

**Video 1.** Point-of-care ultrasound of the right hemithorax showing B-lines and a membrane suspended in a pleural effusion coming in and out of view with the patient’s respiratory cycle.

**Video 2.** Point-of-care ultrasound of the left hemithorax demonstrating a large multivesicular cyst and two areas where the “wall sign”<sup>5</sup> is apparent, demarcating the daughter cysts. As the ultrasound probe is fanned, it is possible to see the spine sign above the diaphragm due to the presence of a pleural effusion surrounding the cyst.

Patient consent has been obtained and filed for the publication of this case report.

*Address for Correspondence:* Alexandra Hill, MD, MDEV, Highland Hospital - Alameda Health System, Department of Emergency Medicine, 1411 East 31st Street, Oakland, California 94602. Email: alexhillmd@gmail.com

*Conflicts of Interest:* By the CPC-EM article submission agreement, all authors are required to disclose all affiliations, funding sources and financial or management relationships that could be perceived as potential sources of bias. The authors disclosed none.

*Copyright:* © 2021 Hill et al. This is an open access article distributed in accordance with the terms of the Creative Commons Attribution (CC BY 4.0) License. See: <http://creativecommons.org/licenses/by/4.0/>

## REFERENCES

- Mantuani D, Frazee BW, Fahimi J et al. Point-of-care multi-organ ultrasound improves diagnostic accuracy in adults presenting to the emergency department with acute dyspnea. *West J Emerg Med.* 2016;17(1):46-53.
- Keikha M, Salehi-Marzijarani M, Soldoozi Nejat R et al. Diagnostic accuracy of rapid ultrasound in shock (RUSH) exam: a systematic review and meta-analysis. *Bull Emerg Trauma.* 2018;6(4):271-8.
- Brunetti E, Kern P, Vuitton DA et al. Expert consensus for the diagnosis and treatment of cystic and alveolar echinococcosis in humans. *Acta Trop.* 2010;114:1-16.
- Moro P and Schantz PM. Echinococcosis: a review. *Int J Infect Dis.* 2009;13:125-33.
- Garg MK, Sharma M, Gulati A et al. Imaging in pulmonary hydatid cysts. *World J Radiol.* 2016;8(6):581-7.
- Pedrosa I, Saiz A, Arrazola J et al. Hydatid disease: radiologic and pathologic features and complications. *Radiographics.* 2000;20:795-817.
- Sarkar M, Pathania R, Jhobta A et al. Cystic pulmonary hydatidosis. *Lung India.* 2016;33(2):179-91.
- Beggs, I. The radiology of hydatid disease. *AJR Am J Roentgenol.* 1985;145:639-48.
- Constantin V, Popa F, Socea B et al. Spontaneous rupture of a splenic hydatid cyst with anaphylaxis in a patient with multi-organ hydatid disease. *Chirurgia (Bucur).* 2014;3(109):393-5.
- Shameen M, Akhtar J, Bhargava R et al. Ruptured pulmonary hydatid cyst with anaphylactic shock and pneumothorax. *Respir Care.* 2011;56(6):863-5.
- Richter J, Hatz C, Häussinger D. Ultrasound in tropical and parasitic diseases. *Lancet.* 2003;362:900-2.
- Morar R and Feldman C. Pulmonary echinococcosis. *Eur Respir J.* 2003;21:1069-77.
- El Fortia M, El Gatit A, Bendaoud M. Ultrasound wall-sign in pulmonary echinococcosis (new application). *Ultraschall Med.* 2006;27(6):553-7.
- Cleveland Manchanda EC, Kharasch SJ, Liteplo AS. Dyspnea in an otherwise healthy 18-year-old: the importance of point-of-care ultrasonography. *Clin Pract Cases Emerg Med.* 2019;3(3):271-4.



# Rat-bite Fever: A Rare Diagnosis for a Common Pediatric Presentation: Case Report

Anthony Edholm, MD\*  
Marissa Heyer, BA†  
Sondra M. Nemetski, MD, PhD‡§

\*Hackensack University Medical Center, Department of Emergency Medicine, Hackensack, New Jersey

†Hackensack Meridian School of Medicine, Nutley, New Jersey

‡Joseph M. Sanzari Children's Hospital, Hackensack Meridian Health, Division of Pediatric Emergency Medicine, Department of Emergency Medicine, Hackensack, New Jersey

§Hackensack Meridian School of Medicine, Department of Pediatrics, Nutley, New Jersey

Section Editor: Melanie Heniff, MD, JD

Submission history: Submitted January 10, 2021; Revision received May 25, 2021; Accepted May 24, 2021

Electronically published October 5, 2021

Full text available through open access at [http://escholarship.org/uc/uciem\\_cpem](http://escholarship.org/uc/uciem_cpem)

DOI: 10.5811/cpcem.2021.5.51412

**Introduction:** Fever and rash is a common pediatric presentation to the emergency department but can present a diagnostic challenge to the clinician. Here we report the successful identification and treatment of a rare zoonotic exanthem that was facilitated by a thorough history and physical exam.

**Case Report:** Rat-bite fever is a potentially fatal systemic illness characterized by relapsing fever, rash, and migratory polyarthralgias. Treatment includes antibiotics for *Streptobacillus moniliformis*, the most common pathogen, as well as appropriate hygiene education and prevention strategies. We report a case of *S. moniliformis* in the absence of an actual rodent bite.

**Conclusion:** Due to the generally non-specific presentation of the illness, as well as the growing trend of caring for domestic rodents, it is crucial that clinicians ask details related to zoonotic and other exposures while obtaining medical histories. [Clin Pract Cases Emerg Med. 2021;5(4):407–411.]

**Keywords:** rat bite fever; rash; pediatric; zoonotic.

## INTRODUCTION

Fever and rash are common reasons for children to seek medical care. While most pediatric exanthems are benign and self-limiting, there are several that represent true medical emergencies or demonstrate serious underlying causes. Identifying those cases can present a diagnostic challenge to the emergency clinician. We present a case of a young woman who experienced relapsing fever, petechial rash, and generalized arthralgias and myalgias, for whom a rare diagnosis was facilitated by a detailed history and physical exam.

## CASE REPORT

In May 2020 a well-appearing, immunized 11-year-old female, with a past medical history of depression, currently being treated with sertraline, arrived to the emergency department (ED) of a children's hospital in the Northeastern

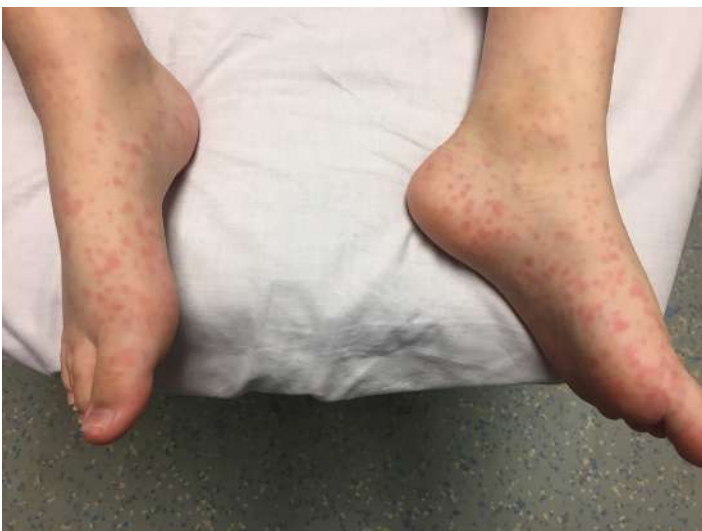United States with her mother for evaluation of a fever of 103.5°F (39.7°C), throbbing frontal headache, generalized muscle aches, and mild photophobia, all of which began three days prior to presentation. The patient also noticed that two days after these symptoms emerged, she developed a rash that started on her palms, distal wrists, and soles of her feet, and then spread proximally. Additionally, she had one episode of non-bloody, non-bilious vomiting after taking acetaminophen; however, she had since been able to tolerate food and fluids by mouth. The patient also endorsed phonophobia, mild sore throat, and neck pain with stiffness.

According to her mother, the patient was hospitalized for an episode of severe depression two months prior to this illness. After that episode, both the mother and patient thought that having a pet would improve the patient's mental health. The patient reported acquiring four pet rats, which frequently

crawled around her and occasionally nibbled on her skin; however, she denied ever having skin punctured. The patient's mother reported that one of the rats was not vaccinated and had been sick; the animal was evaluated by a veterinarian and placed on antibiotics for an upper respiratory infection. The patient and her mother denied any contacts with ill humans; in fact, their social interactions in general had been limited, and the patient was attending school remotely, due to social distancing restrictions put into place during the coronavirus disease 2019 (COVID-19) pandemic.

On physical exam, the patient was alert and oriented with no signs of altered mental status or distress. Vital signs on presentation were significant for a blood pressure of 105 per 52 millimeters mercury, pulse rate of 111 beats/minute, and temperature of 99.9°F (37.7°C). Examination revealed full range of motion of the neck, and both Kernig and Brudzinski signs were negative. The patient had minimal tenderness to palpation of the suprapubic abdominal region and reported myalgias with pain upon palpation of the skin, legs, knees, and elbows. A diffuse, blanching, erythematous, macular rash was observed on bilateral palms and soles (Images 1 and 2), extremities, trunk, and face. Pulmonary and cardiac exams were normal.

Given the patient's history and physical exam findings, the infectious disease team was consulted for a suspected diagnosis of rat-bite fever (RBF). Differential diagnoses also included strep pharyngitis and viral exanthem. Meningitis, Rocky Mountain spotted fever, ehrlichiosis, and severe acute respiratory syndrome coronavirus 2 (SARS-CoV-2) were less likely due to the patient's clinical presentation and no known exposures. Labs, urinalysis, and blood cultures were ordered. A lumbar puncture was considered pending results; however, the patient remained hemodynamically stable and non-toxic appearing, so the procedure was ultimately deferred. Group A streptococcus titer results were negative. Urinalysis was



**Image 1.** Erythematous maculopapular rash observed diffusely throughout the body and extremities with inclusion of soles.

### *CPC-EM Capsule*

What do we already know about this clinical entity?

*Rat-bite fever is a rare systemic illness characterized by relapsing fever, rash, and migratory polyarthralgias, with a high mortality rate if not treated promptly.*

What makes this presentation of disease reportable?

*Despite the lack of a rodent bite, the case was successfully identified and treated based on a thorough history and physical exam.*

What is the major learning point?

*Due to the wide range of differential diagnoses, it is critical to rely on a systematic approach toward analyzing patients presenting with fever and rash.*

How might this improve emergency medicine practice?

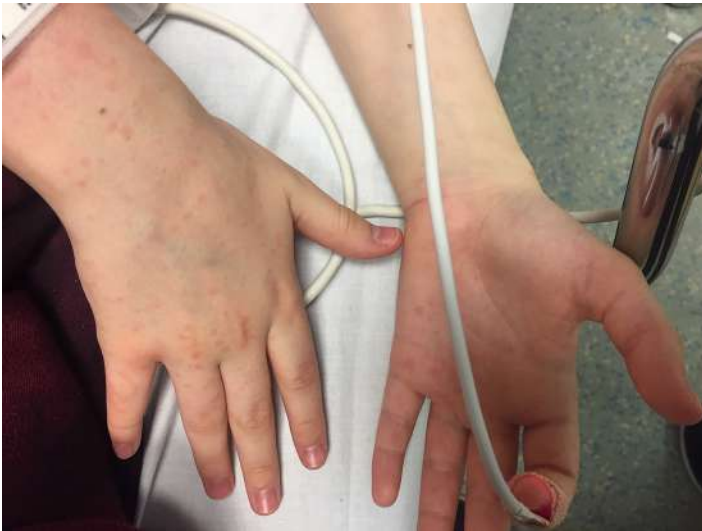*The approach presented here will aid in distinguishing between benign and emergent causes of pediatric rashes.*

positive for moderate bacteria and white blood cells, but suspicion for urinary tract infection was low since the patient did not have any urinary complaints. The patient was monitored and started on intravenous (IV) fluids and broad-spectrum antibiotics.

Since the case occurred during the height of our hospital system's COVID-19 surge, and available beds were limited, the patient's mother was reluctant to agree to admission for IV penicillin and close monitoring. After discussing the case with the on-call pediatric infectious disease physician and shared decision-making with the patient and her mother, the patient was given a dose of ceftriaxone in the ED and discharged on amoxicillin 500 milligrams three times daily. The patient's mother assured close follow-up with the patient's pediatrician within 48 hours of discharge and was advised to return to the ED for any worsening of symptoms. Upon follow-up, the patient's mother reported resolution of fever within two days and rash within three days of the ED visit.

### **DISCUSSION**

Rat-bite fever is considered a rare disease but is not nationally reportable, and many cases may go unreported as a result of failure to properly diagnose.<sup>1</sup> In the Western hemisphere, RBF is typically caused by *Streptobacillus moniliformis*, a pleomorphic, Gram-negative, facultative



**Image 2.** Erythematous maculopapular rash observed over palmar and dorsal surface of hands bilaterally.

anaerobe that inhabits the oropharynx of primarily rats and other domestic rodents.<sup>2</sup> *S. moniliformis* requires microaerophilic conditions to grow; as a result, detection by conventional microbiological techniques is quite difficult and may delay correct and prompt diagnosis and treatment.<sup>3,4</sup>

The natural reservoir responsible for transmitting *S. moniliformis* is rats. The bacterium classically colonizes the upper respiratory tract of the rodent,<sup>5</sup> and while most rats are asymptomatic, some may occasionally show signs and symptoms of an upper respiratory tract infection. Historically, individuals at high-risk for developing RBF are those in occupations that involve direct handling of rats, including laboratory workers, pet store employees, and veterinary staff. However, the incidence of RBF is believed to have increased in recent years, particularly in young children – who represent over 50% of cases – as a result of greater pet rat exposure.<sup>2,6</sup> While the precise rate of rat and other rodent ownership is unknown, the 2019-2020 American Pet Products Association's National Pet Owners Survey found that an estimated 5.4 million American households own a “small animal” as a pet.<sup>7</sup> Additionally, the American Veterinary Medical Association reported that in 2016 2.6% of United States households owned ferrets or “other mammals,” exclusive of dogs, cats, or rabbits.<sup>8</sup> Therefore, obtaining a thorough history of animal exposure, as well as animal milk sources, is crucial when suspicion of a zoonotic illness is high.<sup>5</sup>

As its name suggests, RBF can be transmitted directly via a bite or scratch from rodents, including rats, mice, and possibly gerbils, guinea pigs, and ferrets, infected with the bacteria by entry through a wound, open skin, or mucous membranes.<sup>1</sup> Additionally, the zoonotic bacteria can be transmitted through contact with the urine, saliva, or droppings of infected rats, through contaminated surfaces, or via consumption of food or drinks contaminated with urine or

droppings of an infected rodent.<sup>9</sup> However, up to a third of patients do not report a known bite or rodent exposure.<sup>1,10</sup>

On average, clinical symptoms develop 3-10 days after initial exposure, but may be delayed up to three weeks later.<sup>3</sup> When illness occurs, patients commonly present with abrupt onset of fever and rigors; the fever may resolve within a few days but ultimately relapses.<sup>3</sup> Additional frequently reported symptoms include headache, vomiting, migratory polyarthralgias of large and small joints, and rash.<sup>11</sup> The rash may appear as maculopapular, petechial, or purpuric, and involve the extremities, particularly the hands and feet.<sup>12</sup> In some cases, exquisitely tender hemorrhagic vesicles may develop which, in the setting of an otherwise nonspecific febrile illness, are strongly suggestive of infection with *S. moniliformis*.<sup>3,11</sup> Although rare, complications of untreated RBF include abscess formation, hepatitis, nephritis, polyarteritis nodosa, meningitis, pneumonia, pericarditis, myocarditis, and endocarditis.<sup>13</sup> While RBF usually responds quickly to penicillin, the mortality rate of untreated RBF is approximately 10%.<sup>3</sup>

Penicillin is still regarded as the first-line treatment for proven or highly suspected cases of RBF. Treatment is generally given intravenously for the first 5-7 days, and then orally for an additional seven days.<sup>1,6</sup> Streptomycin, tetracycline, and cephalosporins are recommended for penicillin-allergic patients.<sup>1</sup> However, because tetracycline is known to cause dental abnormalities in children, it should not be used as a first-line agent in pediatric patients.

Proper hygiene education and strategies for prevention of future infections is very important, especially in children and adolescents with pet rats. Emphasis should be placed on safe play to reduce the transmission of germs and reduce the risk of bites from the rodent, as well as proper cleansing and disinfection of hands, surfaces, and rodent habitats and supplies.<sup>11</sup>

Pediatric presentation of fever, migratory polyarthritides, and rash evokes an extensive differential diagnosis. Potential bacterial causes include *Streptococcus pyogenes* (and associated diseases), *Staphylococcus aureus*, disseminated gonorrhea, and meningococemia. Other zoonotic illnesses, such as Lyme disease, ehrlichiosis, brucellosis, and rickettsial infections, particularly Rocky Mountain spotted fever, should be thoroughly explored during history taking.<sup>3</sup> Viral etiologies, such as parvovirus B19, coxsackievirus, and reactive arthritis secondary to viral illness, as well as inflammatory considerations including juvenile idiopathic arthritis, should also be considered.<sup>4</sup>

When evaluating a patient, demographics, season, and geography should be taken into consideration. Our patient was an 11-year-old female being evaluated in an urban region of New Jersey in mid-May. History taking should focus on the onset, progression, associated symptoms, and attempted therapies thus far. In addition, the physician must consider the patient's past medical history, prescribed medications, use of recreational substance or herbal supplements, vaccination



status, and allergies. Social elements are often critical in determining rare diagnoses; therefore, the ED evaluation should include discussions concerning recent activities, occupations, typical diet, living situation, animal exposures, sexual activity, recent travel, and hobbies.

Next, emphasis should be placed on performing a detailed physical exam, which should broadly include features of the rash, such as petechial or purpuric lesions, erythematous appearance, maculopapular appearance, or vesicubullous development. Extra care should be taken to identify potential dermatological emergencies, which can be suggested by associated systemic symptoms as well as specific features of the rash, including lack of blanching; evidence of crepitus; involvement of the palms, soles, genitalia, or mucous membranes; warmth or tenderness to palpation; and presence of Nikolsky's sign.

The patient presented here endorsed specific clues identified on social history and findings on physical exam that helped identify the underlying cause of her symptoms. First, she was found to have prolonged rodent exposure from a pet source. Second, the rash demonstrated unusual features, including involvement of her palms and soles. An accurate travel history, coupled with consideration of the season and geography, also helped exclude alternative diagnoses including Rocky Mountain spotted fever. Knowledge of her complete vaccination status, recent social interactions (ie, minimal exposure to other children due to social distancing measures during the COVID-19 pandemic), and a thorough exam allowed appropriate ranking of other infectious causes within the differential diagnosis. This comprehensive approach to the history and physical exam provided the information needed to make the diagnosis with confidence, even without laboratory confirmation.

Safe discharges from the ED are multifactorial. Clinicians should consider discharge if the interventions initiated in the ED have corrected the course of the patient's pathology, any residual symptoms are tolerable and can be managed with outpatient interventions, the patient does not demonstrate altered mental status, the patient is able to reiterate the shared plan of care back to the provider in their own words, vital signs are within normal limits, and appropriate, reliable follow-up is assured. Patient autonomy and shared decision-making regarding the risks and benefits of admission vs discharge should also weigh upon disposition decisions, especially in borderline or complex cases.

In the case reported here, once the underlying pathology was identified, interventions such as IV antibiotics, analgesia, and antipyretics were initiated to treat the patient's underlying pathology and associated symptoms. While in most cases, RBF is treated with multiple doses of IV antibiotics in the hospital, in this instance the risk of nosocomial infection during the height of the COVID-19 pandemic, as well as the limited availability of inpatient resources at the time, complicated what would usually have been a straightforward disposition. Shared decision-making was then made regarding disposition between the patient, her

mother, the infectious disease physician, and the ED team. The patient appeared alert and oriented to person, place, and time, with no signs of altered mental status. She endorsed significant symptomatic improvement following interventions and was in no distress with stable vital signs. Furthermore, the patient and her mother demonstrated understanding of the pathology of the disease, the antibiotic course required to treat it, and the need for close follow-up and continued monitoring of symptoms, as well as signs or symptoms that would warrant prompt return to medical care. Our team agreed to follow up with the patient's mother over telephone within 24 hours and she would follow up with her primary care provider within three days. Careful considerations of all these factors allowed for a safe discharge and a positive outcome for this patient.

## CONCLUSION

Rat-bite fever is a potentially fatal illness characterized by systemic symptoms, particularly relapsing fever, rash, and migratory polyarthralgias. While considered rare and non-reportable, over 50% of cases have been recorded in children, potentially due to the growing popularity of keeping rats as pets.<sup>1,2</sup> Due to the high risk of mortality if left untreated and the generally non-specific presentation, it is important for physicians to take a thorough medical history, taking particular note of potential exposure to animals, both wild and domesticated, when treating patients with potential zoonotic illnesses.<sup>14</sup> Furthermore, a comprehensive and systematic approach to the history and physical exam is essential in distinguishing between benign and emergent causes of pediatric rashes.

Patient consent has been obtained and filed for the publication of this case report. The authors attest that their institution does not require Institutional Review Board approval. Documentation on file.

---

*Address for Correspondence:* Anthony Edholm, MD, Hackensack University Medical Center, Department of Emergency Medicine, 30 Prospect Avenue, Hackensack, NJ 07601.  
Email: [anthony.edholm@hmn.org](mailto:anthony.edholm@hmn.org).

*Conflicts of Interest:* By the CPC-EM article submission agreement, all authors are required to disclose all affiliations, funding sources and financial or management relationships that could be perceived as potential sources of bias. The authors disclosed none.

*Copyright:* © 2021 Edholm et al. This is an open access article distributed in accordance with the terms of the Creative Commons Attribution (CC BY 4.0) License. See: <http://creativecommons.org/licenses/by/4.0/>

---

## REFERENCES

1. Adam JK, Varan AK, Pong AL, et al. Notes from the field: fatal rat-bite fever in a child - San Diego County, California, 2013. *MMWR*

- Morb Mortal Wkly Rep.* 2014;63(50):1210-1.
2. Graves MH and Janda JM. Rat-bite fever (*Streptobacillus moniliformis*): a potential emerging disease. *Int J Infect Dis.* 2001;5(3):151-4.
  3. Elliott SP. Rat bite fever and *Streptobacillus moniliformis*. *Clin Microbiol Rev.* 2007;20(1):13-22.
  4. Brown CM, Tsai G, Sanchez-Flores X. Oh rats! Fever, rash and arthritis in a young woman. *BMJ Case Rep.* 2015;bcr2015212240.
  5. Wullenweber M. *Streptobacillus moniliformis*--a zoonotic pathogen. Taxonomic considerations, host species, diagnosis, therapy, geographical distribution. *Lab Anim.* 1995;29(1):1-15.
  6. Khatchadourian K, Ovetchkine P, Minodier P, et al. The rise of the rats: a growing paediatric issue. *Paediatr Child Health.* 2010;15(3):131-4.
  7. American Pet Products Association. Pet industry market size, trends & ownership statistics. 2021. Available at: [https://www.americanpetproducts.org/press\\_industrytrends.asp](https://www.americanpetproducts.org/press_industrytrends.asp). Accessed April 22, 2021.
  8. American Veterinary Medical Association. AVMA Pet Ownership and Demographics Sourcebook 2017-2018 Edition. 2018. Available at: <https://www.avma.org/sites/default/files/resources/AVMA-Pet-Demographics-Executive-Summary.pdf>. Accessed April 22, 2021.
  9. Centers for Disease Control and Prevention. Rat-bite fever (RBF). 2019. Available at: <https://www.cdc.gov/rat-bite-fever/transmission/index.html> Accessed July 16, 2020.
  10. Wang NY and Osowicki J. Rat-bite fever in a child without a bite. *Arch Dis Child.* 2021;106(7):652.
  11. Crews JD, Palazzi DL, Starke JR. A teenager with fever, rash, and arthralgia. *JAMA Pediatr.* 2014;168(12):1165-6.
  12. Giorgiutti S and Lefebvre N. Rat bite fever. *N Engl J Med.* 2019;381(18):1762.
  13. Centers for Disease Control and Prevention. Signs and SYMPTOMS OF RAT-BITE FEVER. 2019. Available at: <https://www.cdc.gov/rat-bite-fever/symptoms/index.html>. Accessed July 16, 2020.
  14. Walker JW and Reyes LB. Rat Bite Fever: A Case Report and Review of the Literature. *Pediatr Emerg Care.* 2019;35(2):e28.



# COVID-19 Associated Thyroid Storm: A Case Report

Kevin Sullivan, DO  
Jana Helgeson, MS  
Andrew McGowan, MD

Naval Medical Center San Diego, Department of Emergency Medicine, San Diego, California

Section Editor: Austin Smith, MD

Submission history: Submitted April 5, 2021; Revision received April 11, 2021; Accepted May 28, 2021.

Electronically published August 27, 2021

Full text available through open access at [http://escholarship.org/uc/uciem\\_cpem](http://escholarship.org/uc/uciem_cpem)

DOI: 10.5811/cpem.2021.5.52692

**Introduction:** The distinction between coronavirus disease 2019 (COVID-19) and thyroid storm can be extremely difficult to determine on clinical grounds alone as there is significant overlap between the signs and symptoms of each.

**Case report:** We present a case of a patient with thyroid storm triggered by underlying COVID-19 infection.

**Conclusion:** Infection with severe acute respiratory syndrome coronavirus 2 is linked to dysregulation of the thyroid gland through numerous mechanisms, although thyroid storm triggered by COVID-19 appears rare, with only a single case previously identified in the literature. [Clin Pract Cases Emerg Med. 2021;5(4):412–414.]

**Keywords:** COVID-19; Thyroid storm; thyroiditis.

## INTRODUCTION

Infection with coronavirus disease 2019 (COVID-19) can lead to dysfunction of numerous organ systems, and associated thyroid disease is no exception.<sup>1-3</sup> Both hypothyroidism and hyperthyroidism are documented complications of COVID-19 infection, but there is a paucity of data on the severity of hyperthyroidism in critically ill patients with COVID-19.<sup>4,5</sup> There appears to be only a single case in the literature of overt thyroid storm triggered by severe acute respiratory syndrome coronavirus 2 (SARS-CoV-2) infection.<sup>6</sup> We present a case of a critically ill patient with thyroid storm associated with COVID-19 infection.

## CASE REPORT

A 24-year-old female with a past medical history of Graves' disease presented to the emergency department with one week of fever, cough, myalgias, and congestion. The patient's vital signs included a heart rate of 133 beats per minute, blood pressure of 134/82 millimeters of mercury, respiratory rate of 24 breaths per minute, oxygen saturation of 98% on room air, and an oral temperature of 102.3° Fahrenheit. Her physical exam was notable for a thin,

diaphoretic, and anxious-appearing female who was tremulous and had obvious exophthalmos.

Initial resuscitation included a 2-liter bolus of normal saline, 975 milligrams (mg) of oral acetaminophen, and 400 mg of oral ibuprofen. Antibiotics were considered but not administered given high initial suspicion for thyroid storm with viral trigger. A full complement of laboratory studies, including a complete blood count, basic metabolic panel, venous blood gas, blood cultures, thyroid function tests, urinalysis, and urine pregnancy test, were ordered. Diagnostic imaging included a portable chest radiograph (CXR). Computed tomography pulmonary angiography (CTPA) was considered, but the risks of worsening her potential thyrotoxicosis with an iodine-contrast load was thought to outweigh the benefits. Despite these interventions, the patient's vital signs and clinical condition did not improve.

The patient's labs showed an undetectable thyroid stimulating hormone and a free thyroxine of >7.770 nanograms per deciliter (ng/dL) (reference range 0.89-1.76 ng/dL) along with a positive SARS-CoV-2 polymerase chain reaction. The remainder of her laboratory results were unremarkable, and her CXR was without infiltrates. At

this point, the patient was suspected to be in thyroid storm and had a Burch-Wartofsky score of 60. In consultation with endocrinology, the patient was started on 1 gram of propylthiouracil, 60 mg of propranolol, 100 mg of hydrocortisone, and 4 grams of cholestyramine. She had notable improvement in her symptoms and vital signs and was admitted to the intensive care unit (ICU) for further care. After 36 hours in the ICU, the patient was transferred to a medical-surgical floor and subsequently discharged home with endocrinology follow-up.

## DISCUSSION

There are multiple mechanisms by which thyroid dysfunction may occur in the setting of SARS-CoV-2 infection including lymphocytic proliferation of the thyroid and via a “cytokine storm” induced by the proinflammatory state of COVID-19.<sup>7</sup> The thyroid gland has a relatively high concentration of angiotensin-converting enzyme 2 receptors, which facilitate entry of the virus into cells and may lead to direct thyroid infection.<sup>8</sup> These mechanisms are especially relevant since even mild elevation in thyroid hormone in the setting of COVID-19 is linked to increased mortality.<sup>4</sup>

In the COVID-19 era, it is especially important for clinicians to maintain a high index of suspicion for thyroid storm in toxic-appearing patients. Many of the clinical features of COVID-19 infection including fever, fatigue, tachycardia, and diaphoresis overlap with those of thyroid storm making them difficult to distinguish.<sup>9,10</sup> This has led some researchers to recommend routine thyroid function testing in all critically ill patients admitted for COVID-19.<sup>8</sup> However, relevant studies in the workup of patients with COVID-19 often involve the use of iodine-containing contrast material. This further increases the risk of thyroid storm in predisposed individuals as described by the Jod-Basedow phenomenon, whereby an iodine load causes overproduction of thyroid hormone synthesis in patients with ineffective autoregulation.<sup>11</sup>

These patients may not manifest symptoms of hyperthyroidism until several weeks after the contrast load. This becomes especially problematic when attempting to exclude a diagnosis of pulmonary embolism (PE) in these patients. While infection with SARS-CoV-2 appears to be a risk factor for developing a PE, diagnosing this condition requires the use of a CTPA and thus a contrast load.<sup>12</sup> It is also unclear what role D-dimer has in ruling out PE since D-dimer values tend to be elevated in these patients even in the absence of PE.<sup>13</sup> Clinicians should strongly weigh the benefits and risks of testing for PE in patients with known thyroid disease who are also suspected of having COVID-19.

The treatment of thyrotoxicosis should not vary significantly in those with underlying COVID-19 compared to those with another trigger. Treatment of mild thyrotoxicosis in COVID-19 patients without underlying thyroid disease does not necessitate thionamides, and most

### *CPC-EM Capsule*

What do we already know about this clinical entity?

*Infection with severe acute respiratory syndrome coronavirus 2 can trigger thyroid dysfunction leading to both hypothyroidism and hyperthyroidism*

What makes this presentation of disease reportable?

*The incidence of overt thyroid storm triggered by coronavirus disease 2019 (COVID-19) is rare, with only 2 cases reported in the literature.*

What is the major learning point?

*Clinicians must maintain a high index of suspicion for thyroid storm in patients presenting with COVID-19 as clinical features overlap.*

How might this improve emergency medicine practice?

*Consider ordering thyroid studies in all patients with severe COVID-19 infection.*

of these patients will recover spontaneously.<sup>4</sup> However, patients with thyroid storm should receive treatment with fluids, glucose repletion, thionamides, steroids, and beta blockade in conjunction with endocrinology consultation.<sup>9</sup> Conveniently, treatment of critically ill COVID-19 patients with steroids may provide a mortality benefit and is also recommended in the treatment of thyroid storm.<sup>14</sup>

## CONCLUSION

Infection with SARS-CoV-2 has been linked with thyroid disease, but this is just the second case report of a patient with overt thyroid storm in the setting of COVID-19 infection. Clinicians should consider performing thyroid function testing in critically ill patients admitted with COVID-19, and they should be cautious of using iodine contrast in the diagnostic approach to these patients.

The Institutional Review Board approval has been documented and filed for publication of this case report. Patient consent has been obtained and filed for the publication of this case report.

**Address for Correspondence:** Kevin Sullivan, DO, Naval Medical Center San Diego, Department of Emergency Medicine, 34800 Bob Wilson Drive, San Diego, California 92134. Email: kevin@irishsullivans.com.

**Conflicts of Interest:** By the CPC-EM article submission agreement, all authors are required to disclose all affiliations, funding sources and financial or management relationships that could be perceived as potential sources of bias. The authors disclosed none. The views expressed here are those of the authors and do not reflect the official policy of the Department of the Army, the Department of Defense, or the U.S. Government.

**Copyright:** © 2021 Sullivan et al. This is an open access article distributed in accordance with the terms of the Creative Commons Attribution (CC BY 4.0) License. See: <http://creativecommons.org/licenses/by/4.0/>

## REFERENCES

1. Caron P. Thyroid disorders and SARS-CoV-2 infection: from pathophysiological mechanism to patient management. *Ann Endocrinol (Paris)*. 2020;81(5):507-10.
2. Marazuela M and Giustina A, Puig-Domingo M. Endocrine and metabolic aspects of the COVID-19 pandemic. *Rev Endocr Metab Disord*. 2020;21(4):495-507.
3. Pal R and Banerjee M. COVID-19 and the endocrine system: exploring the unexplored. *J Endocrinol Invest*. 2020;43(7):1027-31.
4. Lania A, Sandri MT, Cellini M, et al. Thyrotoxicosis in patients with COVID-19: the THYRCOV study. *Eur J Endocrinol*. 2020;183(4):381-7.
5. Chen M, Zhou W, Xu W. Thyroid function analysis in 50 patients with COVID-19: a retrospective study. *Thyroid*. 2021;31(1):8-11
6. Pastor S, Molina Á Sr, De Celis E. Thyrotoxic crisis and COVID-19 infection: an extraordinary case and literature review. *Cureus*. 2020;12(11):e11305.
7. Chen G, Wu D, Guo W, et al. Clinical and immunological features of severe and moderate coronavirus disease 2019. *J Clin Invest*. 2020;130(5):2620-9.
8. Muller I, Cannavaro D, Dazzi D, et al. SARS-CoV-2-related atypical thyroiditis. *Lancet Diabetes Endocrinol*. 2020;8(9):739-41.
9. Idrose AM. Acute and emergency care for thyrotoxicosis and thyroid storm. *Acute Med Surg*. 2015;2(3):147-57.
10. Guan WJ, Ni ZY, Hu Y, et al. China Medical Treatment Expert Group for Covid-19. Clinical characteristics of coronavirus disease 2019 in China. *N Engl J Med*. 2020;382(18):1708-20.
11. Lee SY, Rhee CM, Leung AM, et al. A review: Radiographic iodinated contrast media-induced thyroid dysfunction. *J Clin Endocrinol Metab*. 2015;100(2):376-83.
12. Sakr Y, Giovini M, Leone M, et al. Pulmonary embolism in patients with coronavirus disease-2019 (COVID-19) pneumonia: a narrative review. *Ann Intensive Care*. 2020;10:124.
13. Townsend L, Fogarty H, Dyer A, et al. Prolonged elevation of D-dimer levels in convalescent COVID-19 patients is independent of the acute phase response. *J Thromb Haemost*. 2021;19(4):1064-70.
14. RECOVERY Collaborative Group, Horby P, Lim WS, et al. Dexamethasone in hospitalized patients with Covid-19: preliminary report. *N Engl J Med*. 2021;384(8):693-704.

# Nutcracker Syndrome Masquerading as Renal Colic in an Adolescent Athlete: A Case Report

Ron D. Waldrop, MD\*  
Paul Henning, MD†

\*USA Health Systems, Department of Pediatric Emergency Medicine, Mobile, Alabama  
†USA Health Systems, Department of Emergency Medicine, Mobile, Alabama

Section Editor: Melanie Heniff, MD, JD

Submission history: Submitted February 13, 2021; Revision received June 7, 2021; Accepted June 4, 2021.

Electronically published August 27, 2021

Full text available through open access at [http://escholarship.org/uc/uciem\\_cpccem](http://escholarship.org/uc/uciem_cpccem)

DOI: 10.5811/cpcem.2021.6.52140

**Introduction:** Abdominal pain and flank pain cause a significant proportion of emergency department (ED) visits. The diagnosis often remains unclear and is frequently associated with repeat visits to the ED for the same complaint. A rare cause of left upper abdominal and flank pain is compression of the left renal vein between the aorta and the superior mesenteric artery known as nutcracker syndrome. Diagnostic findings on ultrasound include increased left renal vein diameter proximal and peak blood flow velocity increase distal to the superior mesenteric artery. We describe such a patient presenting to an ED repeatedly with severe pain mimicking renal colic before the final diagnosis and intervention occurred.

**Case Report:** A 16-year-old female, long-distance runner presented four times complaining of intractable left upper quadrant abdominal pain radiating to the left flank after exercise. On each visit urinalysis revealed proteinuria and hematuria, and on two visits abdominal computed tomography revealed no kidney stone or dilatation of the collecting system. Ultimately, she was referred to vascular surgery where Doppler ultrasonography was used to diagnose left renal vein compression. Transposition of the left renal vein improved Doppler diameter and flow measurements and eliminated symptoms.

**Conclusion:** Emergency physicians must maintain a large list of possible diagnoses during the evaluation of abdominal and flank pain with a repetitive and uncertain etiology. Nutcracker syndrome may mimic other causes of abdominal and flank pain such as renal colic and requires appropriate referral. [Clin Pract Cases Emerg Med. 2021;5(4):415–418.]

**Keywords:** renal vein; abdominal pain; flank pain; nutcracker syndrome; hematuria; proteinuria; case report.

## INTRODUCTION

Abdominal and flank pain are common complaints in patients presenting to the emergency department (ED).<sup>1</sup> The workup is often extensive, and the etiology frequently remains unclear at the time of discharge. Patients are often given pain relief and sent home for observation and subsequent follow-up. Nonetheless, the repetitive nature of this pain, especially when the cause is uncertain, results in repeat visits to the ED. A rare cause of recurrent left upper abdominal and flank pain is compression of the left renal vein between the aorta and the

superior mesenteric artery (SMA). When symptomatic it is known as nutcracker syndrome (NS).<sup>2,3</sup> To our knowledge NS has not been addressed in the emergency medicine literature and may not be familiar to emergency physicians.

In this case report we describe an adolescent female athlete who presented on four different occasions to the ED with presumed intermittent renal colic due to kidney stones, associated with hematuria and proteinuria. After significant delay, she was ultimately diagnosed with NS and received curative surgical correction.



## CASE REPORT

The patient was a 16-year-old female, long-distance runner with a body mass index of 19 who complained of left upper quadrant abdominal pain radiating to the flank after exercise. She presented to the ED on four occasions over six months with normal vital signs and a complaint of severe pain that resolved with opiate pain management. Abdominal examination each time was not consistent with an emergent surgical problem requiring immediate consultation. Each time urinalysis showed proteinuria and hematuria. On two visits a non-contrast abdominal computed tomography (CT) was performed, which revealed no kidney stone, ureteral calculi, or dilatation of the collecting system.

On the first three occasions after pain management she received instructions to follow up with primary care for further evaluation. After the fourth episode the patient was referred to vascular surgery with a clinical suspicion of NS. Doppler ultrasonography in the standing position demonstrated compression of the left renal vein by the SMA with a hilar (proximal) left renal vein diameter of 9.12 millimeters (mm) and aortico-mesenteric (distal) diameter of 2.1 mm (ratio 4.34), as well as an aortico-mesenteric peak velocity of 141 centimeters per second (cm/sec) and a hilar peak velocity of 20.1 cm/sec (ratio 6.97). The patient ultimately underwent renal vein transposition to a lower aortic position with elimination of her symptoms and resumption of her running career.

## DISCUSSION

Abdominal and flank pain account for up to 10% of all ED visits.<sup>1</sup> Diagnoses may range from mild and self-limiting to life-threatening disease. Because of the repetitive nature and overlapping clinical appearance of this pain as well as the frequently uncertain diagnosis, these patients are prone to diagnostic delay resulting in repeat visits to the ED until definitive referral, management, and intervention.

The SMA originates from the aorta behind the neck of the pancreas at the level of the first lumbar vertebra and creates an angle at its origin from the aorta known as the SMA angle or aorto-mesenteric angle.<sup>4</sup> The left renal vein (LRV) and third part of the duodenum pass in this space leading to two uncommon syndromes: SMA syndrome with compression of the SMA, and anterior nutcracker syndrome (NS) with compression of the LRV when the angle is too acute or devoid of adipose<sup>5</sup> (Figure 1).

Rarely, the LRV arises posterior to the aorta and compression of the LRV may occur between the aorta and vertebral body, which when symptomatic is known as posterior NS. Presence of LRV compression without symptoms is referred to as nutcracker phenomenon.<sup>2</sup> Left renal vein compression in anterior NS impairs LRV blood outflow and is characterized by distention of the hilar (proximal to obstruction) portion of the vein and results in elevation of the peak velocity in the aortico-mesenteric (distal to obstruction)

### CPC-EM Capsule

What do we already know about this clinical entity?

*Nutcracker syndrome (NS) is caused by compression of the left renal vein by the superior mesenteric artery, causing episodic severe left flank pain.*

What makes this presentation of disease reportable?

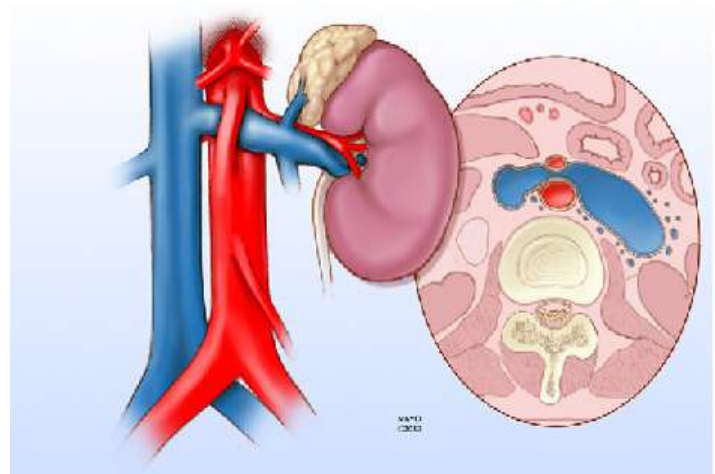
*The patient had repeated clinical presentation to the Emergency Department with symptoms that mimicked renal colic despite lack of imaging evidence to support that diagnosis.*

What is the major learning point?

*A wider differential diagnosis that includes NS could expedite accurate diagnosis, especially in patients with negative imaging studies and repeated visits.*

How might this improve emergency medicine practice?

*Emergency physicians should consider a wider differential diagnosis for patients with left flank pain resembling renal colic.*



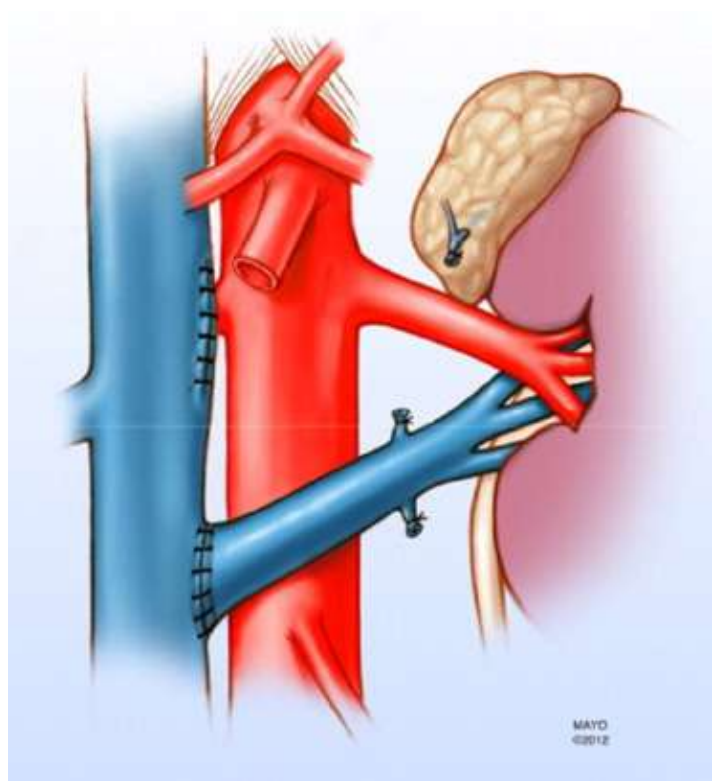
**Figure 1.** Illustration showing the anterior nutcracker syndrome in which the left renal vein is compressed as it passes between the aorta and the superior mesenteric artery resulting in dilation of the portion proximal to the kidney hilum. Reproduced from open access reference 4.

LRV.<sup>6</sup> The most common embryologic explanation for NS is abnormally low or lateral origin of the SMA resulting in an angle of less than 90 degrees.<sup>7</sup> In addition, an abnormally high course of the LRV may contribute to symptoms. Standing may also cause this angle to become more constricted leading to more LRV congestion.<sup>8</sup>

Symptoms resulting from LRV compression in NS were first described in 1950 and have been demonstrated in ages ranging from childhood to the seventh decade.<sup>2,9</sup> Left renal vein compression is believed to cause LRV hypertension and stasis resulting in left-sided abdominal or flank pain with microscopic or macroscopic hematuria resulting from periureteral and gonadal varices, as well as proteinuria by either random or orthostatic sample in children.<sup>10</sup> Hematuria appears to be due to ureteral bleeding as demonstrated on cystoscopy.<sup>11</sup> Nutcracker syndrome is notoriously difficult to diagnose because it mimics many other clinical syndromes such as renal colic due to kidney stones. Some patients may report symptoms exacerbated by standing or walking. Finally, a variety of other symptoms including abdominal pain and neuroendocrine orthostasis have been described and are thought to represent an unknown, associated autonomic disturbance.<sup>12</sup>

Compression of the LRV resulting in NS may be demonstrated by venography, CT arteriography, Doppler ultrasonography (DUS), and magnetic resonance imaging.<sup>13</sup> To decrease invasiveness and expense without sacrificing accuracy, DUS is the most used method to measure diameter and peak velocity in both the hilar and aorto-mesenteric areas of the LRV. Diagnostic measurements from previous studies have suggested a hilar to aortico-mesenteric diameter ratio greater than 4.7 may be predictive of NS with 100% sensitivity and 90% specificity.<sup>14</sup> An aortico-mesenteric to hilar peak velocity ratio of the LRV greater than 7 may also be suggestive, but the range of normal values in children is wide. Finally, DUS measurements in the standing position may be more accurate in demonstrating the effect of a narrow SMA angle on the LRV.<sup>8</sup>

Nutcracker syndrome is associated with non-glomerular hematuria due to ureteral varices resulting from elevated LRV pressure.<sup>10</sup> In case reports, NS has also been associated with co-existing Henoch-Schönlein purpura, immunoglobulin A (IgA) nephropathy, idiopathic hypercalciuria with nephrolithiasis, and membranous nephropathy. Due to the symptom overlap of NS and IgA nephropathy and glomerulonephritis with the presence of flank pain and hematuria, it has been suggested NS should be ruled out with appropriate imaging before diagnostic renal biopsy is performed.<sup>15</sup> Treatment depends on severity and includes conservative and surgical approaches<sup>4,9</sup> (Figure 2). Single or rare occurrences may resolve over time with body habitus change and subsequent deposition of fat along the mesentery preventing angle compression of the LRV. For intractable or recurrent NS, surgical correction may be warranted, with



**Figure 2.** Illustration demonstrating representative surgical correction of compressed left renal vein in anterior Nutcracker syndrome. Reproduced from open access journal reference 4.

transposition of the LRV out of the SMA angle being the most common approach.

## CONCLUSION

Abdominal and flank pain are common complaints in patients presenting to the ED. Frequently, diagnostic testing is inconclusive resulting in an unclear diagnosis and repeat visits to the ED for the same complaint. In the face of this circumstance, emergency physicians must maintain a wide differential diagnosis and low threshold for referral to appropriate specialists. Nutcracker syndrome symptoms and signs may mimic other, more common causes of recurrent abdominal and flank pain such as renal colic due to kidney stones and should be considered by emergency physicians in the differential diagnosis of such patients when diagnostic studies are inconclusive.

The authors attest that their institution requires neither Institutional Review Board approval, nor patient consent for publication of this case report. Documentation on file.

*Address for Correspondence:* Ron D. Waldrop, MD, USA Health Systems, Department of Pediatric Emergency Medicine, 2451 USA Medical Center Drive, Mobile, Alabama 36617. Email: [rwaldrop@health.southalabama.edu](mailto:rwaldrop@health.southalabama.edu).

**Conflicts of Interest:** By the CPC-EM article submission agreement, all authors are required to disclose all affiliations, funding sources and financial or management relationships that could be perceived as potential sources of bias. The authors disclosed none.

**Copyright:** © 2021 Waldrop. This is an open access article distributed in accordance with the terms of the Creative Commons Attribution (CC BY 4.0) License. See: <http://creativecommons.org/licenses/by/4.0/>

## REFERENCES

- Hijaz NM and Friesen CA. Managing abdominal pain in pediatric patients: current perspectives. *Pediatric Health Med Ther.* 2017;8:83-91
- Kurklinsky AK and Rooke TW; Nutcracker phenomenon and nutcracker syndrome. *Mayo Clin Proc.* 2010;85(6):552–9.
- Pournasiri Z. The nutcracker syndrome as a rare cause of chronic abdominal pain: a case report. *J Compr Ped.* 2016;7(3):39-41.
- Said M, Gloviczki P, Kalra M, et al. Renal nutcracker syndrome: surgical options. 2013. *Semin Vasc Surg.* 2013;26(1):35-42.
- Arthurs OJ, Mehta U, Set PAK. Nutcracker and SMA syndromes: What is the normal SMA angle in children? *J Rad.* 2012;81(8):e854-61.
- Ozcakar Z, Birsin Y, Inkaya F, et al. Nutcracker syndrome manifesting with severe proteinuria: a challenging scenario in a single-kidney patient. *Pediatric Nephrol.* 2011;26(6):987-90.
- Hohenfellner M, Steinbach F, Schultz-Lampel D, et al. Nutcracker syndrome: new aspects of pathophysiology, diagnosis, and treatment. *J Urol.* 1991;146(3):685-8.
- Fitoz S, Ekim M, Ozcakar ZB, et al. Nutcracker syndrome in children: the role of upright position examination and superior mesenteric artery angle measurement in the diagnosis. 2007. *J Ultrasound Medicine.* 2007;26(5):573-80.
- Alaygut D, Bayram M, Soylu A, et al. Clinical course of children with nutcracker syndrome. *Urology.* 2013;82(3):686-90.
- Kavukcu S, Kasap B, Goktay Y, et al. Doppler sonographic indices in diagnosing the nutcracker phenomenon in a hematuric adolescent. *J Clin Ultrasound.* 2004;32(1):37-41.
- Park SJ, Lim JW, Cho BS, et al. Nutcracker syndrome in children with orthostatic proteinuria: diagnosis on the basis of Doppler sonography. *J Ultrasound Med.* 2002;21(1):39–45.
- Mazzoni MB, Kottanatu L, Simonetti GD, et al. Renal vein obstruction and orthostatic proteinuria: a review. *Nephrol Dial Transplant.* 2011;26(2):562-5.
- Miro I, Serrano A, Perez-Ardavin J. Eighteen years of experience with pediatric nutcracker syndrome: the importance of the conservative approach 2020. *J Ped Urology.* 2020;16(2):218.e1-218.e6.
- Cheon JE, Kim WS, Kim IO, et al. Nutcracker syndrome in children with gross haematuria: Doppler sonographic evaluation of the left renal vein. *Pediatric Radiology.* 2006;36(7):682–6.
- Ma Z, Liu X, Ning Y, et al. Nutcracker phenomenon in combination with glomerular nephritis in isolated hematuria patients. *Int Urol Nephrol.* 2013;45(3):809-16.

# Gastric Pneumatosis After Accidental Ingestion of Concentrated Hydrogen Peroxide: A Case Report

Christine X.Q. Pham, BS\*  
Casey Graves, MD†  
Michelle Uttaburanont, MD\*  
Karan P. Singh, MD, MBA†‡  
Maciej Witkos, MD†

\*Rancho Family Medical Group, Temecula, California  
†Loma Linda University, Department of Emergency Medicine, Loma Linda, California  
‡University of California, Riverside, School of Medicine, Riverside, California

Section Editor: Steven Walsh, MD

Submission history: Submitted April 25, 2021; Revision received June 3, 2021; Accepted June 4, 2021.

Electronically published October 5, 2021

Full text available through open access at [http://escholarship.org/uc/uciem\\_cpccm](http://escholarship.org/uc/uciem_cpccm)

DOI: 10.5811/cpcem.2021.6.52944

**Introduction:** Hydrogen peroxide is a common oxidizing agent that if ingested may cause injury to the gastrointestinal tract or embolic events. Although therapy is primarily supportive, gastric perforation is a rare but serious complication of corrosive ingestion that may require surgical treatment.

**Case Report:** We report the case of a 77-year-old male who presented for nausea and vomiting after accidentally ingesting approximately 150 milliliters of 35% hydrogen peroxide. Computed tomography revealed gastric pneumatosis and extensive portal venous air. The patient was admitted for observation with plans for endoscopy; however, due to the limitations of our small community hospital, he was transferred to a tertiary care center due to concern for a potential gastric perforation.

**Conclusion:** The presence of portal venous air as a result of peroxide ingestion may be treated conservatively depending on presenting symptoms; however, severe injury such as gastrointestinal perforation may necessitate surgical intervention. [Clin Pract Cases Emerg Med. 2021;5(4):419–421]

**Keywords:** *hydrogen peroxide ingestion; gastric pneumatosis; caustic injury; portal venous air; case report.*

## INTRODUCTION

Hydrogen peroxide is a common oxidizing agent often found in household items such as general-purpose disinfectants, hair dyes, and whitening toothpaste. Higher concentrations of hydrogen peroxide are used as a bleaching agent in the manufacture of paper and textiles, as well as a propellant in rocket fuel. Ingestion of concentrated hydrogen peroxide causes toxicity by one of three mechanisms: corrosive damage; oxygen gas formation; and lipid peroxidation.<sup>1</sup> There is a growing body of literature regarding hydrogen peroxide ingestion causing injury to the gastrointestinal tract or embolic events. Although therapy is primarily supportive, including the use of hyperbaric oxygen therapy in the presence of gas emboli,<sup>2</sup> gastric perforation is a rare but serious complication of corrosive ingestion that may require surgical treatment. We present one such case of a patient who developed gastric pneumatosis following ingestion of concentrated hydrogen peroxide.

## CASE REPORT

A 77-year-old male with a past medical history significant for hypertension, stroke, and prostate cancer presented to the emergency department for accidental ingestion with nausea and vomiting. Approximately 90 minutes prior to arrival, the patient had gone to the refrigerator for water and had mistaken a bottle of 35% hydrogen peroxide for water, subsequently ingesting approximately 150 milliliters (mL). The patient immediately felt a burning sensation in his mouth and throat, followed by nausea and vomiting. He reportedly vomited several times, mostly dry heaving, but at one point had a small amount of blood in the vomitus. He otherwise denied any other complaints.

The patient was in no acute distress upon arrival. His blood pressure was elevated at 157/84 millimeters of mercury, respiratory rate 20 breaths per minute, pulse 65 beats per minute, and arterial oxygen saturation was 98% on room air.



Complete physical examination was negative for posterior oropharyngeal erythema, abdominal tenderness, rebound, or guarding. Laboratory results were significant for an elevated leukocyte count of  $18.9 \times 10^3$  thousand per millimeters cubed ( $K/mm^3$ ) (reference range: 4.5-11.0  $K/mm^3$ ), hemoglobin of 16.4 grams per deciliter (g/dL) (12.0-16.0 g/dL), creatinine of 1.7 milligrams (mg)/dL (0.5-1.4 mg/dL), and lipase of 844 U/L (73-393 U/L). Initial imaging via computed tomography (CT) of the abdomen and pelvis with contrast revealed gastric pneumatosis extending into the distal esophagus with extensive portal venous air, diverticulosis, multiple left renal cysts, and a 5.8-centimeter (cm) adrenal myolipoma (Image).

Given the patient's presenting symptoms combined with the CT findings of gastric pneumatosis, the poison center and gastroenterology were consulted. The patient was admitted for observation with plans for an endoscopy; however, upon surgical consultation, he was emergently transferred to a tertiary care hospital due to concerns for a potential perforation and necrosis of the gastric body and distal esophagus, which may have necessitated a total gastrectomy as well as distal esophagectomy. The patient had been placed on a nothing-by-mouth restriction on admission and was hemodynamically stable on intravenous (IV) fluids, pantoprazole IV drip, and piperacillin-tazobactam at time of transfer.

Upon arrival at the tertiary center, the patient reported overall improvement of his abdominal pain and sore mouth. Esophagogastroduodenoscopy performed there confirmed moderate to severe distal esophagitis and severe pangastritis but no evidence of necrosis, linear ulcerations along the lesser

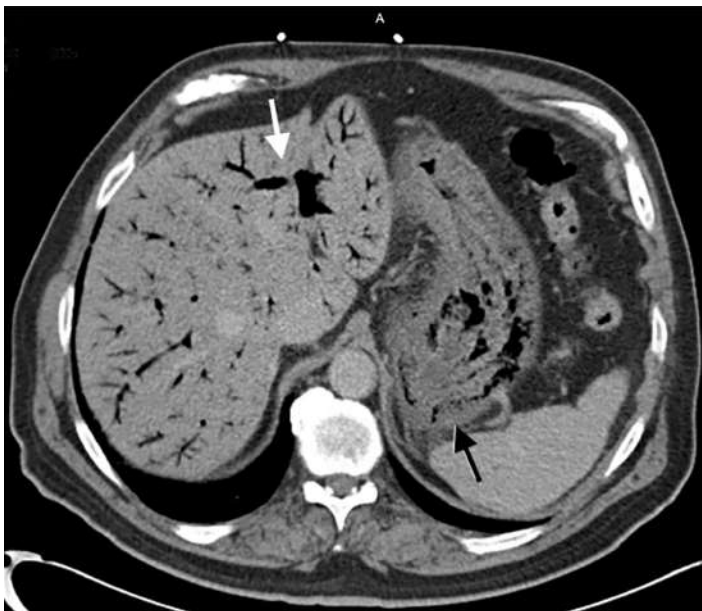### CPC-EM Capsule

What do we already know about this clinical entity?  
*Ingestion of concentrated hydrogen peroxide may result in gastrointestinal, cardiorespiratory, and neurologic effects.*

What makes this presentation of disease reportable?  
*Imaging from the computerized tomography scan clearly demonstrates key findings such as gastric pneumatosis and extensive portal venous gas.*

What is the major learning point?  
*While management of hydrogen peroxide ingestion consists mainly of supportive care, cases of severe injury may require surgical intervention.*

How might this improve emergency medicine practice?  
*Awareness of the clinical manifestations of corrosive ingestion and obtaining prompt imaging can prevent delay in appropriate therapy.*



**Image.** Computed tomography of the abdomen and pelvis without contrast reveals pneumatosis in the walls of the stomach (black arrow) and extensive portal venous gas (white arrow).

curvature, or mild bulbar duodenitis. Gastric biopsy later demonstrated fundic type gastric mucosa with acute inflammation and epithelial erosion. Following his endoscopy, the patient tolerated clear liquids and had his diet advanced to surgical soft. He remained pain-free and was deemed stable for discharge on the third day with recommendations for a repeat endoscopy in two to three months.

### DISCUSSION

Hydrogen peroxide is a colorless, odorless liquid used in many household products and can be easily purchased at high concentrations in health food stores. At-home use of hydrogen peroxide has gained popularity because of the purported, and unproven, health benefits aiding in the treatment of rheumatoid arthritis, cancer, human immunodeficiency virus, and Alzheimer's dementia.<sup>3</sup> Due to the similarity of its characteristics to water, inappropriate storage of this agent can lead to accidental and potentially serious ingestion. The toxicity of concentrated hydrogen peroxide comes from its ability to damage local tissue and to rapidly decompose into water and oxygen in the presence of the enzyme catalase. One

mL of 35% concentrated hydrogen peroxide will liberate 100 mL oxygen. Subsequent generation of large volumes of oxygen in closed body cavities may result in venous or arterial gas embolization, as well as perforation of the hollow viscus.<sup>1</sup>

The most common caustic injury noted on early endoscopy after ingestion is a grade I superficial mucosal injury that often heals spontaneously.<sup>4</sup> Although ingestion of hydrogen peroxide in lower concentrations is typically nontoxic, it has been reported that consumption of even a small amount can cause portal venous gas embolism and hemorrhagic gastritis.<sup>5</sup> Ingestion of hydrogen peroxide in higher concentrations is associated with a wide array of effects including gas embolization, moderate to severe gastrointestinal irritation, cardiorespiratory arrest, and cerebral infarct.<sup>1</sup> In a 10-year retrospective study of 294 cases of high-concentration peroxide ingestion, 13.9% of the patients demonstrated evidence of embolic events.<sup>6</sup>

Management of hydrogen peroxide ingestion depends on the extent of injury, the depth of which can be assessed by endoscopic evaluation. Treatment consists mainly of supportive care, including the use of proton pump inhibitors and H<sub>2</sub> antagonists for mild esophageal and gastric symptoms. In patients who develop neurological symptoms such as altered mental status, seizure, and apnea, as the result of systemic gas emboli, hyperbaric oxygen therapy (HBO) has been successfully used with symptom resolution.<sup>7-9</sup> This process involves intermittent inhalation of 100% oxygen under a pressure greater than 1.0 atmospheres absolute (ATA), usually at least 1.4 ATA.<sup>10</sup> The use of HBO to deliver increased oxygen to body tissues was initially reserved for decompression sickness in deep sea divers but has since been found to be effective as adjunctive therapy for the treatment of acute traumatic wounds, air embolism, gas gangrene, and compartment syndrome.<sup>11</sup>

Additionally, surgical intervention is indicated where there is grade III injury. As there was a strong suspicion for gastric perforation in our patient, an endoscopic examination was not initially performed. Further surgical consultation was deferred to a tertiary care center; however, surgery was ultimately not indicated as the patient was not found to have evidence of esophageal or gastric perforation.

## CONCLUSION

Ingestion of concentrated hydrogen peroxide may result in the presence of gas emboli, gastrointestinal injury, or even death. The presence of portal venous air may be treated conservatively depending on presenting symptoms; however, severe injury such as gastrointestinal perforation may necessitate surgical intervention. Household storage and use of 35% concentrated hydrogen peroxide should be cautioned as there is a need to educate the public on the dangers of corrosives to prevent injury.

The Institutional Review Board approval has been documented and filed for publication of this case report.

*Address for Correspondence:* Casey Graves, MD, Loma Linda University, Department of Emergency Medicine, 600 North Highland Springs Avenue, Banning, California 92220. Email: cgraves@llu.edu.

*Conflicts of Interest:* By the CPC-EM article submission agreement, all authors are required to disclose all affiliations, funding sources and financial or management relationships that could be perceived as potential sources of bias. The authors disclosed none.

*Copyright:* © 2021 Graves. This is an open access article distributed in accordance with the terms of the Creative Commons Attribution (CC BY 4.0) License. See: <http://creativecommons.org/licenses/by/4.0/>

## REFERENCES

1. Watt BE, Proudfoot AT, Vale JA. Hydrogen peroxide poisoning. *Toxicol Rev.* 2004;23(1):51-7.
2. Hendriksen SM, Menth NL, Westgard BC, et al. Hyperbaric oxygen therapy for the prevention of arterial gas embolism in food grade hydrogen peroxide ingestion. *Am J Emerg Med.* 2017;35(5):809.e5-809.e8.
3. yutsis pi. oxygen therapy visionaries: a brief History of Oxygen Therapy. In: Waddell RW, ed. *Oxygen to the Rescue: Oxygen Therapies and How They Help Overcome Disease, Promote Repair, and Improve Overall Function.* North Bergen, NJ: Basic Health Publications Inc; 2003:15-22.
4. Tohda G, Sugawa C, Gayer C, et al. Clinical evaluation and management of caustic injury in the upper gastrointestinal tract in 95 adult patients in an urban medical center. *Surg Endosc.* 2008;22(4):1119-25.
5. Moon JM, Chun BJ, Min YI. Hemorrhagic gastritis and gas emboli after ingesting 3% hydrogen peroxide. *J Emerg Med.* 2006;30(4):403-6.
6. Hatten BW, French LK, Horowitz BZ, et al. Outcomes after high-concentration peroxide ingestions. *Ann Emerg Med.* 2017;69(6):726-36.e2.
7. Vander Heide SJ and Seamon JP. Resolution of delayed altered mental status associated with hydrogen peroxide ingestion following hyperbaric oxygen therapy. *Acad Emerg Med.* 2003;10(9):998-1000.
8. Rider SP, Jackson SB, Rusyniak DE. Cerebral air gas embolism from concentrated hydrogen peroxide ingestion. *Clin Toxicol (Phila).* 2008;46(9):815-8.
9. Byrne B, Sherwin R, Courage C, et al. Hyperbaric oxygen therapy for systemic gas embolism after hydrogen peroxide ingestion. *J Emerg Med.* 2014;46(2):171-5.
10. Kirby JP, Snyder J, Schuerer DJE, et al. Essentials of hyperbaric oxygen therapy: 2019 review. *Mo Med.* 2019;116(3):176-9.
11. Sahni T, Singh P, John MJ. Hyperbaric oxygen therapy: current trends and applications. *J Assoc Physicians India.* 2003;51:280-4.

# The Use of Point-of-care Ultrasound in the Diagnosis of Pott's Puffy Tumor: A Case Report

Josie Acuña, MD  
Daniel Shockey, MD  
Srikar Adhikari, MD, MS

The University of Arizona Tucson, Department of Emergency Medicine, Tucson, Arizona

Section Editor: Gentry Wilkerson, MD

Submission history: Submitted April 8, 2021; Revision received June 1, 2021; Accepted June 8, 2021

Electronically published September 1, 2021

Full text available through open access at [http://escholarship.org/uc/uciem\\_cpccem](http://escholarship.org/uc/uciem_cpccem)

DOI: 10.5811/cpcem.2021.6.52726

**Introduction:** Pott's puffy tumor (PPT) is a rare clinical disease characterized by forehead swelling from a subperiosteal abscess coupled with frontal bone osteomyelitis. It is often associated with severe complications and poor outcomes if left undiagnosed; thus, rapid recognition is crucial. Point-of-care ultrasound (POCUS) may provide an alternative pathway to diagnosis. It can be performed rapidly at the bedside and assist in early screening of patients, identifying those with high suspicion for PPT and prioritizing imaging and consultation.

**Case Report:** A 59-year-old male presented to the emergency department for evaluation of a "lump" on his forehead. He recently had a bifrontal craniotomy to de-bulk a polyp burden in an effort to manage his recurrent sinusitis. To further characterize the mass, a POCUS examination was performed by the treating emergency physician. The examination found a subcutaneous, hypoechoic fluid collection extending superficially along the frontal bone. A discontinuity in the surface of the frontal bone was visualized through which the collection appeared to extend. Given the heightened concern for PPT based on the POCUS examination findings, otolaryngology service was consulted and the patient was admitted for further imaging and treatment.

**Conclusion:** Pott's puffy tumor is a rare diagnosis that has the potential for life-threatening complications. Timely diagnosis is imperative. Point-of-care ultrasound can easily be used to help identify patients with suspicion for PPT in the acute care setting and influence patient management with regard to obtaining further imaging and plans for early consultation. [Clin Pract Cases Emerg Med. 2021;5(4):422–424.]

**Keywords:** *ultrasound; point-of-care; emergency medicine; radiology; case report.*

## INTRODUCTION

Pott's puffy tumor (PPT) is a rare clinical disease characterized by a forehead swelling from a subperiosteal abscess associated with frontal bone osteomyelitis. The condition is commonly associated with frontal sinusitis or trauma to the forehead.<sup>1</sup> Often PPT can lead to complications such as epidural abscess, subdural empyema, and brain abscess.<sup>2</sup> The treatment for PPT is prompt surgical and antibiotic management; thus, rapid recognition is crucial to prevent further complications. Contrast-enhanced computed tomography is typically the initial imaging of choice for PPT in the acute care setting, followed by magnetic resonance imaging if readily available.<sup>3</sup> However, advanced

imaging can be expensive, time prohibitive, and difficult to obtain in a resource-limited setting.

Point-of-care ultrasound (POCUS) may provide an alternative pathway to diagnosis. It can be performed rapidly at the bedside and can assist in screening these patients early on, identifying those with high suspicion for PPT and prioritizing imaging. A limited number of reports in the literature discuss the use of ultrasound as first-line imaging for PPT and primarily describe cases in pediatric patients.<sup>4-6</sup> Even fewer reports discuss the use of POCUS performed by the provider in the acute care setting. We present this case to highlight how POCUS can be a useful modality for the rapid recognition of PPT.



## CASE REPORT

A 59-year-old-male with a history of hypertension, chronic rhinosinusitis with nasal polyps requiring several endoscopic sinus surgeries presented to the emergency department (ED) for evaluation of a “lump” on his forehead. He recently had a bifrontal craniotomy to de-bulk a polyp burden in an effort to manage his recurrent sinusitis. He first noticed the mass 10 days prior to presentation, and it had slowly grown since then. Additionally, he endorsed a constant, pressure-like headache. On arrival to the ED, vital signs demonstrated a temperature of 36.8 degrees Celsius, a heart rate of 106 beats per minute, blood pressure of 114/73 millimeters of mercury, respiratory rate of 18 breaths per minute, and oxygen saturation of 98% on room air. Physical examination revealed a 3 centimeter (cm) x 2 cm x 1 cm mass located centrally on his forehead. The mass was without erythema, induration, or drainage, and was mildly tender to palpation.

Results of a complete blood cell count and complete metabolic panel were within normal limits. To further characterize the mass the treating physician performed a POCUS examination using a high-frequency, linear transducer. This exam revealed a hypoechoic, well-circumscribed area. Periosteal lifting was noted, along with an anechoic subperiosteal collection. Deep to the fluid collection, disruption of the underlying frontal bone was also appreciated. There were no sonographic signs of surrounding cellulitis or other significant findings. Given the heightened concern for PPT based on the POCUS examination, an otolaryngologist was consulted who recommend the patient be admitted for antibiotic treatment and likely surgical intervention.

## DISCUSSION

Early suspicion and diagnosis of PPT increases the chance of good recovery. Pott's puffy tumor is a risk factor for intracranial serious complications such as subdural empyema and brain abscess.<sup>7-8</sup> Although rare, given the high prevalence and severity of complications associated with PPT, providers should have a heightened level of suspicious for this diagnosis. A literature review that described 92 adolescent and pediatric patients with PPT found the overall rate of intracranial complications to be 72%.<sup>9</sup> Although the incidence of complications is lower among adults, literature review found that these patients were still at high risk of serious intracranial complications with a rate of 29%.<sup>10</sup>

In instances where history and clinical signs suggest PPT, a POCUS examination can provide immediate information that can aid in the diagnosis. A linear, high-frequency transducer can be used for this examination. Both transverse and sagittal views of the frontal mass should be obtained. A PPT will appear as a hypoechoic, well-circumscribed area. Periosteal lifting is noted, along with an anechoic subperiosteal collection. The subperiosteal abscess will often demonstrate peripheral hypervascularity. Deep to the fluid collection, disruption of the normally smooth, linear,

### CPC-EM Capsule

What do we already know about this clinical entity?

*Pott's puffy tumor (PPT) is a rare clinical entity associated with life-threatening complications.*

*Timely diagnosis is imperative.*

What makes this presentation of disease reportable?

*This case highlights the use of point-of-care ultrasound for the rapid recognition of PPT.*

What is the major learning point?

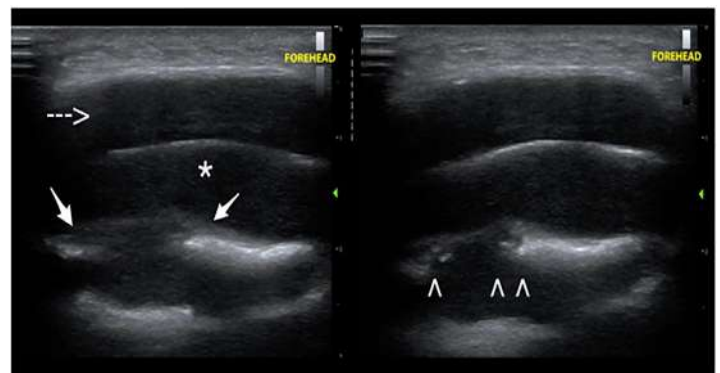
*Point-of-care ultrasound can assist in screening patients for PPT to identify those with high suspicion for this disease and prioritize imaging.*

How might this improve emergency medicine practice?

*Point-of-care ultrasound can be used to help identify patients with suspicion for PPT in the acute care setting and influence patient management.*

underlying frontal bone is appreciated, which is consistent with erosion from osteomyelitis (Image 1).

Signs of cortical disruption should raise concern for intracranial extension and prompt further evaluation with other imaging modalities. Color Doppler may also be used over the area of swelling to further assess the extent of the fluid in cases where intracranial extension is unclear.



**Image 1.** Transverse grayscale images over the area of swelling in the midline forehead demonstrating a hypoechoic superficial fluid (dashed arrow), and a subgaleal fluid collection (\*) extending along the superficial aspect of the frontal bone. Periosteal lifting is noted (arrows). There is focal discontinuity in the surface of the bone (arrowheads), through which the collection appears to extend.

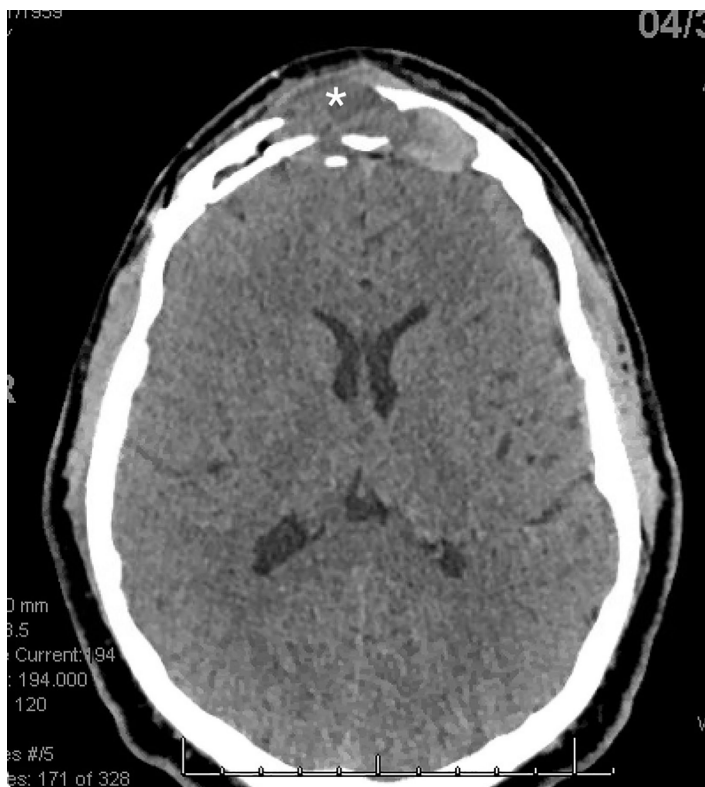

After evaluation of the patient in the ED by otolaryngology, a needle aspiration was performed to take a sample of fluid from the mass. Computed tomography imaging demonstrated a soft tissue mass extending throughout the frontal sinus, including extension into the right frontal lobe consistent with Pott's puffy tumor (Image 2).

The patient was taken to the operating room emergently the next morning. This case demonstrates a unique clinical scenario of POCUS evidence of PPT. One should be aware of the inherent limitations of POCUS, such as its reliance on operator experience. However, this examination involves a technique that can be easily learned by most emergency physicians. Using POCUS as an initial imaging modality in the acute care setting can allow providers to risk-stratify patients, determine the need for other imaging modalities, and obtain consultation more quickly.

## CONCLUSION

Pott's puffy tumor is a rare diagnosis that has the potential for life-threatening complications. Timely diagnosis is imperative. Point-of-care ultrasound can easily be used to help identify patients with suspicion for PTT in the acute care setting and influence patient management with regard to obtaining further imaging and plans for early consultation.



**Image 2:** Computed tomography imaging demonstrating a soft tissue mass (\*) extending through the frontal sinus and the right frontal lobe.

The authors attest that their institution requires neither Institutional Review Board approval, nor patient consent for publication of this case report. Documentation on file.

**Address for Correspondence:** Josie Acuña, MD, The University of Arizona, Tucson, Department of Emergency Medicine, The University of Arizona Medical Center 1501 N. Campbell Ave. AHSL 4165 PO Box 245057, Tucson, AZ 85724-5057. Email: jacuna@aemrc.arizona.edu.

**Conflicts of Interest:** By the CPC-EM article submission agreement, all authors are required to disclose all affiliations, funding sources and financial or management relationships that could be perceived as potential sources of bias. The authors disclosed none.

**Copyright:** © 2021 Acuña. This is an open access article distributed in accordance with the terms of the Creative Commons Attribution (CC BY 4.0) License. See: <http://creativecommons.org/licenses/by/4.0/>

## REFERENCES

1. Tudor RB, Carson JP, Pulliam MW, et al. Pott's puffy tumor, frontal sinusitis, frontal bone osteomyelitis and epidural abscess secondary to a wrestling injury. *Am J Sports Med.* 1981;9(6):390–1.
2. Perić A, Milojević M, Ivetić D. A Pott's puffy tumor associated with epidural - cutaneous fistula and epidural abscess: case report. *Balkan Med J.* 2017;34(3):284-7.
3. Durur-Subasi I, Kantarci M, Karakaya A, et al. Pott's puffy tumor: multidetector computed tomography findings. *J Craniofac Surg.* 2008;19(6):1697–9.
4. Reddan T and Connor P. Not just a bump on the head: ultrasound as first-line imaging in a boy with Pott's puffy tumour. *J Med Radiat Sci.* 2018;65(1):71-73.
5. Shemesh AJ, Panebianco NL, Chen AE. an uncommon complication of sinusitis in a young adolescent. *Pediatr Emerg Care.* 2015;3(7):531-2.
6. Vanderveken OM, De Smet K, Dogan-Duyar S, et al. Pott's puffy tumour in a 5-year-old boy: the role of ultrasound and contrast-enhanced CT imaging; surgical case report. *B-ENT.* 2012;8(2):127-9.
7. Ketenci I, Unlü Y, Tucer B, et al. The Pott's puffy tumor: a dangerous sign for intracranial complications. *Eur Arch Otorhinolaryngol.* 201;268(12):1755-63.
8. Blumfield E and Misra M. Pott's puffy tumor, intracranial, and orbital complications as the initial presentation of sinusitis in healthy adolescents, a case series. *Emerg Radiol* 2011;18(3):203–10.
9. Koltsidopoulos P, Papageorgiou E, Skoulakis C. Pott's puffy tumor in children: a review of the literature. *Laryngoscope.* 2020; 130(1):225-231.
10. Akiyama K, Karaki M, Mori N. Evaluation of adult Pott's puffy tumor: our five cases and 27 literature cases. *Laryngoscope.* 2012;122(11):2382-8.

# Early Extracorporeal Membrane Oxygenation in COVID-19 with Bullous Lung Disease on Mechanical Ventilation: A Case Report

Jason Unold, DO  
Brandon Marshal, MD  
Tolupe Sonuyi, MD

Detroit Receiving Hospital, Department of Emergency Medicine, Detroit, Michigan

Section Editor: Christopher San Miguel, MD

Submission history: Submitted April 21, 2021; Revision received June 10, 2021; Accepted June 11, 2021

Electronically published September 2, 2021

Full text available through open access at [http://escholarship.org/uc/uciem\\_cpccem](http://escholarship.org/uc/uciem_cpccem)

DOI: 10.5811/cpcem.2021.6.52898

**Introduction:** Extracorporeal membrane oxygenation (ECMO) has been well described as a viable option for patients in need of temporary supplemental oxygenation when ventilator capabilities have failed to augment a patient's condition. Less described is the potential use of ECMO for lung protection in the setting of gigantic bullae despite initially adequate oxygenation.

**Case Report:** We describe how the early incorporation of ECMO in a patient with coronavirus disease 2019 and necrotizing pneumonia complicated by multiple large and gigantic bullae led to a favorable outcome.

**Conclusion:** The decision to start ECMO early, despite room for ventilator oxygenation adjustments, may have helped to prevent potential, significant complications such as tension pneumothorax while on positive pressure, thus potentially optimizing the outcome in this patient. [Clin Pract Cases Emerg Med. 2021;5(4):425–428.]

**Keywords:** *resuscitation; critical care; COVID-19; gigantic bullae; ECMO.*

---

## INTRODUCTION

Venovenous extracorporeal membrane oxygenation (VV-ECMO) is a known treatment strategy that can be used for refractory respiratory failure by running the patient's deoxygenated blood through a membrane oxygenator before returning the blood to the area of the right atrium.<sup>1</sup> This form of ECMO relies on the patient's native cardiac function to deliver the now-oxygenated blood throughout the rest of the body. Evidence has also shown ECMO to be a useful surgical adjunct in multiple, video-assisted thoracoscopic surgeries such as treatment of a ruptured empyema, resections of gigantic bullae, difficult single-lung oxygenation surgeries, and in an iatrogenic pneumothorax in which a large bullae caused continued air leak preventing effective treatment with traditional tube thoracostomy.<sup>2-5</sup> As demonstrated in a 2009 multicenter, randomized controlled trial, the typical indication for ECMO secondary to infections were defined as patients

with severe, but potentially reversible, respiratory failure failing typical ventilator augmentations.<sup>6</sup>

Indications for ECMO in the setting of severe acute respiratory distress syndrome (ARDS) secondary to COVID-19 infections have yet to be defined. A review of 10 case reports and three case series failed to outline any specific usefulness of ECMO in the setting of coronavirus infections with severe ARDS sequelae.<sup>7</sup>

While ECMO hasn't been shown to have specific benefits in COVID-19 infections, ECMO may be advantageous in severe but potentially reversible ARDS as well as surgical augmentation. However, ECMO as an option for lung protection in the setting of acute respiratory failure requiring mechanical ventilation with underlying gigantic pulmonary bullae has not yet been reported. It is already known that underlying bullae raise the risk for spontaneous pneumothorax.<sup>8</sup> In the setting of oxygenation

failure, typical treatment strategy to augment poor arterial oxygenation is administration of 100% fraction of inspired oxygen ( $\text{FiO}_2$ ) as well as increasing positive end expiratory pressure (PEEP).<sup>9</sup> However, in the presence of gigantic bullae, the risk of iatrogenic pneumothorax secondary to barotrauma from positive pressure ventilation and high levels of PEEP is a significant consideration. Furthermore, unintentional placement of a chest tube within a gigantic bullae can result in iatrogenic pneumothorax, hemothorax, shock, and death.<sup>10</sup>

We discuss how early initiation of VV-ECMO was used to protect a patient with gigantic bullae requiring mechanical ventilation from developing an iatrogenic pneumothorax while on positive pressure.

## CASE REPORT

A young adult patient presented to our emergency department (ED) via emergency medical services (EMS) as a medical code secondary to respiratory distress and altered mentation. The unidentified male with an estimated age between 20-30 was in respiratory extremis and unable to communicate with providers. Per EMS, when they arrived at the house they found the patient in the bathtub, minimally responsive with a pulse oximetry of 60%. The patient was immediately brought to the ED. Initial Glasgow Coma Scale was six. Vital signs showed a heart rate of 161 beats per minute, blood pressure of 116/75 millimeters of mercury (mm Hg), tachypnea at 34 breaths per minute (bpm), pulse oximetry 90% on 100%  $\text{FiO}_2$  through bag-valve-mask, and a core temperature of 36.7° Celsius.

The decision was made to emergently intubate the patient and place him on mechanical ventilation. His initial ventilator settings were volume control of 450 ml (8 cubic centimeters per kilogram), rate of 16, PEEP of 5 mm Hg, and  $\text{FiO}_2$  of 100%. The patient was also started on broad-spectrum antibiotics and sedated with dexmedetomidine and propofol infusion. Post-intubation chest radiograph (CXR) showed bilateral interstitial infiltrates as well as a gigantic bleb in the right upper lobe (Image 1).

Thoracic computed tomography obtained while within the ED showed a necrotizing multifocal pneumonia with lower lobe predominant bronchiectasis, giant right upper lobe bulla, and large right lower lobe bulla (Images 2, 3).

Initial laboratory evaluation showed an elevated white blood cell count of  $48.0 \times 10^9/\text{liter}$  (L) (reference range: 4.5-11.0  $10^9/\text{L}$ ), lactic acid of 4.4 millimoles per liter (mmol/L) (0.5-2.2 mmol/L), and a positive COVID-19 screen. Initial arterial blood gas showed a pH of 7.155 (reference range: 7.35-7.45), partial pressure of carbon dioxide ( $\text{PCO}_2$ ) of 75.4 mm Hg (35-45 mm Hg), partial pressure of arterial oxygen ( $\text{PaO}_2$ ) 115.5 mm Hg (80-100 mm Hg), and bicarbonate ( $\text{HCO}_3$ ) 25.8 milliequivalents per liter (mEq/L) (reference range: 38-42 mEq/L).

A few hours into the patient's stay, while still in the ED he developed hypotension and hypoxia to 88% on 100%

### CPC-EM Capsule

What do we already know about this clinical entity?

*Extracorporeal membrane oxygenation (ECMO) has been shown to be advantageous in severe but potentially reversible acute respiratory distress syndrome as well as surgical augmentation.*

What makes this presentation of disease reportable?

*ECMO has not yet been reported as an option for lung protection in the setting of respiratory failure requiring mechanical ventilation with underlying gigantic pulmonary bullae.*

What is the major learning point?

*Early initiation of venovenous ECMO in the setting of gigantic bullae, may have helped to avoid an iatrogenic pneumothorax while under positive pressure ventilation.*

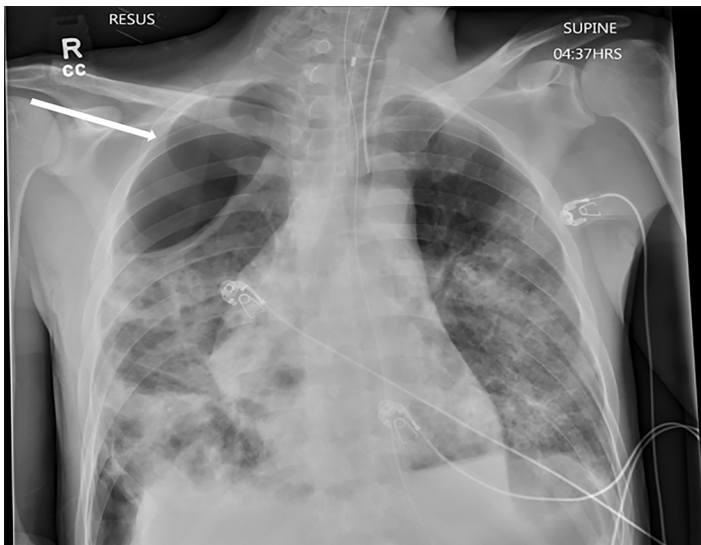How might this improve emergency medicine practice?

*May lead to early identification for the involvement of ECMO equipped facilities to expedite collaboration with critical consultants.*

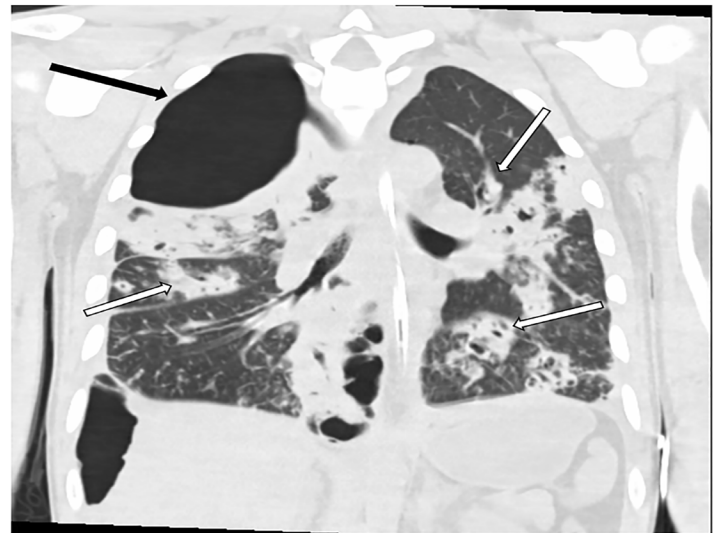
$\text{FiO}_2$  and PEEP of five centimeters of water ( $\text{cm H}_2\text{O}$ ). A STAT repeat CXR confirmed the absence of a pneumothorax, and bedside ultrasound showed a hyperdynamic left ventricle and flat inferior vena cava. The patient was bolused three liters of normal saline while central venous and arterial lines were placed, after which norepinephrine was initiated.

He then developed high peak pressures. Due to the high pressures, the ventilator settings were transitioned to pressure control with a driving pressure of 18  $\text{cm H}_2\text{O}$ , rate of 24 bpm, 100%  $\text{FiO}_2$ , and a PEEP of 5  $\text{cm H}_2\text{O}$ . Repeat arterial blood gas showed a pH 7.19,  $\text{PCO}_2$  71.5 mm Hg,  $\text{PaO}_2$  84.7 mm Hg, and  $\text{HCO}_3$  of 27.2 mEq/L. The patient continued to desaturate down to 85% on 100%  $\text{FiO}_2$ , so PEEP was increased from five to eight  $\text{cmH}_2\text{O}$ . Because of the patient's gigantic bullae, worsening oxygenation and hypercapnia, and concerns for inevitable iatrogenic pneumothorax, the decision was made to consult the ECMO team. Of note, at this time the patient's arterial oxygenation was not in a critical range (84.7 mm Hg), and in a typical situation this value alone would not be a typical indication for ECMO. The





**Image 1.** Post-intubation chest anterior-posterior radiograph demonstrating pneumonia and gigantic bulla (white arrow).



**Image 2.** Thorax computed tomography coronal plane demonstrating right upper lobe gigantic bulla (black arrow) as well as multifocal pneumonia with bronchiectasis (multiple white arrows).

ECMO team agreed that due to the complicated nature of the patient's disease process and underlying severity of lung injury he was an appropriate candidate for VV-ECMO. The patient was taken emergently to the operating room and received a right ventricular assist device, and VV-ECMO was initiated.

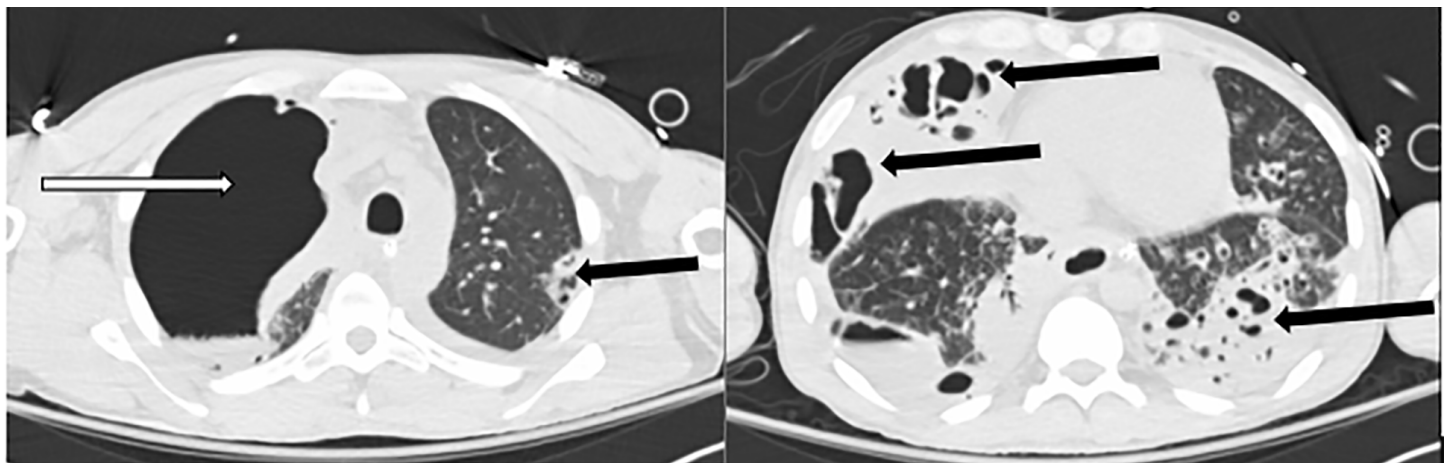
Post VV-ECMO initiation, the patient was extubated in under 24 hours and transitioned to 3L nasal cannula. Sedation was weaned and the patient quickly became fully alert and was able to follow commands and communicate. On hospital day 3 his blood cultures grew positive for methicillin-resistant *Staphylococcus aureus* (MRSA). The patient received daily chest CXRs post-ECMO cannulation to tract placement and lung pathology. Post-extubation chest CXR the following day showed no new pathology; however, on the second morning

post extubation he was found to have developed an asymptomatic spontaneous pneumothorax on routine chest CXR. The patient remained hemodynamically stable and did not require tube thoracostomy, potentially aiding to an outcome that would have been drastically different if he had still been on positive pressure ventilation.

The final diagnosis was established as acute hypoxic respiratory failure due to COVID-19 pneumonia with superimposed MRSA. The patient was discharged to his mother's house with home health care and home oxygen on hospital day 29 on two liters nasal cannula.

## DISCUSSION

As demonstrated by this case, the early initiation of VV-ECMO in the setting of gigantic bullae helped to avoid an



**Images 3.** Thorax computed tomography transverse plane demonstrating giant right upper lobe bulla (white arrow) as well as multifocal pneumonia and bronchiectasis in both images at differing levels (multiple black arrows).



iatrogenic pneumothorax while under positive pressure ventilation, decreased the number of days on mechanical ventilation, maintained hemodynamic stability in the setting of spontaneous pneumothorax, and likely led to an overall decrease in intensive care unit stay. Very early on our patient developed signs of worsening oxygenation status despite 100% FiO<sub>2</sub>. Increasing this patient's PEEP to correct for hypoxia likely would have led to positive pressure iatrogenic pneumothorax, which would have further decompensated the patient's already poor pulmonary baseline. This hypothesis is further supported by the presence of a spontaneous pneumothorax two days post extubation. By initiating ECMO early, mechanical ventilation was discontinued prior to the development of a spontaneous pneumothorax, thus avoiding significant complications and mortality associated with a pneumothorax under positive pressure.

Our report is not without limitations. This treatment strategy requires a facility equipped with ECMO capabilities. While this may not be generalizable to all health centers, it does provide a potential strategy whereby one may begin to engage early on with nearby ECMO-capable facilities for potential transfer. Additionally, because this report was a discussion of one patient there was the possibility of unseen variables that potentially helped impact personal outcome.

## CONCLUSION

Further studies into the use of ECMO to prevent significant complications associated with gigantic bullae and positive pressure ventilation may provide useful information regarding patient care. This information may aid in the earlier identification of disease, necessity of possible transfers to ECMO-equipped facilities, expedited involvement of critical consultants, and potential for favorable patient outcomes.

The authors attest that their institution requires neither Institutional Review Board approval, nor patient consent for publication of this case report. Documentation on file.

*Address for Correspondence:* Jason Unold, DO, Detroit Receiving Hospital, Department of Emergency Medicine, 4201 St Antoine, Detroit, Michigan 48201. [Email: junold@dmc.org](mailto:junold@dmc.org).

*Conflicts of Interest:* By the CPC-EM article submission agreement, all authors are required to disclose all affiliations, funding sources and financial or management relationships that

could be perceived as potential sources of bias. The authors disclosed none.

*Copyright:* © 2021 Unold. This is an open access article distributed in accordance with the terms of the Creative Commons Attribution (CC BY 4.0) License. See: <http://creativecommons.org/licenses/by/4.0/>

## REFERENCES

1. McRae K and de Perrot M. Principles and indications of extracorporeal life support in general thoracic surgery. *J Thorac Dis*. 2018;10(Suppl 8):S931-S46.
2. Brenner M, O'Connor JV, Scalea TM. Use of ECMO for resection of post-traumatic ruptured lung abscess with empyema. *Ann Thorac Surg*. 2010;90(6):2039-41.
3. Redwan B, Biancosino C, Giebel F, et al. Perioperative single-site veno-venous extracorporeal CO2 removal for minimally invasive giant bulla resection. *Perfusion*. 2017;32(8):698-701.
4. Redwan B, Ziegeler S, Freermann S, et al. Intraoperative veno-venous extracorporeal lung support in thoracic surgery: a single-centre experience. *Interact Cardiovasc Thorac Surg*. 2015;21(6):766-72.
5. Oey IF, Peek GJ, Firmin RK, et al. Post-pneumonectomy video-assisted thoracoscopic bullectomy using extra-corporeal membrane oxygenation. *Eur J Cardiothorac Surg*. 2001;20(4):874-6.
6. Peek GJ, Mugford M, Tiruvoipati R, et al. Efficacy and economic assessment of conventional ventilatory support versus extracorporeal membrane oxygenation for severe adult respiratory failure (CESAR): a multicentre randomised controlled trial. *The Lancet*. 2009;374(9698):1351-63.
7. Hu BS, Z Hu, Jiang LX, et al. Extracorporeal membrane oxygenation (ECMO) in patients with COVID-19: a rapid systematic review of case studies. *Eur Rev Med Pharmacol Sci*. 2020;24(22):11945-52.
8. Ohata M and Suzuki H. Pathogenesis of spontaneous pneumothorax. With special reference to the ultrastructure of emphysematous bullae. *Chest*. 1980;77(6):771-6.
9. Brower RG, Matthay MA, Morris A, et al. Ventilation with lower tidal volumes as compared with traditional tidal volumes for acute lung injury and the acute respiratory distress syndrome. *N Engl J Med*. 2000;342(18):1301-8.
10. MacDuff A, Arnold A, Harvey J. BTS Pleural Disease Guideline Group. Management of spontaneous pneumothorax: British Thoracic Society Pleural Disease Guideline 2010. *Thorax*. 2010;65 Suppl 2:ii18-ii31.

# A Case Report of Opisthotonos Associated with Administration of Intramuscular Ketamine

Matthew W. Morgan, MD  
Ellen Dore, MD

Regions Hospital, Department of Emergency Medicine, St. Paul, Minnesota

Section Editor: Jacqueline Le, MD

Submission history: Submitted May 6, 2021; Revision received June 17, 2021; Accepted June 22, 2021

Electronically published October 19, 2021

Full text available through open access at [http://escholarship.org/uc/uciem\\_cpccem](http://escholarship.org/uc/uciem_cpccem)

DOI: 10.5811/cpccem.2021.6.53069

**Introduction:** Ketamine, a commonly used medication to treat agitation, has known adverse effects such as emergence reactions, vomiting, and laryngospasm. Opisthotonos has not been a commonly reported adverse reaction.

**Case Report:** We report a case of opisthotonos brought on by administration of ketamine. A 24-year-old male with a history of schizophrenia was brought in by emergency medical services with opisthotonos shortly after treatment with 250 milligrams intramuscular ketamine by paramedics. He had become increasingly paranoid after being off his aripiprazole for a few weeks, and his family had become afraid for his and their safety. Paramedics administered ketamine to control his combative agitation, per protocol. The patient's extreme neck and back extension rapidly resolved with the administration of midazolam. Further history and workup did not reveal another cause for opisthotonos.

**Conclusion:** This is the first reported case to our knowledge of ketamine-associated opisthotonos in the emergency setting. Emergency care providers should be aware of this potential side effect. [Clin Pract Cases Emerg Med. 2021;5(4):429–431.]

**Keywords:** *case report; ketamine; opisthotonos.*

## INTRODUCTION

Ketamine has been shown to be a safe and effective medication in the prehospital setting for patients requiring emergent sedation.<sup>1</sup> Common side effects include emergence reactions, post-sedation nausea, hypertension, and tachycardia. We present a unique case of opisthotonos that occurred after intramuscular ketamine administration.

## CASE REPORT

A 24-year-old man was brought in by paramedics in apparent extremis after having received a 250-milligram (mg) intramuscular injection of ketamine. Paramedics had been called by family because the patient, who had a history of schizophrenia, had become increasingly paranoid and religiously preoccupied, and his family had become afraid for his and their safety. The family later provided the history that he had been eating and sleeping minimally. That day he had been shaking uncontrollably on the floor while talking about

being possessed. He thought that his medications were poisoning him and thus had been off them for three to four weeks. The paramedics were unable to transport the patient safely and had given him the ketamine to control his agitation per their protocol.

On arrival to the emergency department (ED) the patient displayed opisthotonos, his back consistently held arched in extension. He spoke no discernible words but rather mumbled gibberish or moaned. His eyes were closed initially. When opened by the provider, rotary nystagmus was noted, with normal size and sluggish pupils. He showed no meaningful response to verbal stimuli. His initial vital signs showed him to be tachycardic at 140 beats per minute, hypertensive at 153/100 millimeters mercury, and tachypneic at 30 breaths per minute, but afebrile, with normal oxygen saturations in the upper nineties on room air. His exam did not reveal signs of trauma. His lungs were clear, and he had no rigidity or clonus. He would occasionally flex his upper extremities such as with

stimuli from intravenous line placement, but maintained extended, arched posture.

The patient was immediately given 2.5 mg of midazolam intravenously, which partially relieved his opisthotonos within a few minutes. Instead of nearly constant extensor posturing of the neck it became more intermittent, and arching of the back lessened. A few minutes later he was given an additional 2.5 mg of midazolam, and a few minutes thereafter, cessation of the opisthotonos was noted. His heart rate declined to between 100-110 beats per minute. His breathing also notably slowed to a rate between 20-25 respirations per minute, and his blood pressure normalized.

Upon chart review it was determined that the patient had visited two local hospitals in the prior two days for similar although less severe decompensation of his known mental illness. He was also noted at those times not to be taking his prescribed aripiprazole. He had been given one dose of aripiprazole in the ED the day before the index presentation, but according to family had not taken any since, and as previously noted had not taken his aripiprazole for 3-4 weeks. He was not known to take any other medications. He had been known to use marijuana and cocaine in the past. In 2018 his tetanus was noted to be up to date, but it was unclear when it would need to be updated.

The patient had a long history of medication noncompliance and trialing of multiple antipsychotic medications. Earliest available records in 2017 showed that he was diagnosed with schizophrenia at that time and was initially started on risperidone. He had immediately stopped taking the risperidone and hydroxyzine after discharge and had a long history of re-admissions for decompensations when not taking his medications.

An initial workup was notable for a normal blood glucose and normal electrolytes with the exception of a potassium of 2.5 millimoles per liter (mmol/L) (reference range: 3.6-5.2 mm/L). Magnesium was 1.8 mg per deciliter (dL) (1.7-2.2 mg/dL). An electrocardiogram revealed a QTc-interval of 607 milliseconds (ms) (440-460 ms). This became more pertinent as the patient required more sedation as the effect of the ketamine wore off and he became restless and yelled at staff. He no longer mumbled or spoke in gibberish and had begun clearly pronouncing words in English and in a foreign language as he became more aggressive with staff. No further extension posturing was noted.

The patient was given several more doses of midazolam for a total of 12.5 mg in the ED, followed by a total of 8 mg of lorazepam for longer acting sedation. He also required physical restraints while in the ED. Potassium replacement along with 2 grams of magnesium was initiated, and antipsychotics were avoided due to his prolonged QTc-interval. Just before admission and transfer out of the ED, his repeat electrocardiogram showed a QTc-interval of 411 ms. He remained afebrile and had no leukocytosis. After transfer

up to the floor, he required additional midazolam. The patient was admitted initially to the medicine service, given his hypokalemia, but was soon transferred to the mental health unit upon its resolution.

## DISCUSSION

Dystonic reactions are relatively rare after ketamine administration. Our patient experienced opisthotonos within minutes of receiving ketamine intramuscularly making ketamine administration the most likely etiology. Opisthotonos, a severe dystonic reaction involving hyperextension and spasticity of the neck and back, has been reported rarely in infants receiving ketamine as anesthesia but is otherwise not seen as a reaction to ketamine administration in the medical literature.<sup>2</sup> It has been reported in the veterinary literature in multiple other species.<sup>3</sup> Side effects of ketamine that most providers are aware of include emergence reactions, vomiting and, rarely, laryngospasm.

Opisthotonos is often associated with tetanus but has also been seen in other illnesses such as kernicterus, neurosyphilis, and meningoencephalitis, with

### CPC-EM Capsule

What do we already know about this clinical entity?

*Opisthotonos, an unusual clinical condition characterized by extreme rigidity and curvature of the back, is not a known side effect of ketamine.*

What makes this presentation of disease reportable?

*There are no reported cases of the opisthotonos associated with ketamine in adults and only a few are reported in infants.*

What is the major learning point?

*With increasing use of this agent providers should be aware of this possible side effect so that they may readily treat it. Midazolam appeared to be effective in this case.*

How might this improve emergency medicine practice?

*As with most medications in our armamentarium increasing awareness of adverse effects will potentially improve the quality of our care.*

administration of phenothiazines and propofol, and poisoning involving strychnine.<sup>4-8</sup> The patient's presentation and rapid recovery suggest against any of these alternative etiologies. Opisthotonos has been reported in intoxication with the other major arylcyclohexamine N-methyl-D-aspartate (NMDA) receptor antagonists (other than ketamine) such as phencyclidine and methoxetamine, making it biologically plausible that ketamine could have caused the reaction.<sup>9</sup>

The NMDA receptor antagonists are also known to decrease dopamine reuptake and increase dopamine release, as well as inhibit acetylcholine receptors and decrease its release.<sup>10,11</sup> These effects might be expected to decrease dystonic reactions, as medications typically associated with dystonic reactions are dopamine receptor antagonists and these reactions can be treated with anticholinergics. However, there is some suggestion that dopamine receptor antagonists induce a super-sensitivity in the post-synaptic receptor and that this may account for part of the mechanism for dystonic reaction.<sup>12</sup> Our patient was started on a dopamine antagonist during hospitalization and did not have return of opisthotonos or other dystonic reaction. Lastly, psychostimulants such as amphetamines and related compounds, known to induce movement disorders, are also occasionally associated with dystonic reactions despite increasing dopamine release.<sup>13</sup> Our patient had a drug screen done as an inpatient that was positive only for benzodiazepines, which we had given him.

Suffice it to say that the mechanisms of dystonic reactions are complex and incompletely elucidated. Regardless, the proximity of the reaction to the administration of ketamine and the absence of other more likely causes make ketamine the most likely trigger in our patient. He was effectively treated with midazolam. The benzodiazepines might be expected to be effective as they are for dystonias in general (as well as for emergence reactions). Diphenhydramine and benztropine would also be options for treatment.<sup>14</sup>

## CONCLUSION

Given the increasing use of ketamine as an agent for controlling agitation more adverse reactions such as the one experienced by our patient could be expected to occur. Characterizing, reporting, and attempting to explain them may enhance our care of patients requiring these treatments.

The authors attest that their institution requires neither Institutional Review Board approval, nor patient consent for publication of this case report. Documentation on file.

*Address for Correspondence:* Matthew W. Morgan, MD, Regions Hospital, Department of Emergency Medicine, 640 Jackson St, St. Paul, Minnesota 55101. Email: [matthew.w.morgan@healthpartner.com](mailto:matthew.w.morgan@healthpartner.com).

*Conflicts of Interest:* By the CPC-EM article submission agreement, all authors are required to disclose all affiliations, funding sources and financial or management relationships that could be perceived as potential sources of bias. The authors disclosed none.

*Copyright:* © 2021 Morgan. This is an open access article distributed in accordance with the terms of the Creative Commons Attribution (CC BY 4.0) License. See: <http://creativecommons.org/licenses/by/4.0/>

## REFERENCES

1. Scaggs T, Glass D, Hutchcraft M. Prehospital ketamine is a safe and effective treatment for excited delirium in a community hospital based EMS system. *Prehosp Disaster Med.* 2016;31(5):563-9.
2. Esposito S, Miller A, Rajon R. Complications of otitis media leads to opisthotonos in a toddler. *Am J Emerg Med.* 2020;38(6):1296.e5-1296.e7.
3. Pachaly J and Werner P. Restraint of the paca (Agouti paca) with ketamine hydrochloride, acetylpromazine maleate, atropine sulfate. *J Zoo Wildlife Med.* 1998;29(3):303-6.
4. Das S and von Landeghan F. Clinicopathological spectrum of bilirubin encephalopathy/kernicterus. *Diagnostics.* 2019;9(1):24.
5. Manjunatha N and Mehta U. Recurrent opisthotonos in catatonia: an atypical presentation. *Indian J Med Sci.* 2009;63(11):512-6.
6. Schime I and Tallant E. Tetanus-like reactions to prochlorperazine. Report of eight cases exhibiting extrapyramidal disturbances after small doses. *JAMA.* 1959;171(13):1813-7.
7. Walder B, Trampler M, Margritte S. Seizure-like phenomena and propofol. *Neurology.* 2002;58(9):1327-32.
8. Ferguson M and Vance M. Payment deferred: strychnine poisoning in Nicaragua 65 years ago. *J Toxicol Clin Toxicol.* 200AD;38(1):71-77.
9. Liden C, Lovejoy F, Costello C. Phencyclidine: nine cases of poisoning. *JAMA.* 1975;243(5):513-6.
10. Kokkinou M, Ashok A, Howes O. The effects of ketamine on dopaminergic function: meta analysis and review of the implications for neuropsychiatric disorders. *Mol Psychiatr.* 2018;23:59-69.
11. Sleigh J and Denny B. Ketamine: more mechanisms of action than just NMDA blockade. *Anaesth and Crit Care.* 2014;4(2):76-81.
12. Cornett E, Novitch M, Kaye A. Medication-induced tardive dyskinesia: a review and update. *Ochsner J.* 2017;17(20):162-74.
13. Asser A and Taba P. Psychostimulants and movement disorders. *Front Neuro.* 2015;6:75.
14. Lewis K and O'Day C. Dystonic reactions. 2021. Available at: <https://www.ncbi.nlm.nih.gov/books/NBK531466/>. Accessed June 17, 2021.



# A Chemist with a Strange Etiology of Rhabdomyolysis: A Case Report of a Rare Toxicological Emergency

Rajadurai Meenakshisundaram, MBBS, MD

Joshua Vijay Joseph, MBBS, MEM, PG

Prabakaran Perumal, MBBS

Akmal Areeb, MBBS

Prathap Pancheti, MBBS, MD

Dinesh Kannan Sampath, MBBS, MD

Esther Monica Jared, MBBS

Apollo KH Hospital, Department of Emergency Medicine and Critical Care, Melvisharam, Tamil Nadu, India

Section Editor: Steven Walsh, MD

Submission History: Submitted April 23, 2021; Revision received July 3, 2021; Accepted July 14, 2021

Electronically published September 9, 2021

Full text available through open access at [http://escholarship.org/uc/uciem\\_cpem](http://escholarship.org/uc/uciem_cpem)

DOI: 10.5811/cpcem.2021.7.52923

**Introduction:** Chloroform, a halogenated hydrocarbon, causes central nervous depression, hepatotoxicity, nephrotoxicity, and rhabdomyolysis. Historically, chloroform had been used as a general anaesthetic and today is still used in chemical industries. Lack of proper personal protective equipment and adequate knowledge about its toxic effects can lead to serious harm.

**Case report:** A 33-year-old gentleman presented to the emergency department (ED) with altered mental status. Given his depressed mental status, the decision was made to intubate shortly after arrival for airway protection. Further history raised suspicion of occupational chloroform exposure. Brown-colored urine further strengthened suspicion of chloroform poisoning with resultant rhabdomyolysis. Forced alkaline diuresis and N-acetylcysteine were started in the ED. His mental status and respiratory efforts improved on hospital day two, and he was ultimately extubated. Creatine phosphokinase and myoglobin levels were initially high but gradually came down by hospital day six. On hospital day 10, the patient was deemed stable and safely discharged.

**Conclusion:** A patient with chloroform inhalation who suffered resultant rhabdomyolysis and hepatotoxicity was successfully treated with early initiation of forced alkaline diuresis, N-acetylcysteine, and hemodialysis. [Clin Pract Cases Emerg Med. 2021;5(4):432-435.]

**Keywords:** chloroform; poisoning; rhabdomyolysis; N-acetylcysteine.

---

## INTRODUCTION

Chloroform, or trichloromethane (CHCl<sub>3</sub>), is a colorless, volatile liquid with a pleasant ethereal odor. Although no longer used as an anaesthetic, chloroform is still used in industrial applications as an intermediate in chemical syntheses. Available human data on acute chloroform exposure are from older studies that tested various exposure regimens (680-7200 parts per million for 3-30 minutes); effects reported included detection of strong odor, headaches, dizziness, and vertigo.<sup>1</sup> We describe an early identification and successful outcome of inadvertent chloroform inhalation in a chemist with rhabdomyolysis and hepatic injury.

## CASE REPORT

A 33-year-old gentleman presented to the emergency department (ED) with altered mental status. Given his depressed mental status, the decision was made to intubate shortly after arrival for airway protection. Further history revealed that the patient had been working overnight in a chemical factory and returned home in the morning. Since his return, he had complaints of headache and giddiness. After about two hours, he began vomiting and then became unconscious. A focused history was obtained from relatives regarding the possibility of drug overdose or poisoning. Later in his evaluation, the medical

team was able to contact a colleague from the chemical factory who revealed the patient had been working with high density chloroform all night in his role as a senior scientist with expertise in re-refining lubricants and oils, as well as reverse engineering of customized products. This raised suspicion of occupational high-density chloroform exposure as the cause of the patient's presentation. Brown-colored urine further strengthened the suspicion of chloroform poisoning with resultant rhabdomyolysis. Forced alkaline diuresis (FAD) was initiated within an hour of arrival to the ED, as is customary at our institution, via a multidisciplinary approach with the nephrology and internal medicine services.

The urine alkalinisation by FAD was performed as follows: 500 millilitres (mL) 0.9% normal saline over one hour(hr), followed by 50 milliequivalents (mEq) sodium bicarbonate in 5% dextrose 500 mL over one hr, 20 mEq potassium chloride in 500 mL 0.9% normal saline over one hr, followed by furosemide 40 milligrams (mg) intravenous (IV). This cycle was repeated for the next five days with a target urine pH above 8. The patient was also treated with IV-administered N-acetylcysteine (NAC) 150 mg per kilogram (kg) over one hr, followed by 50 mg/kg over 4 hr, and then was started on an IV infusion at a rate of 6.25 mg/kg/hr. Early dialysis was planned for renal protection and to remove dialyzable compounds; two cycles of ultrafiltration were given on consecutive days. His mental status and respiratory efforts improved on hospital day two, and he was able to be extubated. He confirmed the occupational exposure to high-density chloroform while working in the laboratory, as well as his symptoms of headache and giddiness since then.

His blood work was significant for elevated transaminases and hyperbilirubinemia (Table). Other significant events of his hospital course included QTc interval prolongation noted on hospital day two, without any accompanying cardiac dysrhythmias. Creatine phosphokinase and myoglobin levels were initially high but downtrended by hospital day six. After 10 days in the hospital the patient was able to be safely discharged home. While measurement of blood levels of chloroform was considered, this test was not available at his treatment facility. On follow-up, the patient was clinically asymptomatic and all investigations were within normal limits. The patient was counseled about proper protective equipment for the workplace to avoid further dangerous occupational exposure. The timeline of management is shown in Figure.

## DISCUSSION

In the past, chloroform was used as an inhalational anaesthetic. Today it is used in chemical industries.<sup>1</sup> Chloroform toxicity in the modern day is relatively uncommon; the most recent literature is from about 30 years ago. The most common way that humans are exposed to chloroform is through inhalation; however, poisonings through ingestion have also been recorded.<sup>2</sup> When chloroform was used as an inhalational anaesthetic, the delayed effects observed included drowsiness,

*CPC-EM Capsule*

What do we already know about this clinical entity?  
*Rhabdomyolysis secondary to toxins is managed by forced alkaline diuresis to prevent renal failure.*

What makes this presentation of disease reportable?  
*Rhabdomyolysis is a rare entity presenting to the emergency department after inhalation of chloroform.*

What is the major learning point?  
*Occupational exposure should be considered in patients presenting with unknown poison. Timely management of rhabdomyolysis and chloroform toxicity will improve outcomes.*

How might this improve emergency medicine practice?  
*Early recognition and initiation of management based on occupational exposure should be considered in the emergency department..*

restlessness, vomiting, fever, tachycardia, jaundice, liver enlargement, abdominal tenderness, abnormal liver and kidney function, delirium, and coma. Chloroform may increase cardiac sensitivity to epinephrine, increasing the risk for arrhythmias. Some studies have found that chloroform may also cause injury to red cell membranes, clotting defects, and rhabdomyolysis.<sup>3</sup>

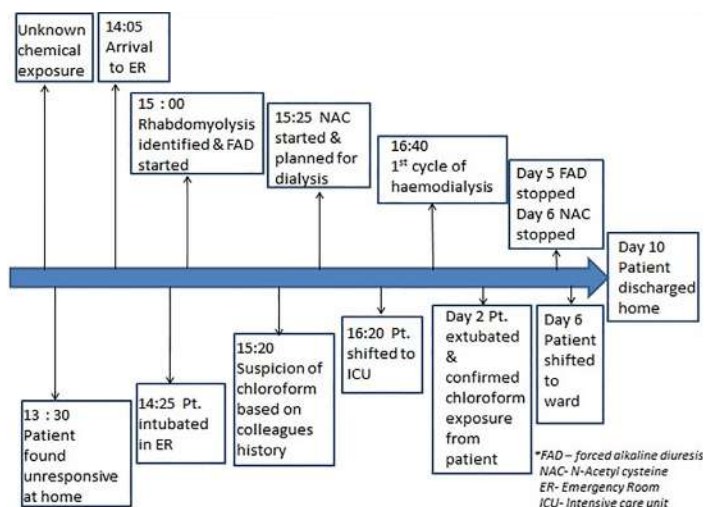
Cytochrome P450 2E1-mediated oxidation plays a major role in chloroform toxicity.<sup>4</sup> The utilization of NAC for chloroform-induced hepatotoxicity has demonstrated successful outcomes in cases with mild hepatotoxicity. The pathophysiology behind this is thought to be that as chloroform causes hepatic damage through free radical injury, NAC may combat this by replenishing glutathione and scavenging free radicals, ultimately decreasing hepatic injury secondary to chloroform exposure.<sup>5</sup>

Rhabdomyolysis is a rapid dissolution of skeletal muscle, which leads to release of electrolytes and intracellular muscle components (such as myoglobin, creatine phosphokinase, aldolase, and lactate dehydrogenase) into the bloodstream and extracellular space. Fluid repletion is important to prevent prerenal azotemia. This repletion is provided with 500 mL/hr saline solution alternated every hour with 500 mL/hr of 5%

**Table.** Laboratory parameters in a patient with chloroform toxicity.

| Day of admission                        | Normal range   | 1 <sup>st</sup> | 3 <sup>rd</sup> | 5 <sup>th</sup> | 8 <sup>th</sup> | 10 <sup>th</sup><br>(discharged) | Follow-up<br>(4 weeks) |
|---|----------------|-----------------|-----------------|-----------------|-----------------|----------------------------------|------------------------|
| Haemoglobin (g/dL)                      | 12-15          | 13.8            | 14.0            | 13.8            | 12.2            | 12.6                             | 12.2                   |
| Total counts (cells/mm <sup>3</sup> )   | 4000-11000     | 15260           | 16780           | 14700           | 11020           | 10640                            | 8100                   |
| Platelet count (cells/mm <sup>3</sup> ) | 150000-450000  | 324000          | 246000          | 208000          | 228000          | 258000                           | 394000                 |
| Urea (mg/dL)                            | 17-43          | 17              | 17              | 14              | 23              | 20                               | 13                     |
| Creatinine (mg/dL)                      | 0.7-1.2        | 1.2             | 1.1             | 0.9             | 1.1             | 1.1                              | 0.8                    |
| Total bilirubin (mg/dL)                 | 0.1-1.2        | 0.6             | 3.4             | 6.2             | 3.8             | 2.2                              | 0.4                    |
| Direct/Indirect (mg/dL)                 | 0.2/0.4        | 0.2/0.4         | 0.8/2.6         | 2.7/3.5         | 2.5/1.3         | 1.2/1.0                          | 0.1/0.3                |
| SGOT/SGPT (IU/L)                        | 10-50/10-50    | 39/28           | 426/104         | 398/688         | 204/599         | 108/298                          | 76/102                 |
| Sodium/ Potassium (mEq/L)               | 135-145/ 3.5-5 | 139/4.3         | 135/3.0         | 132/3.7         | 128/3.2         | 132/3.4                          | 138/3.2                |
| Serum Calcium (mg/dL)                   | 9-11           | 7.9             | 7.5             | 7.5             | 8.5             | 8.6                              | 8.8                    |
| Serum Phosphorus (mg/dL)                | 3-4.5          | 1.9             | 1.4             | 2.4             | 2.2             | 2.4                              | 2.8                    |
| PT/INR (sec)                            | 13-15/1        | 15/1            | 27/1.9          | 24/1.67         | 20/1.3          | 20/1.1                           | 17/1.1                 |
| CPK (IU/L)                              | 0-195          | 20390           | 34040           | 11830           | 1500            | 634                              | 184                    |
| Serum myoglobin (ng/mL)                 | 25-80          | 5895            | -               | 517             | 214             | -                                | -                      |
| Urine myoglobin (ng/mL)                 | <5             | 2625            | -               | -               | -               | -                                | -                      |
| LDH (IU/L)                              | 140-280        | 480             | 1118            | 605             | 273             | -                                | 128                    |
| ECG QTc interval (ms)                   | 431-450        | 413             | 511             | 466             | 423             | 415                              | 410                    |

SGOT, serum glutamic oxaloacetic transaminase; SGPT, serum glutamic pyruvic transaminase; PT, prothrombin time; INR, international normalised ratio; CPK, creatine phosphokinase; LDH, lactate dehydrogenase; ECG, electrocardiography; g/dL, grams per decilitre; mm<sup>3</sup>, cubic millimetres; mg/dL, milligrams per decilitre; ng/mL, nanograms per millilitre; IU/L, international units per litre; ms, milliseconds.



**Figure.** Timeline of our management of patient with chloroform toxicity. ER, emergency room; Pt, patient; NAC, N-acetyl cysteine; ICU, intensive care unit; FAD, forced alkaline diuresis.

glucose solution with 50 millimoles of sodium bicarbonate for each subsequent 2-3 L of solution. A urinary output goal of 200 mL/hr, urine pH greater than 6.5, and plasma pH greater than 7.5 are reasonable targets.<sup>6</sup>

## CONCLUSION

This case report describes a young man who was found to have rhabdomyolysis and hepatic injury after he presented with an uncommon chemical poisoning. He was successfully managed with general measures, N-acetylcysteine administration, forced alkaline diuresis, and dialysis support. High clinical suspicion and focussed history based on occupational exposure were helpful in identifying the compound and initiating appropriate early management.

Patient consent has been obtained and filed for the publication of this case report.

**Address for Correspondence:** Rajadurai Meenakshisundaram, MBBS, MD, FEM, Apollo KH Hospital, Department of Emergency Medicine and Critical Care, Ranipet, Vellore – Chennai Road, Melvisharam, Tamil Nadu, India 632509. Email: [drmrajadurai@gmail.com](mailto:drmrajadurai@gmail.com).

**Conflicts of Interest:** By the CPC-EM article submission agreement, all authors are required to disclose all affiliations, funding sources and financial or management relationships that could be perceived as potential sources of bias. The authors disclosed none.

**Copyright:** © 2021 Meenakshisundaram. This is an open access article distributed in accordance with the terms of the

Creative Commons Attribution (CC BY 4.0) License. See: <http://creativecommons.org/licenses/by/4.0/>

---

## REFERENCES

1. Lionte C. Lethal complications after poisoning with chloroform: case report and literature review. *Hum Exp Toxicol.* 2010;29(7):615-22.
2. Schroeder HG. Acute and delayed chloroform poisoning. *BJA Br J Anaesth.* 1965;37(12):972-5.
3. Sridhar N, Krishnakishore C, Sandeep Y, et al. Chloroform poisoning: a case report. *Ren Fail.* 2011;33(10):1037-9.
4. PubChem. Chloroform. Available at: <https://pubchem.ncbi.nlm.nih.gov/compound/6212>. Accessed April 14, 2021
5. Flanagan RJ and Meredith TJ. Use of N-acetylcysteine in clinical toxicology. *Am J Med.* 1001;91(3C):131S-139S.
6. Criddle LM. Rhabdomyolysis pathophysiology, recognition, and management. *Crit Care Nurse.* 2003;23(6):14-30.



# A Case Report of Acute Prostatitis Secondary to Use of P-valve Condom Catheter During Cave Diving

Ashley Barash, DO<sup>\*,†</sup>  
Evan Stern, MD<sup>\*,†</sup>  
Robyn Hoelle, MD<sup>\*,†</sup>

<sup>\*</sup>North Florida Regional Medical Center, Department of Graduate Medical Education, Gainesville, Florida  
<sup>†</sup>UCF/HCA Healthcare GME Consortium of North Florida, Department of Emergency Medicine, Gainesville, Florida

Section Editor: Manish Amin, DO

Submission History: Submitted March 31, 2021; Revision received July 15, 2021; Accepted July 16, 2021

Electronically published September 9, 2021

Full text available through open access at [http://escholarship.org/uc/uciem\\_cpem](http://escholarship.org/uc/uciem_cpem)

DOI: 10.5811/cpem.2021.7.52639

**Introduction:** Acute bacterial prostatitis is characterized by acute inflammation of the prostate gland accompanied by the presence of pain and other urinary tract or systemic symptoms. Prostatitis is a relatively common disease of the urinary tract in men. However, this case reports a man diagnosed with acute bacterial prostatitis with an unusual presentation, as well as an unusual pathogen and a unique mechanism of colonization.

**Case Report:** A 52-year-old male with no past medical history presented to our facility for right-sided buttock pain associated with dysuria, diarrhea, and perianal burning. The patient was diagnosed with sepsis secondary to acute bacterial prostatitis, and the pathogen identified in his urine was *Aeromonas hydrophila/A. caviae*. His disease process was later recognized as a complication of the use of a P-valve condom catheter while freshwater cave diving.

**Conclusion:** This is the first documented case of prostatitis as a result of the use of a P-valve condom catheter while diving. Furthermore, the pathogen identified is of particular interest as there are very few documented cases of urosepsis secondary to *Aeromonas hydrophila* or *A. caviae*. [Clin Pract Cases Emerg Med. 2021;5(4):436-439.]

**Keywords:** case report; acute bacterial prostatitis; cave diving; *Aeromonas*.

## INTRODUCTION

Prostatitis is the third most common urinary tract disease in men. Acute bacterial prostatitis is characterized by acute inflammation of the prostate gland accompanied by the presence of pain and urinary tract symptoms. It most commonly occurs in men in two predominant groups: those 20-40 years old and those >70. The most common pathogen identified in acute bacterial prostatitis is *Escherichia Coli*; however, *Neisseria gonorrhoea* and *Chlamydia trachomatis* need to be considered in those who are sexually active.<sup>1</sup> While prostatitis is a relatively common disease of the urinary tract, this case report of a man with acute bacterial prostatitis is anything but ordinary. We describe a 52-year-old male with an unusual presentation diagnosed with acute bacterial prostatitis colonized from a condom catheter that he used while cave diving in freshwater.

## CASE REPORT

A 52-year-old male with no past medical history presented to our emergency department (ED) for right-sided buttock pain that started in the middle of the night. He also described dysuria, which progressed to perianal burning associated with an episode of diarrhea and right-sided buttock pain. His pain was severe in nature, waxing and waning and non-radiating. The patient reported freshwater cave diving in north-central Florida 15 hours prior to onset of symptoms. He reported diving to a depth of 100 feet with a slow ascent. He experienced no adverse symptoms and reported feeling normal prior to going to bed the night before.

On initial examination, the patient was tachycardic with a heart rate of 109 beats per minute. Remaining vital signs were within normal limits, including a temperature of 37.1° Celsius.

He appeared in distress secondary to pain. His skin was pale and diaphoretic. His abdominal exam was benign without tenderness to palpation, rebound or guarding. There was tenderness to palpation over the right buttock approximately halfway between the posterior superior iliac spine and ischial tuberosity. No obvious wounds or traumatic injuries were present, and there was no erythema, warmth or swelling to indicate cellulitis or abscess. Repeat vital signs approximately 3.5 hours after initial evaluation remained unchanged with the exception of a rising temperature to 37.9°C.

Labs in the ED were significant for white blood cell count (WBC) of 22.7 thousand per millimeter<sup>3</sup> (K/mm<sup>3</sup>) (reference 4.5-11 K/mm<sup>3</sup>) and lactic acid of 4.8 millimoles per liter (mmol/L) (0.4-2.0 mmol/L). Blood urea nitrogen (BUN) was 16 milligrams per deciliter (mg/dL) (7-18 mg/dL), and creatinine (Cr) was 1.32 mg/dL (0.60-1.30 mg/dL). Urinalysis was significant for small protein mg/dL (reference: negative); small ketones mg/dL (reference: negative); large leukocyte esterase (reference: negative); too numerous to count per high power field (HPF) WBCs (reference: 0-5 per HPF); 30-40 per HPF red blood cells; and moderate hemoglobin (reference: negative).

Computed tomography of the abdomen and pelvis was obtained given concern for abdominal, pelvic or lumbar etiology of the pain and demonstrated “hazy inflammation involving the prostate, rectosigmoid colon and seminal vesicles, which likely represents a prostatitis with possibly associated proctitis. The seminal vesicles also appear inflamed.” The patient received a 30 milliliter per kilogram (mL/kg) normal saline fluid bolus and intravenous cefepime. He was admitted to the inpatient service for continued treatment of sepsis likely secondary to prostatitis/colitis. Urology was consulted as an inpatient.

On day one of hospitalization, he developed acute urinary retention requiring Foley catheter placement. Prostate-specific antigen returned elevated at 8.36 nanograms per milliliter (ng/mL) (reference 0.0–4.4 ng/mL) and urine cultures grew *Aeromonas hydrophila/A caviae*. Urine culture was unable to provide further speciation distinguish between *Aeromonas hydrophila* and *A caviae*. Cefepime was continued for four days based on antibiotic sensitivities with significant clinical improvement. The Foley catheter was removed on day three and the patient was able to void successfully. His WBC count improved to 5.9 K/mm<sup>3</sup>, BUN was 7 mg/dL, and Cr was 0.92 mg/dL. He was discharged on day four with ciprofloxacin 500 milligrams (mg) twice a day for two weeks.

## DISCUSSION

This is a case where a patient presented with a chief complaint of “right buttock pain.” Acute bacterial prostatitis can present with a variety of clinical symptoms to include urinary symptoms, suprapubic, rectal or perianal pain, painful ejaculation, hematospermia, and painful defecation. It often also presents with systemic symptoms such as fever, chills, nausea, emesis, and malaise. While this patient did mention

### *CPC-EM Capsule*

What do we already know about this clinical entity?

*Acute bacterial prostatitis is characterized by acute inflammation of the prostate gland accompanied by localized pain and urinary tract symptoms.*

What makes this presentation of disease reportable?

*We describe a patient diagnosed with acute bacterial prostatitis after use of a condom catheter during underwater cave diving, with an aquatic pathogenic bacteria, Aeromonas Hydrophila.*

What is the major learning point?

*When external water flows in a retrograde fashion into the tubing of a P-valve condom-catheter, divers are at risk of urinary tract infection.*

How might this improve emergency medicine practice?

*Understanding the mechanism of anaerobic bacteria colonization and specific pathogens for which cave divers are at risk will help guide management in the emergency department.*

an episode of dysuria associated with perianal burning, his primary complaint was pain located in the right buttock. The physical examination findings for prostatitis can vary but often include an enlarged, tender, or boggy prostate. There may also be abdominal distention indicative of a distended bladder secondary to obstructive pathology.<sup>2</sup>

This patient’s physical exam was remarkable primarily for tenderness to palpation in the right gluteal region. There are several possibilities as to why the pain localized to this region. One theory is based on information regarding pain associated with chronic nonbacterial prostatitis/chronic pelvic pain syndrome (or Type III prostatitis). Chronic pelvic pain syndrome (CPPS) is described as a pain, pressure or discomfort in the pelvic region, perineum or genitalia that occurs in the absence of bacteria. The pain associated with CPPS is often multifactorial and involves more than one body system. There is evidence of a mechanical relationship between various structures within these anatomical regions; for example, thoracolumbar dysfunction is known to have referred pain into the testicular region. While CPPS occurs in the absence of uropathogenic bacteria, it is possible that

acute bacterial prostatitis has similar physical manifestations resulting in a referred pain mechanism to the gluteal region.<sup>3</sup>

While there are several documented cases of urinary tract infections following scuba diving, most documented cases identified the common pathogen as *Pseudomonas aeruginosa*, most likely because the *Pseudomonas* species thrives in both freshwater and saltwater environments.<sup>4</sup> Our patient, however, presented with urosepsis secondary to *Aeromonas*, a Gram-negative bacteria that primarily thrives in aquatic environments. There are 36 species within the genus with 19 identified pathogens in humans. Ninety-five percent of the pathogens identified in humans were identified as only four species: *Aeromonas caviae* (37.26%), *Aeromonas dhakensis* (23.49%), *Aeromonas veronii* (21.54%), and *Aeromonas hydrophila* (13.07%). In humans, *Aeromonas* has primarily been identified in cases of gastroenteritis, bacteremia and wound infections, and *A hydrophila*, specifically, which was identified as the source of infection in this case, has been identified more in extra-intestinal infections.<sup>5,6</sup>

Examples of urosepsis secondary to *Aeromonas* are limited and were in association with patients who had undergone a recent prostatic biopsy. In a study that assessed complications of transrectal prostate biopsy, urosepsis occurred in 10 patients of whom only one had positive blood culture for *Aeromonas*.<sup>7</sup> Importantly, *Aeromonas* present in extraintestinal samples had high rates of drug resistance according to one study, including those antibiotics commonly used to treat urinary tract infections.<sup>6</sup> Aside from cases associated with prostate manipulation such as transrectal prostate biopsy, we could identify no cases that report colonization secondary to scuba diving. This case is unique both in terms of the uncommon pathogen and the mechanism of colonization. As mentioned, this patient presented 15 hours after freshwater cave diving. He later revealed that during long cave dives, he uses a P-valve condom catheter to urinate. We suspect that this P-valve condom catheter contributed to his mechanism of colonization.

P-valve condom catheters allow urination outside a dry suit during prolonged dives. There are two types of P-valve systems: balanced and unbalanced. Balanced P-valves have a one-way valve and a balancing chamber that allows air to enter catheter tubing, equalizing the pressure within the tubing equal to the pressure at any given depth. Unbalanced tubes have a manual valve that must be opened to release urine out of the catheter and should be primed prior to descent to prevent squeeze during descent. The unbalanced P-valve system can allow external water to flow in a retrograde fashion into the catheter tubing if the manual valve is left open during the dive or when it is opened to urinate.

Our patient used an unbalanced P-valve system and stated that the valve was open throughout the dive. This in turn allowed a constant retrograde flow of water up through the tubing and into the condom catheter. It is therefore likely that bacterial colonization occurred via this mechanism. Our

literature search failed to demonstrate any other similar cases of prostatitis secondary to use of a P-valve condom catheter. One case report identified a 39-year-old professional diver who suffered recurrent cystitis and nephrolithiasis secondary to a P-valve condom catheter. The report, which identified as a case of cystitis and nephrolithiasis due to *Pseudomonas aeruginosa*, demonstrated a failure in the P-valve allowing constant retrograde flow into the valve.<sup>4</sup>

## CONCLUSION

While acute bacterial prostatitis is a common disease with defined common pathogens, this is the first documented case of prostatitis associated with the use of a P-valve condom catheter while diving. Furthermore, the pathogen identified is of interest as there are very few documented cases of urosepsis secondary to *Aeromonas hydrophila/A caviae*. We describe a unique adverse event associated with cave diving that emergency physicians should be prepared to evaluate, diagnose, and treat.

The authors attest that their institution does not require Institutional Review Board approval for publication of this case report. Documentation on file.

Patient consent has been obtained and filed for the publication of this case report.

---

**Address for Correspondence:** Ashley Barash, DO, c/o Kim Watkins, North Florida Regional Medical Center, Department of Emergency Medicine, 1147 NW 64th Terrace, Gainesville, Florida 32605. Email: abbarash@gmail.com

**Conflicts of Interest:** By the CPC-EM article submission agreement, all authors are required to disclose all affiliations, funding sources and financial or management relationships that could be perceived as potential sources of bias. The authors disclosed none. This research was supported (in whole or in part) by HCA Healthcare and/or an HCA Healthcare affiliated entity. The views expressed in this publication represent those of the author(s) and do not necessarily represent the official views of HCA Healthcare or any of its affiliated entities.

**Copyright:** © 2021 Barash et al. This is an open access article distributed in accordance with the terms of the Creative Commons Attribution (CC BY 4.0) License. See: <http://creativecommons.org/licenses/by/4.0/>

---

## REFERENCES

1. Khan FU, Ihsan AU, Khan HU, et al. Comprehensive overview of prostatitis. *Biomed Pharmacother*. 2017;94:1064-76.
2. Coker T and Dierfeldt D. Acute bacterial prostatitis: diagnosis and management. *Am Fam Physician*. 2016;93(2):114-20.
3. Archambault-Ezenwa L, Markowski A, Barral JP. A comprehensive physical therapy evaluation for male chronic pelvic pain syndrome: a case series exploring common findings. *J Bodyw Mov Ther*.

- 2019;23(4):825-34.
4. Bird VY, Chastain-Gross R, Sutkowski R, et al. *Pseudomonas aeruginosa* as an etiologic agent of nephrolithiasis in deep water divers. *J Endourol Case Rep.* 2017;3(1):4-6.
  5. Fernández-Bravo A and Figueras MJ. An update on the genus *Aeromonas*: taxonomy, epidemiology, and pathogenicity. *Microorganisms.* 2020;8(1):129.
  6. Zhou Y, Yu L, Nan Z, et al. Taxonomy, virulence genes and antimicrobial resistance of *Aeromonas* isolated from extra-intestinal and intestinal infections. *BMC Infect Dis.* 2019;19(1):158.
  7. Carmignani, L., Picozzi, S., Spinelli, M. et al. Bacterial sepsis following prostatic biopsy. *Int Urol Nephrol.* 2021;44(4):1055-63.



# Atypical Presentation of Aseptic Meningitis Due to Varicella Zoster: A Case Report

Sharon Jia, MD  
Thuyvi Luong, MD

WellSpan York Hospital, Department of Emergency Medicine, York, Pennsylvania

Section Editor: Melanie Heniff, MD, JD

Submission History: Submitted June 10, 2021; Revision received July 22, 2021; Accepted July 11, 2021

Electronically published August 31, 2021

Full text available through open access at [http://escholarship.org/uc/uciem\\_cpem](http://escholarship.org/uc/uciem_cpem)

DOI: 10.5811/cpem.2021.7.53596

**Introduction:** Varicella zoster virus (VZV) meningitis is primarily an infection of the immunocompromised. However, it can also affect immunocompetent individuals. Reactivation of VZV typically presents with a distinct dermatomal rash suggestive of varicella zoster, but there have also been reports of VZV meningitis presenting without a rash.

**Case Report:** We describe a case of VZV meningitis in a healthy, 30-year-old male presenting to the emergency department shortly after receiving his first coronavirus disease 2019 vaccination. He was treated with intravenous acyclovir and then discharged home on oral valacyclovir.

**Conclusion:** Emergency physicians should consider aseptic meningitis in immunocompetent patients presenting with atypical headaches in this population. [Clin Pract Cases Emerg Med. 2021;5(4):440-442.]

**Keywords:** case report; varicella; meningitis; COVID; headache.

## INTRODUCTION

Varicella zoster virus (VZV) is part of the herpesvirus family. Initial infection causes varicella, also known as chickenpox. The virus becomes latent within the cranial nerve, dorsal root, and autonomic ganglia. Reactivation of the virus can occur as a result of decreased T cell-mediated immunity, typically causing a dermatomal vesicular rash.<sup>1</sup> Major risk factors include age greater than 50, hematopoietic stem cell or organ transplant, autoimmune disease, and human immunodeficiency virus (HIV) infection. Complications of VZV reactivation include postherpetic neuralgia, herpes zoster ophthalmicus, VZV vasculopathy, and aseptic meningitis.<sup>2</sup> Here we present an atypical case of VZV meningitis in an immunocompetent, 30-year-old male presenting to the emergency department following a recent coronavirus disease 2019 (COVID-19) vaccination.

## CASE REPORT

A 30-year-old, previously healthy male presented to the emergency department with a three-day history of a persistent, throbbing headache. He described the headache as worse in the morning upon awakening and exacerbated by

bending over, lying down, and sneezing. The patient reported headaches in the past, but this episode had not responded to ibuprofen as usual. He denied any medical history aside from a diagnosis of Lyme disease approximately 10 years prior. This was treated with a full course of doxycycline and yielded no further complications. He had received his first COVID-19 vaccination 12 days prior to presentation, but otherwise had only taken daily ibuprofen since the onset of his headache. He denied sick contacts, recent travel, and tobacco or drug use history. Review of systems was negative for fever, changes in vision, photophobia, chest pain, shortness of breath, nausea, vomiting, diarrhea, rashes, or recent traumas.

His vital signs were within normal limits. On physical exam, pupils were equal, round, and reactive to light. The patient had no focal neurologic deficits. Cranial nerves II-XII, sensation, motor strength, speech, and coordination were intact. His neck was supple with full range of motion and no rigidity. There were no rashes or skin lesions.

Complete blood count and basic metabolic panel were unremarkable. A non-contrast computed tomography of the head revealed no evidence of acute intracranial hemorrhage

or midline shift, mass, or intra-axial or extra-axial fluid collection. A lumbar puncture was performed and was significant for opening pressure of 29 centimeters (cm) water (reference range: 6-25 cm water). Cerebrospinal fluid was significant for 706 white blood cells/microliter (WBC/uL) (reference range 0-5 WBC/uL), with 95% lymphocytes; 4 red blood cells (RBC)/uL (0 RBC/uL); protein of 144 milligrams/deciliter (mg/dL) (15-45 mg/dL), and glucose 52 mg/dL (40-70 mg/dL). The polymerase chain reaction (PCR) meningitis/encephalitis panel detected VZV. The patient was empirically started on intravenous (IV) vancomycin, ceftriaxone, dexamethasone, and acyclovir. Further questioning revealed that the patient had chickenpox as a child.

The patient was hospitalized and continued treatment with high-dose IV acyclovir (10 mg/kilogram every eight hours). Blood cultures and testing for Lyme disease and HIV returned negative. After a 48-hour hospitalization, the patient requested discharge, and the infectious disease service recommended switching the patient from IV acyclovir to a 10-day course of valacyclovir (1000 mg every eight hours). The patient's headache had resolved prior to discharge, and he was recommended to follow-up with his primary care provider (PCP). Unfortunately, we reviewed the chart a month afterward, and the patient had not followed up with his PCP.

## DISCUSSION

Varicella zoster virus reactivation causes a variety of neurologic complications including acute retinal necrosis, herpes zoster ophthalmicus, and aseptic meningitis. Advanced age and immunocompromised states are considered major risk factors for the development of herpes zoster and other manifestations of VZV reactivation. The most common presentations are a dermatomal rash and neuritis. Complications of VZV include postherpetic neuralgia and aseptic meningitis.<sup>3</sup> The latter typically presents with symptoms such as headache, photophobia, nausea, and vomiting. Varicella zoster virus meningitis is rare in the young, healthy population, and other cases have been reported in the absence of the typical herpes zoster rash.<sup>4</sup>

Although rare, vaccines have also been associated with reactivation of VZV. This has been reported in patients who received vaccinations for hepatitis A, influenza, rabies, and Japanese encephalitis.<sup>5</sup> Varicella zoster virus reactivation has also been seen in association with the COVID-19 vaccine, described in two cases of elderly patients diagnosed with herpes zoster within a week after receiving their vaccinations.<sup>6,7</sup>

Varicella zoster virus can be diagnosed clinically with the presence of a dermatomal rash. It can also be diagnosed in the laboratory by using PCR to analyze vesicular skin material and cerebrospinal fluid.<sup>8</sup> According to Infectious Diseases Society of America guidelines, IV acyclovir is the drug of choice to treat VZV meningoencephalitis.<sup>9</sup> Ganciclovir can be an alternative agent.<sup>9</sup> However, IV acyclovir is not always well tolerated and has been associated with increased risk of neurotoxicity.

### *CPC-EM Capsule*

What do we already know about this clinical entity?

*Reactivation of varicella zoster virus (VZV) can cause meningitis, and typically affects older and immunocompromised patients and presents with a rash.*

What makes this presentation of disease reportable?

*Our case describes an uncommon presentation of aseptic meningitis secondary to VZV in a healthy, young adult without a rash.*

What is the major learning point?

*It is important to consider aseptic meningitis on the differential when evaluating a patient who presents with an atypical headache.*

How might this improve emergency medicine practice?

*Because VZV meningitis is rarely seen in the immunocompetent population, this case report adds additional information for a better understanding of VZV.*

Whereas oral acyclovir is limited by its bioavailability, oral valacyclovir is converted to acyclovir in vivo and has a three- to five-fold increase in acyclovir bioavailability.<sup>10</sup> Oral valacyclovir provides therapeutic cerebrospinal-fluid acyclovir levels and inhibits most VZV strains.<sup>11,12</sup>

Case reports have described successfully treating patients for VZV meningitis with IV acyclovir and transitioning to oral valacyclovir.<sup>13</sup> However, oral valacyclovir by itself does not appear to be a suitable agent as herpes zoster can progress to meningitis despite oral valacyclovir.<sup>15</sup> After an appropriate dose of IV acyclovir, valacyclovir can be a suitable option for treating minimally symptomatic patients in the outpatient setting, such as the young man in this case report.

## CONCLUSION

While rare, aseptic meningitis secondary to VZV can occur in young, healthy, immunocompetent patients and can present without a rash. Emergency physicians should consider this diagnosis for atypical headaches in this population. Once the diagnosis is made, it would be prudent to initiate IV acyclovir and have the inpatient team determine whether to transition to oral valacyclovir.

The Institutional Review Board approval has been documented and filed for publication of this case report.

*Address for Correspondence:* Sharon Jia, MD, WellSpan York Hospital, Department of Emergency Medicine, 1001 S George Street, York, Pennsylvania 17403. Email: [sjia@wellspan.org](mailto:sjia@wellspan.org).

*Conflicts of Interest:* By the CPC-EM article submission agreement, all authors are required to disclose all affiliations, funding sources and financial or management relationships that could be perceived as potential sources of bias. The authors disclosed none.

*Copyright:* © 2021 Jia. This is an open access article distributed in accordance with the terms of the Creative Commons Attribution (CC BY 4.0) License. See: <http://creativecommons.org/licenses/by/4.0/>

## REFERENCES

- Mueller NH, Gilden DH, Cohrs RJ, et al. Varicella zoster virus infection: clinical features, molecular pathogenesis of disease, and latency. *Neurol Clin*. 2008;26(3):675-97.
- Yawn BP, Saddier P, Wollan PC, et al. A population-based study of the incidence and complication rates of herpes zoster before zoster vaccine. *Mayo Clin Proc*. 2007;82(11):1341-9.
- Nagel MA and Gilden D. Complications of varicella zoster virus reactivation. *Curr Treat Options Neurol*. 2013;15(4):439-53.
- Fadhel M, Campbell N, Patel S, et al. Varicella zoster meningitis with hypoglycorrhachia on cerebrospinal fluid (CSF) analysis in a young immunocompetent host without a rash. *Am J Case Rep*. 2019;20:701-4.
- Walter R, Hartmann K, Fleisch F, et al. Reactivation of herpesvirus infections after vaccinations? *Lancet*. 1999;353(9155):810.
- Eid E, Abdullah L, Kurban M, et al. Herpes zoster emergence following mRNA COVID-19 vaccine. *J Med Virol*. 2021;93(9):5231-2.
- Bostan E and Yalici-Armagan B. Herpes zoster following inactivated COVID-19 vaccine: a coexistence or coincidence? *J Cosmet Dermatol*. 2021;20(6):1566-7.
- Gershon AA, Breuer J, Cohen JL, et al. Varicella zoster virus infection. *Nat Rev Dis Primers*. 2015;1:15016.
- Tunkel AR, Glaser CA, Bloch KC, et al. The management of encephalitis: clinical practice guidelines by the Infectious Diseases Society of America. *Clin Infect Dis*. 2008;47(3):303-27.
- Beutner KR, Friedman DJ, Forszpaniak C, et al. Valaciclovir compared with acyclovir for improved therapy for herpes zoster in immunocompetent adults. *Antimicrob Agents Chemother*. 1995;39(7):1546-53.
- Cunha BA and Baron J. The pharmacokinetic basis of oral valacyclovir treatment of herpes simplex virus (HSV) or varicella zoster virus (VZV) meningitis, meningoencephalitis or encephalitis in adults. *J Chemother*. 2017;29(2):122-5.
- Lycke J, Malmeström C, Ståhle L. Acyclovir levels in serum and cerebrospinal fluid after oral administration of valacyclovir. *Antimicrob Agents Chemother*. 2003;47(8):2438-41.
- Gnoni M, Zaheer K, Vasser MM, et al. Varicella zoster aseptic meningitis: report of an atypical case in an immunocompetent patient treated with oral valacyclovir. *IDCases*. 2018;13:e00446.
- Bateman R and Naples R. Herpes zoster meningitis in a young, immunocompetent adult. *J Emerg Med*. 2021;60(5):e99-e101.

# Bilateral Acute Angle-Closure Glaucoma: A Case Report of an Unusual Cause of Acute Headache in a Child

Breelan Kear, MD\*  
Claudia R. Gold, MD†  
Rahul Bhola, MD, MBA†

\*Providence St. Joseph Hospital Orange, Department of Emergency Medicine, Orange, California  
†CHOC Children's Hospital, Department of Pediatric Emergency Medicine, Orange, California

Section Editor: Anna McFarlin, MD

Submission History: Submitted April 2, 2021; Revision received July 18, 2021; Accepted July 26, 2021

Electronically published September 9, 2021

Full text available through open access at [http://escholarship.org/uc/uciem\\_cpem](http://escholarship.org/uc/uciem_cpem)

DOI: 10.5811/cpcem.2021.7.52671

**Introduction:** Acute angle-closure glaucoma (AACG) is typically considered a disease of adulthood. However, AACG may occasionally be seen in children. The clinical presentation is similar to adults, including headache, vomiting, and eye pain. However, the etiology of angle closure in children is different and most often associated with congenital anterior segment abnormalities. A precipitating factor of AACG in children with previous established, anterior segment abnormalities is eye dilation, which may occur during routine ophthalmological examination with topical mydriasis, or physiologic mydriasis upon entering a dark room.

**Case Report:** We describe a 5-year-old child with a history of severe prematurity and retinopathy of prematurity (ROP) presenting with bilateral AACG following a routine outpatient, dilated ophthalmological examination. While angle-closure glaucoma has previously been reported in cases of ROP, a bilateral acute attack of AACG following pupil dilation in regressed ROP has hitherto been unreported.

**Conclusion:** Given the association of ROP and AACG, it can be expected that as the survival rate of premature infants improves, the incidence of ROP and AACG may also increase. It is therefore prudent for the emergency physician to have AACG on the differential for pediatric patients with headache and eye pain. [Clin Pract Cases Emerg Med. 2021;5(4):443-446.]

**Keywords:** *pediatrics; acute angle closure glaucoma; retinopathy of prematurity; case report.*

## INTRODUCTION

Glaucoma is a leading cause of preventable blindness in the United States.<sup>1</sup> The typical age demographic of glaucoma is older adults, peaking between ages 55-70.<sup>2</sup> However, acute angle-closure glaucoma (AACG) can occur in any age group, particularly in those individuals with an anatomical predisposition that promotes angle closure.<sup>3</sup> Retinopathy of prematurity (ROP) and eye dilation are known risk factors for developing AACG in childhood.<sup>2-5</sup> Retinopathy of prematurity is most common in infants with a gestational age of fewer than 30 weeks.<sup>2</sup> In pediatric patients, the clinical presentation of headache, vomiting, and eye pain may initially prompt one to consider non-accidental head trauma, migraine, infection, or intracranial mass in the differential. However, when evaluating these patients it is prudent for the emergency physician to

be aware of the possibility of AACG, particularly in those patients with a history of severe prematurity. Given the advances in neonatology leading to higher survival rates in premature infants, there is now an increased incidence of ROP. This may potentially lead to more cases of pediatric AACG in the future.<sup>5</sup>

## CASE REPORT

This case describes headache, eye pain, and vomiting in a pediatric patient due to bilateral AACG. A 5-year-old boy with a history of extreme prematurity (23 weeks' gestation), presented to the emergency department (ED) with his mother, reporting three days of bilateral eye pain with photophobia, headache, vomiting, and warmth to touch. She noted increased tearing but denied nasal congestion, runny nose, cough,



earache, or sore throat. There was no known exposure to infectious disease, nor any known head or eye injury. There was no home temperature measured.

The patient's past medical history was significant for global development delay, chronic lung disease, epilepsy, strabismus, and severe ROP. He had received laser treatment for retinopathy in infancy and successful strabismus surgery eight months prior to the ED visit. Four days previously, he had been evaluated in the ophthalmology clinic for his regular comprehensive ophthalmological exam. His eyes were dilated at that time as per prior routine (using cyclogyl, tropicamide, and phenylephrine spray) to facilitate dilated fundus exam. No other procedures were performed during that visit, and the ophthalmological exam was stable from prior examinations.

In the ED he was observed to be in significant distress. He was alert, agitated, and uncooperative with examination attempts. Vital signs were normal. There was no evidence of head or facial trauma. Topical proparacaine was used to help facilitate an eye exam; however, he tightly clenched his eyes and vigorously resisted all attempts to open them. Upon limited inspection, he had bilateral conjunctival injection without discharge or hemorrhage. His pupils were midsize and minimally reactive. His corneas appeared cloudy with no obvious abrasions or ulcerations. The remainder of the physical exam was unremarkable, and his mother confirmed he was at baseline neurological status.

The differential diagnosis following limited eye examination included acute iritis, keratitis, and AACG. There was minimal suspicion for infection, corneal abrasions, or ulcerations. We quickly recognized that a more thorough examination with procedural sedation would be required. An ophthalmology consultation was requested immediately. The patient was successfully sedated with intravenous (IV) ketamine. Under sedation, evaluation revealed bilateral corneal haziness, 2+ conjunctival injection, and both centrally and peripherally shallow anterior chambers. Intraocular pressures (IOP) were measured at 44 millimeters of mercury (mm Hg) (reference range: 12-22 mm Hg) oculus sinister (OS), and unrecordable oculus dexter (OD). The OD globe was significantly hardened on digital palpation. All findings pointed to the diagnosis of bilateral AACG.

Topical timolol/dorzolamide drops and IV acetazolamide were administered immediately following ophthalmology examination. Over the next two hours serial pressure measurements were taken with the tonometer and eyedrops were continued by the ophthalmologist in the ED. The patient was more sedated and therefore more cooperative with these serial exams. Intravenous mannitol was added. With this medical regimen, IOPs decreased from 44 mm Hg to 28 mm Hg OS and decreased from unmeasurable to 40 mm Hg OD. The patient was then admitted for observation and scheduled for surgical iridectomies in the morning.

Bromidine drops were ordered on admission. Upon re-evaluation the next morning, he remained in considerable discomfort, though pressures at that time were found to be much lower; 30 mm Hg OD, 14 mm Hg OS.

### *CPC-EM Capsule*

What do we already know about this clinical entity?

*Acute angle closure glaucoma (AACG) is a common cause of blindness and eye pain in adults. However, it can also occur in children.*

What makes this presentation of disease reportable?

*The report describes a rare case of bilateral AACG in a child with a history of retinopathy of prematurity after a routine dilated fundoscopic exam.*

What is the major learning point?

*AACG can occur in children. Risk factors for AACG in children include retinopathy of prematurity, pupil dilation during fundoscopic examination, and certain systemic medications.*

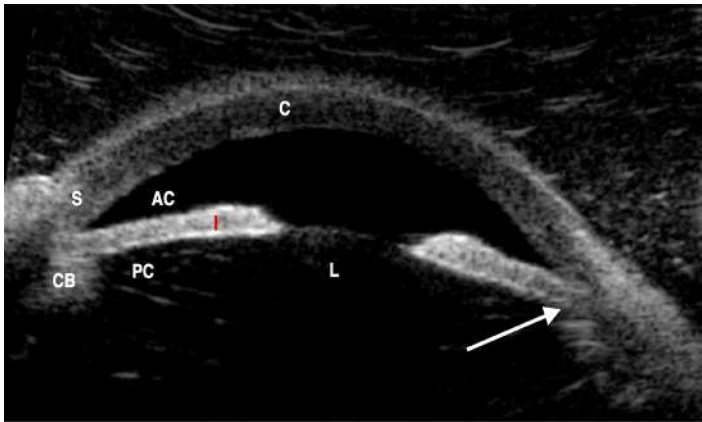
How might this improve emergency medicine practice?

*It is important to keep AACG on the differential for children with headache, eye pain, and vision loss, especially in formerly premature infants where retinopathy of prematurity is common.*

Plans were initiated for more thorough examination under anesthesia, including gonioscopy and B-scan ultrasonography, followed by peripheral iridectomy of the right eye, and possibly the left. The ultrasound biomicroscopy of the right eye, obtained by the ophthalmologist under anesthesia, demonstrates the anterior iris insertion with anteriorly positioned ciliary body that predisposed the patient to AACG (Image). The patient was successfully treated with peripheral right iridectomy and discharged home post surgery without complications. He returned the following day for outpatient left peripheral iridectomy, which was also successful. His progress has been followed in ophthalmology clinic and he continues to do well. No further mydriatic drops have been used to facilitate examinations.

### **DISCUSSION**

Acute angle-closure glaucoma occurs when the angle of the anterior chamber of the eye is reduced and the trabecular meshwork of the iris is blocked, leading to an obstruction of the aqueous humor out of the anterior chamber.<sup>3,6</sup> This leads to elevated IOP, causing severe pain and visual compromise,



**Image.** Ultrasound biomicroscopy of right eye showing anterior iris insertion with anteriorly positioned ciliary body (arrow). The anterior chamber (AC), ciliary body (CB), cornea (C), iris (I), lens (L), posterior chamber (PC), and sclera (S) are annotated.

which can lead to blindness if left untreated.<sup>6</sup> Shallow anterior chamber, farsightedness, and eyes with lens abnormalities are more susceptible to AACG.<sup>6</sup> Retinopathy of prematurity is thought to be a risk factor, possibly due to the anatomical anterior displacement of the lens-iris diaphragm that effectively creates a shallow anterior chamber.<sup>2,4,5</sup> An acute attack of glaucoma can be caused by pupillary dilation (such as entering into a dark room) or, as in the case of our patient, pharmacologic mydriasis during an eye exam.<sup>5-7</sup>

Although the clinical presentation of AACG in children is similar to adults, it is much more difficult to diagnose. This is primarily due to the limited ability of a young child to communicate history and cooperate with a thorough examination. In pediatric patients it may be necessary to both examine and treat the eye under procedural sedation, as occurred in our case.<sup>5</sup> We used ketamine for sedation as it was the most routinely used in our pediatric ED. It is worth noting that ketamine has been thought to increase IOP; however, the evidence for this is poor.<sup>8-10</sup> More recent small studies have measured IOPs of patients with non-ophthalmologic injuries undergoing procedural sedation with ketamine. These studies suggest that there is no increase in IOP or that the increase is negligible.<sup>8-10</sup> However, until larger studies are performed it would have been reasonable to use another medication during sedation that is not theoretically associated with increased IOP.

The classic findings of AACG are unilateral eye redness with a non-reactive, mid-dilated pupil, as well as corneal haziness and high IOP. Patients usually have significant eye pain, vision changes, headache, nausea, and vomiting.<sup>6</sup> The vast majority of AACG affects only one eye. It is exceedingly rare to have bilateral AACG.<sup>11</sup> Only one other case report of bilateral AACG from pharmacologic mydriasis has been described in a three-year-old child, who similarly presented with AACG four days following a dilated eye examination.<sup>7</sup> Pediatric bilateral AACG has also been reported as a result of systemic medications such as lisdexamphetamine dimesylate,<sup>12</sup> carbamazepine,<sup>13</sup> and topiramate,<sup>14</sup> although this is still exceedingly rare.<sup>12-14</sup>

The immediate management of AACG includes decreasing aqueous humor production. This is achieved through the use of ophthalmic timolol drops, a non-selective beta blocker, as well as IV acetazolamide, a carbonic anhydrase inhibitor. In severe cases, IV mannitol also may be used to create an osmotic gradient between the blood and the vitreous to lower vitreous volume.<sup>6,15</sup> An alpha-adrenergic agonist, such as apraclonidine or bromidine drops, is used to decrease aqueous production.<sup>15</sup> Miotic drops, such as pilocarpine, are sometimes used to reopen the angle. These are thought to be ineffective at very high pressures (above 40-50 mm HG) and are sometimes reserved for use once the pressure improves.<sup>6,15</sup> Ultimately, the treatment is iridotomy by an ophthalmologist.

## CONCLUSION

Although acute angle-closure glaucoma is typically considered a disease of older adults, we describe a case of bilateral AACG in a 5-year-old male. This case highlights the importance of keeping AACG on the differential in pediatric patients who present with headache, eye pain, and vomiting. Risk factors include a history of retinopathy of prematurity or recent pharmacological eye dilation. The physical exam findings are paramount in the diagnosis. Sedation may be required to adequately examine the eye, which could inhibit prompt diagnosis. However, early recognition and treatment of AACG in pediatric patients will prevent vision loss.

Patient consent has been obtained and filed for the publication of this case report. The authors attest that their institution does not require Institutional Review Board approval for publication of this case report. Documentation on file.

**Address for Correspondence:** Breelan Kear, MD, Providence St. Joseph Hospital Orange, Department of Emergency Medicine, 1310 W Steward Drive #212, Orange, California 92686. Email: bkear@emsoc.net.

**Conflicts of Interest:** By the CPC-EM article submission agreement, all authors are required to disclose all affiliations, funding sources and financial or management relationships that could be perceived as potential sources of bias. The authors disclosed none.

**Copyright:** © 2021 Kear. This is an open access article distributed in accordance with the terms of the Creative Commons Attribution (CC BY 4.0) License. See: <http://creativecommons.org/licenses/by/4.0/>

## REFERENCES

1. Patel KH, Javitt JC, Tielsch JM, et al. Incidence of acute angle-closure glaucoma after pharmacologic mydriasis. *Am J Ophthalmol.* 1995;120(6):709-17.
2. Ritch R, Chang BM, Liebmann JM. Angle closure in younger patients. *Ophthalmology.* 2003;110(10):1880-9.
3. Ferreira NP, Pinto JM, Pinto F, et al. Angle closure as a cause for intermittent headache in a child. *BMJ Case Rep.* 2017;2017:bcr2017219517.

4. Bremer DL, Rogers DL, Good WV, et al. Glaucoma in the Early Treatment for Retinopathy of Prematurity (ETROP) study. *J AAPOS*. 2012;16(5):449-52.
5. Wu SC, Lee YS, Wu WC, et al. Acute angle-closure glaucoma in retinopathy of prematurity following pupil dilation. *BMC Ophthalmol*. 2015;15:96.
6. Bhatia K and Sharma R. 2013. Eye emergencies. In: J. Adams, E. Barton, J. Collins and P. DeBlieux (Eds.). *Emergency Medicine Clinical Essentials*, 2nd ed (209-211). Philadelphia: Elsevier.
7. Low S, Harsum S, Chang L, et al. Angle-closure. *Ophthalmology*. 2008;115(8):1434-5.
8. Wadia S, Bhole R, Lorenz D, et al. Ketamine and intraocular pressure in children. *Ann Emerg Med*. 2014;64(4):385-8.
9. Drayna PC, Estrada C, Wang W, et al. Ketamine sedation is not associated with clinically meaningful elevation of intraocular pressure. *Am J Emerg Med*. 2012;30(7):1215-8.
10. Halstead SM, Deakyne SJ, Bajaj L, et al. The effect of ketamine on intraocular pressure in pediatric patients during procedural sedation. *Acad Emerg Med*. 2012;19(10):1145-50.
11. Kaushik S, Sachdev N, Pandav SS, et al. Bilateral acute angle closure glaucoma as a presentation of isolated microspherophakia in an adult: case report. *BMC Ophthalmol*. 2006;6:29.
12. Davanian AM, Fitzpatrick JC, Tran DP, et al. Bilateral acute angle closure in a pediatric patient taking lisdexamfetamine dimesylate (Vyvanse). *J Glaucoma*. 2021;30(5):e259-e261.
13. Karuppannasamy D, Andavar R, Arumugam J, et al. DRESS syndrome secondary to carbamazepine therapy presenting with bilateral acute anterior uveitis and angle closure glaucoma. *J Ophthalmic Vis Res*. 2019;14(3):382-6.
14. Rapoport Y, Benegas N, Kuchtey RW, et al. Acute myopia and angle closure glaucoma from topiramate in a seven-year-old: a case report and review of the literature. *BMC Pediatr*. 2014;14:96.
15. Jackson J, Carr LW, Fisch BM, et al. Care of the patient with primary angle closure glaucoma. *Optometry*. 1994:18-29.

# Didelphys Uterus in Pregnancy, an Uncommon Mullerian Duct Anomaly: A Case Report

Colin Jorgensen, MD  
Monika Lusiak, MD

AMITA Health Resurrection Medical Center, Department of Emergency Medicine,  
Chicago, Illinois

Section Editor: Shadi Lahham, MD

Submission History: Submitted May 13, 2021; Revision received July 20, 2021; Accepted July 26, 2021

Electronically published October 19, 2021

Full text available through open access at [http://escholarship.org/uc/uciem\\_cpem](http://escholarship.org/uc/uciem_cpem)

DOI: 10.5811/cpcem.2021.7.53212

**Introduction:** Didelphys uterus, or “double uterus,” is one of the rarest Müllerian duct anomalies (MDA). Due to its rarity, data are sparse on overall outcomes associated with this congenital defect, but it may be associated with several complications, both pregnancy and non-pregnancy related.

**Case Report:** In this case, a pregnant 35-year-old female with vaginal bleeding was subsequently diagnosed with uterus didelphys by transvaginal ultrasound imaging.

**Conclusion:** Despite its rarity, clinicians should be aware of MDAs and their associated complications with pregnancy. [Clin Pract Cases Emerg Med. 2021;5(4):447-449.]

**Keywords:** *didelphys uterus; Mullerian duct anomalies.*

## INTRODUCTION

Müllerian duct anomalies (MDA) are a spectrum of congenital defects arising from the failure of fusion of the Müllerian ducts at 12-16 weeks' embryologic development. Sources vary on incidence of these abnormalities; MDAs range between 0.5-5% of the general population.<sup>1</sup> There are several classification systems of MDAs; the most widely accepted is a modified version of the initial system characterized by the American Fertility Society. Didelphys uterus (MDA class III) accounts for approximately 5% of all MDAs<sup>2</sup> and arises from the complete non-fusion of both Müllerian ducts, resulting with two distinct cervixes.<sup>3</sup>

Didelphys uterus is associated with increased rates of infertility in comparison to normal uterine anatomy, as well as dysmenorrhea or dyspareunia. Additionally, it is characterized with Herlyn-Werner-Wunderlich syndrome, a rare disorder associated with obstructed hemivagina and ipsilateral renal agenesis. Despite its rarity, the emergency physician should be aware of didelphys uterus in the patient who presents with gynecologic and obstetric complaints.

## CASE REPORT

A 35-year-old female gravida two, para one, at approximately eight weeks estimated gestational age (EGA) by last menstrual period presented to the emergency department (ED) for vaginal bleeding, abdominal cramping,

and pain. The patient reported some low abdominal cramping beginning 12 hours prior to arrival, associated with bright red vaginal bleeding, which had soaked two tampons. She and her husband presented from the airport after traveling from Europe where she was stationed for military service. Prior to receiving military clearance for travel, she had completed a scheduled medical exam and transvaginal ultrasound with diagnosis of definitive intrauterine pregnancy. Her husband brought a copy of the ultrasound report. Previous delivery records were not available as the patient had given birth outside the United States, but she reported the delivery was term via caesarean section due to breech position. Her previous pregnancy and postpartum period were reportedly otherwise unremarkable. She stated that she had no other obstetric or gynecological history.

The patient's vital signs were within normal limits on arrival and stable throughout her evaluation in the ED. Her exam was notable for midline and left-sided lower abdominal and pelvic tenderness without guarding or rigidity. Her pelvic exam was normal in external appearance and showed blood in the cervical canal with no cervical motion tenderness or cervical dilation. Her laboratory results revealed a beta human chorionic gonadotropin of 13,340 milli-international units per milliliter (mIU/mL) (reference range: 7500-225,000 mIU/mL based on patient's corresponding EGA); rhesus positive; antibody negative; and her hemoglobin was within normal limits.



Transabdominal ultrasound was attempted, but it was difficult to obtain images consistent with visualization of a definitive intrauterine pregnancy. Subsequent transvaginal ultrasound revealed a uterine didelphys configuration with the right uterus containing a gestational sac and yolk sac that corresponded to an EGA of six weeks and two days. There was no fetal pole visualized or fetal cardiac activity. Her left uterus appeared to have a thickened endometrial stripe. (Image 1, 2)

After reviewing the findings with the patient, she did admit that she was told “something” after her first delivery but could not remember what it pertained to. The patient’s initial presentation and localization of pain to the left lower quadrant correlated with her left nongravid uterus that was likely undergoing withdrawal bleeding secondary to changes in hormone levels. During her stay in the her pain improved with two doses of morphine, and she was discharged in stable condition with close obstetrics follow-up and diagnosis of threatened abortion.

On follow-up, the patient stated that she had an otherwise uneventful pregnancy that progressed without further complications or bleeding. We postulate that alternatively to threatened abortion, bleeding may have been a result of progesterone luteal shift and withdrawal bleeding in her nongravid left uterus. In early pregnancy the corpus luteum produces progesterone to sustain a uterine environment suitable for pregnancy. The placenta takes over progesterone production within the first trimester. In the case presented here, that may have been responsible for the lack of progesterone locally within the left uterus and subsequent hormonal withdrawal bleeding as well as left-sided pain on examination.

**DISCUSSION**

As noted, didelphys uterus is an uncommon MDA, accounting for approximately 5% of cases. It is often

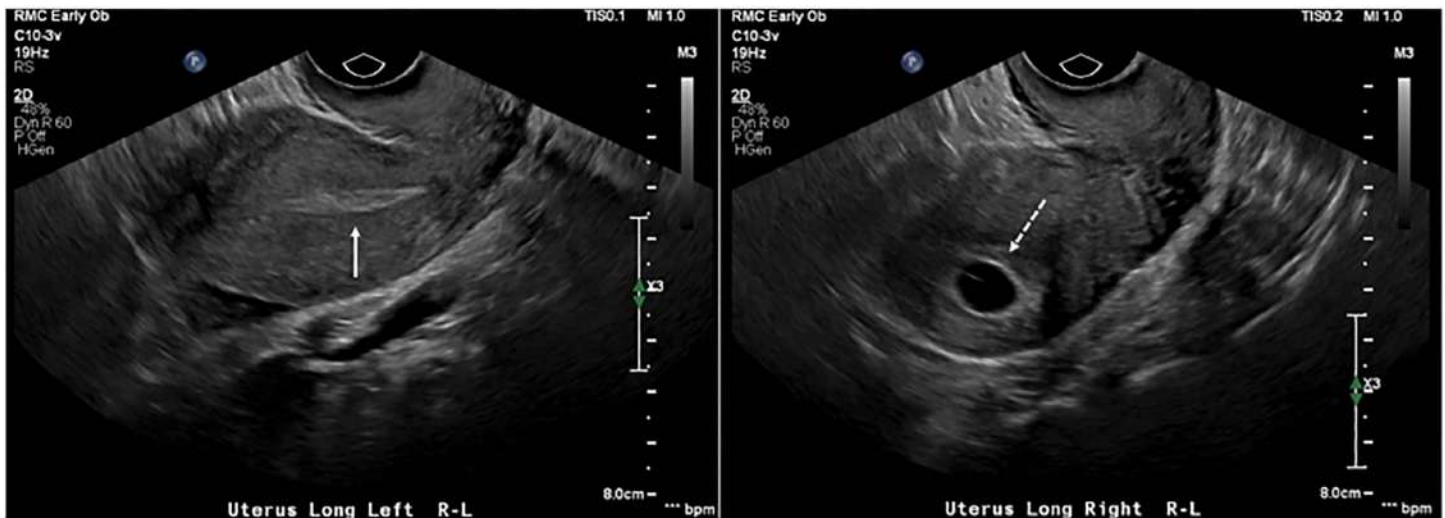
*CPC-EM Capsule*

What do we already know about this clinical entity?  
*Didelphys uterus is a rare Mullerian duct anomaly (MDA) which is associated with dysmenorrhea, dyspareunia, increased infertility rates, and fetal growth restriction.*

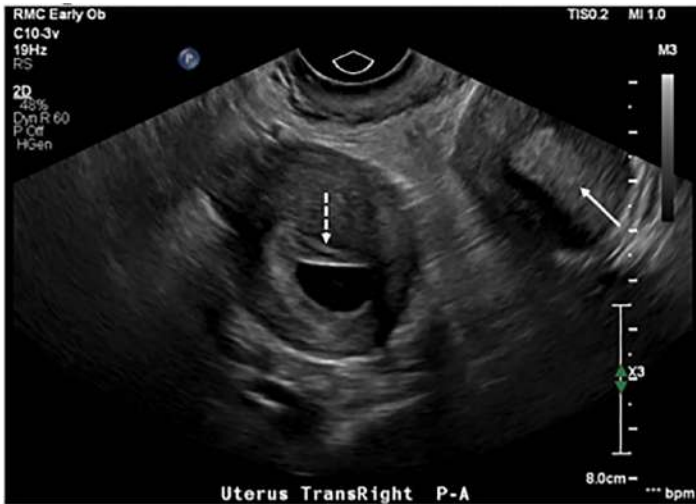What makes this presentation of disease reportable?  
*This is a rarely documented case of first trimester vaginal bleeding in a patient with Didelphys uterus configuration.*

What is the major learning point?  
*Pregnant women with MDAs should have close obstetric follow-up and be educated on increased rates of pregnancy-related complications.*

How might this improve emergency medicine practice?  
*Despite their rarity, early recognition of MDAs may better define patient’s complaints when presenting to the Emergency Department.*



**Image 1.** Transvaginal ultrasound. Longitudinal views of the uterus demonstrate uterus didelphys configuration with the absence of gestational sac in the left uterus (solid continuous arrow, left) and the presence of a gestational sac in the right uterus (interrupted arrow, right).



**Image 2.** Transvaginal ultrasound. Transverse views of the uterus demonstrate uterus didelphys with both the right uterus (interrupted arrow) with gestation sac present and adjacent left uterus (solid arrow) with absence of gestation sac.

asymptomatic, but it may be discovered in association with both pregnancy- and non-pregnancy related complaints. Often diagnosed with menarche as well as with onset of sexual activity, the presence of a vaginal septation may be associated with dysmenorrhea or dyspareunia. The incidence of vaginal septation is estimated at 70%,<sup>4</sup> although it was not present in this case. While exceedingly rare, Herlyn-Werner-Wunderlich syndrome is another MDA variant, which is characterized by uterine didelphys, obstructing hemivagina, and ipsilateral renal agenesis. Previous case reports have documented pediatric patients presenting to the ED with symptoms of severe abdominal pain, likely associated with dysmenorrhea with the onset of menstruation and obstructed hemivaginal septa.<sup>5,6</sup> It is a worthwhile consideration for differential diagnosis in pediatric patients with abnormal physical examination findings such as a blind vagina and perhaps renal agenesis on initial point-of-care ultrasound for abdominal pain.

In cases of pregnancy, there are increased rates of infertility associated with uterus didelphys.<sup>1</sup> It has also been associated with a nearly 33% miscarriage rate and 30% preterm delivery rate.<sup>7</sup> Additionally, didelphys uterus is associated with fetal growth restriction.<sup>8</sup> Generally, surgical management of didelphys uterus is not indicated, nor is there an indication for primary cesarean section.<sup>9</sup>

## CONCLUSION

Müllerian duct anomalies are seen in approximately 0.5% of the general population. Didelphys uterus is among the rarest of these anomalies. Didelphys uterus can be associated with

dysmenorrhea or dyspareunia particularly in the setting of vaginal septation. Despite their rarity, it is important for the emergency physician to be mindful of MDAs, including didelphys uterus, as they are associated with increased rates of infertility and pregnancy complications.

The authors attest that their institution requires neither Institutional Review Board approval nor patient consent for publication of this case report. Documentation on file.

**Address for Correspondence:** Colin Jorgensen, MD, AMITA Health Resurrection Medical Center, Emergency Medicine Residency Program, 7435 W Talcott Avenue, Chicago, Illinois 60631. Email: [colin.t.jorgensen@gmail.com](mailto:colin.t.jorgensen@gmail.com).

**Conflicts of Interest:** By the CPC-EM article submission agreement, all authors are required to disclose all affiliations, funding sources and financial or management relationships that could be perceived as potential sources of bias. The authors disclosed none.

**Copyright:** © 2021 Jorgensen. This is an open access article distributed in accordance with the terms of the Creative Commons Attribution (CC BY 4.0) License. See: <http://creativecommons.org/licenses/by/4.0/>

## REFERENCES

1. Rezaei S, Bisram P, Alcantara IL, et al. Didelphys uterus: a case report and review of the literature. *Case Rep Obstet Gynecol.* 2015;2015:865821.
2. Jolpin JD and Heilbrun M. Imaging of Müllerian duct anomalies. *Top Magn Reson Imaging.* 2010;21(4):225-35.
3. Chandler TM, Machan LS, Cooperberg PL, et al. Müllerian duct anomalies: from diagnosis to intervention. *Br J Radiol.* 2009;82(984):1034-42.
4. Smith BC, Brown DL, Carter RE, et al. Double cervix: clarifying a diagnostic dilemma. *Am J Obstet Gynecol.* 2014;211(1):26.e1-5.
5. Karaca L, Pirimoglu B, Bayraktutan U, et al. Herlyn-Werner-Wunderlich syndrome: a very rare urogenital anomaly in a teenage girl. *J Emerg Med.* 2015;48(3):e73-5.
6. Tridenti G, Armanetti M, Flisi M, et al. Uterus didelphys with an obstructed hemivagina and ipsilateral renal agenesis in teenagers: report of three cases. *Am J Obstet Gynecol.* 1988;159(4):882-3.
7. Grimbizis GF, Camus M, Tarlatzis BC, et al. Clinical implications of uterine malformations and hysteroscopic treatment results. *Hum Reprod Update.* 2001;7(2):161-74.
8. Venetis CA, Papadopoulos SP, Campo R, et al. Clinical implications of congenital uterine anomalies: a meta-analysis of comparative studies. *RBM Online.* 2014;29(6):665-83.
9. Lin PC, Bhatnagar KP, Nettleton GS, et al. Female genital anomalies affecting reproduction. *Fertil Steril.* 2002;78(5):899-915.

# An Uncommon Presentation of Cryptococcal Meningitis in an Immunocompetent Patient: A Case Report

Kelly Correa, MD\*  
Scott Craver, DO†  
Amar Sandhu, BS‡

\*Henry Ford Wyandotte Hospital, Department of Emergency Medicine and Graduate Medical Education, Wyandotte, Michigan

†Ascension St. Vincent Indianapolis Hospital, Department of Emergency Medicine, Indianapolis, Indiana

‡Henry Ford Wyandotte Hospital, Department of Emergency Medicine, Wyandotte, Michigan

Section Editor: Rachel Lindor, MD, JD

Submission History: Submitted May 24, 2021; Revision received July 27, 2021; Accepted August 2, 2021

Electronically published October 12, 2021

Full text available through open access at [http://escholarship.org/uc/uciem\\_cpsem](http://escholarship.org/uc/uciem_cpsem)

DOI: 10.5811/cpcem.2021.8.53368

**Introduction:** Meningitis is a serious and potentially life-threatening infection of the central nervous system. *Cryptococcus neoformans* is a rare fungal cause of meningitis that commonly presents with atypical symptoms. Although this infection is most common in immunocompromised patients, it also occurs in immunocompetent patients. This case report describes an atypical presentation of cryptococcal meningitis in a seemingly immunocompetent patient.

**Case Report:** A 40-year-old immunocompetent patient with no significant past medical history had visited the emergency department (ED) five times within a span of 30 days reporting dental pain and headache. Throughout each of the visits, no clear symptoms signaling the need for a meningitis workup were observed, as the patient had been afebrile, displayed no nuchal rigidity, and his presenting symptoms subsided within the ED after treatment. A lumbar puncture was performed after emergency medical services brought the patient in for his sixth ED visit, initially for stroke-like symptoms and altered mental status. Spinal fluid was indicative of cryptococcal meningitis.

**Conclusion:** This case highlights the challenge of identifying cryptococcal meningitis in the ED, particularly in immunocompetent patients who do not display classic meningitis symptoms. It also highlights the importance of keeping a broad differential and carefully ruling out diagnoses when patients return to the ED multiple times for the same complaint. [Clin Pract Cases Emerg Med. 2021;5(4):450–454.]

**Keywords:** case report; immunocompetent; cryptococcal meningitis; altered mental status; headache.

## INTRODUCTION

*Cryptococcus neoformans* (*C. neoformans*) mediated meningitis is a common opportunistic infection in immunocompromised patients, many of whom are positive for human immunodeficiency virus (HIV).<sup>1</sup> Other susceptible individuals include those undergoing cancer treatment or taking immunosuppressive medications for transplants or autoimmune diseases. Pertinent symptoms of cryptococcal meningitis include fever, headache, nuchal rigidity, and new onset altered mental status. If the disease is suspected, the patient should undergo

imaging of the brain (computed tomography or magnetic resonance imaging) and lumbar puncture.<sup>1</sup> The estimated number of hospitalizations for cryptococcal meningitis in the United States (US) is roughly 3,400 cases per year, with 700 deaths annually in both immunocompromised and immunocompetent individuals, indicating a rather high mortality rate.<sup>2</sup> Almost 22% of cryptococcal meningitis hospitalizations in the US in 2009 were in individuals without HIV.<sup>3</sup>

While the prevalence of cryptococcal meningitis in patients with HIV within the US has been declining, cryptococcal

meningitis in immunocompetent and non-HIV infected patients has been more persistent, accounting for a substantial proportion of all cryptococcal meningitis cases.<sup>4</sup> Identifying the true incidence of cryptococcal meningitis in immunocompetent patients is challenging, since non-HIV infected patients may have a range of levels of immunocompetence. One single-center study stratified patients into HIV-positive, organ transplant recipient, and non-HIV/non-organ transplant groups to better define the immunocompetent population and showed that of 302 cryptococcal meningitis cases, 36% were from the non-HIV/non-organ transplant group, which shows that most cases occurred in patients with a known immunocompromised status.<sup>7</sup>

Interestingly, cryptococcal meningitis has shown higher mortality rate in non-HIV infected individuals than in HIV-infected patients in the US (13.3% and 10.5%, respectively).<sup>3</sup> Clinical presentations can vary, and classic symptoms of meningismus only occur in some patients. Immunocompetent patients may have a longer time from the onset of illness to presentation, a more evident inflammatory response (leading to elevated intracranial pressure), and various comorbidities that may also contribute to poor prognosis.<sup>3,5,6,7</sup>

The purpose of this case report is to illustrate how patients with cryptococcal meningitis may not have the risk factors, patient history, or physical exam findings that are commonly seen in meningitis. Additionally, we emphasize that immunocompetent patients are likely to develop cryptococcal meningitis in the absence of a classic meningitis presentation, thus, the disease should be considered in every patient who presents to the emergency department (ED) with headache, altered mental status, or behavioral change.

## CASE REPORT

A 40-year-old man was brought to the ED by emergency medical services after he was found outdoors displaying an altered mental status, right-sided facial droop, headache, and unsteady gait. On initial evaluation, the patient was drowsy, following commands poorly, and could not answer questions appropriately. His initial Glasgow Coma Scale score was 13 (eye - 3, motor - 4, verbal - 6). Provocative testing revealed inconsistent right-sided ptosis with an otherwise non-focal neurologic exam.

Given this presentation, there was a concern for stroke. The patient underwent computed tomography and computed tomography angiography of the head and neck; both were negative for any evidence of ischemic or hemorrhagic stroke or other abnormalities. During his continued evaluation, he reported a headache, which he described as left temporal pressure with associated dental pain. He reported exacerbation of the headache with light and sound but reported not having had any nausea or vomiting. He conveyed that his headache was consistent with previous migraines, just more severe. He did not report any neck stiffness, fever, or sweats. Medical records showed that the patient had been in the ED five other times in the past 30 days with either headache or dental pain.

### *CPC-EM Capsule*

What do we already know about this clinical entity?  
*Cryptococcal meningitis is a rare form of fungal meningitis that is most common in immunocompromised individuals. It often presents with atypical symptoms and has a high mortality rate.*

What makes this presentation of disease reportable?  
*This case of cryptococcal meningitis in a healthy patient without any identifiable risk factors reviews his atypical presentation, multiple visits, and the symptom that led to diagnosis.*

What is the major learning point?  
*Cryptococcal meningitis can occur in immunocompetent patients. Physicians must have a high suspicion for this disease in patients presenting with change in behavior, and/or headaches.*

How might this improve emergency medicine practice?  
*Knowledge of the possible atypical presentations of cryptococcal meningitis among physicians can lead to earlier diagnosis, treatment, and functional outcome in these patients.*

On one visit the patient reported dental pain, was noted to have poor dentition, and pain was improved after dental block. On another visit the patient reported chronic headaches that were relieved by anti-inflammatory medications. Each of these previous assessments did not reveal any fever, neck stiffness, or altered mental status and thus did not trigger concern for intracranial pathology or meningitis requiring further workup. Each time, after symptomatic improvement with medications given in the ED, the patient was discharged and instructed to follow up with his family medical doctor.

Later in the patient's ED course, a family member arrived and reported that the patient had been mentally decompensating over the previous two weeks. The family member stated that the patient had been acting abnormally, including urinating, and defecating in his bedroom and walking around the house naked. The family member was not aware of the patient having had any recent illness, recent travel, exposure to birds, or having pets at home. The family member reported that the patient worked as a sandblaster and had a sporadic history of marijuana and alcohol use. Given the patient's behavioral change, a lumbar puncture was performed for further investigation.

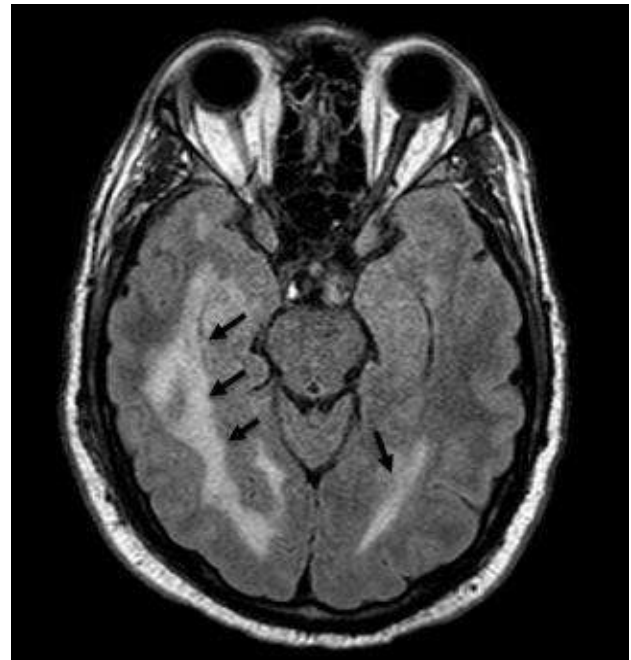


The procedure was performed in the standard fashion, positioned in the left lateral decubitus position. The initial opening pressure was 42 centimeters of water (cmH<sub>2</sub>O) (reference range: 5-25 cmH<sub>2</sub>O). Analysis of cerebrospinal fluid (CSF) from tube four revealed a red blood cell count of 5 millimeters cubed (mm<sup>3</sup>) (reference value: 0 mm<sup>3</sup>), white blood cell count of 178 mm<sup>3</sup> (reference range: 0-5 mm<sup>3</sup>), neutrophils 40% (reference value: 0%), lymphocytes 35% (reference range: 60%-70%), eosinophils 4% (reference value: 0%), protein 100 milligrams per deciliter (mg/dL) (reference range: 15-55 mg/dL), glucose 20 mg/dL (reference range: 40-80 mg/dL) and lactic acid 5.4 millimoles per liter (mmol/L) (reference range: 1.2-2.4 mmol/L). Given the concern for meningitis, the treatment team started the patient on empiric antibiotics (vancomycin 2 grams, ceftriaxone 2 grams, and acyclovir 710mg given parenterally) while the patient was in the ED.

The patient was admitted to the hospital where he was followed by infectious disease specialists and given continued empiric medications as described above. Two days after the initial lumbar puncture, the cryptococcal CSF antigen test returned positive. The patient was then started on amphotericin 450mg parenterally and flucytosine 1750mg orally. Cerebrospinal fluid and blood cultures tested positive for *C. neoformans* on day three. The patient received six therapeutic lumbar punctures during his admission for increased intracranial pressure, as well as eventual placement of a ventriculoperitoneal shunt for persistently elevated intracranial pressure after two months of therapy. A fourth-generation antigen/antibody HIV enzyme-linked immunosorbent assay (ELISA) test during admission was negative. Investigation and workup for other disease processes causing immunosuppression (including cirrhosis, autoimmune disorders, hematologic malignancy, sarcoidosis, previous steroid use, immunosuppressive therapy) were all negative. Further exploration into his alcohol use noted that it was "sporadic" and was thought to be non-contributory. Magnetic resonance imaging done during his hospitalization revealed increased T2/weighted-fluid-attenuated inversion recovery signal representing ventriculitis consistent with cryptococcal meningitis (Image). Hallucinations and odd behaviors were continually noted during the patient's admission, although these symptoms improved gradually. Upon discharge from the hospital, the patient was placed on 1600mg of oral fluconazole daily for three months and then continued maintenance therapy of fluconazole 400mg for 12 months. One year from the patient's initial diagnosis of cryptococcal meningitis, he had some improvement in his cognition and was able to live independently, though he continued to struggle with symptoms of headache despite having a ventriculoperitoneal shunt and was unable to work. He continues to follow with infectious disease to ensure continued remission from cryptococcal meningitis.

## DISCUSSION

The differential diagnosis of headaches and altered mental status is broad and requires thoughtful consideration when



**Image.** Magnetic resonance imaging without contrast. The hyperintense areas (black arrows) in the cerebrum are increased T2/weighted-fluid-attenuated inversion recovery signal representing ventriculitis consistent with cryptococcal meningitis.

narrowing down the etiology of a patient's symptoms. The case presented here illustrates how an otherwise healthy, immunocompetent individual may present with seemingly mild symptoms, such as headache, before more serious symptoms of cryptococcal meningitis develop, such as altered mental status. Our patient's experience highlights the challenge of identifying cryptococcal meningitis in the ED since individuals may not present with obvious signs of meningismus and confirmatory diagnosis via antigen testing takes time and is unlikely to be available while the patient is in the emergency department.

Cryptococcal meningitis is atypical in otherwise immunocompetent patients, with only 0.4 to 1.3 cases per 100,000 people in the United States.<sup>8</sup> Studies have shown that *C. neoformans* uses its many virulence factors and phenotypic plasticity to avoid host macrophages after inhalation from the environment, allowing it to bypass the blood-brain barrier and multiply within a nutrient-depleted environment.<sup>9</sup> There are two leading causes of cryptococcal meningitis infection. The first is a high level of organism exposure, such as exposure to bird excrement where *C. neoformans* are found.<sup>10</sup> The second is immunosuppression from conditions such as HIV, alcoholism, diabetes mellitus, or autoimmune disease.<sup>11</sup>

The current criteria used to evaluate a patient's risk of having cryptococcal meningitis is suboptimal. Meningismus, a classic finding in meningitis, is defined as neck rigidity, photophobia, and headache; however, this constellation of symptoms occurs in less than 20% of patients with

cryptococcal meningitis.<sup>11</sup> Therefore, accurate diagnosis in the ED is challenging. Most patients with cryptococcal meningitis display at least one of the following symptoms: headache, altered mental status, nuchal rigidity, or fever; headache being the most commonly reported symptom.<sup>11,12</sup> When patients who lack the obvious risk factors for cryptococcal meningitis present with vague symptoms or present multiple times with the same symptoms, such as headache in the case of our patient, the physician may mistakenly conclude that the patient has a recurring condition and not an acute pathology. Thus, anchoring bias is a particular barrier to swift and accurate diagnosis of cryptococcal meningitis in otherwise healthy, immunocompetent patients.

Management of cryptococcal meningitis after diagnosis starts with induction therapy to quickly reach sterilization of the CSF and normally includes intravenous combination antifungal therapy with amphotericin B and flucytosine.<sup>13</sup> However, this decision should be made in consultation with an infectious disease specialist. Relieving elevated intracranial pressure via lumbar puncture (or VP shunt) until pressure normalizes is also an important component of treatment for cryptococcal meningitis, due to the significant inflammatory burden.<sup>13,14</sup> A lumbar puncture is typically repeated after two weeks of antifungal induction therapy to confirm sterilization of the CSF, even among patients who have clinically improved.<sup>13</sup> If the CSF is sterile, therapy can be de-escalated to a consolidation dosing range (400mg fluconazole daily). Consolidation and maintenance therapy with fluconazole can proceed for a year or more.<sup>11</sup> Note that specific recommendations vary for specific populations, such as HIV-infected individuals, organ transplant recipients, children, and pregnant women.<sup>14</sup> A comprehensive treatment of cryptococcal meningitis management for ED clinicians can be found in Fisher et al.<sup>5</sup>

Patients with cryptococcal meningitis who are not presenting with classic signs and symptoms of meningitis and who do not have the main risk factors (immunosuppression), often have poor outcomes because diagnosis and treatment are delayed.<sup>11</sup> The most important prognostic factors are the nature of the underlying immunosuppression and the concurrent disease processes. Other factors conferring poor prognosis include positive India ink examination of the CSF, CSF white blood cell count less than 20  $\mu$ L, initial CSF or serum cryptococcal antigen titer greater than 1:32, and high opening pressure on lumbar puncture.<sup>15</sup>

## CONCLUSION

Overall, *C. neoformans* meningitis is a rare cause of meningitis in immunocompetent individuals; however, it is still important to consider in patients with headache and altered mental status given its insidious onset and high mortality rate. A careful and detailed history is warranted for every encounter to evaluate risk factors for serious diseases and narrow the differential diagnoses. Furthermore, when

a patient presents multiple times to the ED with symptoms like headache, it is imperative that clinicians reconsider the differential diagnosis, initiate immediate testing for meningitis-causing microorganisms and begin appropriate supportive care.

*The authors attest that their institution requires neither Institutional Review Board approval, nor patient consent for publication of this case report. Documentation on file.*

*Address for Correspondence:* Kelly Correa, MD, Henry Ford Wyandotte Hospital, Department of Emergency Medicine and Graduate Medical Education, 2333 Biddle Avenue, Wyandotte, Michigan 48192. Email: kcorrea1@hfhs.org.

*Conflicts of Interest:* By the CPC-EM article submission agreement, all authors are required to disclose all affiliations, funding sources and financial or management relationships that could be perceived as potential sources of bias. The authors disclosed none.

*Copyright:* © 2021 Correa et al. This is an open access article distributed in accordance with the terms of the Creative Commons Attribution (CC BY 4.0) License. See: <http://creativecommons.org/licenses/by/4.0/>

## REFERENCES

1. Sloan DJ and Parris V. Cryptococcal meningitis: epidemiology and therapeutic options. *J Clin Epidemiol.* 2014;6:169-82.
2. Rajasingham R, Smith RM, Park BJ, et al. Global burden of disease of HIV-associated cryptococcal meningitis: an updated analysis. *Lancet Infect Dis.* 2017;17(8):873-81.
3. Pyrgos V, Seitz AE, Steiner CA, et al. Epidemiology of cryptococcal meningitis in the US: 1997–2009. *PLoS One.* 2013;8(2):e56269.
4. Pappas PG. Cryptococcal infections in non-HIV-infected patients. *Trans Am Clin Climatol Assoc.* 2013;124:61–79.
5. Fisher KM, Montrieff T, Ramzy M, et al. Cryptococcal meningitis: a review for emergency clinicians. *Intern Emerg Med.* 2021;16(4):1031-42.
6. Lui G, Lee N, Ip M, et al. Cryptococcosis in apparently immunocompetent patients. *QJM.* 2006;99(3):143-51.
7. Brizendine KD, Baddley JW, Pappas PG. Predictors of mortality and differences in clinical features among patients with Cryptococcosis according to immune status. *PLoS One.* 2013;8(3):e60431.
8. Mirza SA, Phelan M, Rimland D, et al. The changing epidemiology of cryptococcosis: an update from population-based active surveillance in 2 large metropolitan areas, 1992-2000. *Clin Infect Dis.* 2003;36(6):789-94.
9. Leopold Wager CM, Hole CR, Wozniak KL, et al. Cryptococcus and phagocytes: complex interactions that influence disease outcome. *Front Microbiol.* 2016;7:105.
10. Soltani M, Bayat M, Hashemi SJ, et al. Isolation of *Cryptococcus*

- neoformans* and other opportunistic fungi from pigeon droppings. *J Res Med Sci.* 2013;18(1):56-60.
11. Poley M, Koubek R, Walsh L, et al. Cryptococcal meningitis in an apparent immunocompetent patient. *J Investig Med High Impact Case Rep.* 2019;7:2324709619834578.
  12. Shih C, Chen Y, Chang S, et al. Cryptococcal meningitis in non-HIV-infected patients. *QJM.* 2000;93(4):245-51
  13. Abassi M, Boulware DR, Rhein J. Cryptococcal meningitis: diagnosis and management update. *Curr Trop Med Rep.* 2015;2(2):90-9.
  14. Perfect JR, Dismukes WE, Dromer F, et al. Clinical practice guidelines for the management of cryptococcal disease: 2010 update by the infectious diseases society of america. *Clin Infect Dis.* 2010;50(3):291-322.
  15. Diamond RD and Bennett JE. Prognostic factors in cryptococcal meningitis. A study in 111 cases. *Ann Intern Med.* 1974;80(2):176-81.

# Small Bowel Volvulus as Delayed Presentation of Undiagnosed Crohn's Disease: A Case Report

Minh Thu T. Nguyen, MD\*

Amir Ali, MD†

Ryan P. Bodkin, MD†

\*University of Rochester Medical Center, Department of Internal Medicine, Rochester, New York

†University of Rochester Medical Center, Department of Emergency Medicine, Rochester, New York

Section Editor: Austin Smith, MD

Submission History: Submitted June 13, 2021; Revision received August 2, 2021; Accepted August 2, 2021

Electronically published October 5, 2021

Full text available through open access at [http://escholarship.org/uc/uciem\\_cpem](http://escholarship.org/uc/uciem_cpem)

DOI: 10.5811/cpem.2021.8.53524

**Introduction:** Emergency department (ED) visits related to flare-ups of inflammatory bowel disease (IBD) are becoming more prevalent. There are many potentially dangerous complications and sequelae of uncontrolled IBD.

**Case Report:** We report a case of a middle-aged woman who presented with a few hours of severe abdominal pain, nausea, and vomiting. Given her hemodynamic instability, she was sent urgently for computed tomography, which showed an incomplete small bowel malrotation, mesenteric volvulus, and high-grade small bowel obstruction with evolving ischemia. The patient underwent exploratory laparotomy to resect most of her small intestines. Biopsies later revealed active Crohn's disease.

**Conclusion:** Patients with flare-ups of IBD are common in the ED, but very few present with a midgut volvulus later in life. Our case is unique and adds to the literature due to the dramatic consequences of undiagnosed Crohn's disease in a patient with intermittent symptoms and extensive workup spanning over two decades. [Clin Pract Cases Emerg Med. 2021;5(4):455-458.]

**Keywords:** *volvulus; small bowel obstruction; mesenteric ischemia; Crohn's disease; case report.*

## INTRODUCTION

Abdominal pain is a common complaint in the emergency department (ED). Abdominal pain associated with flare-ups of inflammatory bowel disease (IBD) is an important consideration in the right clinical context. In 2014, 137,946 ED visits in the United States were attributed to IBD, a significant increase from the 90,846 visits in 2006.<sup>1</sup> With the rising prevalence of IBD-related visits, emergency physicians should become familiar with the dangerous complications of IBD, including fistula formation, intra-abdominal abscesses, bowel perforation, and small bowel obstruction (SBO).<sup>2</sup> Approximately 3-7% of SBOs are secondary to Crohn's disease.<sup>3</sup> Volvulus with concomitant SBO as a consequence of stricturing Crohn's disease is an even rarer entity, with very few cases reported in the literature.<sup>4-6</sup> We describe a case of acute midgut volvulus as a delayed presentation of undiagnosed Crohn's disease.

## CASE REPORT

A 38-year-old woman presented to the ED after a few hours of sudden-onset severe abdominal pain, accompanied by bloating, nausea, vomiting, and diaphoresis. She reported having a bowel movement shortly before her symptoms started and had otherwise been in her normal state of health. Upon the first examination, she appeared cold, clammy, and pale, with a moderately distended abdomen that was diffusely tender to touch without peritoneal signs. Initial vitals showed a blood pressure of 90/65 millimeters mercury, respiratory rate 40 breaths per minute, heart rate 93 beats per minute, temperature 34.1° degree Celsius, and oxygen saturation 100% on room air. The patient recalled dealing with intermittent abdominal pain and bloating for the prior two decades without a clear answer despite multiple evaluations. She was previously diagnosed with abdominal migraines, irritable bowel syndrome (IBS), small intestinal bacterial



overgrowth, and gluten sensitivity. Prior workup included upper and lower endoscopies, small bowel follow-through, and magnetic resonance enterography. Her most recent imaging demonstrated numerous, dilated segments of small bowel without prominent inflammation. The patient had been scheduled for a video capsule endoscopy a year prior but could not complete the procedure due to loss of insurance and employment during the coronavirus disease 2019 pandemic.

Preliminary laboratory data was remarkable for white blood cell count of 11,000 per cubic milliliter (K/uL) (reference range: 4.2 - 9.1 K/uL); hemoglobin of 17.3 milligrams per deciliter (mg/dL) (13.7 - 17.5 mg/dL); C-reactive protein of <3 mg per liter (mg/L) (0 - 8 mg/L); erythrocyte sedimentation rate of 3 millimeters per hour (mm/hr) (0 - 20 mm/hr); lactate of 8.7 millimoles per liter (mmol/L) (0.5 - 2.2 mmol/L); arterial blood gas with pH 7.10 (7.35 - 7.45); and bicarbonate of 16 mmol/L (21 - 26 mmol/L). Given the severity of lactic acidosis and progressive hypotension, aggressive intravenous (IV) crystalloid fluid resuscitation was started, totaling 7 liters. Urgent computed tomography (CT) with IV contrast revealed incomplete small bowel malrotation, mesenteric volvulus at the level of small bowel transition, and a high-grade SBO with two transition points (loops dilated up to 9 centimeters [cm] in diameter) (Image 1 and 2). In addition, there was engorgement of the superior mesenteric venous vasculature and associated mesenteric edema, suspicious for evolving bowel ischemia.

The patient was pan-cultured, decompressed with a nasogastric tube, and received empiric broad coverage for

### CPC-EM Capsule

What do we already know about this clinical entity?

*Inflammatory bowel disease flare-ups are common, with known complications of uncontrolled abdominal pain, abscess formation, or intestinal perforation.*

What makes this presentation of disease reportable?

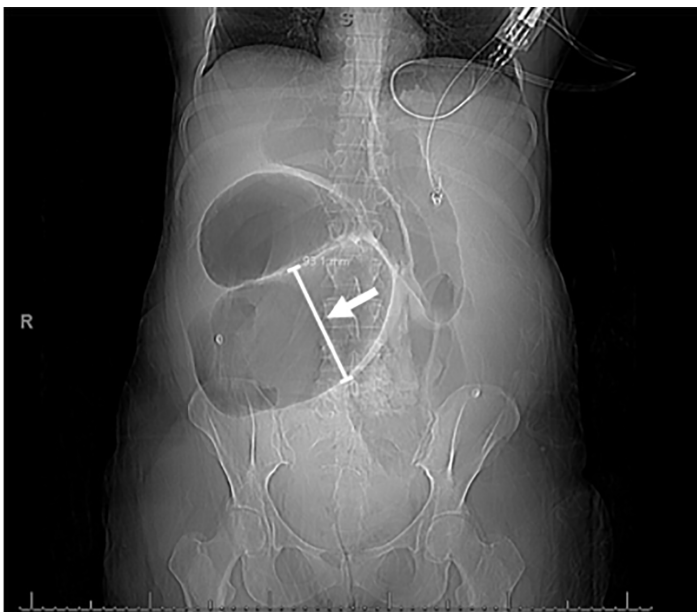
*Midgut volvulus is extremely rare in adults, and its occurrence secondary to stricturing active Crohn's disease is even more exceptional.*

What is the major learning point?

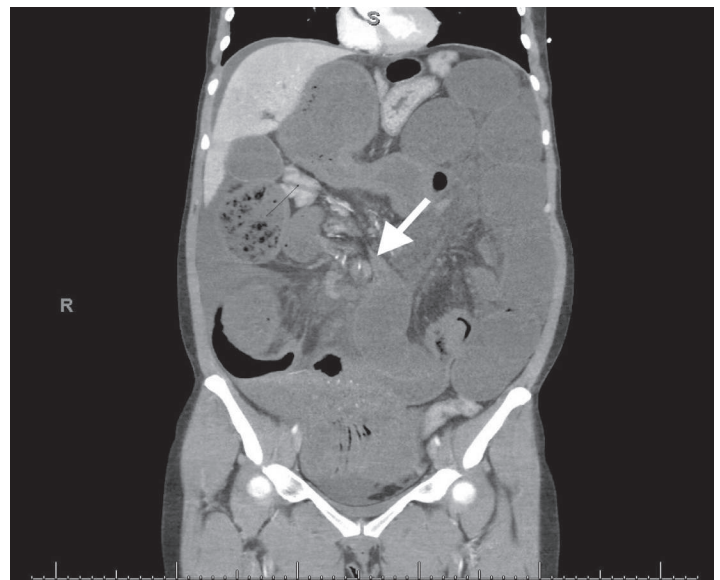
*When patients present with intermittent symptoms and inconclusive prior workup, it is imperative to consider atypical sequelae of the common diseases.*

How might this improve emergency medicine practice?

*This uncommon but dangerous complication of a prevalent pathology highlights the need to broaden the illness script related to heterogeneous Crohn's disease.*



**Image 1.** Coronal view of the patient's scout film prior to computed tomography shows acute midgut volvulus. Loops of proximal small bowel were severely dilated (arrow), measuring 9.31 centimeters in the central anterior abdomen.



**Image 2.** Coronal view of the patient's computed tomography, showing one of the two transition points (arrow) noted of the high-grade small bowel obstruction located in the right mid-abdomen. There was a small amount of free fluid in the dependent aspects of the abdomen, likely reactive.

potential intra-abdominal infection with IV piperacillin-tazobactam. Norepinephrine and phenylephrine IV drips were started for pressor support in light of refractory hypotension. The colorectal surgery team was consulted, and the patient was taken for an emergent exploratory laparotomy. An estimated 75% of her small intestines was resected, followed by abdominal wall closure a few days later. Her postoperative course was uneventful. She was discharged home with close follow-up with colorectal surgery and gastroenterology. Biopsies taken during the resection displayed chronic active enteritis with strictures, transmural inflammation, non-necrotizing granulomas, and pyloric gland metaplasia, all of which are histologically compatible with active Crohn's disease.

## DISCUSSION

Midgut volvulus is more commonly seen in infants and children as the consequence of arrested normal rotation of the embryonic gut.<sup>7</sup> In adult patients, intestinal malrotation is highly unusual but can occur secondary to adhesions after intra-abdominal surgeries, congenital defects, or malignancy.<sup>8</sup> It is theorized that the simultaneous occurrence of small intestinal volvulus and Crohn's disease is rare because the disease's serosal inflammation causes adherence of the bowel to adjacent structures, making the bowel less likely to twist upon itself.<sup>5</sup> Intestinal malrotation without the development of volvulus may present as chronic intermittent abdominal pain, nausea, and vomiting.<sup>9</sup> This can be confirmed with an upper gastrointestinal (GI) series. The patient can undergo a non-emergent open or laparoscopic Ladd procedure to correct the abnormality.<sup>9</sup> The Ladd procedure is an elective surgery in which malrotation is corrected to prevent a volvulus from occurring in the future. This procedure entails counterclockwise detorsion of the small intestine, surgical division of Ladd's bands (naturally occurring fibrous stalks that attach the cecum to the right lower abdomen's retroperitoneum), widening of the mesentery, appendectomy, and reorientation of the small intestine to the right and the colon to the left.<sup>9</sup>

In contrast, intestinal malrotation with volvulus is considered a life-threatening acute abdomen and warrants emergent surgery to salvage viable tissue. As in our case, patients often present acutely with complaints of severe abdominal pain, nausea, vomiting, hematochezia, or hematemesis, coupled with hemodynamic instability. However, chronic intestinal malrotation is a possibility. The clinical presentation of chronic malrotation often involves intermittent vomiting and abdominal pain, associated with food intolerance, malabsorption, and chronic diarrhea. Diagnosis of acute midgut volvulus can be confirmed via imaging, such as CT abdomen and pelvis or abdominal plain film. Patients should receive aggressive IV resuscitation and broad empiric antibiotics, due to the high risk of gut bacteria translocation, prior to being taken to the operating room for an emergent exploratory laparotomy. During laparotomy,

the bowel is detorsed counterclockwise and resected if the tissue appears grossly necrotic.<sup>10</sup> If the bowel is not necrotic-appearing but its viability is uncertain, it may be preserved and reinspected at a second-look operation scheduled approximately 24-48 hours later.<sup>10</sup>

The confirmation of Crohn's disease can be diagnostically challenging as there is no definitive method and the heterogeneous disease can affect anywhere along the GI tract, including the rectum.<sup>11</sup> Colonoscopy with biopsies is a common tool used by gastroenterologists for the initial evaluation of IBD.<sup>12</sup> However, a standard colonoscopy can only reach up to the terminal ileum where the small intestine ends.<sup>12</sup> Therefore, a normal colonoscopy does not exclude Crohn's disease if the inflammation is located farther up along the small intestine. With recent advances in technology, video capsule endoscopy is becoming an increasingly popular method to aid in the diagnosis.<sup>13</sup> In our case, the patient was, unfortunately, unable to engage in this expensive modality due to lack of insurance.

Even without a definitive diagnosis, emergency physicians should consider IBD in young and middle-aged patients with an ongoing history of intermittent abdominal pain. There can be an additional cognitive bias regarding individuals with functional labels, such as abdominal migraines or IBS.<sup>14</sup> Serum inflammatory markers are often not reliable in IBD, as demonstrated in this scenario.<sup>15</sup> Given the patient's hemodynamic instability, severe metabolic derangements, and concerning physical exam, prompt recognition of her critically ill status and the pursuit of urgent imaging ultimately allowed her to have a favorable clinical outcome despite the extensive bowel resection that she required.

## CONCLUSION

Midgut volvulus is an extremely rare but dangerous sequela of Crohn's disease, with only a handful of cases described in the literature. Prompt recognition of volvulus on imaging, rapid IV fluid resuscitation, and emergent exploratory laparotomy are the treatment. Our case highlights the dramatic consequences of undiagnosed Crohn's disease in a patient with intermittent symptoms and extensive workup spanning over two decades.

Patient consent has been obtained and filed for the publication of this case report.

---

*Address for Correspondence:* Minh Thu Nguyen, MD, University of Rochester Medical Center, Department of Internal Medicine, 601 Elmwood Avenue, Box MED, Rochester, New York 14642. Email: minhthu\_nguyen@URMC.rochester.edu.

*Conflicts of Interest:* By the CPC-EM article submission agreement, all authors are required to disclose all affiliations, funding sources and financial or management relationships that could be perceived as potential sources of bias. The authors disclosed none.

Copyright: © 2021 Nguyen. This is an open access article distributed in accordance with the terms of the Creative Commons Attribution (CC BY 4.0) License. See: <http://creativecommons.org/licenses/by/4.0/>

## REFERENCES

1. Ballou S, Hirsch W, Singh P, et al. Emergency department utilisation for inflammatory bowel disease in the United States from 2006 to 2014. *Aliment Pharmacol Ther.* 2018;47(7):913-21.
2. Jung YS, Park DI, Hong SN, et al. Predictors of urgent findings on abdominopelvic CT in patients with Crohn's disease presenting to the emergency department. *Dig Dis Sci.* 2015;60(4):929-35.
3. Miller G, Boman J, Shrier I, et al. Etiology of small bowel obstruction. *Am J Surg.* 2000;180(1):33-6.
4. Kinjo F, Sunagawa T, Hokama A, et al. Crohn's disease and volvulus. *Gastrointest Endosc.* 2003;58(5):758-9.
5. Fink W, Cohen A, Greenstein AJ. Small bowel volvulus in association with recurrent Crohn's disease. *Am J Gastroenterol.* 1980;74(4):337-41.
6. Fiorani C, Biancone L, Tema G, et al. Laparoscopic ileocolic resection for Crohn's disease associated with midgut malrotation. *JSLs.* 2014;18(3)e2014.11192.
7. Kanellos-Becker I, Bergholz R, Reinshagen K, et al. Early prediction of complex midgut volvulus in neonates and infants. *Pediatr Surg Int.* 2014;30(6):579-86.
8. Baty V, Rocca P, Fontaumard E. Acute gastric volvulus related to adhesions after laparoscopic fundoplication. *Surg Endosc.* 2002;16(3):538.
9. Kotobi H, Tan V, Lefevre J, et al. Total midgut volvulus in adults with intestinal malrotation. Report of eleven patients. *J Visc Surg.* 2017;154(3):175-83.
10. Li X, Zhang J, Li B, et al. Diagnosis, treatment and prognosis of small bowel volvulus in adults: a monocentric summary of a rare small intestinal obstruction. *PLoS One.* 2017;12(4):e0175866.
11. Ha F and Khalil H. Crohn's disease: a clinical update. *Therap Adv Gastroenterol.* 2015;8(6):352-9.
12. Cleynen I, Gonzalez JR, Figueroa C, et al. Genetic factors conferring an increased susceptibility to develop Crohn's disease also influence disease phenotype: results from the IBDchip European Project. *Gut.* 2013;62(11):1556-65.
13. Yamada K, Nakamura M, Yamamura T, et al. Diagnostic yield of colon capsule endoscopy for Crohn's disease lesions in the whole gastrointestinal tract. *BMC Gastroenterol.* 2021;21(1):75.
14. Pines JM and Strong A. Cognitive biases in emergency physicians: a pilot study. *J Emerg Med.* 2019;57(2):168-72.
15. Schoepfer AM, Beglinger C, Straumann A, et al. Fecal calprotectin correlates more closely with the Simple Endoscopic Score for Crohn's disease (SES-CD) than CRP, blood leukocytes, and the CDAI. *Am J Gastroenterol.* 2010;105(1):162-9.

# Atypical Presentation of *Haemophilus influenzae* Septic Arthritis: A Case Report

Andrew Steven Tadych, BS\*  
David Enrique Catano, MD†  
April Lynn Brill, DO†

\*Department of Clinical Education, Midwestern University – Chicago College of Osteopathic Medicine, Downers Grove, Illinois  
†Department of Emergency Medicine, Midwestern University, Franciscan Health Olympia Fields, Olympia Fields, Illinois

Section Editor: R. Wilkerson, MD

Submission History: Submitted July 6, 2021; Revision received September 14, 2021; Accepted September 20, 2021

Electronically published October 26, 2021

Full text available through open access at [http://escholarship.org/uc/uciem\\_cpem](http://escholarship.org/uc/uciem_cpem)

DOI: 10.5811/cpcem.2021.9.54043

**Introduction:** Septic arthritis is a destructive form of acute arthritis that requires expeditious recognition. as delayed treatment yields significant morbidity and mortality.

**Case Report:** A 40-year-old male presented to the emergency department with right elbow pain. Examination revealed tachycardia, swelling, redness, tenderness, and decreased range of motion of the right humeroulnar joint. Synovial fluid analysis was consistent with an inflammatory etiology, but blood and joint cultures ultimately revealed *Haemophilus influenzae*.

**Discussion:** This case highlights the importance of trusting clinical findings over laboratory evidence in patients with suspected septic arthritis. [Clin Pract Cases Emerg Med. 2021;5(4):459-462.]

**Keywords:** *Haemophilus influenzae*, septic arthritis, HIV, synovial fluid white cell count, human immunodeficiency virus

## INTRODUCTION

Septic arthritis (SA) is a key differential to consider in any case of acute monoarticular arthritis, as failure to initiate appropriate antibiotic therapy within 24-48 hours of onset can facilitate subchondral bone loss, permanent joint dysfunction, and lead to systemic spread of the infection.<sup>1</sup> Historically, the likelihood of SA increases substantially with increasing synovial fluid (SF) white blood cell (WBC) count, in addition to other markers including serum leukocyte count, erythrocyte sedimentation rate, and C-reactive protein levels, which are often used to guide diagnosis.<sup>2</sup> Conventional thinking suggests using a SF WBC count cutoff of 50,000 cells per cubic milliliter (cells/mm<sup>3</sup>) to guide diagnosis of SA.<sup>3</sup> However, atypical cases of SA in patients with normal vitals, normal inflammatory markers, and inconclusive synovial fluid analyses have been documented.<sup>4</sup>

The most common pathogens isolated in cases of SA include *Staphylococcus aureus* and *Streptococcus pneumoniae*. Other less common pathogens include Gram-negative bacilli, mycobacteria, Gram-negative cocci, Gram-positive bacilli, and anaerobes.<sup>1</sup> *Haemophilus influenzae* has

been identified as a rare cause of SA, which had previously decreased in prevalence secondary to *H influenzae* serotype b (Hib) conjugate vaccine development in 1986.<sup>5</sup> *H influenzae* is an encapsulated, pleomorphic Gram-negative rod with multiple capsular serotypes and commonly colonizes the human respiratory tract.<sup>6</sup> While Hib is considered the most virulent serotype, other serotypes and non-typable *H influenzae* have been implicated in the development of invasive disease. Some invasive infections include meningitis, bacteremia, epiglottitis, SA, cellulitis, purulent pericarditis, endocarditis, and osteomyelitis.<sup>7</sup> Therefore, the early identification and treatment of *H influenzae* SA is crucial in preventing significant morbidity and mortality.

The diagnosis of SA is made with a combination of clinical suspicion, positive blood cultures, and suggestive synovial fluid findings. Clinical presentation is variable, but often includes fever and malaise with localized pain, warmth, swelling, and decreased range of motion of the joint.<sup>1</sup> Blood cultures are often drawn and can aid in the identification of infectious agents since SA is most often caused by hematogenous seeding of a joint.<sup>8</sup> Important synovial fluid studies include Gram stain, leukocyte



count, crystal analysis, and fluid culture. Traditionally, a SF WBC count of 50,000 cells/mm<sup>3</sup> was used as the cutoff for diagnosing SA<sup>3</sup>; however, while increasing SF WBC count is associated with increased likelihood of SA, a low count is insufficient to rule out SA.<sup>9</sup> Therefore, practitioners must rely on their clinical judgment when evaluating patients for SA in the face of inconsistent laboratory results.

## CASE REPORT

We present the case of a 40-year-old male with no significant past medical history, aside from a penicillin allergy, who presented to the emergency department (ED) with a chief complaint of severe right elbow pain, swelling, and limited passive and active range of motion for one day. He reported a prodromal flu-like syndrome of subjective fever, chills, and myalgias with associated right-arm soreness for two days prior to symptom onset. The patient stated that his right elbow started to swell and he progressively experienced increased pain over the following day. He attempted to use heating pads and ice without symptomatic relief. On further history, he reported recent unprotected sex with a new sexual partner in addition to right knee and hip pain without a history of trauma. At the time of his presentation, he denied any penile discharge, burning during urination, or pain in other joints.

On physical exam, the patient was in moderate distress due to pain. His right elbow was erythematous, edematous, warm, and tender to palpation. Passive and active range of motion were limited and worsened pain. Mild effusion was noted on palpation of the joint. He was initially afebrile with a temperature of 99.9°F, mildly tachycardic to 110 beats per minute, normotensive, and had 100% oxygen saturation. Labs were remarkable for an elevated erythrocyte sedimentation rate of 68 millimeters per hour (mm/hr) (reference range: 0-30 mm/hr), borderline leukocytosis of 10.7\*10<sup>3</sup> cells per milliliter (mL) (4.0-11.0\*10<sup>3</sup> cells/mL), mild hyponatremia, and mild hypokalemia. Complete blood count, creatinine kinase, and lactic acid were within normal limits. Blood cultures were obtained for Gram stain and culture.

Right elbow radiograph revealed joint effusion without evidence of fracture or soft tissue swelling (Image). Arthrocentesis from the right elbow was performed with 18 mL of aspirate. Synovial fluid analysis revealed cloudy fluid with small clots, a SF WBC count of 22,000 cells per cubic millimeter (mm<sup>3</sup>) (reference range: 0-200 cells/mm<sup>3</sup>), 90% segmented neutrophils, and 66,500 red blood cells. Synovial fluid was cultured and sent for Gram staining. Intravenous (IV) ketorolac and morphine were given for pain control, and the patient was empirically started on IV clindamycin for suspected skin and soft tissue infection. While he was in the ED, there was suspicion for an inflammatory process of the joint with an overlying soft tissue infection. However, due to the risk of SA, he was admitted to the floor for further workup and evaluation.

On the floor, antibiotics were switched to aztreonam and vancomycin by the primary team due to suspicion of SA.

### CPC-EM Capsule

What do we already know about this clinical entity?

*Septic arthritis is a destructive form of acute arthritis that requires expeditious recognition as delayed treatment yields significant morbidity and mortality.*

What makes this presentation of disease reportable?

*Haemophilus influenzae septic arthritis is rare due to the available immunization. However, in this case the patient had an undiagnosed immunocompromised state.*

What is the major learning point?

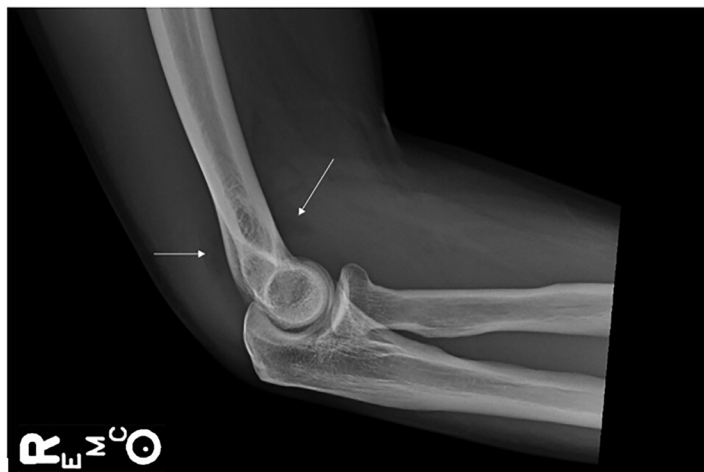*This case highlights the importance of trusting clinical findings as well as a thorough history over laboratory evidence in patients with suspected septic arthritis.*

How might this improve emergency medicine practice?

*Clinical presentations which are suspicious for septic arthritis must prompt careful diagnostic consideration, despite inconsistent laboratory findings.*

Rapid human immunodeficiency virus (HIV)-1/2 antibody/antigen and gonorrhea-chlamydia tests were ordered. Orthopedic and infectious disease teams were consulted for further management and recommendations. Further laboratory testing revealed HIV 1/2 antibody positive, absolute cluster of differentiation (CD4) count of 82 cells/mm<sup>3</sup> (reference range: 518-1,472 cells/mm<sup>3</sup>), CD4:CD8 of 0.2 (0.9-5.0), and positive blood cultures for *H. influenzae*. Upon blood culture results, the infectious disease team switched antibiotics to ceftriaxone and vancomycin to cover for *H influenzae* bacteremia. Due to the low CD4 count of 82 cells/mm<sup>3</sup>, trimethoprim-sulfamethoxazole was started for *Pneumocystis jirovecii* pneumonia (PJP) prophylaxis. The patient underwent right elbow arthrotomy, irrigation, and excisional debridement of the synovium and subcutaneous tissue. Postoperatively, he experienced intermittent fevers that responded to acetaminophen and improved over a few days.

During his hospital course, the patient experienced polyarticular joint pain in his right knee and hip with swelling and difficulty weight bearing. This development was concerning for spread of *H influenzae* to the right hip and/or



**Image.** Lateral radiograph of right arm. Arrows identify displacement of the anterior and posterior fat pads consistent with a joint effusion.

knee. Magnetic resonance imaging (MRI) of the right hip revealed trace effusion with edema within and surrounding the inferior segment of the visualized right iliopsoas muscle. This MRI finding was concerning for myositis secondary to *H influenzae* bacteremia. The patient then underwent aspiration of the right knee, which revealed no organisms and a SF WBC count of 3057 cells/mm<sup>3</sup>. Aspiration of the right hip also revealed an unremarkable SF analysis. Given systemic symptoms, echocardiogram was performed to rule out endocarditis and was negative for vegetations. As pain, swelling, and fever improved, a peripherally inserted central catheter (PICC) line was placed for outpatient IV antibiotics.

After eight days of in-patient evaluation and treatment, the patient's clinical status and acute febrile illness had improved significantly. Per infectious disease final recommendations, the patient was discharged with a PICC line to receive IV ceftriaxone 2 grams daily for four weeks. He was also instructed to continue trimethoprim-sulfamethoxazole for PJP prophylaxis and to follow up with infectious disease as an outpatient to begin anti-retroviral therapy.

## DISCUSSION

This case demonstrates a rare presentation of *H influenzae* SA in an immunocompromised adult. Septic arthritis in a newly diagnosed human immunodeficiency virus (HIV)-positive adult can progress to a polyarthritic infection and further invasive disease. Therefore, early recognition and aggressive treatment combining surgical and medical modalities is often needed for optimal recovery. Unfortunately, as this case shows, there is no established guideline for ruling out SA. Given the presentation of severe pain, limited range of motion, erythema, warmth, and edema of the right elbow, the clinical suspicion for SA was initially high. This suspicion prompted an orthopedic evaluation and arthrocentesis. With a

SF WBC count of 22,000 cells/mm<sup>3</sup> our suspicion for inflammatory bursitis with an overlying skin and soft tissue infection increased while SA became less likely. While accepting this diagnosis may have led to delayed treatment, it would have been reasonable based on a SF WBC count diagnostic cut-off of 50,000 cells/mm<sup>3</sup> for SA.

Prior studies have attempted to identify an appropriate cutoff for SF WBC count in the identification of SA. Margaretten et al published a systematic review analyzing the likelihood ratios (LR) for multiple different SF cutoff levels. They found a LR of 0.32 in adults with SF WBC count less than 25,000 vs SF WBC count greater than or equal to 25,000, which had a LR of 2.9.<sup>9</sup> A newer review by Long et al found that nearly half of all patients with SA had a SF WBC count under 28,000 cells/mm<sup>3</sup>.<sup>10</sup> While the authors suggest using clinical judgment over laboratory cutoffs, this data illustrates how difficult the diagnosis of SA can be.

Other studies have shown how immunodeficiency further increases diagnostic difficulty due to changes in SF findings.<sup>11,12</sup> Notably, immunosuppression increases risk of infection while lowering SF WBC count, which complicates diagnosis. Zalavras et al identified consistently lower SF WBC count in HIV-positive patients with SA when compared to immunocompetent patients with average counts of 40,500 and 69,000 cells/mm<sup>3</sup>, respectively.<sup>12</sup> Contrasted to a SF WBC count of 22,000 cells/mm<sup>3</sup> in a newly diagnosed HIV-positive patient, we see that immunosuppression has a significant yet inconsistent effect on SF WBC count. Altogether, this can make diagnosis of SA particularly difficult. Nevertheless, this case demonstrates the risks of ruling out serious diagnoses based on laboratory data. While the patient was initially worked up for complicated skin and soft tissue infection with an underlying inflammatory condition, it was the emergency physician's insistence on admitting the patient that led to the diagnosis and treatment while preventing further complications.

## CONCLUSION

Any patient presenting with an acute onset of monoarticular joint pain, erythema, warmth, and restricted range of motion should be carefully evaluated for septic arthritis. In cases of contradictory lab findings, clinical judgment should rely more heavily on clinical findings in cases of SA due to a lack of established guidelines. Physicians must also consider immunocompromising comorbidities or potential immunocompromised states when analyzing synovial fluid results. Timely and accurate diagnosis of SA can decrease complications and improve patient outcomes. Therefore, clinical presentations that are suspicious for SA must prompt careful diagnostic consideration, despite inconsistent laboratory findings.

The authors attest that their institution requires neither Institutional Review Board approval nor patient consent for publication of this case report. Documentation on file.

---

**Address for Correspondence:** April Lynn Brill, DO, Midwestern University, Franciscan Health Olympia Fields, 20201 South, Crawford Avenue, Olympia Fields, Illinois 60461. Email: [abrill@midwestern.edu](mailto:abrill@midwestern.edu).

**Conflicts of Interest:** By the CPC-EM article submission agreement, all authors are required to disclose all affiliations, funding sources and financial or management relationships that could be perceived as potential sources of bias. The authors disclosed none.

**Copyright:** © 2021 Tadych. This is an open access article distributed in accordance with the terms of the Creative Commons Attribution (CC BY 4.0) License. See: <http://creativecommons.org/licenses/by/4.0/>

---

## REFERENCES

1. Shirliff ME and Mader JT. Acute septic arthritis. *Clin Microbiol Rev.* 2002;15(4):527-44.
2. Shah K, Spear J, Nathanson LA, et al. Does the presence of crystal arthritis rule out septic arthritis? *J Emerg Med.* 2007;32(1):23-6.
3. Mathews CJ and Coakley G. Septic arthritis: current diagnostic and therapeutic algorithm. *Curr Opin Rheumatol.* 2008;20(4):457-62.
4. Anino-Fernández J, Ramírez-Huaranga MA, Mínguez-Sánchez MD. False negatives of synovial fluid in septic arthritis. *Reumatol Clin.* 2016;12(2):114-5.
5. Soeters HM, Blain A, Pondo T, et al. Current epidemiology and trends in invasive *Haemophilus influenzae* disease—United States, 2009–2015. *Clin Infect Dis.* 2018;67(6):881-9.
6. Musher DM. *Haemophilus* species. 1996. Available at: <https://www.ncbi.nlm.nih.gov/books/NBK8458/>. Accessed May 15, 2021.
7. Langereis JD and de Jonge MI. Invasive disease caused by nontypeable *Haemophilus influenzae*. *Emerg Infect Dis.* 2015;21(10):1711-8.
8. Sharff KA, Richards EP, Townes JM. Clinical management of septic arthritis. *Curr Rheumatol Rep.* 2013;15(6):332.
9. Margaretten ME, Kohlwes J, Moore D, et al. Does this adult patient have septic arthritis? *JAMA.* 2007;297:1478–88.
10. Long B, Koyfman A, Gottlieb M. Evaluation and management of septic arthritis and its mimics in the emergency department. *West J Emerg Med.* 2019;20(2):331-41.
11. Carpenter CR, Schuur JD, Everett WW, et al. Evidence-based diagnostics: adult septic arthritis. *Acad Emerg Med.* 2011;18(8):781-96.
12. Zalavras CG, Dellamaggiora R, Patzakis MJ, et al. Septic arthritis in patients with human immunodeficiency virus. *Clin Orthop Relat Res.* 2006;451:46-9.

# Whirlpool No More: A Case of Misdiagnosed Malrotation with Midgut Volvulus

Michael Fogam, MD\*  
Natasha Leigh, MD†  
Trent She, MD\*

\*Mount Sinai St. Luke's and Mount Sinai West, Department of Emergency Medicine, New York, New York

†Mount Sinai St. Luke's and Mount Sinai West, Department of Surgery, New York, New York

Section Editor: Anna McFarlin, MD

Submission History: Submitted April 3, 2021; Revision received September 12, 2021; Accepted September 20, 2021

Electronically published October 28, 2021

Full text available through open access at [http://escholarship.org/uc/uciem\\_cpem](http://escholarship.org/uc/uciem_cpem)

DOI: 10.5811/cpcem.2021.9.52682

**Introduction:** Adult intestinal malrotation with midgut volvulus is rare and most often diagnosed on abdominal imaging. Once the diagnosis is made, prompt surgical intervention is necessary. A finding suggestive of malrotation with midgut volvulus on abdominal imaging is the “whirlpool” sign where the superior mesenteric vein and superior mesenteric artery twist at the root of the abdominal mesentery. This sign was once thought to be pathognomonic, but recent studies have shown that it can be seen in asymptomatic patients.

**Case Report:** A 20-year-old female presented to our emergency department with diffuse abdominal pain. Computed tomography demonstrated the “whirlpool” sign with a concern for malrotation with midgut volvulus. Surgical consultation was obtained and the patient was rushed to the operating room for an exploratory laparotomy. Normal mesenteric attachments were seen and no significant pathology was identified during the laparotomy. The patient was eventually diagnosed with gastritis and discharged in stable condition.

**Conclusion:** Emergency physicians and surgeons alike should be cautious in confirming malrotation with midgut volvulus solely due to the “whirlpool” sign on abdominal imaging. Premature diagnostic closure can lead to unnecessary procedures and interventions for patients as in the case we report here. [Clin Pract Cases Emerg Med. 2021;5(4):463-465.]

**Keywords:** *malrotation; midgut volvulus; whirlpool sign.*

## INTRODUCTION

Malrotation with midgut volvulus is an uncommon surgical emergency in adults. The diagnosis is established with certain characteristic findings on computed tomography of the abdomen and pelvis (CT A/P). The most notable finding is a counterclockwise twisting of the superior mesenteric vein (SMV) onto the superior mesenteric artery (SMA), also known as the “whirlpool” sign.<sup>1</sup> However, because this finding can sometimes be a normal variant care must be exercised to correlate the “whirlpool” sign with clinical examination to prevent unnecessary intervention.

## CASE REPORT

Our patient was a 20-year-old female who presented to the emergency department (ED) with two hours of diffuse

abdominal pain. She had similar episodes of abdominal pain in the past that occurred once or twice a year after food intake, which were relieved with pain medication. On current presentation, her pain was far worse than usual.

Initial vitals were unremarkable, without tachycardia and without fever. Upon examination, the patient’s abdomen was soft but diffusely tender from the epigastrium to the hypogastrium. She exhibited no guarding or rebound tenderness. Her laboratory studies included an unremarkable chemistry panel, a slight leukocytosis of 11.3 thousand cells per microliter (K/ $\mu$ L) (reference range: 3.9 – 11 K/ $\mu$ L), and a normal serum lactate of 0.76 millimoles per liter (mmol/L) (normal < 2 mmol/L). An upright chest radiograph did not demonstrate pneumoperitoneum. Intravenous morphine and famotidine were administered with minimal relief of



symptoms. Computed tomography of the abdomen and pelvis (CT A/P) with oral and intravenous contrast demonstrated a distended stomach, a duodenum that did not definitively cross midline, mildly dilated small bowel loops that were mostly in the right lower quadrant and, most distinctively, an SMV that twisted in a 360° counterclockwise fashion to the left of the SMA. A presumed diagnosis of malrotation and midgut volvulus was made and prompt surgical consultation was obtained.

The patient was taken emergently to the operating room for an exploratory laparotomy. The bowel was found to be in its proper anatomic position with normal peritoneal attachments and without the presence of any Ladd's bands. (These fibrous bands of peritoneal tissue are embryologic remnants and the ultimate cause of malrotation.) On postoperative day one the patient underwent an upper endoscopy, revealing erosions and erythema in the stomach and superficial duodenal ulcers. Her postoperative recovery was unremarkable, and she was discharged home uneventfully with the diagnosis of gastritis and peptic ulcer disease.

## DISCUSSION

Malrotation is a condition resulting from an embryologic abnormality: failure of the bowel to rotate in a 270° counterclockwise fashion and fixate on the posterior abdominal wall. Without this fixation, the small bowel can twist about the base of its mesentery onto the large bowel, resulting in a midgut volvulus. Classically, this condition presents in infancy, with 90% of cases occurring under the age of one. Only 0.2-0.5% of cases of intestinal malrotation occur in adulthood, and of these cases only 15% present with a midgut volvulus.<sup>1</sup> Traditionally, an upper gastrointestinal (GI) series has been the imaging modality of choice demonstrating a classic "corkscrew" appearance when contrast does not pass through the duodenum.<sup>2</sup> In adults, CT A/P is much more commonly used.<sup>3</sup>

A finding previously considered to be pathognomonic<sup>1</sup> for midgut volvulus is the "whirlpool" sign (Image 1), or the counterclockwise twisting of the superior mesenteric vein on the superior mesenteric artery as the small bowel mesentery

*CPC-EM Capsule*

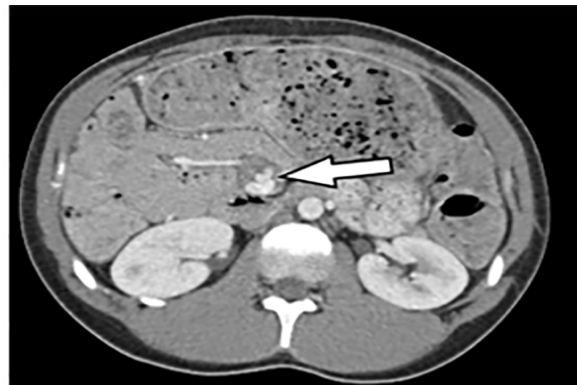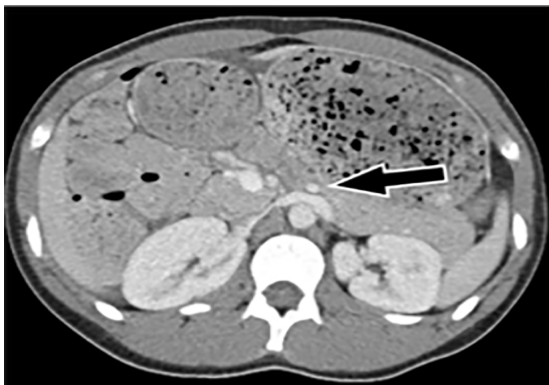
What do we already know about this clinical entity?  
*Malrotation with midgut volvulus is a condition requiring timely diagnosis in the emergency department and may be present at any age. It should not be thought of as a strictly pediatric problem.*

What makes this presentation of disease reportable?  
*Malrotation with midgut volvulus will be suggested by findings on computed tomography including a counterclockwise twisting of the superior mesenteric vein on the superior mesenteric artery.*

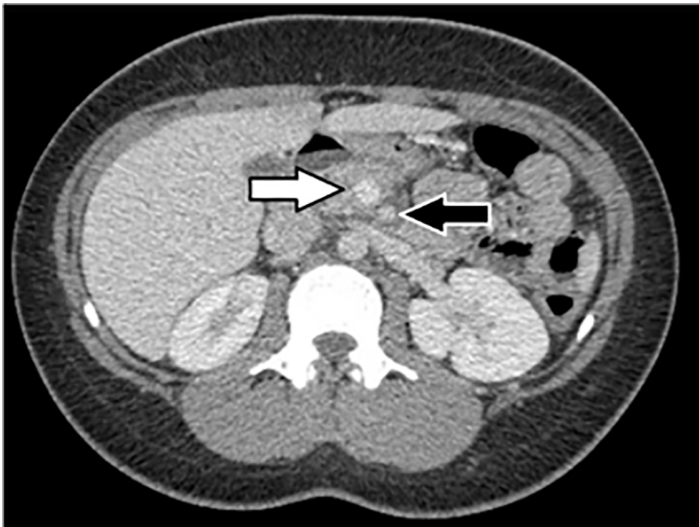
What is the major learning point?  
*Caution must be used when interpreting the above "whirlpool" sign as it is not necessarily pathognomonic of malrotation as was previously thought.*

How might this improve emergency medicine practice?  
*Emergency physicians should not just rely on the finding of the "whirlpool" sign to diagnose malrotation and should consider all clinical and radiographic data available.*

twists about its axis. More recent research suggests that although this sign may be suggestive of midgut volvulus, it is not diagnostically definitive. Although the SMV normally runs concurrently with the SMA in close proximity (Image 2), 10-36% of the pediatric population have SMV/SMA twisting



**Image 1.** Left-hand image showing branch point of the superior mesenteric artery from the abdominal aorta on axial computed tomography views (black arrow). Right-hand image showing "whirlpool" sign (white arrow).



**Image 2.** This axial computed tomography image shows the normal appearance of the superior mesenteric artery (black arrow) and just adjacent to it, the superior mesenteric vein (white arrow).

at baseline,<sup>4,5</sup> and up to 33% of these have a 270° or greater twist.<sup>5</sup> Some coexisting intra-abdominal findings such as renal masses or ascites can be present, but often the reason for this asymptomatic variance is unclear.<sup>6</sup>

Our patient ultimately did not have malrotation with midgut volvulus despite radiographic findings suggestive of malrotation including a positive “whirlpool” sign, gastric distention, and most of the small bowel loops in the right lower quadrant. She did not have any laboratory findings suggestive of ischemia.

Her presentation was suggestive of malrotation but can also be explained by peptic ulcer disease or other upper gastrointestinal causes of pain. Our patient’s case illustrates the point that a “whirlpool” sign is not in itself pathognomonic for malrotation and can be a normal variant, and that clinical correlation is key to determining indications for operative intervention. Rather than surgical intervention in this case, continued observation with serial abdominal exams with possible endoscopic intervention or an upper GI series could have been pursued.

## CONCLUSION

Malrotation with midgut volvulus is an important condition requiring timely diagnosis in the ED and may be present in all age groups. It should not be thought of as a strictly pediatric problem. Very often, the diagnosis

will be suggested by findings on a CT of the abdomen/pelvis including a counterclockwise twisting of the superior mesenteric vein on the superior mesenteric artery. Caution must be used when interpreting this “whirlpool” sign, as it is not necessarily pathognomonic of malrotation as was previously thought.

Patient consent has been obtained and filed for the publication of this case report.

The authors attest that their institution does not require Institutional Review Board approval for publication of this case report. Documentation on file.

*Address for Correspondence:* Trent She, MD, Hartford Hospital, Department of Emergency Medicine, 80 Seymour St, Hartford, CT 06106. Email: trent.she@gmail.com.

*Conflicts of Interest:* By the *CPC-EM* article submission agreement, all authors are required to disclose all affiliations, funding sources and financial or management relationships that could be perceived as potential sources of bias. The authors disclosed none.

*Copyright:* © 2021 Fogam. This is an open access article distributed in accordance with the terms of the Creative Commons Attribution ([CC BY 4.0](http://creativecommons.org/licenses/by/4.0/)) License. See: <http://creativecommons.org/licenses/by/4.0/>

## REFERENCES

1. Butterworth W and Butterworth J. An adult presentation of midgut volvulus secondary to intestinal malrotation: A case report and literature review. *Int J Surg Case Rep.* 2018;50:46-9.
2. Stueland D. The acute presentation of intestinal nonrotation. *Am J Emerg Med.* 1989;7(2):235-7.
3. Tayde P, Wanjari A, Deshmukh A, et al. Midgut malrotation with chronic abdominal pain. *N Am J Med Sci.* 2012;4(4):196-8.
4. Taylor G. CT appearance of the duodenum and mesenteric vessels in children with normal and abnormal bowel rotation. *Pediatr Radiol.* 2011;41(11):1378-83.
5. Sodhi K, Bhatia A, Saxena A, et al. Anticlockwise swirl of mesenteric vessels: a normal CT appearance, retrospective analysis of 200 pediatric patients. *Eur J Radiol.* 2014;83(4):710-4.
6. Blake M and Mendelson R. The whirl sign: a non-specific finding of mesenteric rotation. *Australas Radiol.* 1996;40(2):136-9.

## Diagnosis of Bladder Diverticula with Point-of-Care Ultrasound

Shadi Lahham, MD, MS  
Salvador Gutierrez, BA

University of California, Irvine, Department of Emergency Medicine,  
Orange, California

Section Editor: Gentry R. Wilkerson, MD

Submission History: Submitted May 12, 2021; Revision received July 16, 2021; Accepted July 26, 2021

Electronically published October 26, 2021

Full text available through open access at [http://escholarship.org/uc/uciem\\_cpchem](http://escholarship.org/uc/uciem_cpchem)

DOI: 10.5811/cpcem.2021.7.53199

**Case Presentation:** A 65-year-old male presented to the emergency department with symptoms including fever, abnormal urinalysis, and elevated post-void residual. Point-of-care ultrasound was used to rapidly diagnose a bladder diverticulum. The patient was subsequently seen by urology for outpatient bladder repair.

**Discussion:** Bladder diverticula, an out-pouching of the bladder, may occur congenitally or as a result of various bladder conditions and/or surgery. Although bladder diverticula are rare and often asymptomatic, severe complications including frequent recurring urinary tract infections may arise depending on the patient. [Clin Pract Cases Emerg Med. 2021;5(4):466-467.]

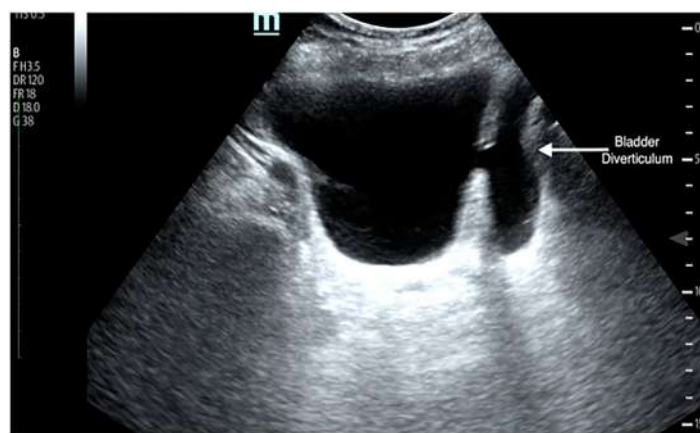
**Keywords:** *bladder diverticulum; laparoscopy.*

### CASE PRESENTATION

A 65-year-old male with a history of benign prostatic hypertrophy presented to the emergency department with generalized weakness, low-grade fever, and urinary frequency. Point-of-care ultrasound (POCUS) demonstrated a post-void residual greater than 500 milliliters, measured with ultrasound machine calculation software, and a large abnormality of the urinary bladder (Image, Video). No hydronephrosis was seen on renal ultrasound. Chart review showed several prior visits for urinary tract infections (UTI) and one hospitalization for sepsis due to pyelonephritis. Given multiple previous infections and sensation of incomplete emptying, a POCUS was performed and aided in making the diagnosis. The patient was treated with intravenous antibiotics and discharged home. Ultimately, given the symptomatic nature of the bladder diverticula with multiple previous UTIs, urology repaired the defect as an outpatient procedure.

### DISCUSSION

A bladder diverticulum is an out-pouching of the bladder that occurs when a part of the bladder lining protrudes through a weakness in the bladder wall. These occur either congenitally or as an acquired condition from bladder outlet obstruction, neurogenic bladder conditions, or from prior bladder surgery.<sup>1</sup> The prevalence of congenital diverticula is



**Image.** Ultrasound demonstrating a bladder diverticulum, with the out-pouching (arrow) to the right of the bladder.

approximately 1.7%.<sup>2</sup> The incidence increases with age and is most common in men with benign prostatic hypertrophy at a rate of up to 6%.<sup>3</sup> The male to female ratio of 9:1 reflects this finding.<sup>4</sup> Because bladder diverticula are typically asymptomatic, they are usually discovered on evaluations for UTIs, hematuria, or lower urethral tract symptoms. Management of bladder diverticula depends on the

complications that arise. Nonoperative, conservative management includes treatment with antibiotics for UTIs and avoidance of medications that cause urinary retention, such as opioids. Malignancy is a feared complication as the diverticula lacks a muscular wall outside the mucosal layer allowing metastatic spread more rapidly. Open or laparoscopic surgical correction options exist and are chosen based on several factors such as malignancy, size, and surgeon experience.<sup>1</sup> This diagnosis can be made with POCUS and may explain the etiology of patients with recurrent UTIs. It is important to note that complete imaging of the bladder may be necessary to capture a definitive image of the break in the bladder wall.

**Video.** A coronal, or long-axis, view of the bladder with an out-pouching bladder diverticulum on the right side of the screen.

The authors attest that their institution requires neither Institutional Review Board approval nor patient consent for publication of this case report. Documentation on file.

**Address for Correspondence:** Shadi Lahham, MD, MS, University of California, Irvine, Department of Emergency Medicine, 333 The City Boulevard West Suite 640, Orange, California 92868. Email: slahham@uci.edu.

**Conflicts of Interest:** By the CPC-EM article submission agreement, all authors are required to disclose all affiliations, funding sources and financial or management relationships that could be perceived as potential sources of bias. The authors disclosed none.

**Copyright:** © 2021 Martinez. This is an open access article distributed in accordance with the terms of the Creative Commons Attribution (CC BY 4.0) License. See: <http://creativecommons.org/licenses/by/4.0/>

### *CPC-EM Capsule*

What do we already know about this clinical entity?

*Bladder diverticulum is an out-pouching of the bladder that may be acquired or congenital.*

What is the major impact of the image(s)?

*Bladder diverticula, which can be identified using point-of-care ultrasound, should be considered in patients with repeat urinary tract infections (UTI).*

How might this improve emergency medicine practice?

*Point-of-care ultrasound can help identify bladder diverticula in patients with repeat UTIs.*

### REFERENCES

1. Pham KN, Jeldres C, Hefty T, et al. Endoscopic management of bladder diverticula. *Rev Urol.* 2016;18(2):114–7
2. Blane CE, Zerlin JM, Bloom DA. Bladder diverticula in children. *Radiology.* 1994;190(3):695-7.
3. Burns E. Diverticula of the urinary bladder. *Ann Surg.* 1944;119(5):656–64.
4. Idrees MT, Alexander RE, Kum JB, et al. The spectrum of histopathologic findings in vesical diverticulum: Implications for pathogenesis and staging. *Hum Pathol.* 2013;44(7):1223-32.



# Computed Tomography Appearance of the “Whirlpool Sign” in Ovarian Torsion

Joshua K. Livingston, MD\*  
Savannah Gonzales, MD†  
Mark I. Langdorf, MD, MHPE\*

\*University of California, Irvine, Department of Emergency Medicine, Orange, California  
†Cedars-Sinai Medical Center, Department of Obstetrics and Gynecology, Los Angeles, California

Section Editor: Jaqueline Le, MD

Submission History: Submitted May 20, 2021; Revision received July 7, 2021; Accepted July 2, 2021

Electronically published October 5, 2021

Full text available through open access at [http://escholarship.org/uc/uciem\\_cpccem](http://escholarship.org/uc/uciem_cpccem)

DOI: 10.5811/cpcem.2021.7.53317

**Case Presentation:** A 28-year-old female presented to the emergency department complaining of right lower abdominal pain. A contrast-enhanced computed tomography (CT) was done, which showed a 15-centimeter right adnexal cyst with adjacent “whirlpool sign” concerning for right ovarian torsion. Transvaginal pelvic ultrasound (US) revealed a hemorrhagic cyst in the right adnexa, with duplex Doppler identifying arterial and venous flow in both ovaries. Laparoscopic surgery confirmed right ovarian torsion with an attached cystic mass, and a right salpingo-oophorectomy was performed given the mass was suspicious for malignancy.

**Discussion:** Ultrasound is the test of choice for diagnosis of torsion due to its ability to evaluate anatomy and perfusion. When ovarian pathology is on the patient’s right, appendicitis is high in the differential diagnosis, and CT may be obtained first. Here we describe a case where CT first accurately diagnosed ovarian torsion by demonstrating the whirlpool sign, despite an US that showed arterial flow to the ovary. Future studies should determine whether CT alone is sufficient to diagnose or exclude ovarian torsion. [Clin Pract Cases Emerg Med. 2021;5(4):468–469.]

**Keywords:** ovarian torsion; computed tomography; ultrasound.

## CASE PRESENTATION

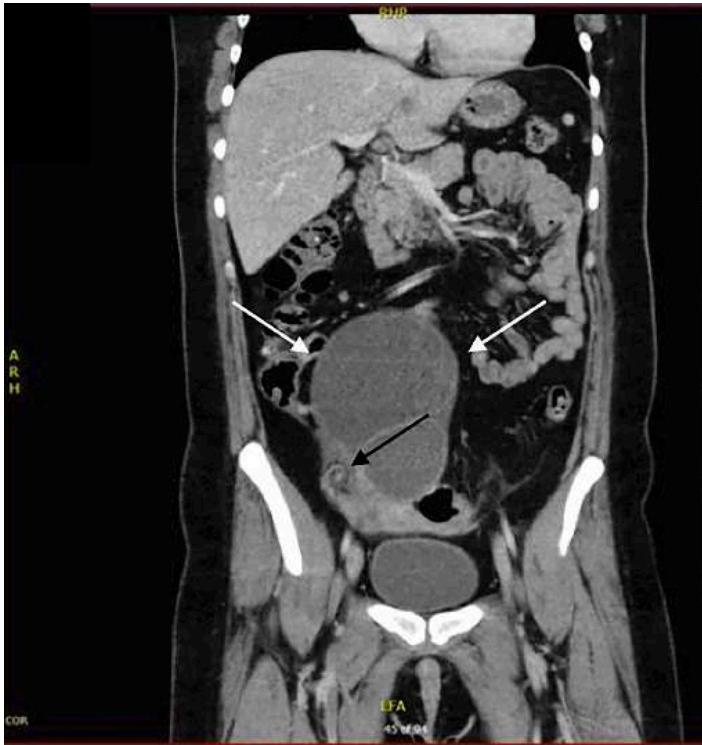A 28-year-old woman presented to the emergency department with constant right lower quadrant abdominal pain for four days. The patient reported a history of an ovarian cyst about five years earlier, for which she did not seek treatment. Vital signs were normal, and she had right lower quadrant fullness with tenderness. Due to suspicion for appendicitis, a contrast-enhanced computed tomography (CT) was done, which showed a 15-centimeter (cm) right adnexal cyst with adjacent “whirlpool sign” concerning for right ovarian torsion (Image).

Transvaginal pelvic ultrasound (US) then revealed a hemorrhagic cyst in the right adnexa measuring 15 x 9 x 13 cm. Duplex Doppler US of the ovaries identified arterial and venous flow in both ovaries. The presence of a whirlpool sign was not identified on the ultrasound studies. Laparoscopic surgery by obstetrics and gynecology that same night revealed a torsed right ovary with an attached cystic mass and a dusky purple- appearing fallopian tube.

Following de-torsion, the fallopian tube was pink and well perfused, and there was no evidence of fallopian or ovarian infarction. However, a right salpingo-oophorectomy was performed because the mass was suspicious for malignancy, with pathology report confirming a mucinous borderline tumor with intraepithelial carcinoma.

## DISCUSSION

Ovarian torsion refers to the complete or partial rotation of the ovary around its ligamentous supports, which can result in partial or complete obstruction of its blood supply.<sup>1</sup> Ultrasound is the test of choice for diagnosis of torsion due to its ability to evaluate anatomy and perfusion.<sup>2</sup> When ovarian pathology is on the patient’s right side, appendicitis is high in the differential diagnosis, and CT may be obtained first. In one multicenter, retrospective case-control study of 20 surgically confirmed cases of torsion and 20 controls, there was no significant difference in sensitivity or specificity between ultrasound and CT.<sup>3</sup> The most common reproducible finding on pelvic US and



**Image.** Coronal view of contrast-enhanced computed tomography in a woman with four days of right lower quadrant/pelvic pain, showing the “whirlpool sign” of ovarian torsion (black arrow), confirmed at laparoscopy. Also shown is 10 x 15 centimeter (cm) right ovarian cystic mass (white arrows).

CT is an adnexal mass, with torsion occurring infrequently in its absence. Other common findings on CT include tube thickening, smooth wall thickening of the twisted ovarian cystic mass, ascites, and uterine deviation to the twisted side.<sup>2,4</sup> Although not often seen, the whirlpool sign of a twisted vascular pedicle in ovarian torsion has been deemed definitive to diagnose torsion on US,<sup>5</sup> and it is also observed on CT.<sup>4</sup>

Here we describe a case where CT first accurately diagnosed ovarian torsion by demonstrating the whirlpool sign. Despite an US that showed arterial flow to the ovary, suspicion was high based on the CT, and laparoscopy confirmed torsion. This emphasizes that Doppler arterial flow to the ovary does not rule out torsion, especially in the setting of a large adnexal mass as present in this case. Although ovarian torsion remains a clinical diagnosis, future studies should determine whether CT alone is sufficient to diagnose or exclude ovarian torsion.

The authors attest that their institution requires neither Institutional Review Board approval nor patient consent for publication of this case report. Documentation on file.

**Address for Correspondence:** Joshua Livingston, MD, University of California, Irvine Medical Center, Department of Emergency Medicine, 333 City Boulevard West, Suite 640, Orange, California 92868. Email: jklivin1@uci.edu.

**Conflicts of Interest:** By the CPC-EM article submission agreement, all authors are required to disclose all affiliations, funding sources

### CPC-EM Capsule

What do we already know about this clinical entity?

*Ultrasound is the test of choice for diagnosis of ovarian torsion due to its ability to evaluate anatomy and perfusion.*

What is the major impact of the image(s)?

*This computed tomography (CT) image accurately diagnosed ovarian torsion by demonstrating “whirlpool sign,” despite an ultrasound without evidence of torsion.*

How might this improve emergency medicine practice?

*Computed tomography can be useful in the diagnosis of ovarian torsion. Providers may consider obtaining a CT, particularly when ultrasound is delayed or non-diagnostic.*

and financial or management relationships that could be perceived as potential sources of bias. The authors disclosed none.

**Copyright:** © 2021 Livingston. This is an open access article distributed in accordance with the terms of the Creative Commons Attribution (CC BY 4.0) License. See: <http://creativecommons.org/licenses/by/4.0/>

### REFERENCES

- Sanfilippo JS. Surgery for benign disease of the ovary. In: Rock JA, ed. *Te Linde's Operative Gynecology*. 10th ed. Philadelphia, Pennsylvania: Wolters Kluwer Health; 2008:629-647.
- Chiou SY, Lev-Toaff AS, Masuda E, et al. Adnexal torsion: new clinical and imaging observations by sonography, computed tomography, and magnetic resonance imaging. *J Ultrasound Med*. 2007;26(10):1289-301.
- Swenson DW, Lourenco AP, Beaudoin FL, et al. Ovarian torsion: case-control study comparing the sensitivity and specificity of ultrasonography and computed tomography for diagnosis in the emergency department. *Eur J Radiol*. 2014;83(4):733-8.
- Rha SE, Byun JY, Jung SE, et al. CT and MR imaging features of adnexal torsion. *Radiographics*. 2002;22(2):283-94.
- Vijayaraghavan SB. Sonographic whirlpool sign in ovarian torsion. *J Ultrasound Med*. 2004;23(12):1643-9.

# Enterocutaneous Fistula and Abscess Diagnosed with Point-of-care Ultrasound

Sarah McCuskee, MD, MPH\*  
Kenton L. Anderson, MD†

\*New York University School of Medicine, Department of Emergency Medicine, New York, New York

†Stanford University School of Medicine, Department of Emergency Medicine, Palo Alto, California

Section Editor: Shadi Lahham, MD

Submission history: Submitted February 1, 2021; Revision received April 12, 2021; Accepted April 21, 2021

Electronically published October 5, 2021

Full text available through open access at [http://escholarship.org/uc/uciem\\_cpem](http://escholarship.org/uc/uciem_cpem)

DOI: 10.5811/cpcem.2021.4.49918

**Case Presentation:** A 64-year-old female with history of umbilical hernia repair with mesh 18 years prior, cystocele, and diabetes mellitus presented with 10 days of abdominal and flank pain. The patient was tachycardic, normotensive, afebrile, and had an erythematous, tender, protuberant abdominal wall mass. Point-of-care ultrasound (POCUS) revealed an irregular, heterogeneous extraperitoneal fluid collection with intraperitoneal communication; these findings were consistent with an abscess and infected mesh with evidence for intraperitoneal extension. The diagnosis of enterocutaneous fistula (ECF) with infected mesh and abdominal wall abscess was confirmed with computed tomography and the patient was admitted for antibiotics and source control.

**Discussion:** A rare complication of hernia repair with mesh, ECF typically occurs later than more common complications including cellulitis, hernia recurrence, and bowel obstruction. In the emergency department, POCUS is commonly used to evaluate for abscess; in other settings, comprehensive ultrasound is used to evaluate for complications after hernia repair with mesh. However, to date there is no literature reporting POCUS diagnosis of ECF or mesh infection. This case suggests that distant surgery should not preclude consideration of mesh infection and ECF, and that POCUS may be useful in evaluating for these complications. [Clin Pract Cases Emerg Med. 2021;5(4):470–472.]

**Keywords:** *ultrasound; fistula; hernia repair.*

## CASE PRESENTATION

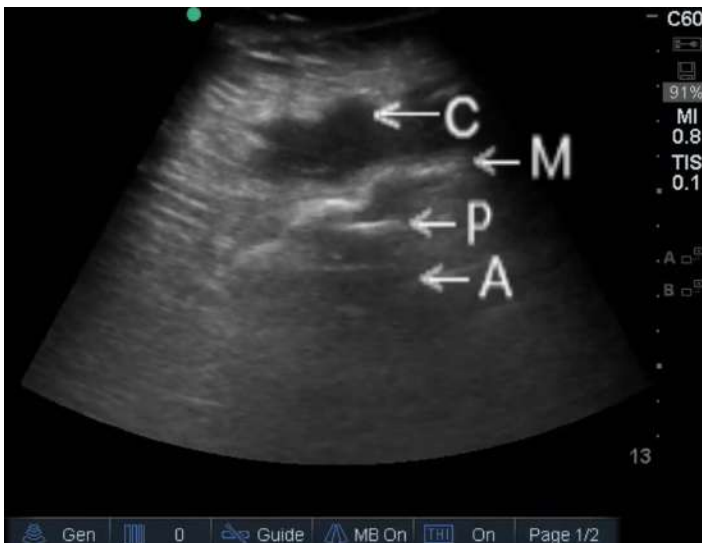A 64-year-old female with history of umbilical hernia repair with mesh 18 years prior, cystocele, and diabetes mellitus presented to the emergency department (ED) with 10 days of abdominal and flank pain. She also had alternating constipation and diarrhea, nausea, anorexia, and chills. She delayed her presentation due to cost. At presentation, the patient was tachycardic (heart rate 116 beats per minute), normotensive (blood pressure 106/58 millimeters of mercury), and afebrile. Physical examination revealed a five-centimeter erythematous, tender, abdominal wall mass. The initial differential diagnosis included incarcerated hernia, diverticulitis, and abscess. Point-of-care ultrasound (POCUS) revealed an irregular, heterogeneous, extraperitoneal fluid

collection with intraperitoneal communication, consistent with abdominal wall abscess extending beyond the surgical mesh into the peritoneum (Video, Image 1).

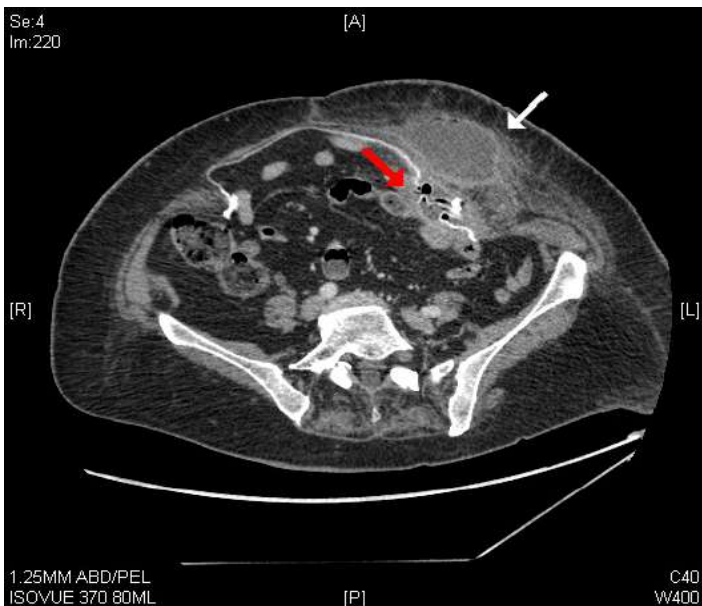
Computed tomography confirmed the enterocutaneous fistula (ECF) and abscess secondary to mesh migration and erosion into the small intestine (Image 2). The patient was admitted for intravenous antibiotics. Drain placement produced 90 milliliters of feculent pus.

## DISCUSSION

Erosion of surgical mesh into the intestinal wall and subsequent ECF formation is a rare complication of hernia repair with mesh. One series of 695 patients with mean follow-up of 4.9 years developed no ECFs,<sup>1</sup> while 3.5% of a



**Image 1.** Point-of-care ultrasound of the abdominal wall abscess, demonstrating surgical mesh (M) and associated fluid collection (C) extending across the peritoneum (P) and communicating with intraperitoneal abscess (A).



**Image 2.** Computed tomography showing extraperitoneal (white arrow) and intraperitoneal (red arrow) abscesses associated with mesh and small intestine.

200-patient series followed for a mean of 6.7 years developed ECFs at 3.3 years median postoperative time.<sup>2</sup> Fistula formation occurred later than more common complications including cellulitis, hernia recurrence, and bowel obstruction. Treatment involves resecting the fistula, associated intestine, and mesh.<sup>3</sup>

Abscesses are frequently diagnosed with POCUS in the emergency department;<sup>4</sup> however, to date no literature reports POCUS diagnosis of ECF or mesh infection. Comprehensive

*CPC-EM Capsule*

What do we already know about this clinical entity?

*Enterocutaneous fistula (ECF) is a rare complication of hernia repair with surgical mesh, which occurs later than other surgical complications.*

What is the major impact of the image(s)?

*This image demonstrates ECF occurring 18 years after hernia repair, diagnosed using point-of-care ultrasound in the emergency department.*

How might this improve emergency medicine practice?

*Distant surgery does not rule out mesh infection and ECF, and point-of-care ultrasound may be useful in making the diagnosis.*

ultrasonography is used to diagnose mesh infections after hernia repair.<sup>5</sup> Abscess due to mesh infection is sonographically similar to abscess from other sources; mesh and bowel function are particularly well visualized with sonography.<sup>5</sup> This case suggests that distant surgery should not preclude consideration of mesh infection and ECF, and that POCUS is useful in evaluating for these complications.

**Video.** Point-of-care ultrasound of the abdominal wall abscess, demonstrating a heterogenous fluid collection (C) associated with surgical mesh (M) extending across the peritoneum (P) and communicating with intraperitoneal abscess (A).

The authors attest that their institution requires neither Institutional Review Board approval, nor patient consent for publication of this case report. Documentation on file.

**Address for Correspondence:** Sarah McCuskee, MD, MPH, NYU School of Medicine, Department of Emergency Medicine, 462 First Avenue, Room A340, New York, NY 10016. Email: [smccuskee@post.harvard.edu](mailto:smccuskee@post.harvard.edu)

**Conflicts of Interest:** By the CPC-EM article submission agreement, all authors are required to disclose all affiliations, funding sources and financial or management relationships that could be perceived as potential sources of bias. The authors disclosed none.

**Copyright:** © 2021 McCuskee. This is an open access article distributed in accordance with the terms of the Creative Commons Attribution (CC BY 4.0) License. See: <http://creativecommons.org/licenses/by/4.0/>



**REFERENCES**

1. Brandi CD, Roche S, Bertone S, et al. No enterocutaneous fistula development in a cohort of 695 patients after incisional hernia repair using intraperitoneal uncoated polypropylene mesh. *Hernia*. 2017;21(1):101-6.
2. Leber GE, Garb JL, Alexander AI, et al. Long-term complications associated with prosthetic repair of incisional hernias. *Arch Surg*. 1998;133(4):378-82.
3. Costa D, Tomás A, Lacueva J, et al. Late enterocutaneous fistula as a complication after umbilical hernioplasty. *Hernia*. 2004;8(3):271-2.
4. Tayal VS, Hasan N, Norton HJ, et al. The effect of soft-tissue ultrasound on the management of cellulitis in the emergency department. *Acad Emerg Med*. 2006;13(4):384-8.
5. Crespi G, Giannetta E, Mariani F, et al. Imaging of early postoperative complications after polypropylene mesh repair of inguinal hernia. *Radiol Med*. 2004;108(1-2):107-15.

# Gastric Pneumatosis: An Atypical Presentation of Desmoid Tumor

Catarina Jorge, MD\*  
Miguel Varela, MD†  
Júlio Ricardo Soares, MD‡  
Hugo Uribe, MD†  
Luis Flores, MD†  
Javier Moreno, MD†

\*University Hospital Centre of Algarve - Faro Unit, Department of Internal Medicine, Faro, Portugal

†University Hospital Centre of Algarve - Faro Unit, Department of Emergency and Intensive Care, Faro, Portugal

‡University Hospital Centre of Algarve - Faro Unit, Department of Anesthesiology, Faro, Portugal

Section Editor: Rick McPheeters, DO

Submission history: Submitted November 7, 2020; Revision received May 7, 2021; Accepted May 11, 2021

Electronically published August 27, 2021

Full text available through open access at [http://escholarship.org/uc/uciem\\_cpccem](http://escholarship.org/uc/uciem_cpccem)

DOI: 10.5811/cpcem.2021.5.50803

**Case presentation:** A middle-aged woman presented to the emergency department with a chief complaint of abdominal pain, fever, vomiting, and diarrhea. Abdominal computed tomography revealed gastric pneumatosis and air in the portal system. The patient had an unfavorable clinical course with pneumoperitoneum and septic shock due to secondary peritonitis. She underwent emergency laparotomy where neof ormation of the mesentery root was found with infiltration of the small intestine and jejunal perforation. The anatomopathological study of the tumor revealed that it was a desmoid tumor.

**Discussion:** To our knowledge this is the first report in the literature of gastric pneumatosis as the initial presentation of a mesenteric desmoid tumor. Although it usually has a benign clinical course, its locally invasive characteristics can lead to critical illness. Physicians shouldn't overlook these types of complications, as early identification and surgical intervention can modify the prognosis and shorten hospital stay. [Clin Pract Cases Emerg Med. 2021;5(4):473–475.]

**Keywords:** *Gastric pneumatosis; desmoid tumor; septic shock.*

## CASE PRESENTATION

A 52-year-old woman with no pertinent past medical history presented to the emergency department for vomiting and diarrhea for one week. The patient also experienced fever and abdominal pain over the previous 24 hours. Upon initial evaluation, she was alert, hemodynamically stable, and afebrile. The abdomen was soft and depressible, nontender and nondistended. Laboratory tests showed an increased lactic acid of 2.5 millimoles per liter (mmol/L) (reference range: 0.5-2 mmol/L), and C-reactive protein of 149 milligrams (mg)/L (<5 mg/L), unchanged hepatic and renal function tests, without other relevant changes. Abdominal-pelvic computed tomography (APCT) revealed marked gastric distension with gastric pneumatosis (GP), parietal thickening of the jejunoileal loops, and air in the portal system (Image).

Upper gastrointestinal endoscopy revealed no disruption of the gastric mucosa or signs of ischemia. Exploratory laparoscopy was performed showing no evidence of visceral pathology. Subsequently, due to the worsening of abdominal pain and fever, a new APCT was ordered, revealing pneumoperitoneum and peritoneal fluid. Emergent laparotomy was performed, which revealed jejunum perforation with peritonitis. Exploration of the abdominal cavity found neof ormation of the root of the mesentery with infiltration of the small intestine. The patient had a segmental enterectomy and excision of tumor of the mesentery (7 centimeters), which was adherent to the intima of the third portion of the duodenum, the jejunum, and invasion of the superior mesenteric artery.

After operative repair, the patient was admitted to the intensive care unit (ICU) due to septic shock most likely

caused by peritonitis. She had a prolonged hospitalization in the ICU for a total of 24 days, with several surgical revisions, requiring invasive ventilation for 19 days and vasopressor support for five days. Her condition gradually improved, due to antibiotics and surgical revisions, with resolution of organ dysfunctions. Histological analysis of neoformation revealed that it was an intra-abdominal desmoid tumor (DT).

The patient was discharged from the hospital after 45 days and was followed up with oncology consultation. After six months of follow-up, she presented with tumor recurrence and, in discussion with a solid tumors reference center, it was decided to start systemic treatment with tamoxifen and indomethacin.

## DISCUSSION

Gastric pneumatosis is a rare radiological entity defined by the presence of air inside the gastric wall.<sup>1</sup> Pneumatosis intestinalis can occur in any part of the gastrointestinal tract, although GP is an uncommon localization.<sup>2</sup> Gastric pneumatosis can be caused by ischemia, infection, mucosal disruption, endoscopic procedure, connective tissue diseases and, rarely, by tumors.<sup>1-3</sup> Desmoid tumors are benign but locally invasive and rare, with an estimated prevalence of 0.03%.<sup>4</sup> Only one case of abdominal DT with hepatic pneumatosis has been reported.<sup>5</sup>

The present case represents the first, atypical, presentation of a DT, which usually has a benign clinical course, but its locally invasive characteristics can lead to critical illness, such as this one. Early identification and urgent surgical intervention influence the prognosis. This image should raise awareness for a possible neoplastic entity as a differential diagnosis, not forgetting that complications may occur as well as the possible need for intensive care.

The authors attest that their institution requires neither Institutional Review Board approval, nor patient consent for publication of this case report. Documentation on file.

### CPC-EM Capsule

What do we already know about this clinical entity?

*Gastric pneumatosis (GP) is a rare radiological entity defined by the presence of air inside the gastric wall. Desmoid tumor (DT) is unusual and benign, but locally invasive and can cause critical illness.*

What is the major impact of the image(s)?

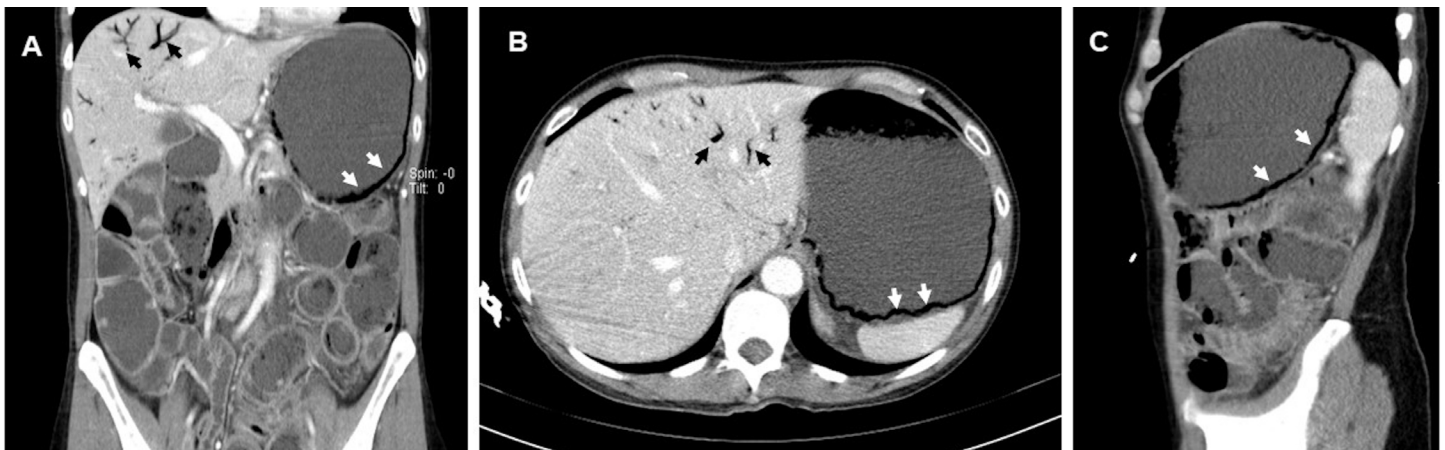
*An atypical case of GP as the first manifestation of a mesenteric DT, which is properly illustrated in this image, but never before reported in the literature.*

How might this improve emergency medicine practice?

*Raising awareness for neoplastic etiology of GP and its possible complications that may require intensive care. Its early identification and urgent surgery modify the prognosis.*

*Address for Correspondence:* Catarina Jorge, MD, University Hospital Centre of Algarve, Department of Internal Medicine, Rua Leão, Faro, Portugal, 8000-386. Email: catarinabjorge@gmail.com.

*Conflicts of Interest:* By the CPC-EM article submission agreement, all authors are required to disclose all affiliations, funding sources and financial or management relationships that could be perceived as potential sources of bias. The authors disclosed none.



**Image.** Abdominal-pelvic computed tomography (A - coronal; B- axial; C- sagittal) showing gastric pneumatosis (white arrow) and hepatic portal venous gas (black arrow).

Copyright: © 2021 Jorge et al. This is an open access article distributed in accordance with the terms of the Creative Commons Attribution (CC BY 4.0) License. See: <http://creativecommons.org/licenses/by/4.0/>

## REFERENCES

1. Johnson PT, Horton KM, Edil BH, et al. Gastric pneumatosis: the role of CT in diagnosis and patient management. *Emerg Radiol.* 2011;18(1):65-73.
2. Voboril R. Pneumatosis cystoides intestinalis: a review. *Acta Medica (Hradec Kralove)*. 2001;44(3):89–92.
3. Bilici A, Karadag B, Doventas A, et al. Gastric pneumatosis intestinalis associated with malignancy: an unusual case report. *World J Gastroenterol.* 2009;15(6):758-60.
4. Reitamo JJ, Häyry P, Nykyri E, et al. The desmoid tumor. I. Incidence, sex-, age- and anatomical distribution in the Finnish population. *Am J Clin Pathol.* 1982;77(6):665-73.
5. Prat A, Peralta S, Cuéllar H, et al. Hepatic pneumatosis as a complication of an abdominal desmoid tumor. *J Clin Oncol.* 2007;25(7):897-8.



## SAPHO Syndrome: An Unusual Cause of Dysphagia

Megan Hoffer, DO  
Michaela Salvo, MD  
Sonal Batra, MD, MST

The George Washington School of Medicine and Health Sciences, Department of  
Emergency Medicine, Washington, District of Columbia

Section Editor: Melanie Heniff, MD, JD

Submission history: Submitted April 30, 2021; Revision received June 24, 2021; Accepted June 25, 2021

Electronically published September 9, 2021

Full text available through open access at [http://escholarship.org/uc/uciem\\_cpccem](http://escholarship.org/uc/uciem_cpccem)

DOI: 10.5811/cpcem.2021.6.53001

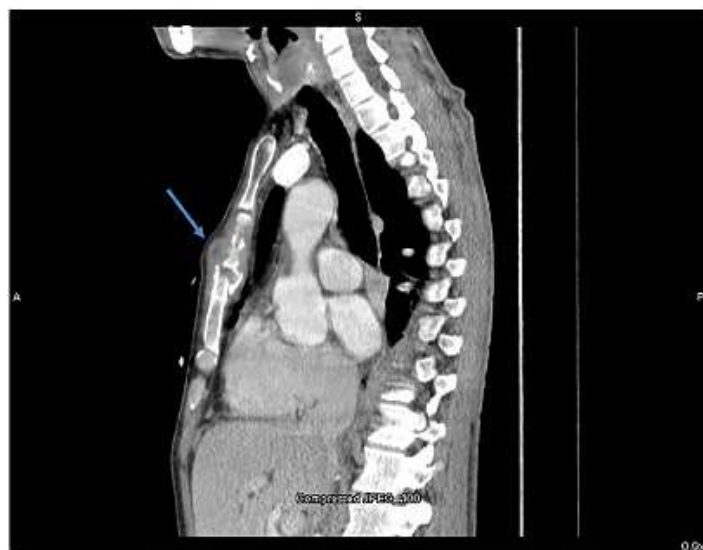**Case Presentation:** This case describes a 51-year-old male who presented to the emergency department with a complaint of two weeks of progressively worsening dysphagia as well as the emergence of superficial fluid collections on the anterior chest and leg during the same period. Computed tomography showed retropharyngeal and paratracheal fluid collections with adjacent vertebral osteitis; however, biopsies were negative for any infectious or mycobacterial source, and instead showed chronic inflammatory changes.

**Discussion:** Synovitis, acne, pustulosis, hyperostosis, osteitis (SAPHO) syndrome is a rare rheumatic disorder that presents with multifocal osteitis and sterile neutrophilia. SAPHO syndrome may be easily mistaken for a diffuse infectious process on initial evaluation and imaging; however, it is treated with anti-inflammatory medications, including non-steroidal anti-inflammatory drugs and corticosteroids. Although most patients achieve remission of symptoms with treatment, the location of the fluid collections and resultant bony destruction may be life-threatening if undiagnosed. [Clin Pract Cases Emerg Med. 2021;5(4):476–478]

**Keywords:** *dysphagia; SAPHO syndrome; emergency department.*

### CASE PRESENTATION

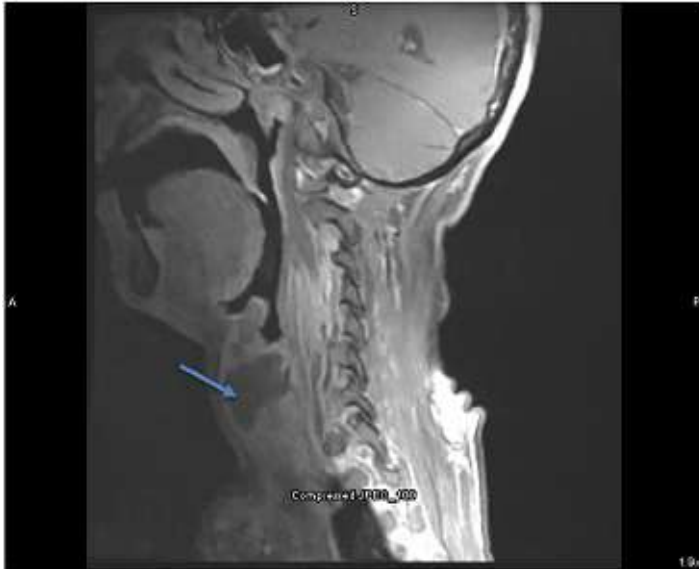
A 51-year-old male with a history of human immunodeficiency virus presented to the emergency department (ED) with two weeks of progressively worsening hoarseness and dysphagia. During the same period of time, he noted the development of two superficial fluctuant areas on the anterior chest and right leg. The patient denied any associated symptoms, including fever. He was born in Brazil and had a negative tuberculosis (TB) test in the United States. During the interview, he was notably hoarse but otherwise non-toxic in appearance. On examination, he had an area of fullness adjacent to the trachea, and a tender, fluctuant mass on the anterior chest. His lungs were clear to auscultation, no stridor was appreciated, and he had no pharyngeal erythema on inspection. He was afebrile, with oxygen saturation of 99% on room air with normal work of breathing and otherwise unremarkable vital signs. Laboratory workup was unremarkable, and computed tomography of the neck and thorax were obtained (Image 1).



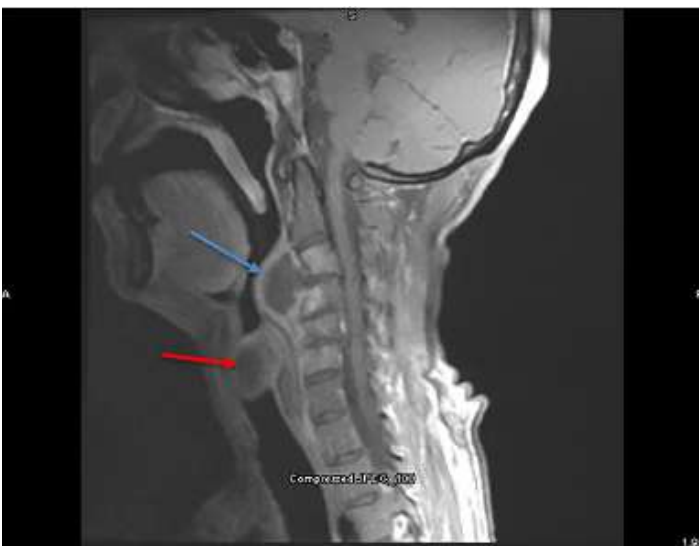**Image 1.** Computed tomography of the chest with contrast (sagittal view) showing fluid enhancing mass overlying the sternum with bony destruction of the sternum (blue arrow).

## CASE DISCUSSION

Synovitis, acne, pustulosis, hyperostosis, osteitis (SAPHO) syndrome. Computed tomography showed multiple fluid collections in the soft tissues of the neck, chest, and lung, with bony destruction of the sternum and vertebrae. Magnetic resonance imaging showed retropharyngeal fluid collection with vertebral osteitis (Images 2-3). Otolaryngology was consulted in the ED, and the fluid collections were biopsied. Broad spectrum antibiotics were initiated, and he was admitted for further inpatient care and anticipated



**Image 2.** Magnetic resonance imaging of the neck (sagittal view) showing anterior fluid collection partially obstructing the trachea (blue arrow).



**Image 3.** Magnetic resonance imaging of the neck (sagittal view) showing two more enhancing fluid collections, one retropharyngeally abutting the first and second cervical vertebrae (blue arrow), and the other extending into the trachea (red arrow).

### *CPC-EM Capsule*

What do we already know about this clinical entity?

*Synovitis, acne, pustulosis, hyperostosis, osteitis syndrome is a rare sterile neutrophilic disorder producing fluid-filled collections which may invade local structures.*

What is the major impact of the image(s)?

*Although the fluid collections may be benign, their location may result in airway compromise and destruction of local bony structures.*

How might this improve emergency medicine practice?

*The presence of a superficial fluid collection in conjunction with 'red-flag' symptoms such as dysphagia warrants imaging to identify lesions in high risk areas.*

otolaryngology intervention. Although initially concerning for a diffuse infectious process, cultures of the fluid collections were negative and pathology showed chronic inflammatory changes with areas of necrosis. Serial TB tests, blood cultures, and an echocardiogram were also negative.

This syndrome is a rare, sterile neutrophilic disorder that can be characterized by multifocal sterile osteitis, most often involving the anterior chest.<sup>1</sup> The diagnosis is made clinically once infectious etiologies are excluded. One theory for the etiology of the disorder is an autoimmune reaction to the common *Propionibacterium acnes* bacteria.<sup>2</sup> Treatment consists of non-steroidal anti-inflammatories, corticosteroids, tumor necrosis factor-alpha inhibitors, and bisphosphonates.<sup>3</sup> Once the condition is identified, patients typically respond well to treatment with remission of symptoms.<sup>4</sup> Following his admission, the patient underwent incision and drainage of the fluid collections adjacent to the trachea with otolaryngology, and recovered well with no complications. He was discharged home to continue outpatient care with rheumatology.

Patient consent has been obtained and filed for the publication of this case report.

The authors attest that their institution does not require Institutional Review Board approval for publication of this case report. Documentation on file.

---

*Address for Correspondence:* Megan Hoffer, DO, The George Washington University School of Medicine and Health Sciences, Department of Emergency Medicine, 900 23<sup>rd</sup> Street NW, Washington, District of Columbia 20037. Email: [meganhoffer@gwu.edu](mailto:meganhoffer@gwu.edu).

*Conflicts of Interest:* By the *CPC-EM* article submission agreement, all authors are required to disclose all affiliations, funding sources and financial or management relationships that could be perceived as potential sources of bias. The authors disclosed none.

*Copyright:* © 2021 Hoffer. This is an open access article distributed in accordance with the terms of the Creative Commons Attribution ([CC BY 4.0](https://creativecommons.org/licenses/by/4.0/)) License. See: <http://creativecommons.org/licenses/by/4.0/>.

---

## REFERENCES

1. Nguyen MT, Borchers A, Selmi C, et al. The SAPHO syndrome. *Semin Arthritis Rheum.* 2012;42(3):254-65.
2. Zimmermann P and Curtis N. Synovitis, acne, pustulosis, hyperostosis, and osteitis (SAPHO) syndrome: a challenging diagnosis not to be missed. *J Infect.* 2016;72:Suppl:S106-14.
3. Cianci F, Zoli A, Gremese E, et al. Clinical heterogeneity of SAPHO syndrome: challenging diagnosis and treatment. *Clin Rheumatol.* 2017;36(9):2151-8.
4. Hayem G, Bouchaud-Chabot A, Benali K, et al. SAPHO syndrome: a long-term follow-up study of 120 cases. *Semin Arthritis Rheum.* 1999;29(3):159-71.

# Pacemaker Lead Migration and Ventricular Perforation in a Patient Presenting with Chest Pain

Maria C. Cañizares-Otero, MD  
Mauricio Danckers, MD

Aventura Hospital & Medical Center, Department of Critical Care Medicine,  
Aventura, Florida

Section Editor: Manish Amin, DO

Submission History: Submitted April 4, 2021; Revision received July 20, 2021; Accepted July 15, 2021

Electronically published September 9, 2021

Full text available through open access at [http://escholarship.org/uc/uciem\\_cpem](http://escholarship.org/uc/uciem_cpem)

DOI: 10.5811/cpem.2021.7.52689

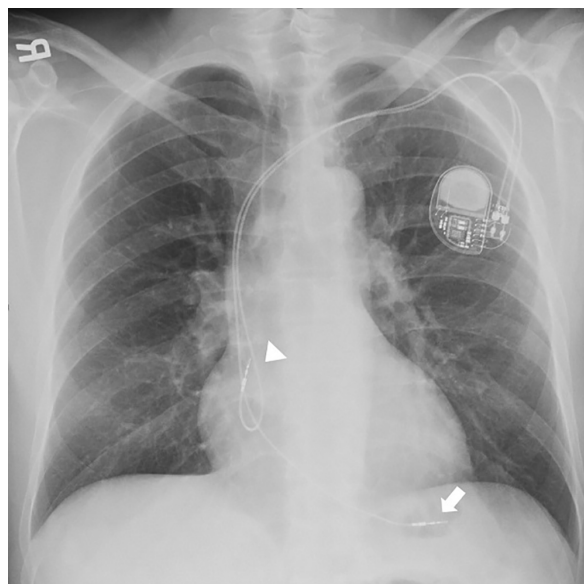
**Case Presentation:** We describe a middle-age male with a past medical history of second-degree atrioventricular block type II status post permanent pacemaker placement the day prior who presented to the emergency department complaining of chest pain. Electrocardiography showed a non-paced ventricular rhythm. Chest radiograph showed the ventricular pacemaker lead located distally overlying the right ventricle apical area. On further investigation, chest computed tomography showed a perforation of the ventricular wall by the pacemaker lead prompting urgent intervention by the cardiothoracic surgery team for lead replacement and right ventricular repair.

**Discussion:** Our case illustrates the importance of timely recognition of a perforated pacemaker lead in a patient presenting with chest pain after device implantation. We additionally describe the risk factors for ventricular perforation, initial clinical presentation, and management approach. [Clin Pract Cases Emerg Med. 2021;5(4):479-481.]

**Keywords:** *pacemaker; ventricular lead; perforation; chest pain.*

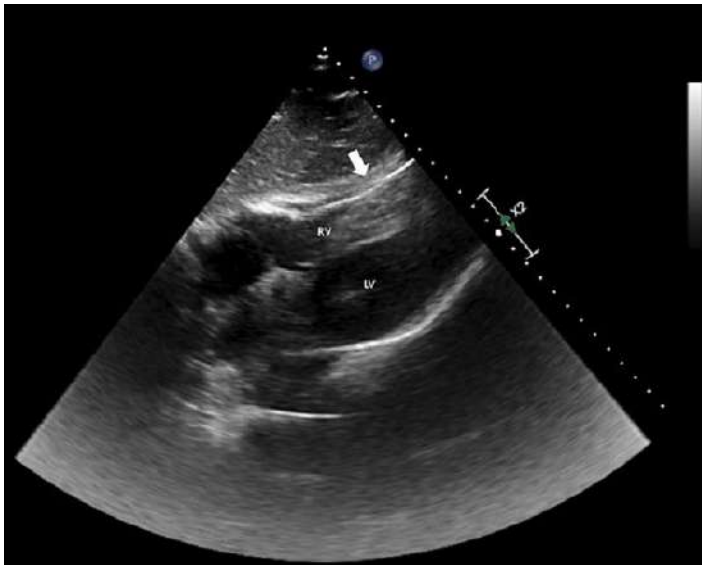
## CASE PRESENTATION

A 52-year-old man with second-degree type II atrioventricular (AV) block and recent dual-chamber pacemaker placement presented to the emergency department with left sided chest pain for the prior two hours. Electrocardiogram showed a second-degree AV block with a ventricular rate of 45 beats per minute. Pacemaker interrogation revealed atrial sensing without ventricular capture. His chest pain was exacerbated with electrical stimulation despite lack of capture and resolved after disabling the pacemaker. Further imaging (chest radiograph [CXR] and point-of-care echocardiogram) revealed ventricular pacer lead mispositioned and a possible cause of acute chest pain (Images 1, 2). Coronal computed tomography (CT) of the chest confirmed lead migration beyond the right ventricle chamber. The patient was emergently taken to the operating room. Exploratory sternotomy confirmed ventricle perforation (Image 3). The patient underwent lead extraction, right ventriculorrhaphy, and epicardial right ventricle pacemaker lead placement. He was discharged home on hospital day four.



**Image 1.** Chest radiograph revealing ventricular pacer lead located distally overlying the right ventricle apical area (arrow) and atrial pacer lead within right atrium area (arrowhead).

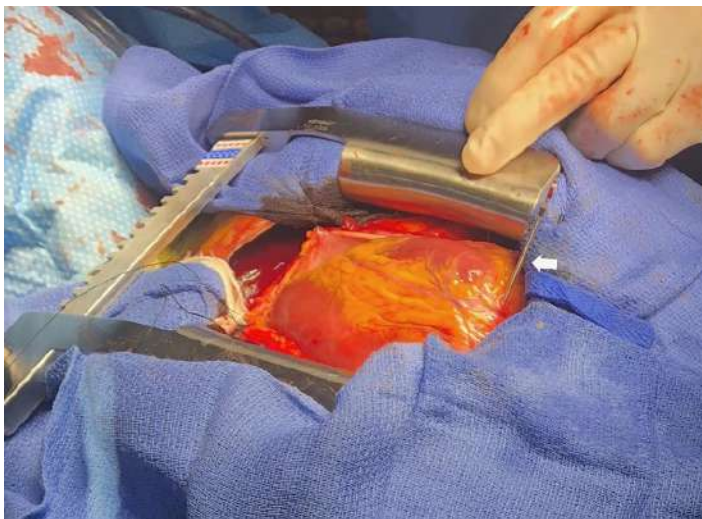




**Image 2.** Point-of-care echocardiogram subcostal view during systole showing ventricular pacer lead (arrow) beyond right ventricular chamber. No pericardial effusion is seen. RV, right ventricle; LV, left ventricle.

## DISCUSSION

Pacemaker lead ventricular perforation is a rare event that occurs in 0.4-5.2% of pacemaker lead placements.<sup>1</sup> Prompt diagnosis requires high clinical suspicion in patients with chest pain and recent history of device placement or lead exchange. Presentation can be acute, subacute, or delayed; perforation most commonly occurs within the first month of placement.<sup>1,2</sup> Risk factors for perforation include prior temporary pacemaker placement, active fixation leads, female gender, and recent steroid use. The pathophysiology of



**Image 3.** Mediastinal exploration via sternotomy revealing ventricular lead piercing through the right ventricular apex (arrow).

### *CPC-EM Capsule*

What do we already know about this clinical entity?

*Pacemaker lead ventricular perforation is a rare complication of pacemaker placement and can present with chest pain, dyspnea, dizziness, syncope, or pacemaker failure.*

What is the major impact of the image(s)?

*Chest radiography followed by point of care echocardiography or computed tomography of the chest are readily available imaging studies to support the diagnosis.*

How might this improve emergency medicine practice?

*Emergency physicians should have a high index of suspicion for pacemaker lead perforation in the clinical setting of chest pain and recent pacemaker placement.*

perforation is attributed to continuous pressure of the thin lead per unit of the myocardial wall.<sup>2,3</sup> Perforation of the right ventricular apex is the area most commonly prone to perforation due to weakness of the wall.

Chest pain, dyspnea, dizziness, syncope, and pacing or sensing pacemaker failure are commonly encountered clinical scenarios. Point-of-care echocardiogram allows for the clinician to promptly rule out emergent conditions such as hemorrhagic pericardial tamponade. Additional workup includes CXR and echocardiogram to evaluate for pericardial effusion; however, a non-contrast CT is usually required to confirm the diagnosis. Management is targeted based on patient's clinical stability and the extent of injuries to nearby structures.<sup>4,5</sup> Clinically unstable or symptomatic patients often need emergent surgical repair.

Patient consent has been obtained and filed for the publication of this case report. The authors attest that their institution does not require Institutional Review Board approval for publication of this case report.

Address for Correspondence: Maria C. Cañizares-Otero, MD, Aventura Hospital & Medical Center, Department of Critical Care Medicine, 20900 Biscayne Boulevard, Aventura, Florida 33180. Email: [maria.canizaresotero@hcahealthcare.com](mailto:maria.canizaresotero@hcahealthcare.com)

**Conflicts of Interest:** By the CPC-EM article submission agreement, all authors are required to disclose all affiliations, funding sources and financial or management relationships that could be perceived as potential sources of bias. The authors disclosed none.

**Copyright:** © 2021 Cañizares-Otero. This is an open access article distributed in accordance with the terms of the Creative Commons Attribution (CC BY 4.0) License. See: <http://creativecommons.org/licenses/by/4.0/>

## REFERENCES

1. Khan MN, Joseph G, Khaykin Y, et al. Delayed lead perforation: a disturbing trend. *Pacing Clin Electrophysiol.* 2005;28(3):251-3.
2. Sterliński M, Przybylski A, Maciag A, et al. Subacute cardiac perforations associated with active fixation leads. *Europace.* 2009;11(2):206-12.
3. Hirschl DA, Jain VR, Spindola-Franco H, et al. Prevalence and characterization of asymptomatic pacemaker and ICD lead perforation on CT. *Pacing Clin Electrophysiol.* 2007;30(1):28-32.
4. Akbarzadeh MA, Mollazadeh R, Sefidbakht S, et al. Identification and management of right ventricular perforation using pacemaker and cardioverter-defibrillator leads: a case series and mini review. *J Arrhythm.* 2017;33(1):1-5.
5. Sivakumaran S, Irwin ME, Gulamhusein SS, et al. Postpacemaker implant pericarditis: incidence and outcomes with active-fixation leads. *Pacing Clin Electrophysiol.* 2002;25(5):833-7.
6. Ahmed A, Shokr M, Lieberman R. Subacute right ventricular perforation by pacemaker lead causing left-sided hemothorax and epicardial hematoma. *Case Rep Cardiol.* 2017;2017:1264734.

## Adrenocortical Carcinoma Discovered with Point-of-care Ultrasound

Mark McIntyre, MD, MBA  
Michael I. Prats, MD

Ohio State University College of Medicine, Department of Emergency Medicine,  
Columbus, Ohio

Section Editor: Shadi Lahham, MD, MS

Submission history: Submitted January 25, 2021; Revision received May 27, 2021; Accepted May 28, 2021

Electronically published October 5, 2021

Full text available through open access at [http://escholarship.org/uc/uciem\\_cpem](http://escholarship.org/uc/uciem_cpem)

DOI: 10.5811/cpem.2021.5.51875

**Case Presentation:** A 34-year-old woman presented to the emergency department with bilateral lower extremity edema and shortness of breath. She had been seen by her primary care provider. Lab work and a follow-up with endocrinology had been unrevealing. Using point-of-care ultrasound we identified a cystic mass in the right upper quadrant prompting further imaging.

**Discussion:** Abdominal and pelvic computed tomography confirmed a mass in the right posterior liver, which was later identified as an adrenocortical carcinoma. Ultrasound is an important diagnostic tool in the setting of lower extremity edema and can be used to assess for heart failure, liver failure, obstructive nephropathy, venous thrombosis, and soft tissue infection. In this case, ultrasound helped expedite the diagnosis and treatment of a rare malignancy. [Clin Pract Cases Emerg Med. 2021;5(4):482–484.]

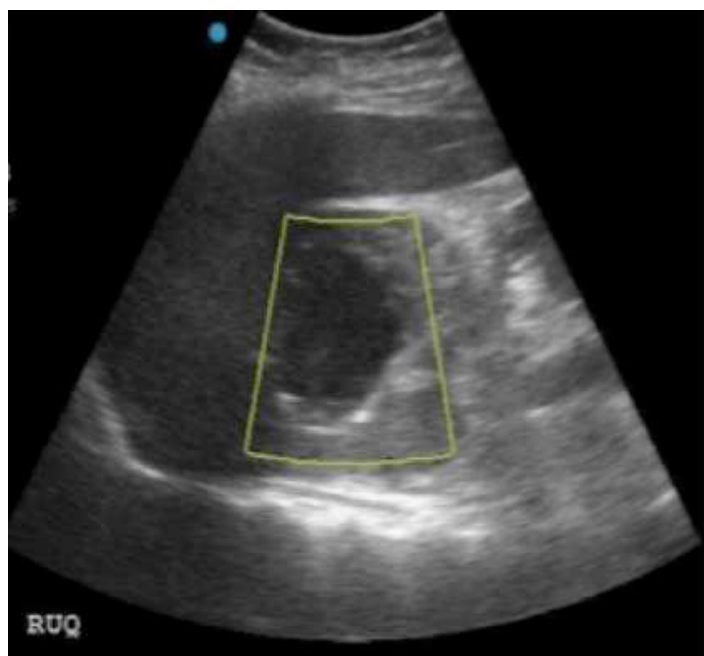
**Keywords:** *ultrasound; imaging; malignancy; oncology; adrenocortical carcinoma.*

### CASE PRESENTATION

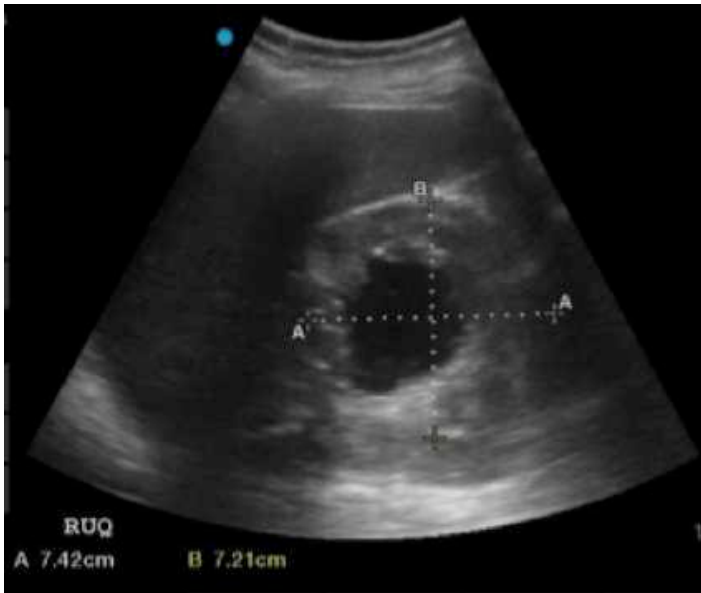A 34-year-old woman presented to the emergency department (ED) with progressive leg swelling. Thorough laboratory testing as an outpatient and in the ED was unrevealing. To evaluate further the causes of her dyspnea and edema, we performed a point-of-care ultrasound (POCUS) of the heart, lungs, and abdomen. While evaluating for evidence of ascites, a large mass with anechoic center was identified in the right upper quadrant (Video, Images 1 and 2). This prompted computed tomography (CT) of the abdomen and pelvis, which confirmed a 7.9 x 9.1 x 8.7 centimeter mass arising from the right posterior liver, extending into the inferior vena cava with an associated near-occlusive tumor thrombus (Image 3). During admission, a biopsy was performed revealing adrenocortical carcinoma (ACC).

### DISCUSSION

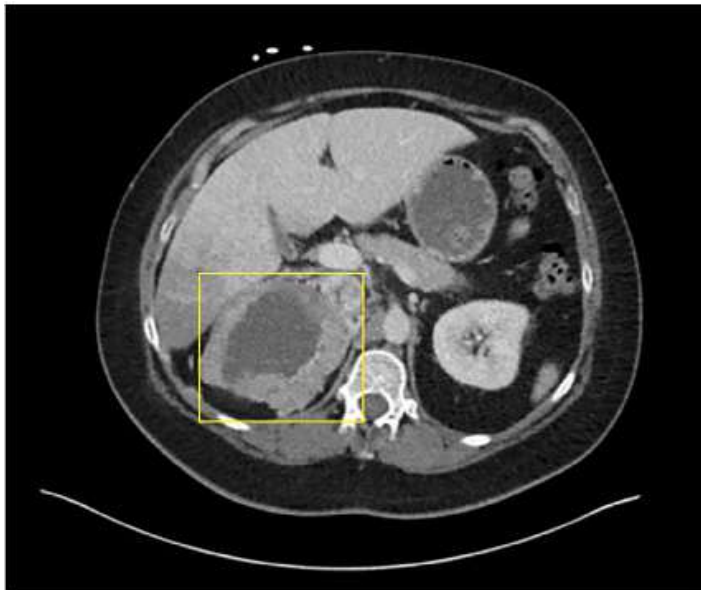Adrenocortical carcinomas can present as either non-secreting or hormone secreting.<sup>1</sup> The diagnostic workup for ACC includes the measurement of steroid hormones produced by tumor, imaging via contrast-enhanced CT or magnetic



**Image 1.** Upper quadrant mass seen on emergency physician-performed point-of-care ultrasound. Color Doppler demonstrating no flow (yellow box).



**Image 2.** Right upper quadrant mass seen on emergency physician-performed point-of-care ultrasound. Measurements showing 7.42 x 7.21 cm in cephalad-caudal and lateral dimensions, respectively.



**Image 3.** Axial computed tomography demonstrating cystic mass in right upper quadrant (yellow box).

resonance, and biopsy if indicated.<sup>2</sup> An ACC can be quite large, which incurs a higher risk of complications such as vasculature obstruction, related to the size of the malignancy.<sup>3</sup> Thus, it is important to identify these tumors expeditiously and begin treatment as soon as possible. The sonographic appearance of ACC is a large, heterogeneous solid or cystic mass positioned adjacent to the kidney.<sup>4</sup>

### *CPC-EM Capsule*

What do we already know about this clinical entity?

*Adrenocortical carcinomas present with a variety of symptoms. Typical diagnostic workup includes measuring steroid hormones, computed tomography or magnetic resonance imaging, and biopsy.*

What is the major impact of the image(s)?

*In these images, the utility of point-of-care ultrasound (POCUS) as a diagnostic tool is demonstrated in the setting of unclear symptom etiology.*

How might this improve emergency medicine practice?

*Using POCUS can help narrow differential diagnosis, identify symptom etiology, and expedite treatment.*

There is a broad differential diagnosis for a patient presenting to the ED with lower extremity edema. Point-of-care ultrasound has proven useful in diagnosing many of these etiologies such as acute heart failure, ascites, obstructive nephropathy, venous thromboembolic disease, and soft tissue infection.<sup>5</sup> In this case, a systematic POCUS evaluation revealed an unexpected cause for the patient's symptoms, thus expediting her workup and treatment. Multiorgan POCUS is a reasonable early step in the diagnostic management of undifferentiated lower extremity edema. Emergency physicians should be able to recognize concerning sonographic findings and pursue the next steps in diagnostic testing for abdominal neoplasms.

**Video.** Right upper quadrant mass. Ultrasound transducer held in the posterior axillary line demonstrating a circular mass with an anechoic center (arrow) as the beam fans from anterior to posterior.

The author attests that their institution requires neither Institutional Review Board approval, nor patient consent for publication of this case report. Documentation on file.

**Address for Correspondence:** Michael I. Prats, MD, Ohio State University Wexner Medical Center, Department of Emergency Department, 757 Prior Hall, 376 W 10th Ave, Columbus, OH 43210. Email: Michael.prats@osumc.edu.

**Conflicts of Interest:** By the CPC-EM article submission agreement, all authors are required to disclose all affiliations,



funding sources and financial or management relationships that could be perceived as potential sources of bias. The authors disclosed none.

*Copyright:* © 2021 McIntyre. This is an open access article distributed in accordance with the terms of the Creative Commons Attribution (CC BY 4.0) License. See: <http://creativecommons.org/licenses/by/4.0/>

## REFERENCES

1. Libè R, Fratticci A, Bertherat J. Adrenocortical cancer: pathophysiology and clinical management. *Endocr Relat Cancer*. 2007;14(1):13-28.
2. Willatt J and Francis IR. Imaging and management of the incidentally discovered renal mass. *Cancer Imaging*. 2009;9 Spec No A(Special Issue A):S30-S37.
3. Amodru V, Taieb D, Guerin C, et al. Large adrenal incidentalomas require a dedicated diagnostic procedure. *Endocr Pract*. 2019;25(7):669-77.
4. Stapa RZ, Kasperlik-Zaluska AA, Migda B, et al. Echogenicity of benign adrenal focal lesions on imaging with new ultrasound techniques – report with pictorial presentation. *J Ultrason*. 2015;15(63):368-76.
5. ACEP Policy Statement. Ultrasound guidelines: emergency, point-of-care and clinical ultrasound guidelines in medicine. *Ann Emerg Med*. 2017; 69(5):e27-e54.

# Traumatic Anterior Dislocation of Ocular Cataract Lens

Tanvi Shirke, DO  
Kyle Wilcox, MD  
Thuyvi Luong, MD

Wellspring York Hospital, Department of Emergency Medicine, York, Pennsylvania

Section Editor: Shadi Lahham, MD

Submission History: Submitted April 8, 2021; Revision received July 17, 2021; Accepted July 16, 2021

Electronically published August 31, 2021

Full text available through open access at [http://escholarship.org/uc/uciem\\_cpem](http://escholarship.org/uc/uciem_cpem)

DOI: 10.5811/cpcem.2021.7.52725

**Case presentation:** A 33-year-old male presented to the emergency department following a motor vehicle collision with complaints of right eye pain after hitting his head on the steering wheel. Point-of-care ultrasound (POCUS) revealed retinal detachment and an anterior lens dislocation.

**Discussion:** Lens dislocations following blunt head trauma can often be diagnosed using POCUS. Anterior ocular lens dislocation is a rare but vision-threatening result of head trauma. This case highlights how POCUS can facilitate early detection of ocular pathology, such as lens dislocation, and improves patient outcomes. [Clin Pract Cases Emerg Med. 2021;5(4):485-487.]

**Keywords:** *traumatic lens dislocation; anterior lens dislocation; lens dislocation; retinal detachment; point-of-care ultrasound; POCUS.*

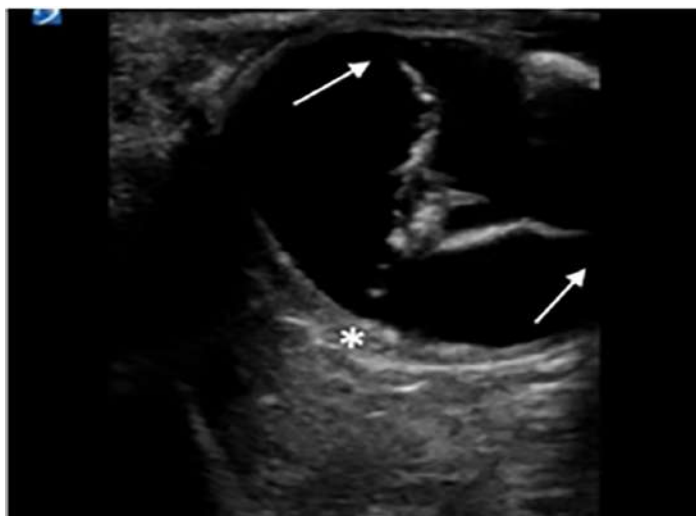## CASE PRESENTATION

A 33-year-old man with a history of blindness in his right eye from a congenital cataract presented to the emergency department with blunt head trauma sustained during a motor vehicle collision. He complained of right eye pain and foreign body sensation. On examination, a round white object was visualized within the anterior chamber; his head was otherwise atraumatic. The patient stated that the white spot had been present prior to the accident but had now changed in size and appearance, noting that the spot had enlarged following his injury.

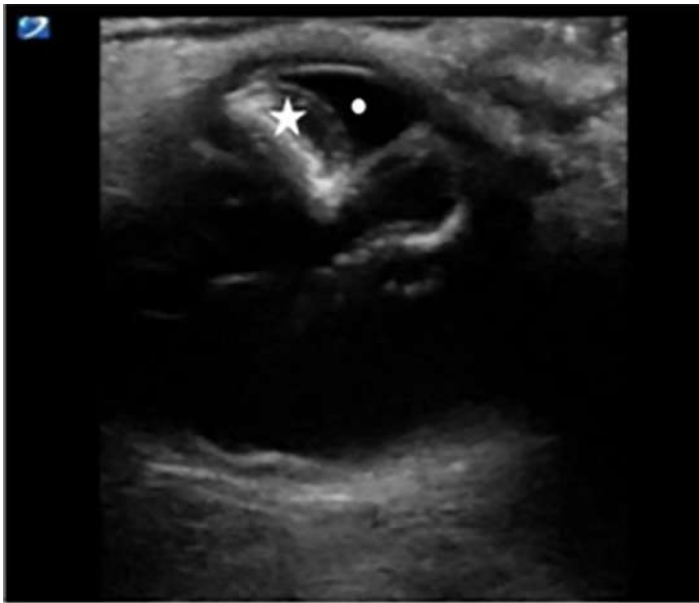
Fluorescein staining showed no abnormalities, and intraocular pressures were normal (18 millimeters mercury [mm Hg] right eye; 20 mm Hg left eye). Light perception was not present. Slit lamp examination demonstrated a round, white-speckled object in the dependent portion of the anterior chamber. Bedside ocular ultrasonography revealed a retinal detachment and an anterior dislocation of a cataract lens through the iris (Images 1-3). Ophthalmology was consulted; anterior lens dislocations are considered an ocular emergency as they can result in acute angle-closure glaucoma and corneal edema; however, given the patient's previous right-sided blindness they recommended next-day follow-up for operative repair.

## DISCUSSION

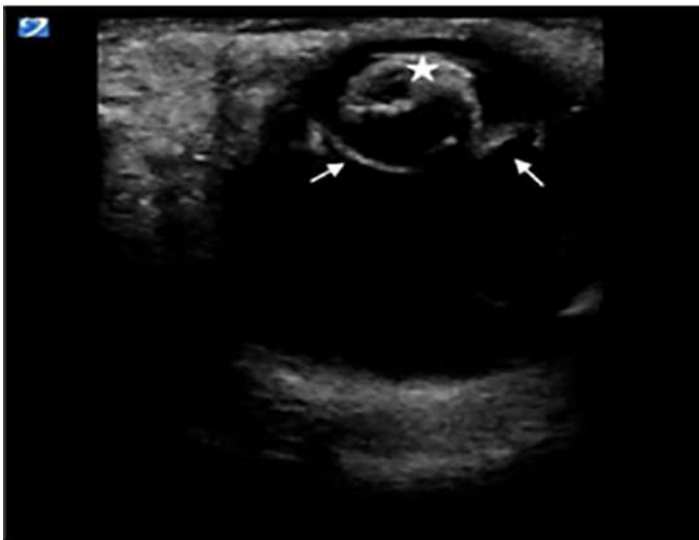Crystalline lens dislocation, or ectopia lentis, occurs primarily after blunt head trauma.<sup>2</sup> Lens dislocations occur



**Image 1.** Right eye transverse view showing retinal separation with attachment at the level of the optic disc (\*) and ora serrata (arrows).



**Image 2.** Right eye sagittal view depicting echogenic lens indicative of cataract (star), as well as subluxation of lens into anterior chamber (white dot) indicative of anterior dislocation of lens.



**Image 3.** Right eye transverse view showing lens (star) displaced anterior to the iris and ciliary bodies (arrows).

as a result of damage to the zonular fibers of the ciliary body, which hold the lens in place. Disruption of the zonular fibers may result in either a partial or complete lens dislocation.<sup>3</sup> In a partial dislocation, the lens partially maintains its position behind the iris. In a complete luxation, the lens is found completely outside of the hyaloid fossa.<sup>3</sup> Often, the lens is found within the vitreous of the posterior compartment of the eye. Very rarely is it found within the anterior chamber.<sup>4,5</sup>

Patients can present with eye pain and visual changes ranging from light distortion to loss of vision.<sup>1,4</sup> If

### *CPC-EM Capsule*

What do we already know about this clinical entity?

*Anterior ocular lens dislocation is a potential result of blunt head trauma. If unrecognized, it can block the anterior chamber causing elevated intraocular pressures.*

What is the major impact of the images?

*The sonographic appearance of anterior lens dislocation has not been well described in emergency medicine literature. These are some of the first reported images.*

How might this improve emergency medicine practice?

*Because anterior lens dislocation can result in vision loss, accurate diagnosis is important. Point-of-care ultrasound can be used to diagnose lens dislocations.*

unrecognized or untreated, anterior dislocations can block the anterior chamber and trabecular meshwork causing elevated intraocular pressures, resulting in glaucoma, pupillary block, and corneal edema.<sup>1,4</sup> Therefore, they are considered vision-threatening emergencies.

Ultrasonography can aid in the diagnosis of all types of lens dislocations and assess for additional ophthalmologic pathology, including retinal detachment and vitreous hemorrhage.<sup>4</sup> Point-of-care ultrasonography (POCUS) can be used to make a rapid diagnosis without the delays associated with magnetic resonance imaging or the ionizing radiation of computed tomography. Diagnosis of posterior lens dislocation by POCUS has been previously described in the literature; however, the sonographic appearance of the rarer anterior lens dislocation has not been well documented.<sup>5</sup> This case provides some of the first reported ultrasound images of an anterior lens dislocation.

The authors attest that their institution requires neither Institutional Review Board approval nor patient consent for publication of this case report. Documentation on file.

*Address for Correspondence:* Tanvi Shirke, MD, WellSpan York Hospital, Department of Emergency Medicine, 1001S George Street, York, Pennsylvania 17403. Email: tshirke2@wellspan.org.

*Conflicts of Interest:* By the CPC-EM article submission agreement, all authors are required to disclose all affiliations,

funding sources and financial or management relationships that could be perceived as potential sources of bias. The authors disclosed none.

*Copyright:* © 2021 Shirke. This is an open access article distributed in accordance with the terms of the Creative Commons Attribution (CC BY 4.0) License. See: <http://creativecommons.org/licenses/by/4.0/>

---

#### REFERENCES

1. Eken C, Yuruktumen A, Yildiz G. Ultrasound diagnosis of traumatic lens dislocation. *J Emerg Med.* 2013;44(1):e109-10.
2. Lee S, Hayward A, Bellamkonda VR. Traumatic lens dislocation. *Int J Emerg Med.* 2015;8:16.
3. Lorente-Ramos RM, Arman J, Munoz-Hernandez A, et al. US of the eye made easy: a comprehensive how-to review with ophthalmoscopic correlation. *RadioGraphics.* 2012;32:E175-E200.
4. Ojaghihaghghi S, Lombardi K, Davis S, et al. Diagnosis of traumatic eye injuries with point-of-care ocular ultrasonography in the emergency department. *Ann Emerg Med.* 2019;74(3):365-71.
5. Shuen JA, Malone M, Burke Z, et al. Traumatic anterior dislocation of the lens. *J Emerg Med.* 2018;55(4):565-6.



## Carpometacarpal Dislocation with Third Metacarpal Fracture

Colin Jorgensen, MD  
Steve C. Christos, DO, MS

AMITA Health Resurrection Medical Center, Department of Emergency Medicine,  
Chicago, Illinois

Section Editor: R. Wilkerson, MD

Submission History: Submitted May 13, 2021; Revision received September 15, 2021; Accepted September 20, 2021

Electronically published November 1, 2021

Full text available through open access at [http://escholarship.org/uc/uciem\\_cpem](http://escholarship.org/uc/uciem_cpem)

DOI: 10.5811/cpcem.2021.9.53202

**Case Presentation:** A 17-year-old male presented to the emergency department (ED) due to trauma to the right hand and wrist after punching a locker at school. He had significant soft tissue swelling. Radiographs demonstrated intra-articular metacarpal fractures with associated carpometacarpal dislocations. The dislocation was reduced bedside in the ED and ultimately underwent closed reduction surgical management with orthopedic surgery.

**Discussion:** Metacarpal fractures result from high-force impact injuries and account for 30-40% of all hand injuries. The most common sites of second through fifth metacarpal fractures are at the neck and the shaft, with the majority involving the fifth metacarpal neck (commonly coined “boxer’s fractures”). Carpometacarpal (CMC) dislocations are a rare injury associated with high-force impact trauma to the wrist. These injuries account for as little as 1% of all acute hand and wrist injuries.<sup>1,2</sup> Carpometacarpal dislocations are often difficult to diagnose on physical examination due to significant soft tissue swelling, and they can easily be missed on anterior-posterior views of the hand. Lateral and oblique plain radiograph views are essential in the diagnosis as they are more likely to show dislocations. Despite appropriate plain radiographic views, subtle CMC dislocations may be difficult to discern dependent on the level of dislocation or subluxation and overlapping of joints. These injuries are rare due to otherwise highly stable ligamentous and muscular attachments within the wrist. Because of these attachments, dislocations are often associated with concomitant metacarpal fractures.<sup>3</sup> [Clin Pract Cases Emerg Med. 2021;5(4):488-490.]

**Keywords:** *carpometacarpal dislocation; metacarpal fracture.*

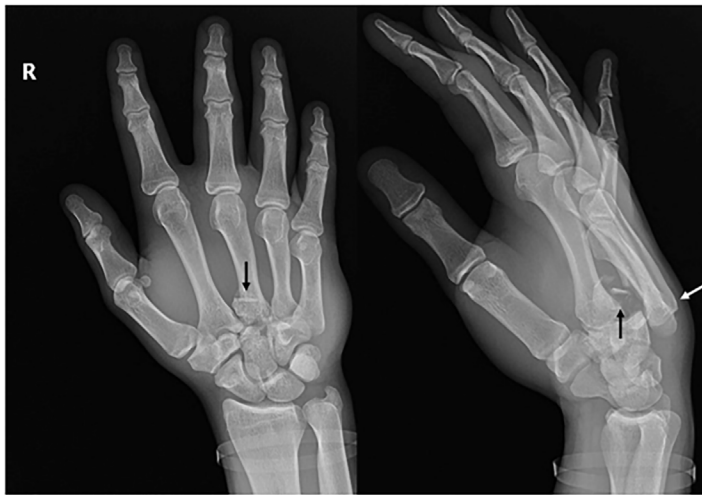### CASE PRESENTATION

A 17-year-old male presented to the emergency department (ED) with a chief complaint of right-hand pain after punching a locker with a closed fist. His vital signs were normal. Physical examination was notable for significant soft tissue swelling over the dorsum of the right hand with tenderness over the third through fifth metacarpals. The hand was neurovascularly intact with intact two-point discrimination. There was significantly limited range of motion at the metacarpophalangeal joints and interphalangeal joints. There were no open wounds. Plain film radiographs demonstrated comminuted intra-articular fractures through the radial aspect of the base of the third metacarpal with dorsal carpometacarpal (CMC) dislocations of the third through fifth metacarpals (Image).

A hematoma block was performed by injection of 10 cubic centimeters of 1:1 solution of 1% lidocaine and 0.5% bupivacaine. The CMC dislocation was reduced by applying axial traction at the metacarpal phalangeal joints with pressure at the dorsum of the proximal CMC joints. Post-reduction radiographs demonstrated successful reduction to anatomic alignment. The hand was immobilized, and the patient was advised to follow up with orthopedic surgery. He ultimately underwent closed reduction with percutaneous placement of Kirschner wires and was immobilized for six weeks.

### DISCUSSION

Metacarpal fractures are common traumatic hand injuries presenting to the ED; the most common site of second through fifth metacarpal fractures occur at the neck and shaft. First



**Image.** Anterior-posterior and oblique plain radiograph of the right hand demonstrates fractures through the radial aspect of the base of the third metacarpal (black arrows) with dorsal carpometacarpal dislocations of the third through fifth metacarpals (white arrow).

metacarpal fractures most commonly occur at the base and include Bennett (simple intra-articular fractures) and Rolando fractures (comminuted/complete intra-articular fractures at base of the first metacarpal). We report a rare third metacarpal base fracture with associated CMC dislocations at the third through fifth metacarpals. These are uncommon injuries due to the intrinsically stable nature of the CMC joints, particularly due to ligamentous insertion and muscular attachments. Dorsal dislocation is more common due to the relatively stronger dorsal interosseous ligaments compared to their volar counterparts.<sup>3</sup>

Diagnosis of CMC dislocations may be difficult due to significant soft tissue swelling and edema, as well as poorly visualized injury on anterior-posterior or posterior-anterior radiographs. While the dislocations are more readily apparent on lateral or oblique views, they are still often difficult to identify if there is minimal dorsal or volar displacement or if positioning does not provide adequate visualization. Management includes prompt identification of injury, manual reduction with immobilization, and early orthopedic surgery follow-up. Manual reduction is essential to providing initial care. Patients should be immobilized with 70-90° of flexion at the MCP joint, slight flexion at the interphalangeal joints, and mild wrist extension.

Although there is discrepancy of thought regarding the necessity for surgery,<sup>1</sup> it is generally definitively repaired surgically. Closed reduction with percutaneous Kirschner wire placement is the approach of choice. Although a primary ulnar nerve injury may be present, delayed treatment may result in neurovascular injury particularly in the presence of significant soft tissue swelling and edema. Additionally, instability at the joint may result in early-onset arthritis and

### *CPC-EM Capsule*

What do we already know about this clinical entity?

*Carpometacarpal (CMC) dislocations are rare wrist injuries. Manual reduction and prompt orthopedic follow-up are essential for management of these injuries.*

What is the major impact of the image(s)?

*This image demonstrates the importance of lateral and oblique radiographic views identifying CMC dislocations.*

How might this improve emergency medicine practice?

*By promptly identifying a CMC dislocation, the emergency clinician is better able to provide initial management of this rare traumatic injury.*

articular degeneration.<sup>4</sup> Delayed closed reduction or inability to successfully reduce the dislocation may result in need for an open reduction approach.<sup>5</sup>

This research was presented at the American Academy of Emergency Medicine 26<sup>th</sup> Annual Scientific Assembly in Phoenix, Arizona.

The authors attest that their institution requires neither Institutional Review Board approval nor patient consent for publication of this case report. Documentation on file.

**Address for Correspondence:** Steve Christos, DO, AMITA Health Resurrection Medical Center, Department of Emergency Medicine, 7435 W Talcott Avenue, Chicago, Illinois 60631. Email: [steve.christos@amitahealth.org](mailto:steve.christos@amitahealth.org).

**Conflicts of Interest:** By the CPC-EM article submission agreement, all authors are required to disclose all affiliations, funding sources and financial or management relationships that could be perceived as potential sources of bias. The authors disclosed none.

**Copyright:** © 2021 Jorgensen. This is an open access article distributed in accordance with the terms of the Creative Commons Attribution (CC BY 4.0) License. See: <http://creativecommons.org/licenses/by/4.0/>

### REFERENCES

1. Storken G, Bogie R, Jansen EJP. Acute ulnar carpometacarpal dislocations. Can it be treated conservatively? A review of Four

- cases. *Hand*. 2011;6(4):420-3.
2. Davies A, Smith K, Eilbert W. Multiple carpometacarpal dislocations. *Clin Pract Cases Emerg Med*. 2019;3(1):71-2.
3. Giacomo L, Khan A, Shahid, I, et al. Carpometacarpal joint concurrent dislocation of four long finger: results of a non-operative management. *EC Orthops*. 2016;4(6):688-93
4. Jumeau H, Lechien P, Dupriez F. Conservative treatment of carpometacarpal dislocation of the three last fingers. *Case Rep Emerg Med*. 2016;2016:1-3.
5. Chikate A and Mthethwa J. A review of the diagnosis and management of index through fifth carpometacarpal dislocations. *MOJ Orthop Rheumatol*. 2019;9(3).

## Disseminated Kaposi Sarcoma

Laura E. Goyack, MD  
Matthew A. Heimann, MD

University of Alabama – Birmingham, Department of Emergency Medicine,  
Birmingham, Alabama

Section Editor: Jacqueline Le, MD

Submission History: Submitted June 17, 2021; Revision received July 8, 2021; Accepted September 20, 2021

Electronically published November 1, 2021

Full text available through open access at [http://escholarship.org/uc/uciem\\_cpccem](http://escholarship.org/uc/uciem_cpccem)

DOI: 10.5811/cpcem.2021.9.53692

**Case Presentation:** A 28-year-old male with a recent diagnosis of human immunodeficiency virus presented to the emergency department with odynophagia and dysphagia for a month. Physical exam revealed Kaposi sarcoma partially occluding the airway. Point-of-care ultrasound was used to assist with the diagnosis of reactive lymphadenopathy, and computed tomography revealed systemic disease. Otolaryngology was urgently consulted, and the patient was admitted for prompt tracheostomy the following day.

**Discussion:** Kaposi sarcoma is a violaceous vascular neoplasm that is an acquired immunodeficiency syndrome (AIDS)-defining illness. Mucocutaneous membranes should be thoroughly evaluated with patients suspected of AIDS. This case demonstrates the vital evaluation of the patient's airway to assess patency. Highly active antiretroviral therapy should be initiated promptly, as well as chemotherapy in severe systemic cases. [Clin Pract Cases Emerg Med. 2021;5(4):491-493.]

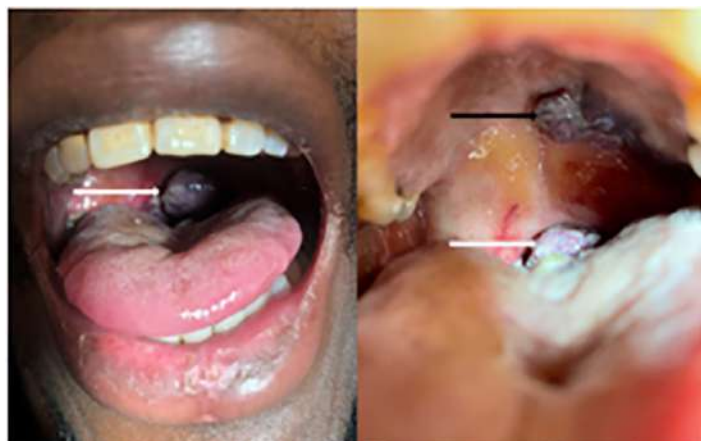
**Keywords:** *Kaposi sarcoma; acquired immunodeficiency syndrome (AIDS); violaceous; adenopathy; point-of-care ultrasound (POCUS).*

### CASE PRESENTATION

A 28-year-old male presented to the emergency department (ED) with progressively worsening odynophagia and dysphagia. He had been diagnosed with human immunodeficiency virus five months prior after initially presenting to an outside hospital with odynophagia and weight loss. Given difficulty affording his antiretrovirals, he reported only intermittently taking emtricitabine-tenofovir and was lost to follow-up. He was unaware of his oral lesions and overall grim clinical status. Seven days prior to presentation he developed mild dyspnea as well as worsening dysphagia. Physical examination of the oral cavity revealed a 3 × 3 centimeter (cm) violaceous, pedunculated, midline posterior mass partially occluding the airway, as well as a 2 × 2 cm anterior hard palate, violaceous mass (Image 1).

The exam was also notable for extensive cervical and inguinal lymphadenopathy, global wasting, and a muffled voice. He was able to speak in full sentences, was tolerating his secretions, and did not have evidence of respiratory distress. Point-of-care ultrasound (POCUS) revealed reactive cervical lymphadenopathy (Image 2).

Computed tomography soft tissue neck (Image 3) and chest revealed nodular thickening of upper airway structures,



**Image 1.** Midline posterior, pharyngeal pedunculated mass (white arrow) and hard palate mass (black arrow).

cervical lymphadenopathy, diffuse ground-glass opacities, and large bilateral pleural effusions.

He was started on broad spectrum antibiotics including trimethoprim/sulfamethoxazole for *Pneumocystis jirovecii* pneumonia prophylaxis. Otolaryngology was consulted in the ED

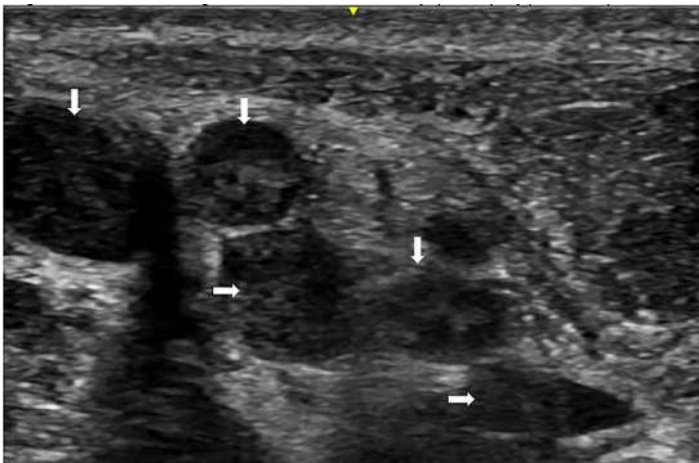


and performed a bedside laryngoscopy. He was admitted for tracheostomy the following day. Excisional biopsy confirmed the diagnosis of disseminated Kaposi sarcoma. Given his extensive disease burden, he was started on systemic chemotherapy.

## DISCUSSION

Kaposi sarcoma traditionally occurs in patients with immunosuppression, such as those with acquired immunodeficiency syndrome (AIDS), or those who are immunosuppressed secondary to organ transplant. Kaposi sarcoma related to AIDS occurs in patients with cluster of differentiation four (CD4) counts less than 200 cells per cubic millimeter and is an AIDS-defining illness.<sup>1</sup> Etiology is human herpesvirus-8, which causes endothelial cell proliferation leading to vascular neoplasia with multisystem involvement.<sup>2</sup> Presentation includes erythematous or violaceous macules and plaques that progress to tumors or nodules.<sup>2</sup> Lesions typically present at mucocutaneous sites, trunk, lower extremities, lymph nodes, lungs, and the gastrointestinal system. Diagnosis is made by history and physical examination revealing lesions and lymphadenopathy and is confirmed by tissue biopsy. Kaposi sarcoma responds to HIV suppression by highly active antiretroviral therapy (HAART). For severe systemic forms, chemotherapy can be combined with HAART.<sup>3</sup>

In our case, we used POCUS to confirm the diagnosis of extensive reactive lymphadenopathy. Other differentials included lymphoma, metastasis, abscess, and tuberculosis. Gray scale sonography can evaluate nodal morphology by noting size, shape, and architecture. Metastatic lymph nodes have loss of hilar architecture and the presence of intranodal calcification and necrosis.<sup>4</sup> Using power Doppler, normal and reactive nodes will reveal hilar vascularity or will be avascular, while metastatic nodes will reveal peripheral or mixed vascularity.<sup>5</sup>



**Image 2.** Point-of-care ultrasound images with extensive cervical reactive lymphadenopathy (white arrows).

*CPC-EM Capsule*

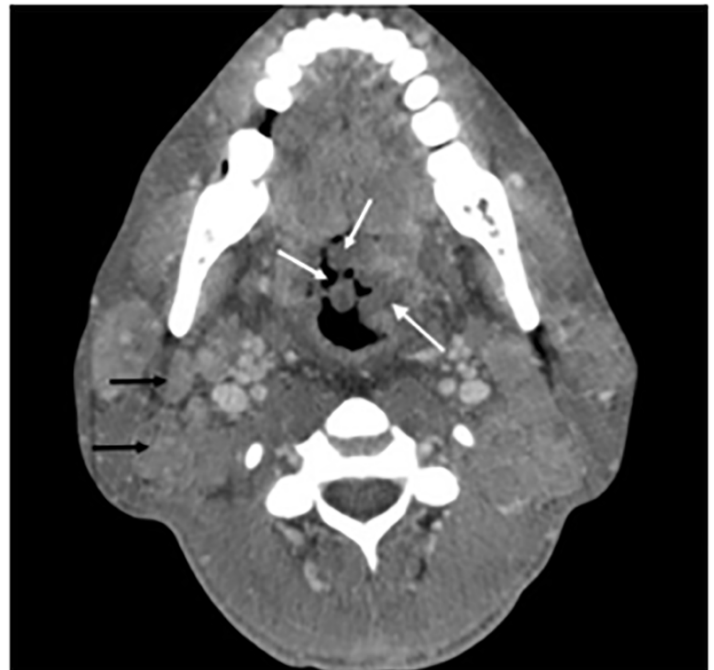What do we already know about this clinical entity?  
*Kaposi sarcoma is an acquired immunodeficiency syndrome-defining illness.*

What is the major impact of the image(s)?  
*Few images of Kaposi sarcoma of the oral cavity exist. This multimodality image approach illustrates the pathology and severity of the illness beyond cutaneous findings.*

How might this improve emergency medicine practice?  
*Thorough physical examination and multimodal imaging could aid the emergency physician in making this life-altering diagnosis.*

The authors attest that their institution requires neither Institutional Review Board approval nor patient consent for publication of this case report. Documentation on file.

*Address for Correspondence:* Laura Goyack, MD, University of Alabama – Birmingham, Department of Emergency Medicine,



**Image 3.** Axial computed tomography soft tissue neck showing diffuse nodular thickening of mucosal surfaces (white arrows) and extensive cervical lymphadenopathy (black arrows).

619 19<sup>th</sup> Street South, Birmingham, Alabama 35233. Email: lauragoyack@yahoo.com.

**Conflicts of Interest:** By the *CPC-EM* article submission agreement, all authors are required to disclose all affiliations, funding sources and financial or management relationships that could be perceived as potential sources of bias. The authors disclosed none.

**Copyright:** © 2021 Goyack. This is an open access article distributed in accordance with the terms of the Creative Commons Attribution ([CC BY 4.0](http://creativecommons.org/licenses/by/4.0/)) License. See: <http://creativecommons.org/licenses/by/4.0/>

## REFERENCES

1. Tounouga DN, Kouotou EA, Nansseu JR, et al. Epidemiological and clinical patterns of Kaposi sarcoma: a 16-year retrospective cross-sectional study from Yaoundé, Cameroon. *Dermatology*. 2018;234(5-6):198-204.
2. Tintinalli JE, Ma OJ, Yealy DM. (2016) Tintinalli's Emergency Medicine Manual, 8th ed. Ch 251 (1666). New York: McGraw-Hill Medical.
3. Schneider JW and Dittmer DP. Diagnosis and treatment of Kaposi sarcoma. *Am J Clin Dermatol*. 2017;18(4):529-39.
4. Ahuja AT, Ying M, Ho SY, et al. Ultrasound of malignant cervical lymph nodes. *Cancer Imaging*. 2008;8(1):48-56.
5. Arijji Y, Kimura Y, Hayashi N, et al. Power Doppler sonography of cervical lymph nodes in patients with head and neck cancer. *Am J Neuroradiol*. 1998;19(2):303-7.

## The Tired Pregnant Woman

Katie VanNatta, DO, MBA, MS\*

Nicole Yuzuk, DO†

David Trotter, MD, FACEP‡

Brandon Wisinski, DO, MBA, MS§

\*Midwestern University, Franciscan Health, Department of Emergency Medicine, Chicago, Illinois

†Saint Joseph's University Medical Center, Department of Emergency Medicine, Paterson, New Jersey

‡Franciscan Health Olympia Fields, Department of Emergency Medicine, Olympia Fields, Illinois

§Midwestern University, Franciscan Physician Network Olympia Fields Clinic, Department of Emergency Medicine, Olympia Fields, Illinois

Section Editor: John Ashurst, DO

Submission history: Submitted December 31, 2020; Revision received May 14, 2021; Accepted May 16, 2021

Electronically published September 27, 2021

Full text available through open access at [http://escholarship.org/uc/uciem\\_cpem](http://escholarship.org/uc/uciem_cpem)

DOI: 10.5811/cpcem.2021.5.51401

**Introduction:** Many pregnant women develop hyperemesis gravidarum. There are numerous gastrointestinal, genitourinary, neurologic, and metabolic causes to consider in this patient population.

**Case Presentation:** This clinicopathological case presentation details the initial assessment and management of an 18-year-old pregnant patient who presented to the emergency department with a complaint of nausea, vomiting, fatigue, and intermittent bleeding.

**Discussion:** This case takes the reader through the differential diagnosis and evaluation of the patient and the signs and symptoms, including her agitation and tachycardia, that led us to the correct diagnosis. [Clin Pract Cases Emerg Med. 2021;5(4):494–498.]

**Key Words:** *CPC; pregnancy; hyperemesis gravidarum.*

### CASE PRESENTATION (DR. KATIE VANNATTA)

An 18-year-old G1P0 female presented to the emergency department (ED) with a chief complaint of nausea, fatigue, and intermittent vaginal bleeding for the prior four days. She believed she was approximately two months pregnant but was unsure about her last menstrual period. She had not followed up with an obstetrician for her pregnancy, per chart review. The patient was given an informal diagnosis of hyperemesis gravidarum based on one previous ED visit when she had presented with emesis and was started on metoclopramide. She had been having six to eight episodes of emesis daily but denied emesis on the day of presentation. She reported light spotting but denied any tissue passage. She stated she had gone through one pad a day in the prior three days. Review of symptoms was positive for fatigue, nausea, vomiting, and vaginal bleeding. The patient had no chronic medical conditions or pertinent social or family history. She was taking metoclopramide 10 milligrams (mg) as needed for nausea and prenatal vitamins daily.

Upon arrival to the ED, the patient had a temperature of 97.9° Fahrenheit, heart rate of 160 beats per minute, a respiratory rate of 18 breaths per minute, oxygen saturation of 96% on room air, and blood pressure of 95/57 millimeters of mercury (mm Hg). On exam, she was tachycardic, had generalized abdominal tenderness, and appeared agitated with a flattened affect. She would answer questions appropriately but tersely with one word. A pelvic exam showed a closed cervical os with white vaginal discharge and a friable erythematous cervix that was tender to palpation, but no adnexal tenderness.

Initial laboratory results are listed in Tables 1 and 2. Other lab results included high sensitivity troponin of 14 (0-12 picograms per milliliter [pg/mL]), and quantitative human chorionic gonadotropin (hCG): >208,656 milli-international units per milliliter (m[IU]/mL). Her urinalysis showed large blood [negative], 3-5 red blood cell count (0-2 per high power field), 80 ketones (0 mg/deciliter), and moderate bacteria (none seen). An electrocardiogram was performed (Image) as

**Table 1.** Complete blood count with differential of an 18-year-old pregnant patient with emesis.

|                      |                                      |
|----------------------|--------------------------------------|
| White Blood Cells    | 6.0 [4.0-11.0 10 <sup>3</sup> /uL]   |
| RBC                  | 5.70 [3.63-5.04 10 <sup>6</sup> /uL] |
| Hemoglobin           | 16.6 [12.0-15.3 g/dL]                |
| Hematocrit           | 47.2 [34.7-45.1 %]                   |
| MCV                  | 82.9 [80.0-100.0 fL]                 |
| MCH                  | 29.1 [26.0-34.0 pg]                  |
| MCHC                 | 35.1 [32.5-35.8 g/dL]                |
| RDW                  | 13.4 [11.9-15.9%]                    |
| Platelets            | 311 [150-450 10 <sup>3</sup> /uL]    |
| Neutrophil %         | 71.3                                 |
| Lymphocyte %         | 19.6                                 |
| Monocytes %          | 8.4                                  |
| Eosinophil %         | 0.5                                  |
| Basophil %           | 0.2                                  |
| Neutrophil ABS CT    | 4.2 [1.7-7.7 10 <sup>3</sup> /uL]    |
| Lymphocyte ABS CT    | 1.2 [0.6-3.4 10 <sup>3</sup> /uL]    |
| Monocyte ABS CT      | 0.5 [0.3-1.0 10 <sup>3</sup> /uL]    |
| Eosinophil ABS CT    | 0.0 [0.0-0.5 10 <sup>3</sup> /uL]    |
| Basophil ABS CT      | 0.0 [0.0-0.2 10 <sup>3</sup> /uL]    |
| Mean Platelet Volume | 10.4 [6.8-10.2 fL]                   |

RBC, red blood cell count; MCV, mean corpuscular volume; MCH, mean corpuscular hemoglobin; MCHC, mean corpuscular hemoglobin concentration; RDW, red cell distribution width; ABS, absorbed; CT, cycle threshold; uL, microliter; dL, deciliter; pg, picogram; g/dL, gram per deciliter; fL, femtoliter.

**Table 2.** Complete metabolic panel of an 18-year-old pregnant woman with emesis.

|                            |                         |
|----------------------------|-------------------------|
| Sodium                     | 131 [133-144 mEq/L]     |
| Potassium                  | 3.0 [3.5-5.1 mEq/L]     |
| Chloride                   | 85 [98-107 mEq/L]       |
| Carbon Dioxide             | 27.9 [21.0-31.0 mEq/L]  |
| Anion Gap                  | 18.1 [6.2 – 14.7 mEq/L] |
| Blood Urea Nitrogen        | 27 [7-25 mEq/L]         |
| Creatinine                 | 1.2 [0.6-1.2 mg/dL]     |
| Calcium                    | 9.8 [8.6-10.3 mg/dL]    |
| Glucose                    | 85 [70-99 mg/dL]        |
| Alkaline Phosphatase Total | 138 [34-104 U/L]        |
| Total Protein              | 8.4 [6.4-8.9 g/dL]      |
| Albumin                    | 3.7 [3.7-8.9 g/dL]      |
| Aspartate aminotransferase | 302 [13-38 U/L]         |
| Alanine aminotransferase   | 928 [7-52 U/L]          |
| Total Bilirubin            | 2.4 [0.0-1.0 mg/dL]     |

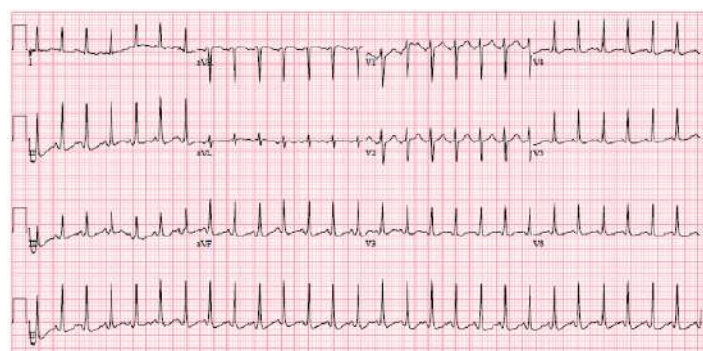
mEq/L, milliequivalents per liter; mg/dL, milligrams per deciliter; U/L, units per liter; g/dL, grams per deciliter.

well as a formal pregnancy ultrasound. The ultrasound demonstrated a single, live intrauterine gestation with crown-rump length corresponding to a gestational age of 10 weeks 4 days +/- 7 days.

With the abnormalities noted on initial labs, a right upper quadrant ultrasound was obtained showing only gallbladder sludge, without wall thickening, pericholecystic fluid, or common bile duct dilation, and a negative sonographic Murphy's sign. Additionally, we obtained a serum lipase, acetaminophen, prothrombin time/international normalized ratio (PT/INR), activated partial thromboplastin time (aPTT), thyroid stimulating hormone (TSH), and alcohol level. The lipase, acetaminophen, and alcohol levels were all negative. The patient received two liters of normal saline with repeat vitals as follows: heart rate 132 beats per minute; blood pressure 127/77 mm Hg; and oxygen saturation 98% on room air. Following discussion with intensive care and obstetrics and gynecology, the patient was transferred to a tertiary care center for a higher level of care.

### CASE DISCUSSION (DR. NICOLE YUZUK)

When encountering nausea and vomiting in a pregnant patient, I think it best to break down the differential diagnosis into systems. There are numerous gastrointestinal, genitourinary, neurologic, and metabolic causes to consider in this patient population. One immediately thinks of gastrointestinal sources with vomiting, such as cholecystitis, pancreatitis, appendicitis, peptic ulcer disease, or small bowel obstruction. Additionally, there are pregnancy-related pathologies to think of as well, such as cholestasis or hemolysis, elevated liver enzymes, or low platelet count (HELLP) syndrome. It is reasonable to consider these diagnoses, especially cholecystitis and pancreatitis, given the patient's liver abnormalities and abdominal tenderness. However, there is no mention of the right upper quadrant ultrasound being diagnostic, and the pain is not localized. Given her lab abnormalities, cholestasis of pregnancy and HELLP syndrome may initially be on the differential;

**Image.** Electrocardiogram of an 18-year-old pregnant patient with emesis.



however, because the patient is only in her first trimester it is too early for either of these diagnoses. From this list we can keep cholecystitis and biliary pathology because of lack of information regarding the patient's ultrasound.

What about genitourinary causes of nausea and vomiting in pregnancy? Our list for this would include ectopic pregnancy, urinary tract infection or pyelonephritis, pelvic inflammatory disease, ovarian torsion, trophoblastic disease, and uremia. The patient's workup ruled out many of these causes including ectopic/torsion, molar pregnancy, and kidney failure, but the emergency physician must still entertain the possibility of infectious causes. Her urinalysis was not convincing of urinary tract infection, and there was no mention of cervical motion tenderness; however, physical exam did reveal abnormal vaginal discharge and a friable cervix. Given these findings, it is reasonable to keep pelvic inflammatory disease on the differential, and one could argue that her vital signs are concerning for sepsis; however, she had no leukocytosis or other lab abnormalities that further supported infection.

Often, providers look to gastrointestinal causes as the most reasonable indication when someone is vomiting. Less commonly it could be the result of an intracranial process. Increased intracranial pressure could cause vomiting; possibilities to consider in the differential would be a central nervous system tumor or even intracranial hemorrhage. Although this is an important part of the differential, I can confidently eliminate this possibility for our patient because there was no mention of headaches, and aside from her agitation her neurologic exam was normal.

Metabolic causes of vomiting are always important to consider as they could range from a simple case of hyperemesis gravidarum to something more complex such as a thyroid disorder. Although I do think her prior hyperemesis diagnosis could be contributing to this patient's pathology, in this case we must also consider thyroid disorders. Her presentation would make a hyperthyroid state more likely given her agitation and tachycardia. As we debate the possible explanations for her presenting complaints the only one that seems to tie everything together is a thyroid disorder. When thinking about hyperthyroidism in pregnancy, clinicians must determine whether the thyroid abnormality is from a primary disorder such as Graves' disease, thyroiditis, or toxic adenoma or whether it is the result of gestational transient thyrotoxicosis. Graves' disease is the most common cause of hyperthyroidism in pregnancy, but these patients often have a history of hyperthyroidism and exhibit other features consistent with the disease such as exophthalmos or goiter.<sup>1</sup> This patient had no significant past medical history aside from the hyperemesis, and the physical exam did not reveal any abnormalities suggestive of thyrotoxicosis; therefore, although not impossible, it seems less likely to be related to these types of disorders.

This leaves us with gestational transient thyrotoxicosis. In pregnancy, thyroid physiology changes and the circulating

hormone, human chorionic gonadotropin (hCG), can act like TSH on the thyroid gland, causing a fleeting increase in their thyroid function.<sup>2</sup> Patients with hyperemesis gravidarum have a higher circulating amount of hCG and thus are at higher risk for this disorder.<sup>3</sup> Patients with gestational transient thyrotoxicosis often do not show clinical features of hyperthyroidism (exophthalmos, goiter, tremor, etc), and the condition peaks at 10-12 weeks gestation. It is, therefore, reasonable when reviewing this case to think that the hyperemesis gravidarum incited this cause of hyperthyroidism and is the reason she is thyrotoxic despite the fact that these patients usually remain asymptomatic.<sup>2</sup> The less common diagnosis hiding behind a presentation frequently seen in the ED is thyroid storm secondary to gestational transient thyrotoxicosis.

### CASE OUTCOME (DR. KATIE VANNATTA)

Before the patient was transferred from the ED to the tertiary care center, her TSH resulted as  $<0.01$  ( $0.27 - 4.20$  milli-international units per liter (mIU/L)) revealing that she was in thyroid storm. On the Burch-Wartofsky point scale (BWPS) the patient's score for thyrotoxicosis was 45 points. Based upon the diagnosis, we obtained free thyroxine ( $T_4$ ) and triiodothyronine ( $T_3$ ) levels. After consulting with the tertiary care center, it was recommended to give 100 milligrams (mg) of intravenous (IV) hydrocortisone and withhold propylthiouracil due to her liver dysfunction. The patient's additional labs resulted after she left the ED: PT:  $>134.0$  ( $10.1-13.1$ s), international normalized ratio INR:  $>11.0$  (INR:  $<1.1$ ), APTT:  $>104.1$  ( $25.0 - 36.0$  s),  $T_3$ , free (FT<sub>3</sub>):  $5.55$  ( $2.52 - 4.34$  pg/mL),  $T_4$ , free (FT<sub>4</sub>):  $4.30$  ( $0.55 - 1.60$  ng/dL).

At the tertiary care center, the patient was admitted to the medical intensive care unit for four days to treat and control her thyroid storm in the setting of first trimester pregnancy. It was determined during her admission that her hyperemesis gravidarum was the underlying factor in her thyroid storm, liver failure, and vitamin K deficiency. Endocrine consult recommended starting hydrocortisone 50 mg IV three times a day, propranolol 10 mg every six hours, and methimazole once her transaminitis improved. She had a thyroid ultrasound and thyroid stimulating immunoglobulin testing, which were within normal limits. The patient's daily  $T_3/T_4$  was downtrending at the time of discharge, and she was sent home on 20 mg of prednisone for seven days. At the time of discharge, she had returned to her baseline.

### RESIDENT DISCUSSION (DR. KATIE VANNATTA)

Hyperemesis gravidarum is commonly encountered in the ED, but less known to emergency providers is the effect it has on thyroid function. These patients can have an increase in thyroid hormone level, but normally it is transient, unlike the patient in this case. The theory stems from the structural similarity of TSH and hCG, which triggers thyroid stimulation as hCG levels increase in pregnancy.<sup>4</sup> Estrogens mediate this increase in sialylation that can reduce the clearance of thyroxine

binding globulin resulting in increased levels of total T<sub>4</sub> and T<sub>3</sub>.<sup>4</sup> As pregnancy progresses, changes in albumin and free fatty acid concentrations can affect the binding of thyroid hormones to its carrier proteins resulting in lower serum levels of free T<sub>3</sub> and free T<sub>4</sub>.<sup>5</sup> Studies have shown that patients with a higher hCG concentration, such as those experiencing hyperemesis, may have an increased severity of vomiting and degree of thyroid stimulation.<sup>6</sup> Most hyperemesis gravidarum patients who develop thyrotoxicosis have a transient course and do not require anti-thyroid medication.<sup>3</sup>

Thyroid storm is a rare, life-threatening condition in pregnancy which occurs in 1-2% of pregnant patients with hyperthyroidism. A hypermetabolic state caused by an excess of thyroid hormone, thyroid storm is diagnosed by a combination of signs and symptoms. It develops abruptly and affects the body's thermo-regulatory, cardiovascular, nervous, and gastrointestinal systems, which in turn leads to multiorgan decompensation.<sup>4</sup> The BWPS score (Table 3) can be used to help identify and predict the likelihood that biochemical thyrotoxicosis is thyroid storm.<sup>7</sup> It is a quantitative diagnostic tool based on three major observations in patients with thyroid storm: continuum of end organ dysfunction; high variability of symptoms and signs between patients; and high mortality associated with missed diagnosis by assigning points for dysfunction of thermoregulatory, gastrointestinal, cardiovascular, and central nervous systems. Table 4 lists the recommendations for patients based on the BWPS score.<sup>7</sup>

Pregnant women with overt hyperthyroidism and thyrotoxicosis should be treated with a thioamide medication, such as methimazole or propylthiouracil, to minimize the risk of adverse outcomes.<sup>8</sup> Historically, propylthiouracil was the preferred treatment for hyperthyroidism in pregnancy because it partially inhibits the conversion of T<sub>4</sub> to T<sub>3</sub> and crosses the placenta less readily than methimazole.<sup>8</sup> The American Thyroid Association and the American Association of Clinical Endocrinologists recommend propylthiouracil therapy during the first trimester followed by a switch to methimazole at the start of the second trimester.<sup>8</sup> This strategy helps avoid the rare complications of hepatotoxicity and methimazole embryopathy seen with use of methimazole early on in pregnancy.<sup>8</sup> Corticosteroids are also a mainstay of treatment because of their effect on thyroid function.<sup>9</sup> Hydrocortisone is commonly used since it inhibits the peripheral conversion of T<sub>4</sub> to T<sub>3</sub>.<sup>3</sup> Propranolol, a beta blocker, can also be used in pregnant patients with hyperthyroidism or thyroid storm. It is readily safe in pregnancy and can help with the symptoms as well as to decrease the conversion of T<sub>4</sub> to T<sub>3</sub>.<sup>9</sup>

A link has been noted between hyperemesis gravidarum and thyrotoxicosis. Lin et al showed that women who were found to be in thyrotoxicosis with a TSH <0.02 also had severe liver dysfunction. Hyperemesis gravidarum can cause elevated liver enzymes because of the severe vomiting. Once the vomiting stops, the transaminitis usually returns to baseline.<sup>10</sup> In a case report Shigemi et al described a link

**Table 3.** The Burch-Wartofsky point scale.<sup>7</sup>

|                                      |   |     |
|--------------------------------------|---|-----|
| Temperature<br>(° Fahrenheit)        | <99   | 0   |
|                                      | 99-99.9 (37.2-37.7)                           | +5  |
|                                      | 100-100.9 (37.8-38.2)                         | +10 |
|                                      | 101-101.9 (38.3-38.3)                         | +15 |
|                                      | 102-102.9 (38.9-39.2)                         | +20 |
|                                      | 103-103.9 (39.3-39.9)                         | +25 |
|                                      | >104 (>40.0)                                  | +30 |
| Central nervous system effects       | Absent  | 0   |
|                                      | Mild (agitation)                              | +10 |
|                                      | Moderate (seizures, coma)                     | +20 |
|                                      | Severe (seizures, coma)                       | +30 |
| Gastrointestinal-hepatic dysfunction | Absent  | 0   |
|                                      | Moderate (diarrhea, vomiting, abdominal pain) | +10 |
|                                      | Severe (unexplained jaundice)                 | +20 |
| Heart rate (beats per minute)        | <90   | 0   |
|                                      | 90-109  | +5  |
|                                      | 110-119                                       | +10 |
|                                      | 120-129                                       | +15 |
|                                      | 130-139                                       | +20 |
|                                      | >140  | +25 |
| Congestive heart failure             | Absent  | 0   |
|                                      | Mild (pedal edema)                            | +5  |
|                                      | Moderate (bibasilar rales)                    | +10 |
|                                      | Severe (pulmonary edema)                      | +15 |
| Atrial fibrillation present          | No (0) Yes (+10)                              |     |
| Precipitating event                  | No (0) Yes (+10)                              |     |

between maternal vitamin K deficiency with hyperemesis gravidarum. The case describes a woman with hyperemesis gravidarum who was found to have an increase in prothrombin time in the setting of mild liver dysfunction. This was complicated by malnutrition due to the severe vomiting most patients experience with hyperemesis gravidarum.<sup>11</sup>

**FINAL DIAGNOSIS**

Thyroid storm in the setting of first trimester pregnancy with acute liver failure and severe vitamin K deficiency due to hyperemesis gravidarum.

**KEY TEACHING POINTS**

- Pregnant patients presenting to the ED with nausea/vomiting usually require only supportive management.
- When diagnosing a pregnant patient with hyperemesis gravidarum it is vital to assess the severity of malnutrition/dehydration to determine appropriate treatment and disposition.
- Less common complications linked to hyperemesis include hyperthyroidism, liver dysfunction, and vitamin K deficiency. Awareness of these conditions is important, as their identification can change disposition and management.

**Table 4.** Recommendations based on the Burch-Wartofsky point scale.<sup>7</sup>

| Score: | Suggestive of:                     | Recommendations:   |
|--------|------------------------------------|--|
| >/=45  | Highly suggestive of thyroid storm | Consider aggressive multimodal management in the intensive care unit                         |
| 25-44  | Impending thyroid storm            | Consider starting thioamides, symptom management and consider intensive care unit monitoring |
| <25    | Unlikely to be thyroid storm       | Need to investigate diagnosis of thyrotoxicosis  |

- Hyperemesis gravidarum usually causes a transient hyperthyroidism in early pregnancy that generally does not warrant treatment; however, in rare cases, thyroid storm can occur.
- Thyroid storm holds the highest mortality rate compared to the other severe complications of pregnancy.<sup>5</sup>
- Recommendations to treat thyroid storm in pregnancy include propylthiouracil in the first trimester and methimazole during the second and third trimesters.
- When presented with a similar, complex case, it is important that the emergency physician expand the workup and narrow a differential to make the less common diagnosis.

The authors attest that their institution requires neither Institutional Review Board approval, nor patient consent for publication of this case report. Documentation on file.

*Address for Correspondence:* Katie VanNatta, DO, Franciscan Health - Olympia Fields, Department of Emergency Department, 20201 South Crawford Ave, Olympia Fields, IL 60461. Email:Vannatta.katie@gmail.com.

*Conflicts of Interest:* By the CPC-EM article submission agreement, all authors are required to disclose all affiliations, funding sources and financial or management relationships that could be perceived as potential sources of bias. The authors disclosed none.

*Copyright:* © 2021 VanNatta. This is an open access article distributed in accordance with the terms of the Creative Commons Attribution (CC BY 4.0) License. See: <http://creativecommons.org/licenses/by/4.0/>

## REFERENCES

1. Alexander EK, Pearce EN, Brent GA, et al. 2017 Guidelines of the American Thyroid Association for the Diagnosis and Management of Thyroid Disease During Pregnancy and the Postpartum. *Thyroid*. 2017;27(3):315-89.
2. Marx H, Amin P, Lazarus JH. Hyperthyroidism and pregnancy. *BMJ*. 2008;336(7645):663-7.
3. Thyroid Disease in Pregnancy: ACOG Practice Bulletin, Number 223. *Obstet Gynecol*. 2020;135(6):1496-9.
4. Casey, B. Thyroid Disease in Pregnancy. *ACOG: Practice Bulletin Number 148*. 2015;125(4):996-1005.
5. Tan, JY, Loh, KC, Yeo, GS, et al. Transient hyperthyroidism of hyperemesis gravidarum. *BJOG*. 2002;109(6):683-88.
6. Panesar NS, Li CY, Rogers MS. Are thyroid hormones or hCG responsible for hyperemesis gravidarum? A matched paired study in pregnant Chinese women. *Acta Obstet Gynecol Scand*. 2001;80(6):519-24.
7. Burch HB and Wartofsky L. Life-threatening thyrotoxicosis. Thyroid storm. *Endocrinol Metab Clin North Am*. 1993;22(2):263-77.
8. Yoshihara A, Noh J, Yamaguchi T, et al. Treatment of Graves' disease with antithyroid drugs in the first trimester of pregnancy and the prevalence of congenital malformation. *J Clin Endocrinol Metab*. 2012;97(7):2396-403.
9. Atkins P, Cohen SB, Phillips BJ. Drug therapy for hyperthyroidism in pregnancy: safety issues for mother and fetus. *Drug Saf*. 2000;23(3):229-44.
10. Lin TY, Shekar AO, Li N, et al. Incidence of abnormal liver biochemical tests in hyperthyroidism. *Clin Endocrinol (Oxf)*. 2017;86(5):755-59.
11. Shigemi D, Nakanishi K, Miyazaki M, et al. A case of maternal vitamin K deficiency associated with hyperemesis gravidarum: its potential impact on fetal blood coagulability. *J Nippon Med Sch*. 2015;82(1):54-8.

## Splenic Injury Following Colonoscopy: A Case Report

Jason Wang, BS\*

Heesun Choi, DO†

John Ashurst, DO, MSc†

\*Touro University Nevada College of Osteopathic Medicine, Henderson, Nevada

†Kingman Regional Medical Center, Department of Emergency Medicine, Kingman, Arizona

Section Editor: R. Gentry Wilkerson, MD

Submission history: Submitted November 3, 2020; Revision received February 5, 2021; Accepted February 12, 2021

Electronically published May 25, 2021

Full text available through open access at [http://escholarship.org/uc/uciem\\_cpsem](http://escholarship.org/uc/uciem_cpsem)

DOI: 10.5811/cpcem.2021.2.50676

**Introduction:** Colonoscopy is a commonly performed outpatient procedure with a low risk of complications. The most common complications seen in the postoperative period include hemorrhage and perforation. Infrequently, splenic injury can occur.

**Case Report:** A 72-year-old male presented with a one-day history of left upper quadrant pain following colonoscopy. During the procedure he had two polyps removed along the transverse colon near the splenic flexure. There were no complications during the procedure or in the immediate postoperative period. On presentation to the emergency department, abdominal tenderness was present in the left upper quadrant without rebound, rigidity, or guarding. Point-of-care ultrasound of the abdomen demonstrated mixed hypoechoic densities confined to the splenic capsule, and computed tomography of the abdomen and pelvis with intravenous contrast noted a grade II/III splenic laceration without active extravasation. The patient was admitted for serial abdominal examination and labs.

**Conclusion:** Splenic injury following colonoscopy is a rare complication of colonoscopy. Emergency providers should be aware of this possible complication, and acute management should include basic trauma care and consultation for possible intervention, if warranted. [Clin Pract Cases Emerg Med. 2021;5(4):499–501.]

**Keywords:** *Colonoscopy; splenic hematoma.*

### INTRODUCTION

Colonoscopy has become a routine diagnostic and treatment option for many colonic diseases and has a relatively low complication rate. The overall complication rate has been reported to range from 0.5% for routine colonoscopy and up to 1.8% for colonoscopy with polypectomy.<sup>1,2</sup> The most common of these complications include hemorrhage and perforation.<sup>3</sup> Less frequently, bacteremia, ileus, mesenteric tears, pneumothorax, pneumoperitoneum, pneumoscrotum and colonic volvulus can occur.<sup>3</sup> We present a case of a splenic injury following colonoscopy with polypectomy that was successfully treated conservatively.

### CASE REPORT

A 72-year-old male presented due to left upper quadrant abdominal pain that radiated to the flank and constipation one

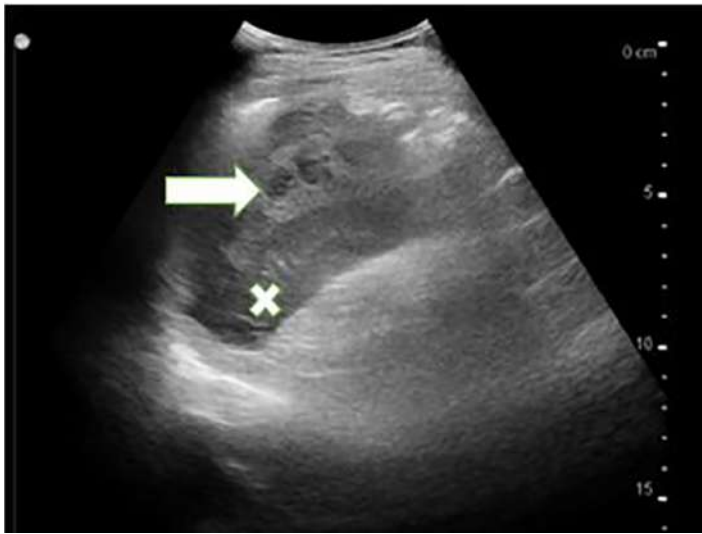
day following a colonoscopy. He reported that he had not had a bowel movement or passed gas since the procedure. The indication for colonoscopy was chronic constipation. Following instructions from his surgeon, the patient had stopped taking clopidogrel and aspirin, both taken for moderate coronary artery disease, several days prior to the colonoscopy. During the procedure, the patient had two polyps removed along the transverse colon near the splenic flexure. Intraoperatively and postoperatively, there were no complications noted.

Upon arrival to the emergency department, his vital signs were as follows: heart rate 66 beats per minute; blood pressure 113/59 millimeters of mercury; respiratory rate 16 breaths per minute; and temperature 98.7 degrees Fahrenheit. Upon examination, the patient appeared in no acute distress due to pain, and his skin and conjunctiva were without pallor. Abdominal examination revealed hypoactive bowel sounds, and there was



tenderness to palpation in the left upper quadrant. No rebound, rigidity or guarding were seen on physical exam. No ecchymosis was noted in the left upper quadrant or the left flank.

A point-of-care ultrasound of the spleen demonstrated mixed hypoechoic densities within the splenic capsule (Image 1). Computed tomography (CT) of the abdomen and pelvis with intravenous contrast showed a perisplenic hematoma with small amounts of blood products extending into the intraperitoneal



**Image 1.** Point-of-care ultrasound of the spleen (X) with mixed hypoechoic densities within the splenic capsule (arrow).

space (Image 2). There were also heterogeneously hyperdense blood products surrounding greater than 50% of the circumference of the spleen, consistent with a grade II/III splenic injury. Initial complete blood counts demonstrated hemoglobin 16.1 grams per deciliter (g/dL) (reference range 13.1 – 17.1 g/dL), hematocrit 47.3% (42-52%), and a white blood cell count 12,600 cells per microliter (cells/ $\mu$ L) (4,800 – 10,800 cells/ $\mu$ L). After consultation with general surgery, he was admitted for serial labs and abdominal examinations. He was discharged from the hospital three days later without requiring further intervention.

## DISCUSSION

Splenic injury following colonoscopy was first described in 1974 and is likely under-reported in the current literature.<sup>4-6</sup> Common risk factors for splenic injury during colonoscopy include a technically demanding procedure, splenocolic adhesions, splenomegaly, underlying splenic disease, or polypectomy in the transverse colon as seen in this patient. Although the exact mechanism for injury is unknown, several theories have been developed.<sup>7</sup> Excess traction upon the splenocolic ligament or adhesions can lead to partial capsular avulsion or splenic tears.<sup>7</sup> Trauma following endoscopic navigation

### *CPC-EM Capsule*

What do we already know about this clinical entity?

*Although complications following colonoscopy occur at a rate of 0.5% to 1.8%, splenic injury is quite rare.*

What makes this presentation of disease reportable?

*This paper highlights the usage of point of care ultrasound as a diagnostic modality in those who present with abdominal pain following colonoscopy.*

What is the major learning point?

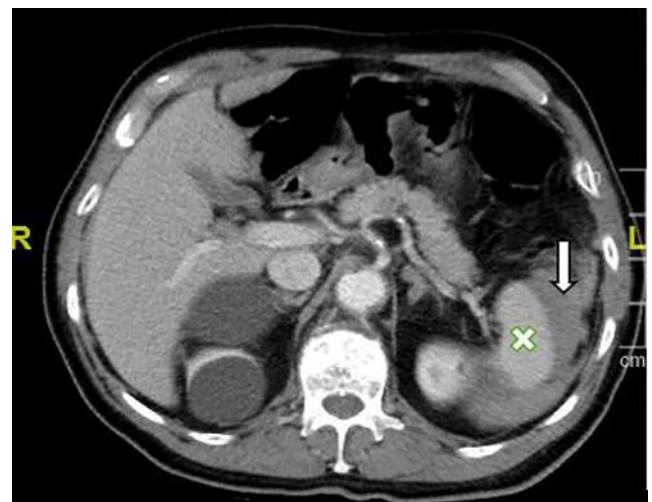
*Although rare, splenic injury following colonoscopy should be treated much like a splenic injury following trauma*

How might this improve emergency medicine practice?

*By keeping a broad differential diagnosis, the emergency medicine physician should employ early consultation and trauma intervention to improve patient outcomes.*

of the splenic flexure has also been described as a mechanism for injury.<sup>7</sup>

Typically, patients will present with abdominal pain or left shoulder pain (Kehr's sign) on the same day as the procedure.<sup>6</sup>



**Image 2.** Computed tomography of the abdomen and pelvis with intravenous contrast depicting a perisplenic hematoma (arrow) with small amounts of blood products extending into the intraperitoneal space from the spleen (X).

However, a delayed presentation can occur and can lead to an increase in morbidity and mortality. In addition to physical exam, patients should be evaluated for signs of hypovolemia. While this patient initially presented with a blood pressure seemingly low for his age, this may have been caused by his daily use of lisinopril for chronic hypertension. Much as in blunt abdominal trauma, CT imaging should be considered the imaging modality of choice in patients who are hemodynamically stable. For those hemodynamically unstable, a focused abdominal sonography for trauma should be completed.

Treatment should follow the guidelines for the management of blunt traumatic splenic injuries. In the unstable patient with a splenic injury, exploratory laparotomy should be considered as the first-line treatment modality. In stable patients with active contrast extravasation from the spleen on CT, interventional radiology angioembolization should be considered after consultation. Those without active extravasation on the CT should be admitted for serial hemoglobin levels and abdominal examinations.

## CONCLUSION

An important part of obtaining a complete history includes eliciting any recent procedures as well as surgeries, including those performed in an outpatient setting. Although rare, splenic injury following outpatient colonoscopy is a complication that the emergency physician should include in the differential diagnosis for patients who present in the postoperative period. Early consultation, intervention, and appropriate trauma management should be used to avoid immediate and long-term morbidity and mortality.

The authors attest that their institution requires neither Institutional Review Board approval, nor patient consent for publication of this case report. Documentation on file.

*Address for Correspondence:* John Ashurst DO, MSc, Kingman Regional Medical Center, Department of Emergency Medicine, 3269 Stockton Hill Road, Kingman, AZ 86409. Email: Ashurst.john.32.research@gmail.com.

*Conflicts of Interest:* By the CPC-EM article submission agreement, all authors are required to disclose all affiliations, funding sources and financial or management relationships that could be perceived as potential sources of bias. The authors disclosed none.

*Copyright:* © 2021 Wang et al. This is an open access article distributed in accordance with the terms of the Creative Commons Attribution (CC BY 4.0) License. See: <http://creativecommons.org/licenses/by/4.0/>

## REFERENCES

1. Levin TR, Zhao W, Conell C, et al. Complications of colonoscopy in an integrated health care delivery system. *Ann Intern Med.* 2006;145(12):880-6.
2. Smith LE. Fiberoptic colonoscopy: complications of colonoscopy and polypectomy. *Dis Colon Rectum.* 1976;19(5):407-12.
3. Sarhan M, Ramcharan A, Ponnappalli S. Splenic injury after elective colonoscopy. *JSLs.* 2009;13(4):616-9.
4. Wherry DC and Zehner H Jr. Colonoscopy-fiberoptic endoscopic approach to the colon and polypectomy. *Med Ann Dist Columbia.* 1974;43(4):189-92.
5. Patel DD, Shih-Della Penna DC, Terry SM. Splenic trauma from colonoscopy: a case series. *Int J Surg Case Rep.* 2020;71:30-3.
6. Jehangir A, Poudel DR, Masand-Rai A, et al. A systematic review of splenic injuries during colonoscopies: evolving trends in presentation and management. *Int J Surg.* 2016;33Pt A:55-9.
7. Skipworth JR, Raptis DA, Rawal JS, et al. Splenic injury following colonoscopy: an underdiagnosed, but soon to increase, phenomenon? *Ann R Coll Surg Engl.* 2009;91(4):W6-11.

## 48-year-old with Altered Mental Status and Respiratory Failure: A Case Report

Justin E. Pile, DO, MS\*  
Justina Truong, DO†

\*Swedish Hospital, Northshore University HealthSystem, Department of Emergency Medicine, Chicago, Illinois

†Kingman Regional Medical Center, Department of Emergency Medicine, Kingman, Arizona

Section Editor: John Ashurst, DO

Submission history: Submitted December 27, 2020; Revision received March 4, 2021; Accepted March 8, 2021

Electronically published April 23, 2021

Full text available through open access at [http://escholarship.org/uc/uciem\\_cpem](http://escholarship.org/uc/uciem_cpem)

DOI: 10.5811/cpem.2021.3.51331

**Introduction:** The differential diagnosis for altered mental status and respiratory failure is broad. Careful physical examination, appropriate use of diagnostic tools, and accurate interpretation and correlation of test results are important for piecing together the puzzle of a patient with altered mental status that emergency physicians commonly face. In certain cases, such as this one, rapid diagnosis and management is crucial for improving patient morbidity and mortality.

**Case Presentation:** A 48-year-old male with altered mental status and respiratory failure presented to the emergency department after being found unconscious on his porch. Vital signs were notable for temperature 105.5 °F, blood pressure 202/102 millimeters of mercury, pulse 126 beats per minute, respiratory rate 30 breaths per minute, and oxygen saturation 91% on room air. Physical examination revealed an obese male lying in bed awake in severe distress with labored breathing and unable to converse. His physical examination was significant for dry mucous membranes, tachycardia, and bilateral lower extremity 1+ pitting edema. He also appeared to have Kussmaul respirations with severe tachypnea, but his breath sounds were clear to auscultation bilaterally. On further examination, the patient appeared to have intravenous (IV) injection markings along his arms suggesting the possibility of IV drug use.

**Discussion:** With limited history, the only context clues initially available to assist in the diagnosis were abnormal vital signs and physical examination. The patient was tachycardic, hyperthermic, hypertensive, hypoxic, and tachypneic with altered mental status; he eventually required endotracheal intubation for hypoxic respiratory failure. The complexity of his condition prompted a large list for the differential diagnoses. Toxidromes, endocrine abnormalities, infectious process, cardiac and/or renal etiologies, and neurological pathology such as a cerebrovascular accident were considered. In the case of this patient, urgent diagnosis and management was crucial to prevent further decompensation and improve his outcome. [Clin Pract Cases Emerg Med. 2021;5(4):502–506.]

**Keywords:** *Cardiorenal Syndrome, Respiratory Failure, Altered Mental Status, Sepsis, Case Report.*

### CASE PRESENTATION (Resident Presentation)

A 48-year-old male presented to the emergency department (ED) via ambulance after being found unconscious on his porch. The paramedics stated the patient had labored breathing and altered mental status but did answer a few questions appropriately. The patient denied any drug use, but emergency medical services had administered eight

milligrams of naloxone to him prior to arrival to the ED. In the ED, additional history including a review of systems was limited secondary to the patient's clinical condition.

Vital signs were as follows: temperature 105.5 degrees Fahrenheit (°F), blood pressure 202/102 millimeters of mercury, pulse 126 beats per minute, respiratory rate 30 breaths per minute, and oxygen saturation 91% on room air.

Physical examination revealed an obese male lying in bed awake in severe distress with labored breathing and unable to converse. Due to patient distress, orientation could not be assessed. He was able to move all extremities and had no facial asymmetry, but a full neurological exam was limited secondary to clinical condition. His physical examination was significant for dry mucous membranes, tachycardia, and bilateral lower extremity 1+ pitting edema. He also appeared to have Kussmaul respirations with severe tachypnea but had breath sounds clear to auscultation bilaterally. On further examination, the patient appeared to have intravenous (IV) injection markings along his arms suggesting the possibility of IV drug use.

Laboratory and imaging evaluation in the ED included numerous diagnostic tests. Abnormal laboratory results were found within the complete blood count, comprehensive metabolic panel, lactic acid, lactate dehydrogenase, creatine kinase, C-reactive protein, procalcitonin, high-sensitivity troponin, B-type natriuretic peptide, D-dimer, international normalized ratio, fibrinogen, urinalysis, urine culture, blood cultures, arterial blood gas, and urine drug screen. An electrocardiogram (ECG), chest radiograph (CXR), computed tomography (CT) of the head without contrast, and CT of the chest, abdomen, and pelvis with contrast were ordered.

Unfortunately, the patient's mental and respiratory status did not improve while in the ED and he was intubated and mechanically ventilated due to hypoxic respiratory failure. He was started on a propofol infusion for post-intubation sedation, which assisted in blood pressure reduction. Given his hyperthermia at 105.5°F, passive cooling was initiated, and judicious fluid administration was considered in light of possible congestive heart failure. Thus, a one-liter normal saline bolus was administered. Broad spectrum antibiotics including vancomycin and piperacillin/tazobactam were initiated as well. The patient was admitted to the intensive care unit (ICU).

### CASE DISCUSSION (Attending Discussion)

Based on the limited information, the differential diagnosis inferred from the patient's presentation remained broad. The top considerations were infection, toxidrome, endocrine abnormality, or metabolic emergency. Based on the laboratory and imaging results presented below in Table 1 and Images 1 and 2, certain diagnoses were considered more or less likely. For example, due to the patient's tachycardia, hyperthermia, and altered mental status, thyroid storm was considered in the differential diagnosis. No thyroid studies were ordered as there were other more likely causes of the patient's presentation. Another endocrine abnormality considered was diabetic ketoacidosis, but this was less likely considering a blood glucose level in the high 100s, negative ketones in the urine, as well as a pH that was slightly alkaline. Examination showed no signs of major trauma or focal neurological deficits. Imaging of

**Table 1.** Laboratory values of a 48-year-old male with respiratory distress and altered mental status.

| Laboratory name   | Laboratory value     | Reference ranges |
|---|----------------------|------------------|
| <b>Complete Blood Count</b>                                   |                      |                  |
| White blood cell  | 16.35                | 4.50-11 mL       |
| Hemoglobin  | 13.7                 | 13.5-18 g/dL     |
| Hematocrit  | 43.9                 | 40.0-54.0%       |
| Platelet count  | 194                  | 130-500 K/mL     |
| Neutrophil percentage   | 88.1                 | 40.0-74.0%       |
| Lymphocyte percentage   | 4.8                  | 19.0-48.0%       |
| <b>Comprehensive Metabolic Panel</b>                          |                      |                  |
| Sodium  | 131                  | 135-147 3.4-     |
| Potassium   | 4.0                  | 5.3 mEq/L        |
| Chloride  | 96                   | 96-108 mEq/L     |
| Carbon dioxide  | 21                   | 22-32 mEq/L      |
| Anion gap   | 14                   | 0-16             |
| Glucose   | 186                  | < 133            |
| Blood urea nitrogen   | 43                   | 7-23 mg/dL       |
| Creatinine  | 2.2                  | 0.4-1.3 mg/dL    |
| Estimated glomerular filtration rate (Black/African American) | 38.9                 | ≥ 60             |
| Blood urea nitrogen/ Creatinine ratio                         | 19                   | 7-28 Ratio       |
| Calcium   | 9.1                  | 8.6-10.5 mg/dL   |
| Total Bilirubin   | 8.7                  | 0.2-1.4 mg/dL    |
| Aspartate aminotransferase                                    | 151                  | 5-34 U/L         |
| Alanine aminotransferase                                      | 47                   | 5-50 U/L         |
| Alkaline phosphatase  | 95                   | 46-116 U/L       |
| Total protein   | 7.2                  | 6.0-8.0 g/dL     |
| Albumin   | 3.8                  | 3.5-5.0 g/dL     |
| <b>Miscellaneous Labs</b>                                     |                      |                  |
| Lactic acid   | 2.6                  | 0.5-2.2 mmol/L   |
| Procalcitonin   | 125.37               | <0.050 ng/ml     |
| High sensitivity troponin #1                                  | 492.4                | 0-53.5 ng/ml     |
| High sensitivity troponin #2                                  | 585.9                | 0-53.5 ng/ml     |
| Myoglobin   | >900                 | <10-110 ng/ml    |
| Total creatine kinase   | 5913                 | 46-171 U/L       |
| Lactate dehydrogenase   | 457                  | 120-246 U/L      |
| Brain natriuretic peptide                                     | 1317.6               | 0-100.0 pg/ml    |
| C-reactive protein  | 185.9                | 0-10 mg/L        |
| International normalized ratio                                | 1.4                  | 0.8-1.2          |
| Partial thromboplastin time                                   | 34.3                 | 25.0-37.0 sec    |
| D-dimer   | 1.810                | <0.500 mg/ml     |
| Fibrinogen  | 604                  | 175-400 mg/dL    |
| Salicylates   | <3.0                 | 2.0-29.0 mg/dL   |
| Acetaminophen   | 4                    | 0-199 mg/ml      |
| Ethyl alcohol   | <10                  | 0-10 mg/dL       |
| COVID-19 PCR  | Presumptive negative | Not Detected     |
| <b>Arterial Blood Gas</b>                                     |                      |                  |
| pH  | 7.49                 | 7.35-7.45 pH     |
| pCO <sub>2</sub>  | 27.5                 | 35.0-45.0 mm Hg  |

*mL*, microliters; *g*, grams; *dL*, deciliter; *K*, thousand; *mEq*, milliequivalents; *L*, liter; *mg*, milligrams; *U*, units; *mmol*, millimoles; *ng*, nanogram; *ml*, milliliters; *sec*, seconds; *COVID-19 PCR*, coronavirus disease 2019 polymerase chain reaction test; *pCO<sub>2</sub>*, partial pressure of carbon dioxide.



**Table 1.** Continued.

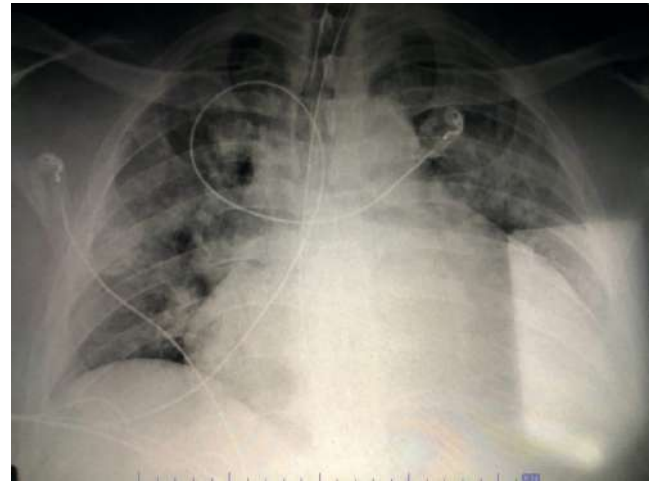
| Laboratory name          | Laboratory value | Reference ranges     |
|--------------------------|------------------|----------------------|
| pO <sub>2</sub>          | 75.5             | 80.0-100 mm Hg       |
| HCO <sub>3</sub>         | 20.3             | 22.0-26.0 mEq/L      |
| Total CO <sub>2</sub>    | 21.1             | 22-32 mEq/L          |
| Oxygen Saturation        | 93%              | 94-97%               |
| <b>Urinalysis</b>        |                  |                      |
| Urine protein            | 4+               | Negative             |
| Urine ketones            | Negative         | Negative             |
| Urine blood              | 3+               | Negative             |
| Urine nitrite            | Positive         | Negative             |
| Urine leukocyte esterase | 1+               | Negative             |
| Urine red blood cells    | 0-4              | 0-4/high power field |
| Urine white blood cells  | 75-100           | 0-2/high power field |
| Urine epithelial cells   | Moderate         | No Units. No Range.  |
| Urine bacteria           | Marked           | No Units. No Range.  |
| Urine glucose            | Negative         | Negative             |
| <b>Urine Drug Screen</b> |                  |                      |
| Amphetamines             | Positive         | Negative             |
| Methamphetamines         | Positive         | Negative             |
| Cannabinoids             | Positive         | Negative             |

*mm Hg*, millimeters of mercury; *pO<sub>2</sub>*, partial pressure of oxygen; *mm Hg*, millimeters of mercury; *HCO<sub>3</sub>*, bicarbonate; *mEq*, milliequivalents; *L*, liter.

the head, chest, abdomen, and pelvis showed no acute fractures or hemorrhage, decreasing the chance of the patient suffering from pathology such as pneumothorax, internal bleeding, or an acute cerebral vascular accident.

The patient presented in obvious respiratory distress and had oxygen saturations of only 91% on arrival, making cardiopulmonary diagnoses high on our list of differential diagnoses. Given the pitting edema, respiratory failure, and the CXR (Image 1) showing cardiomegaly, new-onset heart failure was suspected. The patient also had an elevated troponin level, but no signs of ST-segment elevation on ECG as seen in Image 2. The troponin was likely elevated due to the patient's significantly elevated blood pressure suggesting hypertensive emergency. His elevated white blood cell count, slightly elevated lactic acid level, and abnormal vital signs indicated severe sepsis likely from an infectious source with the most likely etiology an acute urinary tract infection, based on urinalysis results. Renal insufficiency was noted on laboratory evaluation as well, likely resulting from cardiac dysfunction or severe sepsis with multiorgan dysfunction.

Toxidromes or overdose were also considered. The patient had no reported or known medical history, so prescribed psychiatric medications were unlikely. Salicylate toxicity was considered given the patient's respiratory alkalosis, pulmonary



**Image 1.** Anterior-posterior chest radiograph of a 48-year-old male with respiratory distress and altered mental status.

edema, hyperthermia, and altered mental status. However, initial salicylate levels were negative as were acetaminophen and ethanol levels. Alcohol withdrawal was considered as well due to the patient's altered mental status and autonomic instability, but no other exam or history findings supported this. His urine drug screen was positive for methamphetamine, amphetamines, and cannabinoids. The physical exam findings were concerning for signs of IV drug use suggesting that this patient's acute illness was possibly related to polysubstance abuse. Infective endocarditis was a consideration as well based on his fever, IV drug use, and likely new congestive heart failure. However, further diagnostic studies with echocardiogram and blood culture results would be needed to include or exclude this diagnosis.

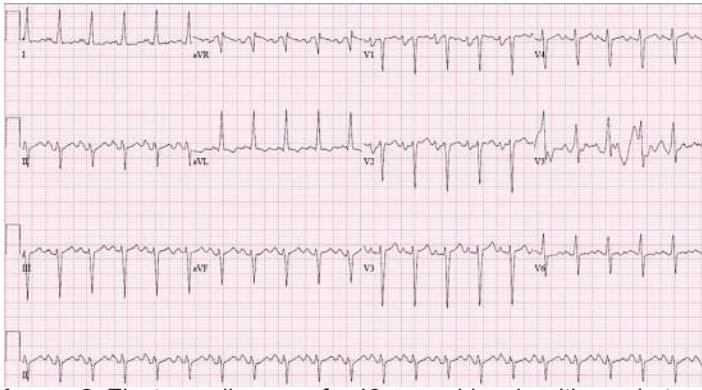Central nervous system infection was considered as well and further testing with lumbar puncture could be performed to assess for this. Given the patient's presentation, vital signs, labs, and imaging findings, the conclusion could be made that he suffered from cardiogenic and septic shock. Sources of acute illness include urinary infection, possible endocarditis or bacteremia, and polysubstance abuse.

## CLINICAL DIAGNOSIS

Cardiorenal syndrome (CRS) secondary to septic shock and tachycardia-induced cardiomyopathy.

## CASE OUTCOME

In the ED, the patient was diagnosed with cardiorenal syndrome based on a combination of other diagnoses including severe sepsis secondary to urinary tract infection, congestive heart failure, non-ST segment elevation myocardial infarction (NSTEMI), hypertensive emergency, hypoxic respiratory failure, acute kidney injury, and polysubstance abuse including methamphetamine and marijuana. He was admitted to the ICU, and consulting



**Image 2.** Electrocardiogram of a 48-year-old male with respiratory distress and altered mental status.

specialties included neurology, cardiology, nephrology, pulmonology, and infectious disease.

The neurologist reported the patient's acute metabolic encephalopathy was multifactorial and related to methamphetamine abuse, hyperthermia, hypoxia, and sepsis. While in the ICU, the patient self-extubated after three days and was alert and oriented to person, place, and time. Evaluation by cardiology determined that the patient suffered from hypertensive emergency with non-STEMI and was started on aspirin and a heparin drip. Transesophageal echocardiogram was negative for vegetations or valvular lesions. Left ventricular ejection fraction was 15–20% with signs of combined systolic and diastolic heart failure and was attributed to methamphetamine use. The patient required vasopressor therapy with norepinephrine and vasopressin as well as dobutamine for cardiogenic shock. The cardiologist discussed potential cardiac catheterization once stabilized; however, given global hypokinesia, it was unlikely for there to be single vessel disease.

The pulmonologist and nephrologist agreed the acute respiratory failure with hypoxia was due to pulmonary edema. After chart review, the patient was found to have acute on chronic kidney disease. The cause of this injury was likely multifactorial including CRS given the clinical picture of volume overload, tachycardia-induced cardiomyopathy from methamphetamine abuse with decreased left ventricular ejection fraction, and potential acute tubular necrosis secondary to septic shock. A furosemide trial did not produce adequate urine output, so the patient was started on sustained, low-efficiency dialysis and his respiratory status improved. Nephrology supported the diagnosis of CRS and mentioned that the patient might have a mixed picture of cardiogenic and septic shock, which would be consistent with CRS, specifically type five.

The infectious disease specialist diagnosed the patient with septic shock due to bacteremia from Gram-positive cocci in chains likely secondary to IV drug use, and initiated treatment with ceftriaxone and clindamycin. Based on leukocytosis and increasing procalcitonin, IV immunoglobulin was added for possible toxic shock syndrome secondary to

**Table 2.** Classification of cardiorenal syndrome based on a system proposed by Ronco and McCullough.<sup>2</sup>

| Cardiorenal Syndrome Type      | Characteristics   |
|--------------------------------|---|
| Type 1 (acute cardiorenal)     | Acute cardiac impairment leading to acute kidney injury         |
| Type 2 (chronic cardiorenal)   | Chronic cardiac impairment leading to renal impairment          |
| Type 3 (acute renocardiac)     | Acute kidney injury leading to cardiac impairment               |
| Type 4 (chronic renocardiac)   | Chronic kidney disease leading to cardiac impairment            |
| Type 5 (secondary cardiorenal) | Systemic condition leading to both cardiac and renal impairment |

group A streptococcal bacteremia. The patient responded positively to the above treatments. On repeat blood cultures, he was positive for *Enterococcus faecalis*. In addition, he had an elevated rapid plasma reagin titer consistent with late, latent syphilis. The patient ultimately left the hospital against medical advice despite extensive discussion regarding his multiple diagnoses requiring further management and care.

## RESIDENT DISCUSSION

Cardiorenal syndrome encompasses a spectrum of disorders involving both the heart and kidneys in which acute or chronic dysfunction in one organ may induce acute or chronic dysfunction in the other organ.<sup>1</sup> Cardiorenal syndrome is divided into two major groups, cardiorenal and renocardiac syndromes, and five subgroups based on which organ is the cause of damage to the other organ.<sup>2</sup> These hemodynamic interactions of the heart and kidney are affected by heart failure and atherosclerotic disease in both organ systems. They are also affected by chronic kidney disease (CKD) and the alterations it causes in the neurohormonal activation, cytokines, and the biochemical perturbations across the anemia–inflammation–bone mineral axis.<sup>1</sup> Structural changes in the heart unique to kidney disease progression also play a role in the development of CRS.<sup>1</sup>

As summarized in Table 2, there are five types of CRS:<sup>2</sup> CRS type 1 is characterized by acute worsening of cardiac function leading to an acute kidney injury (AKI);<sup>3</sup> CRS type 2 is characterized by chronic cardiac dysfunction leading to renal dysfunction and can be used to describe chronic heart failure leading to renal failure;<sup>3</sup> CRS type 3 is characterized by acute cardiac dysfunction as a result of acute renal impairment;<sup>3</sup> CRS type 4 describes CKD leading to cardiac dysfunction (left ventricular failure or diastolic heart failure);<sup>3</sup> and CRS type 5 is characterized by simultaneous cardiac and renal dysfunction as a part of a systemic condition whether it be acute or chronic. This most commonly includes systemic conditions such as sepsis and less so other conditions such as amyloid or vasculitis.<sup>3</sup>

In the acute setting, severe sepsis represents the most common and serious condition, which can affect both

organs.<sup>4</sup> It can induce AKI while leading to profound myocardial depression.<sup>4</sup> The onset of myocardial functional depression and a state of inadequate cardiac output can further decrease renal function as discussed in type 1 CRS, and the development of AKI can affect cardiac function as described in type 3 CRS.<sup>1</sup> Renal ischemia may then induce further myocardial injury in a vicious cycle injurious to both organs.<sup>1</sup>

To diagnose CRS, tools include biomarkers such as brain natriuretic peptide, echocardiography, and renal ultrasound. In addition, measuring central venous pressure, systolic pulmonary artery pressure, pulmonary capillary wedge pressure and left atrial pressure, and cardiac output will help in determining degree of congestion.<sup>1</sup> Renal ultrasonography helps identify renal venous congestion and its clinical significance in CRS.<sup>1</sup>

Diuretics are key in treating CRS.<sup>1</sup> However, the kidneys can stop responding due to the “braking phenomenon.”<sup>1</sup> For cardiogenic shock and severe hypotensive episodes in patients with CRS, which can cause oliguria or anuria, inotropes are frequently used to improve cardiac output and renal blood flow.<sup>5</sup> Historically, low-dose dopamine has been used to increase renal blood flow although there is conflicting evidence regarding its effect upon glomerular filtration rate.<sup>5</sup> No clinical trial to date has demonstrated a benefit with regard to lower mortality rates.<sup>5</sup> Trials of dobutamine and milrinone have shown improvement of cardiac index and, in proportion, renal blood flow; however, this has not translated into survival benefit.<sup>5</sup> Treatment is directed at the prompt identification, eradication, and treatment of the source of infection while supporting organ function with invasively guided fluid resuscitation in addition to inotropic and vasopressor drug support.<sup>6</sup>

## FINAL DIAGNOSIS

Cardiorenal syndrome type 5.

## KEY TEACHING POINTS

- Cardiorenal syndrome is considered dysfunction in the heart or kidneys that worsens the function of the other organ. It has multiple contributing factors such as neurohormonal system activation leading to reduced forward flow and renal perfusion and increased venous pressure.<sup>3</sup>
- CRS is classified into two major groups, cardiorenal and renocardiac, and five subgroups based on which organ is the cause of damage to the other organ.
- To diagnose CRS, tools include biomarkers such as brain natriuretic peptide, echocardiography,

and renal ultrasound as well as measuring central venous pressure, systolic pulmonary artery pressure, pulmonary capillary wedge pressure and left atrial pressure, and cardiac output.

- Early diagnosis is important, and medical treatment options are focused on improving cardiac function, reducing volume overload, and managing heart failure and chronic kidney disease.<sup>3</sup>

The authors attest that their institution requires neither Institutional Review Board approval, nor patient consent for publication of this case report. Documentation on file.

*Address for Correspondence:* Justin E. Pile, DO, MS, Swedish Hospital Part of Northshore, Department of Emergency Medicine, 5140 North California Avenue, Chicago, IL60625. Email: [jpile@schosp.org](mailto:jpile@schosp.org).

*Conflicts of Interest:* By the *CPC-EM* article submission agreement, all authors are required to disclose all affiliations, funding sources and financial or management relationships that could be perceived as potential sources of bias. The authors disclosed none.

*Copyright:* © 2021 Pile et al. This is an open access article distributed in accordance with the terms of the Creative Commons Attribution ([CC BY 4.0](http://creativecommons.org/licenses/by/4.0/)) License. See: <http://creativecommons.org/licenses/by/4.0/>

## REFERENCES

1. Ranganwami J, Bhalla J, Chang T, et al. Cardiorenal Syndrome: Classification, Pathophysiology, Diagnosis, and Treatment Strategies: a scientific statement from the American Heart Association. *Circulation*. 2019;139(16):e840-78.
2. Ronco C, McCullough P, Anker S, et al. Cardio-renal syndromes: report from the Consensus Conference of the Acute Dialysis Quality Initiative. *Eur Heart J*. 2010;31(6):703-11.
3. Hadjiphilippou S and Kon S. Cardiorenal syndrome: review of our current understanding. *J R Soc Med*. 2016;109(1):12-7.
4. Ronco C and Di Lullo L. Cardiorenal syndrome. *Heart Fail Clin*. 2014;10(2):251-80.
5. Shah BN and Greaves K. The cardiorenal syndrome: a review. *Int J Nephrol*. 2010;2011:920195.
6. Ronco C, Haapio M, House A, et al. Cardiorenal syndrome. *J Am Coll Cardiol*. 2008;52(19):1527-39.

# Acute Myocardial Infarction in a Patient with Twin Pregnancy: A Case Report

Tony Michaelis, DO\*  
Satheesh Gunaga, DO\*  
Tyson McKechnie, DO\*  
Kaiser Shafiq, MD†

\*Henry Ford Wyandotte Hospital, Department of Emergency Medicine,  
Wyandotte, Michigan

†Henry Ford Wyandotte Hospital, Department of Medicine/Division of Cardiology,  
Wyandotte, Michigan

Section Editor: R. Gentry Wilkerson, MD

Submission history: Submitted May 2, 2021; Revision received June 25, 2021; Accepted June 22, 2021

Electronically published October 5, 2021

Full text available through open access at [http://escholarship.org/uc/uciem\\_cpchem](http://escholarship.org/uc/uciem_cpchem)

DOI: 10.5811/cpchem.2021.6.52939

**Introduction:** Acute myocardial infarction (AMI) rarely occurs during pregnancy and presents unique challenges in diagnosis and management. Traditionally, pregnancy has not readily been considered a risk factor for AMI in the emergency department despite the potential for adverse impacts on maternal and fetal health. As cardiovascular risk factors and advanced maternal age become more prevalent in society over time, the incidence will continue to increase. Prior cases with singular gestation have been reported; however, only one previous case during a twin pregnancy was identified in the medical literature.

**Case Report:** We describe a rare case of acute ST-segment elevation myocardial infarction in a 37-year-old woman at 24 weeks gestation with a dichorionic diamniotic twin pregnancy.

**Conclusion:** It is important for the emergency physician to recognize acute coronary syndrome as a part of the differential diagnosis of chest pain in pregnant patients and be familiar with the diagnostic and management options available for this special population. [Clin Pract Cases Emerg Med. 2021;5(4): 507-510.]

**Keywords:** Case report; acute myocardial infarction; STEMI; twin pregnancy; acute coronary syndrome.

## INTRODUCTION

It can be difficult to discern which seemingly healthy young women with no prior cardiovascular risk factors are suddenly at risk for acute myocardial infarction (AMI) simply because they are pregnant. Acute myocardial infarction has a reported incidence in pregnancy between three to 100 per 100,000 live births.<sup>1-3</sup> Traditional cardiovascular risk factors remain pertinent in all patient populations; however, pregnancy-specific risk factors for AMI include advanced maternal age, preeclampsia, thrombophilia, postpartum infection, and hemorrhage.<sup>3,4</sup> Physiologic changes in pregnancy contribute to increased cardiac demand, and overall the risk of ischemic cardiac events increases with maternal age.<sup>1,3,4</sup> Acute myocardial infarction in pregnancy presents unique diagnostic and management challenges as seen in this case. Here we discuss an ST-segment elevation myocardial infarction (STEMI) in a 37-year-old woman at 24 weeks

gestation with a dichorionic diamniotic twin pregnancy who presented to the emergency department (ED).

## CASE REPORT

A 37-year-old, gravida 4 para 3003, Caucasian female in her twenty-fourth week of pregnancy presented to the ED with intermittent bilateral arm pain of two days duration. The pain began suddenly, lasted less than 10 minutes, and resolved spontaneously without exacerbating or alleviating factors. Past medical history included hypothyroidism, anemia, and anxiety but did not include traditional cardiovascular risk factors. Her presenting blood pressure was 100/70 millimeters of mercury with a heart rate of 115 beats per minute. Physical exam was unremarkable, with normal heart sounds, no murmurs, clear lung sounds bilaterally, no peripheral edema, normal pulses, and a gravid abdomen. Initial electrocardiography showed sinus tachycardia with T-wave inversions in leads III and aVF,



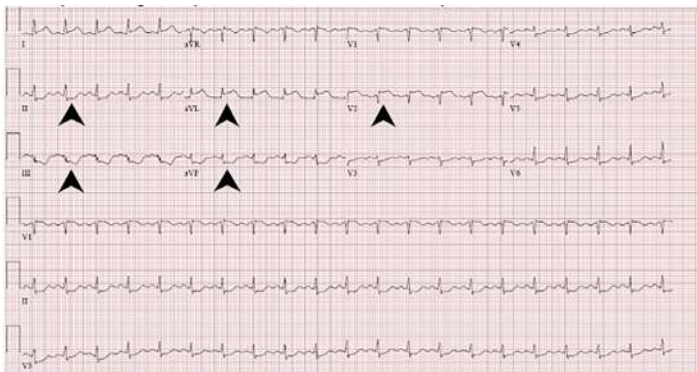
but no ST-segment elevations or depressions. Laboratory analysis showed a hemoglobin of 8.5 grams per deciliter (g/dL) (reference range: 12-15 g/dL) consistent with baseline anemia; otherwise, her basic metabolic, coagulation, renal, and hepatic panels were within normal limits.

Differential diagnosis included pericarditis, myocarditis, coronary dissection, coronary vasospasm, and musculoskeletal pain. However, AMI was low on the initial differential, and troponins were not ordered on initial laboratory studies. Approximately one hour later, she experienced another episode of bilateral arm pain with radiation to her upper back. A repeat electrocardiogram was then obtained, which showed ST-segment elevations in leads I, aVL, V1 and V2 with reciprocal depressions in II, III and aVF (Image 1).

Add-on troponin-I to the initial laboratory studies was 217 nanograms per liter (ng/L) (reference range: less than 19 ng/L). Because the etiology of ST-segment changes in pregnancy can be from entities other than a ruptured atherosclerotic plaque, such as coronary dissection or vasospasm, the cardiologist and emergency physician obtained a STAT formal transthoracic echocardiogram. This showed hypokinesis of the entire anterior, anteroseptal, and anterolateral left ventricular walls and reduced ejection fraction of 40% without pericardial effusion or right ventricular enlargement (Video).

In the presence of significant wall motion abnormalities, AMI was highly likely, and the patient underwent emergent percutaneous coronary intervention (PCI). A repeat troponin level at two hours was 2447 ng/L. Emergent PCI revealed 90% stenosis of the proximal left anterior descending artery due to plaque rupture and thrombus, and the lesion was repaired using balloon angioplasty and placement of a drug-eluting stent (DES) (Image 2).

The patient was treated with dual antiplatelet therapy (DAPT) including aspirin and clopidogrel. She was transferred



**Image 1.** Repeat electrocardiogram one hour into emergency department visit performed during recurrence of symptoms. Black arrows on aVL and V2 show prominent ST-segment elevation, and black arrows on II, III, and aVF show reciprocal ST-segment depression. Lead I is also elevated but less prominent.

### CPC-EM Capsule

What do we already know about this clinical entity?

*Acute myocardial infarction (AMI) affects less than 0.1% of pregnancies, however when it occurs the lives of both mother and fetus are at significant risk of morbidity and mortality.*

What makes this presentation of disease reportable?

*Pregnancy causes physiologic changes that uniquely predispose young women towards increased risk for AMI. This is the second reported case of AMI in a twin pregnancy.*

What is the major learning point?

*Emergency medicine physicians should increase their suspicion for AMI in the pregnant population, especially in the setting of atypical symptoms.*

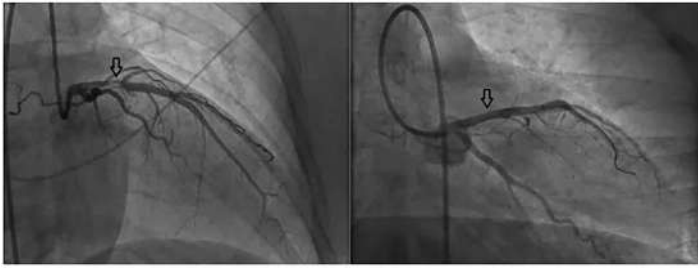
How might this improve emergency medicine practice?

*Early recognition of pregnancy specific risk factors and maintaining broad differentials for chest pain in pregnancy can help improve patient outcomes.*

to a tertiary care hospital for high-risk maternal-fetal medicine and cardiology evaluations. Her post-PCI course was uneventful, and three days later she was discharged home. She delivered two healthy children at 35 weeks via cesarean section (C-section) that was complicated by postpartum hemorrhage. She recovered fully and remained asymptomatic on DAPT without bleeding complications on follow-up six months later.

### DISCUSSION

Acute myocardial infarction is a rare and life-threatening condition during pregnancy. Most AMIs will occur during the third trimester and peak around the peripartum and postpartum periods.<sup>5</sup> Pregnant patients are a vulnerable population that may present with atypical signs and symptoms, inconsistent with classic anginal symptoms such as chest pain, shortness of breath, diaphoresis, and nausea. Symptoms may be dismissed as disorders common to pregnancy including gastroesophageal reflux, musculoskeletal complaints, and shortness of breath due to a cephalad deviation of abdominal organs.<sup>4</sup> The cornerstone of emergency medicine is evaluating patients for life-threatening etiologies, especially in a pregnant patient who is at increased risk



**Image 2.** Cardiac catheterization images were taken before and after stent placement. On the left, the arrow identifies disruption of blood flow from the left anterior descending artery occlusion before stent placement. On the right, the arrow identifies the repaired left anterior descending artery after stent placement.

of morbidity and mortality. Although rare, AMI in pregnancy holds maternal and fetal mortality rates of up to 11% and 9%, respectively; thus, consideration of this diagnosis is critical.<sup>2</sup>

The etiology of STEMI in pregnancy includes atherosclerotic disease, coronary dissection, thrombosis, vasospasm of the coronary arteries, acute pulmonary embolism, and ischemia secondary to substance abuse with cocaine. One third of AMIs in pregnancy are due to underlying coronary artery disease and occur in the anterior wall involving the left anterior descending coronary artery.<sup>6</sup> Our patient had none of the classic risk factors such as smoking, hypertension, obesity, family history, or diabetes, but she had pregnancy-specific risks. She was 37 years old and had an active third trimester, twin pregnancy. When compared to singleton pregnancies, multiparous gestations have a significantly higher prevalence of preeclampsia, thrombophilia, and post-partum complications, all of which are pregnancy-related risk factors for AMI.<sup>3,4,7</sup> While no formal definition for advanced maternal age exists, 75% of AMI in pregnancy occurs after age 30, and 43% after age 35.<sup>3,4</sup> Pregnant women above age 40 are more than 30 times more likely to have an AMI.<sup>3</sup>

Physiological changes make pregnancy a hypercoagulable state due to increased progesterone and estrogen, increasing risk of thrombosis that can cause AMI and pulmonary embolism. Other physiologic changes in pregnancy include blood volume expansion, causing increased cardiac preload, which places higher metabolic demands on the myocardium, thus increasing the risk for ischemic events. These changes contribute to a 3- to 4-fold increased risk of AMI in pregnancy.<sup>1,3</sup> Race has not been shown to increase the risk.<sup>3</sup>

Electrocardiogram and troponin-I levels remain the cornerstone of AMI diagnosis. The rare occurrence of these events in combination with atypical symptoms in otherwise healthy pregnant woman often makes the diagnosis of AMI challenging. In this case, the initial ECG did not show ST-segment elevations or depressions. Acute myocardial infarction was reconsidered after her symptoms returned in the ED, which prompted the repeat ECG that showed a STEMI.

Elevated troponin I is also seen in the case of pericarditis, myocarditis, demand ischemia, acute pulmonary embolism, and other cardiac conditions. However, troponins remain the standard for evaluating cardiac ischemia as levels are not affected by pregnancy, unlike creatine kinase-MB, which elevates with uterine contractions.<sup>4</sup>

Imaging can also be helpful in evaluating possible diagnoses and may include computed tomography and echocardiogram. We chose to obtain an echocardiogram as it is a safe, non-radiating tool that allows for maximal diagnostic return to evaluate for a pericardial effusion (dissection or pericarditis), right ventricle enlargement (pulmonary embolism), and cardiac wall motion abnormalities (AMI). Echocardiogram may also reveal pregnancy-related changes such as left ventricular hypertrophy.<sup>2</sup> Computed tomography angiography for pulmonary embolism or dissection in pregnancy does not have an absolute contraindication and provides valuable diagnostic information, but risks and benefits for mother and fetus should always be considered. The American College of Obstetricians and Gynecologists recommends that life-saving interventions not be withheld from patients solely based on pregnancy.<sup>8,9</sup>

“Time is muscle” when it comes to AMI: the primary goal is reversal of the blockage as quickly as possible to preserve heart function and decrease mortality. Keys to successful treatment of an AMI include anticoagulation and emergent cardiac catheterization. Anticoagulation is a mainstay treatment for any acute coronary syndrome, excluding those caused by coronary artery and aortic dissections. Unfractionated heparin and low molecular weight heparin are preferred anticoagulation agents and are appropriate for use for AMI in pregnancy.<sup>10</sup> In addition to anticoagulation, cardiac catheterization with PCI is of the utmost importance in pregnancy as a means of revascularizing the coronary arteries. The radial artery approach is preferred over femoral to minimize radiation risk and vascular damage near the fetus.<sup>2,11</sup> Femoral access was used in our patient because of the small diameter of her radial artery and potential need of mechanical circulatory support considering she had a left anterior descending artery STEMI in twin pregnancy.

After coronary stent placement, DAPT is required to prevent stent thrombosis. For bare metal stents at least four weeks of DAPT is required, while a DES requires at least 12 months of DAPT. Studies indicate that for DES after three months, DAPT may be interrupted safely if needed. Our patient received the latest generation DES because these stents have a lower rate of in-stent restenosis and successful interruption of DAPT.<sup>2,12</sup> Low-dose aspirin has not been shown to increase maternal or fetal mortality or cause premature closure of the ductus arteriosus, nor has it been shown to have increased risk of complications with epidural anesthesia.<sup>10</sup> Given the duration and increased risk of bleeding, epidural anesthesia is contraindicated in patients receiving DAPT. Clopidogrel is identified as a class B medication in pregnancy and its use is

associated with a higher incidence of C-section hemorrhages, which is likely what contributed to the postpartum hemorrhage seen in our patient on DAPT.<sup>2,4</sup>

## CONCLUSION

In summary, myocardial infarction in pregnancy is a rare but life-threatening event. This case of a twin pregnancy is even more rare, with only one prior case reported in the literature.<sup>13</sup> Evaluation with imaging techniques such as an echocardiogram are of high diagnostic yield and can help guide management of STEMI in pregnancy. Early anticoagulation with low molecular weight heparin or unfractionated heparin, as well as coronary artery revascularization by PCI, are lifesaving measures that should be employed in similar case settings. Acute myocardial infarction in pregnancy is a life threat in a patient population that is generally under-recognized as being at risk. Pregnancy must be considered as a potential risk factor for cardiac disease, particularly in the face of an atypical presentation as seen in this case. The emergency physician must be vigilant in considering a broad differential diagnosis in pregnant patients and be prepared to manage this rare but potentially fatal condition.

**Video.** Apical four-chamber formal echocardiogram with arrows highlighting septal and apical hypokinesis. LA, left atrium; LV, left ventricle; RA, right atrium; RV, right ventricle.

The authors attest that their institution requires neither Institutional Review Board approval nor patient consent for publication of this case report. Documentation on file.

---

*Address for Correspondence:* Tyson McKechnie, DO, Henry Ford Wyandotte Hospital, Department of Graduate Medical Education, 2333 Biddle Ave., Wyandotte, MI 48192. Email: tysonmck@gmail.com.

*Conflicts of Interest:* By the CPC-EM article submission agreement, all authors are required to disclose all affiliations, funding sources and financial or management relationships that could be perceived as potential sources of bias. The authors disclosed none.

*Copyright:* © 2021 Michaelis et al. This is an open access article distributed in accordance with the terms of the Creative Commons Attribution (CC BY 4.0) License. See: <http://creativecommons.org/licenses/by/4.0/>

---

## REFERENCES

1. Iadanza A, Del Pasqua A, Barbati R, et al. Acute ST elevation myocardial infarction in pregnancy due to coronary vasospasm: a case report and review of literature. *Int J Cardiol.* 2007;115(1):81-5.
2. Ismail S, Wong C, Rajan P, et al. ST-elevation acute myocardial infarction in pregnancy: 2016 update. *Clin Cardiol.* 2017;40(6):399-406.
3. James AH, Jamison MG, Biswas MS, et al. Acute myocardial infarction in pregnancy: a United States population-based study. *Circulation.* 2006;113(12):1564-71.
4. Poh CL and Lee CH. Acute myocardial infarction in pregnant women. *Ann Acad Med Singap.* 2010;39(3):247-53.
5. Yilmaz S, Sahinkus S, Kilic H, et al. Acute coronary syndrome during pregnancy: a case report and literature review. *Turk J Emerg Med.* 2016;14(3):135-8.
6. Elkayam U, Jalnapurkar S, Barakkat MN, et al. Pregnancy-associated acute myocardial infarction: a review of contemporary experiences in 150 cases between 2006 and 2011. *Circulation.* 2014;129(16):1695-702.
7. Norwitz E, Edusa V, Park JS. Maternal physiology and complications of multiple pregnancy. *Seminars in Perinatology.* 2005;29(5):338-48.
8. ACOG Committee Opinion No. 775: Nonobstetric surgery during pregnancy. *Obstet Gynecol.* 2019;133(4):e285-6.
9. Committee Opinion No.723: Guidelines for diagnostic imaging during pregnancy. *Obstet Gynecol.* 2017;130(4):e210–6.
10. Yarrington CD, Valente AM, Economy KE. Cardiovascular management in pregnancy: antithrombotic agents and antiplatelet agents. *Circulation.* 2015;132(14):1354-64.
11. Kuba K, Wolfe D, Schoenfeld AH, et al. Percutaneous coronary intervention in pregnancy: modeling of the fetal absorbed dose. *Case Rep Obstet Gynecol.* 2019;2019:8410203.
12. Levine GN, Bates ER, Blankenship JC, et al. 2015 ACC/AHA/SCAI focused update on primary percutaneous coronary intervention for patients with ST-elevation myocardial infarction: an update of the 2011 ACCF/AHA/SCAI guideline for percutaneous coronary intervention and the 2013 ACCF/AHA guideline for the management of ST-elevation myocardial infarction. *J Am Coll Cardiol.* 2016;67(10):1235-50.
13. Pildner von Steinburg S, Klein E, Langwieser N, et al. Coronary stenting after myocardial infarction during twin pregnancy: a case report. *Hypertens Pregnancy.* 2011;30(4):485-9.

## Needle Decompression of Tension Pneumoperitoneum: A Case Report

Joseph Ray, MD  
Nadin Exantus, MD

AdventHealth East Orlando, Department of Emergency Medicine, Orlando, Florida

Section Editor: John Ashurst, DO

Submission History: Submitted May 30, 2021; Revision received August 11, 2021; Accepted August 14, 2021

Electronically published November 1, 2021

Full text available through open access at [http://escholarship.org/uc/uciem\\_cpem](http://escholarship.org/uc/uciem_cpem)

DOI: 10.5811/cpcem.2021.8.53447

**Introduction:** Tension pneumoperitoneum is rarely encountered in the emergency department but can have disastrous effects on the body when it is. However, an emergency physician has skills that can be readily applied to needle decompress the abdomen for rapid stabilization.

**Case Report:** A 42-year-old male arrived via ambulance after a likely overdose with mental status improvement following naloxone administration. He was found to be in respiratory distress due to a rigid, distended abdomen that required intubation for stabilization. Computed tomography imaging showed significant pneumoperitoneum with tension physiology. Surgery consultation was unable to intervene immediately, and needle decompression with an angiocatheter was performed at the bedside with immediate ventilatory improvement.

**Conclusion:** Tension pneumoperitoneum is a rare but potentially disastrous consequence of overdose secondary to emesis and rupture of the gastric wall. Needle decompression is a skillset already in the emergency physician's toolbox and can be applied for emergency stabilization of a tension pneumoperitoneum with proper forethought and technique. [Clin Pract Cases Emerg Med. 2021;5(4):511-514.]

**Keywords:** *tension pneumoperitoneum; needle decompression; overdose; gastric perforation.*

### INTRODUCTION

Tension pneumoperitoneum is a rare disease process that few will encounter in the emergency department (ED) setting. While frequently an unexpected adverse event of endoscopic procedures, any perforation of an abdominal hollow viscus can develop into a tension pneumoperitoneum in the right setting.<sup>1</sup> Although definitive management to correct the hollow viscus injury remains surgical, intervention by the emergency physician is warranted in the setting of unstable vital signs or prolonged delay in transfer to the operating room. This case illustrates the use of bedside needle decompression for immediate tension relief and restoration of abdominal organ perfusion prior to operative internal repair.

### CASE REPORT

A 42-year-old male presented to the ED via emergency medical services (EMS) after being found unconscious on

his porch by a neighbor. The EMS team found him minimally responsive with pinpoint pupils and emesis nearby. He was given 2 milligrams (mg) of intranasal naloxone followed by 6 mg of intravenous (IV) naloxone by EMS during transport and regained consciousness. Initially oxygen saturation was 72% and he was placed on 12 liters of supplemental oxygen via a non-rebreather with improvement to 88% by arrival to the ED.

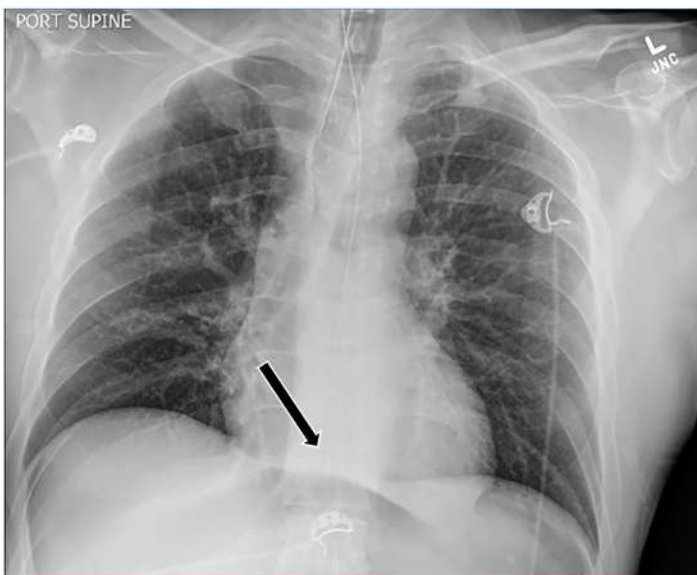
Upon arrival, the patient was awake and noted that he had no past medical history and was not on any prescription medications. He stated he had taken a handful of alprazolam for recreational purposes earlier in the day. His only complaints were significant shortness of breath and mild diffuse abdominal pain. Initial vital signs were heart rate of 154 beats per minute, respiratory rate of 45 breaths per minute, oxygen saturation of 93% on 12 liters per minute oxygen by non-rebreather. Physical examination showed a



male with vomitus on his shirt. He was tachypneic with shallow labored breathing without crackles or wheezing. His abdomen was distended and tense with mild diffuse tenderness to palpation and no external signs of trauma. He was awake and responding appropriately to questions but only in two- to three-word phrases secondary to dyspnea. Remaining physical exam was unremarkable, including peripheral pulses, pupils, and motor function.

The patient's respiratory status continued to deteriorate and he was emergently intubated. His oxygen saturation immediately improved to 98% on the ventilator. A single dose of rocuronium (50 mg) was given for ventilator dyssynchrony, despite the increasing propofol infusion that was initiated for continued and post-intubation sedation. His abdomen remained distended and firm despite orogastric (OG) tube, Foley catheter, and improving respiratory status. Post-intubation chest radiograph (Image 1) showed an OG tube at the level of the diaphragm, a correctly placed endotracheal tube, and no identifiable pathology.

With his improved vital signs and increased stability post intubation, the patient was sent for a computed tomography of the abdomen. Point-of-care labs drawn prior to intubation showed significant values of pH 7.12 (reference range: 7.31-7.41) and partial pressure of carbon dioxide of 61.3 millimeters of mercury (mm Hg) (45-50 mm Hg) on venous blood gas, creatinine of 1.7 milligrams per deciliter (mg/dL) (0.6-1.2 mg/dL), and lactic acid of 5.5 millimoles per liter (mmol/L) (0.5-1.9 mmol/L). Other laboratory results were mostly unremarkable but included white blood cell count of 12.2 thousand/microliter (uL) (4.4-10.5 thousand/uL), glucose



**Image 1.** Post-intubation radiograph showing endotracheal tube placement and orogastric tube just superior to the level of the diaphragm, as shown by arrow.

### *CPC-EM Capsule*

What do we already know about this clinical entity?

*High intraperitoneal pressures do cause immediate life threatening distress and require emergent intervention*

What makes this presentation of disease reportable?

*This entity is most frequently encountered in a surgical setting and managed via operative intervention – leaving emergency medicine physicians less experienced with management*

What is the major learning point?

*Needle decompression, a technique we are well accustomed to regarding the thorax, can also be applied for temporary stabilization of tension pneumoperitoneum.*

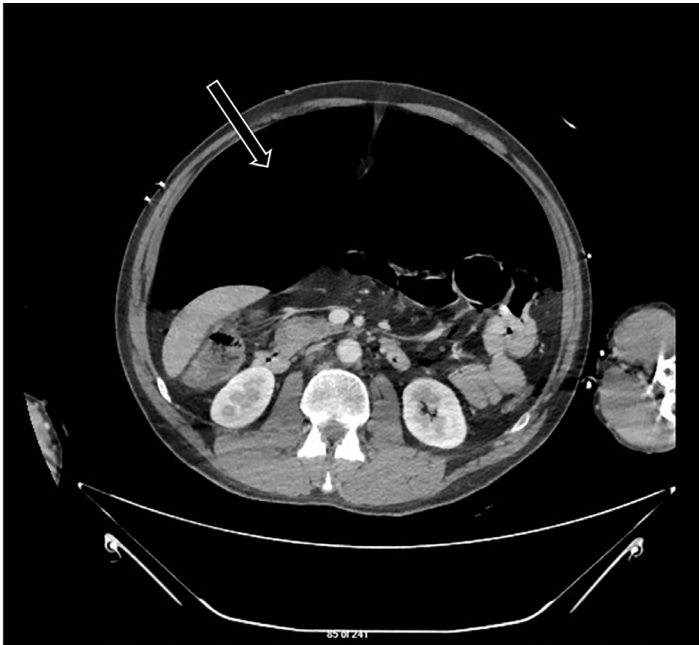How might this improve emergency medicine practice?

*Further heightening suspicion for this disease process and educating on emergency department management.*

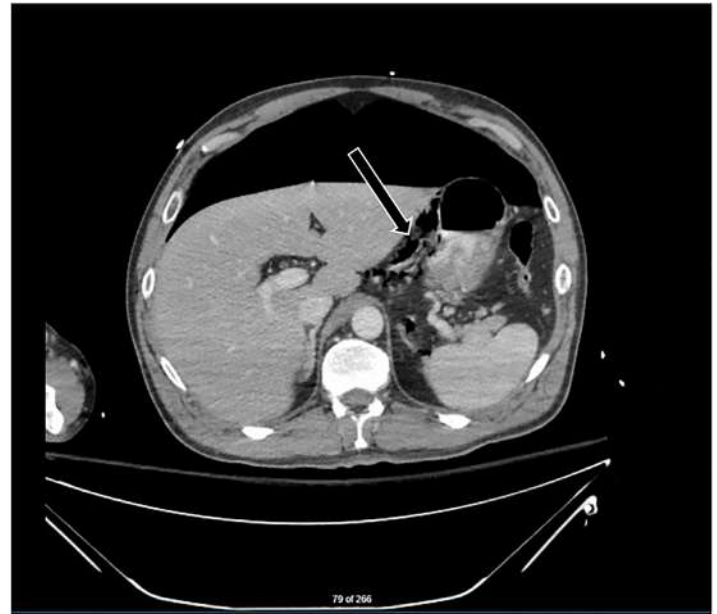of 332 mg/dL (70-100mg/dL), and mildly elevated transaminases. The patient was given vancomycin, cefepime, and IV fluids for presumed severe sepsis.

Computed tomography of the abdomen revealed a large amount of pneumoperitoneum creating tension physiology in the abdominal compartment (Image 2), and general surgery was consulted. Given the emergent nature of the condition, the temporal limitation with the operating room, and surgical staff availability, it was decided that the ED team would needle decompress the abdomen while the operating room was being assembled.

The patient was placed in a supine position and his abdomen sterilized with chlorhexidine. A 14 French angiocath was inserted into the anterior right lower quadrant of the abdomen until a rush of air returned. At that point, the catheter was advanced and the needle removed while air continued to flow from the peritoneal cavity. Once the abdomen was soft, a Luer lock was placed on the angiocath and the angiocath secured with an occlusive dressing. After decompression, ventilator dyssynchrony significantly improved.



**Image 2.** Computed tomography of the abdomen with intravenous contrast at the level of the inferior tip of the liver and kidneys showing large pneumoperitoneum, as noted by arrow, with tension physiology.



**Image 3.** Computed tomography of the abdomen and pelvis with oral contrast at the level of the stomach performed after needle decompression. Large pneumoperitoneum was still present but without tension. Arrow points to air bubbles seen along lesser gastric curvature suggesting location of perforation.

With the patient stabilized, the general surgeon requested a CT of the abdomen and pelvis with oral contrast for further localization of the injury. Due to concerns for perforation, the decision was made to not advance the previously short OG tube any farther but to continue to use it to instill water-soluble contrast into the gastrointestinal tract. While the repeat imaging was not definitive, the likely site of viscous perforation was thought to be the lesser curvature of the stomach (Image 3).

Ultimately the patient was found to have a 1-centimeter (cm) perforation of the lesser curvature of the stomach, which was surgically repaired. He was subsequently admitted to the intensive care unit (ICU) following surgery and discharged home on hospital day seven.

## DISCUSSION

Few cases of tension pneumoperitoneum have been reported in the medical literature; most are the result of either endoscopic procedures or trauma.<sup>1-3</sup> Cardiopulmonary resuscitation (CPR) with rib fracture perforating the stomach has also been noted as a cause of tension pneumoperitoneum.<sup>4</sup> However, the case described here had neither endoscopy nor trauma, instead originating from a spontaneous gastric perforation in conjunction with overdose and intense vomiting.

Tension pneumoperitoneum may be compared to abdominal compartment syndrome in clinical presentation.<sup>5</sup> This may present with abdominal distention, poor abdominal

organ perfusion, and resulting elevated lactic acid levels.<sup>6</sup> The high abdominal compartment pressures will cause splinting of the diaphragm, preventing adequate ventilation, as well as compression of the vena cava, thus decreasing venous return and consequently cardiac output.<sup>6</sup> Patients will likely be critically ill and require immediate stabilization. Our patient required mechanical ventilation due to the diaphragmatic splinting as part of initial stabilization, but cases resulting from trauma or CPR may have multiple concomitant injuries, such as tension pneumothorax,<sup>3</sup> contributing to respiratory failure.

As with tension pneumothorax, needle decompression can provide temporary stabilization by reducing intracompartment pressures. While tension pneumoperitoneum has been described in the surgical literature after endoscopic procedures or abdominal trauma, it has not been well documented as a result of a spontaneous gastric perforation. Furthermore, cases that are documented have been frequently managed by either needle decompression in a surgical ICU or with emergent laparotomy. The case described here is novel for both being the result of a spontaneous gastric perforation and for requiring the needle decompression intervention to be performed by an emergency physician.

While no standard of care has been established on how to perform such a procedure, our technique with a readily available angiocath was highly effective and easy to perform. This technique has been used in surgical services for iatrogenic bowel perforation causing tension

pneumoperitoneum but can also be applied in the ED setting.<sup>7</sup> Consideration of angiocath insertion under ED bedside ultrasound guidance should be considered when attempting to mitigate the risk of further viscous injury. Just as would be the case in an abdominal paracentesis, potential complications include failed procedure, abdominal wall hematoma, spontaneous hemoperitoneum due to mesenteric bleeding, hollow viscus perforation, catheter loss in the abdominal cavity, and major blood vessel laceration.<sup>8</sup>

Many of these risks are mitigated in this situation because the increase in abdominal pressure displaces much of the intra-abdominal contents. Furthermore, surgical entry of the abdominal cavity for definitive management allows for evaluation and resolution of many of the possible complications. Successful placement is verified with the expulsion of air. The patient will still require definitive operative repair; thus, angiocatheter decompression of tension pneumoperitoneum should be done in consultation with a surgeon if the situation and time permits.

## CONCLUSION

Tension pneumoperitoneum has a variety of causes but ultimately requires procedural intervention. Resuscitation will likely be required prior to obtaining this diagnosis, but management will always include surgical consultation. This patient in this case is unique in that his injury was not iatrogenic or traumatic; rather he presented via EMS to the ED with spontaneous perforation after overdose. Furthermore, the needle decompression was performed in the ED prior to exploratory laparotomy. Our case illustrates use of a needle decompression technique for temporization before operative intervention that is easy to perform, provides immediate relief, and is relatively safe when done correctly.

The authors attest that their institution requires neither Institutional Review Board approval nor patient consent for publication of this case report. Documentation on file.

*Address for Correspondence:* Joseph Ray, MD, AdventHealth East Orlando, Department of Emergency Medicine, 7727 Lake

Underhill Road, Orlando, Florida 32822. Email: [joseph.ray.MD@AdventHealth.com](mailto:joseph.ray.MD@AdventHealth.com).

*Conflicts of Interest:* By the CPC-EM article submission agreement, all authors are required to disclose all affiliations, funding sources and financial or management relationships that could be perceived as potential sources of bias. The authors disclosed none. This research was presented at the ACOEP 2021 FOEM Case Report Competition.

*Copyright:* © 2021 Ray. This is an open access article distributed in accordance with the terms of the Creative Commons Attribution (CC BY 4.0) License. See: <http://creativecommons.org/licenses/by/4.0/>

## REFERENCES

1. Serrano-Deunas M, Rodriguez-Munoz M, Portilla-Botelho M. Delayed tension pneumoperitoneum after colonoscopy. *Med Intensive (Engl Ed)*. 2018;42(7):e18.
2. Lin BW and Thanassi W. Tension pneumoperitoneum. *J Emerg Med*. 2010;38(1):57-9.
3. Gumpert R, Archan S, Kugler B, et al. Pneumoperitoneum following tension pneumothorax in combination with traumatic rupture of the diaphragm mimics intraabdominal bleeding. *Injury Extra*. 2008;39:368-70.
4. Johnson S, McCracken J, Baidoun F. Tension pneumoperitoneum after bystander cardiopulmonary resuscitation: a case report. *Int J Surg Case Rep*. 2018;42:227-32.
5. Roepke C, Benjamin E, Jhun P, et al. Air in the belly: a discussion of abdominal compartment syndrome. *Ann Emerg Med*. 2016;67(1):17-9.
6. Rogers W and Garcia L. Intraabdominal hypertension, abdominal compartment syndrome, and the open abdomen. *Chest*. 2018;153(1):238-50.
7. Chiapponi C, Stocker U, Körner M, et al. Emergency percutaneous needle decompression for tension pneumoperitoneum. *BMC Gastroenterol*. 2011;11:48.
8. Duggal P, Farah KF, Anghel G, et al. Safety of paracentesis in inpatients. *Clin Nephrol*. 2006;66(3):171-6.

## Bilateral Cranial Nerve VI Palsies in Cryptococcal Meningitis, HIV, and Syphilis: A Case Report

Germaine Rival, DO, MPH  
Onyi Okorji, DO  
Rachael Kern, DO  
Preya Patel, MD  
Kate Fradeneck, DO  
Darragh Cullen, DO

Jefferson Health Northeast, Department of Emergency Medicine,  
Philadelphia, Pennsylvania

Section Editor: John Ashurst, DO

Submission History: Submitted May 22, 2021; Revision received August 22, 2021; Accepted August 21, 2021

Electronically published November 1, 2021

Full text available through open access at [http://escholarship.org/uc/uciem\\_cpem](http://escholarship.org/uc/uciem_cpem)

DOI: 10.5811/cpem.2021.8.53347

**Introduction:** Cranial nerve (CN) VI palsy is a common complaint seen in the emergency department (ED) and has a wide range of causes. Bilateral CN VI palsies are uncommon and appear to be associated with more severe complications.

**Case Report:** A 29-year-old male presented to the ED from an ophthalmology office for diplopia, headache, and strabismus. He was found to have bilateral CN VI palsies and new-onset seizure in the ED. A lumbar puncture revealed cryptococcal meningitis. Additional tests revealed a new diagnosis of human immunodeficiency virus (HIV), acquired immunodeficiency syndrome (AIDS), and syphilis.

**Conclusion:** Cryptococcal meningitis remains a life-threatening complication of HIV/AIDS. Coinfections with HIV, particularly syphilis, further complicate a patient's prognosis as both can lead to devastating neurological sequelae. In cryptococcal meningitis, elevated intracranial pressure is a complication that can manifest as seizures, altered mental status, and cranial nerve palsies. [Clin Pract Cases Emerg Med. 2021;5(4):515-518.]

**Keywords:** *bilateral cranial nerve VI palsies; cryptococcal meningitis; HIV/AIDS; syphilis; case report.*

---

### INTRODUCTION

Cranial nerve (CN) palsies involving the third, fourth, and sixth cranial nerves are common complaints seen in the emergency department (ED). Cranial nerve VI palsy is the most common isolated ocular neuropathy and is seen in 50% of patients.<sup>1</sup> Causes of CN VI palsies include trauma, demyelination, neoplasm, microvascular ischemia, infection, and elevated intracranial pressure (ICP).<sup>1</sup> Bilateral CN VI palsies herald ominous causes, such as intracranial hemorrhage and brainstem infarction.<sup>1</sup> Patients with this palsy typically present with the inability to abduct the affected eye. Given the potentially life-threatening implications associated with bilateral CN VI palsy, it is important to determine the cause and manage it immediately.

### CASE REPORT

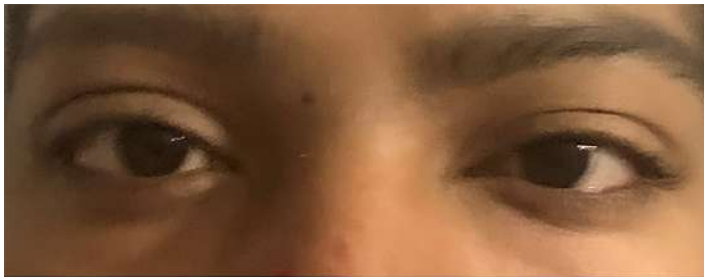A 29-year-old male with a past medical history of Kawasaki disease presented to the ED from an outpatient ophthalmology office for diplopia and strabismus for three days. The patient reported frontal headache with rhinorrhea for five days and was being treated with clindamycin for suspected sinusitis by his primary care physician. The patient was subsequently evaluated by an ophthalmologist, who diagnosed him with bilateral cranial nerve VI palsies and referred him to the ED for further evaluation and management. The patient denied fever, chills, slurred speech, facial droop, vision loss, weakness, or recent trauma. The patient also denied any surgical history, medications, allergies, or any history of smoking,



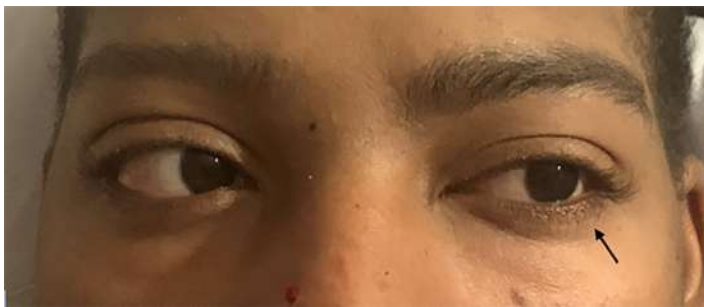excessive alcohol use, or recreational drug use. While in the ED, the patient had a witnessed tonic-clonic seizure, which was successfully managed with intravenous (IV) lorazepam.

On exam, his vitals were as follows: temperature of 37.1 °C, blood pressure 142/88 millimeters mercury, heart rate 94 beats per minute, respiratory rate 20 breaths per minute, and pulse oximetry 100% on room air. The patient was well-appearing and in no acute distress. His head, eyes, ear, nose, and throat exam showed round and equally reactive pupils without nystagmus. The patient's neurologic exam showed an awake, alert and oriented male with bilateral CN VI palsies. Apart from his bilateral CN VI palsies, the rest of his cranial nerve exam was grossly intact. He had 5/5 muscle strength in upper and lower extremities. Finger to nose test was intact. His skin exam revealed bilateral palmar rashes (Images 1, 2, 3).

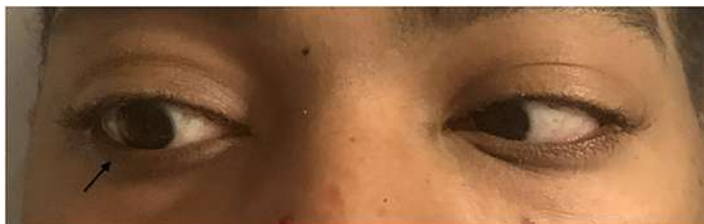The patient's blood tests were significant for mild hyponatremia, leukopenia, and lymphopenia. Computed



**Image 1.** Disconjugate gaze of the left eye.



**Image 2.** Leftward gaze. Patient with difficulty abducting left eye with a leftward gaze.



**Image 3.** Rightward gaze. Patient with difficulty abducting right eye with a rightward gaze.

### *CPC-EM Capsule*

What do we already know about this clinical entity?

*Cryptococcal meningitis is a well-known complication of HIV/AIDS, which can present with unilateral cranial nerve palsy. However, literature on bilateral cranial nerve palsies is limited.*

What makes this presentation of disease reportable?

*This patient presented with atypical symptoms of bilateral CN VI palsies associated with new diagnoses of cryptococcal meningitis, HIV, AIDS, and syphilis.*

What is the major learning point?

*Bilateral CN VI palsies are atypical, yet critical presentations of cryptococcal meningitis, HIV/AIDS, and syphilis.*

How might this improve emergency medicine practice?

*Recognizing atypical presentations of cryptococcal meningitis, such as bilateral CN VI palsies can lead to early evaluation, diagnosis and management.*

tomography (CT) of his brain without IV contrast revealed no mass or hemorrhage. Magnetic resonance imaging (MRI) of his brain and cranial nerves were likewise unrevealing for acute pathology.

He was subsequently admitted for further investigation of his diplopia, bilateral CN VI palsies, and new-onset seizure. Further inpatient evaluation involved a CT venography of the brain, which showed no evidence of cavernous sinus thrombosis. A lumbar puncture revealed an opening pressure of 60 centimeters of water (cm H<sub>2</sub>O) (reference range: 10-25 cm H<sub>2</sub>O), cerebrospinal fluid (CSF) glucose 28 milligrams per deciliter (mg/dL) (40-70 mg/dL), CSF protein 41 mg/dL (15-45 mg/dL), and a positive CSF cryptococcal antigen. Serum rapid plasma reagin and fluorescent treponemal antibody absorption test were both reactive. The fourth-generation HIV immunoassay revealed positive serum HIV-1 antigen and HIV-1 antibody. Absolute CD4 count was 6 cells per microliter (μL) (490 - 1740 cells/μL). In the presence of cryptococcal meningitis along with an absolute CD4 count of 6 cells/μL, the patient met diagnostic criteria for AIDS. The patient was treated with penicillin, amphotericin B, and flucytosine. Trimethoprim-sulfamethoxazole was administered

as prophylactic treatment for *Pneumocystis carinii* pneumonia. The patient was discharged with anti-retroviral therapy and outpatient follow-up with infectious disease. He returned to the ED a few months later for altered mental status and was found to have recurrent cryptococcal meningitis and CN palsy.

## DISCUSSION

Cryptococcal meningitis is a widely recognized complication in immunocompromised patients, particularly those with solid-organ transplants as well as those with HIV/AIDS. It is the leading cause of mortality in these populations, and HIV remains the primary risk factor in contracting cryptococcus worldwide. Elevated ICP, defined as CSF pressure greater than 25 cm H<sub>2</sub>O, is a common complication of cryptococcal meningitis, which results from a failure of CSF resorption in the arachnoid villa due to physical obstruction by the cryptococcal polysaccharide capsule, thus leading to cerebral edema.<sup>2</sup> The larger the size of the cryptococcal capsule and the amount of cryptococcal organisms present in the arachnoid granulations, the more elevated the ICP.<sup>2</sup> Cerebral edema can manifest as headaches, persistent vomiting, papilledema, vision disturbances, blindness, cranial nerve palsy, altered mental status, and coma.

Diagnosis is made by microscopy with India ink staining of CSF or a Sabouraud dextrose agar culture. More recently, cryptococcal antigen flow assays have been used due to their high sensitivity and specificity. Despite this, it is important to note that a normal CSF analysis does not exclude cryptococcal meningitis; this is, in fact, a poor prognostic indicator.<sup>3</sup> According to the 2010 Infectious Diseases Society of America guide-lines, a combination of amphotericin B and flucytosine is the recommended antifungal regimen for cryptococcal meningitis in HIV patients. Management of cryptococcal meningitis can be categorized into three phases: 1) induction; 2) consolidation; and 3) maintenance therapy.<sup>3</sup> Induction therapy's aim is rapid clearance of cryptococcus in the CSF. This can be achieved with a combination of amphotericin B 0.7-1.0 (milligrams per kilogram per day (mg/kg/day) intravenously and flucytosine 100 mg/kg daily orally. Consolidation therapy should be initiated approximately two weeks after induction therapy and consists of fluconazole 400 mg/day for at least eight weeks. After successful sterilization of the CSF with induction and consolidation therapies, culture-negative patients can transition to fluconazole 200 mg/day for maintenance therapy.<sup>4</sup>

Syphilis, a sexually transmitted infection caused by *Treponema pallidum*, has been resurgent in the United States over the past 20 years. Furthermore, high rates of coinfection between syphilis and HIV have been found, which has been largely attributed to similar at-risk populations, such as men who have sex with men.<sup>5</sup> Studies have also demonstrated that HIV viral load is higher when patients are coinfecting with syphilis when compared to those without this coinfection. Moreover, HIV patients whose syphilis infections have been

treated have shown decreased HIV viral loads.<sup>6</sup> Therefore, it is crucial to screen for additional sexually transmitted infections, particularly syphilis, when a diagnosis of HIV/AIDS is suspected or established. Intramuscular penicillin is the recommended antibiotic treatment for syphilis.

Isolated cranial nerve involvement in cryptococcal meningitis is well-documented in literature. However, literature involving bilateral CN VI palsies have been sparse. Case reports of CN VI palsy from infectious causes include Lyme disease, varicella zoster virus (VZV) and neurosyphilis. Nevertheless, these cases are often unilateral and involve additional cranial nerves, such as oculomotor, facial and vagus nerves.<sup>7,8,9</sup> Joo, Lee and Kim (2019) reported a 71-year-old female who presented with vocal cord paralysis and diplopia who later developed a skin rash. A biopsy of the skin lesions showed VZV and the mechanism by which CN VI was involved remain poorly understood.<sup>7</sup> Another case report involving unilateral CN VI palsy was discussed by Lundin et al (2020) in a 70-year-old man with right eye pain and double vision who later developed erythema migrans. This patient was found to have optic neuritis with CN VI palsy secondary to Lyme disease.<sup>8</sup> Jordan, Marino and Damast (1978) were one of the first to document a case report of bilateral cranial nerve paresis in a 61-year-old male with neurosyphilis; however, it involved the oculomotor nerves (CN III) only.<sup>9</sup>

Although this patient was also diagnosed with syphilis, which could have contributed to his bilateral CN VI palsies, his symptoms appeared to improve once amphotericin B and flucytosine were initiated to treat his cryptococcal meningitis, suggesting a possible association between cryptococcal meningitis and CN VI palsy. This could perhaps be due to improvement in cerebral edema and ICP as treatment for meningitis was continued. This case report highlights the possible association of elevated ICP in cryptococcal meningitis with bilateral CN VI palsies complicated by a coinfection with HIV/AIDS and syphilis. Therefore, it is important to stress the significance of immediate recognition and management of cryptococcal meningitis, especially in patients exhibiting signs of increased ICP.

## CONCLUSION

Sexually transmitted infections and complications of HIV/AIDS are common complaints seen in the ED today. Cryptococcal meningitis is a common yet life-threatening complication of HIV. A patient's prognosis could be further complicated by the presence of coinfections, particularly syphilis as both infections have been associated with severe neurological sequelae. Therefore, it is important for emergency physicians to remain vigilant and maintain a high index of suspicion when managing patients with known HIV infection or with atypical presentations.

Patient consent has been obtained and filed for the publication of this case report.

**Address for Correspondence:** Germaine Rival, DO, MPH, Jefferson Health Northeast, Department of Emergency Medicine, 10800 Knights Road, Philadelphia, Pennsylvania 19144. Email: [germaine.rival@jefferson.edu](mailto:germaine.rival@jefferson.edu).

**Conflicts of Interest:** By the CPC-EM article submission agreement, all authors are required to disclose all affiliations, funding sources and financial or management relationships that could be perceived as potential sources of bias. The authors disclosed none. This research was presented at the ACOEP 2021 Spring Seminar Case Poster Competition.

**Copyright:** © 2021 Rival. This is an open access article distributed in accordance with the terms of the Creative Commons Attribution (CC BY 4.0) License. See: <http://creativecommons.org/licenses/by/4.0/>

## REFERENCES

1. Elder C, Hainline C, Galetta SL, et al. Isolated abducens nerve palsy: update on evaluation and diagnosis. *Curr Neurol Neurosci Rep.* 2016;16(8):69-76.
2. Abassi M, Boulware D, Rhein J. Cryptococcal meningitis: diagnosis and management. *Curr Trop Med Rep.* 2015;2(2):90-9.
3. Temfack E, Boyer-Chammard T, Lawrence D, et al. New insights into cryptococcus spp. Biology and cryptococcal meningitis. *Curr Neurol Neurosci Rep.* 2019;19(10):81-91.
4. Perfect JR, Dismukes WE, Dromer F, et al. Clinical practice guidelines for the management of cryptococcal disease: 2010 update by the Infectious Diseases Society of America. *Clin Infect Dis.* 2010;50:291-322.
5. Kidd S, Torrone E, Su J, et al. Reported primary and secondary syphilis cases in the United States: implications for HIV infection. *Sex Transm Dis.* 2018;45(9):S42-S47.
6. Merins V and Hahn K. Syphilis and neurosyphilis: HIV-coinfection and value of diagnostic parameters in cerebrospinal fluid. *Eur J Med Res.* 2015;20:81-8.
7. Joo T, Lee Y, Kim T. Herpes zoster involving the abducens and vagus nerves without typical skin rash: a case report and literature review. *Medicine.* 2019; 98(19):e15619-e15622.
8. Lundin M, Sandel S, Suci C, Spicehandler D. Lyme disease with erythema migrans presenting concurrently with optic nerve perineuritis and abducens nerve palsy. *BMJ Case Rep.* 2020;13:e231889-e231891.
9. Jordan K, Marino J, Damast M. Bilateral oculomotor paralysis due to neurosyphilis. *Ann Neurol.* 1978;3(1):90-3.



Journal of Education & Teaching *in* Emergency Medicine

*A publication of* **CORD**

*Education*

We believe that all learners should benefit from active learning.

We are an online, open access, peer-reviewed journal-repository for EM educators in all major topic areas.

*Scholarship*

We believe educators should advance through the scholarship of their educational work. JETem gives you the opportunity to publish & distribute your outstanding, scholarly academic work.

**Submit your content or contact us to become a reviewer!**



*visualem*



*small groups*



*tbl*



*simulation*



*lecture*



*oral boards*



*podcasts*



*curriculum*



*innovations*

[www.jetem.org](http://www.jetem.org)



*published by*

**eScholarship University of California**



**JOIN  
CAL/AAEM!**



**CALAAEM**

CALIFORNIA CHAPTER DIVISION OF THE  
AMERICAN ACADEMY OF EMERGENCY MEDICINE

*Championing  
individual physician rights  
and workplace fairness*

## **BENEFITS**

- *Western Journal of Emergency Medicine* Subscription
- CAL/AAEM News Service email updates
- Discounted AAEM pre-conference fees
- And more!

## **CAL/AAEM NEWS SERVICE**

- Healthcare industry news
- Public policy
- Government issues
- Legal cases and court decisions

In collaboration with our official journal

**WestJEM** Integrating Emergency Care  
with Population Health



FACEBOOK.COM/CALAAEM



FOLLOW US @CALAAEM

[HTTP://WWW.CALAAEM.ORG](http://www.calaaem.org)



**CALIFORNIA ACEP**

**50**

**ANNIVERSARY**