

UC Irvine

Clinical Practice and Cases in Emergency Medicine

Title

CPC-EM Full Text Issue

Permalink

<https://escholarship.org/uc/item/15w5d3b9>

Journal

Clinical Practice and Cases in Emergency Medicine, 6(2)

Authors

Rafi, Rubina
Nguyen, Trina

Publication Date

2022

DOI

11/cpcem.2022.5.57469

Copyright Information

Copyright 2022 by the author(s). This work is made available under the terms of a Creative Commons Attribution License, available at <https://creativecommons.org/licenses/by/4.0/>

Peer reviewed

CPC Emergency Medicine

Volume 6, Number 2, May 2022

Open Access at www.cpcem.org

ISSN: 2474-252X

Clinical Practice and Cases in Emergency Medicine

In Collaboration with the *Western Journal of Emergency Medicine*

Clinicopathological Cases from the University of Maryland

- 112 **58-year-old Male with a Headache, Hand Numbness, and Phantasmia**
Felipe N, Alblahied L, Dezman ZD, Bontempo LJ

Case Reports

- 117 **Testicular Torsion Appearance and Diagnosis on Computed Tomography of the Abdomen and Pelvis: Case Report**
Stephenson G, Patel MM, Thom C, Moak J
- 121 **A Rare Cause of Chest Pain Identified on Point-of-care Echocardiography: A Case Report**
Chin BW, King KA, George NK, Neeki MM, Mistry JT
- 125 **Valsalva Retinopathy Masking as a Retinal Detachment on Point-of-care Ocular Ultrasound: A Case Report**
Johnson S, Ryan T, Omari A, Schnieder S, Bahl A
- 129 **Ultrasound in the Emergency Department Identifies Ectopic Pregnancy Post Hysterectomy: A Case Report**
Cohen A, Shi D, Keraney E, Stankard B, Nelson M
- 133 **Uterine Sacculation on Point-of-care Ultrasound in a Pregnant Female Patient: A Case Report**
Puri A, Kaur H, Roit Z, Nelson M
- 137 **Acquired Methemoglobinemia in a Ketamine Ulcerative Cystitis Patient: A Case Report**
Kozik S, Kirkham C, Sudario G
- 141 **Postpartum Ovarian Vein Thrombosis: Case Report**
Ferguson SM, Arbona D, Furiato A
- 146 **Delayed Blunt Traumatic Carotid Artery Dissection After a Scooter Accident: A Case Report**
Rigby R, Agrawal S

Contents continued on page iii



UC Irvine Health



A Peer-Reviewed, International Professional Journal



**ACOEP stands with all emergency
physicians and providers on the
front line. We thank you for your
tireless work and effort.**



www.acoep.org

Clinical Practice and Cases in Emergency Medicine

Indexed in PubMed and full text in PubMed Central

Rick A. McPheeters, DO, Editor-in-Chief
Kern Medical/UCLA- Bakersfield, California

Gentry Wilkerson, MD, Deputy Editor
University of Maryland School of Medicine

Mark I. Langdorf, MD, MHPE, Senior Associate Editor
University of California, Irvine School of Medicine- Irvine, California

Shahram Lotfipour, MD, MPH, Senior Associate Editor
University of California, Irvine School of Medicine- Irvine, California

Shadi Lahham, MD, MS, Associate Editor
Kaiser Permanente- Orange County, California

Manish Amin, DO, Associate Editor
Kern Medical/UCLA- Bakersfield, California

John Ashurst, DO, Decision Editor/ ACOEP Guest Editor
Kingman Regional Health Network, Arizona

Anna McFarlin, MD, Decision Editor
Louisiana State University Health Science Center- New Orleans, Louisiana

Christopher Sampson, MD, Decision Editor
University of Missouri- Columbia, Missouri

Joel Moll, MD, Decision Editor
Virginia Commonwealth University School of Medicine- Richmond, Virginia

Steven Walsh, MD, Decision Editor
Einstein Medical Center Philadelphia-Philadelphia, Pennsylvania

Melanie Heniff, MD, JD, Decision Editor
University of Indiana School of Medicine- Indianapolis, Indiana

Austin Smith, MD, Decision Editor
Vanderbilt University Medical Center-Nashville, Tennessee

Rachel A. Lindor, MD, JD, Decision Editor
Mayo Clinic College of Medicine and Science

Jacqueline K. Le, MD, Decision Editor
Desert Regional Medical Center

Christopher San Miguel, MD, Decision Editor
Ohio State University Wexner Medical Center

Editorial Board

Amin A. Kazzi, MD, MAAEM
The American University of Beirut, Beirut,
Lebanon

Anwar Al-Awadhi, MD
Mubarak Al-Kabeer Hospital, Jabriya,
Kuwait

Arif A. Cevik, MD
United Arab Emirates University
College of Medicine and Health Sciences, Al
Ain, United Arab Emirates

Abhinandan A. Desai, MD
University of Bombay Grant Medical
College, Bombay, India

Bandr Mzahir, MD
King Fahad Medical City, Riyadh, Saudi
Arabia

Barry E. Brenner, MD, MPH
Case Western Reserve University

Brent King, MD, MMM
University of Texas, Houston

Daniel J. Dire, MD
University of Texas Health Sciences Center
San Antonio

David F.M. Brown, MD
Massachusetts General Hospital/Harvard
Medical School

Edward Michelson, MD
Texas Tech University

Edward Panacek, MD, MPH
University of South Alabama

Erik D. Barton, MD, MBA
Icahn School of Medicine, Mount Sinai,
New York

Francesco Dellacorte, MD
Azienda Ospedaliera Universitaria "Maggiore
della Carità," Novara, Italy

Francis Counselman, MD
Eastern Virginia Medical School

Gayle Galleta, MD
Sørlandet Sykehus HF, Akershus
Universitetssykehus, Lorenskog, Norway

Hjalte Björnsson, MD
Icelandic Society of Emergency Medicine

Jacob (Kobi) Peleg, PhD, MPH
Tel-Aviv University, Tel-Aviv, Israel

Jonathan Olshaker, MD
Boston University

Katsuhiko Kanemaru, MD
University of Miyazaki Hospital, Miyazaki, Japan

Khrongwong Musikatavorn, MD
King Chulalongkorn Memorial Hospital,
Chulalongkorn University, Bangkok,
Thailand

Leslie Zun, MD, MBA
Chicago Medical School

Linda S. Murphy, MLIS
University of California, Irvine School of
Medicine Librarian

Nadeem Qureshi, MD
St. Louis University, USA
Emirates Society of Emergency Medicine,
United Arab Emirates

Niels K. Rathlev, MD
Tufts University School of Medicine

Pablo Aguilera Fuenzalida, MD
Pontificia Universidad Católica de Chile,
Región Metropolitana, Chile

Peter A. Bell, DO, MBA
Baptist Health Science University

Peter Sokolove, MD
University of California, San Francisco

Robert M. Rodriguez, MD
University of California, San Francisco

Robert Suter, DO, MHA
UT Southwestern Medical Center

Robert W. Derlet, MD
University of California, Davis

Rosidah Ibrahim, MD
Hospital Serdang, Selangor, Malaysia

Samuel J. Stratton, MD, MPH
Orange County, CA, EMS Agency

Scott Rudkin, MD, MBA
University of California, Irvine

Scott Zeller, MD
University of California, Riverside

Steven Gabaeff, MD
Clinical Forensic Medicine

Steven H. Lim, MD
Changi General Hospital, Simei, Singapore

Terry Mulligan, DO, MPH, FIFEM
ACEP Ambassador to the Netherlands Society of
Emergency Physicians

Vijay Gautam, MBBS
University of London, London, England

Wirachin Hoonpongmanont, MD, MSBATS
Siriraj Hospital, Mahidol University, Bangkok,
Thailand

Advisory Board

Amal Khalil, MBA
UC Irvine Health School of Medicine

Elena Lopez-Gusman, JD
California ACEP
American College of Emergency Physicians

Adam Levy, BS
American College of Osteopathic Emergency
Physicians

John B. Christensen, MD
California Chapter Division of AAEM

Randy Young, MD
California ACEP
American College of Emergency
Physicians

Mark I. Langdorf, MD, MHPE
UC Irvine Health School of Medicine

Jorge Fernandez, MD
California ACEP
American College of Emergency Physicians
University of California, San Diego

Peter A. Bell, DO, MBA
American College of Osteopathic Emergency
Physicians
Baptist Health Science University

Robert Suter, DO, MHA
American College of Osteopathic Emergency
Physicians
UT Southwestern Medical Center

Shahram Lotfipour, MD, MPH
UC Irvine Health School of Medicine

Brian Potts, MD, MBA
California Chapter Division of AAEM
Alta Bates Summit-Berkeley Campus

Editorial Staff

Isabelle Nepomuceno, BS
Executive Editorial Director

Shreya Gupta, BS
WestJEM Editorial Director
Associate Marketing Director

Sohrab Kharabaf, BS
CPC-EM Editorial Director
Associate Marketing Director

Stephanie Burmeister, MLIS
WestJEM Staff Liaison

June Casey, BA
Copy Editor

Cassandra Saucedo, BS
Executive Publishing Director

Nathan Do, BS
WestJEM Publishing Director

Trina Nguyen, BS and Rubina Rafi, BS
CPC-EM Publishing Director

Paul Abdo, BS
WestJEM Associate Publishing Director
Associate Marketing Director

Official Journal of the California Chapter of the American College of Emergency Physicians, the American College of Osteopathic Emergency Physicians, and the California Chapter of the American Academy of Emergency Medicine



Available in MEDLINE, PubMed, PubMed Central, Google Scholar, eScholarship, DOAJ, and OASPA.

Editorial and Publishing Office: WestJEM/Department of Emergency Medicine, UC Irvine Health, 333 City Blvd, West, Rt 128-01, Orange, CA 92866, USA

Office: 1-714-456-6389; Email: Editor@westjem.org

Clinical Practice and Cases in Emergency Medicine

Indexed in PubMed and full text in PubMed Central

This open access publication would not be possible without the generous and continual financial support of our society sponsors, department and chapter subscribers.

Professional Society Sponsors

AMERICAN COLLEGE OF OSTEOPATHIC EMERGENCY PHYSICIANS
CALIFORNIA ACEP

CALIFORNIA CHAPTER DIVISION OF
AMERICAN ACADEMY OF EMERGENCY MEDICINE

Academic Department of Emergency Medicine Subscribers

Albany Medical College Albany, NY	INTEGRIS Health Oklahoma City, OK	Robert Wood Johnson University Hospital New Brunswick, NJ	University of Florida, Jacksonville Jacksonville, FL
American University of Beirut Beirut, Lebanon	Kaweah Delta Health Care District Visalia, CA	Rush University Medical Center Chicago, IL	University of Illinois at Chicago Chicago, IL
Arrowhead Regional Medical Center Colton, CA	Kennedy University Hospitals Turnersville, NJ	Southern Illinois University Carbondale, IL	University of Illinois College of Medicine Peoria, IL
Augusta University Augusta GA	Kern Medical Bakersfield, CA	St. Luke's University Health Network Bethlehem, PA	University of Iowa Iowa City, IA
Baystate Medical Center Springfield, MA	Lakeland HealthCare St. Joseph, MI	Stanford/Kaiser Emergency Medicine Residency Program Stanford, CA	University of Louisville Louisville, KY
Beaumont Hospital Royal Oak, MI	Lehigh Valley Hospital and Health Network Allentown, PA	Staten Island University Hospital Staten Island, NY	University of Maryland Baltimore, MD
Beth Israel Deaconess Medical Center Boston, MA	Loma Linda University Medical Center Loma Linda, CA	SUNY Upstate Medical University Syracuse, NY	University of Michigan Ann Arbor, MI
Boston Medical Center Boston, MA	Louisiana State University Health Sciences Center New Orleans, LA	Temple University Philadelphia, PA	University of Missouri, Columbia Columbia, MO
Brigham and Women's Hospital Boston, MA	Madigan Army Medical Center Tacoma, WA	Texas Tech University Health Sciences Center El Paso, TX	University of Nebraska Medical Center Omaha, NE
Brown University Providence, RI	Maimonides Medical Center Brooklyn, NY	University of Alabama, Birmingham Birmingham, AL	University of South Alabama Mobile, AL
Carl R. Damall Army Medical Center Fort Hood, TX	Maricopa Medical Center Phoenix, AZ	University of Arkansas for Medical Sciences Little Rock, AR	University of Southern California/Keck School of Medicine Los Angeles, CA
Conemaugh Memorial Medical Center Johnstown, PA	Massachusetts General Hospital Boston, MA	University of California, Davis Medical Center Sacramento, CA	University of Tennessee, Memphis Memphis, TN
Desert Regional Medical Center Palm Springs, CA	Mayo Clinic College of Medicine Rochester, MN	University of California Irvine Orange, CA	University of Texas, Houston Houston, TX
Doctors Hospital/Ohio Health Columbus, OH	Mt. Sinai Medical Center Miami Beach, FL	University of California, Los Angeles Los Angeles, CA	University of Texas Health San Antonio, TX
Eastern Virginia Medical School Norfolk, VA	North Shore University Hospital Manhasset, NY	University of California, San Diego La Jolla, CA	University of Warwick Library Coventry, United Kingdom
Einstein Healthcare Network Philadelphia, PA	Northwestern Medical Group Chicago, IL	University of California, San Francisco San Francisco, CA	University of Washington Seattle, WA
Emory University Atlanta, GA	Ohio State University Medical Center Columbus, OH	UCSF Fresno Center Fresno, CA	University of Wisconsin Hospitals and Clinics Madison, WI
Genesys Regional Medical Center Grand Blanc, Michigan	Ohio Valley Medical Center Wheeling, WV	University of Chicago, Chicago, IL	Wake Forest University Winston-Salem, NC
Hartford Hospital Hartford, CT	Oregon Health and Science University Portland, OR	University of Colorado, Denver Denver, CO	Wright State University Dayton, OH
Hennepin County Medical Center Minneapolis, MN	Penn State Milton S. Hershey Medical Center Hershey, PA	University of Florida Gainesville, FL	
Henry Ford Hospital Detroit, MI	Presence Resurrection Medical Center Chicago, IL		

State Chapter Subscribers

ARIZONA CHAPTER DIVISION OF THE
AMERICAN ACADEMY OF EMERGENCY MEDICINE
CALIFORNIA CHAPTER DIVISION OF THE
AMERICAN ACADEMY OF EMERGENCY MEDICINE
FLORIDA CHAPTER DIVISION OF THE
AMERICAN ACADEMY OF EMERGENCY MEDICINE

GREAT LAKES CHAPTER DIVISION OF THE
AMERICAN ACADEMY OF EMERGENCY MEDICINE
TENNESSEE CHAPTER DIVISION OF THE
AMERICAN ACADEMY OF EMERGENCY MEDICINE

UNIFORMED SERVICES CHAPTER DIVISION OF THE
AMERICAN ACADEMY OF EMERGENCY MEDICINE
VIRGINIA CHAPTER DIVISION OF THE
AMERICAN ACADEMY OF EMERGENCY MEDICINE

International Society Partners

EMERGENCY MEDICINE ASSOCIATION OF TURKEY
LEBANESE ACADEMY OF EMERGENCY MEDICINE
MEDITERRANEAN ACADEMY OF EMERGENCY MEDICINE

NORWEGIAN SOCIETY FOR EMERGENCY MEDICINE
SOCIEDAD ARGENTINA DE EMERGENCIAS

SOCIEDAD CHILENO MEDICINA URGENCIA
THAI ASSOCIATION FOR EMERGENCY MEDICINE

To become a *WestJEM* departmental sponsor, waive article processing fee, receive print and copies for all faculty and electronic for faculty/residents, and free CME and faculty/fellow position advertisement space, please go to <http://westjem.com/subscribe> or contact:

Alissa Fiorentino
WestJEM Staff Liaison
Phone: 1-800-884-2236
Email: sales@westjem.org

JOURNAL FOCUS

Clinical Practice and Cases in Emergency Medicine (CPC-EM) is a MEDLINE-indexed internationally recognized journal affiliated with the *Western Journal of Emergency Medicine* (WestJEM). It offers the latest in patient care case reports, images in the field of emergency medicine and state of the art clinicopathological and medicolegal cases. CPC-EM is fully open-access, peer reviewed, well indexed and available anywhere with an internet connection. CPC-EM encourages submissions from junior authors, established faculty, and residents of established and developing emergency medicine programs throughout the world.

Table of Contents *continued*

- 151 **A Pop from a Shock: A Case Report of an Unusual Cause of Achilles Tendon Rupture**
CY Lee, M Newberry
- 155 **To Drain or not to Drain? Point-of-care Ultrasound to Investigate an Axillary Mass: Case Report**
K Patel, Z Khan, J Costumbrado
- 159 **Case Report: Vertebral Artery Dissection After Use of Handheld Massage Gun**
K Sulkowski, G Grant, T Brodie
- 162 **Newly Diagnosed Multiple Sclerosis Presenting as Brown-Séquard Syndrome: A Case Report**
S Hoebee, L Howard, J Komara, M McElhinny
- 166 **Weakness After an Intra-articular Steroid Injection: A Case Report of Acute Steroid-induced Myopathy**
MR Jordan, LA Hensley, ML Jackson
- 169 **Vaginal Swelling After Intercourse: A Case Report**
MJ Bono, DM Woolum, AS Jones, FL Counselman
- 173 **Submucosal Duodenal Artery Pseudoaneurysm Causing Massive Gastrointestinal Hemorrhage: A Case Report**
S Elliott, A Trtchounian, B Danesh, W Bober, D Levy

Images in Emergency Medicine

- 177 **Identification of Spontaneous Shoulder Hemarthrosis with Point-of-Care Ultrasound in the Emergency Department**
KA Padrez, W Shyy, K Gandhi, N Anaya, RS Knight
- 180 **Post-intravitreal Injection Endophthalmitis Identified with Point-of-care Ultrasound**
V Zograbyan, M Barden, A Kurzweil
- 183 **A Case of a Carotid Cavernous Fistula**
RH Mahmoud, BA Hensley
- 186 **Infected Urachal Cyst Masquerading as Acute Appendicitis on Point-of-care Ultrasound**
V Quinn, F Luks, E Constantine

Policies for peer review, author instructions, conflicts of interest and human and animal subjects protections can be found online at www.cpcem.org.

Table of Contents *continued*

- 189 **Adult Presentation of Anomalous Pulmonary Artery from the Descending Aorta: A Rare Cause of Exertional Chest Pain**
R Offman, V Wilson, N Adams
- 192 **Simultaneous Bilateral Quadriceps Tendon Rupture in an Adult Man**
MC Doehring, SL Propst
- 194 **Brugada-like ECG Changes After Conducted Electrical Weapon Exposure: A Case Report**
C Trumbetta, M Galuska

Clinical Practice and Cases in Emergency Medicine (CPC-EM) is a open-access Medline-indexed internationally recognized journal affiliated with the *Western Journal of Emergency Medicine* (WestJEM). CPC-EM is distributed electronically to 19,000 emergency medicine scholars. This includes our sponsors California ACEP, the American College of Osteopathic Emergency Physicians, California Chapter of AAEM, and over 83 academic department of emergency medicine subscribers and 8 AAEM State Chapters.

CPC**EM** Clinical Practice & Cases

CALL FOR SUBMISSIONS

- Patient Care Case Reports
- Images in Emergency Medicine

Fully open-access, peer reviewed, well indexed: CPC-EM is available anywhere with an internet connection at **CPCEM.org**

Clinical Practice and Cases in Emergency Medicine is an internationally recognized journal affiliated with the MEDLINE-indexed ***Western Journal of Emergency Medicine***

CPC-EM encourages submissions from junior authors and countries with developing emergency medicine programs

CPC**EM** Clinical Practice & Cases

CALL FOR CPC-EM SECTION EDITORS!

- Medical-Legal Case Reports
- Case Reports/Images in Emergency Medicine

Send your CV and letter of interest to editor@westjem.org



Journal of Education & Teaching *in* Emergency Medicine

A publication of **CORD**

Education

We believe that all learners should benefit from active learning.

We are an online, open access, peer-reviewed journal-repository for EM educators in all major topic areas.

Scholarship

We believe educators should advance through the scholarship of their educational work. JETem gives you the opportunity to publish & distribute your outstanding, scholarly academic work.

Submit your content or contact us to become a reviewer!



visualem



small groups



tbl



simulation



lecture



oral boards



podcasts



curriculum



innovations

www.jetem.org



published by

eScholarship University of California



Revenue Cycle & Practice Management Solutions.

Brault offers scalable services to support your emergency medicine practice.

Whether you're looking for a full-service RCM partner, a support team to manage your business functions, or a group of experts to advise and help grow your practice—**Brault** has everything you need under one umbrella.



Schedule a Free Review today at www.Brault.us

58-year-old Male with a Headache, Hand Numbness, and Phantasmia

Naillid Felipe, MD, MPH*

Leen Alblaihed, MBBS, MHA[†]

Zachary D.W. Dezman, MD, MS, MS^{†,‡}

Laura J. Bontempo, MD, MEd[†]

*University of Maryland Medical Center, Department of Emergency Medicine, Baltimore, Maryland

[†]University of Maryland School of Medicine, Department of Emergency Medicine, Baltimore, Maryland

[‡]University of Maryland, Department of Epidemiology and Public Health, Baltimore, Maryland

Section Editor: Joel Moll, MD

Submission history: Submitted February 21, 2022; Revision received April 29, 2022; Accepted April 29, 2022

Electronically published May 15, 2022

Full text available through open access at http://escholarship.org/uc/uciem_cpccem

DOI: 10.5811/cpcem.2022.4.56508

Introduction: A 58-year-old male presents to the emergency department with headache, hand numbness, and phantasmia.

Case Presentation: Magnetic resonance imaging showed multiple acute and early subacute lesions involving the cortex and subcortical white matter of the left frontal lobe, left parietal lobe, left temporal lobe, left caudate, and left putamen.

Discussion: This case takes the reader through the subtle findings that led to the diagnosis and ultimately to treatment. [Clin Pract Cases Emerg Med. XXXX;X(X):X–X.]

Keywords: *status epilepticus; temporal lobe seizure; phantasmia; CPC.*

CASE PRESENTATION (DR. FELIPE)

A 58-year-old Korean male was brought to the emergency department (ED) for evaluation with a chief complaint of two days of acting differently. The patient had no complaints and stated he was unsure why he was in the ED. According to his son, the patient had complained of headaches, bilateral hand numbness, and strange smells for the prior three days. The family noticed the patient was speaking more slowly than usual and replying with one-word answers. The patient had no known past medical or surgical history. He drank four shots of liquor a day and had a 20 pack-year smoking history. He had no recent travel history. A full review of systems was unremarkable.

The patient was alert and oriented to self and date of birth but not to time or place. His temperature was 36.3° Celsius, with a heart rate of 81 beats per minute, respiratory rate of 16 breaths per minute, blood pressure of 142/83 millimeters of mercury, and an oxygen saturation of 96% on room air. He had a body mass index of 28 kilogram per square meter. He appeared well developed and well

nourished. His head was normocephalic and atraumatic. He had moist mucous membranes, without oral lesions, and with a normal oropharynx. Pupils were 3 millimeters, equal and reactive to light. The neck was supple and without significant lymphadenopathy, meningismus, or cervical spine tenderness. The patient's heart beats were regular without murmurs. Breath sounds were clear bilaterally, the abdomen was soft and nontender, and the extremities were warm and well perfused.

Neurologic exam was limited due to the patient's inability to follow simple commands, but he had grossly intact extraocular movements, symmetric facial movements, grossly intact hearing, and non-slurred speech. His gait was stable, and he ambulated without any assistance. There was grossly 5/5 strength throughout the bilateral upper and lower extremities with normal tone and normal sensation. Speech, given that he was Korean speaking, was difficult to assess, but according to a medical interpreter he was speaking slowly and using neologisms. The skin was warm, dry, and without any rash. The patient was calm, minimally

interactive, and staring at the wall. He did not appear to be responding to internal stimuli or hallucinations.

The patient's initial laboratory test results are listed in Table 1. His electrocardiogram showed normal sinus rhythm, with normal axis, normal intervals and no ST-segment elevation or depression. Due to a concern for possible intracranial bleeding, the patient had a computed tomography (CT) of the head. Representative axial and coronal images are shown in Image 1. Throughout his stay in the ED, the patient remained hemodynamically stable and was able to eat a complete meal. He was noted to be intermittently staring out at the wall and was minimally interactive with staff or his environment. Given his ongoing altered mental status, a lumbar puncture was performed and cerebrospinal fluid (CSF) was obtained. The CSF results are shown in Table 2. A diagnostic test was then done, which confirmed the diagnosis.

CASE DISCUSSION (DR. ALBLAIHED)

As I was reviewing this case initially, what stood out to me was that this was a clinicopathologic case presentation and, therefore, there had to be an interesting diagnosis behind these vague, subjective symptoms. In the ED, patients who present similarly may be considered for discharge with instructions to follow up with their primary care physician and possibly a psychiatrist if the workup does not reveal a dangerous or treatable cause for the presentation. This patient is a great reminder that new symptoms, as vague and nonspecific they may be, warrant a medical workup before diagnosing, perhaps falsely, a psychiatric etiology, especially when there is no prior history of mental illness. The emergency physician is uniquely situated to catch those patients early, prevent deterioration or death, and improve the quality of their lives.

To recap, the patient's symptoms include headache, slow speech, olfactory hallucinations, hand numbness, and confusion for three days. This makes the brain the organ that is most likely affected.

On physical examination the patient had normal gait and cranial nerve testing. The most remarkable findings on exam

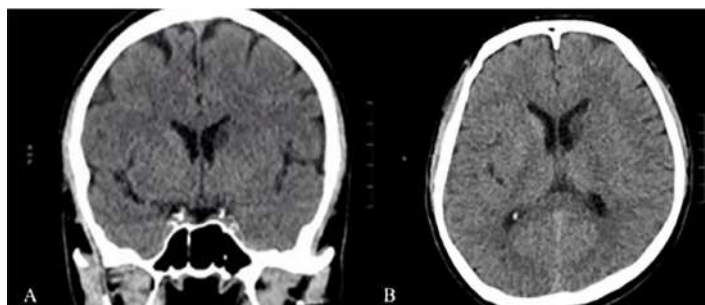


Image 1. Coronal (A) and axial (B) brain computed tomography representative images of a 58-year-old male presenting with a headache, hand numbness, and phantosmia.

Table 1. Blood laboratory results of a 58-year-old male presenting with a headache, hand numbness, and phantosmia.

Test Name	Patient Value	Reference Range
Complete Blood Count		
White Blood Cell	6.6 K/mcL	4.5 - 11 K/mcL
Hemoglobin	13.2 g/dL	11.9 - 15.7 g/dL
Hematocrit	39.8%	35.0 - 45.0%
Platelets	240 K/mcL	153 - 367 K/mcL
Complete Metabolic Panel		
Sodium	135 mmol/L	136 - 145 mmol/L
Potassium	4.2 mmol/L	3.5 - 5.1 mmol/L
Chloride	104 mmol/L	98 - 107 mmol/L
Bicarbonate	23 mmol/L	21 - 30 mmol/L
Blood urea nitrogen	18 mg/dL	7 - 17 mg/dL
Creatinine	0.77 mg/dL	0.52 - 1.04 mg/dL
Glucose	107mg/dL	70-100 mg/dL
Albumin	4.1 g/dL	3.2 - 4.6 g/dL
Total bilirubin	0.8 mg/dL	0.3 - 1.2 mg/dL
Aspartate aminotranferase	23 units/L	14 - 36 units/L
Alanine aminotransferase	10 units/L	0 - 34 units/L
Alkaline phosphatase	67 units/L	38 - 126 units/L
Additional Labs		
Acetaminophen	<10.0 mcg/mL	<10.0 mcg/mL
Salicylate Level	<1.0 mg/dL	<1.0 mg/dL
Ethanol Level	<10.0 mg/dL	<10.0 mg/dL

K, thousands; *mcL*, microliter; *g*, grams; *dL*, deciliter; *mmol*, millimole; *L*, liter; *mg*, milligram; *mcg*, microgram; *mL*, milliliter.

were the noted confusion and difficulty with speech. The blood laboratory tests were non-diagnostic and did not provide an explanation of the patient's presenting symptoms.

The CSF analysis, however, was abnormal with the presence of marked red blood cells (RBC) and white blood cells (WBC). There was no information about the CSF opening pressure; so it is unknown whether it was normal or elevated. The number of RBCs in the fourth tube is much less (56% less) than that in the first tube. This diminishing, or clearing, of the RBCs is most likely from a traumatic lumbar puncture. In the event of a subarachnoid hemorrhage, I would expect a uniform amount of RBC to be present in all tubes with no clearing.

There was also evidence of xanthochromia on the CSF analysis. Xanthochromia (or yellow pigmentation) is caused by breakdown of RBCs to oxyhemoglobin and then bilirubin. Xanthochromia is determined by two methods: using spectrometry, or visual comparison to a white sheet of paper. In emergency medicine, we are trained to associate

Table 2. Cerebral spinal fluid results of a 58-year-old male presenting with a headache, hand numbness, and phantosmia. Tube 1 is the first tube obtained during lumbar puncture; Tube 4 is the last tube obtained during lumbar puncture.

Test	Tube 1	Tube 4	Reference Range
Glucose	62 mg/dL		40–85 mg/dL
Protein	608 mg/dL		15–45 mg/dL
WBC	55 cells/mm ³	22 cells/mm ³	0 to 5 cells/mm ³
Polycytes	30%	42%	0–5%
Lymphocytes	70%	50%	40–80%
Monocytes	N/A	4%	15–45%
Eosinophils	N/A	4%	0–10%
RBC	402,500 cells/mm ³	177,500 cells/mm ³	0 cells/mm ³
CSF pre-centrifuge color	Bloody	Bloody	Colorless
CSF pre-centrifuge clarity	Cloudy	Clear	Clear
CSF post-centrifuge color	Xanthochromic	Xanthochromic	Colorless

dL, deciliter; mg, milligram; mm³, cubic millimeter; WBC, white blood cells; RBC, red blood cells, CSF, cerebrospinal fluid.

the word “xanthochromia” with subarachnoid hemorrhage; however, there are several other reasons it can be present. One explanation would be a traumatic lumbar puncture especially if there were greater than 10,000 RBC present in the first collected tube, as in this case. Other causes of xanthochromia include hyperbilirubinemia and elevated proteins.

When I reviewed the patient’s head CT, I saw a hypodensity in the left caudate nucleus. This can be seen more evidently when you compare both hemispheres in both the axial and coronal views (Image 2). Since the hypodensity is seen in more than one view, it is not artifactual but a real finding. This caudate hypodensity is not as hypodense as the CSF and there is no volume loss (seen as larger ventricle on one side), which means it is not a chronic finding and is more likely acute or subacute, raising concerns for a lacunar infarct or stroke involving the left caudate nucleus.

The caudate nucleus connects the associative cortex (including frontal, parietal, and temporal lobes) with deeper anatomic structures. Symptoms of caudate stroke include the following:

- Cognitive and behavioral changes
- Abulia, which includes decreased spontaneous activity and speech, lack of initiative, indifference, psychic akinesia (affective stagnation), prolonged latency in responding to questions and other stimuli, bradykinesia, and akinetic mutism.

The possibility of a caudate stroke in this patient explains his headache, the CSF findings, the lacunar hypodensity on CT imaging, the confusion or being described as “out of it,” and the lack of speech. However, a caudate stroke does not explain two of the patient’s symptoms: 1) the bilateral hand numbness; and 2) the phantosmia (olfactory hallucinations). The causes of bilateral hand numbness are numerous and include stroke, alcohol use disorder, and paraneoplastic syndrome among others. The causes of olfactory hallucinations includes

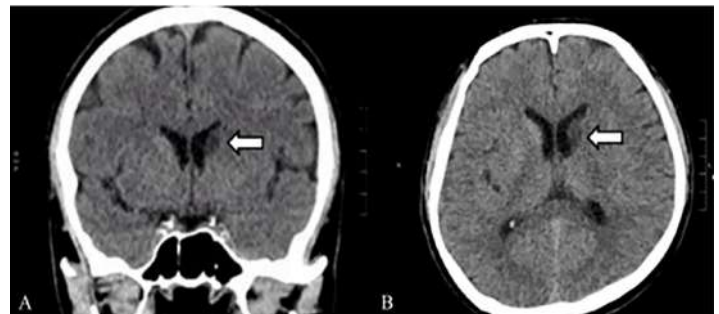


Image 2. Coronal images of a brain computed tomography without contrast of a 58-year-old male presenting with a headache, hand numbness, and phantosmia showing a hypodensity in the left caudate nucleus in the (A) coronal (arrow) and (B) axial (arrow) views.

seizures, intracranial hemorrhage, migraines, Parkinson’s disease, strokes, brain tumors, alcohol withdrawal, and herpes simplex virus (HSV) encephalitis.

The patient has multiple neurological symptoms (olfactory hallucinations, impaired speech, trouble with direction, and apathy/indifference) that point toward involvement of the temporal lobe. However, the caudate nucleus (involved in this case as evident by CT imaging) is not located in the temporal lobe.

Given that the patient is elderly and presenting with confusion, HSV encephalopathy must be on the differential diagnosis list especially in that it can explain his symptoms of olfactory hallucinations as well. The HSV causes a necrotizing infection of the mesocortex and allocortex, usually involving the bilateral temporal lobes, but can involve any part of the brain. The virus is transmitted via the olfactory nerve (causing changes in the sense of smell) or, more commonly, via the trigeminal nerve. Fever is a predominant symptom in HSV encephalitis and is the presenting symptom in 90% of

the cases along with progressively worsening mental status changes and confusion. The patient in this case did not have any progression of his confusion over the prior three days. In fact, he was sitting comfortably in the ED eating a sandwich and was afebrile. Other symptoms of HSV encephalitis include headache, psychiatric and personality changes, seizures (focal or generalized), dysphasia, and focal weakness.

If I were clinically taking care of this patient, I would empirically treat him for the possibility of HSV encephalitis pending the CSF culture and polymerase chain reaction result. Herpes simplex virus encephalitis has different presenting symptoms and should be considered in an elderly person with confusion, fever, or when RBCs are found in the CSF. I would also obtain brain and cervical spine magnetic resonance imaging (MRI) and I would place the patient on continuous electroencephalogram (EEG) monitoring to assess for subclinical seizures, focal seizures or status epilepticus. All of which could be caused by infections or cerebral ischemic changes, as evident in the patient's non-contrast CT showing the presence of caudate hypodensity, possibly indicating an infarct.

My main differential diagnoses in this case are as follows:

- HSV encephalitis:
 - This would explain his personality change, dysphasia, headache, olfactory hallucinations (either through direct invasion of olfactory nerve, or through temporal lobe damage resulting in seizures).
 - This would not explain the lack of fever and not having progressive worsening of his condition.
- Caudate stroke
 - This would explain the CT finding, the CSF finding, his behavioral and cognitive changes.
 - This would not explain the olfactory hallucinations.
- Seizures (mesotemporal)
 - This would explain his change in behavior and cognition, olfactory hallucinations, trouble following direction, and speech defect. However, seizure symptoms are usually intermittent as opposed to being continuous and unchanged for three days.
 - This would not explain the caudate hypodensity presented on the CT imaging and lack of temporal lobe involvement on the CT.

Given the patient's overall presentation and ED workup, my test of choice for this patient would be an MRI to diagnose a stroke to the caudate nucleus and temporal lobe, with possible seizures as a result. This patient will also need a continuous EEG since the possibility of ongoing seizures remains.

CASE OUTCOME (DR. FELIPE)

The diagnostic study used in this case was a continuous EEG which was initiated in the ED. The patient was admitted to the neurology service. The EEG showed multiple, prolonged, left mid-temporal electrographic seizures consistent with nonconvulsive status epilepticus (NCSE) originating in the temporal lobe. An MRI study was obtained, which showed multiple acute and early subacute lesions involving the cortex and subcortical white matter of the left frontal lobe, left parietal lobe, left temporal lobe, left caudate, and left putamen, thought to be thromboembolic in origin.

While hospitalized, the patient was started on the anti-epileptic medications fosphenytoin and levetiracetam. Given concern for the temporal lobe as the focus of seizures and hemorrhagic lumbar puncture results, the patient was started on acyclovir to empirically treat for HSV encephalitis; however, following negative viral studies, treatment was discontinued. Additionally, the patient had a bilateral carotid ultrasound, which showed significant carotid stenosis of the left common carotid artery and internal carotid artery. His mental status returned to baseline. He continued on anti-epileptic medications, was advised to cease tobacco and ethanol use, and was discharged home.

RESIDENT DISCUSSION (DR. FELIPE)

Status epilepticus arises when mechanisms for seizure termination falter, resulting in prolonged epileptiform activity with risk of long-term consequences.¹ Status epilepticus is defined as seizure activity lasting more than five minutes or recurrent seizures with no return to the patient's baseline mental status. It can be divided into convulsive and nonconvulsive types.² In NCSE, patients have absence of typical tonic-clonic motor symptoms.¹ Nonconvulsive status epilepticus is defined as a persistent change in mental status without motor symptoms but with evidence of seizure activity on EEG.² There are two subtypes of NCSE: generalized NCSE, and focal NCSE.³

The incidence of NCSE is difficult to report due to the varying definitions throughout the years and overall difficulty in diagnosing the condition. Up to 50% of all cases of status epilepticus might be NCSE.⁴ The mortality and morbidity of NCSE is predicted to be as high as 65%, although studies have shown inconsistent results.⁵

Clinicians should have a high index of suspicion for NCSE in patients with a history of a seizure disorder, recent changes in anti-epileptic medications, prolonged postictal state after a generalized tonic-clonic seizure, or unexplained altered mental status.⁴ The signs and symptoms of NCSE will vary depending on the subtype of NCSE with which the patient presents. Generalized NCSE usually presents as an absence seizure, which is characterized by perioral and eyelid myoclonus.³ Focal NCSE will differ depending on the lobe affected.³ A frontal lobe NCSE affects cognitive functions.

Temporal lobe NCSE affects autonomic functions. Parietal lobe NCSE affects somatosensory functions, and occipital lobe NCSE affects visual function.³ The symptoms could be further divided into negative and positive symptoms.⁵ Negative symptoms include anorexia, confusion, aphasia, amnesia, and/or staring.⁵ Positive symptoms include delusions, blinking, automatisms, lip smacking, facial twitching, perseveration, nausea/vomiting, laughter, and/or crying.⁵

As noted above, NCSE can present with many different signs and symptoms. The workup in the ED will be geared toward the patient's presentation and the severity of illness at the time of evaluation. The etiology of NCSE can be broad, encompassing metabolic derangements, toxicology, infections, trauma, encephalopathy, and primary neurological disease among others. Nonetheless, it is essential to keep NCSE in the differential diagnosis and to consider NCSE in patients who are postictal for an extended period.⁴ It is recommended to start with labs including a complete blood count, comprehensive metabolic panel, urine analysis, and also obtain an electrocardiogram and CT of the brain. If these are inconclusive, consider a lumbar puncture and neurology consultation for urgent EEG initiation.^{2,4} It is paramount to consider diagnoses that can mimic NCSE such as psychiatric disturbances, migraine auras, strokes, transient ischemic attacks, and transient global amnesia.⁶

In patients with suspected NCSE the first line of treatment is benzodiazepines, such as lorazepam at 0.1 milligrams per kilogram intravenously.^{4,5} Of note, a clinical improvement immediately after antiepileptic medication is given is not sufficient evidence to rule out NCSE.⁵ An EEG should be used to determine when to stop treatment of rapid-acting antiepileptic drugs.⁵

FINAL DIAGNOSIS

Left temporal lobe nonconvulsive status epilepticus secondary to ischemic stroke.

KEY TEACHING POINTS

- Consider nonconvulsive status epilepticus in patients with altered mental status and a prolonged postictal state after the visible seizure activity has stopped.

- Temporal lobe epilepsy can present with auras and automatisms.
- Nonconvulsive status epilepticus is treated initially with benzodiazepines. Continuous EEG monitoring can be used to decide when to stop treatment. Long-term treatment is with anti-epileptic medications.

The authors attest that their institution requires neither Institutional Review Board approval, nor patient consent for publication of this case report. Documentation on file.

Address for Correspondence: Laura J Bontempo, MD, MEd, University of Maryland, Department of Emergency Medicine, 110 S Paca St, 6th floor, Suite 200, Baltimore, MD 21201. Email: Lbontempo@som.umaryland.edu.

Conflicts of Interest: By the CPC-EM article submission agreement, all authors are required to disclose all affiliations, funding sources and financial or management relationships that could be perceived as potential sources of bias. The authors disclosed none.

Copyright: © 2022 Felipe. This is an open access article distributed in accordance with the terms of the Creative Commons Attribution (CC BY 4.0) License. See: <http://creativecommons.org/licenses/by/4.0/>

REFERENCES

1. Trinka E, Cock H, Hesdorffer D, et al. A definition and classification of status epilepticus--report of the ILAE Task Force on Classification of Status Epilepticus. *Epilepsia*. 2015;56(10):1515-23.
2. Brophy GM, Bell R, Claassen J, et al. Guidelines for the evaluation and management of status epilepticus. *Neurocrit Care*. 2012;17(1):3-23.
3. Kaplan PW. The clinical features, diagnosis, and prognosis of nonconvulsive status epilepticus. *Neurologist*. 2005;11(6):348-61.
4. Shah AM, Vashi A, Jagoda A. Review article: Convulsive and non-convulsive status epilepticus: an emergency medicine perspective. *Emerg Med Australas*. 2009;21(5):352-66.
5. Foreman B and Hirsch LJ. Epilepsy emergencies: diagnosis and management. *Neurol Clin*. 2012;30(1):11-2.
6. Holtkamp M and Meierkord H. Nonconvulsive status epilepticus: a diagnostic and therapeutic challenge in the intensive care setting. *Ther Adv Neurol Disord*. 2011;4(3):169-81.

Testicular Torsion Appearance and Diagnosis on Computed Tomography of the Abdomen and Pelvis: Case Report

Graham S. Stephenson, MD
Mark I. Langdorf, MD, MHPE

University of California, Irvine, Department of Emergency Medicine, Orange, California

Section Editor: Christopher San Miguel, MD

Submission History: Submitted November 6, 2021; Revision received January 23, 2022; Accepted February 4, 2022

Electronically published April 21, 2022

Full text available through open access at http://escholarship.org/uc/uciem_cpem

DOI: 10.5811/cpcem.2022.2.55315

Introduction: Testicular torsion, or the twisting of the spermatic cord compromising blood flow to the testis, is a urologic emergency with the potential to cause infertility in male patients. The diagnosis may be clinical or confirmed using imaging, with ultrasound being the modality of choice.

Case Report: We present a case of right lower quadrant pain with radiation to the groin and right scrotum in a young male. A computed tomography of the abdomen and pelvis was ordered to assess for appendicitis, which showed a “whirl” sign on the inferior periphery of the images near the scrotum. The finding was not appreciated during the emergency department visit and the patient was discharged home. He returned 48 hours later due to continued pain and was ultimately diagnosed with testicular torsion via ultrasound and surgical pathology.

Conclusion: This is the first reported case to our knowledge identifying “whirl” sign for the diagnosis of testicular torsion. This finding was not appreciated by multiple clinicians during the initial patient presentation, highlighting the uncommon nature of the finding. [Clin Pract Cases Emerg Med. 2022;6(2):117-120.]

Keywords: *testicular torsion; whirl sign; abdominal pain.*

INTRODUCTION

The internal and external spermatic arteries travel through the spermatic cord to supply blood to the testicles. Testicular torsion, or the twisting of the testes on the spermatic cord, impedes this supply and is a urologic emergency. Failure to promptly reduce torsion may result in infertility from ischemic loss of germ cells or the generation of anti-sperm antibodies.¹ Although most common in neonates and pre-pubertal males, torsion may occur at any age with nearly 40% outside typical demographics.² In the United States, testicular torsion occurs 5.9 times per 100,000 males ages 1–17 years, and 1.3 per 100,000 over the age of 18.³

A concerning physical exam is sufficient to make the diagnosis of testicular torsion. Presenting symptoms include a firm and tender testicle, abnormal testicle lie (horizontal or high riding), loss of the cremasteric reflex, nausea and vomiting, and lower abdominal pain.⁴ Symptoms often present after physical activity or minor trauma, although younger patients may be startled from sleep due to nocturnal

cremasteric contraction. Testicular torsion during adolescence will frequently occur within the tunica vaginalis, causing a “bell clapper” deformity where the affected testicle has an abnormal transverse lie in the standing patient.⁵

When clinical exam is equivocal, imaging is highly sensitive and can confirm the diagnosis. Ultrasound with color Doppler is the test of choice with sensitivity and specificity of 82% and 100%, respectively.^{6,7,8} Ultrasound findings concerning for torsion include direct visualization of twisted cord with a “whirl” sign, diminished blood flow on Doppler, abnormal echo texture of the affected side, reactive hydrocele, or scrotal wall thickening and hyperemia. Objectively, computed tomography (CT) is an inferior imaging modality for evaluation of suspected testicular torsion with data for efficacy limited to small-scale experimental perfusion studies.^{9,10}

We present a case of right-sided testicular torsion where a CT of the abdomen and pelvis was obtained for suspicion of acute appendicitis. The visible “whirl” sign at the periphery of the abdominopelvic CT, representing the twisted spermatic cord, was

not appreciated by the radiologist or the emergency physician (EP). Testicular torsion was later confirmed by ultrasound 48 hours after the initial presentation. To our knowledge, this is the first reported case of “whirl” sign representing testicular torsion seen on CT, and it highlights the importance of critical evaluation of imaging in concert with presenting symptoms.

CASE REPORT

A 21-year-old man with no previous medical history presented to the emergency department (ED) with sudden right lower quadrant (RLQ) pain for 3.5 hours. The pain was constant and radiated to his scrotum, with reported pain when the scrotum was touched. He had the urge to defecate at onset, with increased flatulence, and multiple episodes of diarrhea. He denied frequency, urgency, penile discharge, and dysuria. He was not sexually active.

The presenting vital signs were blood pressure of 128/71 millimeters of mercury, heart rate of 92 beats per minute, respiratory rate of 16 breaths per minute, temperature of 36.6° Celsius, and oxygen saturation of 100% on room air. His documented exam included mild RLQ tenderness to palpation without rebound or guarding. His physical exam was otherwise marked as normal, with no genitourinary exam documented.

The physician’s assistant ordered tests from triage, including a urinalysis, complete blood count with differential, comprehensive metabolic panel, intravenous (IV) fluids, pain control, and a CT of the abdomen and pelvis with IV contrast. The patient was given 15 milligrams (mg) of ketorolac, 4 mg of morphine sulphate, and 1 liter (L) of normal saline. Laboratory tests showed white blood cell (WBC) count of 11.6 x 10⁹ cells/L (reference range [RR] 3.8-11 x 10⁹ cells/L), normal serum electrolytes, urinalysis with 3 WBCs per high powered field (hpf) (0-5/ hpf), negative leukocyte esterase and nitrite (RR negative), and no bacteria (RR none/hpf). Urine polymerase chain reaction tests for gonorrhea and chlamydia resulted negative the following day.

A CT of the abdomen and pelvis with IV contrast was ordered to evaluate for appendicitis. The radiology report of the abdomen and pelvis (Image 1, Image 2) was as follows: “unremarkable CT of the abdomen and pelvis. The appendix is not discretely identified; however, no inflammatory changes are seen in the right lower quadrant to suggest acute appendicitis.” There was no comment on the scrotum in the report. The patient’s symptoms were documented as improved upon re-evaluation and he was discharged home.

The patient’s symptoms continued, and roughly 48 hours later he was seen in urgent care. There, he had a testicular ultrasound showing no arterial or venous flow in the right testicle. He was sent to the same ED, and re-evaluation was documented as “phallus circumcised without lesions. Right testis is high riding, exquisitely tender and mildly edematous. Left testis is normal and non-tender.” A urologist was consulted for emergent right orchiectomy and left

CPC-EM Capsule

What do we already know about this clinical entity?
Testicular torsion is a urologic emergency. Although primarily a clinical diagnosis, ultrasound is often used to confirm clinical suspicion.

What makes this presentation of disease reportable?
We present a case of abdominal pain in a young male. Computed tomography (CT) demonstrated a “whirl” sign of the spermatic cord later confirmed to be testicular torsion.

What is the major learning point?
This is the first report detailing abnormal image findings on CT that support the diagnosis of testicular torsion.

How might this improve emergency medicine practice?
“Whirl” sign on CT should greatly raise the clinician’s concern for underlying ischemia, including during evaluation of testicular pain.

orchiopexy. The operative report documented a necrotic right testis, and the surgeon noted 540 degrees (1.5 rotations) of spermatic cord torsion. Pathology report confirmed, “hemorrhagic infarct of the testicular and epididymal

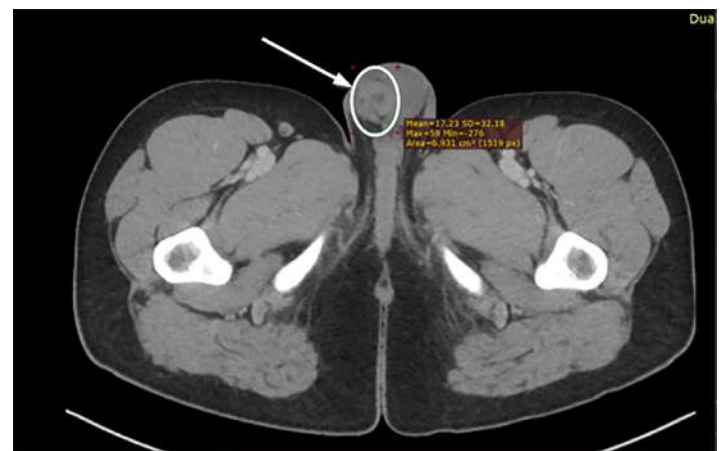

Image 1. Axial computed tomography of the abdomen and pelvis showing “whirl” sign in the right scrotum at the inferior periphery of the image suggestive of testicular torsion. The white arrow and circle highlight this finding.

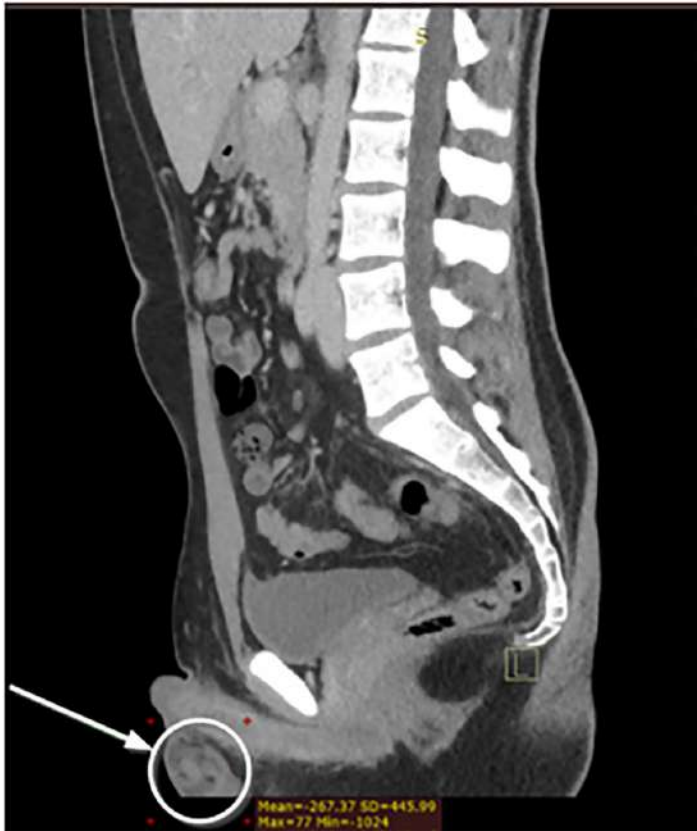

Image 2. Right parasagittal computed tomography of the abdomen and pelvis showing “whirl” sign consistent with testicular torsion in the right scrotum at the inferior periphery of the image. The white arrow and circle highlight this finding.

parenchyma consistent with torsion. Spermatic cord with vascular congestion. No evidence of malignancy.”

DISCUSSION

Testicular torsion stems from the twisting of the testes on the spermatic cord when there is inadequate fixation of the testes on the tunica vaginalis. Although gross testicle and sperm viability begins to decline at eight hours after torsion, this progresses over the next 18-24 hours, and some salvage may occur during or after this period.¹¹ Therefore, prompt diagnosis and treatment are critical to preserve fertility. When exam alone is not diagnostic, imaging should be done. In this case, the “whirl” sign was visible at the periphery of the CT.

The “whirl sign” is evident on CT in other body organs that twist, including the fallopian tube, ovary, and mesentery (cecal or sigmoid volvulus).¹² It is diagnostic on high-resolution ultrasound of the spermatic cord and fallopian tube.^{13,14} High-resolution ultrasound may detect torsion with up to 96% sensitivity and 99% specificity. The CT appearance here mimics these known examples of twisting organs. We report this case to encourage EPs and radiologists to scrutinize the periphery of the CT to potentially improve the diagnosis of testicular torsion.

CONCLUSION

As with other bodily organs that can twist, the “whirl” sign may be seen on CT in cases of testicular torsion as demonstrated in this case. Although ultrasound is the diagnostic study of choice, CT can provide evidence supporting the diagnosis of testicular torsion and should not be ignored during the evaluation of patients with genitourinary pain.

The authors attest that their institution requires neither Institutional Review Board approval nor patient consent for publication of this case report. Documentation on file.

Address for Correspondence: Graham S. Stephenson, MD, University of California, Irvine, Department of Emergency Medicine, 101 The City Drive South, Route 128-0, Orange, CA 92868. Email: gsstephe@hs.uci.edu.

Conflicts of Interest: By the CPC-EM article submission agreement, all authors are required to disclose all affiliations, funding sources and financial or management relationships that could be perceived as potential sources of bias. The authors disclosed none.

Copyright: © 2022 Stephenson. This is an open access article distributed in accordance with the terms of the Creative Commons Attribution (CC BY 4.0) License. See: <http://creativecommons.org/licenses/by/4.0/>

REFERENCES

- Jarow JP and Sanzone JJ. Risk factors for male partner antisperm antibodies. *J Urol.* 1992;148(6):1805-7.
- Cummings JM, Boullier JA, Sekhon D, et al. Adult testicular torsion. *J Urol.* 2002;167(5):2109-10.
- Greear GM, Romano MF, Katz MH, et al. Testicular torsion: epidemiological risk factors for orchiectomy in pediatric and adult patients. *Int J Impot Res.* 2021;33(2):184-90.
- Tintinalli JE, Ma O, Yealy DM, et al. eds. (2020) Male genital problems. In: *Tintinalli's Emergency Medicine: A Comprehensive Study Guide, 9e.* New York, NY: McGraw Hill Education.
- Taghavi K, Dumble C, Hutson JM, et al. The bell-clapper deformity of the testis: the definitive pathological anatomy. *J Pediatr Surg.* 2021;56(8):1405-10.
- Kapasi Z and Halliday S. Best evidence topic report. Ultrasound in the diagnosis of testicular torsion. *Emerg Med J.* 2005;22(8):559-60.
- Pepe P, Panella P, Pennisi M, et al. Does color Doppler sonography improve the clinical assessment of patients with acute scrotum? *Eur J Radiol.* 2006;60(1):120-4.
- Ovali GY, Yilmaz O, Tarhan S, et al. Perfusion CT evaluation in experimentally induced testicular torsion. *Can Urol Assoc J.* 2009;3(5):383-6.
- Naranjo ID and Alcalá-Galiano Rubio A. Inguinoscrotal pathology on computed tomography: an alternative perspective. *Can Assoc Radiol J.* 2016;67(3):225-33.
- Mellick LB, Sinex JE, Gibson RW, et al. A systematic review of testicle survival time after a torsion event. *Pediatr Emerg Care.* 2019;35(12):821-5.

11. Rha SE, Byun JY, Jung SE, et al. CT and MR imaging features of adnexal torsion. *Radiographics*. 2002;22(2):283-94.
12. Lee EJ, Kwon HC, Joo HJ, et al. Diagnosis of ovarian torsion with color Doppler sonography: depiction of twisted vascular pedicle. *J Ultrasound Med*. 1998;17(2):83-9.
13. Kalfa N, Veyrac C, Lopez M, et al. Multicenter assessment of ultrasound of the spermatic cord in children with acute scrotum. *J Urol*. 2007;177(1):297-301.

A Rare Cause of Chest Pain Identified on Point-of-care Echocardiography: A Case Report

Brian W. Chin, MD*
Kassandra A. King, DO[†]
Nicholas K. George, MD*
Michael M. Neeki, DO*
Jamshid T. Mistry, DO*,[‡]

*Arrowhead Regional Medical Center, Department of Emergency Medicine, Colton, California

[†]Arrowhead Regional Medical Center, Department of Medicine, Colton, California

[‡]Riverside Community Hospital, Department of Critical Care, Riverside, California

Section Editor: Shadi Lahham, MD

Submission History: Submitted June 7, 2021; Revision received September 9, 2021; Accepted September 19, 2021

Electronically published March 7, 2022

Full text available through open access at http://escholarship.org/uc/uciem_cpem

DOI: 10.5811/cpcem.2021.9.53553

Introduction: Cardiac masses are a rare cause of chest pain. They can often be missed on a chest radiograph performed to evaluate non-specific chest pain and are not readily evaluated with traditional laboratory testing. However, these masses can be visualized with point-of-care ultrasound.

Case Report: We present a case of a 19-year-old female presenting with intermittent chest pain, palpitations, and weakness present for two months. The patient had previously been evaluated at our emergency department one week earlier and was diagnosed with anxiety before being discharged. Besides a tachycardic and labile heart rate, physical examination and laboratory testing were unremarkable. Point-of-care cardiac echocardiography subsequently demonstrated findings concerning for a cardiac mass.

Conclusion: Cardiac masses are a rare cause of chest pain and palpitations that are easily missed. The advent of point-of-care ultrasonography has afforded us the ability to rapidly assess for structural and functional cardiac abnormalities at bedside, and incorporation of this tool into the evaluation of patients with chest pain offers the ability to detect these rare pathologies. [Clin Pract Cases Emerg Med. 2022;6(2):121–124.]

Keywords: *ultrasound; point-of-care; cardiac mass; case report; chest pain.*

INTRODUCTION

The incidence of primary cardiac tumors in the general population is unclear due to rarity of the condition, with most sources citing numbers less than 0.1%.¹ Secondary tumors from other sites are much more prevalent and outnumber primary tumors by about 20:1. Cardiac pseudotumors such as intracardiac thrombi are also significantly more common than primary cardiac tumors.² Primary cardiac tumors are mostly benign with malignant tumors making up about 10% of all primary cardiac tumors. Of these malignant tumors, sarcomas are the most common. Overall, benign primary cardiac tumors have a good prognosis with most patient responding favorably to surgery

while malignant tumors carry a significantly worse prognosis.^{3,4,5}

Symptomatic primary cardiac tumors can cause a range of symptoms including chest pain, arrhythmia, and even sudden death.^{6,7,8} Additionally, primary tumors can serve as a nidus for the formation of thrombi that can subsequently embolize.⁹ Evaluation of cardiac masses often begins with either transthoracic or transesophageal echocardiography. Cardiac computed tomography and cardiac magnetic resonance imaging can subsequently be obtained if further characterization of the mass is deemed to be necessary.^{10,11} Overall, benign primary cardiac tumors have a good prognosis with most patients responding favorably to surgery.⁵

CASE REPORT

A 19-year-old female presented to the emergency department (ED) with the chief complaint of chest pain, palpitations, and generalized weakness intermittently, which were present for two months but had become more prominent during the prior week and worsening over the immediately preceding day. She had been seen in our ED one week prior for similar symptoms and was diagnosed with anxiety before being discharged. The patient did not report any other previous medical or surgical history, denied any history of familial disease to the best of her knowledge, and reported marijuana use several days earlier.

On presentation, the patient was tachycardic with a rate of 126 beats per minute (bpm), hypertensive at 169/84 millimeters of mercury, and mildly tachypneic with a respiratory rate of 17 breaths per minute. Otherwise, she was afebrile and not hypoxic. Examination revealed a young female who appeared stated age and mildly anxious. Her cardiac exam revealed tachycardia with a regular rhythm and no appreciable murmurs. The patient's lungs were clear to auscultation bilaterally and she was in no respiratory distress. Her skin was without any notable lesions or rashes, and she had no lower extremity edema or calf tenderness to palpation. Of note, the patient exhibited pronounced heart rate lability and would often be noted to have a resting heart rate between 90-100 bpm on telemetry when alone in the room, which increased to 120-140 bpm whenever staff entered.

Point-of-care echocardiography demonstrated an approximately 3.42 x 2.80 centimeters (cm) ovular echogenic structure in the left ventricular outflow tract in the parasternal long window. The structure was also visualized in the apical four-chamber window (Image 1, video). On bedside echocardiography the patient was noted to be tachycardic without global left ventricular hypokinesis, and the right ventricle was not dilated. A chest radiograph was obtained that did not demonstrate any cardiopulmonary abnormality (Image 2), and 12-lead electrocardiogram demonstrated sinus tachycardia without ST-segment changes.

Laboratory testing demonstrated a mild microcytic anemia with a hemoglobin level of 10.6 grams per deciliter (g/dL) (reference range: 11.5-15.5 g/dL) and mean corpuscular volume of 77 femtoliters (fL) (80-100 fL). Otherwise, the patient's white blood cell counts were within reference range, but she had a mild thrombocytosis at 400 thousand cells per microliter (th/ μ L) (120-360 th/ μ L). Chemistries were primarily remarkable for a mildly low potassium level of 3.0 milliequivalents per liter (mEq/L) (3.5-5.5 mEq/L), carbon dioxide level of 19 millimoles per liter (mmol/L) (24-34 mmol/L), iron level of 22 micrograms per deciliter (mcg/dL) (40-150 mcg/dL), and ferritin of 11.6 nanograms per milliliter (ng/mL) (20-300 ng/mL). Urine toxicology returned positive for marijuana, and thyroid stimulating hormone (TSH) levels were within normal reference range. Urinalysis was unremarkable, and urine pregnancy test was negative.

CPC-EM Capsule

What do we already know about this clinical entity?

Cardiac tumors are rare and oftentimes asymptomatic. They are not easily seen on laboratory testing or radiography and are easily missed.

What makes this presentation of disease reportable?

This case highlights how point-of-care ultrasonography was able to detect a rare clinical entity that had been missed on previous visits.

What is the major learning point?

Ultrasonography should be routinely considered for evaluation of chest pain and can detect several clinical entities not readily captured by other methods.

How might this improve emergency medicine practice?

Point-of-care ultrasonography is becoming a staple of emergency medicine. Regular use can help avoid missed diagnoses and delays in treatment.

The patient received two liters of normal saline for fluid resuscitation and repeat vitals after administration of fluid demonstrated improvement in tachycardia. As seen in the lab values, the patient was mildly anemic with a microcytic anemia consistent with iron deficiency anemia. Unfortunately, date of last menstrual period was unknown; however, this finding is not unexpected secondary to menses in a reproductive-age woman. There was less suspicion for thyroid dysfunction given normal TSH levels, and the patient's symptoms were considered unlikely to be secondary to acute marijuana toxicity given the reported timeline of use. Urine fractionated metanephrines and plasma free metanephrine levels were not obtained, however, pheochromocytoma should also have been considered in this young, hypertensive patient.

The case was discussed with cardiology, and heparin infusion was initiated over concerns of adherent thrombi that could embolize. The patient was subsequently admitted to the hospital, and a computed tomography (CT) of the thorax with intravenous contrast was performed; however, the CT was not obtained using a cardiac protocol. No mass was noted on the final report. The patient underwent transesophageal echocardiography that confirmed the presence of a 3.5 x 2.25

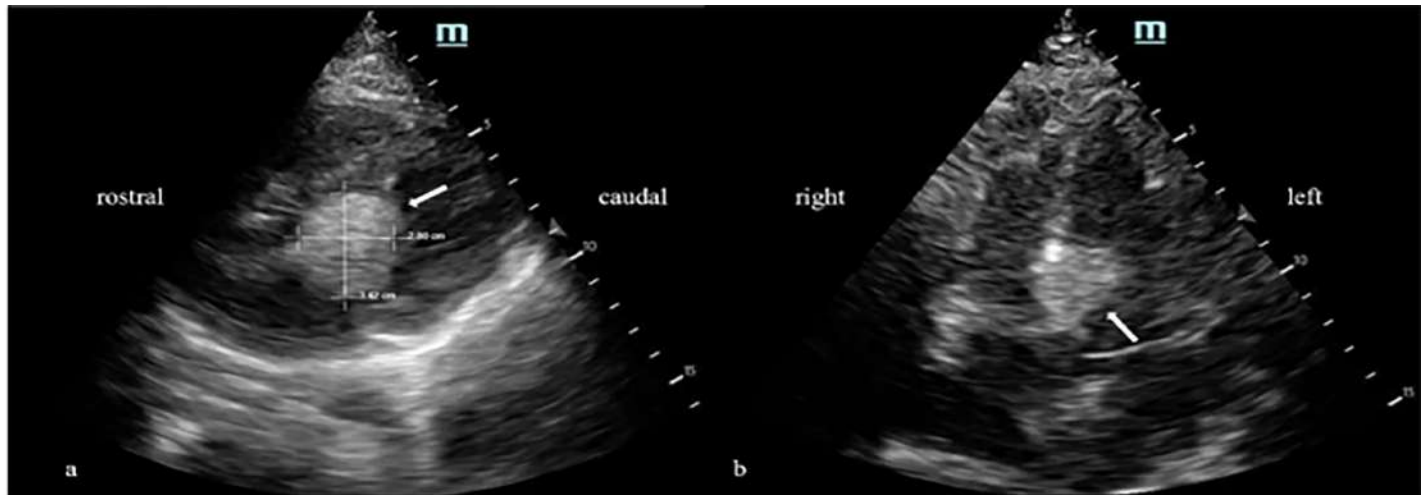


Image 1. A) Parasternal long view demonstrating hyperechoic cardiac mass measuring 3.42 x 2.80 centimeters (arrow). B) Apical four-chamber view demonstrating same hyperechoic mass on septum (arrow).

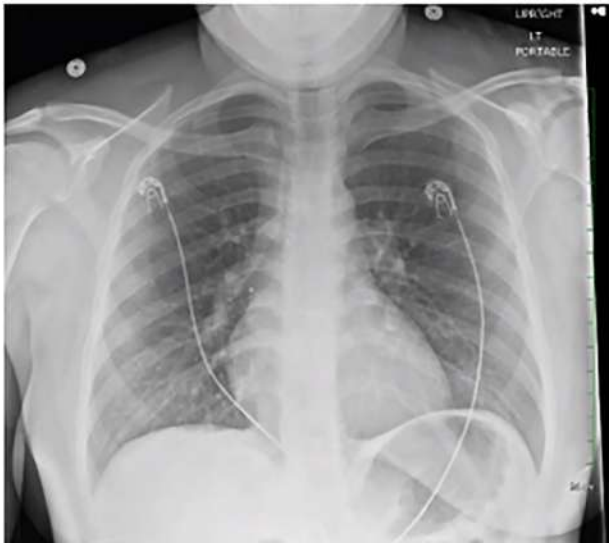

Image 2. Portable upright anterior-posterior chest radiograph not demonstrating appreciable cardiopulmonary disease.

cm interventricular septal mass just below the aortic valve. The patient was subsequently transferred to a tertiary medical center for cardiothoracic surgical evaluation.

DISCUSSION

The differential diagnosis for a young female presenting with a chief complaint of chest pain is broad, but with point-of-care ultrasonography we were able to rapidly identify a cause: cardiac mass. The mass did not seem to stem from a valve, and the lack of fever and other Duke criteria for infective endocarditis made endocarditis unlikely.¹² The patient also did not report any history of immunologic disease, thereby making non-infective vegetations unlikely. Pure thrombus was deemed unlikely

given her normal prothrombin time, partial thromboplastin time, international normalized ratio, and location of the mass. Sigmoidal hypertrophic cardiomyopathy could present similarly; however, the general appearance of the mass was more discrete than would be expected with hypertrophy.¹³ In our case, the patient was young and without previous medical history making secondary cardiac tumor, while not impossible, relatively less likely than in the general population. The cardiac mass also appeared to be left-sided in origin, which decreases the likelihood of malignancy since right-sided primary cardiac tumors are more likely to be malignant.¹⁴ Overall, the mass was most likely a rhabdomyoma, lipoma, or fibroma given ventricular location, although histologic examination would be required for the ultimate diagnosis.¹⁵

CONCLUSION

This case demonstrates the benefit of point-of-care echocardiography as an adjunct for chest pain workup. While many patients receive plain films of the chest as part of the workup, this examination notably does not have the ability to assess for structural abnormalities of the heart. As demonstrated by this case, even more advanced imaging modalities such as CT may not detect cardiac masses if a cardiac-specific protocol is not used.¹⁰ In this regard, ultrasonography can offer improved diagnostic yield when compared to other imaging modalities. Point-of-care ultrasonography holds the unique ability to evaluate for intracardiac pathology at bedside and should routinely be considered for the evaluation of chest pain.

Furthermore, ultrasonography can provide functional insight that traditional imaging often lacks, such as ejection fraction, regurgitant flow across valves, and Doppler flow gradients for obstructive physiology. Although quantification of some of these exams can be technically challenging, even

gross qualitative assessments of cardiac structure and function can assist with treatment decisions and resuscitation. In this case, the location of the cardiac mass in the left ventricular outflow tract (LVOT) raised suspicion for obstructive physiology. Additional fluid can help improve cardiac output in intravascularly depleted patients and would be especially helpful for a patient with obstruction from a LVOT mass.

Video. Parasternal long axis view visualizing left atrium (LA), left ventricle (LV), aortic root (AR), and right ventricle (RV). White arrow indicates location of mass between aortic root and left ventricle in the left ventricular outflow tract.

The Institutional Review Board approval has been documented and filed for publication of this case report.

Address for Correspondence: Brian Chin, MD, Arrowhead Regional Medical Center, Department of Emergency Medicine, 400 N. Pepper Avenue, Colton, California 92324. Email: chinbr@armc.sbcounty.gov.

Conflicts of Interest: By the CPC-EM article submission agreement, all authors are required to disclose all affiliations, funding sources and financial or management relationships that could be perceived as potential sources of bias. The authors disclosed none.

Copyright: © 2022 Chin. This is an open access article distributed in accordance with the terms of the Creative Commons Attribution (CC BY 4.0) License. See: <http://creativecommons.org/licenses/by/4.0/>

REFERENCES

1. Cresti A, Chiavarelli M, Glauber M, et al. Incidence rate of primary cardiac tumors: a 14-year population study. *J Cardiovasc Med (Hagerstown)*. 2016;17(1):37-43.
2. Dinesh Kumar US, Shetty SP, Sujay KR, et al. Left ventricular mass: a tumor or a thrombus diagnostic dilemma. *Ann Card Anaesth*. 2016;19(4):728-32.
3. He S, Cao Y, Qin W, et al. Prevalence of primary cardiac tumor malignancies in retrospective studies over six decades: a systematic review and meta-analysis. *Oncotarget*. 2017;8(26):43284-94.
4. Petris AO, Alexandrescu DM, Costache II. Cardiac tumors. *Rev Med Chir Soc Med Nat Iasi*. 2014;118(2):289-92.
5. Hoffmeier A, Sindermann JR, Scheld HH, et al. Cardiac tumors--diagnosis and surgical treatment. *Dtsch Arztebl Int*. 2014;111(12):205-11.
6. Bussani R, Castrichini M, Restivo L, et al. Cardiac tumors: diagnosis, prognosis, and treatment. *Curr Cardiol Rep*. 2020;22(12):169.
7. Jayaprakash S. Clinical presentations, diagnosis, and management of arrhythmias associated with cardiac tumors. *J Arrhythm*. 2018;34(4):384-93.
8. Shapiro LM. Cardiac tumours: diagnosis and management. *Heart*. 2001;85:218-22.
9. Dias RR, Fernandes F, Ramires FJ, et al. Mortality and embolic potential of cardiac tumors. *Arq Bras Cardiol*. 2014;103(1):13-8.
10. Kim EY, Choe YH, Sung K, et al. Multidetector CT and MR imaging of cardiac tumors. *Korean J Radiol*. 2009;10(2):164-75.
11. Motwani M, Kidambi A, Herzog BA, et al. MR imaging of cardiac tumors and masses: a review of methods and clinical applications. *Radiology*. 2013;268(1):26-43.
12. Durack DT, Lukes AS, Bright DK. New criteria for diagnosis of infective endocarditis: utilization of specific echocardiographic findings. Duke Endocarditis Service. *Am J Med*. 1994;96(3):200-9.
13. Bos JM, Towbin JA, Ackerman MJ. Diagnostic, prognostic, and therapeutic implications of genetic testing for hypertrophic cardiomyopathy. *J Am Coll Cardiol*. 2009;54(3):201-11.
14. Leja MJ, Shah DJ, Reardon MJ. Primary cardiac tumors. *Tex Heart Inst J*. 2011;38(3):261-2.
15. Burke A and Tavora F. The 2015 WHO classification of tumors of the heart and pericardium. *J Thorac Oncol*. 2016;11(4):441-52.

Valsalva Retinopathy Masking as a Retinal Detachment on Point-of-care Ocular Ultrasound: A Case Report

Steven Johnson, DO*

Thomas Ryan, MD*

Amro Omari, MD[†]

Samantha Schneider, DO[‡]

Amit Bahl MD, MPH*

*Beaumont Hospital, Department of Emergency Medicine, Royal Oak, Michigan

[†]Beaumont Hospital, Department of Ophthalmology, Royal Oak, Michigan

[‡]Ascension Eye Institute, Department of Ophthalmology, Warren, Michigan

Section Editor: Shadi Lahham, MD

Submission History: Submitted October 22, 2021; Revision received December 24, 2021; Accepted January 4, 2022

Electronically published March 7, 2022

Full text available through open access at http://escholarship.org/uc/uciem_cpccem

DOI: 10.5811/cpcem.2022.1.55173

Introduction: Approximately two million people present to the emergency department (ED) with eye-related complaints each year in the United States. Differentiating pathologies that need urgent consultation from those that do not is imperative. For some physicians, ocular ultrasound has eclipsed the dilated fundoscopic exam as the standard posterior segment evaluation in the ED.

Case report: A 60-year-old female presented with sudden onset visual disturbance in her right eye. Point-of-care ultrasound showed a hyperechoic band in the posterior segment concerning for a retinal detachment. Ophthalmology was consulted and diagnosed the patient with a condition known as Valsalva retinopathy. The patient was discharged from the ED with expectant management.

Conclusion: This case highlights an important differential diagnosis that should be considered when ocular ultrasound demonstrates a hyperechoic band in the posterior segment. While previous literature has demonstrated that emergency physicians are able to accurately identify posterior segment pathology using ultrasound, there is limited information regarding their ability to differentiate between pathologies, some of which may not require urgent consultation. We highlight the important differentials that should be considered when identifying posterior segment pathology on point-of-care ultrasound and their appropriate dispositions. [Clin Pract Cases Emerg Med. 2022;6(2):125–128.]

Keywords: *ocular ultrasound; point-of-care ultrasound; ophthalmology; case report; pre-retinal hemorrhage; valsalva retinopathy.*

INTRODUCTION

Approximately two million people present to the emergency department (ED) with eye-related complaints each year in the United States.¹ Point-of-care ultrasound (POCUS) is a safe and effective way to screen for and triage intraocular pathologies, especially those of the posterior segment such as retinal detachments (RD). Prior research has shown that emergency physicians can perform ocular POCUS with high diagnostic accuracy.² Valsalva retinopathy (VR) is an acute pathology of the posterior segment that can be identified using POCUS. However, POCUS findings and the clinical presentation of VR may be difficult to

discern from RD. Although VR can cause vision loss that may need ophthalmic intervention, unlike RD, VR does not need immediate evaluation by a vitreoretinal surgeon.³ Thus, differentiating these pathologies can make a significant impact on patient care. Here we describe a case of Valsalva retinopathy that was successfully differentiated from a RD by careful ultrasonography.

CASE REPORT

A 60-year-old female with a past medical history of hypertension and type 2 diabetes presented to the ED due to vision changes in the right eye. She noted that after a

sneezing fit, she experienced a sudden onset of floaters and a large cloud coming down into her vision. She described it as if she were looking through blood or ink spots. She did not have any eye pain and denied any trauma to the eye. She had no prior history of ophthalmic surgery or any anticoagulant use. Visual acuity was 20/30 in the left eye and 20/70 in the right eye. On exam, pupils were equal, round, and reactive, extraocular movements were intact, and the anterior segment exam was unremarkable. Confrontational visual fields were intact. The emergency physician performed an ultrasound of the right eye, and the images were obtained (Images 1 and 2, Video).

The POCUS showed a hyperechoic line raised off the posterior segment of the eye, which crossed the boundary of the optic nerve sheath. It was minimally mobile with eye movement, and scattered echoes were seen behind this stripe

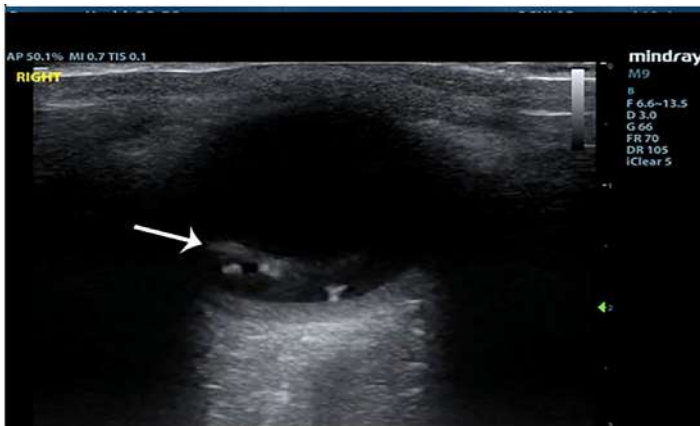


Image 1. B-mode ultrasound of the right eye showing hyperechoic band (arrow) in the posterior segment with underlying scattered echoes.

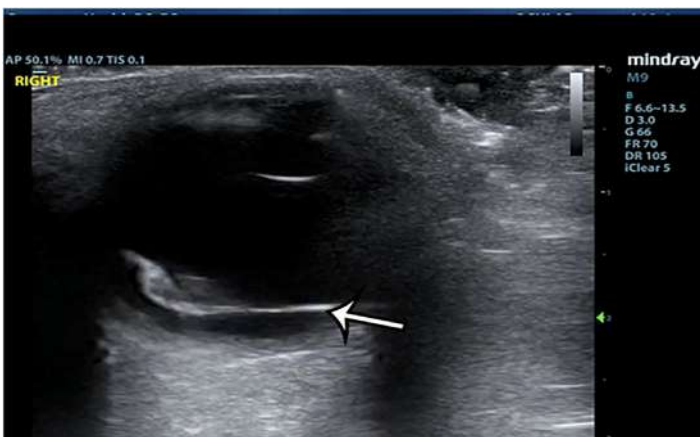

Image 2. B-mode ultrasound of the right eye showing hyperechoic band (arrow) in the posterior segment spanning the entire globe.

CPC-EM Capsule

What do we already know about this clinical entity?

Valsalva retinopathy is a common cause of pre-retinal hemorrhage and is not acutely vision threatening but may be confused with other more serious pathologies on Point-of-care ultrasound (POCUS).

What makes this presentation of disease reportable?

In our case ocular POCUS showed a hyperechoic line raised structure off the posterior segment, which crossed the boundary of the optic nerve, representing the pre-retinal membrane rather than the retina.

What is the major learning point?

Point-of-care ultrasound can differentiate pre-retinal hemorrhage from other pathologies that cause permanent vision loss by using several key features: echogenicity, mobility, and relation to the optic nerve.

How might this improve emergency medicine practice?

Since pre-retinal hemorrhage is not acutely vision threatening, accurate diagnosis by the ED physician may help alleviate the cost of unnecessary emergent consults and transfers in the future.

suggesting hemorrhage. Ophthalmology was consulted and observed extensive vitreous, intraretinal, and subhyaloid hemorrhage. The retina was not corrugated and there were no retinal breaks on their dilated eye exam, although some of the view was obscured by vitreous hemorrhage.

The patient returned to retina clinic the next morning for follow-up assessment, where repeat ultrasound was performed. This study confirmed that the retina was flat and that there were no signs of a retinal break underlying the hemorrhage. Based on the exam findings of retinal hemorrhages in multiple layers and recent sneezing history, along with an intact retina on ultrasound, the diagnosis of Valsalva retinopathy was made. No immediate intervention was required, but the patient eventually underwent a vitrectomy to remove the large amount of vitreous hemorrhage.

DISCUSSION

Point-of-care ultrasound is commonly used in the ED by both ophthalmologists and emergency physicians to aid in the diagnosis of acute posterior segment pathologies that can cause permanent visual impairment. In this patient, the predominant findings were vitreous opacities and a raised hyperechoic strip that was concerning for a RD. Emergency physicians should be aware that these findings have several additional differential diagnoses that should be considered. There are distinctive features that can be observed on POCUS to help differentiate between these entities (Table).

Retinal detachments are relatively common, occurring at an incidence of 12.5 per 100,000.⁴ On ultrasound it takes the appearance of a linear hyperechoic structure raised off the back of the eye. It does not cross the optic nerve and is mobile with extraocular movements. One end will be adherent to the edge of the optic nerve sheath, but the other ends may or may not be free. Spontaneous posterior vitreous detachment (PVD) is an even more commonly seen posterior segment pathology. Posterior vitreous detachment occurs in about 24% of patients aged 50-59 and 87% of patients over 80 years old.⁵ A PVD will generally require higher gain to be visible and will move with a “swishing” motion with extraocular movement. A less hyperechoic band may be seen posteriorly and will appear very thin compared to the thicker, very hyperechoic band seen in a RD. In a PVD this band represents the posterior hyaloid of the vitreous and not the retina; therefore, it can cross the optic nerve. It is notable that a VD and RD often occur together, and care must be taken not to miss a RD in cases of vitreous pathology. These are the most common posterior segment pathologies seen on POCUS, but as this case demonstrates there are other differential diagnoses that have similar findings.

The ultrasound findings on this patient were consistent with pre-retinal hemorrhage. In cases of pre-retinal hemorrhage, retinal capillaries rupture, causing blood to accumulate either in the level of the subhyaloid space, between the retina and the posterior vitreous face, or under the inner limiting membrane (ILM). If there is no

hemorrhage overlying the macula, the patient may be completely asymptomatic. In this case, the patient’s pre-retinal hemorrhage was likely caused by her sneezing fit, suggesting a diagnosis of Valsalva retinopathy. The linear hyperechoic structure seen in this case accumulated above the retina, while the retina itself remained fully attached. The echogenic material seen behind the ILM is pre-retinal blood. With extraocular movement, there may be some movement seen, but it won’t move in the swishing/swirling pattern that a PVD will. Additionally, given that this hyperechoic band is not the retina, it can cross the optic nerve, as was seen in this case.

Another entity that should be considered is choroidal detachment. The choroid, which sits behind the retina, can detach from the sclera, and appear similar to the above pathologies. However, the detachments are deeper on ultrasound and appear convex (Table). While this can occur spontaneously, this less common entity usually occurs in the setting of hypotony after intraocular surgery. Emergency physicians should maintain a high index of suspicion in at-risk patients, and early ophthalmology consultation is recommended in these cases.

CONCLUSION

Valsalva retinopathy, a common cause of pre-retinal hemorrhage, has some characteristic features on POCUS. As was found in our case, POCUS can help to differentiate it from other pathologies that cause permanent vision loss. Given that pre-retinal hemorrhage is not acutely vision threatening, accurate diagnosis by the emergency physician may help alleviate the cost of unnecessary emergent consults and transfers in the future. However, while current literature demonstrates that emergency physicians can accurately identify RDs and PVDs on POCUS, more studies are needed to assess whether ED-performed POCUS can safely exclude RD in cases of pre-retinal hemorrhage.

Video. A narrated B-mode ultrasound video of the right eye showing a thin, minimally mobile, hyperechoic band in the posterior segment that crosses the optic nerve, with underlying scattered echoes.

Table. Summary of ultrasound findings of posterior chamber pathology.

Pathology	Movement	Morphology/ Prominence	Respects optic nerve boundary?
Retinal detachment	Moderate movement, may be free on one end	Visible at low gain	Yes
Vitreous detachment	Moves freely in swishing/swirling motion	Visible at high gain	No
Pre-retinal hemorrhage	Little to none	Thin, hyperechoic strip with echogenic material posterior	No
Choroidal detachment	Little to none	Thick and convex	Yes

The authors attest that their institution requires neither Institutional Review Board approval nor patient consent for publication of this case report. Documentation on file.

Address for Correspondence: Steven Johnson, DO, Beaumont Hospital, Department of Emergency Medicine, 3601 13 Mile Rd, Royal Oak, MI 48072. Email: steven.johnson2@beaumont.org.

Conflicts of Interest: By the *CPC-EM* article submission agreement, all authors are required to disclose all affiliations, funding sources and financial or management relationships that could be perceived as potential sources of bias. The authors disclosed none.

Copyright: © 2022 Johnson. This is an open access article distributed in accordance with the terms of the Creative Commons Attribution ([CC BY 4.0](https://creativecommons.org/licenses/by/4.0/)) License. See: <http://creativecommons.org/licenses/by/4.0/>

REFERENCES

1. Vaziri K, Schwartz SG, Flynn HW Jr, et al. Eye-related emergency department visits in the United States, 2010. *Ophthalmology*. 2016;123(4):917-9.
2. Propst SL, Kirschner JM, Strachan CC, et al. Ocular point-of-care ultrasonography to diagnose posterior chamber abnormalities. *JAMA Network Open*. 2020;3(2):e1921460.
3. Mukherjee C, Kumar A, Mitra A. Valsalva maculopathy: to treat or not to treat. *Oman J Ophthalmol*. 2018;11(1):78-81.
4. Subramanian ML and Topping TM. Controversies in the management of primary retinal detachments. *Int Ophthalmol Clin*. 2004;44(4):103-14.
5. Ramovecchi P, Salati C, Zeppieri M. Spontaneous posterior vitreous detachment: a glance at the current literature. *World J Exp Med*. 2021;11(3):30-6.

Ultrasound in the Emergency Department Identifies Ectopic Pregnancy Post Hysterectomy: A Case Report

Allison Cohen, MD
Dorothy Shi, MD
Evan Keraney, PA-C
Brendon Stankard, PA-C
Mathew Nelson, DO

North Shore University Hospital, Department of Emergency Medicine, Manhasset, New York

Section Editor: Shadi Lahham, MD

Submission History: Submitted September 30, 2021; Revision received February 6, 2022; Accepted February 10, 2022

Electronically published May 5, 2022

Full text available through open access at http://escholarship.org/uc/uciem_cpem

DOI: 10.5811/cpcem.2022.2.54929

Introduction: Ruptured ectopic pregnancy is one of the leading causes of maternal death. Point-of-care ultrasound (POCUS) has been shown to be highly sensitive for excluding ectopic pregnancy. Ectopic pregnancy after a hysterectomy is a rare but life-threatening occurrence. We present a case where POCUS helped to diagnose a post-hysterectomy ectopic pregnancy.

Case report: A 36-year-old female with a prior surgical history of hysterectomy without oophorectomy presented to the emergency department with lower abdominal pain. A POCUS revealed free fluid in the right upper quadrant with an unremarkable gallbladder. Subsequently, the pelvic POCUS noted free fluid as well as a heterogeneous structure in the right adnexa. The clinician ordered a serum beta human chorionic gonadotropin level, which was 173.2 international units per milliliter (IU/mL) (negative: < 5m IU/ml). Transvaginal ultrasound revealed a right adnexal echogenic structure with surrounding vascularity and moderate, complex free fluid suggestive of hemorrhage. Given the concern for possible ectopic pregnancy, obstetrics took the patient to the operating room where a right tubal ectopic pregnancy was confirmed.

Conclusion: A ruptured ectopic pregnancy is a life-threatening condition that requires rapid diagnosis. Ectopic pregnancy post hysterectomy is an uncommon occurrence infrequently considered in the differential diagnosis of lower abdominal pain, leading to considerable delays in diagnosis. Although uncommon, emergency clinicians must consider this diagnosis in female patients with lower abdominal pain. [Clin Pract Cases Emerg Med. 2022;6(2):129-132.]

Keywords: *point-of-care ultrasound; ectopic pregnancy; case report.*

INTRODUCTION

Ectopic pregnancy occurring after a hysterectomy is a rare occurrence that is often difficult to diagnose and is associated with high morbidity and mortality. This diagnosis is often challenging as presenting symptoms are non-specific. There have been multiple reported cases in the literature of ectopic pregnancies occurring post hysterectomy,^{1,4,8,16} with the majority occurring during the time interval directly following the procedure.¹ This case demonstrates how point-of-care

ultrasound (POCUS) helped to diagnose a patient with a post-hysterectomy ectopic pregnancy.

CASE REPORT

A 36-year-old gravida 4 para 2-0-2-2 female, who had a history of ovarian cysts and cervical cancer with prior total laparoscopic hysterectomy without oophorectomy three months prior, presented to the emergency department (ED) with a chief complaint of lower abdominal pain. The patient

reported severe lower abdominal pain that started earlier that day after intercourse. The pain radiated to the right upper quadrant and was worse with deep inspiration. The pain was associated with nausea and vomiting. The patient denied any fevers, chills, chest pain, shortness of breath, dysuria, vaginal bleeding, or vaginal discharge. She had taken acetaminophen prior to ED arrival without any improvement. On presentation the patient was hemodynamically stable with a blood pressure of 129/85 millimeters of mercury, a heart rate of 76 beats per minute, and temperature of 36.7° Celsius. Physical exam was significant for lower abdominal and right upper quadrant tenderness. A point-of-care ultrasound (POCUS) of the right upper quadrant was performed initially, which revealed free fluid (Image 1) and an unremarkable gallbladder.

Given the presence of free fluid in the upper abdomen, and because the patient was a female of childbearing age who reported lower abdominal pain as well, the sonographer expanded the exam to evaluate the lower abdomen. In the right lower abdomen, a heterogeneous structure was visualized in the right adnexa surrounded by complex free fluid (Image 2). Transvaginal POCUS was then performed showing a right adnexal echogenic structure with surrounding vascularity and complex free fluid concerning for a ruptured ectopic pregnancy. A beta human chorionic gonadotropin was ordered after performing the ultrasound given the high clinical suspicion for an ectopic pregnancy.

Laboratory values showed no evidence of anemia with a hemoglobin of 12.8 grams per deciliter (g/dL) (reference range: 11.5-15.5 g/dL) and a mild leukocytosis of 12.4 kilo per microliter (K/uL) (3.8-10.5 K/uL). The human gonadotropin level returned at 173.2 milli-international units per milliliter (mIU/mL) (negative: < 5 mIU/mL). Obstetrics was consulted and took the patient to the operating room. The patient was found to have a ruptured right fallopian-tube ectopic pregnancy with approximately 200 mL of intraperitoneal blood. In the operating room she received bilateral

salpingectomy with removal of the ectopic pregnancy. The patient had an uneventful recovery after the procedure and was discharged home the next day without further complications.

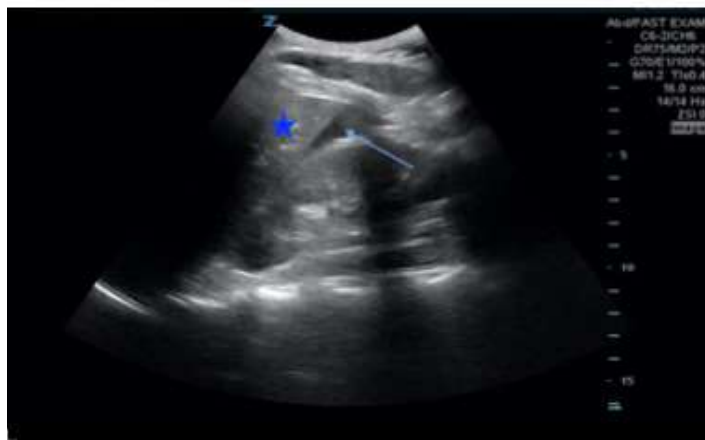

Image 1. A point-of-care ultrasound view of the right upper quadrant showing free fluid (arrow) between the liver (star) and kidney.

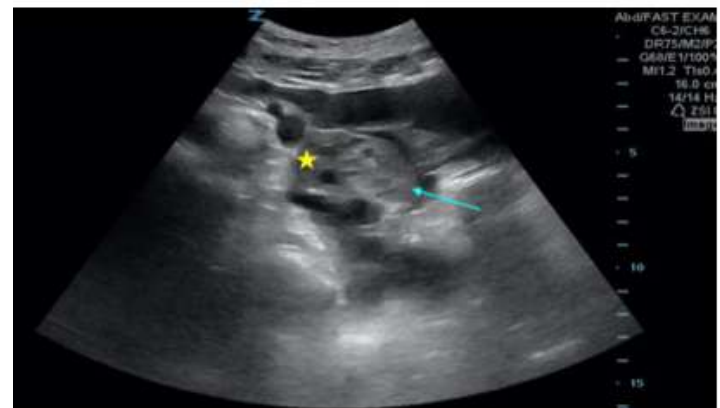


Image 2. Point-of-care ultrasound of the pelvis in transverse view showing a complex structure (arrow) adjacent to the right ovary (star).

CPC-EM Capsule

What do we already know about this clinical entity?

Ectopic pregnancy post hysterectomy is a rare but life-threatening occurrence. The majority occur directly following the procedure.

What makes this presentation of disease reportable?

Post-hysterectomy ectopic pregnancy is difficult to diagnose and is associated with morbidity. Point-of-care ultrasound (POCUS) helped to make this diagnosis.

What is the major learning point?

Erroneously, ectopic pregnancy is often removed from the differential diagnosis in patients who are post hysterectomy, leading to a significant delay in diagnosis.

How might this improve emergency medicine practice?

Increased mortality rates in patients with late post-hysterectomy ectopic pregnancy make rapid detection with POCUS essential to expedite treatment.

DISCUSSION

Ectopic pregnancy after a hysterectomy is a rare but life-threatening condition that requires rapid diagnosis. Erroneously, ectopic pregnancy is often removed from the differential diagnosis in patients who are post hysterectomy, leading to a significant delay in making this critical diagnosis. The presenting symptoms of post-hysterectomy ectopic pregnancy are generally non-specific and range from lower abdominal pain to nausea and vomiting. Vaginal bleeding, which is a common presenting symptom of ectopic pregnancy in a patient with a uterus, is relatively uncommon in post-hysterectomy ectopic pregnancies and it was the presenting symptom in only a few reported cases.²

While post-hysterectomy ectopic pregnancies are rare, there have been reported cases leading to a further classification of the phenomenon as either early or late.^{8,17,18} Early presentations occur when either conception or potential for conception occurs at the time of the hysterectomy.^{2,3} In these cases, fertilization occurred prior to the hysterectomy. It has previously been reported that many of these patients who present soon after the hysterectomy procedure are often diagnosed with postoperative complications leading to a delay in the diagnosis of ectopic pregnancy.⁴

Late presentation ectopic pregnancy occurs well after the hysterectomy has been completed and can occur up to 12 years post procedure.^{2,4} Although the pathophysiology remains unclear, multiple theories have been proposed. One potential mechanism is the creation of a fistula tract between the vaginal dome and the peritoneum or vaginal dome and the fallopian tube.^{5,6} This would create a passageway for sperm to fertilize an ovum. Another possible mechanism is that the fallopian tube prolapses into the vagina creating a communication between the two structures and allowing for fertilization to occur. Although the majority of documented post-hysterectomy ectopic pregnancies occurred after vaginal hysterectomy, it can still be diagnosed in patients after an abdominal hysterectomy with the most common location being in the fallopian tube.^{7,8,11,12}

Early ordering of beta human chorionic gonadotropin levels can aid emergency physicians (EP) in making this diagnosis. In the majority of previously reported post-hysterectomy ectopic pregnancy cases the diagnosis was often delayed and unexpected.⁴ An additional tool that can aid EPs in making this diagnosis is early use of POCUS. In the ED, POCUS is a useful diagnostic tool for evaluating undifferentiated causes of abdominal pain. Point-of-care ultrasound has been shown to be helpful in confirming intrauterine pregnancy and recognizing hemorrhage due to an ectopic pregnancy. Prior studies have shown that EPs can accurately and rapidly use POCUS to detect an intrauterine pregnancy, and previous data has shown a clear role for early ultrasound in patients at risk for ectopic pregnancy.^{9,10,11,12}

Early diagnosis of a ruptured ectopic pregnancy is essential as it is a leading cause of first-trimester maternal

death. Additionally, there have been reports of increased mortality rates in patients with late post-hysterectomy ectopic pregnancy compared with those with intact uteri ectopic pregnancy.^{8,13} Therefore, rapid and accurate detection is essential to reduce mortality and expedite treatment.⁷

CONCLUSION

Ectopic pregnancies in patients with a previous hysterectomy are rare occurrences making the diagnosis difficult. Although it is often on the differential for female patients presenting with abdominal pain, it may be overlooked in patients with a history of a hysterectomy. This case demonstrates the use of point-of-care ultrasound in helping to diagnose a ruptured ectopic pregnancy in a patient with a prior hysterectomy. In this case the findings seen on the POCUS exam facilitated early consultation, resuscitation, and operative intervention. Additionally, as the rate of hysterectomy in child-bearing women is rising, it is expected that the incidence of ectopic pregnancy post hysterectomy will increase.⁸ It is, therefore, important for emergency physicians to remember that prior hysterectomy does not exclude the diagnosis of ectopic pregnancy, and thus EPs must continue to have a high clinical suspicion for this pathology.

The authors attest that their institution requires neither Institutional Review Board approval nor patient consent for publication of this case report. Documentation on file.

Address for Correspondence: Mathew Nelson, DO, North Shore University Hospital, Department of Emergency Medicine, 300 Community Dr., Manhasset, NY 11030. Email: mnelson9@optonline.net

Conflicts of Interest: By the CPC-EM article submission agreement, all authors are required to disclose all affiliations, funding sources and financial or management relationships that could be perceived as potential sources of bias. The authors disclosed none.

Copyright: © 2022 Nelson. This is an open access article distributed in accordance with the terms of the Creative Commons Attribution (CC BY 4.0) License. See: <http://creativecommons.org/licenses/by/4.0/>

REFERENCES

1. Fylstra DL. Ectopic pregnancy after hysterectomy: a review and insight into etiology and prevention. *Fertil Steril.* 2010;94(2):431-5.
2. Villegas E, González-Mesa E, Benítez MJ, et al. Tubal ectopic pregnancy two years after laparoscopic supracervical hysterectomy. *BMC Womens Health.* 2014;14:69.
3. Brown WD, Burrows L, Todd CS. Ectopic pregnancy after cesarean hysterectomy. *Obstet Gynecol.* 2002;99(5 Pt 2):933-4.
4. Shao EX, Hopper K, McKnoulty M, et al. A systematic review of ectopic pregnancy after hysterectomy. *Int J Gynaecol Obstet.* 2018;141(2):159-65.

5. Anupama R, Beegum TR, Indu RN. Ruptured ectopic pregnancy 11 years after supracervical hysterectomy: a case report. *Eur J Obstet Gynecol Reprod Biol.* 2012;162(1):116-7.
6. Barhate KP, Domkundwar S, Patil N, Pai B. Sonographic diagnosis of ectopic pregnancy 2 years after total hysterectomy. *J Clin Ultrasound.* 2009;37(6):347-9.
7. Hitti E, Ghulmiyyah L, Pipkin M. Rare case of recurrent late post-hysterectomy ectopic pregnancy. *Aust N Z J Obstet Gynaecol.* 2010;50(3):303-4.
8. Kaplan BC, Dart RG, Moskos M, et al. Ectopic pregnancy: prospective study with improved diagnostic accuracy. *Ann Emerg Med.* 1996;28(1):10-7.
9. Saad Aldin E, Saadeh J, Ghulmiyyah L, et al. Review article: late post-hysterectomy ectopic pregnancy. *Emerg Med Australas.* 2012;24(3):239-43.
10. Stein JC, Wang R, Adler N, et al. Emergency physician ultrasonography for evaluating patients at risk for ectopic pregnancy: a meta-analysis. *Ann Emerg Med.* 2010;56(6):674-83.
11. Durham B, Lane B, Burbridge L, et al. Pelvic ultrasound performed by emergency physicians for the detection of ectopic pregnancy in complicated first-trimester pregnancies. *Ann Emerg Med.* 1997;29(3):338-47.
12. Blaivas M, Sierzenski P, Plecque D, et al. Do emergency physicians save time when locating a live intrauterine pregnancy with bedside ultrasonography? *Acad Emerg Med.* 2000;7(9):988-93.
13. Wattimena J, Pelosi M, Cheney K, et al. Factors affecting length of stay for women presenting with early pregnancy complications to a public hospital emergency department. *Emerg Med Australas.* 2013;25(1):22-7.
14. Lehner R, Kucera E, Jirecek S, et al. Ectopic pregnancy. *Arch Gynecol Obstet.* 2000;263(3):87-92.
15. McRae A, Murray H, Edmonds M. Diagnostic accuracy and clinical utility of emergency department targeted ultrasonography in the evaluation of first-trimester pelvic pain and bleeding: a systematic review. *CJEM.* 2009;11(4):355-64.
16. Sobczyk O, Levy-Zauberman Y, Houllier M, et al. Ectopic pregnancy 6 years after subtotal hysterectomy: a case report. *J Gynecol Obstet Hum Reprod.* 2018;47(2):95-7.
17. Yeşilyurt H, Özyer Ş, Uzunlar Ö, et al. Abdominal pregnancy after hysterectomy: a rare cause of hemoperitoneum. *J Emerg Med.* 2014;47(4):e99-e101.
18. Zolli A and Rocko JM. Ectopic pregnancy months and years after hysterectomy. *Arch Surg.* 1982;117(7):962-64.

Uterine Sacculaton on Point-of-care Ultrasound in a Pregnant Female Patient: A Case Report

Ajay Puri, MD
Hersimran Kaur, MD
Zhanna Roit, MD
Mathew Nelson, DO

North Shore University Hospital, Department of Emergency Medicine, Manhasset, New York

Section Editor: Shadi Lahham, MD

Submission History: Submitted October 25, 2021; Revision received February 6, 2022; Accepted February 10, 2022

Electronically published May 5, 2022

Full text available through open access at http://escholarship.org/uc/uciem_cpem

DOI: 10.5811/cpcem.2022.2.55216

Introduction: Uterine rupture is a rare but potentially fatal complication of pregnancy. The incidence of uterine rupture is estimated to be between 0.3 and 11 per 10,000. Additionally, uterine sacculaton is a sac or outpouching of the uterus that can lead to uterine rupture in pregnancy. Here we describe a case of a patient who was found to have a uterine sacculaton on point-of-care ultrasound in the emergency department (ED) that was complicated by uterine rupture.

Case Report: A 32-year-old female at approximately 18 weeks gestation presented to the ED with three days of abdominal discomfort. The patient's medical history was significant for prior uterine fibroids requiring recent myomectomy. On arrival the patient was tachycardic, and her abdominal exam revealed distention with mild tenderness to palpation in all quadrants. A point-of-care transabdominal obstetric ultrasound was performed to evaluate the fetal heart rate, which was 157 beats per minute; it also revealed a defect in the uterine wall compatible with a uterine sacculaton. The patient underwent magnetic resonance imaging, which revealed a sac-like structure in the fundal portion of the uterus containing a portion of gestational sac and pregnancy contents. Subsequently, she became hypotensive and tachycardic and was taken emergently to the operating room for concern for uterine rupture. Intraoperatively, uterine rupture was confirmed. The patient underwent surgical repair with evacuation of fetal tissue and recovered in the surgical intensive care unit.

Conclusion: Point-of-care ultrasound is a useful and readily available procedure to identify uterine sacculaton. Early identification can help escalate the urgency of the patient complaint and may lead to a need for further maternal-fetal evaluation. Emergency physicians should keep a high index of suspicion when evaluating the pregnant patient with a history of uterine surgery. [Clin Pract Cases Emerg Med. 2022;6(2):133-136.]

Keywords: *uterine sacculaton; point-of-care ultrasound; uterine rupture.*

INTRODUCTION

Uterine rupture is a rare but potentially fatal complication of pregnancy. The incidence of uterine rupture is estimated to be 11 per 10,000 and 0.3 per 10,000 in women with and without a history of a cesarean delivery, respectively. Additionally, uterine sacculaton is a rare pathology that can lead to uterine rupture in pregnancy.¹ Here we describe a

case of a patient who was found to have a uterine sacculaton on point-of-care ultrasound (POCUS) in the emergency department (ED) that was complicated by uterine rupture.

CASE REPORT

A 32-year-old female at approximately 18 weeks gestation by dates presented to the ED with three days of generalized

abdominal discomfort, “bloating,” and constipation. The patient endorsed not being able to pass a bowel movement for three days and denied being able to pass flatus on the day of presentation. She denied any episodes of emesis, dysuria, hematuria, vaginal bleeding, or leakage of fluid from her vaginal canal. The patient endorsed feeling normal fetal movements. Her medical history was significant for prior uterine fibroids requiring an abdominal myomectomy in 2019 and a laparoscopic revision of the myomectomy due to persistent fibroids three months prior to conceiving. The patient had a confirmed, single, intrauterine pregnancy on her previous outpatient obstetric visits.

Her vital signs in the ED were as follows: heart rate 111 beats per minute; blood pressure 143/65 millimeters of mercury (mm Hg); oral temperature 98.7° Fahrenheit, respiratory rate of 22 breaths per minute, and an oxygen saturation of 97% on room air. Physical examination revealed a mildly uncomfortable-appearing female with dry mucous membranes. Abdominal exam revealed distention appropriate for 18 weeks gestation with mild tenderness to palpation in all quadrants.

A 12-lead electrocardiogram revealed her tachycardia to be sinus rhythm. A point-of-care transabdominal obstetric ultrasound was performed to evaluate the fetal heart rate, which was 157 beats per minute, but also revealed a defect in the uterine wall compatible with a uterine sacculation (Image 1).

The obstetrics and gynecology team was emergently consulted given this finding. The consensus was to have the patient undergo an emergent magnetic resonance imaging (MRI) of the abdomen and pelvis to evaluate the sacculation further, as well as to evaluate for a small bowel obstruction, given the patient had been unable to pass bowel movements or flatus and had a history of abdominal surgery. The MRI revealed a sac-like structure measuring 4.4 centimeters (cm) in the fundal portion of the uterus containing a portion of gestational sac and pregnancy contents with intact serosa (Image 2). The radiologist highlighted that the sacculation placed the patient at increased risk of uterine rupture. She was admitted to the obstetrics service to determine next steps in conjunction with the maternal fetal medicine team.

Five hours after admission, the patient began to exhibit increased lethargy, and her skin appeared pale with her blood pressure becoming hypotensive to approximately 80/40 mm Hg and her heart rate becoming tachycardic to approximately 130 beats per minute. She was given two units of emergent-release packed red blood cells and was taken emergently to the operating room for concern for uterine rupture. Intraoperatively, uterine rupture was confirmed with two liters of hemoperitoneum. The patient underwent surgical repair with evacuation of fetal tissue. She recovered well in the surgical intensive care unit.

DISCUSSION

Uterine sacculation is defined as a transitory pouch or sac-like structure developing from a portion of gravid uterus,

CPC-EM Capsule

What do we already know about this clinical entity?

Uterine sacculation is a rare outpouching of the uterine wall that has been thought to increase the chances of uterine rupture.

What makes this presentation of disease reportable?

Our patient was correctly identified to have a uterine sacculation on a point-of-care ultrasound (POCUS), which expedited emergency department management.

What is the major learning point?

Uterine sacculation can progress to uterine rupture in a short time. It can be identified on POCUS and warrants emergent obstetrics consultation.

How might this improve emergency medicine practice?

Adding uterine sacculation to the list of differential diagnoses and knowing that it may be identified on POCUS will improve care of the pregnant patient.

containing all layers of the uterus.¹ Some sources cite the incidence to be 1 in 3000; however, this incidence refers to sacculations in the setting of uterine incarceration. Uterine sacculation has been extensively reported in patients with concomitant uterine incarceration.^{2,3} Ultrasound and MRI both are excellent imaging options for uterine sacculation; however, it is likely to be discovered only when a patient is imaged for another differential diagnosis of the presenting complaint.

Risk factors for uterine sacculation include uterine malformations, endometriosis, a primary myometrial defect, and prior surgery. In contrast, our patient had a sacculation containing fetal parts through a portion of the uterine fundus likely weakened by her prior laparoscopic myomectomy. It is unclear how often the precise process that occurred in our patient happens. On POCUS, our patient presented with a defect in the uterine wall with concomitant thinning of the wall compared to the rest of the uterus. Given the corroboration on MRI, such findings should raise suspicion of a uterine sacculation with possible impending rupture. Uterine rupture is suggested by free fluid surrounding the uterus in the setting of abdominal pain, distention, or hemodynamic instability.

Most uterine ruptures are associated with patients who have had a prior cesarean section and are attempting a trial of

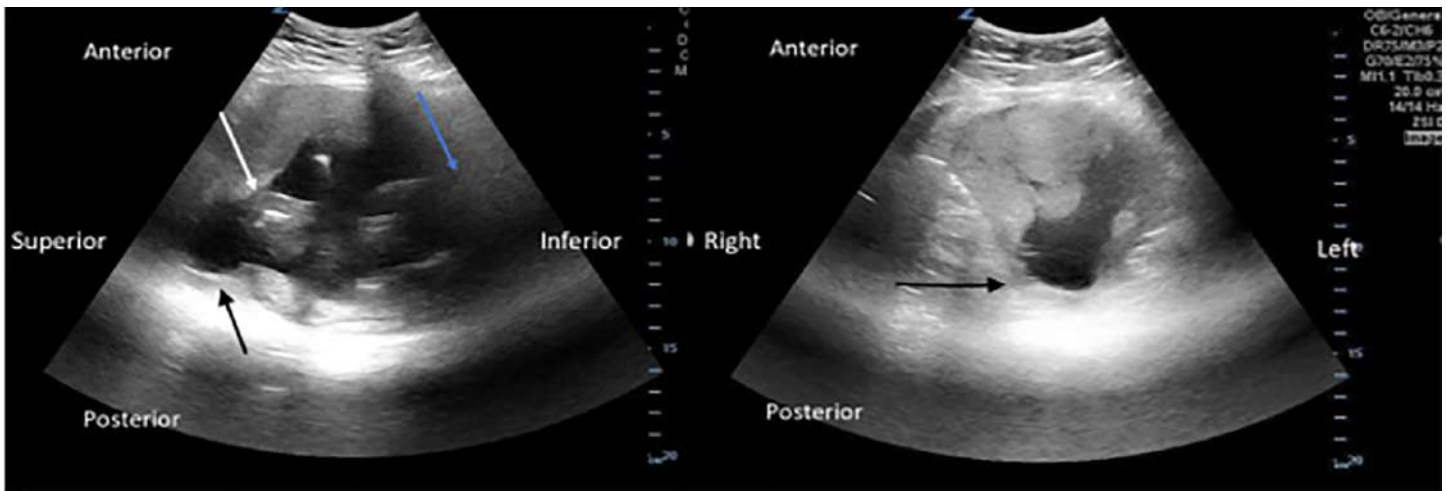


Image 1. A point-of-care transabdominal obstetric ultrasound in the sagittal and transverse views, respectively. The black arrow demonstrates a defect with thinning of the uterine wall compatible with a uterine sacculation in the uterine fundus. The white arrow indicates fetal parts within the uterus. The blue arrow points toward the inferior portion of the uterus. There was no free fluid surrounding the uterus to suggest uterine rupture at this point.

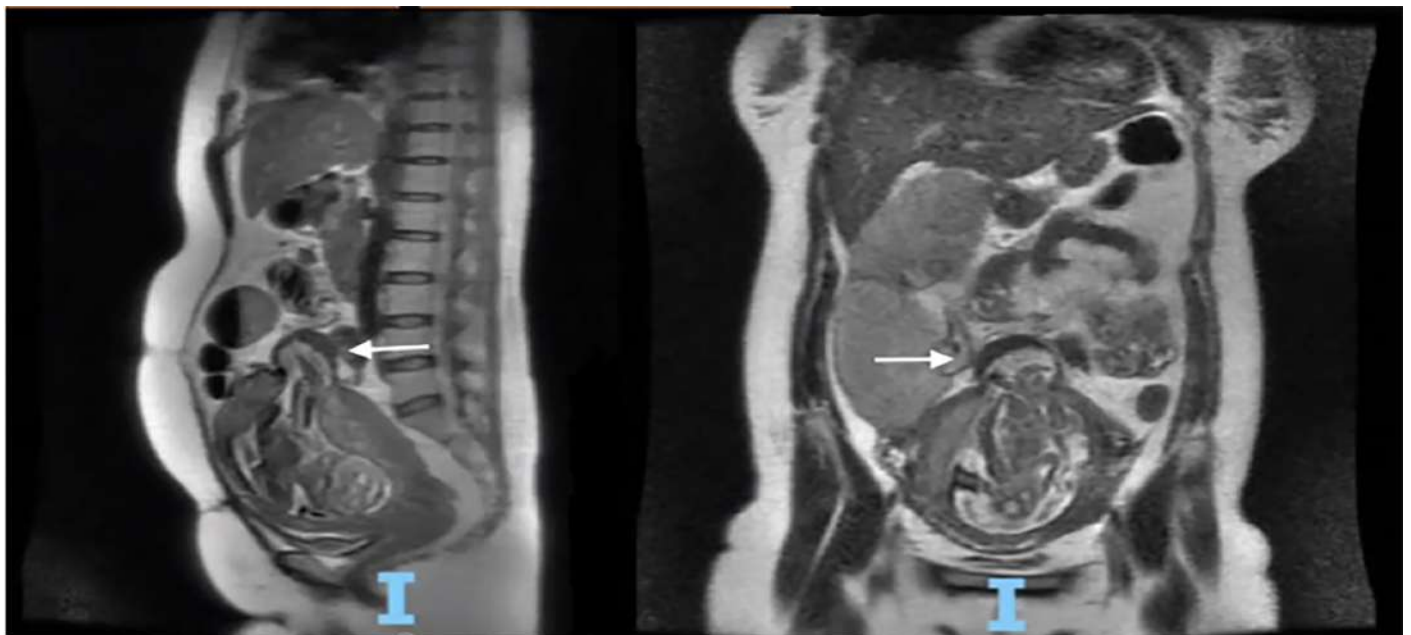


Image 2. Magnetic resonance imaging with white arrow demonstrating a sac-like structure measuring 4.4 centimeters in the fundal portion of the uterus, containing a portion of gestational sac and pregnancy contents with intact serosa seen in the sagittal and coronal views, respectively.

labor.⁴ Upon review of the literature, we found that 31% of cases of uterine rupture occurred in women with prior surgery involving the uterus with 36% of these cases following a laparoscopic myomectomy, which our patient had previously received.⁵ The most frequently encountered symptom or sign prior to diagnosis of uterine rupture is a fetal heart rate abnormality, usually fetal bradycardia, occurring in up to 87.5% of cases.⁴ This is followed by abdominal pain, vaginal bleeding, altered uterine contractions, and hypotension.⁶ In our case, our patient's abdominal discomfort and tenderness

to palpation is what eventually led to her diagnosis of uterine sacculation, but she did not have any identified fetal heart rate abnormalities. Determining a fetal heart rate, even in the fetus that is not yet viable, may be clinically important as it may allude to critical illness affecting the patient.

Our patient's pregnancy was deemed high risk by her obstetrician as she conceived five months after her laparoscopic myomectomy, despite a six-month minimum recommendation. To our knowledge, sources differ on the recommended time period and there isn't clear literature to

support the time periods recommended. Some have suggested three to six months, others recommend waiting at least six months to avoid uterine rupture.^{7,8} A case series of 14 uterine ruptures after laparoscopic myomectomy by Kim et al found the time interval between uterine rupture and myomectomy was between 12-84 months, highlighting that the risk of uterine rupture persists even after significant time has passed since myomectomy.⁹ Hence, it is important to determine whether the pregnant patient presenting with abdominal complaints has had a history of uterine surgery, particularly with recent proximity to conception.

CONCLUSION

Uterine rupture is a devastating intrapartum emergency. It may be preceded by a uterine sacculation caused by prior uterine surgery. Point-of-care ultrasound is a useful and readily available procedure to identify this rare pathology. Early identification can help escalate the concern of our obstetric colleagues and determine the need for further maternal fetal evaluation. Emergency physicians should keep a high index of suspicion when evaluating the pregnant patient with a history of uterine surgery even without the late clinical findings of fetal bradycardia, severe abdominal pain, or heavy vaginal bleeding.

The authors attest that their institution requires neither Institutional Review Board approval nor patient consent for publication of this case report. Documentation on file.

Address for Correspondence: Mathew J. Nelson, DO, North Shore University Hospital, Department of Emergency Medicine, 300 Community Dr., Manhasset, NY 11030. Email: mnelson9@optonline.

Conflicts of Interest: By the CPC-EM article submission agreement, all authors are required to disclose all affiliations, funding sources and financial or management relationships that could be perceived

as potential sources of bias. The authors disclosed none.

Copyright: © 2022 Nelson. This is an open access article distributed in accordance with the terms of the Creative Commons Attribution (CC BY 4.0) License. See: <http://creativecommons.org/licenses/by/4.0/>

REFERENCES

1. Frei KA, Duwe DG, Bonel HM, et al. Posterior sacculation of the uterus in a patient presenting with flank pain at 29 weeks of gestation. *Obstet Gynecol.* 2005;105(3):639-41.
2. Feusner A and Mueller P. Incarceration of a gravid fibroid uterus. *Ann Emerg Med.* 1997;30(6):821-4.
3. Gottschalk EM, Siedentopf JP, Schoenborn I, et al. Prenatal sonographic and MRI findings in a pregnancy complicated by uterine sacculation: case report and review of the literature. *Ultrasound Obstet Gynecol.* 2008;32(4):582-6.
4. Smith JG, Mertz HL, Merrill DC. Identifying risk factors for uterine rupture. *Clin Perinatol.* 2008;35(1):85-viii.
5. Walsh CA and Baxi LV. Rupture of the primigravid uterus: a review of the literature. *Obstet Gynecol Surv.* 2007;62(5):327-54.
6. Fitzpatrick K, Kurinczuk J, Alfirevic Z, et al. Uterine rupture by intended mode of delivery in the UK: a national case-control study. *PLoS Med.* 2012;9(3):e1001184.
7. Lipman J. Pregnancy after fibroid surgery or can I become a happy mom? 2018. Available at: <https://atlii.com/pregnancy-after-fibroid-surgery/>. Accessed October 4, 2021.
8. Mayo Clinic. Myomectomy. 2021. Available at: <https://www.mayoclinic.org/tests-procedures/myomectomy/about/pac-20384710>. Accessed October 4, 2021.
9. Kim H, Oh S, Choi S, et al. Uterine rupture in pregnancies following myomectomy: a multicenter case series. *Obstet Gynecol Sci.* 2016;59(6):454.

Acquired Methemoglobinemia in a Ketamine-induced Ulcerative Cystitis Patient: A Case Report

Spencer Kozik, BS*
Cali Kirkham, MD†
Gabriel Sudario, MD, MEd†

*University of California – Irvine, School of Medicine, Irvine, California
†University of California – Irvine Medical Center, Department of Emergency Medicine, Orange, California

Section Editor: Melanie Heniff, MD, JD

Submission History: Submitted November 2, 2021; Revision received November 2, 2021; Accepted January 4, 2022

Electronically published March 7, 2022

Full text available through open access at http://escholarship.org/uc/uciem_cpem

DOI: 10.5811/cpcem.2022.1.55277

Introduction: As ketamine gains traction as an alternative to opiates in the treatment of chronic pain, ketamine-induced ulcerative cystitis is now being recognized as a complication of its use. The first-line treatment is phenazopyridine, an over-the-counter medication for dysuria that historically has been known to cause methemoglobinemia. This report details the case of a patient presenting to the emergency department (ED) with methemoglobinemia.

Case Report: A 66-year-old woman with a complicated medical history presented to the ED with anemia and hypoxia after extended use of phenazopyridine for treatment of ketamine-induced ulcerative cystitis. She was found to have methemoglobinemia secondary to phenazopyridine used to treat her ketamine-induced ulcerative cystitis, a previously undocumented sequelae of chronic ketamine use. She was admitted to the hospital for three days and made a full recovery.

Conclusion: This case highlights the need to suspect ketamine-induced ulcerative cystitis in patients who use ketamine chronically and be judicious in the use of phenazopyridine for symptom management to prevent life-threatening complications. [Clin Pract Cases Emerg Med. 2022;6(2):137-140.]

Keywords: *cystitis; ketamine; phenazopyridine; methemoglobinemia; case report.*

INTRODUCTION

The use of opioids as a mainstay for pain control has been falling out of favor in recent years due to the risk of abuse, respiratory depression, and accidental overdose. Ketamine, which acts as an analgesic and has dissociative properties, has gained traction in recent years as comparable to morphine but with more benign side effects.¹ Historically known as a drug of abuse, ketamine and the risks of chronic use in a controlled setting are not completely understood.² However, there is an emerging awareness of a rare urologic condition termed ketamine-induced ulcerative cystitis.^{3,4} The prevalence of this disorder is difficult to appreciate given its recent emergence as a clinical entity.

In patients with ketamine cystitis, phenazopyridine, a common over-the-counter (OTC) medication used for

dysuria, is a first-line medication to treat symptoms.

However, phenazopyridine is historically known to cause methemoglobinemia. While methemoglobinemia is a rare condition and the incidence due to phenazopyridine use is unknown, the American Association of Poison Control Centers recently reported 1,234 cases of phenazopyridine exposure over the time frame of one year.⁵ Given its accessibility, caution must be used to limit serious reactions. Here, we present a case of a previously unreported combination of complications of chronic ketamine use in a patient presenting with methemoglobinemia secondary to phenazopyridine use for treatment of ketamine cystitis. Despite the novelty of this presentation, the sequelae of difficult-to-diagnose complications of chronic ketamine use warrants discussion.

CASE REPORT

The patient was a 66-year-old female with past medical history of endometrial carcinoma status post total abdominal hysterectomy (seven years prior), small bowel adenocarcinoma status post resection (12 years prior), and inoperable partial small bowel obstruction. She was being treated for chronic abdominal pain on home ketamine via patient-controlled analgesia pump. Her history was complicated by a recent diagnosis of ketamine-induced cystitis. She presented to the emergency department (ED) from an outside physician for abnormal hemoglobin of 6.1 grams per deciliter (g/dL) (reference range: 12.0-16.0 g/dL).

On evaluation, the patient reported one to two weeks of hematuria without melena, hematochezia, or hematemesis. She reported continued dysuria, frequency, and suprapubic abdominal pain. She also endorsed worsening fatigue and malaise. She denied dyspnea, chest pain, cough, fevers, lightheadedness, or syncopal episodes. Presentation vital signs showed an oxygen saturation of 85% on room air, blood pressure of 113/67 millimeters of mercury (mm Hg), heart rate of 91 beats per minute, and respiratory rate of 18 breaths per minute. She was started on six liters of nasal cannula oxygen without improvement of oxygen saturation.

Of note, the patient had been admitted three weeks prior with dysuria and suprapubic pain. During hospitalization, she was given ceftriaxone for a presumed urinary tract infection without clinical improvement and with negative urine culture. She was ultimately diagnosed with ketamine-induced cystitis, and her pain regimen was modified with the addition of gabapentin, diazepam, venlafaxine, and phenazopyridine. Although asymptomatic, she was incidentally found to be coronavirus disease 2019 (COVID-19)-positive during that admission. At the current visit, the patient reported improvement in dysuria since starting the new pain regimen. She reported that she took her phenazopyridine more frequently than directed, six to eight tablets per day.

On exam the patient was alert and oriented with no signs of trauma, but conjunctival pallor was present. Heart, lungs, and abdominal exam were all normal. Repeat labs in the ED were notable for hemoglobin of 7.4 g/dL, hematocrit of 22.5 (reference range: 36-46%). Venous blood gas revealed a pH of 7.34 (7.35-7.45), partial pressure of carbon dioxide of 50.1 mm Hg (33-45 mm Hg), and partial pressure of oxygen of 38.9 mm Hg (75-105 mm Hg). D-dimer was 690 nanograms per deciliter (ng/dL) (reference range: less than 250 ng/dL), and urinalysis showed moderate hemoglobin, moderate leukocyte esterase, nitrite positive, red blood cell count of 7 per high power field (HPF) (0-3/HPF), and white blood cell count of 32/HPF (0-5/HPF). On imaging a chest radiograph (CXR) showed no abnormalities, and computed tomography angiogram chest was without evidence of pulmonary embolism or other thoracic abnormalities.

The patient's initial presentation was concerning for COVID-19 given her marked hypoxia and recent positive test on prior hospitalization, although the lack of response

CPC-EM Capsule

What do we already know about this clinical entity?

Ketamine-induced ulcerative cystitis is a complication of chronic ketamine use, and the first line treatment, phenazopyridine, has been known to cause methemoglobinemia.

What makes this presentation of disease reportable?

The intersection of two rare diagnoses, ketamine cystitis and methemoglobinemia, sheds lights on the potential complications of two common analgesic medications.

What is the major learning point?

Suspect ketamine-induced ulcerative cystitis in patients with chronic ketamine use and be judicious in the use of phenazopyridine for symptom management.

How might this improve emergency medicine practice?

This case highlights that in medically complex patients, common and easily accessible medications such as phenazopyridine may result in life threatening adverse outcomes.

to supplemental oxygen and unremarkable CXR made this unlikely. Given the history of increased phenazopyridine use, a methemoglobin level was obtained, showing an elevated level of 11.6% (reference range: 0.0-1.5%). After consultation with the Poison Control Center the patient was started on methylene blue in the ED with near immediate improvement of oxygen saturation to 92-93% on 2-4 liters nasal cannula. She was then admitted to the inpatient telemetry unit and was hospitalized for three days. She was transitioned from oxygen support, and palliative care was consulted for her pain regimen. Phenazopyridine was discontinued, and she was transitioned to her outpatient regimen of gabapentin, diazepam, and venlafaxine.

DISCUSSION

Ketamine, a derivative of phencyclidine, was first developed in the 1960s and marketed for its anesthetic properties. Recreational use soon gained popularity due in part to its dissociative and psychedelic effects. Although fatal overdoses are incredibly rare, it is not unusual to see sequelae of recreational ketamine in the ED.⁶ The most common

presentation in the ED is altered mental status, although abdominal pain, urinary complaints, and dizziness are also seen.⁷ The sustained use of ketamine may also induce elevated liver enzymes and biliary dilation, as well as the newly recognized ketamine-induced ulcerative cystitis.⁸

Despite the potential side effects, ketamine continues to gain popularity as a chronic pain treatment. In 2010 the Institute of Medicine released a report estimating that one in three Americans are living with chronic pain and that estimated costs range from \$560-635 billion annually.⁹ In response to concerns over the opioid epidemic, alternative treatments are gaining traction. As recently as 2017, several anesthesia and pain management societies adopted consensus guidelines for ketamine use in chronic pain.¹⁰ They state that despite the lack of large clinical trials, there is sufficient evidence to suggest that ketamine is safe and effective in managing chronic pain. As more patients turn to ketamine as a means of pain control, it is imperative that we understand its pharmacologic properties and potential complications.

Ketamine primarily acts as a noncompetitive N-methyl-D-aspartate (NMDA) antagonist in the central nervous system, most notably in the prefrontal cortex and hippocampus.¹⁰ Ketamine decreases the frequency of channel opening in these regions, leading to lower levels of neuronal activity. In the absence of ketamine, NMDA receptor activation plays a significant role in cognition, chronic pain, central sensitization, and opioid tolerance.¹⁰ To a lesser extent, ketamine also acts through the activation of other receptors such as opioid and D₂ dopamine receptors and through antagonistic effects on muscarinic receptors, sodium, and potassium channels.¹⁰ While the secondary pathways are poorly understood, they may contribute to analgesia and mood regulation.

The term ketamine cystitis first emerged in 2007 after a series of daily ketamine users presented with dysuria, urgency, frequency, and hematuria with sterile urine cultures.³ On computed tomography (CT) imaging these patients displayed evidence of severe inflammation such as bladder wall thickening, decreased capacity, and perivascular stranding, as well as ulcerative cystitis on cystoscopy. Radiologic studies have since correlated these CT findings as well as the occasional presence of hydronephrosis and ureteral wall thickening.¹¹ The pathophysiology of urinary tract damage is not well understood and may be secondary to direct or indirect injury. While symptomatic treatment may help to relieve some of the discomfort in the short term, abstinence from ketamine appears to be the best treatment.^{3,12}

Phenazopyridine is a commonly used OTC medication for the treatment of urinary discomfort. It has historically been associated with methemoglobinemia, although reported cases are rare.³ Methemoglobinemia occurs when ferrous iron (Fe²⁺) is oxidized to the ferric state (Fe³⁺), which decreases the oxygen binding capacity.¹³ Clinically this often presents as headaches, fatigue, shortness of breath, and cyanosis, with severe cases having the potential to be

fatal. Due to a leftward shift of the oxygen dissociation curve, patients are often hypoxic without improvement on supplemental oxygen, as seen in our patient. Physiologically, there are two mechanisms that allow for reduction of methemoglobin to its ferrous state. The primary mechanism is through a nicotinamide adenine dinucleotide hydrogen-dependent reaction via cytochrome B5 reductase and secondarily through a less active nicotinamide adenine dinucleotide phosphate hydrogen (NADPH)-dependent reaction generated by G6PD.¹³

Methemoglobinemia is either congenital or acquired. Congenital causes are due to cytochrome B5 reductase deficiency and hemoglobin M disease.¹³ Acquired cases are often secondary to a drug reaction. Many medications can induce methemoglobinemia; of note, these include dapsone, benzocaine, nitrates and nitrites, sulfonamides, and, as in our case, phenazopyridine. Diagnosis of methemoglobinemia requires an arterial blood gas with methemoglobin levels. A level of greater than 5% is consistent with the diagnosis of methemoglobinemia, although symptoms are typically observed at higher levels, unless other complications such as anemia or lung disease are present. Treatment with methylene blue is not indicated in levels less than 20% unless individuals are symptomatic.¹³ Levels above 30% are often considered fatal unless treatment is initiated. In our patient, the anemia caused by hematuria from ketamine cystitis provided increased sensitivity to lower methemoglobin levels and clinical hypoxia.

The primary treatment of methemoglobinemia is methylene blue, although for acquired cases at lower levels, discontinuation of the offending agent may suffice. Methylene blue is dosed at 1-2 milligrams per kilogram intravenously over several minutes; it acts as an electron transporter in the NADPH-dependent pathway to reduce methemoglobin.¹³ Often, patient response is rapid, although repeat dosing may be necessary. A major contraindication to methylene blue is G6PD deficiency, which causes severe hemolysis.¹⁴ In these patients, ascorbic acid (vitamin C) may be used in place of methylene blue, which acts via a similar mechanism. In refractory cases, the use of hyperbaric oxygen and plasma exchange can be considered.¹⁴

CONCLUSION

As the use of ketamine increases in both recreational and controlled medical settings, it is important for the emergency physician to consider the diagnosis of ketamine-induced ulcerative cystitis in patients with urinary tract symptoms in the absence of positive urine cultures and to obtain a thorough history of drug use. This case also highlights that in medically complex patients, common and easily accessible medications such as phenazopyridine may precipitate life-threatening complications.

The authors attest that their institution requires neither Institutional Review Board approval nor patient consent for publication of this case report. Documentation on file.

Address for Correspondence: Gabriel Sudario, MD, MEd, University of California – Irvine Medical Center, Department of Emergency Medicine, 333 City Blvd W, Suite 640, Orange, CA 92868. Email: gsudario@uci.edu.

Conflicts of Interest: By the CPC-EM article submission agreement, all authors are required to disclose all affiliations, funding sources and financial or management relationships that could be perceived as potential sources of bias. The authors disclosed none. Dr. Gabriel Sudario is a member of WestJEM's sponsoring society California ACEP.

Copyright: © 2022 Kozik. This is an open access article distributed

REFERENCES

- Motov S, Rockoff B, Cohen V, et al. Intravenous subdissociative-dose ketamine versus morphine for analgesia in the emergency department: a randomized controlled trial. *Ann Emerg Med.* 2015;66(3):222-9.e1.
- Niesters M, Martini C, Dahan A. Ketamine for chronic pain: risks and benefits. *Br J Clin Pharmacol.* 2014;77(2):357-67.
- Shahani R, Streutker C, Dickson B, et al. Ketamine-associated ulcerative cystitis: a new clinical entity. *Urology.* 2007;69(5):810-2.
- Gray T and Dass M. Ketamine cystitis: an emerging diagnostic and therapeutic challenge. *Br J Hosp Med (Lond).* 2012;73(10):576-9.
- Gummin DD, Mowry JB, Spyker DA, et al. 2018 Annual Report of the American Association of Poison Control Centers' National Poison Data System (NPDS): 36th Annual Report. *Clin Toxicol (Phila).* 2019;57(12):1220-413.
- Kalsi SS, Wood DM, Dargan PI. The epidemiology and patterns of acute and chronic toxicity associated with recreational ketamine use. *Emerg Health Threats J.* 2011;4:7107.
- Ng SH, Tse ML, Ng HW, et al. Emergency department presentation of ketamine abusers in Hong Kong: a review of 233 cases. *Hong Kong Med J.* 2010;16(1):6-11.
- Noppers IM, Niesters M, Aarts LPHJ, et al. Drug-induced liver injury following a repeated course of ketamine treatment for chronic pain in CRPS type 1 patients: a report of 3 cases. *Pain.* 2011;152(9):2173-8.
- Institute of Medicine (US) Committee on Advancing Pain Research, Care, and Education. *Relieving Pain in America: A Blueprint for Transforming Prevention, Care, Education, and Research.* 2011. Available at <https://www.ncbi.nlm.nih.gov/books/NBK91497>. Accessed August 20, 2021.
- Cohen SP, Bhatia A, Buvanendran A, et al. Consensus guidelines on the use of intravenous ketamine infusions for chronic pain from the American Society of Regional Anesthesia and Pain Medicine, the American Academy of Pain Medicine, and the American Society of Anesthesiologists. *Reg Anesth Pain Med.* 2018;43(5):521-46.
- Huang LK, Wang JH, Shen SH, et al. Evaluation of the extent of ketamine-induced uropathy: the role of CT urography. *Postgrad Med J.* 2014;90(1062):185-90.
- Tsai TH, Cha TL, Lin CM, et al. Ketamine-associated bladder dysfunction. *Int J Urol.* 2009;16(10):826-9.
- Tintinalli JE and Stapczynski JS. (2011). *Tintinalli's Emergency Medicine: A Comprehensive Study Guide.* 7th Ed. New York: McGraw-Hill.
- Price DP. (2015). Methemoglobin inducers. In: Hoffman RS, Howland M, Lewin NA, Nelson LS, Goldfrank LR, editors. *Goldfrank's Toxicologic Emergencies.* 10th Ed. New York: McGraw-Hill.

Postpartum Ovarian Vein Thrombosis: Case Report

Stephen M. Ferguson, MD
David Arbona, MD
Anthony Furiato, DO

HCA Healthcare/University of South Florida Morsani College of Medicine GME/
Brandon Regional Hospital, Department of Emergency Medicine, Brandon, Florida

Section Editor: Joell Moll, MD

Submission History: Submitted June 19, 2021; Revision received January 4, 2022; Accepted January 10, 2022

Electronically published April 14, 2022

Full text available through open access at http://escholarship.org/uc/uciem_cpccem

DOI: 10.5811/cpcem.2022.1.53749

Introduction: Postpartum ovarian vein thrombosis (POVT) is an uncommon diagnosis that may lead to morbidity or mortality if unrecognized.

Case Report: This report discusses a single case of POVT in a community hospital, along with the treatment and clinical course.

Conclusion: The mechanism is believed to be right-sided clot formation provoked by anatomical and hormonal changes of gestation. Diagnosis is challenging as most patients are previously healthy and symptoms are often vague. Although the differential is broad, modern imaging is sensitive and specific for diagnosis. Prompt treatment with broad-spectrum antibiotics and anticoagulation may reduce morbidity, and prognosis following treatment is excellent. [Clin Pract Cases Emerg Med. 2022;6(2):141-145.]

Keywords: *ovarian vein thrombosis; postpartum; puerperal; hypercoagulability; case report.*

INTRODUCTION

Postpartum ovarian vein thrombosis (POVT) is a rare diagnosis most commonly made in the postpartum period. Estimates place its incidence as 0.5-2 cases per 1000 vaginal deliveries, and 20 cases per 1000 cesarean deliveries.^{1,2} It was first described in 1956 and has subsequently appeared in case reports and small observational studies.³ The pathophysiology of POVT is likely multifactorial, consisting of biochemical and structural alterations.

Pregnancy influences all three elements of Virchow's triad to augment clot formation. Hormonal changes, including increased estrogen levels, contribute to hypercoagulability. Coagulation factors II, VII, VIII, and X, as well as platelet activating factors and von Willebrand factor, increase during pregnancy. Additionally, protein S and antithrombin III levels decrease and resistance to activated protein C is common.⁴ Endothelial injury occurs due to pro-inflammatory status, direct intrapartum insult, or bacterial endothelial damage.^{5,6} Bacterial spread, especially via right ovarian vein from intrauterine sources, may contribute to pathogenesis. Septic thrombophlebitis, considered an infectious variant, depends largely on this spread and the right ovarian vein's antegrade course.⁷

Gestational venous stasis promotes POVT, while physiological and anatomical variations predispose the right ovarian vein particularly. Approximately 90% of POVT are right-sided. The right gonadal vein follows a longer course, is narrower, and features incompetent valves.^{6,8-10} Extrinsic factors include dextrorotation compressing the inferior vena cava (IVC) and right ovarian vein, as well as flow reversal during delivery.^{2,6,9}

Known risk factors include prior pro-coagulable state, multiparity, and surgical delivery.^{1,2,10,11} Cesarean section significantly increases POVT risk, especially when combined with underlying coagulopathy.^{1,2,7,11} Some cases concern patients lacking any non-gestational risk factors, however.⁹ Onset is usually within seven days of delivery but may be up to four weeks postpartum.^{7,9} The classic presentation is fever, right lower abdominal pain, and a palpable mass. Rarely, however, do patients present with all three elements.⁹ Symptoms are often non-specific, further complicating diagnosis.² Important differential diagnoses include appendicitis, ovarian torsion, endometritis, and tubo-ovarian abscess.

Ovarian vein thrombosis is generally diagnosed via imaging, rather than clinically or surgically.² Ultrasonography, computed

tomography (CT), or magnetic resonance imaging (MRI) may be used. Treatment usually consists of antibiotic therapy and months-long or lifetime anticoagulation.^{1,2,7,10,12} Antibiotic therapy is usually broad spectrum, with coverage for causative agents in endometritis. Surgical intervention or vena cava filter placement are reserved for rare cases of failed medical management.^{1,12}

Morbidity in POVT is due to clot extension, sepsis, and intrauterine infection. Pulmonary embolism is the most feared complication and occurs in approximately 13-25% of cases, accounting for much of the 4-5% overall mortality.^{6,9,10,12} Most patients recover without significant morbidity.¹³ This report describes a POVT case identified in the emergency department (ED), exemplifying the diagnostic and therapeutic controversies concerning this rare condition.

CASE REPORT

The patient was a 20-year-old female who presented to the ED with complaints of right-sided flank and abdominal pain. Her past medical history included idiopathic osteochondromas and benign thyroid nodules. Family history did not elucidate additional risk factors. The patient was primiparous, postpartum day five from vaginal delivery with epidural anesthesia. Term induction of labor was employed due to small gestational size. No other pregnancy complications were reported, apart from second trimester cystitis and third trimester round ligament pain. Clear artificial rupture of membranes was performed; there was no prolonged rupture interval. She tolerated delivery well and was discharged on postpartum day one.

The patient indicated a gradual onset of right lower back pain and lower abdominal pain from postpartum day three onward. She described both pains as “sharp” and positional in nature. She denied prior instances of similar pain, traumatic insult, fever, malodorous vaginal discharge, dysuria, incontinence, or lower extremity paresis. Initial vital signs were as follows: heart rate 119 beats per minute; blood pressure 135/82 millimeters of mercury; oxygen saturation 98% on room air; temperature 37.1° Celsius; and respiration rate of 18 breaths per minute. Examination revealed an uncomfortable, otherwise well-appearing young female with right lumbar tenderness and right suprapubic tenderness.

The differential diagnosis included ascending infection or other causes of sepsis, muscular strain, and post-epidural hematoma or abscess. Contrast CT imaging of lumbar spine, abdomen, and pelvis was obtained. Complete blood count, metabolic panel, lactic acid, and blood cultures were also evaluated. Pain was controlled with intravenous morphine and topical lidocaine. Initial laboratory studies were non-contributory. White blood cell count was 10,400 per microliter (uL) (reference range: 4.5-11.0/uL) without left shift.

The lumbar spine CT showed no mass effect or soft tissue pathology. Abdominal CT demonstrated an “ill-defined tubular structure with extensive fat stranding” following expected right ovarian vein course, terminating in inferior vena cava confluence (IVC) (Images 1 and 2). Subsequent pelvic ultrasound was

CPC-EM Capsule

What do we already know about this clinical entity?

Postpartum ovarian vein thrombosis (POVT) represents a life-threatening cause of puerperal pelvic pain. Diagnosis depends on imaging studies and is complicated by non-specific symptoms.

What makes this presentation of disease reportable?

Our patient presented with classic symptoms, but lacked established gestational risk factors of pro-coagulable state, multiparity, or surgical delivery.

What is the major learning point?

Early recognition, imaging, and treatment of postpartum women presenting with lower abdominal and or pelvic pain can aid diagnosis and reduce morbidity and mortality.

How might this improve emergency medicine practice?

The case highlights this rare postpartum differential and diagnostic difficulties, as well as therapeutic uncertainties. This case particularly emphasizes how patients may lack any predisposing factors and the diagnosis merits consideration for postpartum patients presenting to the emergency department.

ordered to further characterize these findings. A complex right adnexal structure was noted but was “indeterminate.”

Anticoagulation with enoxaparin and empirical antibiotics were initiated. The patient was admitted to the obstetrical service. Hematology consultants recommended IVC ultrasound to better characterize suspected thrombus. Ultrasound confirmed IVC patency, but inadequately visualized culprit ovarian vein. On review of initial imaging, the reading radiologist felt that MRI was not warranted as POVT was highly probable. The patient remained asymptomatic and in stable condition. She was transitioned to oral apixaban and discharged on admission day three.

DISCUSSION

This case highlights multiple areas of ongoing discussion regarding this rare diagnosis. Given its low incidence, POVT risk factors, clinical presentation, preferred imaging modality, and long-term management are all subjects of debate. Risk factors predisposing POVT, ostensibly absent in this case, may be more common than originally understood. Our patient

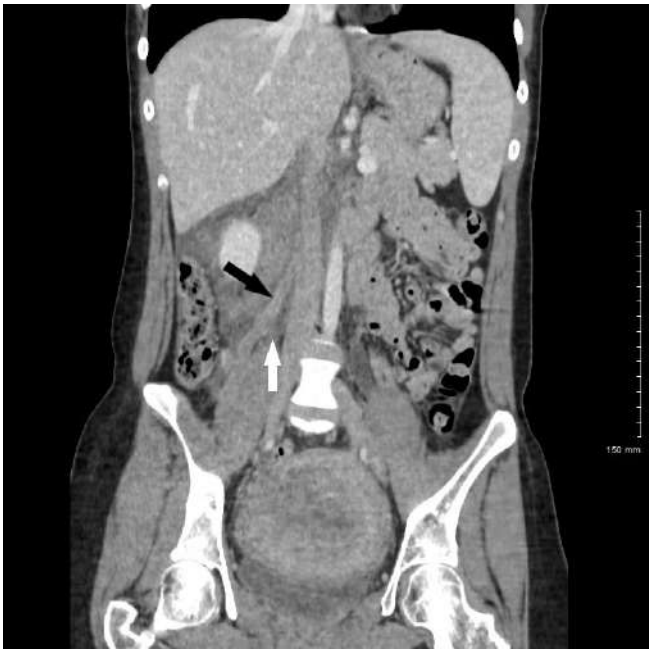

Image 1. Contrast-enhanced coronal computed tomography image showing tubular enhancing structure along the expected course of right ovarian vein (black arrow) with surrounding fat stranding (white arrow).

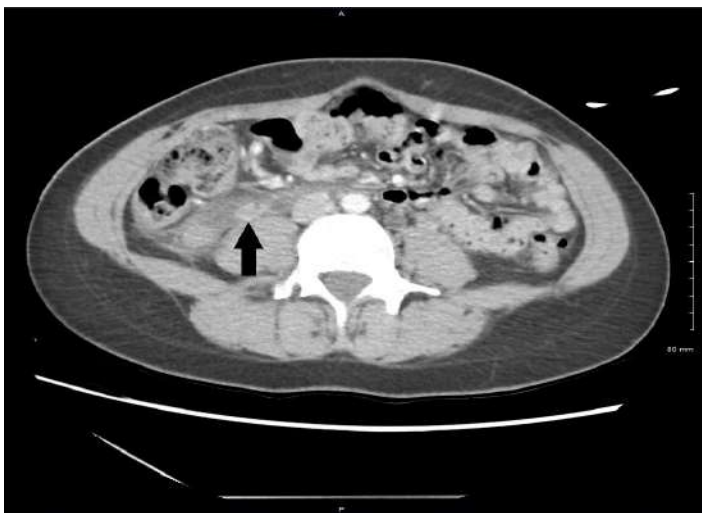

Image 2. Contrast-enhanced axial computed tomography image showing hyperdense border and lumen corresponding to thrombosis along course of right ovarian vein (black arrow).

lacked the conventional peripartum risk factors of cesarean delivery, endometritis, or multiparity. She further lacked personal or family history of hypercoagulability.

Small studies have suggested that many such patients have occult genetic mutations that may not manifest except with the provocation of gestation. For instance, Salomon et al studied 22 patients with POVT, finding that 11 of them had genetic markers for hypercoagulability. The authors

went so far as to suggest “prothrombotic tendency” as an element of POVT pathophysiology.¹¹ This data demonstrates how outpatient testing for hypercoagulability may aid in prognostication and may guide decisions regarding long-term anticoagulation or future prophylaxis.

In this case, the clinical picture comported with more recent studies on presenting signs and symptoms. The patient had only one element of the classical POVT description comprising fever, pelvic or low abdominal pain, and palpable mass. Furthermore, the patient’s pain was positional and associated with lower back discomfort. Accounting for the patient’s recent epidural anesthesia, the differential broadens beyond even the acute abdomen. Prior to widely available advanced imaging, diagnosis was often made via laparotomy for acute abdomen.¹ Recent studies describe cases in which the patients lacked specific POVT features or when it was an incidental imaging finding.^{2,7,9} Jenayah et al found that “only half will experience right lower quadrant abdominal pain.” One study of 50 patients with ovarian vein thrombosis from all causes noted that 18% were discovered incidentally on imaging.² Taken together, the body of literature on POVT implies that diagnosis requires clinical suspicion and low threshold for imaging in equivocal presentations.

Due to diagnostic uncertainty, our patient’s evaluation required multiple imaging modalities, a feature discussed in multiple small studies. For instance, a prospective study of 76 patients with presentations concerning for POVT compared ultrasound, CT, and MRI. In the 12 patients with diagnosed POVT both CT and MRI had sensitivity and specificity of greater than 90%.¹⁴ In a study of ovarian vein thrombosis in 45 patients from all causes, Wysosinska et al noted that 92% were diagnosed via CT.¹⁵ Contrast-enhanced CT imaging of the abdomen was employed first in this case. Surrounding fat stranding and tubular mass in the presumed area of ovarian vein course were noted, although images did not demonstrate a clear lumen or clot burden. The original radiologist suggested delayed venous phase imaging, as the contrast load would more clearly delineate the venous system.

Twickler et al used a delayed intravenous contrast load, which may be considered for imaging of suspected POVT. Pelvic ultrasound is commonly employed as a radiation-sparing and cost-effective initial choice, although it was employed for a timely secondary evaluation in this case. Ultrasound lacks sufficient sensitivity (50-56% by some estimates), however, and is often technically limited.^{7,9,10,14} In our case, too, ultrasound proved inadequate for definitive diagnosis due to patient discomfort. Ultrasound of the vena cava was able to ensure patency and exclude clot extension. Contrast-enhanced MRI was considered in this case, but not undertaken. Of note, no reviewed literature involved cases in which MRI discovered POVT that CT failed to detect.

Long-term management of POVT may be the most controversial clinical question regarding the diagnosis. The standard of care includes broad-spectrum antibiotics for presumed endometritis extension and anticoagulation

for months, or lifelong.^{1,10} One case report cites a 52% mortality without any treatment, with reduction to 5-25% with anticoagulation.⁹ Conversely, multiple articles question anticoagulation's role, citing limited supporting data.^{2,13} Brown et al conducted a randomized intention-to-treat trial of 14 POVT patients. The two study groups were given antibiotics with or without heparin. The results were similar in terms of length of febrile illness and hospitalization. None had continued morbidity or recurrence at three months.¹³

Similarly, Plastini et al reported "no statistically significant correlation found between treatment and no treatment in terms of overall outcomes for patients diagnosed with OVT," based on a retrospective review of 50 patients with ovarian vein thrombosis from all causes.² The argument against long-term anticoagulation is supported further by radiology-based studies showing thrombus resolution in 7-14 days.⁷ Exceptions to these recommendations are cases of a chronic hypercoagulable state or patients with recurrent thrombosis. These cases likely warrant long-term or gestational anticoagulation.^{1,4,9}

In this case, the patient received one milligram/kilogram enoxaparin twice daily during inpatient anticoagulation. Antibiotics were vancomycin and piperacillin-tazobactam. Antibiotic choice has not been studied, but gentamicin and clindamycin are common choices to cover Gram-positive and anaerobic bacteria. The patient was then transitioned to apixaban. Apixaban was chosen due to its safety and monitoring profile, although it should be noted that this patient did not desire to breastfeed. Novel oral anticoagulants, unlike warfarin, are not recommended in breastfeeding mothers. No trials have compared novel anticoagulants vs warfarin in POVT.¹⁰ Aspirin is not recommended for prophylaxis.⁴

The recurrence rate of POVT is unknown, but ovarian thrombosis from all causes may recur at rates similar to deep vein thrombosis.^{12,15} To date, no recommendations exist regarding prophylaxis in future pregnancy.^{1,6} Given this, empirical prophylaxis in future pregnancies is not recommended routinely. Further study via controlled trial or meta-analysis may be an opportunity to study treatment of this rare disease with a sufficiently powered sample.

CONCLUSION

Postpartum ovarian vein thrombosis is an uncommon, but important, diagnosis for emergency physicians to be familiar with. This unique disorder results from puerperal predisposition to thrombosis, any underlying prothrombotic state, and ascending infection. Diagnosis is difficult, owing to its vague symptoms and a broad differential of more common diagnoses. Imaging with CT is usually sufficient for diagnosis, although other modalities may be required. Treatment consists of anticoagulation to treat thrombosis and antibiotic coverage for a presumed infectious component. Morbidity is due to clot extension or sepsis. The prognosis with treatment is most commonly complete resolution.

This research was supported (in whole or in part) by HCA Healthcare and/or an HCA Healthcare-affiliated entity. The views expressed in this publication represent those of the author(s) and do not necessarily represent the official views of HCA Healthcare or any of its affiliated entities.

The authors attest that their institution requires neither Institutional Review Board approval nor patient consent for publication of this case report. Documentation on file.

Address for Correspondence: Anthony Furiato, DO, HCA Healthcare/USF Morsani College of Medicine GME/Brandon Regional Hospital, Department of Emergency Medicine, 119 Oakfield Drive, GME Office #214 C/O Naureen Khan, Brandon, FL 33511. Email: stephen.ferguson@hcahealthcare.com.

Conflicts of Interest: By the CPC-EM article submission agreement, all authors are required to disclose all affiliations, funding sources and financial or management relationships that could be perceived as potential sources of bias. The authors disclosed none.

Copyright: © 2022 Ferguson. This is an open access article distributed in accordance with the terms of the Creative Commons Attribution (CC BY 4.0) License. See: <http://creativecommons.org/licenses/by/4.0/>

REFERENCES

1. Arkadopoulos N, Dellaportas D, Yiallourou A, et al. Ovarian vein thrombosis mimicking acute abdomen: a case report and literature review. *World J Emerg Surg.* 2011;6(1):45.
2. Plastini T, Henry D, Dunleavy K. Ovarian vein thrombus: to treat or not to treat? *Blood Adv.* 2017;1(15):1120-3.
3. Austin OG. Massive thrombophlebitis of the ovarian veins; a case report. *Am J Obstet Gynecol.* 1956;72(2):428-9.
4. Marik PE, Plante LA. Venous thromboembolic disease and pregnancy. *N Engl J Med.* 2008;359(19):2025-33.
5. Yockey LJ and Iwasaki A. Interferons and proinflammatory cytokines in pregnancy and fetal development. *Immunity.* 2018;49(3):397-412.
6. Togan T, Turan H, Ciftci E, et al. Ovarian and renal vein thrombosis: a rare cause of fever outer the postpartum period. *Case Rep Obstet Gynecol.* 2015;2015:817862.
7. Khilfi A, Kebaili S, Hammami M, et al. Postpartum ovarian vein thrombophlebitis: report of a case and review of the literature. *N Am J Med Sci.* 2010;2(8):389-91.
8. Ghosh A and Chaudhury S. A cadaveric study of ovarian veins: variations, measurements and clinical significance. *Anat Cell Biol.* 2019;52(4):385-9.
9. Jenayah AA, Saoudi S, Boudaya F, Bouriel I, Sfar E, Chelli D. Ovarian vein thrombosis. *Pan Afr Med J.* 2015;21:251.
10. Kodali N, Veytsman I, Martyr S, et al. Diagnosis and management of ovarian vein thrombosis in a healthy individual: a case report and a literature review. *J Thromb Haemost.* 2017;15(2):242-5.
11. Salomon O, Apter S, Shaham D, et al. Risk factors associated with postpartum ovarian vein thrombosis. *Thromb Haemost.* 1999;82(3):1015-9.

12. Sinha D, Yasmin H, Samra JS. Postpartum inferior vena cava and ovarian vein thrombosis--a case report and literature review. *J Obstet Gynaecol.* 2005;25(3):312-3.
13. Brown CE, Stettler RW, Twickler D, et al. Puerperal septic pelvic thrombophlebitis: incidence and response to heparin therapy. *Am J Obstet Gynecol.* 1999;181(1):143-8.
14. Twickler DM, Setiawan AT, Evans RS, et al. Imaging of puerperal septic thrombophlebitis: prospective comparison of MR imaging, CT, and sonography. *AJR Am J Roentgenol.* 1997;169(4):1039-43.
15. Wysokinska EM, Hodge D, McBane RD 2nd. Ovarian vein thrombosis: incidence of recurrent venous thromboembolism and survival. *Thromb Haemost.* 2006;96(2):126-31.

Delayed Blunt Traumatic Carotid Artery Dissection After a Scooter Accident: A Case Report

Robert Rigby, DO
Suneil Agrawal, MD

Desert Regional Medical Center, Department of Emergency Medicine, Palm Springs, California

Section Editor: Christopher Sampson, MD

Submission History: Submitted October 14, 2021; Revision received January 27, 2022; Accepted January 25, 2022

Electronically published April 25, 2022

Full text available through open access at http://escholarship.org/uc/uciem_cpem

DOI: 10.5811/cpem.2022.1.55058

Introduction: Traumatic carotid artery dissections (CAD) are rare but produce potentially devastating injuries. Most patients develop symptoms within 72 hours of traumatic injury.

Case Report: We report the case of a 33-year-old, previously healthy male who presented to the emergency department for evaluation of transient, right-sided facial droop with visual changes. His symptoms began 12 days after falling off a scooter. Imaging revealed an extracranial internal CAD.

Conclusion: Symptoms of CAD may present weeks after blunt trauma, making clinical diagnosis difficult. Clinicians must have high suspicion for vascular injury and consider neuroimaging in cervical flexion/extension injuries. [Clin Pract Cases Emerg Med. 2022;6(2):146-150.]

Keywords: *blunt traumatic injury; carotid artery dissection; CT angiogram neck; case report.*

INTRODUCTION

A carotid artery dissection (CAD) results from tearing in the intimal layer of the artery leading to thrombus formation, wall hematoma, and even lumen occlusion. A dissection occurs spontaneously or traumatically and is classified as extracranial or intracranial. Extracranial arteries are more mobile and thus, hypothetically, more prone to injury. A traumatic dissection may occur from penetrating injury or from blunt injury. There are four fundamental mechanisms of blunt carotid artery injury described: direct application of force to the neck (type I); hyperextension and contralateral rotation of the head and neck (type II); intraoral trauma affecting the carotid artery at the angle of the jaw (type III); or lacerations of the carotid artery resulting from a basilar skull fracture (type IV).¹

The reported annual incidence rate of CAD is 2.6 to 2.9 per 100,000.² Internal CADs (ICAD) sustained from blunt traumatic injuries are the most common subset of cerebrovascular injuries identified.² There is an increase in cervical artery dissection diagnosis, likely secondary to increased use of computed tomography angiography (CTA) performed in the screening of trauma patients. Recent publications indicate a blunt cerebrovascular injury (BCVI)

incidence between 1-2% of in-hospital trauma population and up to 9% of patients with severe head injury.³ Vertebral and carotid artery dissections are the most frequent cause of cerebrovascular accidents in the young, with over half presenting with stroke or transient ischemic attacks (TIA).⁴ Typical symptoms of cervical artery dissections include neurologic symptoms involving the anterior or posterior circulation, Horner's syndrome, cranial or cervical neuropathies, or pulsatile tinnitus. Patients classically have a headache or neck pain at or prior to neurological symptom onset, although typical symptoms may be absent in older patients.⁵ Local or neurological symptom onset is typically within 72 hours of injury, although there are reports of delayed symptoms up to six months.⁶

The incidence of electric scooter injuries has nearly doubled in the United States between 2018 and 2019, and the head is the most common site of injury in scooter-injury patients presenting to the emergency department (ED).⁷ There is one case report of a seven-year-old male who sustained a traumatic vertebral artery dissection and basilar artery occlusion/stroke four days after falling off a scooter.⁸ To our knowledge, there are no case reports of delayed ICAD from a scooter accident.

CASE REPORT

A 33-year-old Black male with no significant past medical history presented to the ED for evaluation of intermittent, right-sided facial droop and blurred vision. Symptoms were intermittent, lasting approximately 15 minutes at a time, and onset one hour prior to arrival while sitting in a chair. He had a total of three episodes prior to coming into the ED. He had a mild left frontal headache described as dull and non-radiating, with associated lightheadedness, confusion, and palpitations. There were no modifying or alleviating factors. The headache occurred shortly after he noticed a right-sided facial droop in a mirror. His symptoms had completely resolved at the time of initial evaluation.

His right upper extremity was in a splint because of an injury to his wrist sustained 12 days prior after falling off an electric scooter. He denied current arm pain. He denied hitting his head or loss of consciousness during the scooter accident. He denied neck or back pain but stated he may have “whipped” his neck back and forth during the fall. He was not on blood thinners. He denied weakness or numbness/tingling in his arms or legs. Vitals signs were stable with a temperature of 37° Celsius, blood pressure of 128/67 millimeters of mercury, heart rate of 58 beats per minute, respiratory rate of 20 breaths per minute, and an oxygen saturation of 97% on room air. Initial physical examination demonstrated no neurological deficits.

There was no Marfanoid habitus, or evidence of Horner’s syndrome or cranial nerve palsies. He had no dysmetria, and he ambulated normally without ataxia. The motor strength of his right upper extremity was difficult to fully assess as he had a splint in place, but he had 5/5 motor strength in his proximal and distal upper and lower extremities bilaterally. His sensation to light touch appeared intact in all extremities. Other than a splint to his right upper extremity, there was no evidence of trauma on examination.

An electrocardiogram revealed normal sinus rhythm without abnormalities. Laboratory work including a complete blood count, basic metabolic panel, and troponin were all within normal limits. Neuroimaging was performed and he had a normal computed tomography (CT) of his head without contrast. The CT angiogram (CTA) of the neck demonstrated significant stenosis extending distal to the left carotid bulb to near the skull base with a carotid string sign (Image 1 and 2), consistent with ICAD. A carotid string sign is produced by a stenotic, diminished, weak antegrade flow of contrast material in the internal carotid artery.¹⁶

He developed very subtle right-sided facial droop, lightheadedness, and a left frontal headache after imaging was performed. Magnetic resonance imaging (MRI) of the brain demonstrated multiple foci of acute infarct involving the left hemisphere (Image 3).

Vascular surgery and neurology were consulted. He was admitted to the telemetry unit of the hospital. Intravenous heparin and oral rosuvastatin were started inpatient. His

CPC-EM Capsule

What do we already know about this clinical entity?

Carotid artery dissection (CAD) can be caused by blunt trauma and is the most frequent cause of cerebrovascular accident in the young.

What makes this presentation of disease reportable?

This case highlights a man with a CAD resulting in a transient ischemic attack weeks after a minor mechanism scooter accident.

What is the major learning point?

Carotid artery dissection can occur after a minor whiplash mechanism and can present with delayed neurologic deficits.

How might this improve emergency medicine practice?

Patients presenting to the emergency department with flexion/extension injury should be considered for computed tomography angiogram neck to evaluate for CAD, although guidelines make no absolute recommendations.

symptoms resolved completely, and he had an unremarkable hospital stay. He had a normal transthoracic echocardiogram with bubble study performed inpatient. He was discharged two days later on rosuvastatin and apixaban. He was asymptomatic at a six-month phone call follow-up and had normal appearance of the left internal carotid artery on imaging one year later.

DISCUSSION

Carotid artery dissections sustained from blunt traumatic injuries may have a delayed diagnosis given vast symptoms, and some may only become symptomatic and diagnosed once neurological symptoms ensue, as in this case. This patient likely sustained a type II CAD secondary to a whiplash injury resulting in multiple TIAs. The patient was examined by an unknown medical professional the day of his scooter accident and was diagnosed with a right wrist injury. He was placed in a splint; however, he had no neurological or physical complaints until his visit to the ED 12 days later. He specifically denied neck or back pain following the event. It is possible he experienced subtle neck discomfort at the time of

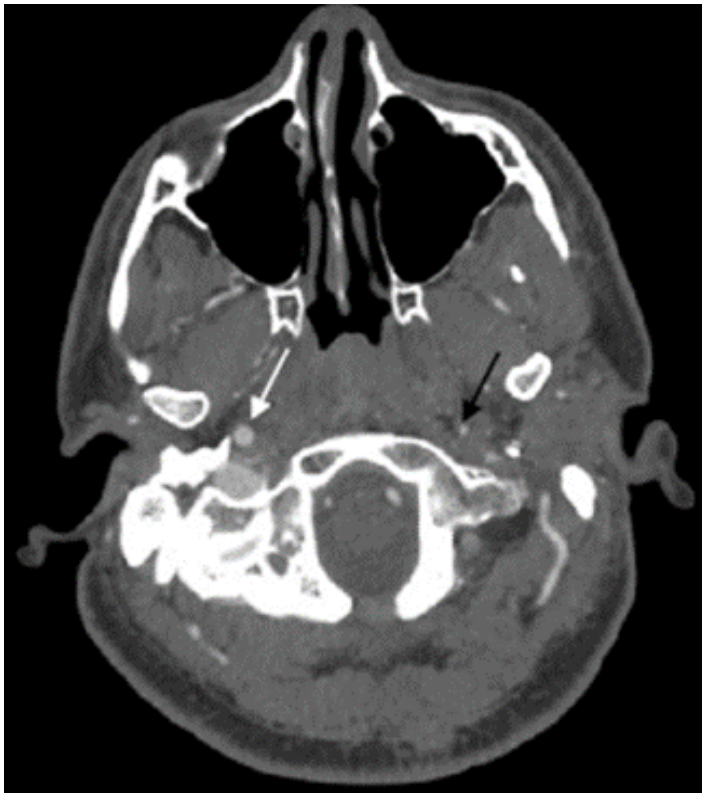

Image 1. Axial computed tomography demonstrating significant stenosis of the left internal carotid artery (black arrow) vs the patent right internal carotid artery (white arrow).

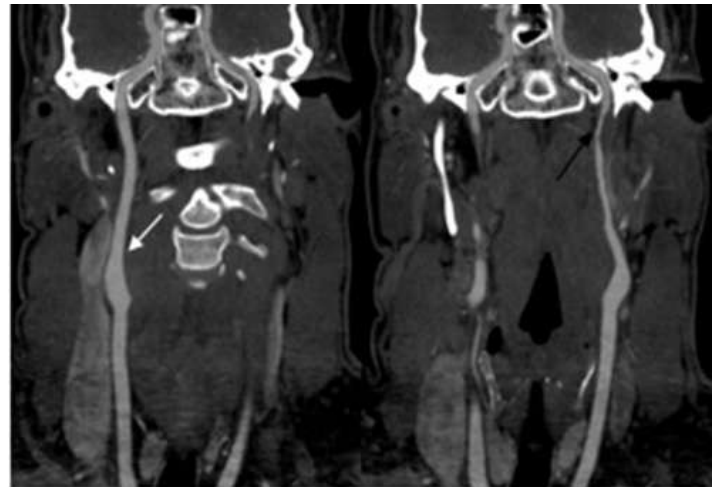


Image 2. Coronal computed tomography demonstrating patent right internal carotid artery (white arrow) and the stenosis of the left internal carotid artery depicting the "carotid string sign" (black arrow).

injury with a distracting right upper extremity injury, but this was never reported. Given the recent trauma with an adequate mechanism to explain his arterial injury, his dissection was likely traumatic rather than spontaneous, although categorization may be difficult to determine, especially when the initial symptom onset is delayed from the time of arterial injury. Nonetheless, many case reports in the literature demonstrating a delayed presentation of CAD describe a delayed diagnosis, rather than delayed symptom onset.^{9,10}

A delay in diagnosis before development of neurological symptoms ensue could be prevented with universal screening for BCVI with CTA of the neck. Recent literature supports the application of expanded Denver criteria and supports the liberal use of CTA in trauma patients, as up to 30% of BCVI do not meet screening criteria.^{11,12} Expanded Denver criteria recommends CTA if there are signs/symptoms or risk factors for BCVI, which include one or more of the following: arterial hemorrhage from the neck/nose/mouth; cervical bruit in patients less than 50 years old; expanding cervical hematoma; a focal neurological deficit; a neurological exam incongruous with head CT findings; or stroke on secondary CT.

Risk factors for BCVI include a high-energy transfer mechanism with any of the following: Le Fort II or III injury; mandible fracture; complex skull, basilar skull, or occipital

skull fracture; severe traumatic brain injury (TBI) with Glasgow Coma Scale <6; cervical spine fracture; subluxation or ligamentous injury at any level; near hanging with anoxic brain injury; seat belt abrasion with significant swelling; pain or altered mental status; TBI with thoracic injury; scalp degloving; thoracic vascular injury; blunt cardiac rupture; or upper rib fracture.³

A 2020 study by Leichtle et al showed that adopting universal screening for BCVI with CTA of the neck yielded a diagnosis of BCVI in nearly 20% of patients who would have gone undiagnosed using the most sensitive and extensive screening criteria.¹³ Recent practice management guidelines from the Eastern Association for the Surgery of Trauma (EAST) recommend screening CTA of the neck in high-risk cervical spine injuries and conditionally recommend screening CTA of the neck in low-risk cervical spine injuries.¹² A high-risk cervical spine injury includes upper cervical spine (C1-C3) fractures, subluxation, and cervical spine fractures that extend into the transverse foramen. Low-risk cervical spine fracture patterns or injuries include any cervical spine injury. Given the incidence of BCVI in low-risk cervical spine injuries ranging from 2-9%, EAST guidelines recommend performing CTA on a case-by-case basis.¹² Given the mechanism of injury in the patient presented here, there was justification for performing a CTA of the neck during his initial medical visit, although none of the guidelines absolutely required it. If the imaging had been performed, an early diagnosis of CAD may have been made, although his outcome may not have changed.

The patient presented here had an MRI demonstrating multiple tiny acute infarcts to all lobes of the left hemisphere of the brain. It is more common for an ICAD to produce an arterial occlusion by an embolization of a local thrombus

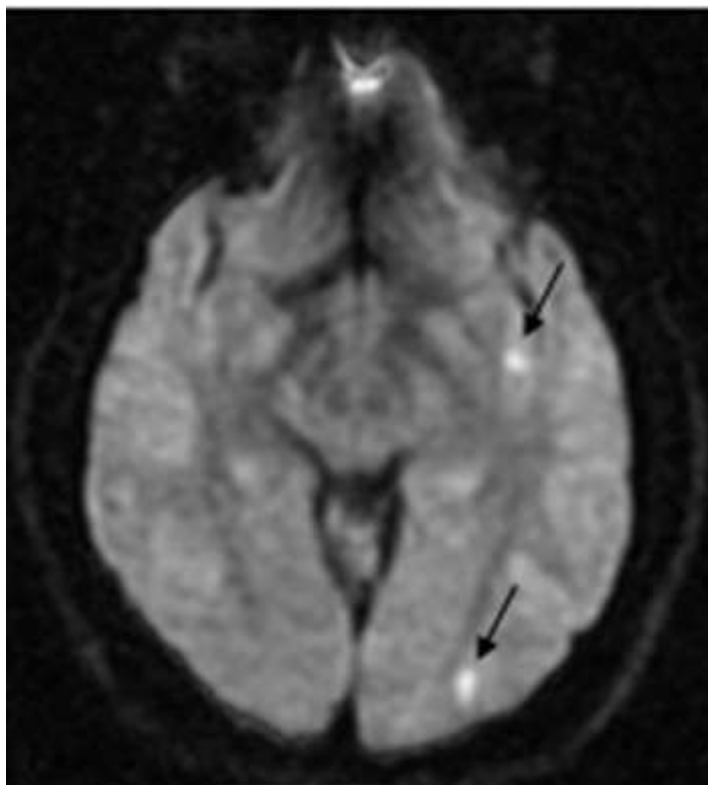


Image 3. Diffusion-weighted magnetic resonance imaging demonstrating multiple small acute infarcts in the temporal and occipital lobes of the left hemisphere (black arrows). Acute infarcts located in the frontal and parietal region of the left hemisphere are not shown.

rather than the stenosis produced by the dissection. Carotid arteries supply the anterior circulation of the brain, and vertebral arteries predominately supply the posterior circulation of the brain. A fetal posterior cerebral artery (PCA) is present in approximately 20-30% of people and occurs when the PCA partially or fully originates from the internal carotid artery.¹⁴ This patient had a partial fetal PCA responsible for the infarct to the left occipital lobe.

Specific treatment guidelines of BCVI continue to be controversial, but it is recommended to initiate antithrombotic therapy, either an anticoagulant or antiplatelet, as soon as considered safe, even in the setting of severe head injury or other solid organ injury.¹² There is a paucity of high-quality evidence guiding specific choice of medical treatment. Some authors recommend low-molecular weight heparin at an antithrombotic dose initially, transitioning to aspirin when feasible.³ Routine stenting as treatment is rarely necessary as the potential harms often outweigh the potential benefits.¹²

CONCLUSION

Traumatic blunt cerebrovascular injuries are a potentially devastating but rare injury. Strokes after a carotid dissection

are associated with a mortality rate of 25% and morbidity of 38%.¹⁵ The integration of CTA head and neck into polytrauma protocols is becoming more common, but there must still be a high clinical suspicion for BCVI in what appear to be minor whiplash injuries. This case supports the conditional recommendation of the recent EAST guidelines and the recent 2020 study by Leichtle et al regarding universal screening for BCVI with CTA neck in all trauma patients. Patients presenting to the ED for evaluation of a flexion/extension cervical injury should be informed of potentially life-threatening and neurological sequelae and provided strict precautions to return to the ED if initial vascular imaging is not obtained.

This research was presented at the Desert Regional Medical Center Residency Research Symposium in September 2021.

The authors attest that their institution requires neither Institutional Review Board approval nor patient consent for publication of this case report. Documentation on file.

Address for Correspondence: Suneil Agrawal, MD, Desert Regional Medical Center, Department of Emergency Medicine, 1150 N Indian Canyon Drive, Palm Springs, CA 92262. Email: suneil.agrawal@vituity.com.

Conflicts of Interest: By the CPC-EM article submission agreement, all authors are required to disclose all affiliations, funding sources and financial or management relationships that could be perceived as potential sources of bias. The authors disclosed none.

Copyright: © 2022 Rigby. This is an open access article distributed in accordance with the terms of the Creative Commons Attribution (CC BY 4.0) License. See: <http://creativecommons.org/licenses/by/4.0/>

REFERENCES

1. Crissey MM and Bernstein EF. Delayed presentation of carotid intimal tear following blunt craniocervical trauma. *Surgery*. 1974;75(4):543-9.
2. Blum CA and Yaghi S. Cervical artery dissection: a review of the epidemiology, pathophysiology, treatment, and outcome. *Arch Neurosci*. 2015;2(4):e26670.
3. Brommeland T, Helseth E, Aarhus M, et al. Best practice guidelines for blunt cerebrovascular injury (BCVI). *Scand J Trauma Resusc Emerg Med*. 2018;26:90.
4. Morris NA, Merkler AE, Gialdini G, et al. Timing of incident stroke risk after cervical artery dissection presenting without ischemia. *Stroke*. 2017;48(3):551-5.
5. Traenka C, Dougoud D, Simonetti BG, et al. Cervical artery dissection in patients ≥60 years often painless, few mechanical triggers. *Neurology*. 2017;88(14):1313-20.
6. Pozzati E, Giuliani G, Poppi M, et al. Blunt traumatic carotid dissection with delayed symptoms. *Stroke*. 1989;20:412-6.
7. Farley KX, Aizpuru M, Wilson JM, et al. Estimated incidence of electric scooter injuries in the US from 2014 to 2019. *JAMA Netw Open*. 2020;3(8):e2014500.

8. Phung B and Shah T. Traumatic vertebral artery dissection and basilar artery occlusion/stroke in a 7-year-old child: a case report. *J Pediatr Intensive Care*. 2019;8(4):233-7.
9. Edmundson SP, Hirpara KM, Ryan RS, et al. Delayed presentation of carotid artery dissection following major orthopaedic trauma resulting in dense hemiparesis. *J Bone Joint Surg*. 2009;91:536-9.
10. Pampin JB, Tamayo NM, Fonseca RH, et al. Delayed presentation of carotid dissection, cerebral ischemia, and infarction following blunt trauma: two cases. *J Clin Forensic Med*. 2002;9(3):136-40.
11. Bensch FV, Varjonen EA, Pyhältö, TT, et al. Augmenting Denver criteria yields increased BCVI detection, with screening showing markedly increased risk for subsequent ischemic stroke. *Emerg Radiol*. 2019;26:365-72.
12. Kim DY, Biffi W, Bokhari F, et al. Evaluation and management of blunt cerebrovascular injury: a practice management guideline from the Eastern Association for Surgery of Trauma. *J Trauma Acute Care Surg*. 2020;88(6):875-87.
13. Leichtle SW, Banerjee D, Schrader R, et al. Blunt cerebrovascular injury: the case for universal screening. *J Trauma Acute Care Surg*. 2020;89(5):80-6.
14. Christoph DH, Souza-Lima F, Saporta MA, et al. Isolated posterior cerebral artery infarction caused by carotid artery dissection. *Arch Neurol*. 2009;66(8):1034-5.
15. Schicho A, Luerken L, Meier R, et al. Incidence of traumatic carotid and vertebral artery dissections: results of cervical vessel computed tomography angiogram as a mandatory scan component in severely injured patients. *Ther Clin Risk Manag*. 2018;14:173-8.
16. Kashyap V and Clair D. Carotid string sign. *J Vasc Surg*. 2006;43(2):401.

A Pop from a Shock: A Case Report of an Unusual Cause of Achilles Tendon Rupture

Chia-Yuan Michael Lee, DO
Mark A. Newberry, DO

Mount Sinai Medical Center, Department of Emergency Medicine, Miami Beach, Florida

Section Editor: Christopher San Miguel, MD

Submission History: Submitted October 22, 2021; Revision received January 24, 2022; Accepted February 4, 2022

Electronically published April 6, 2022

Full text available through open access at http://escholarship.org/uc/uciem_cpem

DOI: 10.5811/cpem.2022.2.55090

Introduction: Achilles tendon ruptures often occur during physical activity where the tendon is frequently stressed. Although rare, rupture can also result from electric shock.

Case Report: We present the case of a 63-year-old female who presented with pain in the lower leg after enduring an electric shock. She was diagnosed with a ruptured Achilles tendon based on physical exam and ultrasound.

Conclusion: This case highlights an uncommon mechanism for a relatively common injury. Because Achilles tendon ruptures are frequently misdiagnosed, clinicians need to be aware of unusual causes and use tools at their disposal to ensure timely and accurate diagnosis. [Clin Pract Cases Emerg Med. 2022;6(2):151-154.]

Keywords: *case report; Achilles tendon injury; electric shock injuries; point-of-care ultrasound.*

INTRODUCTION

Despite being the thickest and strongest tendon of the human body, the Achilles tendon (AT) is the one that most often completely ruptures.^{1,2} Because it is at an increased risk of rupture during excessive eccentric muscle contraction or explosive plyometric movements, most AT ruptures occur during physical activity.³ Here, we present a case of AT rupture after an uncontrolled and unexpected muscle contraction triggered by the unintentional exposure to a low-voltage household current.

CASE REPORT

A 63-year-old female presented to the emergency department (ED) with pain just posterior to the left medial malleolus after experiencing an electric shock. She had stepped on an exposed wire on her way to bed after a shower and felt a shock followed immediately by a left calf spasm. She denied falls, syncope, or additional blunt trauma to her leg. Initially, she thought it was a minor cramp that would resolve. Although she was able to ambulate, persistent discomfort and new-onset bruising behind the malleoli prompted her to go to the ED the next day.

On evaluation, her vitals were unremarkable. There was decreased plantarflexion both actively and when her calf was squeezed. An area of ecchymosis was present above her calcaneus and posterior to her medial malleolus. There were no burns or wounds noted at the electrocution site. Her labs, including a complete blood cell count, basic metabolic panel, and creatine phosphokinase were unremarkable. Her electrocardiogram revealed a normal sinus rhythm.

The overall clinical picture was suspicious for AT injury, prompting the use of point-of-care ultrasound to evaluate the integrity of the tendon in both the sagittal and transverse planes. The images obtained supported the diagnosis of a complete AT rupture (Image 1, 2, and 3).

The patient was placed in a posterior short leg splint with her foot in plantarflexion and discharged with crutches. She was instructed to follow up with an orthopedic surgeon.

DISCUSSION

Achilles tendon ruptures are a relatively common injury with an estimated incidence between seven and 40 per 100,000 people per year.³ Over the past few decades, the incidence of ruptures has risen significantly, likely due

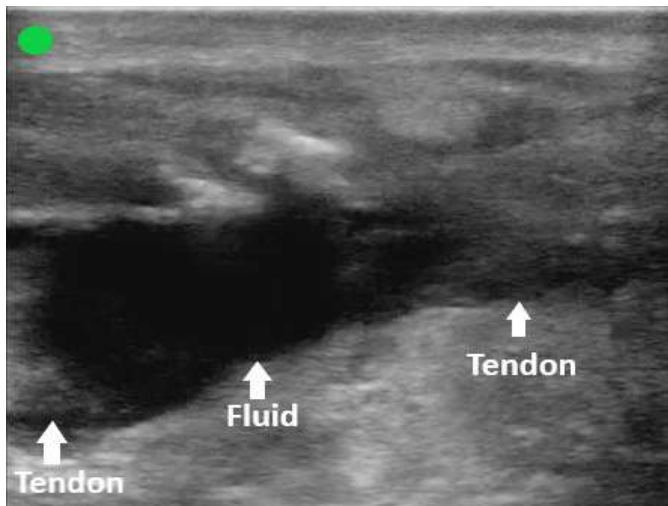


Image 1. Sagittal view of the proximal Achilles tendon. Point-of-care ultrasound image obtained with a high-frequency linear probe with the probe marker directed cephalad. A large anechoic fluid collection is present between two distinct ends of the ruptured tendon.

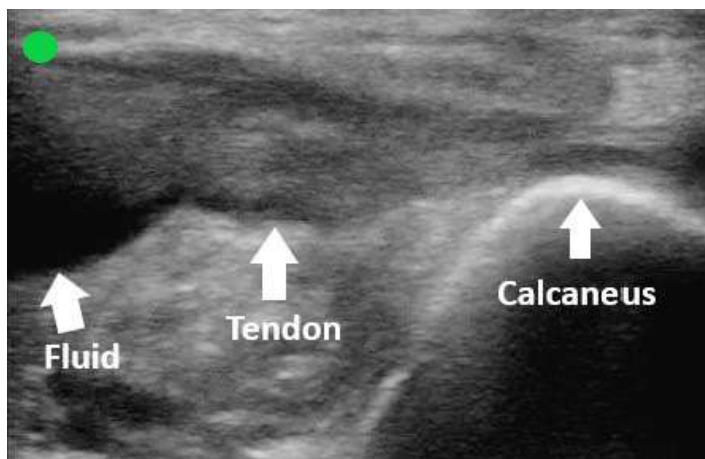


Image 2. Sagittal view of the distal Achilles tendon. Point-of-care ultrasound image obtained with a high-frequency linear probe with the probe marker directed cephalad. An anechoic fluid collection is present just proximal to where the Achilles tendon attaches to the calcaneus.

to increased participation in physical activity.^{3,4,5} Multiple studies have demonstrated that most AT ruptures occur during sports.^{2,3,4,6,7} Approximately 80% of AT ruptures occur two to six centimeters above its insertion point at the calcaneus as this region is vulnerable to injury due to its relatively poor blood supply.^{2,4,6} The injury predominantly occurs in males with a male-to-female ratio ranging from 2:1 to 12:1.^{1,4} White-collar professionals who only intermittently engage in athletics comprise a significant portion of these patients.^{1,6}

The most frequent mechanism of injury is pushing off the forefoot while extending the knee, a movement commonly performed in sports such as basketball, soccer, volleyball, and

CPC-EM Capsule

What do we already know about this clinical entity?
Achilles tendon ruptures frequently occur during physical activity.

What makes this presentation of disease reportable?
Achilles tendon rupture resulting from an involuntary muscle contraction secondary to an electric shock is an uncommon and unusual mechanism of injury.

What is the major learning point?
Achilles tendon ruptures are frequently misdiagnosed. Simple physical exam maneuvers and ultrasound can help make the diagnosis.

How might this improve emergency medicine practice?
Familiarity with uncommon causes of Achilles tendon rupture and competency with point-of-care ultrasound may expedite time to diagnosis and prevent delay in proper management.

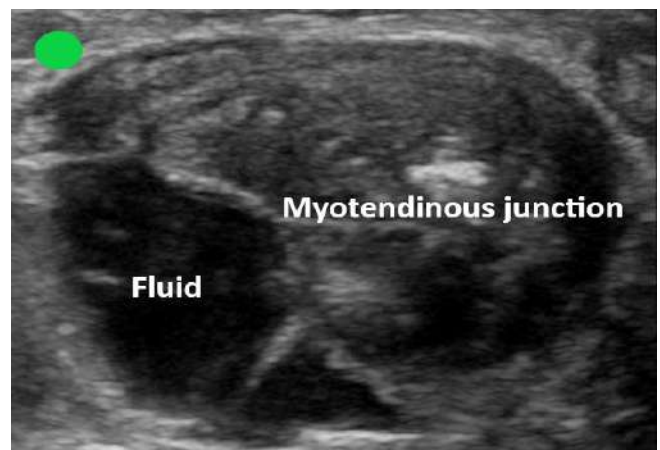


Image 3. Transverse view of the Achilles myotendinous junction. Point-of-care ultrasound image obtained with a high-frequency linear probe with the probe marker directed to the left of a prone patient. A large anechoic fluid collection is present among the fibers of the myotendinous junction.

gymnastics.¹ Other common mechanisms of injury include abrupt unexpected dorsiflexion (eg, stumbling into a hole or slipping down steps) and extreme dorsiflexion of a foot in plantarflexion (eg, falling from height).¹

While the exact etiology for tendon rupture is unclear, there are intrinsic and extrinsic factors that can predispose

an individual to tendinopathy and injury.^{4,7} Intrinsic factors include anatomical malalignments, biomechanics, weight, age, or gender.⁷ Certain conditions such as autoimmune and inflammatory disease, renal insufficiency, and gout may also increase risk of rupture.^{7,8} Extrinsic factors consist of training errors, environment, and medications such as steroids.^{4,7} The patient in this case had no known predisposing factors other than her age.

In a noteworthy scenario, our patient suffered a rupture from an electric shock. To the best of our knowledge, there has only been one other case report of AT rupture from an electric shock. In that case, a woman experienced a shock while blow drying her hair, causing her to jerk her leg uncontrollably and rupture her tendon.⁹

Approximately 10,000 patients present annually to the ED for evaluation after experiencing an electric shock, which typically occurs at home or work.¹⁰ Electric shock injuries (ESI) can result from thermal energy due to heat, electrical damage from the current, or mechanical damage from trauma or forced contractions.¹⁰ The extent of injury depends on factors including resistance, voltage, current type, and duration of contact.¹⁰⁻¹² Although ESI most commonly present as skin burns, it is common for ESI victims to also experience bone, muscle, or tendon injury.¹⁰ High-voltage currents will typically cause burns while low-voltage currents are more likely to cause muscle tetany.¹¹ Most household electrical sources consist of alternating current, which is more damaging than direct current given equal voltages.¹¹ Furthermore, household currents are typically low frequency, which tend to cause muscle contractions.¹¹ At times, the contractions may even be strong enough to cause fractures and dislocations.¹⁰⁻¹²

The classic presentation of an AT rupture is sudden pain in the leg that may be associated with a pop or snap. Patients may report feeling as if they were struck in the calf or heel. They may struggle with walking and pushing off the affected leg. Approximately 25% of AT ruptures are initially misdiagnosed, frequently as ankle sprains.^{1,5,6} Unexpected mechanisms, lack of pain, and ability to ambulate or plantarflex may confuse clinicians and lead to error.^{5,6} For the emergency clinician, it is of utmost importance to avoid missing the diagnosis. Failure to diagnose or delay in treatment can result in chronic issues such as pain, ambulatory dysfunction, loss of strength, and difficulty in returning to baseline activities.⁵ Thus, the emergency clinician should be familiar with physical exam findings and imaging modalities that can assist in identifying an AT rupture.

Clinical diagnostic tests that can be used to evaluate for AT rupture include palpating for a defect along the tendon, the calf squeeze test, Matles test, Copeland test, and O'Brien test. The calf squeeze test and Matles test have the highest sensitivity and, unlike the Copeland and O'Brien tests, do not require additional equipment.¹³ To perform the calf-squeeze test, the examiner should squeeze the patient's calf to induce plantarflexion of the foot. If the AT is ruptured, there should

be no or little plantarflexion induced.¹³ To perform the Matles test, the patient should lie prone and flex both knees to 90 degrees. The examiner should then evaluate the position of the feet. If the AT is intact, the foot should be in slight plantarflexion, and if the AT is ruptured, the foot should be in a neutral position or in dorsiflexion.¹³

If clinical testing is ambiguous or limited due to pain or body habitus, further imaging, such as clinical ultrasound (CUS) and magnetic resonance imaging (MRI), can be considered. Although MRI is the gold standard for imaging, it is more expensive and time consuming than CUS and less likely to be available.^{5,8} Clinical ultrasound provides real-time analysis, allows for efficient dynamic examination of the tendon, and has been shown to have high diagnostic capability with some studies reporting a sensitivity of up to 100%.^{8,14} Musculoskeletal ultrasound is routinely used by emergency physicians and taught in emergency medicine residency programs; it is included as a core application for emergency physicians in the most recent emergency, point-of-care and clinical ultrasound guidelines.¹⁵

To perform ultrasound evaluation of the AT, the patient should lie prone. The fibers of the tendon should be evaluated in both a sagittal and transverse plane. For assessment in the sagittal plane, the probe should be placed directly on top of and in line with the tendon. For assessment in the transverse plane, the probe should be placed perpendicular to the tendon. Using a high-frequency linear probe, the examiner should start scanning at the calcaneal tuberosity where the AT inserts and then slide the probe proximally to the myotendinous junction. A normal AT will have fibers that are linear, regular, and without interruption. A ruptured tendon may have fibers with thick irregular edges, interruptions along the course of the tendon, or anechoic areas that may represent hematoma.

Once the diagnosis is made, the emergency clinician should splint the patient's affected extremity in the equinus position (plantarflexion), provide crutches and analgesics, and refer the patient to an orthopedic surgeon for follow-up ideally within two days.⁶ Definitive treatment of the injury centers on restoring the tendon to its normal length and tension and rehabilitating calf muscle strength and function.⁶ Currently, there is no consensus on whether a conservative or operative approach is the optimal treatment for acute AT ruptures.^{1,2,8} Ultimately, patient-specific factors and shared decision-making with an orthopedic surgeon should determine the definitive treatment plan.

CONCLUSION

Although Achilles tendon ruptures are common, not all result from obvious mechanisms. Uncommon and atypical mechanisms, such as an electric shock, can also lead to tendon injury. Emergency clinicians need to remain astute, so that they do not miss the diagnosis and delay proper treatment. If there is doubt regarding the diagnosis, ultrasound can help confirm the presence of an AT rupture.

The authors attest that their institution requires neither Institutional Review Board approval nor patient consent for publication of this case report. Documentation on file.

Address for Correspondence: Chia-Yuan Michael Lee, DO, Mount Sinai Medical Center, Department of Emergency Medicine, 4300 Alton Road, Miami Beach, FL 33140. Email: chia-yuan.michaellee@msmc.com.

Conflicts of Interest: By the CPC-EM article submission agreement, all authors are required to disclose all affiliations, funding sources and financial or management relationships that could be perceived as potential sources of bias. The authors disclosed none.

Copyright: © 2022 Lee. This is an open access article distributed in accordance with the terms of the Creative Commons Attribution (CC BY 4.0) License. See: <http://creativecommons.org/licenses/by/4.0/>

REFERENCES

1. Longo UG, Ronga M, Maffulli N. Acute ruptures of the Achilles tendon. *Sports Med Arthrosc.* 2009;17(2):127-38.
2. Park S-H, Lee HS, Young KW, et al. Treatment of acute Achilles tendon rupture. *Clin Orthop Surg.* 2020;12(1):1-8.
3. Lemme NJ, Li NY, DeFroda SF, et al. Epidemiology of Achilles tendon ruptures in the United States: athletic and nonathletic injuries from 2012 to 2016. *Orthop J Sports Med.* 2018;6(11):2325967118808238.
4. Hess GW. Achilles tendon rupture: a review of etiology, population, anatomy, risk factors, and injury prevention. *Foot Ankle Spec.* 2010;3(1):29-32.
5. Gravlee JR, Hatch RL, Galea AM. Achilles tendon rupture: a challenging diagnosis. *J Am Board Fam Pract.* 2000;13(5):371-3.
6. Ufberg J, Harrigan RA, Cruz T, et al. Orthopedic pitfalls in the ED: Achilles tendon rupture. *Am J Emerg Med.* 2004;22(7):596-600.
7. Järvinen TAH, Kannus P, Maffulli N, et al. Achilles tendon disorders: etiology and epidemiology. *Foot Ankle Clin.* 2005;10(2):255-66.
8. Gulati V, Jaggard M, Al-Nammari SS, et al. Management of Achilles tendon injury: a current concepts systematic review. *World J Orthop.* 2015;6(4):380-6.
9. Bhaskaran A and Dharmarajan R. Unusual mechanism of tendoachilles injury. *BMJ Case Rep.* 2010;2010:bcr0520103035.
10. Gentges J, Schieche C, Nusbaum J, et al. Points & pearls: electrical injuries in the emergency department: an evidence-based review. *Emerg Med Pract.* 2018;20(Suppl 11):1-2.
11. Zemaitis MR, Foris LA, Lopez RA, et al. (2021). Electrical injuries. In: *StatPearls.* Treasure Island, FL; StatPearls Publishing.
12. Yoo JH, Rhee SM, Shim HY, et al. Acute rotator cuff tears due to low voltage electrical injury: a case report. *Clin Shoulder Elb.* 2018;21(2):101-4.
13. Maffulli N. The clinical diagnosis of subcutaneous tear of the Achilles tendon. A prospective study in 174 patients. *Am J Sports Med.* 1998;26(2):266-70.
14. Dams OC, Reininga IHF, Gielen JL, et al. Imaging modalities in the diagnosis and monitoring of Achilles tendon ruptures: a systematic review. *Injury.* 2017;48(11):2383-99.
15. Ultrasound Guidelines: Emergency, point-of-care and clinical ultrasound guidelines in medicine. *Ann Emerg Med.* 2017;69(5):e27-e54.

To Drain or not to Drain? Point-of-care Ultrasound to Investigate an Axillary Mass: Case Report

Kishan Patel, BS*
Zara Khan, MD†
John Costumbrado, MD†

*University of California, Riverside School of Medicine, Riverside, California
†Riverside Community Hospital/University of California, Riverside, Department of
Emergency Medicine, Riverside, California

Section Editor: Rachel Lindor, MD, JD

Submission History: Submitted May 23, 2021; Revision received February 2, 2022; Accepted February 4, 2022

Electronically published April 18, 2022

Full text available through open access at http://escholarship.org/uc/uciem_cpem

DOI: 10.5811/cpcem.2022.2.53357

Introduction: Point-of-care ultrasound (POCUS) has great sensitivity in the diagnosis of abscesses and swollen lymph nodes. Many studies outline the characteristics that distinguish abscesses from lymph nodes on POCUS.

Case Report: We present a case from the emergency department in which a patient presented with a potential abscess but was found to have a malignant lymph node on imaging.

Conclusion: Point-of-care ultrasound can be used to differentiate an abscess from a swollen lymph node. Abscesses are generally anechoic or hypoechoic with septae, sediment or gas contents, and they lack internal vascularity. Benign lymph nodes are echogenic with hypoechoic cortex with hilar vascularity. [Clin Pract Cases Emerg Med. 2022;6(2):155–158.]

Keywords: *point-of-care ultrasound; POCUS; abscess; lymph node; case report.*

INTRODUCTION

Evaluation of abscesses versus enlarged lymph nodes is an important distinction to be made in the emergency department (ED) prior to performing incision and drainage in a patient who presents with a “lump.” Point-of-care ultrasound (POCUS) is a diagnostic tool that has been shown to have a greater sensitivity than physical exam alone to diagnose both abscesses and enlarged lymph nodes in the ED.^{1,2,3,4,5} Previous ED studies have shown that POCUS can allow clinicians to diagnose abscesses with significant accuracy and speed, often changing medical management as a result.^{6,7} Previous studies have also characterized distinctive qualities of abscesses and lymph nodes that can be used to confirm the presence of one as opposed to the other.^{4,5,7,8,9,10,11} From experiences in the ED with patient presentations requiring accurate identification of an abscess against a lymph node, we recognized that POCUS can play an instrumental role in the rapid detection and distinction between the two.

The echogenicity of abscess on sonography varies based on the characteristics of the abscess itself. However, a common distinguishing factor for all abscesses is the absence

of internal vascularity.^{3,12} Lymph nodes, on the other hand, typically display significant hilar vascularity, with malignant nodes having mixed or absent hilar vascularization.^{4,8} However, unlike the varied echogenicity of an abscess, lymph nodes are frequently small, oval, and hypoechoic in appearance.^{4,5} With an understanding of the common characteristics and qualities of both abscesses and lymph nodes, benign or metastatic, we believe POCUS can be used in conjunction with a thorough physical exam to guide medical management. We present a case in the ED where a patient presented with signs and symptoms of an abscess but instead was confirmed to have an enlarged lymph node, raising suspicion for underlying metastatic disease.

CASE REPORT

A 54-year-old female with a past medical history of kidney transplantation, hypertension, and mitral valve replacement presented to the ED for two days with a painful lump in her left axilla. She was seen at urgent care two days prior and prescribed oral clindamycin. The lump did not change in size after the antibiotic; she denied fevers or

discharge from the area. She had a prior history of a tooth abscess. A 10-point review of systems was otherwise negative. The patient stated she wished to have the “abscess” drained.

Her vitals were unremarkable. Her physical exam was significant for a firm lump in the left center axilla visible on inspection and palpation, three centimeters (cm) in diameter and at the site of the expected central axillary nodes. No erythema or active drainage was noted. Her laboratory findings were significant only for a normocytic anemia with hemoglobin of 9.6 grams per deciliter (g/dL) (reference range: 12.0-15.5 g/dL).

Despite the patient’s expressed concern that she had an abscess and that she was being treated with outpatient antibiotics, and requested that the suspected abscess be drained, we performed a point-of-care ultrasound (POCUS) because the physical exam findings did not obviously indicate an abscess. The POCUS findings were more consistent with a lymph node prompting further imaging studies, and no incision and drainage was performed (Image 1).

Computed tomography (CT) chest without intravenous (IV) contrast revealed an enlarged, left supraclavicular lymph node measuring 2.5 x 4.6 cm. In addition, a 1.5 x 2.4 x 2.3 cm soft tissue nodule with surrounding edema representing an enlarged lymph node with superimposed infection was found in the left axilla. We were unable to obtain a contrast study as the patient was refusing IV access at the time after discussing risks, benefits, and alternatives. Overall, the findings were suspicious for nodal metastases. A breast ultrasound found left breast hypoechoic mass at the two o’clock position, two cm from the nipple and 3.9 cm in size, along with an enlarged left axillary lymph node.

DISCUSSION

There is growing interest in using POCUS to identify abscess and lymph nodes in the ED. In this case, we present a report of a

CPC-EM Capsule

What do we already know about this clinical entity?

Point-of-care-ultrasound (POCUS) is used widely in emergency medicine to diagnose abscesses and lymph nodes.

What makes this presentation of disease reportable?

This report discusses a patient with a suspected abscess requesting drainage; however, POCUS results suggested an alternative diagnosis, which altered management.

What is the major learning point?

Point-of-care-ultrasound can be used to differentiate an abscess from a lymph node using specific sonographic features.

How might this improve emergency medicine practice?

Understanding the sonographic differences can allow immediate identification and influence management of lymph nodes or abscess in the emergency department.

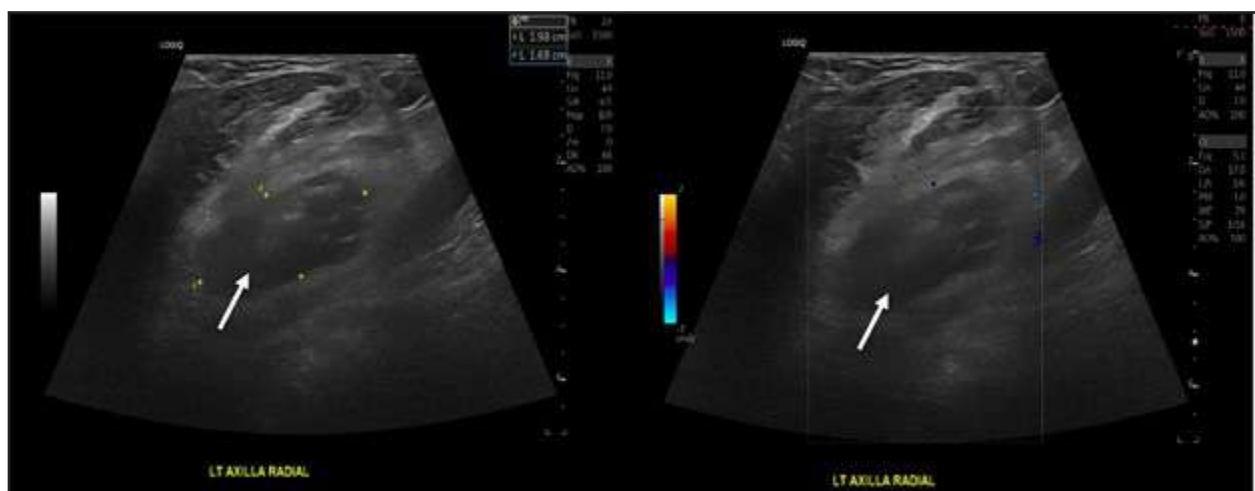


Image 1. (Left panel) White arrow indicates point-of-care ultrasound (POCUS) image of abnormal left axillary lymph node on B-mode. (Right panel) White arrow points to POCUS image of abnormal left axillary lymph node with no vascularity on color Doppler mode.

patient with a suspected abscess who was found to have evidence of possible metastatic disease on CT. Hence, it is crucial to identify the sonographic differences between an abscess and an enlarged lymph node as it can influence management.

Early ultrasound studies have shown that an abscess possesses several unique sonographic patterns.^{3,11} A well-formed abscess has been shown to appear as round, anechoic, or hypoechoic masses with posterior enhancement and septae, sediment, or gas contents.^{11,13} Most are also surrounded by some cellulitis or edema leading to a cobblestoning appearance near the fluid collection. Further, ultrasonic fluctuance is common where gentle pressure over the abscess leads to abscess contents swirling.^{11,13} Color Doppler often reveals a lack of internal vascularity – a common distinguishing characteristic of an abscess (Image 2).^{3,14}

Ultrasound elastography has also been found to distinguish the induration of an abscess from surrounding healthy tissue.¹³ With these characteristics, POCUS was found to have about 98% sensitivity with 69-88% specificity, much greater than a physical exam sensitivity of 78% and specificity of 66%.^{1,2} Studies have also looked at using sonographic patterns to identify benign and metastatic lymph nodes.^{4,5,8} Typical normal lymph nodes have been shown to be predominately small and oval, with an echogenic hilum with hypoechoic peripheral cortex, and demonstrate significant hilar vascularity (Image 3).^{4,5}

Malignant lymph nodes are commonly larger and rounded, with a loss of echogenic hilum; they appear more homogeneously hypoechoic and present with peripheral or mixed vascularity with loss of hilar vascularization.^{4,8} It is also imperative to apply clinical suspicion when looking at particular locations in the anatomy for lymph nodes compared to abscesses, as lymph nodes are readily identified at the axillary, mediastinal, mesenteric, inguinal, and femoral regions. As compared to abscesses, lymph nodes will not display posterior enhancement, will lack cobblestoning, will not display ultrasonic fluctuance, and will classically appear at expected locations unlike metastases.^{4,8} Although we focused on looking at an abscess compared to lymph nodes, ultrasound can be used to identify other anatomic structures as well, including nerves, vessels, and muscle.¹

CONCLUSION

Understanding the common sonographic features of abscesses and lymph nodes can allow immediate identification and medical management of the appropriate condition, as evidenced in this case where POCUS imaging changed the medical management of the patient. We suggest that the use of POCUS at bedside can be both a diagnostic tool to provide immediate data to guide distinction of an abscess from a lymph node as well as a tool to educate the patient by sharing and discussing the images at the bedside. Ultimately, this patient's non-contrast CT imaging was concerning for underlying malignancy. We did not discuss appropriate use

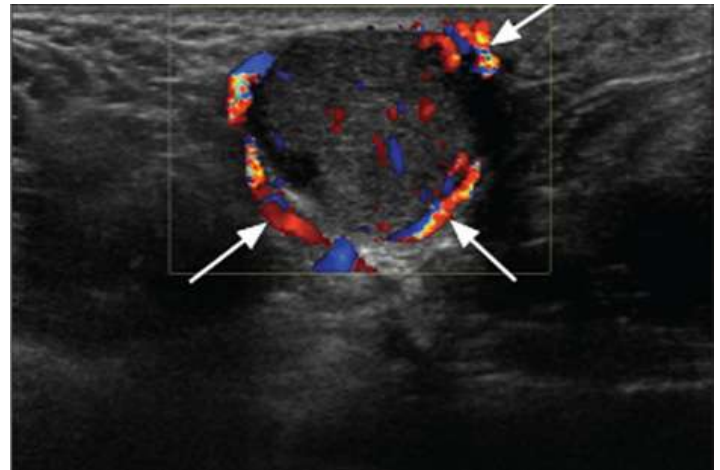


Image 2. White arrows indicate point-of-care-ultrasound color Doppler image of axillary abscess showing minimal central vascularity, increased peripheral vascularity, posterior acoustic enhancement, and round hypoechoic central contents of abscess.¹⁴

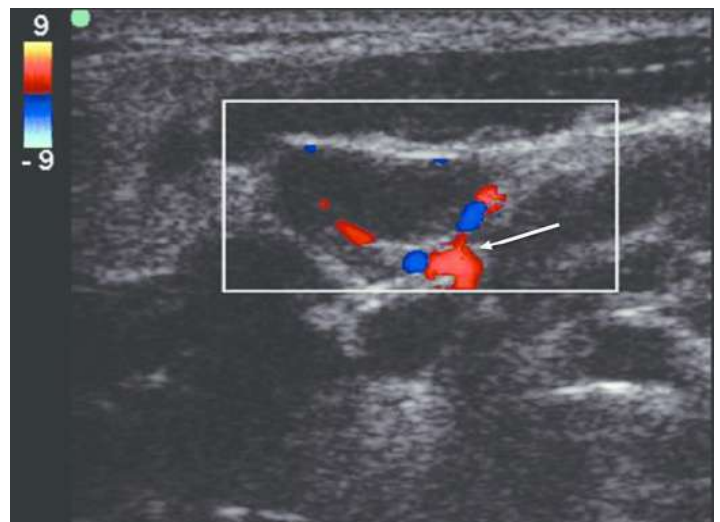


Image 3. White arrow points to point-of-care-ultrasound color Doppler image of benign cervical lymph node showing hilar/central vascularity.¹⁵

of CT imaging to confirm ultrasound findings. The patient was counselled on the findings and instructed that she would likely require a biopsy for confirmation. An incision and drainage was not performed, and the patient was otherwise in stable condition for discharge and had access to short-interval follow-up. Confirmation of the diagnosis is not available as the patient has not followed up with any of our hospital-affiliated clinics per medical records.

The authors attest that their institution requires neither Institutional Review Board approval nor patient consent for publication of this case report. Documentation on file.

Address for Correspondence: Kishan Patel, BS, University of California, Riverside, School of Medicine, 92521 Botanic Gardens Dr. Riverside, CA 92507. Email: kishanpatel7396@gmail.com

Conflicts of Interest: By the CPC-EM article submission agreement, all authors are required to disclose all affiliations, funding sources and financial or management relationships that could be perceived as potential sources of bias. The authors disclosed none. This research was supported (in whole or in part) by HCA Healthcare and/or an HCA Healthcare affiliated entity. The views expressed in this publication represent those of the author(s) and do not necessarily represent the official views of HCA Healthcare or any of its affiliated entities. This research has not been presented at any local or national meetings.

Copyright: © 2022 Patel. This is an open access article distributed in accordance with the terms of the Creative Commons Attribution (CC BY 4.0) License. See: <http://creativecommons.org/licenses/by/4.0/>

REFERENCES

- Iverson K, Haritos D, Thomas R, et al. The effect of bedside ultrasound on diagnosis and management of soft tissue infections in a pediatric ED. *Am J Emerg Med.* 2012;30(8):1347-51.
- Squire BT, Fox JC, Anderson C. ABSCESS: applied bedside sonography for convenient evaluation of superficial soft tissue infections. *Acad Emerg Med.* 2005;12(7):601-6.
- Adams CM, Neuman MI, Levy JA. Point-of-care ultrasonography for the diagnosis of pediatric soft tissue infection. *J Pediatr.* 2016;169:122-7.e1.
- Prativadi R, Dahiya N, Kamaya A, et al. Ultrasound characteristics of benign vs malignant cervical lymph nodes. *Semin Ultrasound CT MR.* 2017;38(5):506-15.
- Ying M, and Ahuja AT. Ultrasound of neck lymph nodes: How to do it and how do they look? *Radiography.* 2006;12(2):105-17.
- Tayal VS, Hasan N, Norton HJ, Tomaszewski CA. The effect of soft-tissue ultrasound on the management of cellulitis in the emergency department. *Acad Emerg Med.* 2006;13(4):384-8.
- Subramaniam S, Bober J, Chao J, et al. Point-of-care ultrasound for diagnosis of abscess in skin and soft tissue infections. *Acad Emerg Med.* 2016;23(11):1298-306.
- Cui XW, Jenssen C, Saftoiu A, et al. New ultrasound techniques for lymph node evaluation. *World J Gastroenterol.* 2013;19(30):4850-60.
- Loyer EM, DuBrow RA, David CL, et al. Imaging of superficial soft-tissue infections: sonographic findings in cases of cellulitis and abscess. *AJR Am J Roentgenol.* 1996;166(1):149-52.
- Nelson CE, Chen AE, Bellah RD, et al. Ultrasound features of purulent skin and soft tissue infection without abscess. *Emerg Radiol.* 2018;25(5):505-11.
- Marin JR, Dean AJ, Bilker WB, et al. Emergency ultrasound-assisted examination of skin and soft tissue infections in the pediatric emergency department. *Acad Emerg Med.* 2013;20(6):545-53.
- Chau CL and Griffith JF. Musculoskeletal infections: ultrasound appearances. *Clin Radiol.* 2005;60(2):149-159.
- Gaspari R, Blehar D, Mendoza M, et al. Use of ultrasound elastography for skin and subcutaneous abscesses. *J Ultrasound Med.* 2009;28(7):855-60.
- Misra D, Panjwani S, Rai S, et al. Diagnostic efficacy of color Doppler ultrasound in evaluation of cervical lymphadenopathy. *Dent Res J (Isfahan).* 2016;13(3):217-24.
- Park JE, Sohn YM, Kim EK. Sonographic findings of axillary masses: What can be imaged in this space? *J Ultrasound Med.* 2013;32(7):1261-70.

Case Report: Vertebral Artery Dissection After Use of Handheld Massage Gun

Kathryn Sulkowski, MD*
Georgina Grant, MD*
Thomas Brodie, MD†

*University of Nevada, Las Vegas, Emergency Medicine Residency Program, Las Vegas, Nevada
†Mike O'Callaghan Federal Medical Center, Department of Emergency Medicine, Las Vegas, Nevada

Section Editor: R. Wilkerson, MD

Submission History: Submitted January 10, 2022; Revision received February 9, 2022; Accepted February 10, 2022

Electronically published April 6, 2022

Full text available through open access at http://escholarship.org/uc/uciem_cpem

DOI: 10.5811/cpem.2022.2.56046

Introduction: Arterial dissection is well known as a potential cause of stroke in young patients. Vertebral artery dissection occurs most commonly in the setting of minor trauma but has been seen in cases of cervical manipulation. With advances in at-home therapeutic modalities for neck pain came the advent of handheld massage guns. These massage guns have gained considerable popularity in recent years, but their safety for use in the cervical region has not been well studied.

Case report: In this case report, we discuss a 27-year-old female who presented with headache, neck pain, and dizziness who was found to have vertebral artery dissection after repetitive use of a handheld massage gun.

Conclusion: In young patients presenting with headache, neck pain, and vague neurologic symptoms it is important to consider vertebral artery dissection as a cause of symptoms as it can lead to serious morbidity. When considering an inciting event such as minor trauma, it may also be important to assess whether there has been use of a handheld massage gun. Although causality is difficult to establish, with the increase in use of handheld massage guns we may find more frequent association between their use and vertebral artery dissection. [Clin Pract Cases Emerg Med. 2022;6(2):159-161.]

Keywords: *vertebral artery dissection; handheld massage gun.*

INTRODUCTION

The reported incidence of vertebral artery dissection (VAD) is estimated to be 2.6-3/100,000.¹ Vertebral artery dissection is a known cause of stroke in patients younger than 45 years of age. Unfortunately, because its clinical features and symptoms tend to be vague and/or nonspecific, diagnosis may not even be considered. Upon close review of the literature, we found very few cases reported of VAD secondary to neck massage and none related to the use of a handheld massage gun. Given the increase in popularity of at-home, handheld massage, the importance of safety while using these devices is of the utmost importance. In this report we describe a case of VAD in a young woman after the use of a handheld massage gun. She was treated with aspirin and discharged with no residual neurological deficits.

CASE REPORT

A 27-year-old female presented to the emergency department (ED) with a two-week history of progressively worsening dizziness. She described the dizziness as a combination of vertiginous symptoms as well as disequilibrium. Over the prior four days she noticed a headache and neck pain. She denied any recent trauma but had recently begun using a handheld massage gun on her neck over the preceding three weeks. The patient denied any past medical history and used no medications regularly, except for occasional over-the-counter ibuprofen, which did not alleviate her symptoms. She had a family history significant for migraine headaches. She endorsed occasional alcohol and daily tobacco use but denied any illicit substance use. She denied fever, diplopia, blurry vision,

photophobia, phonophobia, or vomiting but endorsed mild associated nausea.

Physical examination revealed a young female resting comfortably. Vital signs were all within normal limits. On examination, she demonstrated full range of motion of the neck without pain. She had no audible carotid bruit, no notable swelling, ecchymosis, or midline cervical spinal tenderness to palpation. On a detailed neurologic examination, the patient had a Glasgow Coma Scale of 15 and was alert and oriented to person, place, and time. She had a normal cranial nerve exam, full strength in the upper and lower extremities, normal reflexes, and no ataxia. She had a negative Romberg test and normal, rapid alternating movement testing and finger-to-nose testing.

Initial diagnostic evaluation demonstrated a normal complete blood count. Comprehensive metabolic panel demonstrated no abnormalities, and all electrolytes were within normal limits. Beta human chorionic gonadotropin was undetectable. She was administered 25 milligrams (mg) meclizine orally, 1000 mg acetaminophen intravenously, 10 mg prochlorperazine intravenously, and a one-liter bolus of lactated Ringer's solution for her symptoms.

Because the patient had prolonged symptoms and endorsed a history of massage gun use, both a computed tomography (CT) without contrast of the head and a CT angiogram (CTA) with intravenous contrast of the head and neck were obtained. The CT of the head without contrast demonstrated no notable abnormalities. The CTA of the head and neck revealed a long segment of irregular stenosis of the right vertebral artery extending from the second to the fifth cervical vertebra, most compatible with a vertebral artery dissection (VAD).

The patient was administered 324 mg aspirin orally and was transferred and admitted overnight to a tertiary accepting center with vascular surgery capability. Vascular surgery was consulted and recommended non-operative management and suggested consultation with interventional radiology. Interventional radiology was consulted and recommended continuing aspirin, and admission for observation with neurological checks every four hours. The patient was neurologically stable during the admission and was discharged with prescriptions for 324 mg aspirin orally daily as well as 25 mg meclizine orally as needed. She was given follow-up with neuro-interventional radiology in two weeks as an outpatient. The patient did not re-present to our hospital for follow-up.

DISCUSSION

Dissection of the vertebral arteries related to handheld massage devices is not well documented, and we found no case reports in the literature of handheld massage devices potentially leading to VAD. When considering the anatomy of the extracranial vertebral artery, it is susceptible to dissection in three segments: its origin at the subclavian artery; as it traverses the intervertebral foramen; or at the site of entry into the cranium.² Neurologic sequelae of VAD vary widely based on the location of the dissection and the amount of ischemic

CPC-EM Capsule

What do we already know about this clinical entity?

Arterial dissection is a potential cause of stroke in young patients. Vertebral artery dissection (VAD) usually occurs with minor trauma but has been seen with cervical manipulation.

What makes this presentation of disease reportable?

We could find no prior reported cases of VAD associated with use of a handheld massage gun.

What is the major learning point?

In young patients presenting with headache, neck pain, and vague neurologic symptoms, it is important to consider VAD as a cause of symptoms.

How might this improve emergency medicine practice?

Given the rising popularity of handheld massage guns, emergency physicians should be aware of the evaluation and management of VAD.

damage to the posterior circulation territory (cerebellum, brainstem, and posterior cerebrum). Early identification of VAD is crucial to improving outcomes; thus, it is imperative to maintain a high index of suspicion.

Headache, neck pain, and dizziness are very common chief complaints that are evaluated in the ED and outpatient clinics. The clinician must make a distinction between patients who have benign conditions and patients with life-threatening conditions. Much of this determination rests upon clinical suspicion based on a patient's history as well as the use of imaging modalities.

Handheld massage guns have risen in popularity and become more accessible to the everyday user. There are many new handheld massage guns on the market, ranging in price from \$50 to over \$1000 for higher end models.⁴ Most of these devices rely on percussive motion (low amplitude, high frequency) to relieve tension in muscles. On many models, pulses per minute can be adjusted. While most user instruction manuals caution against holding the device in one place or using the device on the neck, they do advertise its use on the posterior neck, trapezius, and shoulder muscles.

Unfortunately, despite the increase of popularity, proper use is not clearly demonstrated. In website image searches for these devices, many ads show models using the device around the upper and lateral neck as well as on more anterior

muscle tissues. Users with either no background in medicine or knowledge of the underlying anatomy may not realize the significance of the vasculature beneath these tissues and how they may be damaged with the use of handheld massage guns. While the patient in our case did not suffer any long-lasting deficits, this may not always be the case. If handheld massage guns pose a risk when used in improper locations, consumers must be made aware of these potential consequences.

Management options for VAD are varied and based on numerous factors such as presentation, time of onset, and imaging results. Options include antiplatelet or anticoagulation medications, endovascular management, or vascular surgery.³ In patients with severe deficits, reperfusion therapy is an option to more immediately restore blood flow to areas of the brain that can be salvaged. These options include alteplase, tenecteplase, or mechanical thrombectomy. These therapies are not without risk as they have the potential to increase the size of the intramural hematoma. These therapeutic modalities have been studied much more thoroughly in cases of cervical artery dissections with minimal literature to support their use in cases of VAD.^{5,6,7}

Anticoagulation or antiplatelet therapy is more widely used for VAD.^{8,9} Medically stable patients, like our patient, can be started on low molecular weight heparin, direct oral anticoagulants or antiplatelet therapy based on the ABCD2 score, similar to the risk stratification performed on other transient ischemic attack/stroke patients. Those deemed low risk by the ABCD2 score are started on 324 mg of aspirin daily, whereas high-risk patients are placed on dual antiplatelet therapy with both aspirin and clopidogrel.¹⁰ Most cases of nontraumatic VAD are shown to heal within the first few months of the inciting event. In one study of patients with VAD, 62% of cases showed complete healing of the dissection at six months.¹¹

CONCLUSION

We report the case of a 27-year-old female who presented with two weeks of worsening dizziness and four days of neck pain who had recently used a handheld massage device and was subsequently found to have vertebral artery dissection. Although rare, VAD is a known cause of stroke, particularly in young patients. In this patient population with presenting symptoms of dizziness, headache, and/or neck pain it is important to consider VAD as early diagnosis is imperative in improving outcomes. It is also crucial to take a complete social history to determine whether there were any provoking factors, such as the use of a handheld massage device. Treatment with antiplatelet or anticoagulation may be appropriate in the correct patient population.

With the rise in popularity of handheld massage guns, more research must be performed in evaluating their safety. Although causality is difficult to establish, we may find an increase in incidence of VAD as popularity of these devices continues to rise. In some circumstances we may ultimately discover that the use of handheld massage guns may be implicated as a cause of VAD.

The Institutional Review Board approval has been documented and filed for publication of this case report.

Address for Correspondence: Kathryn Sulkowski, MD, University of Nevada, Las Vegas, Emergency Medicine Residency Program, 901 Rancho Lane, STE 135, Las Vegas, NV 89106. Email: kathryn.sulkowski@unlv.edu.

Conflicts of Interest: By the CPC-EM article submission agreement, all authors are required to disclose all affiliations, funding sources and financial or management relationships that could be perceived as potential sources of bias. The authors disclosed none.

Copyright: © 2022 Sulkowski. This is an open access article distributed in accordance with the terms of the Creative Commons Attribution (CC BY 4.0) License. See: <http://creativecommons.org/licenses/by/4.0/>

REFERENCES

1. Finley A, Rogers B, Richards T Jr, et al. Postpartum vertebral artery dissection. *BMJ Case Rep.* 2015;2015:bcr2015211872.
2. Dutta G, Jagetia A, Srivastava AK, et al. "Crick" in neck followed by massage led to stroke: uncommon case of vertebral artery dissection. *World Neurosurg.* 2018;115:41-43.
3. Gomez-Rojas O, Hafeez A, Gandhi N, et al. Bilateral vertebral artery dissection: a case report with literature review. *Case Rep Med.* 2020;2020:8180926.
4. Perez, O. Premium massage guns in 2021: *Sports Illustrated* reviews. 2021. Available at: <https://www.si.com/review/best-massage-gun/>. Accessed December 1, 2021
5. Zinkstok SM, Vergouwen MD, Engelter ST, et al. Safety and functional outcome of thrombolysis in dissection-related ischemic stroke: a meta-analysis of individual patient data. *Stroke.* 2011;42(9):2515-2520.
6. Bernardo F, Nannoni S, Strambo D, et al. Intravenous thrombolysis in acute ischemic stroke due to intracranial artery dissection: a single-center case series and a review of literature. *J Thromb Thrombolysis.* 2019;48(4):679-84.
7. Hoving JW, Marquering HA, Majoie CBLM. Endovascular treatment in patients with carotid artery dissection and intracranial occlusion: a systematic review. *Neuroradiology.* 2017;59(7):641-7.
8. CADISS trial investigators, Markus HS, Hayter E, et al. Antiplatelet treatment compared with anticoagulation treatment for cervical artery dissection (CADISS): a randomised trial. *Lancet Neurol.* 2015;14(4):361-7.
9. Markus HS, Levi C, King A, et al. Cervical Artery Dissection in Stroke Study (CADISS) investigators. Antiplatelet therapy vs anticoagulation therapy in cervical artery dissection: the Cervical Artery Dissection in Stroke Study (CADISS) randomized clinical trial final results. *JAMA Neurol.* 2019;76(6):657-64.
10. Johnston SC, Rothwell PM, Nguyen-Huynh MN, et al. Validation and refinement of scores to predict very early stroke risk after transient ischaemic attack. *Lancet.* 2007;369(9558):283-92.
11. Arauz A, Márquez JM, Artigas C, et al. Recanalization of vertebral artery dissection. *Stroke.* 2010;41(4):717-21.

Newly Diagnosed Multiple Sclerosis Presenting as Brown-Séquier Syndrome: A Case Report

Shelby Hoebee, MD*
Levi Howard, DO†
James Komara, DO†
Megan McElhinny, MD*,†

*Creighton University Arizona Health Education Alliance, Valleywise Health, Department of Emergency Medicine, Phoenix, Arizona
†Mayo Clinic Arizona, Department of Emergency Medicine, Phoenix, Arizona

Section Editor: Jacqueline Le, MD

Submission History: Submitted November 7, 2021; Revision received February 10, 2022; Accepted February 10, 2022

Electronically published May 6, 2022

Full text available through open access at http://escholarship.org/uc/uciem_cpem

DOI: 10.5811/cpem.2022.2.55317

Introduction: Brown-Séquier syndrome is a rare neurological disorder due to hemisection of the spinal cord that can occur from a variety of causes, most commonly trauma.

Case Report: We present a case of a 25-year-old woman presenting with Brown-Séquier syndrome as her first clinical presentation of multiple sclerosis.

Conclusion: This case highlights the need to have demyelinating disease on the differential as an exceedingly rare, but important, possible cause of Brown-Séquier syndrome. [Clin Pract Cases Emerg Med. 2022;6(2):162-165.]

Keywords: *Brown-Séquier syndrome; case report; multiple sclerosis.*

INTRODUCTION

Brown-Séquier syndrome (BSS) is a neurological disorder caused by hemisection of the spinal cord. It is characterized by ipsilateral upper motor neuron motor weakness below the level of lesion, lower motor neuron type at the level of lesion, and loss of ipsilateral proprioception with contralateral loss of pain and temperature sensations below the level of lesion.¹ The syndrome was first described by Charles-Édouard Brown-Séquier in 1849 through his experiments with animal models.² Most commonly, BSS is caused by trauma such as stab wounds and is occasionally caused by tumors, with lesser known causes including degenerative diseases, infection, and ischemia.³

Brown-Séquier syndrome is considered an incomplete spinal cord injury. Hemisection of the spinal cord resulting in classic presentation is much more rare than partial hemisection.⁴ Therefore, clinical presentation of BSS can range from mild to severe neurological deficits depending on the degree of hemisection. We report a case of an undiagnosed multiple sclerosis in a 25-year-old female that presented with BSS.

CASE REPORT

A 25-year-old, right-hand dominant, White female with no significant past medical history presented to the emergency department with complaints of one week of right lower extremity numbness from her toes to her hip and three days of left lower extremity weakness. The patient's weakness had been progressively getting worse to the point of using crutches because she was unable to pick up her left foot. She stated that she fell from standing height onto her left side, landing on a fully inflated air mattress while playing with her daughter three days before her numbness started, but reported no other traumatic injuries. She stated that the fall was minor and she didn't think much of it. She stated that she went to a chiropractor two days after developing the right leg numbness without any significant improvement or worsening of her symptoms. The patient denied fevers, chill, facial weakness, numbness or paresthesias in upper extremities, difficulty swallowing, changes in speech, or visual symptoms.

On examination, the patient was alert and oriented to person, place, time, and situation. She was conversant, and her speech production and comprehension as well as cranial nerves were all normal. Visual fields were fully intact with no

evidence of nystagmus or extraocular muscle weakness. Motor exam revealed complete, symmetrical strength, reflexes, and sensation in bilateral upper extremities. Lower extremity exam was significant for 3/5 strength in left hip flexion, 4/5 in left knee extension, 3/5 strength in left foot dorsiflexion, and 5/5 strength in left plantarflexion. The right leg showed full 5/5 strength in the previously mentioned muscle groups.

Following these exam findings, neurology was consulted with confirmation of the above findings as well as additional sensory deficits. Their exam showed right lower extremity with decreased pinprick and temperature sensation up to the thoracic (T) 11- T12 dermatomes. Left lower extremity had diminished proprioception and vibration with dysesthesia from the mid-shin down, but she was able to feel temperature and pinprick. The patient had sustained clonus at the left patella with 6-7 beats on the right patella. Ankle jerk was normal and symmetric. Babinski reflex was equivocal with significant withdrawal and negative Hoffman sign. Coordination was intact.

A magnetic resonance imaging (MRI) of the patient's brain, cervical, thoracic, and lumbar spine was completed to evaluate for the cause. Imaging showed multifocal areas of T2 hyperintensity throughout the spine with contrast enhancement, suspicious for a demyelinating or inflammatory disease without space-occupying lesions. The patient had large regions of active demyelination in the mid and lower cervical spine with nearly all levels involved. Although greatest areas of demyelination spanned from the fifth to seventh cervical vertebrae, these areas were asymptomatic (Image 1). Magnetic resonance imaging of the head showed periventricular, juxtacortical, and infratentorial enhancing lesions, typical of multiple sclerosis (Image 2).

Axial T2-weighted MRI images showed high signal intensity hemisecting the spinal cord at a level of the first lumbar vertebra, likely leading to her symptoms of BSS (Image 3). Following the above findings, a diagnosis of Brown-Séquad syndrome was made and the patient was admitted for further workup as to the etiology of her neurologic deficits. Upon admission, the patient received further laboratory studies including workup for tuberculosis, John Cunningham virus, human immunodeficiency virus, extractable nuclear antigen antibody, antinuclear antibody, hepatitis C, neuromyelitis optica (NMO), hepatitis B, autoimmune encephalopathy, and kappa free light chains, all of which were within normal limits. The patient's lumbar puncture revealed a lymphocytic pleocytosis.

As treatment, the patient received one gram of intravenous (IV) methylprednisolone for seven days with near complete recovery of strength by day three. She was discharged with mild residual numbness, but otherwise had a complete recovery. She was placed on outpatient IV ocrelizumab every six months as a disease-modifying agent.

DISCUSSION

Brown-Séquad syndrome is caused by damage to the ipsilateral corticospinal tracts and dorsal column as well as the contralateral spinothalamic tract. This results in the

CPC-EM Capsule

What do we already know about this clinical entity?

Brown-Séquad syndrome is caused by hemisection of the cord and characterized by a unique distribution of upper and lower motor neurons symptoms.

What makes this presentation of disease reportable?

This is a reportable presentation because it is an extremely rare etiology of Brown-Séquad.

What is the major learning point?

It is important to keep demyelinating disorders on the differential as a potential cause of Brown-Séquad.

How might this improve emergency medicine practice?

Recognizing multiple sclerosis as the cause of Brown-Séquad can change management and highlight the need for a broad differential even in rare presentations.

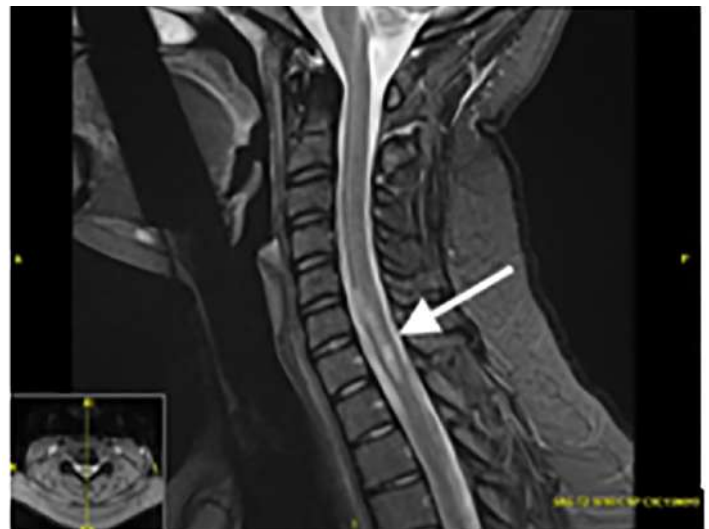


Image 1. Sagittal T2-weighted magnetic resonance imaging with asymptomatic hyperintensity within the cervical spine, worse at cervical level 5-7 (arrow).

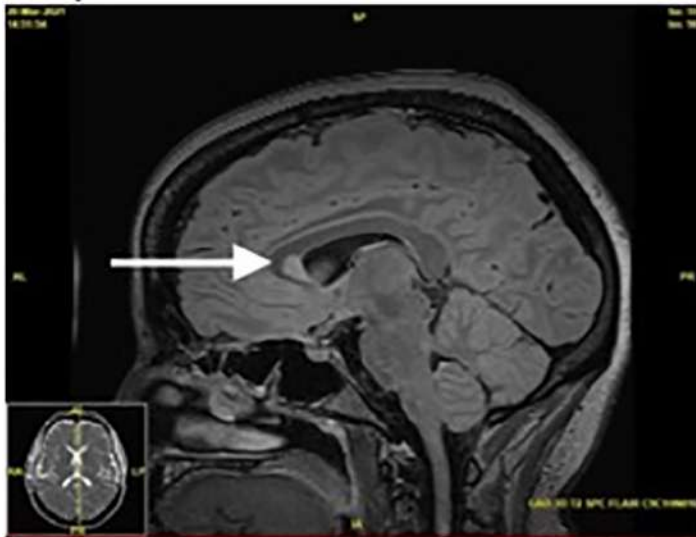

Image 2. Sagittal T2-weighted magnetic resonance imaging showing periventricular hyperintensity characteristic of multiple sclerosis.

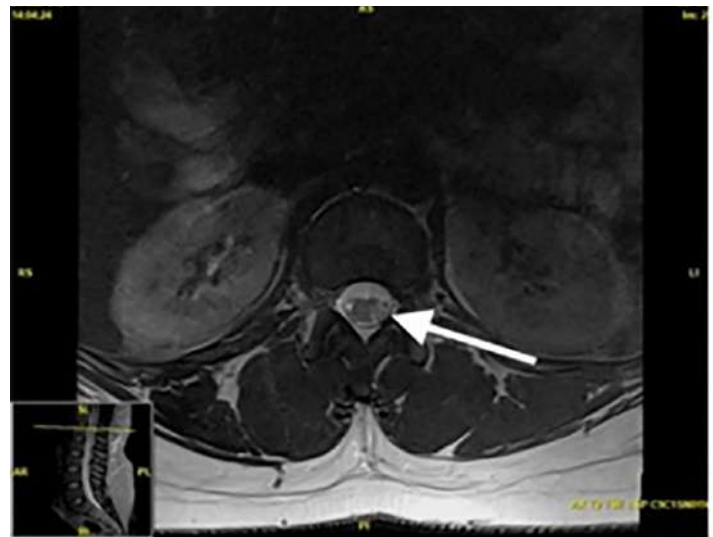

Image 3. Axial T2-weighted magnetic resonance imaging showing a high signal intensity within the left spinal cord at the level of the first lumbar vertebra (arrow).

ipsilateral loss of strength and proprioception as well as contralateral loss of temperature and pinprick sensation.⁵ Most commonly, patients present with a partial BSS due to a partial hemisection; pure BSS is extremely rare.

Our patient presented with a subacute onset of symptoms that were suggestive of BSS, and she was later confirmed to have a spinal cord lesion causing hemisection. Aside from the minor fall the patient had described, there was no other evidence or history of significant trauma. The symptoms of acute BSS typically occur immediately following traumatic injuries.⁶ Therefore, the patient's fall was likely coincidental in timing and largely unrelated to the development of her symptoms. Imaging ruled out etiologies such as cervical disc herniation, epidural hematoma, or syringomyelia as a cause. Lesser known causes such as NMO or infection were ruled out through negative blood and cerebrospinal fluid (CSF) studies. Given the patient's classic findings of multiple sclerosis (MS) on both her head and spinal MRIs, steroids were started. This treatment resulted in significant resolution of her symptoms, confirming our suspicion of MS.

Multiple sclerosis is an autoimmune, chronic inflammatory disorder that predominately affects White females aged 20–40 with symptoms varying in involvement of sensory, motor, visual, and brainstem pathways.⁷ The diagnosis of MS is clinical, but supportive evidence can be found through modalities such as MRI or CSF analysis. Multiple sclerosis is diagnosed by at least two typical attacks or by a single typical demyelinating event combined with evidence of dissemination in space or time by MRI.⁷ Dissemination in space (DIS) is defined as one demyelinating lesion in at least two of four areas (periventricular, juxtacortical, infratentorial, and spinal). Dissemination in time (DIT), on the other hand, is defined as simultaneous presence of asymptomatic gadolinium-enhancing

and non-enhancing lesions at any time.⁷ Although it was our patient's first known attack of MS, she had evidence of both DIT and DIS lesions on her MRI.

Upon reviewing the literature, we found that MS is one of the rarest known causes of BSS with very few case reports in existence.^{1,8,9,10} The exact incidence of BSS due to MS could not be found, likely secondary to its relative rarity. Occasionally, BSS presents as a complication in a patient with known MS,¹¹ but BSS as an initial presentation is even more rare.

CONCLUSION

Our patient presented with Brown-Séquard Syndrome as her first and only presentation of a new diagnosis of multiple sclerosis. We report this case due to the rarity of presentation and to record that a demyelinating disorder can initially present as an atypical neurological condition such as Brown-Séquard syndrome.

The authors attest that their institution requires neither Institutional Review Board approval nor patient consent for publication of this case report. Documentation on file.

Address for Correspondence: Shelby Hoebee, MD, Valleywise Medical Center, Department of Emergency Medicine, 2601 E. Roosevelt St., Phoenix, AZ 85008 Email: sho44447@creighton.edu.
Conflicts of Interest: By the CPC-EM article submission agreement, all authors are required to disclose all affiliations, funding sources and financial or management relationships that could be perceived as potential sources of bias. The authors disclosed none.

Copyright: © 2022 Hoebee. This is an open access article distributed in accordance with the terms of the Creative Commons Attribution (CC BY 4.0) License. See: <http://creativecommons.org/licenses/by/4.0/>

REFERENCES

1. Ralot TK, Singh R, Bafna C, et al. Brown-Séquard syndrome as a first presentation of multiple sclerosis. *Malays J Med Sci.* 2017;24(4):106-10.
2. Shams S and Arain A. Brown Séquard Syndrome. 2020. Available at: <https://www.ncbi.nlm.nih.gov/books/NBK538135/>. Accessed October 10, 2021.
3. Kobayashi N, Asamoto S, Doi H, et al. Brown-Séquard syndrome produced by cervical disc herniation: report of two cases and review of the literature. *Spine J.* 2003;3(6):530-3.
4. Mastronardi L and Ruggeri A. Cervical disc herniation producing Brown-Séquard syndrome: case report. *Spine (Phila Pa 1976).* 2004;29(2):E28-E31.
5. Shen CC, Wang YC, Yang DY, et al. Brown-Séquard syndrome associated with Horner's syndrome in cervical epidural hematoma. *Spine (Phila Pa 1976).* 1995;20(2):244-7.
6. Sato M, Kuriyama A, Ohtomo R. Unilateral loss of thoracic motion after blunt trauma: a sign of acute Brown-Séquard syndrome. *Clin Exp Emerg Med.* 2019;6(3):268-71.
7. Yamout BI and Alroughani R. Multiple sclerosis. *Semin Neurol.* 2018;38(2):212-25.
8. Sinha MK, Malhotra HS, Agarwal V, et al. Brown-Séquard syndrome produced by hemicord myelitis: a case report. *Ann Neurosci.* 2008;15(1):25-6.
9. Kraus JA, Stüper BK, Berlit P. Multiple sclerosis presenting with a Brown-Séquard syndrome. *J Neurol Sci.* 1998;156(1):112-3.
10. Ozaki I, Suzuki C, Baba M, et al. Multiple sclerosis manifesting as a Brown-Séquard syndrome. *Eur J Neurol.* 2003;10(2):190-1.
11. Koehler PJ and Endtz LJ. The Brown-Séquard syndrome. True or false? *Arch Neurol.* 1986;43(9):921-4.

Weakness After an Intra-articular Steroid Injection: A Case Report of Acute Steroid-induced Myopathy

Matthew R. Jordan, MD*

Lauren A. Hensley, DO†

Michael L. Jackson, DO‡

*Navy Medicine Readiness and Training Command, Department of Emergency Medicine, Camp Lejeune, North Carolina

†Navy Medicine Readiness and Training Command, Department of Internal Medicine, Portsmouth, Virginia

‡Navy Medicine Readiness and Training Command, Department of Emergency Medicine, Portsmouth, Virginia

Section Editor: Steven Walsh, MD

Submission History: Submitted January 3, 2022; Revision received February 17, 2022; Accepted February 21, 2022

Electronically published April 25, 2022

Full text available through open access at http://escholarship.org/uc/uciem_cpem

DOI: 10.5811/cpcem.2022.2.55995

Introduction: Weakness is a common chief complaint in the emergency department, and the use of glucocorticoids is pervasive in medicine. Muscle weakness, or myopathy, is a well documented side effect of chronic glucocorticoid use. However, acute myopathy, with an onset shortly after initiation of glucocorticoids, is much rarer.

Case Report: We present a case of acute steroid-induced myopathy after a single intra-articular dose of triamcinolone in a young, healthy, active male. To our knowledge, this is the first case described in the medical literature of acute steroid-induced myopathy following a single intra-articular injection.

Conclusion: In a patient who presents with proximal muscle weakness and has a history of glucocorticoid use, the diagnosis of steroid-induced myopathy should be considered. Acute steroid-induced myopathy should be high on the differential in a patient who presents with typical symptoms and has been prescribed glucocorticoids for less than 14 days or, in rare cases, may have recently received a single dose of glucocorticoids. Treatment is supportive and outpatient management is typically indicated, as respiratory muscle involvement is rare. [Clin Pract Cases Emerg Med. 2022;6(2):166-168.]

Keywords: *myopathy; steroid; glucocorticoids; intraarticular; case report.*

INTRODUCTION

The differential diagnosis of muscle weakness, or myopathy, is very wide. The use of glucocorticoids has been associated with myopathy, typically occurring in patients with long-term oral steroid use. Acute steroid-induced myopathy, developing within 14 days of initiation of glucocorticoids in ambulatory patients, is poorly recognized and rare, with less than 20 cases documented in the literature.¹ This case report details a presentation of acute steroid-induced myopathy. To our knowledge, it is the first case described in the medical literature following a one-time intra-articular injection.

CASE REPORT

A 39-year-old male with a history of osteoarthritis, on as-needed non-steroidal anti-inflammatories, presented to the emergency department (ED) around 3 AM with acute onset of bilateral lower extremity proximal muscle weakness. The patient reported going to bed that evening without any issue and awoke around 2 AM to go to the bathroom, which was not unusual for him. However, he noticed profound weakness of the lower extremities. He could not flex at the hips and was unable to swing his legs out of bed. Eventually the patient was able to pull himself out of bed and slowly guide himself to the bathroom, noting continued severe weakness in his lower

extremities. He also noted lacking the usual shoulder strength to wipe himself after using the bathroom. Approximately 18 hours prior to presentation to the ED, he had undergone a fluoroscopy-guided, intra-articular steroid injection of his right shoulder. The injection consisted of 7 milliliters (mL) of triamcinolone/ropivacaine mixture containing 2 mL of triamcinolone 40 milligrams per milliliter (mg/mL) (total of 80 mg of triamcinolone) and 5 mL of ropivacaine 0.75%. The procedure was uncomplicated, and he reported a 1/10 pain level post-procedure, down from 5/10 pre-procedure.

Upon presentation to the ED, he was well appearing, well nourished, and in no acute distress. He was afebrile and vital signs were as follows: heart rate 110 beats per minute; blood pressure 140/80 millimeters of mercury (mm Hg); respiratory rate 20 breaths per minute; oxygen saturation 98%; and temperature 97.5°F. Neurologic exam revealed 5/5 strength in his bilateral upper extremities, as well as at the knees and ankles bilaterally. However, he possessed only 3+/5 flexion strength of the bilateral hips. Patellar and Achilles reflexes were 2+ bilaterally. Vibratory sense was intact in both feet. Rectal tone was normal. The rest of his physical exam was unremarkable.

A differential diagnosis was formulated to include stroke, spinal compression syndrome, Guillain-Barré syndrome, rhabdomyolysis, electrolyte derangement, including hypokalemic periodic paralysis, transverse myelitis, myositis, and myopathy.

Emergency department diagnostics included a complete blood count, complete metabolic panel, creatine kinase (CK), erythrocyte sedimentation rate, and C-reactive protein level, all of which were within the reference ranges. Peak flow was 500 liters per minute (L/min) (normal range 300-660 L/min), and post-void residual volume on point-of-care ultrasound was 70 mL (normal <200 mL). Urinalysis showed greater than 500 mg/dL glucose (reference range negative), trace ketones (reference range negative), and small protein (reference range negative). Given the patient's history of glucocorticoid use, exam with decreased hip flexion strength, reassuring lab work, peak flow, and post-void residual, a diagnosis of acute steroid-induced myopathy was made.

The internal medicine team was consulted to evaluate the patient in the ED. They agreed with the diagnosis of acute steroid-induced myopathy. The patient reported some improvement in his strength while in the ED, although not back to baseline, but he was able to ambulate. Neurology was consulted by the internal medicine team. Given his improvement in the ED, it was recommended by neurology that the patient follow up as an outpatient. The patient was discharged from the ED and followed up in the neurology clinic three days later. At that time, he reported complete resolution of his symptoms about 48 hours after presentation to the ED without residual deficits. Neurology ultimately diagnosed him with a transient myopathy and recommended that he avoid intra-articular glucocorticoid injections in the future.

CPC-EM Capsule

What do we already know about this clinical entity?

Weakness, or myopathy, is a well documented side effect of chronic glucocorticoid use. Myopathy in the acute setting of glucocorticoid use is much rarer.

What makes this presentation of disease reportable?

This case report describes the first case in the medical literature of acute steroid-induced myopathy after a single intra-articular injection.

What is the major learning point?

In a patient with muscle weakness who has been on glucocorticoids, either single dose or long term, the diagnosis of steroid-induced myopathy must be considered.

How might this improve emergency medicine practice?

The diagnosis should be considered in the correct clinical picture. Myopathy should also be considered as a potential side effect of short-dose glucocorticoid use.

DISCUSSION

Weakness is a common presenting symptom in the ED. Due to its vague nature, it encompasses complaints ranging from generalized malaise to focal motor weakness and in severity from routine to emergent. This case details a presentation of weakness ultimately diagnosed as acute steroid-induced myopathy. This is a rare syndrome characterized by development of muscle weakness, most commonly affecting the proximal large muscle groups, within 14 days of initiation of glucocorticoids. Pelvic girdle and proximal lower extremity muscles are typically more severely involved than the upper extremities with sparing of the cranial nerves and sphincters. Rarely, the respiratory and/or distal muscles can be affected.^{1,2} Acute steroid-induced myopathy is rarer than a myopathy developing in patients on long-term glucocorticoids or in those admitted to critical care units on high-dose intravenous (IV) glucocorticoids.

Acute steroid-induced myopathy is highly unpredictable and should be considered in any patient with muscle weakness previously treated with glucocorticoids regardless of dose, route of administration, or duration of treatment. A previous case report detailed two patients who developed symptoms

within hours of steroid administration.¹ This same case report also reviewed all known case reports of acute steroid-induced myopathy in the literature, totaling 16 cases. The routes of administration were oral (eight cases), IV (five cases), and intramuscular, epidural, and intranasal (each with one case). No cases were intra-articular. Dosing was highly variable with one patient developing symptoms after a single dose of 40 mg of oral prednisone, while another was administered 1000 mg of IV hydrocortisone for 10 days before developing symptoms. Time to myopathy onset was between one hour and four weeks. Most made a full recovery over weeks to months. A single case of triamcinolone-induced acute steroid myopathy from an epidural injection has also previously been reported.³

Symptoms tend to occur more often with the fluorinated glucocorticoids, such as dexamethasone, triamcinolone, and betamethasone.⁴ Serum levels of muscle-associated enzymes such as CK and lactate dehydrogenase are usually normal. Electromyography is also typically normal, especially in the early phase of disease. Muscle biopsy tends to be non-specific, making acute steroid-induced myopathy a clinical diagnosis.^{1,2} A high index of suspicion is required to make the diagnosis.

Clinical improvement is expected over weeks to months with cessation of steroids or changing to non-fluorinated glucocorticoids, such as prednisone. Treatment is otherwise supportive.

In the rare case of respiratory muscle involvement, the patient should be admitted to a monitored unit for close airway observation. Otherwise, ED disposition centers around the patient's functional ability. A physical therapy and occupational therapy evaluation may be appropriate. If being discharged, patients should have close follow up with neurology. Additionally, the patient should follow up with the physician prescribing his glucocorticoids. This clinician will need to reevaluate the need for glucocorticoids with the patient and discuss risks of continuing. Patients presenting with weakness who are prescribed short-burst dose glucocorticoids or who present after a single dose of glucocorticoid should be counseled to avoid further doses, if feasible, pending completion of appropriate follow-up medical care.

CONCLUSION

In a patient who has received glucocorticoids and presents with muscle weakness, the diagnosis of steroid-induced myopathy should be considered. Glucocorticoid use can be of any duration, from chronic use to even a single dose. The

associated muscle weakness tends to affect the proximal muscles, especially in the lower extremities. Therefore, acute steroid-induced myopathy should be considered in the differential of a patient presenting with proximal muscle weakness within 14 days of initiation of glucocorticoids. To our knowledge, this is the first case in the literature of an onset of acute steroid-induced myopathy following a single intra-articular injection.

The authors attest that their institution requires neither Institutional Review Board approval nor patient consent for publication of this case report. Documentation on file.

Address for Correspondence: Matthew R. Jordan, MD, Navy Medicine Readiness and Training Command, Department of Emergency Medicine, 100 Brewster Blvd., Camp Lejeune, NC 28547. Email: matthew.r.jordanmd@gmail.com

Conflicts of Interest: By the CPC-EM article submission agreement, all authors are required to disclose all affiliations, funding sources and financial or management relationships that could be perceived as potential sources of bias. The authors disclosed none. The views expressed here are those of the authors and do not reflect the official policy of the Department of the Army, the Department of Defense, or the U.S. Government. The authors are military service members. This work was prepared as part of our official duties. Title 17 U.S.C. 105 provides that "Copyright protection under this title is not available for any work of the United States Government." Title 17 U.S.C. 101 defines a United States Government work as a work prepared by a military service member or employee of the United States Government as part of that person's official duties.

Copyright: © 2022 Jordan. This is an open access article distributed in accordance with the terms of the Creative Commons Attribution (CC BY 4.0) License. See: <http://creativecommons.org/licenses/by/4.0/>

REFERENCES

1. Haran M, Scatner A, Kozak N, et al. Acute steroid myopathy: a highly overlooked entity. *QJM*. 2018;111(5):307-11.
2. Pereira RM and Freire de Carvalho J. Glucocorticoid-induced myopathy. *Joint Bone Spine*. 2011;78(1):41-4.
3. Boonen S, Van Distel G, Westhovers R, et al. Steroid myopathy induced by epidural triamcinolone injection. *Br J Rheumatol*. 1995;34(4):385-6.
4. Gupta A and Gupta Y. Glucocorticoid-induced myopathy: pathophysiology, diagnosis, and treatment. *Indian J Endocrinol Metab*. 2013;17(5):913-6.

Vaginal Swelling After Intercourse: A Case Report

Michael J. Bono, MD*,†

Dylan M. Woolum, MD*

A. Shirley Jones, DO*

Francis L. Counselman, MD*,†

*Eastern Virginia Medical School, Department of Emergency Medicine,
Norfolk, Virginia

†Emergency Physicians of Tidewater, Norfolk, Virginia

Section Editor: R. Wilkerson, MD

Submission History: Submitted November 3, 2021; Revision received January 13, 2022; Accepted February 25, 2022

Electronically published April 25, 2022

Full text available through open access at http://escholarship.org/uc/uciem_cpccem

DOI: 10.5811/cpcem.2022.2.55284

Introduction: A vulvar hematoma is a hemorrhagic fluid collection in the female external genitalia. The majority occur as an obstetrical complication, especially during labor. Non-obstetrical vulvar hematomas are usually the result of trauma, with coitus being the most common etiology.

Case Report: We present the case of a 25-year-old woman with significant vaginal pain and swelling after vigorous sexual intercourse. She exhibited tenderness and swelling of the left labia majora and minora. The differential diagnosis included bleeding, abscess, and deep venous thrombosis. Laboratory studies were normal and computed tomography of the pelvis indicated the swelling was most likely due to blood. The patient was taken to the operating room, and approximately 150 cubic centimeters of clot was evacuated. The patient had an uneventful recovery and was discharged home the next day.

Conclusion: This case illustrates the unique presentation and challenges in making the diagnosis of vulvar hematoma. [Clin Pract Cases Emerg Med. 2022;6(2):169-172.]

Keywords: *vaginal swelling; vulvar hematoma; labia majora; labia minora; case report.*

INTRODUCTION

We present the case of a 25-year-old woman who presented to the emergency department (ED) with the complaint of increasing pain and swelling of the left side of her vagina. She admitted to frequent and vigorous sexual intercourse the day prior. Physical exam was remarkable for a swollen, dark, and tender left labia majora and minora. Laboratory studies were normal and computed tomography imaging of the pelvis revealed the swelling was most likely due to blood. The patient was taken to the operating room (OR) where 150 cubic centimeters (cc) of clot was evacuated and a bleeding arteriole was ligated. She was discharged the day after surgery and had an uneventful recovery. We discuss vulvar hematoma, an uncommon diagnosis, its presentation, and management.

CASE REPORT

A 25-year-old woman presented to the ED complaining of left-sided vaginal pain and swelling. She stated she had woken

up approximately five hours earlier with these symptoms, which had been progressing. She described the pain as severe and throbbing. She stated she was unable to sit comfortably and that it was painful to walk. The patient reported having five episodes of sexual intercourse over a two-hour period the day prior; afterwards, she applied ice to the area. She denied abdominal pain, vaginal bleeding, or discharge. The patient was in good health otherwise and denied any medical problems, including sickle cell disease or bleeding disorders. She was not on any medications and denied drug allergies.

Physical exam revealed a young woman in mild distress secondary to severe pain. Vital signs revealed a pulse of 96 beats per minute, respiratory rate of 14 breaths per minute, blood pressure of 123/86 millimeters of mercury (mm Hg), temperature of 97° Fahrenheit (36.1° Celsius), and 100% oxygen saturation on room air. Examination of the heart, lungs, and abdomen was normal. Genitourinary exam revealed marked swelling of the left labia majora and minora. The

swollen area was dark, firm, and tender to palpation (Image). Speculum exam was deferred due to the significant amount of pain and swelling.

We were concerned for hematoma primarily, but also considered abscess or a deep venous thrombosis (DVT). An intravenous (IV) line was established and the patient was administered morphine four milligrams (mg) and ondansetron four mg IV for pain. She required repeated dosing in the ED for adequate pain control. Laboratory studies were sent for a complete blood count (CBC), basic metabolic profile (BMP), coagulation studies, D-dimer, urinalysis, and urine pregnancy test. Results included a normal CBC, BMP, coagulation studies, D-dimer, and urinalysis. The urine pregnancy test was negative.

The gynecology service was consulted; they also were unable to perform a speculum exam. After discussion, it was mutually agreed to image the patient with a computed tomography (CT) of the pelvis. The CT of the pelvis with IV contrast showed an enlarged left labial mass-like lesion, most likely due to focal hemorrhage or hematoma, but no definite involvement of the base of the bladder or urethra. There was a 6.6 x 4.8 cm hyperdense ovoid focus within the left labial region. Given this finding, and that the swelling appeared to be expanding, the patient was taken to the OR. A two-centimeter incision was made on the mucosal surface of the labia minora and approximately 150 cc of clot was evacuated. Also identified was an area of arterial bleeding, which was ligated with 3.0 Vicryl suture (Ethicon, Inc., Somerville, NJ).

On the first postoperative day, the patient felt much improved, with significant reduction in the swelling and pain. Her hemoglobin and hematocrit were unchanged from the day prior. She was discharged home with a diagnosis of vulvar hematoma, with instructions to follow up in one week and for pelvic rest for one month.

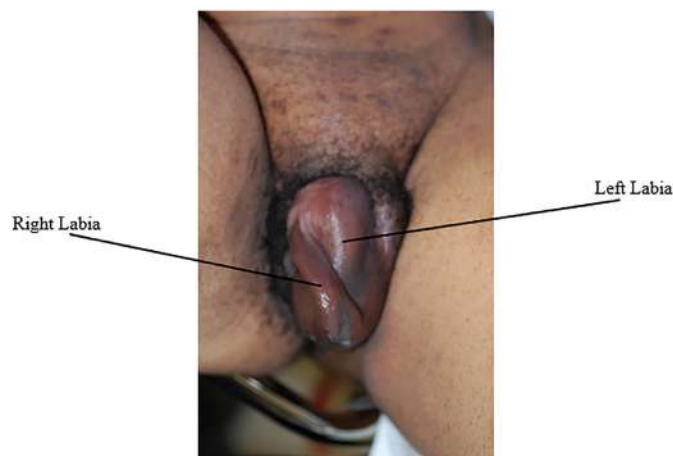

Image. Swollen, darkened left labia majora in patient with vulvar hematoma.

CPC-EM Capsule

What do we already know about this clinical entity?

The majority of vulvar hematomas are a result of obstetrical complications. The majority of non-obstetrical vulvar hematomas are related to trauma, including sexual assault and coitus.

What makes this presentation of disease reportable?

This is an excellent example of a non-obstetrical vulvar hematoma due to trauma. The physical exam findings are classic for this condition, and emphasize the importance of appropriate imaging.

What is the major learning point?

The role of ultrasound and computed tomography, the pros and cons of each, in evaluating a vulvar hematoma.

How might this improve emergency medicine practice?

This case should broaden the differential diagnosis when evaluating a woman complaining of vulvar pain and swelling. The appropriate evaluation and management strategy are reviewed.

DISCUSSION

The vulva comprises the external sex organs made of smooth muscle and connective tissue that surrounds the vaginal introitus and urethra. A vulvar hematoma is a hemorrhagic fluid collection within these connective tissues.^{1,2} The vulva is well vascularized by the internal pudendal artery. The pudendal artery is a branch off the internal iliac artery, and it supplies the majority of the perineum. Once through the pudendal canal located in the ischioanal fossa, the pudendal artery subdivides into smaller branches, including the perineal artery, which provides vascular flow to the external genitalia.² ³ The pudendal artery, along with its branches, accounts for the majority of vulvar hematomas.² Less common culprit lesions may include injury to the internal iliac artery, given its more proximal origin, or venous bleeding.⁴

Obstetric complications account for most vulvar hematomas, with an incidence of 1-2 per 1000 deliveries.⁵ Most of these occur during labor. Outside the pregnant population, vulvar hematomas have an incidence of 3.7% and represent only 0.8% of all gynecologic admissions.⁶ The majority of non-obstetric vulvar hematomas are related to various traumatic insults, including saddle injuries, falling from a height, sexual assault, and coitus.⁶

^{7,8} If there is no history of trauma then a spontaneous vessel rupture, such as a pseudoaneurysm of the internal iliac artery or pudendal artery, should be considered.² As in our case, coitus is the most common non-obstetric etiology of a vulvar hematoma.¹ Hematoma formation is suspected to be due to direct compression of the labial and vaginal soft tissues against adjacent pelvic bone resulting in laceration of underlying vasculature.⁸

Common presentations for a vulvar hematoma include perineal pain and unilateral swelling. Non-obstetric vulvar hematomas follow a bimodal age distribution. It is more common during childhood or early adolescence (because the labia majora is less developed) and in postmenopausal women as a result of hypoestrogenism, making the vulva more prone to injury.⁷ For unknown anatomic reasons, the majority of vulvar hematomas are right sided (70%).⁷ When significant swelling is present, pain may be accompanied by urological manifestations, including dribbling or urinary retention secondary to urethral obstruction.⁴ Importantly, if hematoma formation is secondary to aggressive coitus, clinicians should privately discuss with the patient any concerns for sexual assault.

Physical examination involves visual inspection of the vulva and vagina. Although pain and swelling may limit this exam, the vaginal canal should be directly visualized to exclude mucosal laceration. In the setting of trauma, associated injuries such as fractures must be considered.⁸ Due to inflammation and edema of surrounding soft tissue, erythema and tenderness may be mistaken for Bartholin's gland abscess or folliculitis.^{1, 8, 9} Additional considerations in the differential diagnosis include coagulopathies, varicosities, contact (condom) dermatitis, angioedema, DVT, or carcinoma.

Most patients with clinically significant hematomas should have a CBC performed to evaluate for anemia. Further coagulation studies or blood screening and cross-matching may be necessary, should bleeding be significant. A variety of imaging modalities can be used in diagnosing and monitoring vulvar hematomas, including CT, ultrasound, and magnetic resonance imaging.¹⁰ Transperineal sonography, using 7.5- and 10-megahertz transducers, has been shown to be effective in depicting the size of vulvar hematomas.¹¹ Ultrasound has the advantages of being able to be performed at the bedside, a lack of ionizing radiation to the genital region, and lower cost. A CT with use of IV contrast can accurately identify the size of the fluid collection and the presence of extravasation. This is at the expense of higher cost and exposure of the genital region to ionizing radiation. Magnetic resonance imaging has long been used for the imaging of vulvar malignancies, due to its high soft tissue contrast and excellent anatomic detail, without ionizing radiation.¹² However, the increased cost and time delay must be considered.

There is no consensus for the management of vulvar hematomas. In practice, smaller hematomas with gradual onset and minimal pain are often managed conservatively with ice packs, analgesia, and bed rest.¹ Appropriate monitoring and follow-up are warranted to avoid complications such as

pressure necrosis or infection.¹⁰ Larger hematomas that are either expanding or have associated pressure necrosis or pelvic injury, and are greater than 10 cm in size, or have associated hemodynamic instability, must be recognized and managed early.⁶ Conservative management of large hematomas has been found to be associated with a longer period of hospitalization, and a greater need for antibiotics and blood transfusion.^{7, 13} Management includes surgery or directed arterial embolization in consultation with interventional radiology. For our patient, given her degree of pain and the progressive swelling in the ED, the patient was taken to the OR for hematoma evacuation. The culprit bleeding artery was directly visualized and ligated.

CONCLUSION

Although mortality is rarely associated with a vulvar hematoma, its potential morbidity makes this one diagnosis that emergency physicians must consider when evaluating a woman with a perineal complaint. The potential complications include necrosis, infection, neurologic compromise, urinary obstruction, and hemo-dynamic instability. While most vulvar hematomas are related to obstetric complications, they may also occur spontaneously or from local trauma, such as coitus.

Patient consent has been obtained and filed for the publication of this case report.

Address for Correspondence: Francis L. Counselman, MD, Eastern Virginia Medical School, Room 304, Raleigh Building, Department of Emergency Medicine, 600 Gresham Drive, Norfolk, VA 23507 Email: counselfl@evms.edu.

Conflicts of Interest: By the CPC-EM article submission agreement, all authors are required to disclose all affiliations, funding sources and financial or management relationships that could be perceived as potential sources of bias. The authors disclosed none.

Copyright: © 2022 Bono. This is an open access article distributed in accordance with the terms of the Creative Commons Attribution (CC BY 4.0) License. See: <http://creativecommons.org/licenses/by/4.0/>

REFERENCES

1. Mangwii AA, Ebasone PV, Aroke D, et al. Non-obstetric vulva hematomas in a low resource setting: two case reports. *Pan Afr Med J.* 2019;33(314):1-8
2. Hong HR, Hwang KR, Kim SA, et al. A case of vulvar hematoma with rupture of pseudoaneurysm of pudendal artery. *Obstet Gynecol Sci.* 2014;57(2):168.
3. Jaraquemada JMP, Monaco RG, Barbosa NE, et al. Lower uterine blood supply: extrauterine anastomotic system and its application in surgical devascularization techniques. *Acta Obstet Gynecol Scand.* 2007;86(2):228.
4. Egan E, Dundee P, Lawrentschuk N. Vulvar hematoma secondary to spontaneous rupture of the internal iliac artery: clinical review. *Am J Obstet Gynecol.* 2009; 200(1): e17.

5. Villella J, Garry D, Levine G, et al. Postpartum angiographic embolization for vulvovaginal hematoma. A report of two cases. *J Reprod Med.* 2001;46(1): 65.
6. Jones ISC and O'Connor A. Non-obstetric vulval trauma. *Emerg Med Australasia.* 2013;25(1):36.
7. Oong GC and Eruo FU. Vulvar Hematoma. [Updated 2021 Aug 14]. In: StatPearls [Internet]. Treasure Island (FL): StatPearls Publishing; 2022 Jan. Available from: <https://www.ncbi.nlm.nih.gov/books/NBK560753/>
8. Virgili A, Bianchi A, Mollica G, et al. Serious hematoma of the vulva from a bicycle accident. a case report. *J Reprod Med.* 2000; 45(8):662.
9. Perkins JD and Morris PF. Traumatic vulvar hematoma masquerading as a Bartholin duct cyst in a postmenopausal woman. *J Mississippi State Med Assoc.* 2013;54(1):8.
10. Papoutsis D and Haefner HK. Large vulvar haematoma of traumatic origin. *J Clin Diagn Res.* 2017;11(9):QJ01.
11. Sherer DM, Stimphil R, Hellmann M, et. al. Transperineal sonography of a large vulvar hematoma following blunt perineal trauma. *J Clin Ultrasound.* 2006;34(6):309.
12. Hosseinzadeh K, Heller MT, Houshmand G. Imaging of the female perineum in adults. *RadioGraphics.* 2012;32(4):E129.
13. Benrubi G, Neuman C, Nuss RC, et. al. Vulvar and vaginal hematomas: a retrospective study of conservative versus operative management. *South Med J.* 1987;80(88):991.

Submucosal Duodenal Artery Pseudoaneurysm Causing Massive Gastrointestinal Hemorrhage: A Case Report

Stephen Elliott, DO*
Anna Trtchounian, MD*
Babak Danesh, MD†
Wojciech Bober, DO*
David Levy, DO*

*Good Samaritan Hospital, Department of Emergency Medicine, West Islip, New York
†Good Samaritan Hospital, Department of Gastroenterology, West Islip, New York

Section Editor: Manish Amin, DO

Submission History: Submitted August 29, 2021; Revision received February 27, 2022; Accepted March 09, 2022

Electronically published May 6, 2022

Full text available through open access at http://escholarship.org/uc/uciem_cpem

DOI: 10.5811/cpem.2022.3.54564

Introduction: Acute upper gastrointestinal bleeding is a common emergency presentation. The United States Centers for Disease Control and Prevention 2018 survey of emergency department (ED) visits reported 436,000 ED visits for unspecified gastrointestinal bleeding that year.¹

Case Report: We present the case of a submucosal duodenal pseudoaneurysm causing massive gastro-intestinal hemorrhage in a male on anticoagulation.

Conclusion: Prompt recognition of critical gastrointestinal bleeding, appropriate ED management, and early consultation for emergent intervention are the essential components to reduce morbidity and mortality for patients with massive gastrointestinal hemorrhages. [Clin Pract Cases Emerg Med. 2022;6(2):173-176.]

Keywords: *case report; pseudoaneurysm; gastrointestinal hemorrhage; massive transfusion protocol.*

INTRODUCTION

Upper gastrointestinal (GI) bleeding has been estimated to account for up to 20,000 deaths annually in the United States.² Overall incidence of acute upper GI hemorrhage has been estimated to be 50-100/100,000 annually.² Upper GI bleeding is defined as bleeding that occurs from a source proximal to the ligament of Treitz. Bleeding from the upper GI tract is about four times more common than bleeding from the lower GI tract.³ Common presentations of acute upper GI hemorrhage include hematemesis and/or melena.⁴ The identification and early resuscitation of these patients is pivotal, as the mortality rate of upper GI bleeding can be from 6-10%.⁵ This rate significantly increases and can be fatal when a ruptured pseudoaneurysm is the source of a GI bleed.⁶

CASE REPORT

An 82-year-old male, with a past medical history significant for atrial fibrillation on apixaban and amiodarone, presented to our emergency department (ED) with coffee-

ground emesis, fatigue, and maroon-colored stool. Symptoms started 18 hours prior to arrival. The patient denied abdominal pain, use of non-steroidal anti-inflammatory medications, history of GI bleeding, peptic ulcer disease, or aortic pathology. Other medical history included hyperlipidemia and hypertension for which he was taking metoprolol and amlodipine. All other review of systems was negative.

The patient was an elderly Black male who was diaphoretic, with dry, crusted dark-colored emesis on chin and chest, and with copious foul-smelling, dark-colored stools. The patient's initial vitals were blood pressure of 86/37 millimeters of mercury (mm Hg), heart rate 60 beats per minute (BPM), respiratory rate 30 breaths per minute, rectal temperature 96° Fahrenheit, and oxygen saturation of 100% on two liters by nasal cannula. The patient had labored breathing, with unremarkable lung sounds on auscultation. His abdomen was soft, non-tender, and non-distended. A point-of-care blood analysis showed an immeasurable "low" hemoglobin grams per deciliter (g/dL)

(reference range 12-17g/dL and reportable range 5.1-25.5g/dL) and a hematocrit of less than 15% (reference range 38-51% and reportable range 15-75%).

Two large-bore peripheral intravenous catheters, a central venous catheter, and an arterial monitoring catheter were established. Massive blood transfusion protocol was activated. A total of 10 units of packed red blood cells, four units of fresh frozen plasma, and one unit of platelets were rapidly transfused. Prothrombin complex concentrate, proton pump inhibitor, and vasopressors were administered. The patient was endotracheally intubated for airway protection. After these measures, his blood pressure improved to 112/67 mm Hg with a heart rate in the 50s BPM. Repeat hemoglobin was 7.0 g/dL.

Emergent bedside upper GI endoscopy revealed an area of extrinsic compression on duodenum with a fresh blood clot and minimal oozing. Abdominal computed tomography (CT) angiogram demonstrated a 2.5-centimeter pseudoaneurysm in the anterior aspect of the proximal transverse duodenum (Image 1) with no evidence of aortic involvement. The pseudoaneurysm was deemed to be likely submucosal in location with mild surrounding mucosal edema.

A repeat bedside upper GI endoscopy showed an intense submucosal hemorrhage with brisk bleeding (Image 2). Endoscopic maneuvers with submucosal epinephrine injection with good blanching and the placement of a hemostatic clip failed to achieve hemostasis. A location to place another clip could not be identified due to intensity of bleeding.

The patient was emergently taken to the operating room for an exploratory laparotomy and retroperitoneal exploration. A pulsatile mass was found within the third portion of the duodenum, abutting the pancreatic head, with active pulsatile hemorrhage. The bleeding vessel was not accurately identified due to the vast amount of bleeding. A partial duodenectomy was performed to remove this mass, which pathology specimen analysis confirmed was a ruptured submucosal pseudoaneurysm within the duodenum. No further GI bleeding was encountered. The patient's hospital course was complicated by postoperative ileus and Gram-negative septicemia. He gradually improved, was re-started on anticoagulation therapy, and discharged to a rehabilitation facility.

DISCUSSION

Visceral artery pseudoaneurysms, defined as those affecting the celiac, superior or inferior mesenteric arteries, and/or their branches, are rare with a reported incidence of 0.1-0.2%.⁷ However, the exact number is difficult to account for because most patients are asymptomatic.^{7,8} The diagnosis is on the rise due to incidental detection from increased use of advanced imaging techniques and iatrogenic causes from an increase in procedures that use instrumentation.⁷ The most common artery involved is the splenic artery.^{7,8}

Although the exact vessel could not be identified in this case, based on imaging and surgical findings,

CPC-EM Capsule

What do we already know about this clinical entity?

Acute upper gastrointestinal (GI) bleeding is a common culprit in patients presenting to emergency departments with hematemesis and/or melena.

What makes this presentation of disease reportable?

A duodenal arterial pseudoaneurysm is a rare cause of acute upper GI bleeding and is associated with a high mortality rate.

What is the major learning point?

Have a high level of suspicion for active GI bleeding to appropriately stabilize and resuscitate these critically ill patients prior to definitive therapy.

How might this improve emergency medicine practice?

We review the steps of management in the emergency department for these complex patients and emphasize the importance of getting specialists involved early when minutes matter.

a pseudoaneurysm of one of the terminal branches of the pancreaticoduodenal artery of the proximal transverse duodenum was the most likely culprit. Less than 2% of all visceral aneurysms are comprised from pancreaticoduodenal artery.⁸ Pseudoaneurysms have a high incidence of rupturing; thus, patients can present with signs of hemodynamic collapse from catastrophic GI bleed.⁷ Mortality rate of pseudoaneurysm rupture into the GI tract ranges from 25-70%.^{7,8}

The acute ED management of GI bleeding is critical. In patients with abnormal vital signs due to active bleeding, initial resuscitation may involve activating massive transfusion protocol based on clinical impression rather than a laboratory value. Current evidence supports transfusion of plasma to platelets to packed red blood cells in either a 1:1:1 or a 1:1:2 ratio.⁹ Platelet transfusion is recommended if the platelet count is less than 50,000 per microliter.⁴ Intubation should be considered in patients who are not protecting their airway or who are at risk of aspiration from ongoing hematemesis. However, intubating a patient with an upper GI bleed has also been associated with increased risk of

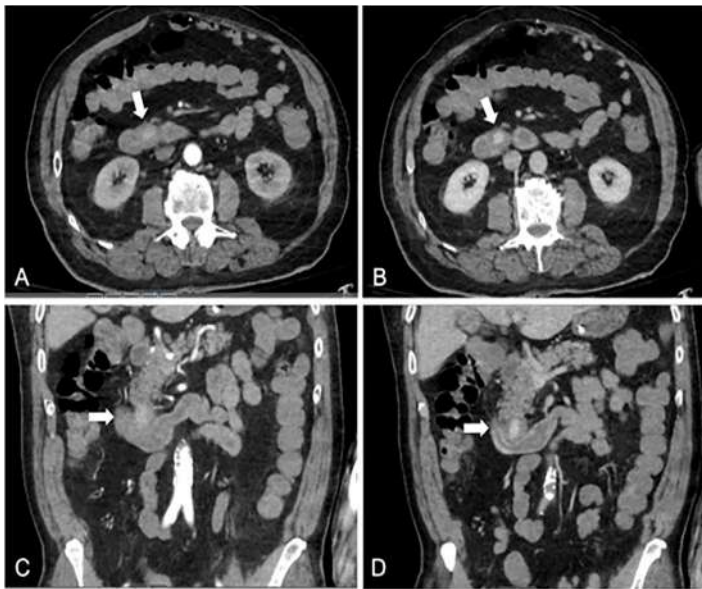


Image 1. Computed tomography angiogram of abdomen showing submucosal duodenal pseudoaneurysm (white arrows) causing massive gastrointestinal hemorrhage in (A) transverse plane arterial phase, (B) transverse plane venous phase, (C) coronal plane arterial phase, and (D) coronal plane venous phase.

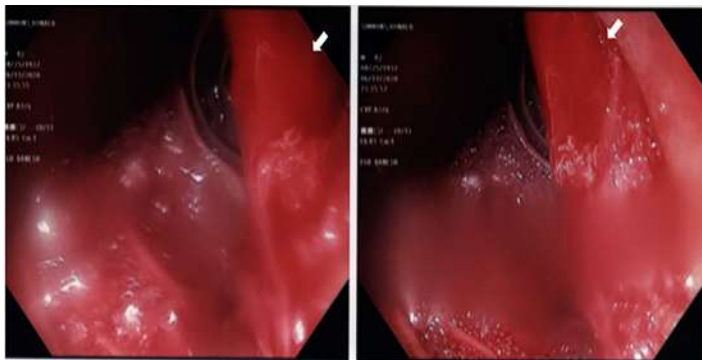


Image 2. Endoscopy images of active arterial bleeding (white arrow) from submucosal duodenal pseudoaneurysm that caused a massive gastrointestinal hemorrhage.

adverse cardiopulmonary events such as pulmonary edema, acute respiratory distress syndrome, myocardial infarction, or cardiac arrest.¹⁰

Pharmacotherapy for all patients with suspected severe upper GI bleeding generally include a proton pump inhibitor (PPI). Recommendations include administering a dose equivalent of esomeprazole 80 milligrams (mg) when there is evidence of active bleeding and 40 mg if no evidence of active bleeding. Studies have shown that intermittent PPI is not inferior to continuous PPI.⁴ However, the decision to use a PPI continuous drip should be made in consultation with a gastroenterologist. Somatostatins, such as octreotide, are not recommended in nonvariceal upper GI bleeds.⁴ Patients

suspected of or with a history of cirrhosis have demonstrated benefits and decreased mortality from the administration of prophylactic antibiotics.⁴ Tranexamic acid demonstrated no benefit in GI bleeding.¹¹

Consideration must be given to reversal of anticoagulation. Recent recommendations include administration of prothrombin complex concentrate and vitamin K to patients on warfarin with elevated international normalized ratio levels. If prothrombin complex concentrate is not available, fresh frozen plasma can be given instead.⁴ Direct oral anticoagulants (DOAC) generally have a lower risk of life-threatening and/or fatal bleeding in comparison to warfarin. Reversal of DOACs can be more challenging as only dabigatran has a specific reversal agent. For patients on DOACs, recommendations include administration of prothrombin complex concentrate or andexanet alfa, which binds to factor Xa inhibitors.⁴

After resuscitation, a computed tomography angiography may be obtained to detect the source of upper GI bleeding. Consultation with a gastroenterologist is essential since the diagnostic modality of choice is endoscopy. Once the bleeding site is located, hemostasis can be obtained endoscopically.⁴ Hemostasis may not be achieved in ruptured pseudoaneurysms, in which case, surgery or an interventional radiology team may attempt to stop the bleed by surgically removing the problem area or by arterial embolization.⁸ Studies have shown that surgical treatment of visceral pseudo-aneurysm is associated with higher mortality in comparison to treatment by embolization.^{5,8} Balloon tamponade may be performed in the ED when endoscopic, surgical, or interventional radiology treatment modalities are not rapidly available for patients with life-threatening upper GI hemorrhages.⁵ This procedure is a temporary means of stabilization until more definitive therapy can be obtained.⁵ A crucial step is early consultation with a gastroenterologist as well as with a surgeon and/or interventional radiologist as adjuncts for potential surgical intervention.

CONCLUSION

Acute upper GI bleeds, although a common emergency presentation, can be life-threatening, especially if the culprit is a ruptured pseudoaneurysm. Close attention must be paid to alarming vital signs and clinical appearance. Given the pivotal role of early and adequate resuscitation, its importance cannot be overemphasized. The triad of prompt recognition of critical upper GI bleeds, appropriate early management, and early consultation for emergent intervention are the essential components to reduce morbidity and mortality in patients with massive GI hemorrhages.

The authors attest that their institution requires neither Institutional Review Board approval nor patient consent for publication of this case report. Documentation on file.

Address for Correspondence: Anna Trtchounian, MD, MS, Good Samaritan Hospital. Department of Emergency Medicine, 1000 Montauk Highway, West Islip, NY 11795. Email: Anna.Trtchounian@gmail.com

Conflicts of Interest: By the CPC-EM article submission agreement, all authors are required to disclose all affiliations, funding sources and financial or management relationships that could be perceived as potential sources of bias. The authors disclosed none.

Copyright: © 2022 Elliott. This is an open access article distributed in accordance with the terms of the Creative Commons Attribution (CC BY 4.0) License. See: <http://creativecommons.org/licenses/by/4.0/>

REFERENCES

1. U.S. Department of Health and Human Services, Centers for Disease Control and Prevention, National Center for Health Statistics. National hospital ambulatory medical care survey: 2018 emergency department summary tables. 2018. Available at: https://www.cdc.gov/nchs/data/nhamcs/web_tables/2018-ed-web-tables-508.pdf. Accessed June 24, 2020.
2. El-Tawil AM. Trends on gastrointestinal bleeding and mortality: Where are we standing? *World J Gastroenterol*. 2012;18(11):1154-8.
3. Upchurch B, Cerulli MA, Iqbal S. Upper gastrointestinal bleeding (UGIB). 2021. Available at: <https://emedicine.medscape.com/article/187857>. Accessed September 10, 2020.
4. Saltzman J. Approach to acute upper gastrointestinal bleeding in adults. 2021. Available at: <https://www.uptodate.com/contents/approach-to-acute-upper-gastrointestinal-bleeding-in-adults>. Accessed September 10, 2020.
5. Fallah MA, Prakash C, Edmumdowicz S. Acute gastrointestinal bleeding. *Med Clin North Am*. 2000;84(5):1183-208.
6. Ahmed G, Abid M, Hosmane S, et al. Unusual case of upper gastrointestinal haemorrhage secondary to a ruptured gastroduodenal artery pseudoaneurysm: case presentation and literature review. *BMJ Case Rep*. 2020;13(11):e236463.
7. Sumpio B. Overview of visceal artery aneurysm and pseudoaneurysm. 2020. Available at: <https://www.uptodate.com/contents/overview-of-visceral-artery-aneurysm-and-pseudoaneurysm>. Accessed September 10, 2020.
8. Park CY, Ju JK, Kim JC. Damage control surgery in patient with delayed rupture of pseudoaneurysm after blunt abdominal trauma. *J Korean Surg Soc*. 2012;83(2):119-22.
9. Lal DS and Shaz BH. Massive transfusion: blood component ratios. *Curr Opin Hematol*. 2013;20(6):521-5.
10. Hayat U, Lee PJ, Ullah H, et al. Association of prophylactic endotracheal intubation in critically ill patients with upper GI bleeding and cardiopulmonary unplanned events. *Gastrointest Endosc*. 2017;86(3):500-9.e1.
11. HALT-IT Trial Collaborators. Effects of a high-dose 24-h infusion of tranexamic acid on death and thromboembolic events in patients with acute gastrointestinal bleeding (HALT-IT): an international randomised, double-blind, placebo-controlled trial. *Lancet*. 2020;395(10241):1927-36.

Identification of Spontaneous Shoulder Hemarthrosis with Point-of-Care Ultrasound in the Emergency Department

Kevin A. Padrez, MD
William Shyy, MD
Kavita Gandhi, MD, PhD
Nancy Anaya, MD
R. Starr Knight, MD

University of California, San Francisco, Department of Emergency Medicine, San Francisco, California

Section Editor: Anna McFarlin, MD

Submission History: Submitted May 27, 2021; Revision received July 19, 2021; Accepted July 26, 2021

Electronically published March 7, 2022.

Full text available through open access at http://escholarship.org/uc/uciem_cpem

DOI: 10.5811/cpcem.2021.7.53408

Case presentation: A 32-year-old man with a history of hemophilia A presented to the emergency department with right shoulder pain, swelling, and decreased range of motion.

Discussion: Emergency physicians can use ultrasound to quickly and accurately identify hemarthrosis at the bedside. [Clin Pract Cases Emerg Med. 2022;6(2):177–179.]

Keywords: *ultrasound; hemophilia; hemarthrosis.*

CASE PRESENTATION

A 32-year-old man with a history of hemophilia A presented to the emergency department (ED) with right shoulder pain, swelling, and decreased range of motion. The patient had previously been treated with factor VIII replacement every three days for maintenance therapy but currently lacked access to established outpatient care after relocating from a nearby city. He was experiencing homelessness and sleeping outside. He denied preceding trauma, numbness, or weakness. His vital signs included: temperature 36.6°C, heart rate 93 beats per minute, respiration rate 16 breaths per minute, blood pressure 173/127 millimeters mercury, and blood oxygen saturation of 100% on room air. His physical examination was remarkable for right shoulder swelling and tenderness along the right deltoid with decreased range of motion secondary to pain (Image 1). His distal motor and sensory function were intact.

The treating emergency physician performed a point-of-care ultrasound to evaluate for a right shoulder hemarthrosis. This exam was performed using a curvilinear 5-2 megahertz probe (Sonosite, Bothell, WA). While standing behind the patient, the probe was placed parallel to the ground just below the scapular spine. The probe marker was oriented to the patient's left, which allows the

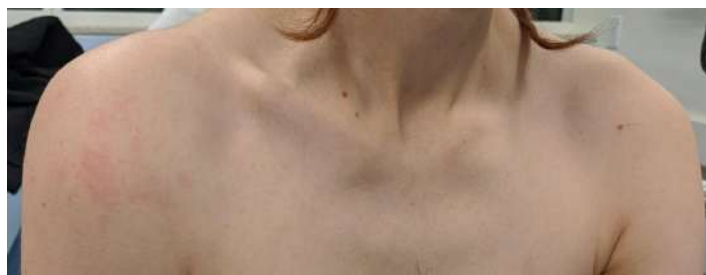

Image 1. Photo of patient demonstrating asymmetric swelling of the right shoulder.

anatomy on the screen to match the patient's anatomy. The probe was then moved laterally until the glenoid, humeral head, and infraspinatus tendon were visualized. Both the affected and unaffected shoulders were evaluated using a similar technique.

In this patient, a collection with heterogeneous echogenicity was visualized above the humeral head and below the infraspinatus tendon, asymmetric to the unaffected side. These findings were consistent with a spontaneous hemarthrosis (Image 2). He was admitted to the hospital. Hematology was consulted and the patient was restarted on factor VIII treatment with improvement

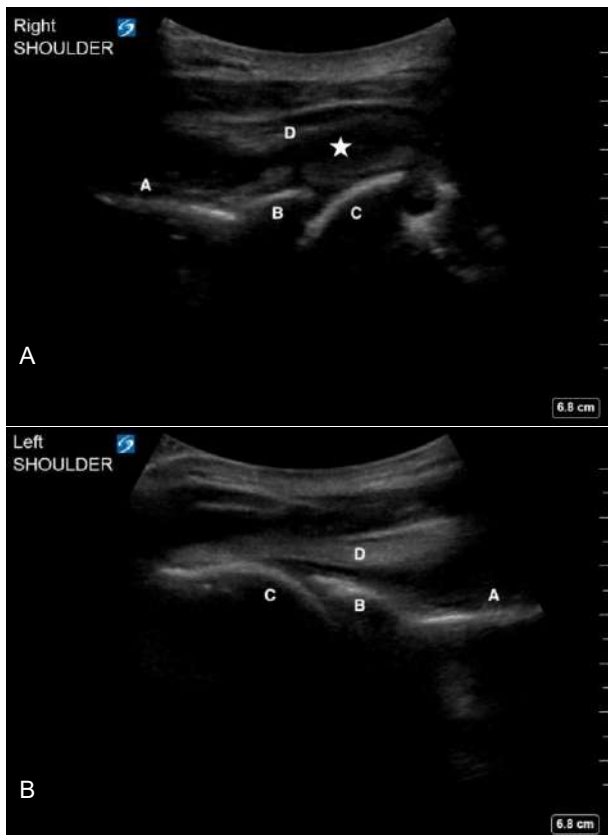


Image 2. Ultrasound images of the affected right shoulder (2A) and unaffected left shoulder (2B) showing scapular spine (A), glenoid (B), humeral head (C) and infraspinatus tendon (D). A mixed-echotexture collection consistent with an intraarticular hemarthrosis (star) is visualized in the right shoulder.

in his shoulder symptoms. He established care with the local hematology clinic to initiate regular factor VIII maintenance therapy.

DISCUSSION

Spontaneous hemarthrosis is a common cause of morbidity and pain for patients with congenital hemophilia.¹ While magnetic resonance imaging (MRI) is considered the conventional imaging modality for evaluating hemophilic arthropathy, ultrasound offers many benefits including less time, lower cost, and better accessibility than MRI.² The detection of a joint effusion remains a core use of point-of-care ultrasound in the ED³ and has also been shown to accurately diagnose hemarthrosis in the outpatient setting.^{4,5} Emergency physicians can use point-of-care ultrasound to quickly and accurately identify hemarthrosis and expedite care for hemophilia patients.

The described technique to identify spontaneous hemarthrosis in the shoulder uses a curvilinear probe. The larger footprint of the probe allows for better visualization of the complete shoulder anatomy compared to a linear probe. However, a similar technique may be applied using

CPC-EM Capsule

What do we already know about this clinical entity?

Point-of-care ultrasound is commonly used to identify joint effusions.

What is the major impact of the image(s)?

Spontaneous shoulder hemarthrosis may be quickly and accurately identified using point-of-care ultrasound.

How might this improve emergency medicine practice?

Point-of-care ultrasound should be considered for the identification of spontaneous hemarthrosis in hemophilia patients presenting with joint pain.

the linear probe, especially in pediatric patients. Gentle internal and external rotation of the arm can help confirm the identification of the humeral head (video). Some small effusions may only be visible with external rotation of the affected arm.

Video. Gentle internal and external rotation of the shoulder can help identify humeral head. Annotation identifies the glenoid (GI), humeral head (HH), and hemarthrosis (star).

The Institutional Review Board approval has been documented and filed for publication of this case report.

Address for Correspondence: Kevin A. Padrez, MD, University of California, San Francisco, Department of Emergency Medicine, 505 Parnassus Avenue M24, San Francisco, California 94143. Email: kpadrez@gmail.com

Conflicts of Interest: By the CPC-EM article submission agreement, all authors are required to disclose all affiliations, funding sources and financial or management relationships that could be perceived as potential sources of bias. The authors disclosed none.

Copyright: © 2022 Padrez et al. This is an open access article distributed in accordance with the terms of the Creative Commons Attribution (CC BY 4.0) License. See: <http://creativecommons.org/licenses/by/4.0/>

REFERENCES

1. Wyseure T, Mosnier LO, von Drygalski A. Advances and challenges in hemophilic arthropathy. *Semin Hematol.*

- 2016;53(1):10-9.
2. Doria AS. State-of-the-art imaging techniques for the evaluation of haemophilic arthropathy: present and future. *Haemophilia*. 2010;16Suppl5:107-14.
3. American College of Emergency Physicians. Emergency ultrasound imaging criteria compendium. *Ann Emerg Med*. 2016;68(1):e11-48.
4. Kidder W, Nguyen S, Larios J, et al. Point-of-care musculoskeletal ultrasound is critical for the diagnosis of hemarthroses, inflammation and soft tissue abnormalities in adult patients with painful haemophilic arthropathy. *Haemophilia*. 2015;21(4):530-7.
5. Aznar JA, Abad-Franch L, Perez-Alenda S, et al. Ultrasonography in the monitoring of management of haemarthrosis. *Haemophilia*. 2011;17(5):826-8.

Post-intravitreal Injection Endophthalmitis Identified with Point-of-care Ultrasound

Vahe Zograbyan, BS*
Matthias Barden, MD†
Ami Kurzweil, MD†

*St. George's University School of Medicine, Grenada, West Indies
†Eisenhower Health, Department of Emergency Medicine, Rancho Mirage, California

Section Editor: Christopher San Miguel, MD

Submission History: Submitted August 23, 2021; Revision received November 18, 2021; Accepted November 22, 2021

Electronically published May 5, 2022

Full text available through open access at http://escholarship.org/uc/uciem_cpem

DOI: 10.5811/cpcem.2021.11.54515

Case Presentation: An 88-year-old female presented to the emergency department (ED) with complaints of painful vision loss four days after an intravitreal injection for her neovascular macular degeneration. Her right eye visual acuity was markedly diminished with an absence of red reflex. A point-of-care ocular ultrasound was performed and demonstrated hyperechoic vitreous debris concerning for endophthalmitis.

Discussion: Endophthalmitis is an infection of the vitreous or aqueous humors commonly caused by exogenous sources, such as inoculation of bacteria into the eye from surgery, injections, or trauma. It is an ophthalmologic emergency as it is a vision-threatening infection. Although a rare complication, post-surgery or post-injection are the leading causes of endophthalmitis. Point-of-care ocular ultrasound findings suggestive of endophthalmitis, such as hyperechoic vitreous debris, aid in the timely diagnosis and treatment of patients in the ED. [Clin Pract Cases Emerg Med. 2022;6(2):180-182.]

Keywords: *endophthalmitis; ocular ultrasound; ultrasound; vitreous; ophthalmology.*

CASE PRESENTATION

An 88-year-old female with a past medical history of neovascular macular degeneration presented to the emergency department (ED) with complaints of right eye pain, worsening vision, floaters, and eye dryness since receiving an intravitreal, anti-vascular endothelial growth factor injection four days prior. On physical exam the patient's right eye had crusted exudates on eyelid margins, conjunctival injection, and absent red reflex. Visual acuity was markedly diminished with 20/200 in the right eye and 20/100 in the left eye. Tetracaine ophthalmic drops were administered for topical analgesia to both eyes, and intraocular pressures were measured to be within normal limits. Fluorescein dye and Wood's lamp exam found no uptake or corneal abrasion. A point-of-care ocular ultrasound demonstrated significant swirling echogenic debris within the posterior vitreous humor and attached, thickened retina (Image and Video). Normal retinal thickness is around 0.1-0.3 millimeters, although this is not commonly measured

on point-of-care ocular ultrasound.⁶ All findings were concerning for endophthalmitis.

The patient's ophthalmologist was consulted regarding the findings and recommended tobramycin-dexamethasone

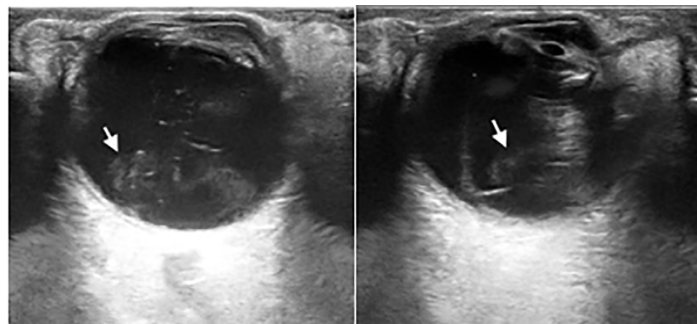


Image. Point-of-care ocular ultrasound demonstrating hyperechoic debris (white arrows) within the vitreous chamber in a patient with endophthalmitis.

ophthalmic drops and cefazolin two grams intramuscular in the ED with a disposition for immediate follow-up at their office for intravitreal cultures and antibiotic administration.

DISCUSSION

Endophthalmitis is a bacterial or fungal infection of aqueous or vitreous humors. Most cases of endophthalmitis are caused by exogenous sources: usually inoculation from surgery, injections, or trauma. Endogenous endophthalmitis is much less common and caused by seeding of the eye from the bloodstream, which then extends from the choroid to the vitreous humor. Most cases of acute endophthalmitis are caused by bacteria, and it is an ophthalmologic emergency as it is a vision-threatening infection.

Acute post-cataract surgery and post-injection are the most common causes of endophthalmitis.¹ Neovascular macular degeneration, as with our patient, is commonly treated with monthly intravitreal injections of anti-vascular endothelial growth factor medications. Although post-injection endophthalmitis is rare (0.09% per injection),² patients receiving these monthly injections are increasingly vulnerable due to cumulative risk. Ocular ultrasound plays an important role in timely diagnosis of this vision-threatening complication and is easily applied in the ED setting.^{3,4,5}

The differential diagnosis for mobile echogenic debris within the posterior vitreous chamber is broad. Common pathologies seen are vitreous hemorrhage, vitreous detachment, retinal detachment, foreign bodies, and lens dislocations. Some rare findings can include inflammatory or infectious etiologies such as intermediate uveitis, vitritis, or endophthalmitis.⁹ The patient's risk factors and clinical presentation lend to narrowing the diagnosis. Although there are no specific test characteristics for detecting endophthalmitis, ocular ultrasound has been shown to have sensitivities between 81.9-96.9% and specificities ranging from 82.3-96.3% for the diagnosis of vitreous hemorrhage and retinal detachments.^{7,8} These pathologies, especially vitreous hemorrhage, have similar appearances on ocular ultrasound. Treatment of endophthalmitis includes intravitreal cultures and empiric antibiotics with vitrectomy reserved for severe cases.

Video. Point-of-care ocular ultrasound demonstrating mobile echogenic debris within the vitreous chamber in a patient with endophthalmitis.

The authors attest that their institution requires neither Institutional Review Board approval, nor patient consent for publication of this case report. Documentation on file.

Address for Correspondence: Ami Kurzweil, MD, Eisenhower Health, Department of Emergency Medicine, 39000 Bob Hope Drive, Rancho Mirage, CA 92270. Email: akurzweil@eisenhowerhealth.org

Conflicts of Interest: By the CPC-EM article submission agreement, all authors are required to disclose all affiliations,

CPC-EM Capsule

What do we already know about this clinical entity?

Endophthalmitis is a rare vision-threatening emergency that may occur after an intravitreal injection or ophthalmologic surgery.

What is the major impact of the image(s)?

The ocular ultrasound images display the common findings and characteristics in a patient with endophthalmitis. If not identified and treated in a timely manner, irreversible blindness may occur.

How might this improve emergency medicine practice?

Given that ultrasound is readily available, safe, and fast; recognition of ocular ultrasound findings may improve patient care through timely diagnosis and treatment of endophthalmitis.

funding sources and financial or management relationships that could be perceived as potential sources of bias. The authors disclosed none.

Copyright: © 2022 Zograbyan. This is an open access article distributed in accordance with the terms of the Creative Commons Attribution (CC BY 4.0) License. See: <http://creativecommons.org/licenses/by/4.0/>

REFERENCES

1. Durand ML, Miller JW, Young LH. (2018). Endophthalmitis: An Overview. In T. Das (Eds.), *Endophthalmitis* (1-16). New York City: Springer International Publishing.
2. Day S, Acquah K, Mruthyunjaya P, et al. Ocular complications after anti-vascular endothelial growth factor therapy in Medicare patients with age-related macular degeneration. *Am J Ophthalmol.* 2011;152(2):266-72.
3. Kohanim S, Daniels AB, Huynh N, et al. Utility of ocular ultrasonography in diagnosing infectious endophthalmitis in patients with media opacities. *Semin Ophthalmol.* 2012;27(5-6):242-5.
4. Kilker BA, Holst JM, Hoffmann B. Bedside ocular ultrasound in the emergency department. *Eur J Emerg Med.* 2014;21(4):246-53.
5. Tucker J, Patane J, Lahham S. Point-of-care ultrasound detection of endophthalmitis. *J Educ Teach Emerg Med.* 2018;3(1):V25-26.
6. Chan A, Duker JS, Ko TH, et al. Normal macular thickness measurements in healthy eyes using Stratus optical coherence tomography. *Arch Ophthalmol.* 2006;124(2):193-8.

7. Gottlieb M, Holladay D, Peksa GD. Point-of-care ocular ultrasound for the diagnosis of retinal detachment: a systematic review and meta-analysis. *Acad Emerg Med*. 2019;26(8):931-9.
8. Lahham S, Shniter I, Thompson M, et al. Point-of-care ultrasonography in the diagnosis of retinal detachment, vitreous hemorrhage, and vitreous detachment in the emergency department. *JAMA Netw Open*. 2019;2(4):e192162-e192162.
9. Shah R, Rychwalski P, Kurzweil A, et al. Ocular point-of-care ultrasound: description of intermediate uveitis in an adolescent female. *Pediatr Emerg Care*. 2021;37(7):382-3.

A Case of a Carotid Cavernous Fistula

Rami H. Mahmoud, BS*
Brooke A. Hensley, MD†

*University of Miami Miller School of Medicine, Miami, Florida
†University of Miami Miller School of Medicine, Jackson Memorial Hospital,
Department of Emergency Medicine, Miami, Florida

Section Editor: Manish Amin, DO

Submission history: Submitted October 11, 2021; Revision received January 21, 2022; Accepted January 21, 2022

Electronically published April 25, 2022

Full text available through open access at http://escholarship.org/uc/uciem_cpem

DOI: 10.5811/cpem.2022.1.55033

Case Presentation: A 73-year-old male presented to the emergency department complaining of pain in his right eye for four weeks. He denied any trauma, and the pain was accompanied by ptosis, proptosis, swelling, redness, blurred vision, and a frontal headache. On examination, conjunctival arterialization was also appreciated. Magnetic resonance imaging and angiography showed evidence of a carotid cavernous fistula for which the patient underwent successful transvenous coiling and embolization.

Discussion: Carotid cavernous fistulas are classified as higher flow, direct fistulas or lower flow, indirect fistulas; the latter is more insidious in onset. Classic symptoms include conjunctival arterialization, proptosis, ptosis, palpebral edema, ocular palsy, vibratory sensation, elevated intraocular pressure without pupillary or visual acuity deficits, and headache. The treatment of choice is transvenous embolization. [Clin Pract Cases Emerg Med. 2022;6(2):183–185.]

Keywords: *carotid cavernous fistula; Indirect carotid cavernous fistula; cavernous sinus; proptosis; transvenous embolization.*

CASE PRESENTATION

A 73-year-old male with a past medical history of gastroesophageal reflux disease, hypertension, chronic obstructive pulmonary disease, and type 2 diabetes presented to the emergency department (ED) of our university hospital with a chief complaint of pain in his right eye for four weeks. This was accompanied by palpebral swelling, redness, blurred vision, and a frontal headache. The patient denied diplopia on presentation but slowly developed it over the course of his hospitalization. He also denied any trauma. He described the pain as constant, pulsatile and throbbing, and localized behind his right forehead; he denied prior episodes. The review of systems was otherwise negative, and social and family histories were noncontributory. The patient was taking 81 milligrams aspirin daily.

Physical examination revealed 20/20 and 20/25 visual acuity in the right and left eye, respectively. Intraocular pressure (reference range: 10-21 millimeters of mercury [mm Hg]) was 19 mm Hg in the right eye and 17 mm Hg in the left. The pupils were 3 mm and reactive to light bilaterally. Examination of the right eye was notable for scleral injection,

proptosis, ptosis, and conjunctival arterialization or hyperemia (Images 1 and 2). Proptosis of the right eye is better visualized from above (Image 2). Extraocular movements were intact, and visual fields were normal. There were no additional cranial nerve deficits, ocular palsies, or facial numbness; and the patient was otherwise neurologically intact throughout. A

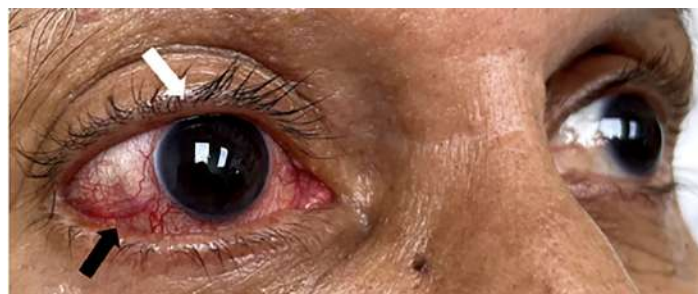

Image 1. Conjunctival arterialization (black arrow) and ptosis as well as palpebral edema (white arrow) of the right eye.

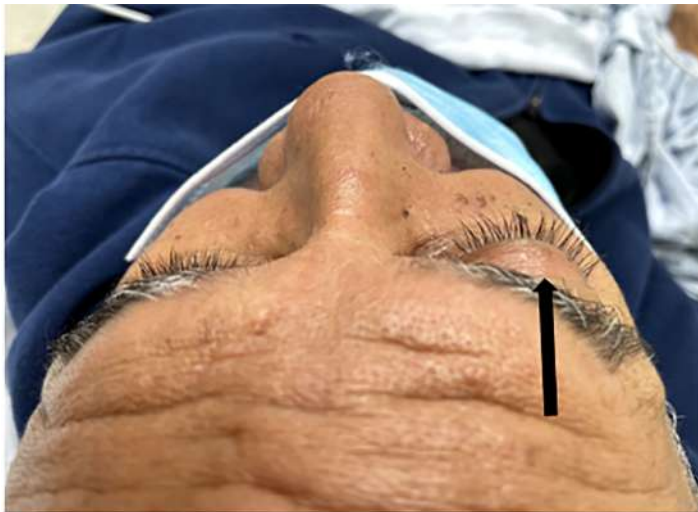

Image 2. Proptosis of the right eye as visualized from above (arrow) in a case of carotid-cavernous fistula.

computed tomography without contrast of the brain revealed mild involutional changes and mild periventricular hypodensities. Asymmetric enlargement of the right superior ophthalmic vein, fat stranding of the right orbit, proptosis of the right globe, and prominence of the right extraocular muscles were also appreciated. Magnetic resonance imaging (MRI) and angiography revealed the right middle meningeal artery merging into the right cavernous sinus, consistent with a cavernous carotid fistula (CCF).

DISCUSSION

A CCF is an abnormal arterial venous connection within the cavernous sinus. Located lateral to the sella turcica, the cavernous sinus is a trabeculated venous cavity housed by the dura matter.¹ Coursing through the cavernous sinus are several major neural and vascular structures, including the internal carotid artery (ICA) and cranial nerves III, IV, V1, V2, and VI.¹ Carotid cavernous fistulas are classified as direct, characterized by a direct connection of the ICA and the cavernous sinus. or indirect, lower flow fistulas, where communications between cavernous arterial branches and the cavernous sinus are established.^{1,2}

The Barrow classification, divided into four types (A through D), is used to specify the different anatomical variations of CCFs. Type A represents direct fistulas, and types B through D represent indirect fistulas.^{1,2,3,4} Type B is defined by connections between the dural branches of the ICA and the cavernous sinus, whereas type C fistulas are supplied by the dural branches of the external carotid artery (ECA).^{1,2,3,4} Angiography of the right and left ICAs in our patient revealed a Type D CCF, defined by involvement from the meningeal branches of the ICA and ECA.^{1,2,3,4}

Further classification of type D CCFs has been established with type D1 and D2 representing unilateral or bilateral arterial supply, respectively.³ Possible etiologies of indirect

CPC-EM Capsule

What do we already know about this clinical entity?

Carotid cavernous fistulas (CCF) may occur spontaneously or secondary to trauma. The treatment of choice is transvenous coiling and embolization.

What is the major impact of the image(s)?

These images bring attention to the presentation of CCFs, outlining characteristic clinical clues for timely diagnosis.

How might this improve emergency medicine practice?

Left unmanaged, CCFs may result in irreversible injury to the involved eye, highlighting the importance of a broad differential when presented with a common complaint (eye pain).

CCFs include hypertension, connective tissue disorders, and ICA dissections.² Conjunctival arterialization is classically present (Image 1), with other common findings that may include chemosis, proptosis, diplopia, and ophthalmoparesis.¹ The gold standard imaging modality for the diagnosis of CCFs is a cerebral angiogram; however, less invasive imaging via computed tomography (CT), MRI, or CT/MR angiography are typically performed first.¹ The goal of CCF treatment is to occlude the fistula while preserving flow through the ICA.^{1,3,4} Our patient underwent successful transvenous coiling and embolization of his CCF (Image 3), which is the preferred

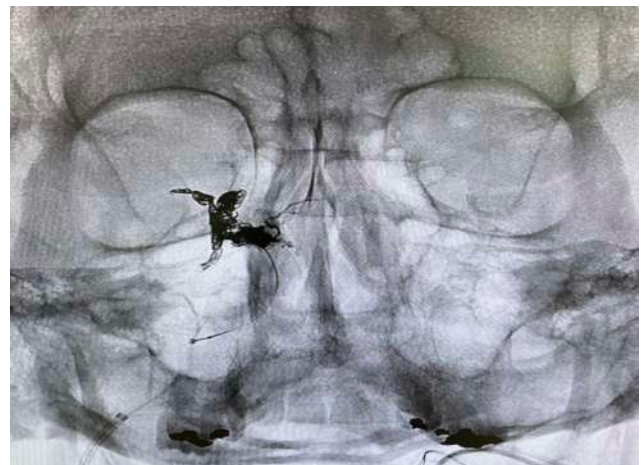


Image 3. Post-operative imaging revealing successful coiling and embolization of the CCF.

treatment modality for indirect CCFs.⁴ Postoperatively, the patient did well and had no complications.

The authors attest that their institution requires neither Institutional Review Board approval, nor patient consent for publication of this case report. Documentation on file.

Address for Correspondence: Rami H. Mahmoud, BS, University of Miami School of Medicine, 1600 NW 10th Ave #1140, Miami, FL 33136. Email: rhm74@med.miami.edu.

Conflicts of Interest: By the CPC-EM article submission agreement, all authors are required to disclose all affiliations, funding sources and financial or management relationships that could be perceived as potential sources of bias. The authors disclosed none.

Copyright: © 2022 Mahmoud. This is an open access article distributed in accordance with the terms of the Creative Commons

Attribution (CC BY 4.0) License. See: <http://creativecommons.org/licenses/by/4.0/>

REFERENCES

1. Ellis JA, Goldstein H, Connolly ES, et al. Carotid-cavernous fistulas. *Neurosurgical Focus*. 2012;32(5).
2. Henderson AD and Miller NR. Carotid-cavernous fistula: current concepts in aetiology, investigation, and management. *Eye (Lond)*. 2018;32(2):164-72.
3. Korkmazer B, Kocak B, Tureci E, et al. Endovascular treatment of carotid cavernous sinus fistula: a systematic review. *World J Radiol*. 2013;5(4):143-55.
4. Gonzalez Castro LN, Colorado RA, Botelho AA, et al. Carotid-cavernous fistula: a rare but treatable cause of rapidly progressive vision loss. *Stroke*. 2016;47(8):207-9.

Infected Urachal Cyst Masquerading as Acute Appendicitis on Point-of-care Ultrasound

Victoria Quinn, DO*
Francois Luks, MD†
Erika Constantine, MD‡

*Brown University Warren Alpert Medical School, Hasbro Children's Hospital, Department of Pediatrics, Providence, Rhode Island
†Brown University Warren Alpert Medical School, Hasbro Children's Hospital, Division of Pediatric Surgery, Providence, Rhode Island
‡Brown University Warren Alpert Medical School, Hasbro Children's Hospital, Department of Pediatrics and Pediatric Emergency Medicine, Providence, Rhode Island

Section Editor: Melanie Heniff, MD, JD

Submission history: Submitted October 30, 2021; Revision received January 13, 2022; Accepted January 21, 2022

Electronically published May 5, 2022

Full text available through open access at http://escholarship.org/uc/uciem_cpem

DOI: 10.5811/cpcem.2022.1.55243

CASE PRESENTATION: A seven-year-old male presented to the pediatric emergency department with one day of abdominal pain. His physical exam was significant for rebound, guarding, and tenderness in the right lower quadrant, and his labs demonstrated a leukocytosis. Both a point-of-care ultrasound and radiology-performed ultrasound were concerning for acute appendicitis with a periappendiceal abscess, but on emergent laparoscopy the patient was found to have an infected urachal cyst.

DISCUSSION: Infected urachal remnants are a rare but important cause of pediatric abdominal pain. In this case, inflammation surrounding the patient's midline urachal cyst triggered a serositis that involved the appendix and pulled the cyst to the right. This created a clinical and radiologic presentation similar to appendicitis. This atypical presentation of an already rare anomaly highlights the importance of maintaining a broad differential during the work-up of pediatric abdominal pain. [Clin Pract Cases Emerg Med. 2022;6(2):186–188.]

KEYWORDS: *urachal cyst; point-of-care ultrasound (POCUS); appendicitis; case report.*

CASE PRESENTATION

A seven-year-old male with no past medical history presented to the pediatric emergency department with one day of right lower abdominal pain. On arrival, he was uncomfortable, but afebrile and hemodynamically stable. Physical exam demonstrated periumbilical and right lower quadrant tenderness with rebound and guarding. Labs revealed a leukocytosis of $17.2 \times 10^9/\text{liter}$ (L) (reference range $4.4 - 11.0 \times 10^9/\text{L}$) and a negative urinalysis (no leukocytes esterase, nitrites, or blood). Point-of-care and radiology-performed ultrasounds both revealed a well-circumscribed, heterogeneous collection superior and to the right of the bladder, and closely approximated with the distal appendix (Video, Images 1 and 2). These findings, in addition to significant inflammatory changes and posterior acoustic

enhancement, were concerning for a perforated appendicitis with periappendiceal abscess. The patient was started on piperacillin/tazobactam and admitted to pediatric surgery.

At laparoscopy, a mildly inflamed appendix without perforation was visualized in the right lower quadrant, but further dissection revealed a significantly inflamed midline mass attached to the superior aspect of the bladder. The surgical team removed the appendix and mass, taking care to suture-ligate its connection with the dome of the bladder. Surgical pathology revealed that the mass was a urothelial-lined cyst consistent with a urachal remnant, with necrosis, hemorrhage, granulation tissue, and acute-on-chronic inflammation. Additionally, the appendix had serosal fibrinopurulent exudate and minimal transmural inflammation. The patient had an uneventful postoperative course.

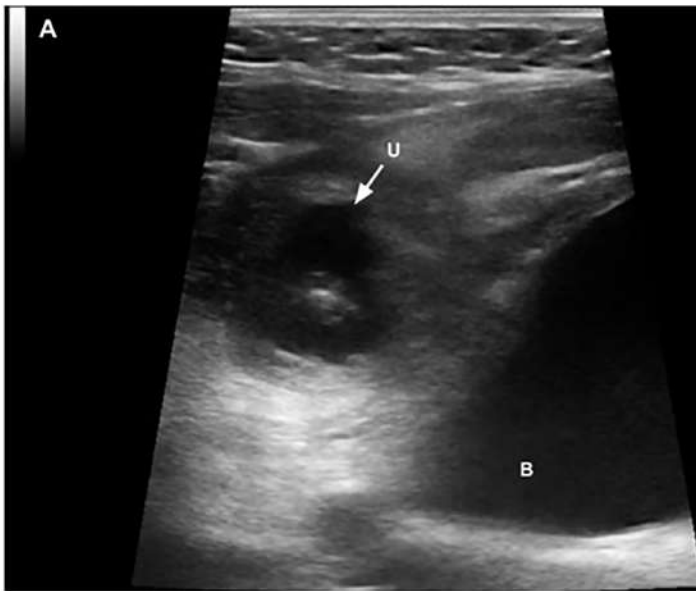


Image 1. A point-of-care ultrasound image obtained with a linear transducer in the transverse plane illustrates a heterogeneous collection superior and to the right of the urinary bladder surrounded by hyperechoic inflammatory changes. (U = urachal cyst; B = bladder)

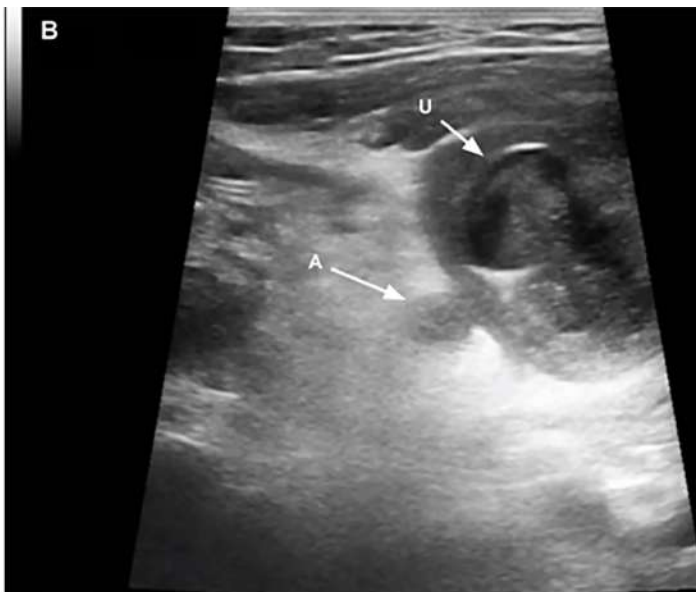

Image 2. Point-of-care ultrasound image obtained with a linear transducer in the transverse plane illustrating the proximity of the urachal cyst to the distal tip of the appendix. (U = urachal cyst, A = distal tip of the appendix).

DISCUSSION

Urachal remnants arise when the urachus, an embryonic tract between the allantois and the bladder, does not involute. The most common result is a urachal cyst, which forms when either end of the urachus seals off but the middle remains

CPC-EM Capsule

What do we already know about this clinical entity?

While urachal cysts are the most common urachal remnant, they are still rare and often go undiagnosed until they become infected or appear incidentally on imaging.

What is the major impact of the image(s)?

These images of a misdiagnosed urachal cyst demonstrate the variety of sonographic findings associated with infected urachal remnants.

How might this improve emergency medicine practice?

This case highlights the importance of imaging structures in multiple planes and maintaining a broad differential of pediatric abdominal pain in the emergency department.

patent, fills with fluid, and can become infected with urologic flora.¹ Most cysts are asymptomatic and go undiagnosed until they become infected or appear incidentally on imaging. Several case series have highlighted the utility of sonography as a screening modality for uncomplicated urachal remnants, but the diagnostic sensitivity and specificity, especially for infected remnants, remains undefined.² To our knowledge, there is only one other report demonstrating the utility of point-of-care ultrasound to diagnose infected urachal cysts.³

A urachal cyst typically appears on ultrasound and computed tomography as a non-communicating, fluid-filled pocket between the umbilicus and the bladder. When infected, these cysts are associated with a variety of sonographic and clinical findings based on their size, effect on surrounding tissue, and location of patient pain.^{1,4,5} While infected urachal cysts typically present with periumbilical pain because they are midline, surrounding inflammation can trigger a serositis that moves the cyst from midline. As demonstrated in this case, the resulting parietal peritonitis caused adhesion of the cyst to the tip of the appendix that pulled the cyst right, presented as right lower quadrant pain, and created sonographic findings that are more typically associated with appendicitis. This case demonstrates the importance of adequately imaging structures in multiple planes, as well as the importance of maintaining a broad differential during the work-up of pediatric abdominal pain to evaluate for common etiologies and rare congenital anomalies.

Video: Point-of-care ultrasound performed with a high-frequency linear probe demonstrating a heterogeneous collection superior and to the right of the urinary bladder, closely approximated with the distal tip of the appendix, and surrounded by significant inflammatory change and posterior acoustic enhancement.

This case, including its video and images, was presented at the Pediatric Emergency POCUS Educational Collaborative Virtual Session on February 25, 2021.

The authors attest that their institution requires neither Institutional Review Board approval, nor patient consent for publication of this case report. Documentation on file.

Address for Correspondence: Victoria Quinn, DO, Hasbro Children's Hospital, Department of Pediatrics, 593 Eddy St, Providence, RI 02903. Email: victoria_quinn@brown.edu.

Conflicts of Interest: By the CPC-EM article submission agreement, all authors are required to disclose all affiliations, funding sources and financial or management relationships that could be perceived as potential sources of bias. The authors disclosed none.

Copyright: © 2022 Quinn. This is an open access article distributed in accordance with the terms of the Creative Commons Attribution (CC BY 4.0) License. See: <http://creativecommons.org/licenses/by/4.0/>

REFERENCES

1. Allen JW, Song J, Velcek FT. Acute presentation of infected urachal cysts: case report and review of diagnosis and therapeutic interventions. *Pediatr Emerg Care*. 2004;20(2).
2. Fred Avni E, Matos C, Diard F, et al. Midline omphalovesical anomalies in children: contribution of ultrasound imaging. *Urol Radiol*. 1988;10(1).
3. Austin S, Jersey C, Soltis M, et al. Identification of an infected urachal cyst using point-of-care ultrasound. *Pediatr Emerg Care*. 2021;37(6).
4. Robert Y, Hennequin-Delerue C, Chaillet D, et al. Urachal remnants: sonographic assessment. *J Clin Ultrasound*. 1996;24(7).
5. Tazi F, Ahsaini M, Khalouk A, et al. Abscess of urachal remnants presenting with acute abdomen: a case series. *J Med Case Rep*. 2012;6:226.

Adult Presentation of Anomalous Pulmonary Artery from the Descending Aorta: A Rare Cause of Exertional Chest Pain

Ryan Offman, DO
Veronica Wilson, DO
Nicholas Adams, MD

Michigan State University College of Osteopathic Medicine, Mercy Health –
Muskegon, Department of Emergency Medicine, Muskegon, Michigan

Section Editor: Anna McFarlin, MD

Submission History: Submitted December 10, 2021; Revision received February 27, 2022; Accepted February 25, 2022

Electronically published April 25, 2022

Full text available through open access at http://escholarship.org/uc/uciem_cpchem

DOI: 10.5811/cpcem.2022.2.55637

Case Presentation: A 20-year-old female presented to the emergency department for evaluation of exertional, right-sided chest pain. The patient underwent a computed tomography angiogram of her chest as part of her workup, demonstrating the right lower-lobe pulmonary artery arising from the abdominal aorta.

Discussion: Anomalous pulmonary arterial supply is exceedingly rare. In adult patients, it is likely to be found incidentally during workup for more common medical conditions. Symptoms may include chest pain, exertional dyspnea, or hemoptysis. The high pressure of systemic blood in a low-pressure pulmonary system can result in right heart strain, pulmonary hypertension, and high-output cardiac failure. [Clin Pract Cases Emerg Med. 2022;6(2):189-191.]

Keywords: *anomalous pulmonary artery; pulmonary hypertension; chest pain.*

CASE PRESENTATION

A 20-year-old female with no previous past medical history, other than a recent evaluation for Ehlers-Danlos syndrome, presented to the emergency department for chest pain. She described exertional right-sided chest pain increasing over the previous two months. Vital signs were stable, and her physical exam was unrevealing. Electrocardiogram demonstrated poor R-wave progression in the precordial leads. Laboratory testing included an unremarkable complete blood count, comprehensive metabolic panel, and troponin. Chest radiograph was normal. Her history of possible Ehlers-Danlos syndrome prompted the emergency physician to complete a computed tomography angiogram (CTA) of the chest and abdomen for consideration of aortic dissection. The CTA revealed a pulmonary artery originating from the descending aorta above the celiac plexus, supplying the right lower lobe of the lung (Images 1 and 2). Outpatient follow-up with primary care, cardiology, and cardiothoracic surgery was ensured. Outpatient echocardiogram revealed mild tricuspid regurgitation. Definitive management of the anomalous vessel was accomplished by endovascular closure

using a 10-millimeter (mm) x 7 mm Amplatzer vascular plug (Abbott Laboratories, Abbott Park, IL).

DISCUSSION

An anomalous origin of a pulmonary artery branch is a rare congenital abnormality that comprises 0.12% of all congenital heart defects.¹ The majority of reported cases involve left pulmonary arteries originating from the ascending aorta. Less frequently, anomalous pulmonary arteries have been described arising from the descending aorta and occasionally the celiac artery.^{2,3} Our patient's specific congenital abnormality is unusual because her pulmonary artery originates from the descending aorta, supplying her right lower lobe.

Symptoms such as chest pain, hemoptysis, and exertional dyspnea may help identify patients with anomalous pulmonary vasculature. The high pressure of systemic blood in a low-pressure pulmonary system can result in right heart strain, pulmonary hypertension, and high-output cardiac failure.⁴ However, most cases are discovered in utero and are associated with other congenital anomalies. Cases that are

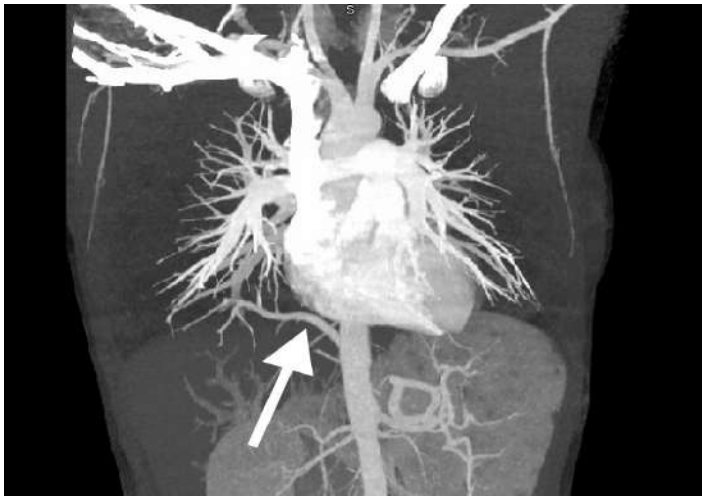

Image 1. Computed tomography angiogram demonstrating the right lower lobe pulmonary artery arising from the descending aorta beyond the level of the diaphragm (arrow).

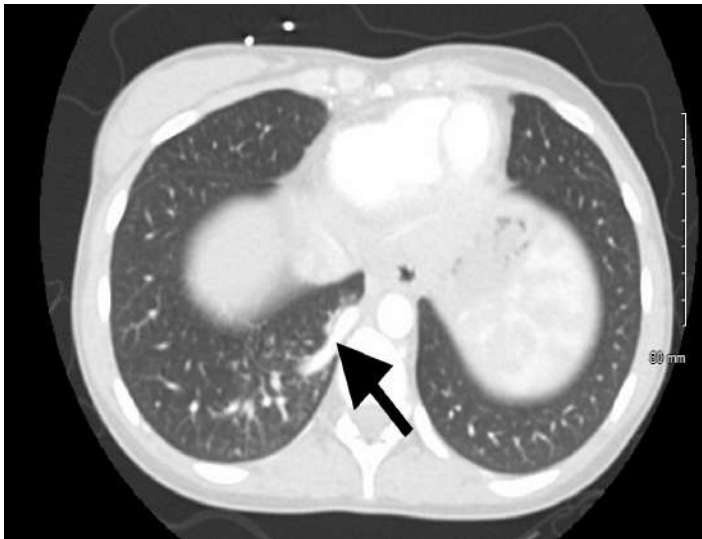


Image 2. There is no evidence of pulmonary embolism or aortic dissection on the computed tomography angiogram. Arrow shows anomalous pulmonary artery originating from descending aorta.

discovered in early childhood or adolescence typically present with suboptimal weight gain, heart murmur, or abnormal chest radiograph (revealing an enlarged cardiac silhouette or persistent retrocardiac/lower lobe opacity).³

Understanding the significance of congenital anomalous pulmonary arteries is imperative for emergency physicians to aid in identification of this abnormality. If the patient is hemodynamically stable, patients may be followed closely as an outpatient with cardiothoracic surgery and cardiology. Surgical treatment is reserved for those with severe symptoms or those who have developed pulmonary hypertension to prevent cardiomyopathy and valvular disease. Endovascular embolization has been successful in certain cases.⁵

CPC-EM Capsule

What do we already know about this clinical entity?

Anomalous pulmonary artery is a rare congenital disease that typically presents early in life with congestive heart failure.

What is the major impact of the image(s)?

These images are an example of a rare disease entity as a cause of chest pain and respiratory distress, which are common presenting symptoms in the emergency department.

How might this improve emergency medicine practice?

Although rarely discovered in adulthood, recognition of anomalous pulmonary arterial supply can lead to expedited referral and definitive management.

The authors attest that their institution requires neither Institutional Review Board approval nor patient consent for publication of this case report. Documentation on file.

Address for Correspondence: Ryan Offman, MD, Mercy Health – Muskegon, Department of Emergency Medicine, 1500 E Sherman Blvd, Muskegon, MI 49444. Email: Ryan.offman@mercyhealth.com

Conflicts of Interest: By the CPC-EM article submission agreement, all authors are required to disclose all affiliations, funding sources and financial or management relationships that could be perceived as potential sources of bias. The authors disclosed none.

Copyright: © 2022 Offman. This is an open access article distributed in accordance with the terms of the Creative Commons Attribution (CC BY 4.0) License. See: <http://creativecommons.org/licenses/by/4.0/>

REFERENCES

1. Kutsche LM and Van Mierop LH. Anomalous origin of a pulmonary artery from the ascending aorta: associated anomalies and pathogenesis. *Am J Cardiol.* 1988;61(10):850-6.
2. Moreau de Bellaing A, Bonnet D, Houyel L. Abnormal origin of the left pulmonary artery from the descending aorta and heterotaxy syndrome: an undescribed phenotypic association. *Cardiol Young.* 2021;31(7):1193-6.
3. Liu WL, Lin MC, Jan SL. Isolated partial anomalous origin of a branch pulmonary artery from the descending aorta. *Cardiol Young.* 2021. In press.

4. Miller EJ, Singh SP, Cerfolio RJ, et al. Pryce's type 1 pulmonary intralobar sequestration presenting with massive hemoptysis. *Ann Diagn Pathol.* 2001;5(2):91-5.
5. Cho MJ, Kim DY, Kim SC, et al. Embolization versus surgical resection of pulmonary sequestration: clinical experiences with a thoracoscopic approach. *J Pediatr Surg.* 2012;47(12):2228-33.

Simultaneous Bilateral Quadriceps Tendon Rupture in an Adult Man

Marla C. Doehring, MD*
Steven L. Propst, MD†

*Indiana University, Department of Emergency Medicine, Indianapolis, Indiana
†University of Missouri, Department of Emergency Medicine, Springfield, Missouri

Section Editor: Melanie Heniff, MD, JD

Submission History: Submitted December 13, 2021; Revision received February 26, 2022; Accepted March 09, 2022

Electronically published May 5, 2022

Full text available through open access at http://escholarship.org/uc/uciem_cpem

DOI: 10.5811/cpcem.2022.3.55675

Case Presentation: A previously healthy 45-year-old man presented to the emergency department with bilateral knee pain and inability to extend his knees after a slip and fall on ice. The clinical diagnosis of bilateral quadriceps tendon rupture was confirmed by computed tomography (CT) of bilateral knees. The patient underwent successful operative repair the following day.

Discussion: Bilateral quadriceps tendon rupture is rare and can be difficult to diagnose due to the impossibility of comparing the affected to the unaffected limb. Plain radiographs are usually not helpful, but ultrasound, CT, and magnetic resonance imaging may be used to confirm the clinical diagnosis. [Clin Pract Cases Emerg Med. 2022;6(2):192–193.]

Keywords: case report; quadriceps tendon rupture; bilateral.

CASE PRESENTATION

A 45-year-old man with no significant past medical or surgical history presented to the emergency department after a mechanical fall. He took no daily medications and had a body mass index (BMI) of 44.2 kilograms per squared meter. The patient slipped on ice while walking and felt “pops” over both knees while falling. Exam demonstrated bilateral knees with no obvious swelling or bruising. He had good passive range of motion and mild tenderness to palpation superior to the patella on both knees. The patient was unable to perform straight leg raise with either leg.

Plain radiographs of bilateral knees demonstrated mild soft tissue swelling over bilateral superior patellae but no other evidence of injury (Image 1). Computed tomography (CT) of bilateral knees confirmed the clinical diagnosis of simultaneous bilateral quadriceps tendon rupture (Images 2 and 3). Near-complete tears of both distal quadriceps tendons were surgically repaired the following day.

DISCUSSION

Bilateral extensor mechanism rupture is rare and can be difficult to diagnose, with an initial missed rate reported up to 30-50%.^{1,2} Patients at risk usually have underlying comorbidities such as chronic renal disease, diabetes mellitus, rheumatologic

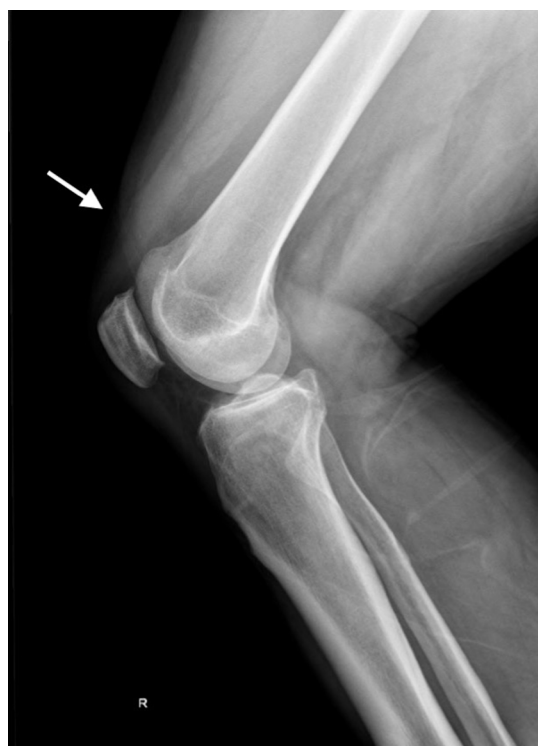

Image 1. Plain radiograph of the right knee demonstrating mild suprapatellar soft tissue swelling (arrow).

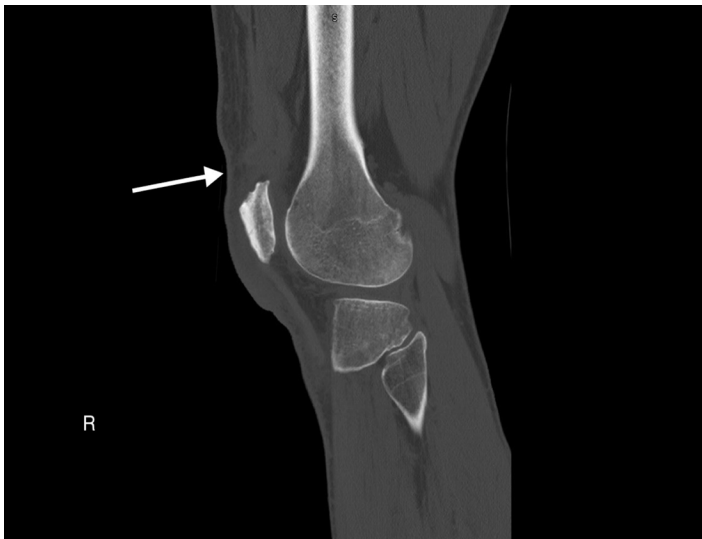

Image 2. Computed tomography of right knee demonstrating near-complete tear of quadriceps tendon with retraction of the central portion of the tendon (arrow).

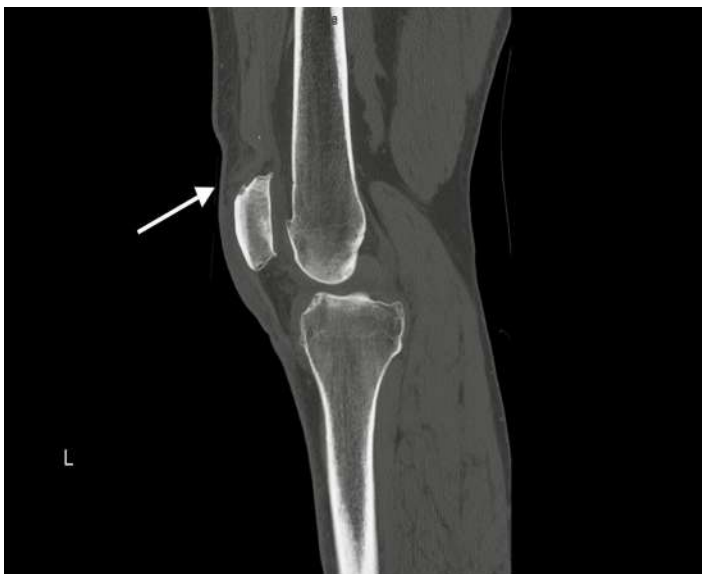

Image 3. Computed tomography of left knee demonstrating near-complete tear of quadriceps tendon with retraction of the central portion of the tendon (arrow).

disorder, chronic steroid use, or obesity. This patient had an elevated BMI but no other risk factors. The classic triad for clinical diagnosis of quadriceps tendon rupture is knee pain, inability to actively extend knee, and palpable suprapatellar gap.^{2,3}

Tendon rupture often occurs due to indirect trauma. While attempting to regain balance the quadriceps rapidly contracts with the knee flexed. Rupture is likely from the maximum quadriceps contraction rather than the fall itself.⁴ The diagnosis is clinical, and plain films are rarely diagnostic. Ultrasound, CT, or magnetic resonance imaging may be useful to confirm the clinical diagnosis. In cases of bilateral quadriceps tendon rupture, the initial clinical diagnosis is

CPC-EM Capsule

What do we already know about this clinical entity?

Simultaneous bilateral quadriceps tendon rupture is a rare event, especially in patients without significant comorbidities.

What is the major impact of the image(s)?

Plain radiographs are rarely diagnostic but ultrasound, computed tomography, or magnetic resonance imaging may be helpful to make the diagnosis in the emergency department.

How might this improve emergency medicine practice?

Include bilateral quadriceps tendon rupture in the differential diagnosis when evaluating a patient whose clinical presentation is consistent with this rare entity.

made more challenging by the impossibility of comparing the affected limb to the unaffected limb. Treatment is surgical fixation followed by immobilization and physical therapy.²

The authors attest that their institution does not require Institutional Review Board approval for publication of this case report. Documentation on file.

Address for Correspondence: Marla C. Doehring, MD, Indiana University, Department of Emergency Medicine, 720 Eskenazi Ave, Indianapolis, IN 46202. Email: mdoehrin@iu.edu

Conflicts of Interest: By the CPC-EM article submission agreement, all authors are required to disclose all affiliations, funding sources and financial or management relationships that could be perceived as potential sources of bias. The authors disclosed none.

Copyright: © 2022 Doehring. This is an open access article distributed in accordance with the terms of the Creative Commons Attribution (CC BY 4.0) License. See: <http://creativecommons.org/licenses/by/4.0/>

REFERENCES

1. Neubauer T, Wagner M, Potschka T, et al. Bilateral, simultaneous rupture of the quadriceps tendon: a diagnostic pitfall? Report of three cases and meta-analysis of the literature. *Knee Surg Sports Traumatol Arthrosc.* 2007;15(1):43–53.
2. Camarda L, D'Arienzo, A, Morello S, et al. Bilateral ruptures of the extensor mechanism of the knee: a systematic review. *J Orthop.* 2017;14(4):445–53.
3. Shah MK. Simultaneous bilateral rupture of quadriceps tendons: analysis of risk factors and associations. *South Med J.* 2002;95(8):860–6.
4. Hak DJ, Sanchez A, Trobisch P. Quadriceps tendon injuries. *Orthopedics.* 2010;33(1):40–6.

Brugada-like ECG Changes After Conducted Electrical Weapon Exposure: A Case Report

Christopher Trumbetta, DO
Michael Galuska, MD

Conemaugh Memorial Medical Center, Department of Emergency Medicine,
Johnstown, Pennsylvania

Section Editor: John Ashurst, DO

Submission History: Submitted April 21, 2021; Revision received May 3, 2021; Accepted June 10, 2021

Electronically published April 25, 2022

Full text available through open access at http://escholarship.org/uc/uciem_cpem

DOI: 10.5811/cpem.2021.6.52893

Introduction: A 38-year-old with suicidal ideation and alcohol intoxication received conducted energy from a conducted energy weapon (CEW) and subsequently was found to have a transient electrocardiogram (ECG) abnormality consistent with Brugada waveform that resolved over a period of three hours.

Case Report: A 38-year-old male with no pertinent medical history presented with suicidal ideation and alcohol intoxication after an altercation with the police. The patient received two CEW exposures during an encounter with law enforcement prior to transport to the emergency department. He was asymptomatic, but an ECG was performed as part of the triage process given his reported CEW exposure. His initial ECG showed ST-segment and T-wave changes in the precordial leads similar to those found in Brugada syndrome. After a three-hour period of observation and resolution of the patient's alcohol intoxication, a repeat ECG was performed that showed resolving Brugada morphology.

Conclusion: Review of the literature surrounding the safety profile associated with CEW exposure shows few if any documented concerning cardiac electrophysiology changes and suggests that routine electrocardiographic studies or monitoring is not required. This case presents an isolated but interesting instance of a transient ECG abnormality associated with a CEW exposure. [Clin Pract Cases Emerg Med. 2022;6(2):194–197.]

Keywords: *conducted energy weapon; Brugada syndrome; electrocardiogram.*

INTRODUCTION

Exposure to a conducted energy weapon (CEW) in the field has been shown to result in little risk of serious medical injury to patients in multiple studies conducted over the past 15 years.¹ Two recent meta-analyses including 37 appropriate articles and studies revealed zero cases of significant electrocardiographic changes after exposure to a CEW.^{1,2} These studies and the subsequent reviews have led to recommendations that no routine electrocardiogram (ECG) or cardiac enzyme evaluation are indicated in asymptomatic patients after CEW exposure. With this prior evidence in mind, we present a case of an asymptomatic patient status post CEW exposure with an ECG revealing significant

electrocardiographic changes similar in morphology to Brugada syndrome.

CASE REPORT

A 38-year-old male with a past medical history of mild, intermittent asthma presented with suicidal ideation and alcohol intoxication. Reports from the local police department transporting the patient to the emergency department (ED) indicated he was uncooperative in the field and required two CEW exposures for officers to safely transport him. The patient did admit to telling police to “end his life” by shooting him but also admitted to alcohol consumption earlier in the evening and a domestic dispute

causing him to be emotional. He did regret those statements and denied any suicidal or homicidal ideation at time of initial evaluation. The patient denied any symptoms of chest pain and noted no family history of sudden cardiac death.

Initial evaluation included a negative physical examination. An ECG performed as part of the triage process, given the reported CEW exposure, revealed Brugada type II pattern ST-segment and T wave changes in precordial leads (Image 1). This initial ECG was performed approximately one hour post CEW exposure. Laboratory studies included a negative complete blood count, complete metabolic panel, and troponin. Laboratory studies were significant for an ethanol level of 143 milligrams per deciliter (mg/dL) (reference: less than 10 mg/dL).

The patient was observed in the ED under suicide precautions until he was no longer intoxicated. A repeat ECG after the three-hour observation period showed improvement and resolving Brugada-like changes noted previously (Image 2). He continued to be physically asymptomatic and denied suicidal or homicidal ideation and was able to demonstrate clear and coherent thought. Psychiatry was consulted, and after evaluation determined that the patient was no longer intoxicated and was competent to make his own medical decisions. The psychiatry consult also determined that he was not a significant danger to himself or anyone else and recommended further evaluation with psychiatry on an outpatient basis. At that time, he was discharged to home in stable condition with psychiatry and family practice follow-up.

DISCUSSION

Evaluation of patients after encounters with law enforcement is common in the ED. On certain occasions, patients are exposed to CEWs to be safely subdued before transport to the ED. A CEW causes pain and temporary neuromuscular incapacitation by delivering a closed circuit of energy to the patient by direct contact of two electrode

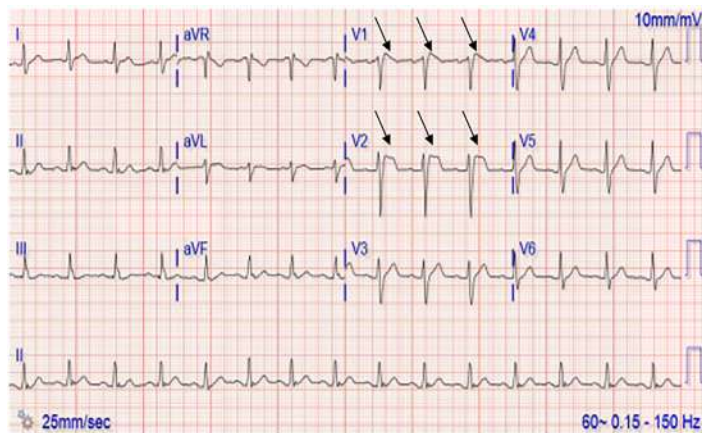


Image 1. Patient's initial electrocardiogram showing ST-segment and T-wave changes in leads V1 and V2 (arrows) consistent with a Brugada type II pattern without a prior for comparison.

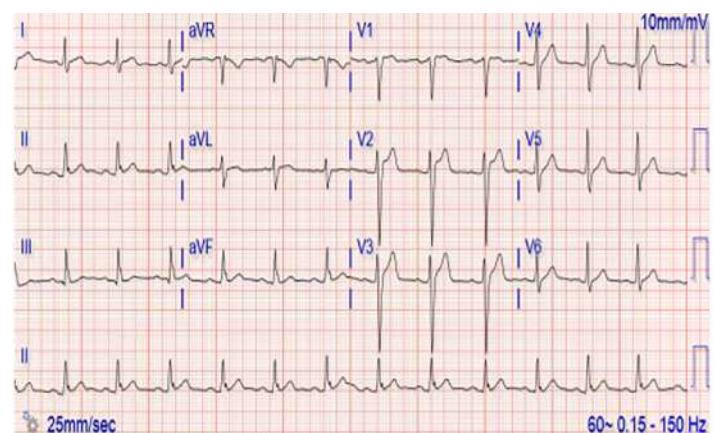


Image 2. Patient's repeat electrocardiogram after a three-hour observation period showing persistent J point elevation but resolving ST-segment "saddleback" elevation in leads V1 and V2.

CPC-EM Capsule

What do we already know about this clinical entity?

The use of conducted electrical weapons (CEW) to subdue persons in the field has largely been found to be safe, specifically regarding cardiovascular physiology.

What makes this presentation of disease reportable?

Recent meta-analysis reviews have found very little evidence of electrocardiographic changes documented after CEW exposure.

What is the major learning point?

This is an isolated but potentially significant case of a transient Brugada type electrocardiographic pattern in a patient after CEW exposure.

How might this improve emergency medicine practice?

This case may lead the emergency physician to at least consider cardiac electrophysiology pathologies after CEW exposure in the appropriate clinical setting.

Early studies of the safety of CEW exposure included investigation of whether the energy could potentiate cardiac dysrhythmias.² There were isolated case reports of cardiac dysrhythmias following CEW exposure, including one from a prehospital report in 2005 in which a young, healthy patient was found to be in cardiopulmonary arrest with a ventricular fibrillation rhythm shortly after exposure.⁶ However, numerous studies investigating the safety of CEW exposure have demonstrated little to no cardiovascular risk and few, if any, documented cardiac dysrhythmias. This finding was confirmed in a recent meta-analysis by Vilke et al¹ that reviewed the results of 37 studies conducted from 1998–2018 on the safety of CEW exposure and found zero incidence of immediate or delayed cardiac ischemia or dysrhythmias.¹ Based on their meta-analysis, the authors advised against routine electrocardiographic study on an asymptomatic patient with recent CEW exposure.¹

Here we present a case in which transient ECG changes suggestive of an abnormal QRS conduction consistent with Brugada pattern were found shortly after CEW exposure. Brugada syndrome is a genetic condition most commonly associated with sodium channelopathies that is linked to polymorphic ventricular tachycardias and sudden cardiac death.⁷ This is not to be confused with a Brugada pattern, which is described as ECG findings not associated with any cardiac symptoms.⁷ The ECG findings classically described with a Brugada pattern are ST-T segment changes in V1 and V2 generally broken down into two types, I and II.⁸ Type I demonstrates a “coved,” elevated but downward sloping ST segment that transitions into an inverted T wave, while type II demonstrates a “saddleback” elevated ST segment with either an upright or inverted T wave.⁹ The ECG changes in this case most closely represent a type II Brugada pattern, with clearly identifiable “saddleback” ST-segment elevation in lead V2 of Image 1. While lead V1 of image 1 does appear to have a more “coved” appearance to the ST-segment elevation, there is no clear T-wave inversion, a distinctive feature of a type I Brugada pattern.

The patient who presented with Brugada-type waveform documented in this case did have an initial ethanol level of 143 mg/dL but was calm, cooperative, oriented to person, place, month and date, and had no clinical signs of acute intoxication and a negative urine drug analysis. He had no family history of sudden cardiac death and his presentation was not associated with any clinical signs or symptoms of cardiac ischemia or elevation in serum cardiac biomarkers. In addition, the ECG changes spontaneously improved and began resolving after a period of observation, and no ventricular dysrhythmias were noted while the patient was observed on the cardiac monitor while in the ED. It is worth noting that there are several other well documented causes of transient Brugada patterns including ethanol ingestion, cocaine ingestion, cardiac ischemia, and fever. In addition, the current literature on CEW exposure supports the notion

that cardiac dysrhythmias are rare. While our patient did develop a transient Brugada pattern, we never identified a cardiac dysrhythmia. Nonetheless, the temporal relationship with recent CEW exposure and transient Brugada pattern is interesting and worth adding to the evolving picture of the safety profile associated with these weapons.

CONCLUSION

Evaluation of patients in the ED setting after exposure to a conducted electrical weapon is common. Studies over the past 20 years on the potential harmful effects of CEW exposure suggest that no cardiovascular pathology is imposed on the patient and that routine electrocardiographic studies or monitoring are not required. The case presented here is an isolated but interesting instance of a transient ECG abnormality associated with CEW exposure.

The Institutional Review Board approval has been documented and filed for publication of this case report.

Address for Correspondence: Christopher Trumbetta, DO, Conemaugh Memorial Medical Center, Department of Emergency Medicine, 1086 Franklin Street, Johnstown, PA 15905. Email: ctrumbet@conemaugh.org.

Conflicts of Interest: By the *CPC-EM* article submission agreement, all authors are required to disclose all affiliations, funding sources and financial or management relationships that could be perceived as potential sources of bias. The authors disclosed none.

Copyright: © 2022 Trumbetta. This is an open access article distributed in accordance with the terms of the Creative Commons Attribution ([CC BY 4.0](https://creativecommons.org/licenses/by/4.0/)) License. See: <http://creativecommons.org/licenses/by/4.0/>

REFERENCES

1. Vilke G, Chan T, Bozeman WP, et al. Emergency department evaluation after conducted energy weapon use: review of the literature for the clinician. *J Emerg Med.* 2019;57(5):740-6.
2. Vilke GM, Bozeman WP, Chan TC. Emergency department evaluation after conducted energy weapon use: review of the literature for the clinician. *J Emerg Med.* 2011;40(5):598-604.
3. Strote J and Hutson HR. Emergency department evaluation of conducted energy weapon (CEW)-injured patients. *J Emerg Med.* 2014;46(4):533.
4. Ho JD, Miner JR, Lakireddy DR, et al. Cardiovascular and physiologic effects of conducted electrical weapon discharge in resting adults. *Acad Emerg Med.* 2006;13(6):589-95.
5. Fish RM and Geddes LA. Effects of stun guns and tasers. *Lancet.* 2001;358(9283):687.
6. Kim PJ and Franklin WH. Ventricular fibrillation after stun-gun discharge. *N Engl J Med.* 2005;353(9):958-9.

7. Brugada J, Campuzano O, Arbelo E, et al. Present status of Brugada syndrome: JACC state-of-the-art review. *J Am Coll Cardiol*. 2018;72(9):1046.
8. Bayés de Luna A, Brugada J, Baranchuk A, et al. Current electrocardiographic criteria for diagnosis of Brugada pattern: a consensus report. *J Electrocardiol*. 2012;45(5):433-42.
9. Antzelevitch C, Brugada P, Borggrefe M, et al. Brugada syndrome: report of the second consensus conference: endorsed by the Heart Rhythm Society and the European Heart Rhythm Association. *Circulation*. 2005;111(5):659.

**JOIN
CAL/AAEM!**



CALAAEM

CALIFORNIA CHAPTER DIVISION OF THE
AMERICAN ACADEMY OF EMERGENCY MEDICINE

*Championing
individual physician rights
and workplace fairness*

BENEFITS

- *Western Journal of Emergency Medicine* Subscription
- CAL/AAEM News Service email updates
- Discounted AAEM pre-conference fees
- And more!

CAL/AAEM NEWS SERVICE

- Healthcare industry news
- Public policy
- Government issues
- Legal cases and court decisions

In collaboration with our official journal

WestJEM Integrating Emergency Care
with Population Health



[FACEBOOK.COM/CALAAEM](https://www.facebook.com/CALAAEM)



FOLLOW US @CALAAEM

[HTTP://WWW.CALAAEM.ORG](http://www.calaaem.org)

The background is a dark, almost black, color. It is decorated with numerous yellow starburst patterns of varying sizes, each consisting of multiple thin lines radiating from a central point. There are also several small, solid yellow stars scattered across the background. The overall effect is that of a night sky filled with fireworks or stars.

CALIFORNIA ACEP

50

ANNIVERSARY