

# CPC Emergency Medicine

Volume 7, Number 3, August 2023

Open Access at [www.cpcem.org](http://www.cpcem.org)

ISSN: 2474-252X

## *Clinical Practice and Cases in Emergency Medicine*

*In Collaboration with the Western Journal of Emergency Medicine*

### Clinicopathological Cases from the University of Maryland

- 121 **57-Year-Old Male Veteran with Recurrent Fevers**  
*Chu E, King SA, Bontempo LJ, Windsor TA*

### Case Series

- 127 **Point-of-care Ultrasound Identification of Tension Hydrothorax in the Emergency Department: A Case Series**  
*Clark A, Lampley P, Tran VH*
- 132 **Erector Spinae Plane Block Performed in the Emergency Department for Abdominal Pain: A Case Series**  
*Parsons-Moss S, Martin D, Condori M, Dreyfuss A*

### Case Reports

- 136 **Extreme Paralysis Following Rocuronium Administration in a Myasthenia Gravis Patient: A Case Report**  
*Billups K, Collins C, Weber A*
- 140 **Internal Carotid Artery Occlusion as a Rare Presentation of Infectious Endocarditis: A Case Report**  
*Wolf T, Dewey K, Adler D*
- 144 **Implanted Progestin Causing Pain and Psychiatric Disturbances in Porphyrria Attack: A Case Report**  
*Misek RK, Riitano MF*
- 148 **A Previously Healthy Infant with Lemierre Syndrome in the Emergency Department: Case Report**  
*Kosoko AA, Clement OO*
- 153 **Posterior Reversible Encephalopathy Syndrome in a Patient with Septic Shock: A Case Report**  
*Boccio E, Mastroianni F, Slesinger T*

*Contents continued on page iii*



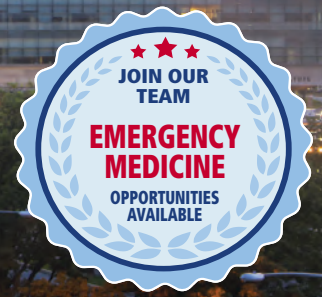UC Irvine Health





**ACOEPE stands with all emergency  
physicians and providers on the  
front line. We thank you for your  
tireless work and effort.**





# Penn State Health Emergency Medicine

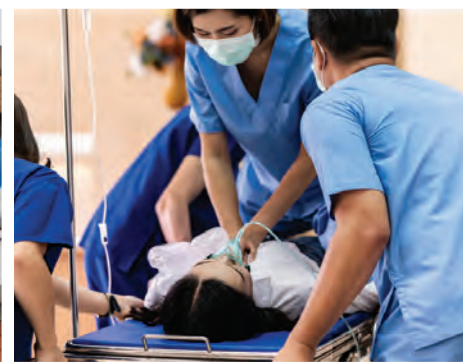## About Us:

Penn State Health is a multi-hospital health system serving patients and communities across central Pennsylvania. We are the only medical facility in Pennsylvania to be accredited as a Level I pediatric trauma center and Level I adult trauma center. The system includes Penn State Health Milton S. Hershey Medical Center, Penn State Health Children’s Hospital, and Penn State Cancer Institute based in Hershey, Pa.; Penn State Health Hampden Medical Center in Enola, Pa.; Penn State Health Holy Spirit Medical Center in Camp Hill, Pa.; Penn State Health St. Joseph Medical Center in Reading, Pa.; Penn State Health Lancaster Pediatric Center in Lancaster, Pa.; Penn State Health Lancaster Medical Center (opening fall 2022); and more than 3,000 physicians and direct care providers at more than 126 outpatient practices in 94 locations. Additionally, the system jointly operates various health care providers, including Penn State Health Rehabilitation Hospital, Hershey Outpatient Surgery Center, Hershey Endoscopy Center, Horizon Home Healthcare and the Pennsylvania Psychiatric Institute.

We foster a collaborative environment rich with diversity, share a passion for patient care, and have a space for those who share our spark of innovative research interests. Our health system is expanding and we have opportunities in both academic hospital as well community hospital settings.

## Benefit highlights include:

- Competitive salary with sign-on bonus
- Comprehensive benefits and retirement package
- Relocation assistance & CME allowance
- Attractive neighborhoods in scenic central Pa.



**PennState Health**

**FOR MORE INFORMATION PLEASE CONTACT:**

Heather Peffley, PHR CPRP - Penn State Health Lead Physician Recruiter

[hpeffley@pennstatehealth.psu.edu](mailto:hpeffley@pennstatehealth.psu.edu)

Penn State Health is fundamentally committed to the diversity of our faculty and staff. We believe diversity is unapologetically expressing itself through every person’s perspectives and lived experiences. We are an equal opportunity and affirmative action employer. All qualified applicants will receive consideration for employment without regard to age, color, disability, gender identity or expression, marital status, national or ethnic origin, political affiliation, race, religion, sex (including pregnancy), sexual orientation, veteran status, and family medical or genetic information.

# Clinical Practice and Cases in Emergency Medicine

Indexed in PubMed and full text in PubMed Central

**Rick A. McPheeters, DO, Editor-in-Chief**  
Kern Medical/UCLA- Bakersfield, California

**R. Gentry Wilkerson, MD, Deputy Editor**  
University of Maryland School of Medicine

**Mark I. Langdorf, MD, MHPE, Senior Associate Editor**  
University of California, Irvine School of Medicine- Irvine, California

**Shahram Lotfipour, MD, MPH, Senior Associate Editor**  
University of California, Irvine School of Medicine- Irvine, California

**Shadi Lahham, MD, MS, Associate Editor**  
Kaiser Permanente- Orange County, California

**Manish Amin, DO, Associate Editor**  
Kern Medical/UCLA- Bakersfield, California

**John Ashurst, DO, Decision Editor/ ACOEP Guest Editor**  
Kingman Regional Health Network, Arizona

**Anna McFarlin, MD, Decision Editor**  
Louisiana State University Health Science Center- New Orleans, Louisiana

**Lev Libet, MD, Decision Editor**  
Kern Medical/UCLA- Bakersfield, California

**Christopher Sampson, MD, Decision Editor**  
University of Missouri- Columbia, Missouri

**Joel Moll, MD, Decision Editor**  
Virginia Commonwealth University School of Medicine- Richmond, Virginia

**Steven Walsh, MD, Decision Editor**  
Einstein Medical Center Philadelphia-Philadelphia, Pennsylvania

**Melanie Heniff, MD, JD, Decision Editor**  
University of Indiana School of Medicine- Indianapolis, Indiana

**Austin Smith, MD, Decision Editor**  
Vanderbilt University Medical Center-Nashville, Tennessee

**Rachel A. Lindor, MD, JD, Decision Editor**  
Mayo Clinic College of Medicine and Science

**Jacqueline K. Le, MD, Decision Editor**  
Desert Regional Medical Center

**Christopher San Miguel, MD, Decision Editor**  
Ohio State University Wexner Medical Center

Amin A. Kazzi, MD, MAAEM  
The American University of Beirut, Beirut,  
Lebanon

Anwar Al-Awadhi, MD  
Mubarak Al-Kabeer Hospital, Jabriya,  
Kuwait

Arif A. Cevik, MD  
United Arab Emirates University  
College of Medicine and Health Sciences, Al  
Ain, United Arab Emirates

Abhinandan A. Desai, MD  
University of Bombay Grant Medical  
College, Bombay, India

Bandr Mzahim, MD  
King Fahad Medical City, Riyadh, Saudi  
Arabia

Barry E. Brenner, MD, MPH  
Case Western Reserve University

Brent King, MD, MMM  
University of Texas, Houston

Daniel J. Dire, MD  
University of Texas Health Sciences Center  
San Antonio

David F.M. Brown, MD  
Massachusetts General Hospital/Harvard  
Medical School

Edward Michelson, MD  
Texas Tech University

Edward Panacek, MD, MPH  
University of South Alabama

Erik D. Barton, MD, MBA  
Icahn School of Medicine, Mount Sinai,  
New York

Francesco Dellacorte, MD  
Azienda Ospedaliera Universitaria "Maggiore  
della Carità," Novara, Italy

Francis Counselman, MD  
Eastern Virginia Medical School

Gayle Galleta, MD  
Sørlandet Sykehus HF, Akershus  
Universitetssykehus, Lorenskog, Norway

Hjalti Björnsson, MD  
Icelandic Society of Emergency Medicine

Jacob (Kobi) Peleg, PhD, MPH  
Tel-Aviv University, Tel-Aviv, Israel

Jonathan Olshaker, MD  
Boston University

Katsuhiko Kanemaru, MD  
University of Miyazaki Hospital, Miyazaki, Japan

Khrongwong Musikatavorn, MD  
King Chulalongkorn Memorial Hospital,  
Chulalongkorn University, Bangkok,  
Thailand

Leslie Zun, MD, MBA  
Chicago Medical School

Linda S. Murphy, MLIS  
University of California, Irvine School of  
Medicine Librarian

Nadeem Qureshi, MD  
St. Louis University, USA  
Emirates Society of Emergency Medicine,  
United Arab Emirates

Niels K. Rathlev, MD  
Tufts University School of Medicine

Pablo Aguilera Fuenzalida, MD  
Pontificia Universidad Católica de Chile,  
Región Metropolitana, Chile

Peter A. Bell, DO, MBA  
Baptist Health Science University

Peter Sokolove, MD  
University of California, San Francisco

Robert M. Rodriguez, MD  
University of California, San Francisco

Robert Suter, DO, MHA  
UT Southwestern Medical Center

Robert W. Derlet, MD  
University of California, Davis

Rosidah Ibrahim, MD  
Hospital Serdang, Selangor, Malaysia

Samuel J. Stratton, MD, MPH  
Orange County, CA, EMS Agency

Scott Rudkin, MD, MBA  
University of California, Irvine

Scott Zeller, MD  
University of California, Riverside

Steven Gabaeff, MD  
Clinical Forensic Medicine

Steven H. Lim, MD  
Changi General Hospital, Simei, Singapore

Terry Mulligan, DO, MPH, FIFEM  
ACEP Ambassador to the Netherlands Society of  
Emergency Physicians

Vijay Gautam, MBBS  
University of London, London, England

Wirachin Hoonpongmanont, MD, MSBATS  
Siriraj Hospital, Mahidol University, Bangkok,  
Thailand

## Editorial Board

## Advisory Board

Amal Khalil, MBA  
UC Irvine Health School of Medicine

Elena Lopez-Gusman, JD  
California ACEP  
American College of Emergency Physicians

DeAnna McNett, CAE  
American College of Osteopathic Emergency  
Physicians

John B. Christensen, MD  
California Chapter Division of AAEM

Randy Young, MD  
California ACEP  
American College of Emergency  
Physicians

Mark I. Langdorf, MD, MHPE  
UC Irvine Health School of Medicine

Jorge Fernandez, MD  
California ACEP  
American College of Emergency Physicians  
University of California, San Diego

Peter A. Bell, DO, MBA  
American College of Osteopathic Emergency  
Physicians  
Baptist Health Science University

Robert Suter, DO, MHA  
American College of Osteopathic Emergency  
Physicians  
UT Southwestern Medical Center

Shahram Lotfipour, MD, MPH  
UC Irvine Health School of Medicine

Brian Potts, MD, MBA  
California Chapter Division of AAEM  
Alta Bates Summit-Berkeley Campus

## Editorial Staff

Isabelle Nepomuceno, BS  
Executive Editorial Director

Visha Bajaria, BS  
WestJEM Editorial Director

Emily Kane, MA  
WestJEM Editorial Director

Stephanie Burmeister, MLIS  
WestJEM Staff Liaison

Cassandra Saucedo, MS  
Executive Publishing Director

Nicole Valenzi, BA  
WestJEM Publishing Director

June Casey, BA  
Copy Editor

Official Journal of the California Chapter of the American College of Emergency Physicians, the American College of Osteopathic Emergency Physicians, and the California Chapter of the American Academy of Emergency Medicine



Available in MEDLINE, PubMed, PubMed Central, Google Scholar, eScholarship, DOAJ, and OASPA.

Editorial and Publishing Office: WestJEM/Department of Emergency Medicine, UC Irvine Health, 3800 W. Chapman Ave. Suite 3200, Orange, CA 92868, USA

Office: 1-714-456-6389; Email: Editor@westjem.org



# Clinical Practice and Cases in Emergency Medicine

Indexed in PubMed and full text in PubMed Central

This open access publication would not be possible without the generous and continual financial support of our society sponsors, department and chapter subscribers.

## Professional Society Sponsors

AMERICAN COLLEGE OF OSTEOPATHIC EMERGENCY PHYSICIANS  
CALIFORNIA ACEP

CALIFORNIA CHAPTER DIVISION OF  
AMERICAN ACADEMY OF EMERGENCY MEDICINE

## Academic Department of Emergency Medicine Subscribers

Albany Medical College Albany, NY	INTEGRIS Health Oklahoma City, OK	Robert Wood Johnson University Hospital New Brunswick, NJ	University of Florida, Jacksonville Jacksonville, FL
American University of Beirut Beirut, Lebanon	Kaweah Delta Health Care District Visalia, CA	Rush University Medical Center Chicago, IL	University of Illinois at Chicago Chicago, IL
Arrowhead Regional Medical Center Colton, CA	Kennedy University Hospitals Turnersville, NJ	Southern Illinois University Carbondale, IL	University of Illinois College of Medicine Peoria, IL
Augusta University Augusta GA	Kern Medical Bakersfield, CA	St. Luke's University Health Network Bethlehem, PA	University of Iowa Iowa City, IA
Baystate Medical Center Springfield, MA	Lakeland HealthCare St. Joseph, MI	Stanford/Kaiser Emergency Medicine Residency Program Stanford, CA	University of Louisville Louisville, KY
Beaumont Hospital Royal Oak, MI	Lehigh Valley Hospital and Health Network Allentown, PA	Staten Island University Hospital Staten Island, NY	University of Maryland Baltimore, MD
Beth Israel Deaconess Medical Center Boston, MA	Loma Linda University Medical Center Loma Linda, CA	SUNY Upstate Medical University Syracuse, NY	University of Michigan Ann Arbor, MI
Boston Medical Center Boston, MA	Louisiana State University Health Sciences Center New Orleans, LA	Temple University Philadelphia, PA	University of Missouri, Columbia Columbia, MO
Brigham and Women's Hospital Boston, MA	Madigan Army Medical Center Tacoma, WA	Texas Tech University Health Sciences Center El Paso, TX	University of Nebraska Medical Center Omaha, NE
Brown University Providence, RI	Maimonides Medical Center Brooklyn, NY	University of Alabama, Birmingham Birmingham, AL	University of South Alabama Mobile, AL
Carl R. Damall Army Medical Center Fort Hood, TX	Maricopa Medical Center Phoenix, AZ	University of Arkansas for Medical Sciences Little Rock, AR	University of Southern California/Keck School of Medicine Los Angeles, CA
Conemaugh Memorial Medical Center Johnstown, PA	Massachusetts General Hospital Boston, MA	University of California, Davis Medical Center Sacramento, CA	University of Tennessee, Memphis Memphis, TN
Desert Regional Medical Center Palm Springs, CA	Mayo Clinic College of Medicine Rochester, MN	University of California Irvine Orange, CA	University of Texas, Houston Houston, TX
Doctors Hospital/Ohio Health Columbus, OH	Mt. Sinai Medical Center Miami Beach, FL	University of California, Los Angeles Los Angeles, CA	University of Texas Health San Antonio, TX
Eastern Virginia Medical School Norfolk, VA	North Shore University Hospital Manhasset, NY	University of California, San Diego La Jolla, CA	University of Warwick Library Coventry, United Kingdom
Einstein Healthcare Network Philadelphia, PA	Northwestern Medical Group Chicago, IL	University of California, San Francisco San Francisco, CA	University of Washington Seattle, WA
Emory University Atlanta, GA	Ohio State University Medical Center Columbus, OH	UCSF Fresno Center Fresno, CA	University of Wisconsin Hospitals and Clinics Madison, WI
Genesys Regional Medical Center Grand Blanc, Michigan	Ohio Valley Medical Center Wheeling, WV	University of Chicago, Chicago, IL	Wake Forest University Winston-Salem, NC
Hartford Hospital Hartford, CT	Oregon Health and Science University Portland, OR	University of Colorado, Denver Denver, CO	Wright State University Dayton, OH
Hennepin County Medical Center Minneapolis, MN	Penn State Milton S. Hershey Medical Center Hershey, PA	University of Florida Gainesville, FL	
Henry Ford Hospital Detroit, MI	Presence Resurrection Medical Center Chicago, IL		

## State Chapter Subscribers

ARIZONA CHAPTER DIVISION OF THE  
AMERICAN ACADEMY OF EMERGENCY MEDICINE  
CALIFORNIA CHAPTER DIVISION OF THE  
AMERICAN ACADEMY OF EMERGENCY MEDICINE  
FLORIDA CHAPTER DIVISION OF THE  
AMERICAN ACADEMY OF EMERGENCY MEDICINE

GREAT LAKES CHAPTER DIVISION OF THE  
AMERICAN ACADEMY OF EMERGENCY MEDICINE  
TENNESSEE CHAPTER DIVISION OF THE  
AMERICAN ACADEMY OF EMERGENCY MEDICINE

UNIFORMED SERVICES CHAPTER DIVISION OF THE  
AMERICAN ACADEMY OF EMERGENCY MEDICINE  
VIRGINIA CHAPTER DIVISION OF THE  
AMERICAN ACADEMY OF EMERGENCY MEDICINE

## International Society Partners

EMERGENCY MEDICINE ASSOCIATION OF TURKEY  
LEBANESE ACADEMY OF EMERGENCY MEDICINE  
MEDITERRANEAN ACADEMY OF EMERGENCY MEDICINE

NORWEGIAN SOCIETY FOR EMERGENCY MEDICINE  
SOCIEDAD ARGENTINA DE EMERGENCIAS

SOCIEDAD CHILENO MEDICINA URGENCIA  
THAI ASSOCIATION FOR EMERGENCY MEDICINE

To become a *WestJEM* departmental sponsor, waive article processing fee, receive print and copies for all faculty and electronic for faculty/residents, and free CME and faculty/fellow position advertisement space, please go to <http://westjem.com/subscribe> or contact:

Stephanie Burmeister  
*WestJEM* Staff Liaison  
Phone: 1-800-884-2236  
Email: [sales@westjem.org](mailto:sales@westjem.org)

## JOURNAL FOCUS

*Clinical Practice and Cases in Emergency Medicine* (CPC-EM) is a MEDLINE-indexed internationally recognized journal affiliated with the *Western Journal of Emergency Medicine* (WestJEM). It offers the latest in patient care case reports, images in the field of emergency medicine and state of the art clinicopathological and medicolegal cases. CPC-EM is fully open-access, peer reviewed, well indexed and available anywhere with an internet connection. CPC-EM encourages submissions from junior authors, established faculty, and residents of established and developing emergency medicine programs throughout the world.

## Table of Contents *continued*

- 158 **Acute Epiglottitis Secondary to the Severe Acute Respiratory Syndrome Coronavirus 2: A Case Report**  
*M Gunchenko, M Abboud, ZW Risler, RC Gibbons*
- 161 **Acute Focal Bacterial Nephritis in a Patient with Solitary Kidney: Case Report**  
*A Guella, RZ Muhammad, M Aljallabi, A Mursi, M Elmahi*
- 165 **A Case Report of Nitrous Oxide-induced Myelopathy: An Unusual Cause of Weakness in an Emergency Department**  
*MS Birch, EJ Samones, T Phan, M Guptill*
- 168 **Retropharyngeal Hematoma Causing Airway Compromise After Tissue Plasminogen Activator Administration: A Case Report**  
*C Provenza, AC Habermann, J Metter, JR Walker III*
- 172 **Emergency Department Point-of-care Ultrasound Identification of Suspected Lemierre's Syndrome: A Case Report**  
*P Craven, B End, P Griffin*
- 175 **The Diagnostic Dilemma in Delayed Subarachnoid Hemorrhage: A Case Report**  
*DA Bazer, N Koroneos, M Orwitz, J Amar, R Corn, E Wirkowski*
- 178 **Delayed-onset Angioedema Following a Snakebite in a Patient on ACE Inhibitors: A Case Report**  
*CS Sampson, E Schwarz*
- 182 **Low-dose Fosphenytoin for Aborting Acute Trigeminal Neuralgia Pain: A Case Report**  
*J Baydoun, A Lin, J Miya*
- 185 **Intracranial Hemorrhage and Facial Fractures After Nose Blowing and Sternutation: A Case Report**  
*CG Hanson, C Stewart, K Cronovich*
- 189 **Shone Complex: A Case Report of Congenital Heart Disease Detected Using Point-of-care Ultrasound**  
*JC Seaback, DA Masneri, JH Schoeneck*
- 193 **Spontaneous Coronary Sinus Thrombosis Detected by Point-of-care Transthoracic Echo: A Case Report**  
*LL Berrin, K Howell, A Foote, J Mullings, A Desai, M Montgomery, S Barbant, A Nagdev*

Policies for peer review, author instructions, conflicts of interest and human and animal subjects protections can be found online at [www.cpcem.org](http://www.cpcem.org).

# *Clinical Practice and Cases in Emergency Medicine*

Indexed in PubMed and full text in PubMed Central

## JOURNAL FOCUS

*Clinical Practice and Cases in Emergency Medicine* (CPC-EM) is a MEDLINE-indexed internationally recognized journal affiliated with the *Western Journal of Emergency Medicine* (WestJEM). It offers the latest in patient care case reports, images in the field of emergency medicine and state of the art clinicopathological and medicolegal cases. CPC-EM is fully open-access, peer reviewed, well indexed and available anywhere with an internet connection. CPC-EM encourages submissions from junior authors, established faculty, and residents of established and developing emergency medicine programs throughout the world.

## Table of Contents *continued*

### Images in Emergency Medicine

- 197    **A Man with Severe, Left Lower Quadrant Abdominal Pain**  
*TJ Wen, YT Su, HY Ke, KC Lai*
- 200    **Female with Atraumatic Abdominal Bruising**  
*ZS Pacheco, G Johnson, EF Shufflebarger*
- 202    **Leser-Trélat Sign as a Marker for Underlying Pancreatic Cancer**  
*K Modi, R Chen, L Abubshait*

Policies for peer review, author instructions, conflicts of interest and human and animal subjects protections can be found online at [www.cpcem.org](http://www.cpcem.org).

# CPC**EM** Clinical Practice & Cases

## CALL FOR SUBMISSIONS

- Patient Care Case Reports
- Images In Emergency Medicine

Fully open-access, peer reviewed, well indexed: CPC-EM is available anywhere with an internet connection at **CPCEM.org**

*Clinical Practice and Cases in Emergency Medicine* is an internationally recognized journal affiliated with the MEDLINE-indexed *Western Journal of Emergency Medicine*

CPC-EM encourages submissions from junior authors and countries with developing emergency medicine programs

# CPC**EM** Clinical Practice & Cases

## **CALL FOR CPC-EM SECTION EDITORS!**

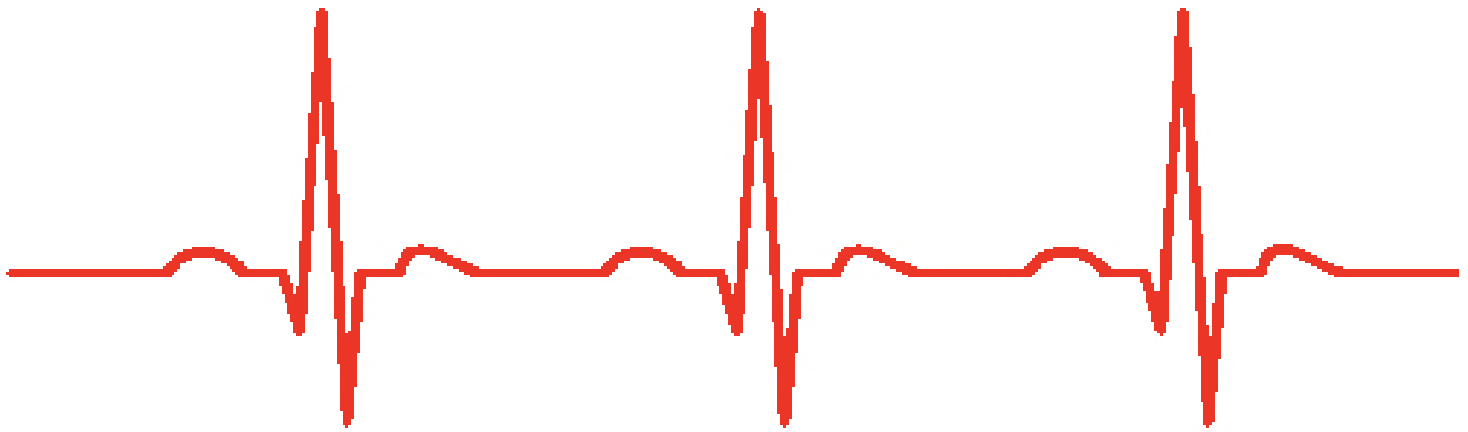
- Medical-Legal Case Reports
- Case Reports/Images in Emergency Medicine

**Send your CV and letter of interest to**  
**editor@westjem.org**



*West***JEM** Integrating Emergency Care  
with Population Health

**Call for Reviewers!**



Please send your CV and letter of interest to  
[editor@westjem.org](mailto:editor@westjem.org)

**CPC***EM* Clinical  
Practice  
& Cases



EISENHOWER HEALTH

## Education Fellowship at Eisenhower Medical Center, Rancho Mirage, CA

### ABOUT THE PROGRAM

- SAEM-approved Education Fellowship
- Opportunities to learn in both Graduate and Undergraduate Medical Education
- Offer "Training to Teach in Medicine" certificate program from Harvard Medical School
- One- or two-year fellowship
- Competitive salary with full-benefits from Eisenhower Health

### ABOUT EISENHOWER MEDICAL CENTER

- Rated among the region's Best Hospitals by *U.S. News & World Report*
- More than 85,000 visits per year
- Advanced Primary Stroke Center, STEMI Center, Accredited Geriatric Emergency Department and Level Four Trauma Center
- State-of-art medical center
- 50 private patient rooms
- Best EMR: Epic
- Three-year Emergency Medicine residency program

### LIVING IN THE DESERT

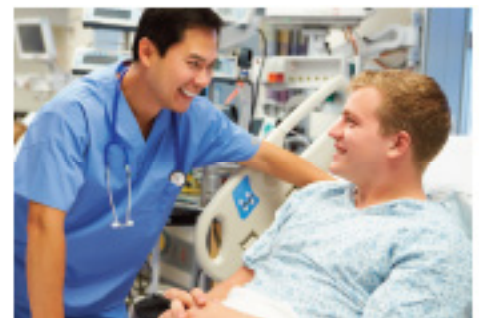- Affordable cost of living
- Variety of activities: hiking, shopping, dining, golfing, etc.
- Within two hours from many big cities (L.A. and San Diego)

### CONTACT

**Wirachin Haonpongmanont, MD, MS**

Cell: 862-216-0466 ■ Email: [wirachin@gmail.com](mailto:wirachin@gmail.com)

website: [gma.eisenhowerhealth.org](http://gma.eisenhowerhealth.org)



L I V E . W O R K . P L A Y . P R O S P E R .

39000 Bob Hope Drive, Rancho Mirage, CA 92270 ★ [EisenhowerHealth.org](http://EisenhowerHealth.org)

## 57-Year-Old Male Veteran with Recurrent Fevers

Eileen Chu, MD, MS\*  
Samantha A. King, MD†  
Laura J. Bontempo, MD, MEd†  
T. Andrew Windsor, MD†

\*University of Maryland Medical Center, Baltimore, Maryland  
†University of Maryland School of Medicine, Department of Emergency Medicine,  
Baltimore, Maryland

Section Editor: Joel Moll, MD

Submission history: Submitted July 18, 2023; Revision received July 20, 2023; Accepted July 21, 2023

Electronically published August 9, 2023

Full text available through open access at [http://escholarship.org/uc/uciem\\_cpccem](http://escholarship.org/uc/uciem_cpccem)

DOI: 10.5811/cpcem.1546

A 57-year-old male veteran presented to the emergency department for recurrent fevers for 10 days. The patient was febrile but had an overall benign physical exam. This interesting case explores the broad differential diagnosis and evaluation in a patient who presents with fever of unknown origin. [Clin Pract Cases Emerg Med. 2023;7(3):121–126.]

### CASE PRESENTATION (Dr. Chu)

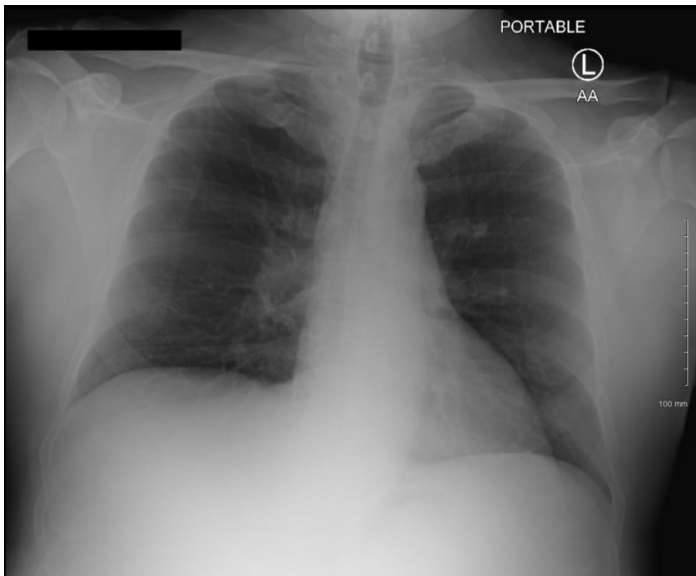
A 57-year-old male veteran presented to the emergency department (ED) with recurrent fevers. The patient reported that he'd had a fever for 10 nights with a maximum temperature of 104° Fahrenheit (F) / 40° Celsius (C). He also mentioned having right upper quadrant (RUQ) abdominal pain for about a week, which he believed was related to his inflammatory bowel disease (IBD). He stated that he went to an urgent care on three separate occasions for his symptoms where he tested negative multiple times for severe acute respiratory syndrome coronavirus 2 (SARS-CoV-2) and influenza. The urgent care obtained laboratory studies, which showed a mild leukocytosis of 14,000 white blood cells per microliter (mcL) on the second visit and 12,000/mcL on the third visit. On one of his visits, the patient complained of a headache and reported prior sinus infections; so he was started on doxycycline for presumed sinusitis. When asked about new medications, the patient reported the initiation of infliximab infusions for his IBD two months earlier and was last infused the month prior to the ED visit. He denied any recent foreign travel or exotic animal exposures.

The patient's past medical history included IBD, hyperlipidemia, and obstructive sleep apnea. He had no past surgical history. His social history included prior heavy alcohol use (although he reported quitting in 2015), and no tobacco or illicit drug use. His home medications were atorvastatin nightly, diclofenac as needed, lactase as needed, and infliximab monthly. He had no known drug allergies. Greater than 10 years ago, the patient reported being stationed in areas such as Japan, Bahrain, Qatar, Egypt, Kuwait, and Cyprus. His review of systems was positive for abdominal

pain, a single episode of diarrhea, myalgias, chronic back pain, and a headache. He denied any upper respiratory symptoms, such as cough, sore throat, or rhinorrhea. He denied any chest pain, shortness of breath, nausea, or vomiting.

On examination, the patient was in no acute distress, but he appeared uncomfortable. He was febrile to 101.8°F/38.8°C with a heart rate of 94 beats per minute, blood pressure 154/77 millimeters of mercury, and his oxygen saturation was 95% on room air. He weighed 98.4 kilograms (body mass index = 32.0 kg/m<sup>2</sup>). His head was normocephalic and atraumatic. His sclera were anicteric and his pupils were equal, round, and reactive to light. His oropharynx was clear and moist. His neck was supple with normal range of motion and without meningeal signs. His heart had a regular rate and rhythm without any murmurs, rubs or gallops. His lungs were clear to auscultation bilaterally without wheezes, rales, or rhonchi. Despite the patient's complaint of RUQ pain, his abdomen was soft, nondistended, and nontender. There was no hepatomegaly. His skin examination was without any rash. He had full range of motion of all extremities. His neurologic exam was without gross abnormalities.

The patient was given one gram of acetaminophen and received one liter of normal saline intravenously (IV). Laboratory studies, a respiratory viral panel swab, and blood cultures were obtained. A chest radiograph was performed (Image 1). The patient's initial lab results are shown in the Table. His labs were significant for a mild leukocytosis. His chemistry panel showed a decreased bicarbonate level, anion gap of 15, and very mildly elevated liver function tests. He had a normal lactate and urinalysis (UA). His coagulation studies were elevated.



**Image 1.** Portable chest radiograph of a 57-year-old male veteran with recurrent fevers.

In the ED, an additional test was ordered, and a diagnosis was made.

### CASE DISCUSSION (Dr. King)

This is a case of a 57-year-old male who presented to the ED with a chief complaint of intermittent fevers in the setting of an underlying autoimmune disorder, IBD. He had some other varying complaints in his history and review of systems including RUQ abdominal pain, which was thought to be attributed to his IBD, chronic back pain, and myalgias, headaches, and chills, which are all incredibly non-specific. He has a remote history of alcohol use disorder but was not actively drinking or using illicit substances. The team astutely obtained a detailed travel history, which noted that the patient has been out of the country on several occasions but not recently. Additionally, he was undergoing monthly infliximab infusions. Outside these key features, there is not much that is narrowed down from this history.

In the ED, his vitals were notable for a fever but were otherwise unremarkable. Additionally, despite the other complaints in his history, his abdominal examination was overall unremarkable with no complaints of tenderness on examination. The remainder of his examination was otherwise non-specific, similar to his history.

The team initiated a limited laboratory work-up looking for possible sources of the patient's fever including a SARS-CoV-2 test (although he had previously tested negative), UA, and blood counts. There were a few key findings including very mildly elevated liver enzymes and international normalized ratio, without an elevated bilirubin. He also had a slight acidosis with a normal lactate and normal anion gap. His chest radiograph was unremarkable, without signs of infiltrates, consolidations, or effusions. Unfortunately,

in combination with his relatively unremarkable history and physical, his lab work and imaging thus far are non-conclusive, and the differential diagnosis remains broad.

Creating a differential diagnosis for fever without an organized system can be overwhelming, risking having diagnoses be overlooked or missed. One system that can be applied here is to create a differential diagnosis for fever of unknown origin (FUO). While this patient does not technically meet the definition of FUO (which requires fever documented  $>38.3^{\circ}\text{C}$  on several occasions over the course of three weeks with a one-week hospital work-up), systems for evaluating FUO can still be helpful as an organizational method for approaching patients who do not have an obvious underlying source of their fever.<sup>1</sup> One such system uses the mnemonic I-MADE to organize the differential diagnosis.<sup>2</sup> This mnemonic stands for infections, malignancy, autoimmune disorders, drug-induced, and everything else.

Within this mnemonic, infection is the broadest category and should be addressed last, unless there is a very high suspicion. The next category to consider is malignancy. This patient did complain of abdominal pain and had mildly elevated liver enzymes, which may suggest a primary or metastatic lesion to the liver. He was on the younger end of the age spectrum where malignancy would be expected but not out of the realm of possibility. However, the patient lacked other symptoms classically associated with malignancy such as weight loss or night sweats. Also, the time course would have been very rapid to have developed malignancy-related fevers over one to two weeks without any other symptoms. Therefore, malignancy is unlikely to be the cause of this patient's presentation.

Next for consideration is autoimmune diseases. This patient already had an underlying autoimmune disease, and while it is possible that his IBD was the underlying cause of his symptoms, he was actively undergoing therapeutic treatment and one would expect his symptoms to be improving and not getting worse. Autoimmune disorders often come in clusters; so, it is possible that he developed an additional disorder. His infliximab treatment, however, would likely have been therapeutic for additional autoimmune disease, such as rheumatoid arthritis, that would lead to a fever. He was also missing hallmark features of these diseases such as joint pain, rashes, or focal muscular tenderness/weakness. Thus, an additional autoimmune disorder was also unlikely to be the underlying cause.

The next category, drug-induced fevers, is difficult as it is only diagnosed by elimination since there does not typically exist a test for diagnosis. However, it is an important category to keep in mind. The patient was taking atorvastatin, a non-steroidal anti-inflammatory, and an over-the-counter lactose intolerance medication daily. None of these medications are likely to cause a fever, but the patient was additionally on infliximab infusions. Infliximab is known to cause many of the patient's symptoms. Infliximab is associated with fevers, headaches, and liver enzyme elevation; all of which were key features of this case.<sup>3</sup> While this diagnosis initially appears



**Table.** Initial laboratory results of a 57-year-old male veteran with recurrent fevers.

Test name	Patient value	Reference range
Complete blood count		
White blood cells	12.6 K/mcL	4.5 - 11 K/mcL
Hemoglobin	14.2 g/dL	11.9 - 15.7 g/dL
Hematocrit	42.3%	35.0 - 45.0%
Platelets	285 K/mcL	153 - 367 K/mcL
Complete metabolic panel		
Sodium	135 mmol/L	136 - 145 mmol/L
Potassium	3.6 mmol/L	3.5 - 5.1 mmol/L
Chloride	101 mmol/L	98 - 107 mmol/L
Bicarbonate	19 mmol/L	21 - 30 mmol/L
Blood urea nitrogen	11 mg/dL	7 - 17 mg/dL
Creatinine	1.0 mg/dL	0.52 - 1.04 mg/dL
Glucose	105 mg/dL	70-100 mg/dL
Albumin	2.9 g/dL	3.2 - 4.6 g/dL
Total bilirubin	0.4 mg/dL	0.3 - 1.2 mg/dL
Aspartate aminotransferase	66 units/L	14 - 36 units/L
Alanine aminotransferase	54 units/L	0 - 34 units/L
Alkaline phosphatase	73 units/L	38 - 126 units/L
Anion gap	15 mmol/L	6-15 mmol/L
Coagulation		
Prothrombin Time	18.2 seconds	12.1-15.0 seconds
Partial thromboplastin time	33.4 seconds	25-38 seconds
International normalized ratio	1.6	0.8-1.1
Urinalysis		
Appearance	Clear	Clear
Color	Yellow	
Bilirubin	Negative	Negative
Ketones	Negative	Negative
Leukocyte esterase	Negative	Negative
Mucus	1+	Negative
Nitrite	Negative	Negative
pH	5.50	5.0-8.0
Protein	1+	Negative
Specific gravity	1.024	1.002-1.030
Blood	1+	Negative
Glucose	Negative	Negative
Urobilinogen	4.0	Negative
White blood cells	0-5 cells/hpf	0-5 cells/hpf
Red blood cells	0-5 cells/hpf	0-2 cells/hpf
Additional labs		
SARS-CoV-2	Negative	Negative
Lactate	0.9 mmol/L	0.5-2.2 mmol/L

K, thousands; *mCL*, microliter; *g*, grams; *dL*, deciliter; *mmol*, millimole; *L*, liter; *mg*, milligram; *dL*, deciliter; *hpf*, high powered field; SARS-CoV-2, severe acute respiratory syndrome coronavirus 2.

promising, it should only be the diagnosis of choice after all others have been eliminated. Additionally, his last infusion was nearly a month prior to presentation, and one would have expected to see symptoms sooner than this presentation.

The last category in this mnemonic is a catch-all of everything else. However, key diagnostic groupings to consider within this category include thromboembolism, endocrine disorders, neurologic dysregulation, environmental exposure, and factitious disorder. The patient did not present with any signs of thromboembolism such as shortness of breath, tachypnea, hypoxia, leg swelling or pain, so this is less likely to be the cause. For endocrinopathies and neurologic dysregulation, one would have expected to see other associated features such as skin changes, vital sign abnormalities, and/or lab abnormalities. Since these features were not present, these are less likely to be the cause. For the last two groupings of environmental exposure and factitious disorders, it is less likely that the patient would have a persistent fever once removed from the environmental source, and one should not assume a factitious disorder without ruling out of all other medical conditions.

This brings me back to the first category of infection. This category is broad and has several ways to further break it down, such as by body system or by type of infection (viral, fungal, etc). For body systems, the only focal areas concerning for infections were his abdomen (RUQ pain) and head (headaches). This would add an intra-abdominal abscess - most likely liver but sparing the biliary system given his normal bilirubin - and meningitis/encephalitis to the differential diagnosis. For the latter diagnoses, the patient was immunosuppressed but did not have typical associated signs or symptoms such as neck pain, nuchal rigidity, or altered mental status, and his headache was only noted on review of systems. In terms of a liver abscess, the patient had only mildly elevated transaminases and did not have tenderness on his examination. However, given his immunosuppressed status, it is possible once again that these might not have been as prominent. Unlike his headache though, his abdominal pain was more noteworthy and a focus of his presentation. Therefore, liver abscess remains on the differential.

Within the category of systemic infections, viral infections such as cytomegalovirus, human immunodeficiency virus, hepatitises, and Epstein-Barr virus are all possible. However, most of these viruses should have been screened for prior to initiating infliximab treatment or would have had other features such as a rash or changes to blood counts. Pathologies like parasitic and fungal infections, such as anaplasmosis, ehrlichiosis, or leptospirosis, often have anemia or, if invading the liver (to explain the RUQ pain), would have had a cholestatic pattern on lab testing. These infections are difficult to rule out but do not greatly explain the patient's symptoms and predominantly normal lab work, including a non-elevated bilirubin and alkaline phosphatase. In a patient with international travel, malaria, dengue fever, and typhoid fever should be considered. Once again, the patient lacked key features for these diagnoses including anemia, rashes,

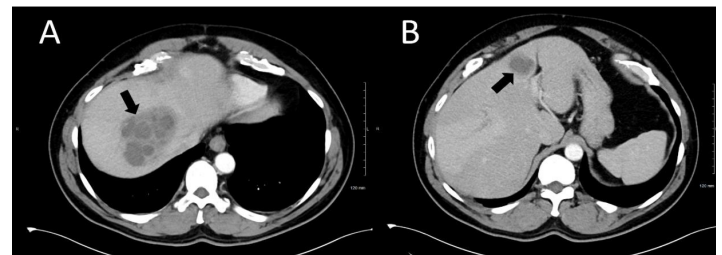
and profuse diarrhea. Another consideration in patients with international travel is tuberculosis (TB). The patient should have been screened out for this disease prior to initiating infliximab; however, there are several reports of false-negative screening and presentation of TB after infliximab infusion. Therefore, TB must remain on the differential diagnosis.

While the list of possible infections can go on and on, focusing on the patient's chief complaints along with the fever, narrows the differential diagnosis to liver abscess and TB. Ultimately, while the patient did not have RUQ tenderness on exam, this was a key history point, and he had the elevated liver enzymes on his lab work. While TB could explain these findings, case reports of occurrences after initial screening are rare, and it is likely, given the patient's military history, that he would have undergone multiple screenings for TB in his lifetime.

Therefore, my final diagnosis is liver abscess, and my diagnostic test of choice would be computed tomography (CT) of the abdomen and pelvis with IV contrast. Of note, an ultrasound of this area would also be an appropriate initial test but would potentially miss other sources of abscess in this area; so in the undifferentiated patient, a CT would be the most preferred testing modality.

#### CASE OUTCOME (Dr. Chu)

The diagnostic test ordered was a CT abdomen/pelvis with IV contrast (Image 2). The CT was interpreted by the radiologist as having two hypoenhancing lesions within the right hepatic dome, and these "findings could be compatible with hepatic pyogenic abscesses or hypoenhancing liver metastases, which could be differentiated based on clinical context." The patient reconfirmed with us that he had no cancer history, recent international travel, or possible exotic exposures. Given the patient's recurrent fevers, abdominal pain, recent infliximab infusion, and lack of cancer history or other symptoms such as fatigue, night sweats or weight loss to suggest a cancer diagnosis, the initial diagnosis of pyogenic liver abscess was pursued. The patient was admitted to the internal medicine service. Piperacillin/tazobactam and



**Image 2.** Computed tomography of the abdomen and pelvis with intravenous contrast of a 57-year-old male veteran with recurrent fevers identifying hypoenhancing lesions, which are consistent with a 9.2-centimeter (cm) abscess in the right hepatic dome (A) and a 3.5 cm abscess in hepatic segment 4 (B) (black arrows).

metronidazole were ordered, and interventional radiology (IR) was consulted for drainage of his liver abscesses the next day. The patient had no further fevers after drainage of his abscesses. Drainage Gram stain was negative, and cultures showed no growth during hospitalization. The infectious disease service was consulted and recommended downgrading his antibiotics from piperacillin/tazobactam to amoxicillin/clavulanate. On hospital day five, the patient tested positive for *Entamoeba histolytica* antibodies, which led to his final diagnosis of amoebic liver abscess. He was restarted on metronidazole, and paromomycin was initiated by the time of his hospital discharge. It was ultimately thought that the patient had been infected with *E. histolytica* on his prior military tours and had a dormant cyst that was reactivated when started on the infliximab infusions.

### RESIDENT DISCUSSION (Dr. Chu)

Liver abscesses are primarily classified as either pyogenic or amoebic depending on the cause. A pyogenic liver abscess is the most common intra-abdominal organ abscess.<sup>4</sup> Most pyogenic liver abscesses are polymicrobial, although enteric Gram-negative bacilli and streptococci can commonly be identified in abscess specimens.<sup>5,6</sup> The disease generally occurs in patients with predisposing factors such as diabetes mellitus, hepatobiliary disease, or current proton pump inhibitor use.<sup>7,8</sup> Common clinical symptoms include fever, abdominal pain, nausea, vomiting, and malaise, although fever and abdominal pain are among the most frequently seen in patients.<sup>9</sup>

Amoebic liver abscesses are commonly caused by *E. histolytica*, which is a protozoan parasite that is predominantly found in developing regions. Over 100,000 annual deaths are attributed to *E. histolytica* infection.<sup>10</sup> When diagnosed in patients living in more developed regions, those infected are likely to be migrants from endemic regions or travelers to areas such as Africa, Central and South America, Mexico, and South Asia, where they have had contact with fecal contaminated sources of food, water, and/or to a lesser extent, sexual transmission.<sup>11,12</sup> *E. histolytica* exists in two forms: the cyst form, which is the infectious form that begins after ingestion; and the trophozoite form, which is the invasive form of the disease that can cause tissue inflammation and ultimately necrosis in intestinal sites or sites such as the liver (the most common extra-intestinal manifestation), brain, lung, or heart.<sup>11,13</sup> Although most *E. histolytica* infections are asymptomatic, symptoms are similar to a pyogenic liver abscess. Symptoms may or may not also include diarrhea, weight loss, and bloody stools, depending on whether there is a concurrent intestinal infection.<sup>11</sup>

The imaging test of choice for any liver abscess comes down to ultrasound vs CT with IV contrast. Computed tomography is considered more sensitive with up to a 97% sensitivity.<sup>14</sup> Subsequent work-up of a liver abscess seen on imaging usually entails needle aspiration by IR for both diagnostic and/or therapeutic purposes.<sup>11</sup> If pyogenic, Gram stains will show leukocytes and bacteria. *E. histolytica*, on

the other hand, may be diagnosed by stool microscopy, stool antigen testing, stool polymerase chain reaction, or serology. Because most cases of amoebic abscesses may occur without intestinal infection, there is a lower sensitivity to stool studies and, thus, serology is preferred.<sup>5,11</sup>

In addition to drainage, antibiotic treatment is also necessary. For pyogenic liver abscesses, antibiotic selection starts with broad-spectrum coverage with empiric *E. histolytica* coverage until the parasitic infection is ruled out. This is most typically done with piperacillin/tazobactam with metronidazole (to provide coverage for *E. histolytica*), or a third generation or later cephalosporin with metronidazole, and then tailored for coverage of aspirate growth cultures. The type of treatment needed to eliminate *E. histolytica* depends on the patient's presentation. Asymptomatic patients are treated with an intraluminal agent, such as paromomycin, iodoquinol, or diloxanide furoate, to prevent disease progression and transmission. Symptomatic patients, however, are treated with an intraluminal agent after they have received systemic therapy with a tissue active agent such as metronidazole.

### FINAL DIAGNOSIS

*Entamoeba histolytica* liver abscess

### KEY TEACHING POINTS

- Most *Entamoeba histolytica* infections are asymptomatic, but symptomatic patients may have recurrent fever and abdominal pain.
- Symptomatic patients require both an intraluminal agent, such as paromomycin, AND a tissue active agent, such as metronidazole, for elimination of the parasite.
- Undifferentiated fevers in the emergency department have a broad differential. Consider using the fever of unknown origin mnemonic I-MADE as a starting point.

The authors attest that their institution does not require institutional review board approval. Patient consent has been obtained for publication of this clinicopathological case report. Documentation on file.

---

*Address for Correspondence:* T. Andrew Windsor, MD, University of Maryland School of Medicine, Department of Emergency Medicine, 110 S Paca Street, 6th Floor, Suite 200, Baltimore, MD 21201. Email: awindsor@som.umaryland.edu.

*Conflicts of Interest:* By the CPC-EM article submission agreement, all authors are required to disclose all affiliations, funding sources and financial or management relationships that could be perceived as potential sources of bias. The authors disclosed none.

*Copyright:* © 2023 Chu et al. This is an open access article distributed in accordance with the terms of the Creative Commons Attribution (CC BY 4.0) License. See: <http://creativecommons.org/licenses/by/4.0/>

---

## REFERENCES

1. Brown I and Finnigan NA. Fever of unknown origin. 2022. Available at: <https://www.ncbi.nlm.nih.gov.proxy-hs.researchport.umd.edu/books/NBK532265/>. Accessed January 22, 2023.
2. Gulati U. How do you work up FUO? Inspired MedEd. 2020. Available at: <https://inspiredmeded.com/2020/05/19/how-do-you-work-up-fuo/>. Accessed July 1, 2023.
3. Fatima R, Bittar K, Aziz M. Infliximab. 2022. Available from: <https://www.ncbi.nlm.nih.gov.proxy-hs.researchport.umd.edu/books/NBK500021/>. Accessed January 22, 2023.
4. Altemeier WA, Culbertson WR, Fullen WD, et al. Intra-abdominal abscesses. *Am J Surg*. 1973;125(1):70-9.
5. Johannsen EC, Sifri CD, Madoff LC. Pyogenic liver abscesses. *Infect Dis Clin North Am*. 2000;14(3):547-63.
6. Meddings L, Myers RP, Hubbard J, et al. A population-based study of pyogenic liver abscesses in the United States: incidence, mortality, and temporal trends. *Am J Gastroenterol*. 2010;105(1):117-24.
7. Akhondi H and Sabih DE. Liver abscess. 2022. Available at: <https://www.ncbi.nlm.nih.gov/books/NBK538230/>. Accessed January 22, 2023.
8. Sayek I and Onat D. Pyogenic and amebic liver abscess. In: Holzheimer RG, Mannick JA, ed. Surgical treatment: evidence-based and problem-oriented. 2001. Available at: <https://www.ncbi.nlm.nih.gov/books/NBK6955>. Accessed January 21, 2023.
9. Mohsen AH, Green ST, Read RC, et al. Liver abscess in adults: ten years experience in a UK centre. *QJM*. 2002;95(12):797-802.
10. Bercu TE, Petri WA, Behm JW. Amebic colitis: new insights into pathogenesis and treatment. *Curr Gastroenterol Rep*. 2007;9(5):429-33.
11. Shirley DT, Farr L, Watanabe K, et al. A Review of the global burden, new diagnostics, and current therapeutics for amebiasis. *Open Forum Infect Dis*. 2018;5(7):ofy161.
12. Billet AC, Salmon Rousseau A, Piroth L, et al. An underestimated sexually transmitted infection: amoebiasis. *BMJ Case Rep*. 2019;12(5):e228942.
13. Stanley SL Jr. Amoebiasis. *Lancet*. 2003;361(9362):1025-34.
14. Yu SC, Ho SS, Lau WY, et al. Treatment of pyogenic liver abscess: prospective randomized comparison of catheter drainage and needle aspiration. *Hepatology*. 2004;39(4):932-8.



# Point-of-care Ultrasound Identification of Tension Hydrothorax in the Emergency Department: A Case Series

Allison Clark, MD  
Peyton Lampley, DO  
Vu Huy Tran, MD

Aventura Hospital and Medical Center, Emergency Medicine Residency Program,  
Aventura, Florida

Section Editor: Shadi Lahham, MD

Submission history: Submitted July 11, 2022; Revision received May 4, 2023; Accepted May 5, 2023

Electronically published August 2, 2023

Full text available through open access at [http://escholarship.org/uc/uciem\\_cpccem](http://escholarship.org/uc/uciem_cpccem)

DOI: 10.5811/cpcem.1584

**Introduction:** Tension hydrothorax is an uncommon emergent condition in which hemodynamic instability and respiratory compromise may occur. Emergency physicians may diagnose tension hydrothorax by point-of-care ultrasound.

**Case Series:** We discuss the key sonographic features assisting in identification. Four patients with history of malignancy who were found to have tension hydrothorax exhibited the following common ultrasound findings: massive, left-sided pleural effusion; complete, compressive atelectasis; and shift of cardiac structures into the right hemithorax, resulting in right-sided probe placement to obtain cardiac views.

**Conclusion:** This is the first instance to our knowledge of point-of-care ultrasound findings in tension hydrothorax to be described in the literature. [Clin Pract Cases Emerg Med. 2023;7(3):127–131.]

**Keywords:** *tension hydrothorax; point-of-care ultrasound.*

## INTRODUCTION

Tension hydrothorax (TH) is a rare but life-threatening condition caused by a large pleural effusion displacing mediastinal structures including the heart, lungs, and great vessels. This shift raises intrathoracic pressures causing hemodynamic compromise. Due to tension physiology and obstructive shock, patient presentations range from dyspnea and orthopnea to shock and respiratory insufficiency.<sup>1</sup>

In adults the two most common causes of TH are infectious or malignant processes, although many causes have been identified.<sup>2</sup> The diagnosis is made based on clinical suspicion and can be supported with imaging via chest radiograph (CXR), point-of-care ultrasound (POCUS), or computed tomography (CT). These modalities may show hemithorax opacification or pleural effusion with contralateral mediastinal displacement.

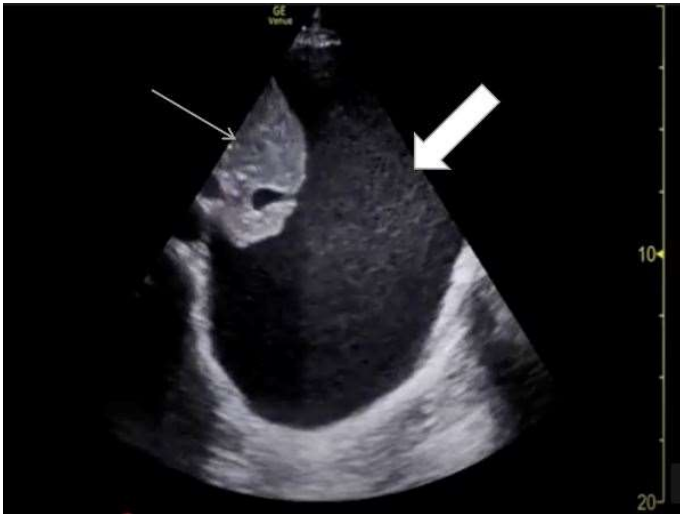We describe four patients who presented to our emergency department (ED) with TH with specific, unique cardiothoracic ultrasound findings. To our knowledge, this is the first case series of POCUS findings in TH.

## CASE SERIES

### Case 1

A 56-year-old male of Chinese descent without reported past medical history presented to the ED with days of shortness of breath and pleuritic chest pain. He was diagnosed with a large left pleural effusion via outpatient CXR. Initial vital signs were heart rate (HR) of 98 beats per minute (bpm), blood pressure (BP) of 148/83 millimeters mercury (mm Hg), respiratory rate (RR) of 18 respirations per minute (rpm), oxygen saturation (SpO<sub>2</sub>) of 98% on room air (RA), and an oral temperature of 98.6° Fahrenheit (°F). Physical exam showed no distress with decreased breath sounds on left lung auscultation. Laboratory studies were largely within normal limits, including complete blood count, C-reactive protein (CRP), erythrocyte sedimentation rate (ESR), and chemistry panel.

The CXR in the ED showed complete opacification of the left hemithorax with rightward mediastinal shift. Thoracic POCUS showed atelectatic lung within a large left pleural effusion, and absent cardiac views from normal left chest windows (Image 1). Chest CT confirmed a massive left pleural



**Image 1.** Thoracic point-of-care ultrasound showing atelectatic lung (thin arrow) within a large left pleural effusion (thick arrow), and absent cardiac views from normal left chest windows.

effusion and complete left lung collapse causing rightward mediastinal shift, with concern for a lingular mass. The patient was admitted to the medical service, where an ultrasound-guided thoracentesis removed a total of 3.8 liters (L) of exudative fluid. Pathology of the biopsy from the lingular mass confirmed stage IV adenocarcinoma. The patient was discharged home with a chest tube in situ for close outpatient follow-up.

### Case 2

A 79-year-old female with past medical history of hypertension (HTN), hyperlipidemia, chronic obstructive pulmonary disease on home oxygen therapy, and metastatic lung adenocarcinoma with brain metastases undergoing chemotherapy, presented to the ED with sudden onset of dyspnea. Initial vital signs were as follows: HR 75 bpm; BP 125/80 mm Hg, RR 18 rpm; SpO<sub>2</sub> 100% on 3L of oxygen via nasal cannula (NC), which was increased from baseline therapy; and an oral temperature of 97.8°F. Her physical exam was significant for mild respiratory distress and bilateral decreased breath sounds. Laboratory studies showed white blood count (WBC) 18.2 x10<sup>3</sup>/microliters (μL) (reference range 4.0-10.5 x10<sup>3</sup>/μL), hemoglobin 9.7 grams per deciliter (g/dL) (11.2-15.7 g/dL), D-dimer of 4,632 nanograms per deciliter (ng/mL) (0-316 ng/mL), CRP of 16.5 milligrams/dL (0.0-1.0 mg/dL), and erythrocyte sedimentation rate ESR of 53 millimeters per hour (mm/hr) (0-10 mm/hr). Arterial blood gas showed pH 7.39 (7.35-7.45), partial pressure of carbon dioxide 50 mm Hg (35.0-45.0 mm Hg), and partial pressure of oxygen of 108 mm Hg (80.0-105.0 mm Hg) on 3L NC.

Point-of-care ultrasound revealed a large left pleural effusion with rightward mediastinal shift and a plethoric

### CPC-EM Capsule

What do we already know about this clinical entity?  
*Rare but life threatening, tension hydrothorax occurs when large pleural fluid collections compress and shift mediastinal structures, causing hemodynamic instability.*

What makes this presentation of disease reportable?  
*Tension hydrothorax is a rare complication of large pleural effusion that can lead to life-threatening tamponade physiology and hemodynamic instability.*

What is the major learning point?  
*Adjusting ultrasound probe positioning to the right hemithorax can help decrease time to diagnosis and treatment in emergent scenarios such as tension hydrothorax.*

How might this improve emergency medicine practice?  
*If emergency medicine providers understand and can quickly identify tension hydrothorax, it can help prevent further complications or death.*

inferior vena cava with minimal inspiratory collapse. Chest radiograph showed complete left-sided opacification with rightward mediastinal shift. Computed tomography angiography of the chest demonstrated an enlarged left hilar and subcarinal mass when compared to previous CT. New findings included occlusion of the left mainstem bronchus; compression of the mid-esophagus; collapse of the left lung; and a large left pleural effusion. Treatment with thoracentesis was considered but not performed due to the unlikelihood of lung re-expansion and minimal therapeutic benefit. Ultimately, the patient opted for comfort measures only and was discharged to hospice.

### Case 3

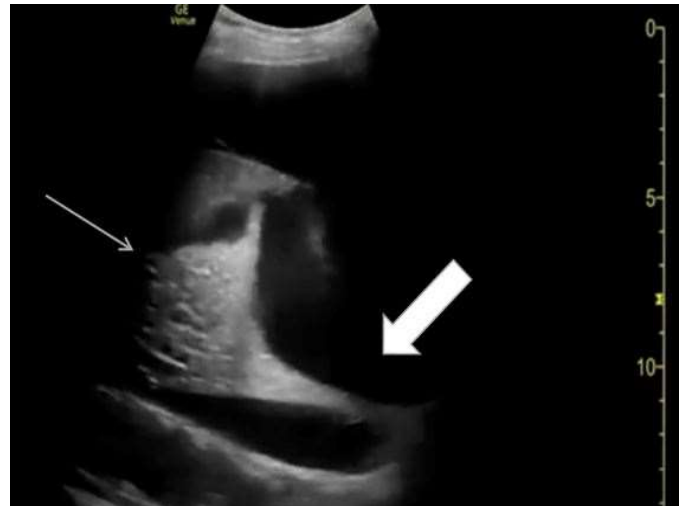
A 59-year-old male with history of metastatic neuroendocrine cancer presented to the ED with his hospice nurse for concern of increased dyspnea and decreased oral intake. Initial vital signs were as follows: HR 118 bpm; BP 118/78 mm Hg; RR 20 rpm; SpO<sub>2</sub> 96% on 4L NC; and temperature of 98.2°F. Physical exam was significant for rales and diminished breath sounds throughout left lung fields. Relevant laboratory studies were as follows: WBC 15.8 x10<sup>3</sup>/μL (reference range 4.0-10.5 x10<sup>3</sup>/μL); lactic acid 4.4 millimoles [mmol]/L (0.4-2.0 mmol/L), lactate dehydrogenase of 1,537 units/L (84-246 U/L); CRP 40.59 mg/dL (0-1.0 mg/

dL), B-type natriuretic peptide 1,520 units/L (0-217 U/L); troponin I 0.016 ng/mL (0.000-0.034 ng/mL); and D-dimer 812 ng/mL D-dimer units (0-316 ng/mL). Chest radiograph revealed complete opacification of the left hemithorax with rightward mediastinal shift. Point-of-care ultrasound showed large, loculated, left-sided pleural effusion, rightward mediastinal shift, and hyperdynamic left ventricular function on echocardiography (Image 2).

On admission, interventional radiology was consulted for palliative thoracentesis; however, the patient's healthcare proxy decided against invasive procedures, and he was discharged to hospice.

#### Case 4

A 72-year-old female with a history of HTN and lung cancer, undergoing chemotherapy, presented with bilateral lower extremity swelling and dyspnea for one week. Initial vital signs were as follows: HR 108 bpm; BP 170/99 mm Hg; RR 20 rpm; SpO<sub>2</sub> 95% on RA; and an oral temperature of 98.6°F. Physical exam was significant for a tachypneic, moderately distressed woman with biphasic wheezing and diminished breath sounds bilaterally. Relevant laboratory studies were as follows: platelet level of  $132 \times 10^3$  U/L (reference range 150-400  $\times 10^3$  U/L), aspartate aminotransferase of 64 U/L (10-40 U/L), and D-dimer of greater than 5,250 ng/mL (0-316 ng/mL). Chest radiograph showed complete opacification of the left lung and enlarged mediastinum, while POCUS showed a large, left-sided pleural effusion and absent cardiac structures in the left hemithorax (Image 3). The heart was visualized in the right hemithorax showing a small pericardial effusion without evidence of tamponade. Chest CT angiography showed right lower lobe pulmonary embolism, left upper and lower lobe infiltrates, left pleural effusion, and slight rightward midline shift. A bedside thoracentesis removed 3L of straw-colored fluid, improving



**Image 3.** Point-of-care ultrasound in sagittal view of the left hemithorax showing a large, septated pleural effusion (thick arrow) with compressive atelectatic lung (thin arrow).

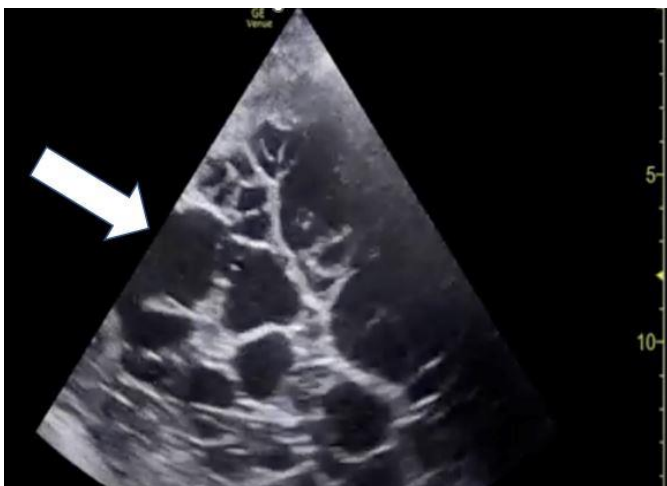
both respiratory and hemodynamic status, but was complicated by an iatrogenic pneumothorax. She received a tube thoracostomy placed by interventional radiology and was later discharged in stable condition.

#### DISCUSSION

A pleural effusion can be considered massive when fluid accumulates to two-thirds or more of the hemithorax. Large volumes of any fluid composition may compress and displace structures within the mediastinum. This can trigger cascading events of decreased venous return, impaired right-sided filling, and diminished cardiac output, all resulting in hemodynamic compromise. At this stage, pathophysiology of TH is comparable to tension pneumothorax. The pleural space is similar in pressure and dynamics as the pericardial space; therefore, build-up in intrapleural pressure results in increased pericardial space pressure. This causes tamponade physiology and similar emergent hemodynamic instability.<sup>3</sup> For that reason, assessment for tamponade physiology on POCUS is imperative for early intervention and prevention of further complications or death.

The most common causes of pleural effusions are malignancy and infection.<sup>2</sup> Other potential causes are fluid overload states as seen in heart or liver failure; pulmonary embolism; congenital abnormalities; rheumatologic diseases; trauma; or iatrogenic causes.<sup>2,4</sup> Unusual causes include disseminated endometriosis,<sup>5</sup> gastric perforation,<sup>4,6</sup> and ventriculopleural shunt.<sup>7</sup> Most of our cases had known malignancy history, likely having malignant or paramalignant causes of TH.<sup>8</sup>

Patients may present to the ED with normal or abnormal vital signs. Despite its association with shock, TH patients may present with either hypotension or hypertension.<sup>2</sup> Malignant pleural effusions may arise over long periods,



**Image 2.** Point-of-care ultrasound in transverse view of the left hemithorax depicting a large, loculated pleural effusion (thick arrow).

allowing for compensatory mechanisms such as fluid retention and tachycardia.<sup>2</sup> Physical exam findings may show decreased to absent breath sounds on the affected side, pleural rubs, dullness to percussion<sup>9</sup> with or without tracheal deviation, and jugular venous distention.<sup>2</sup>

The modalities of physical assessment, radiographs, ultrasounds, and CT imaging can diagnose pleural effusions; each with its advantages and disadvantages. Chest radiographs can show near or complete opacification of the affected hemithorax and mediastinal shift. While quick and cost effective, CXRs require more than 50 mL or 200 mL on upright and supine radiographs, respectively, to detect pleural effusions.<sup>10</sup> Ultrasound can detect volumes as small as 5 mL but more reliably 20 mL.<sup>10</sup> For this reason, physical exam findings and plain films could be considered inferior in diagnostic accuracy to ultrasound. Computed tomography can help identify small pleural effusions, assess for complexity such as loculations, and assess for concomitant pleural and parenchymal pathology.<sup>12</sup>

Ultrasound and CT are useful in characterizing, quantifying, and assessing the complexity of the pleural effusion. This information aids in differentiating between transudative vs exudative, supplementary to pleural fluid analysis, and may aid in diagnosing the ultimate cause. Benefits of using POCUS over CT include accessibility, efficiency, reliability, time effectiveness, low cost, safety with lack of ionizing radiation and contrast material, and ability to aid in procedural guidance.<sup>10</sup>

Fortunately for our cohort, our patients initially presented hemodynamically stable. Several showed exam findings we would expect with TH such as dyspnea or hypoxia. All showed hemithorax opacification with mediastinal shift on CXR. Point-of-care ultrasound consistently showed large pleural effusions with atelectatic lung. Two cases had abnormal cardiac ultrasound findings with hyperdynamic function without evidence of tamponade.

All four patients in this cohort exhibited the following POCUS findings: a large, left-sided pleural effusion with compressive atelectasis, with left hemithorax devoid of cardiac views; and rightward displacement of cardiac structures that required repositioning of the transducer to the right parasternal area to obtain adequate views. Additional findings seen in some patients, which would be expected in cases of obstructive shock, are dilation of the inferior vena cava (>2 centimeters) and hyperdynamic echocardiogram findings.

Thus, it is vital to use POCUS to assess for tamponade physiology, as early intervention may prevent further complications or death. Jain et al, who describe a patient with tension hydrothorax due to cirrhosis and portal hypertension, had echocardiogram findings of right atrial and ventricular collapse due to a large transudative pleural effusion. The patient was emergently stabilized with a tube thoracostomy.<sup>9</sup> Treatment for TH may require urgent vs emergent thoracentesis or tube thoracostomy, dependent on

hemodynamic instability. Other cases of TH, regardless of etiology, are treated similarly.<sup>1,11</sup>

## CONCLUSION

Clinicians should be cognizant of the following POCUS findings associated with tension hydrothorax: large pleural effusion; left hemithorax devoid of the heart; and rightward cardiac displacement requiring right-sided probe placement in search of possible tamponade physiology. In this scenario, there are additional complications that may change immediate management, such as evaluation for right heart strain, volume status, and cardiac tamponade.

The authors attest that their institution requires neither Institutional Review Board approval, nor patient consent for publication of this case series. Documentation on file.

---

*Address for Correspondence:* Allison Clark, MD, Aventura Hospital and Medical Center, 20900 Biscayne Boulevard, Suite 821, 8<sup>th</sup> floor South Tower, Aventura, Florida 33180. Email: aclark184@gmail.com.

*Conflicts of Interest:* By the CPC-EM article submission agreement, all authors are required to disclose all affiliations, funding sources and financial or management relationships that could be perceived as potential sources of bias. Dr. Tran has done consulting for GE Healthcare. This work did not affect the substance in this paper in any way. This research was supported (in whole or in part) by HCA Healthcare and/or an HCA Healthcare affiliated entity. The views expressed in this publication represent those of the author(s) and do not necessarily represent the official views of HCA Healthcare or any of its affiliated entities. The authors report no conflicts of interest.

*Copyright:* © 2023 Clark et al. This is an open access article distributed in accordance with the terms of the Creative Commons Attribution (CC BY 4.0) License. See: <http://creativecommons.org/licenses/by/4.0/>

---

## REFERENCES

1. Vinck EE, Garzón JC, Peterson T, et al. Tension hydrothorax: emergency decompression of a pleural cause of cardiac tamponade. *Am J Emerg Med.* 2018;36(8):1524.e1-4.
2. Demidovich J, Nasser H, Vasoya A, et al. Tension hydrothorax. *Clin Pulm Med.* 2012;19(1):50-2.
3. Chidambaram S, Sangareddi V, Ganesan G, et al. An echocardiographic assessment of cardiovascular hemodynamics in patients with large pleural effusion. *Indian Heart J.* 2013;65(6):666–70.
4. Karkhanis VS and Joshi JM. Pleural effusion: diagnosis, treatment, and management. *Open Access Emerg Med.* 2012;4:31-52.
5. Deal A, Evans D, Counselman FL. Tension hydrothorax from disseminated endometriosis. *West J Emerg Med.* 2016;17(1):88-90.
6. Park EY and Rose E. An unusual case of tension hydrothorax in a pediatric patient. *J Emerg Med.* 2016;50(6):891-2.
7. Wu TS and Kuroda R. Tension hydrothorax in a pediatric patient with



- a ventriculopleural shunt. *J Emerg Med.* 2011;40(6):637-9.
8. Fenton KN and Richardson JD. Diagnosis and management of malignant pleural effusions. *Am J Surg.* 1995;170(1):69-74.
  9. Jain S, Erickson HL, Pezzulo A. Ultrasound diagnosis of hemodynamic compromise in a patient with hepatic hydrothorax. *Ann Am Thorac Soc.* 2016;13(3):444-6.
  10. Soni NJ, Franco R, Velez MI, et al. Ultrasound in the diagnosis and management of pleural effusions. *J Hosp Med.* 2015;10(12):811-6.
  11. Porter ED, Finley DJ, Phillips JD. Tension hydrothorax secondary to small cell lung cancer. *Respirol Case Rep.* 2019;7(5):e00420.
  12. Putnam JB. Malignant pleural effusions. *Surg Clin North Am.* 2002;82(4):867-83.

# Erector Spinae Plane Block Performed in the Emergency Department for Abdominal Pain: A Case Series

Daniel Parsons-Moss, MD\*  
David Martin, MD†  
Maribel Condori MD‡  
Andrea Dreyfuss, MD, MPH\*

\*Hennepin County Medical Center, Department of Emergency Medicine, Minneapolis, Minnesota  
†Alameda Health System - Highland Hospital, Department of Emergency Medicine, Alameda, California  
‡Hospital Nacional Dos de Mayo, Department of Emergency Medicine, Cercado de Lima, Peru

Section Editor: Shadi Lahham, MD

Submission history: Submitted July 6, 2022; Revision received June 1, 2023; Accepted May 30, 2023

Electronically published August 2, 2023

Full text available through open access at [http://escholarship.org/uc/uciem\\_cpccm](http://escholarship.org/uc/uciem_cpccm)

DOI: 10.5811/cpcem.1587

**Introduction:** Ultrasound-guided nerve blocks are fast becoming a core part of opioid-sparing, multimodal, acute pain management in the emergency department (ED) setting. The ultrasound-guided erector spinae plane block (ESPB) has been shown to be effective in treating a variety of musculoskeletal and neuropathic painful conditions in the ED.

**Case Series:** Here we report the effective use of the ESPB for pain control in four patients who presented with acute abdominal pain related to biliary obstruction in a resource-limited setting.

**Conclusion:** The ESPB may be helpful in treating abdominal pain related to biliary obstruction, which is a novel indication for this well-established technique. This application is particularly relevant in resource-limited settings with significant delay in definitive surgical management. Further research is needed prior to widespread adoption. [Clin Pract Cases Emerg Med. 2023;7(3):132–135.]

**Keywords:** *Erector spinae block; regional anesthesia; multimodal pain control; ultrasound-guided nerve blocks; case series.*

## INTRODUCTION

Ultrasound-guided nerve blocks (UGNB) are a core component of opioid-sparing, multimodal analgesia in the emergency department (ED). The erector spinae plane block (ESPB) is a technique that has been shown to be effective in a variety of painful conditions. The use of this UGNB in the ED was first reported in 2017 by Luftig et al. as an improved alternative to the serratus anterior block for posterior rib fractures.<sup>1</sup> Since that time, innovative clinicians are finding an expanding list of indications where it may be used successfully to treat visceral pain including pancreatitis, appendicitis, and ureteral colic.<sup>2-7</sup>

There is continued uncertainty regarding the exact mechanism of action of the ESPB. The most widely accepted theory is diffusion throughout the fascial plane below the erector spinae muscles and direct action on the ventral and dorsal rami of the spinal nerves.<sup>8</sup> This provides a reasonable anatomic basis for visceral pain relief as the visceral afferent

fibers join the spinal nerves just proximal to the bifurcation of the ventral and dorsal rami, and there is likely some diffusion of anesthetic deep to the erector spinae plane.

Here we present four cases where an ultrasound-guided ESPB was used successfully for visceral pain control in a spectrum of disorders related to biliary obstruction: biliary colic; choledocholithiasis; and gallstone pancreatitis. To our knowledge this is the first report of its use in the ED for pain secondary to biliary obstruction.

## CASE SERIES

### Case 1

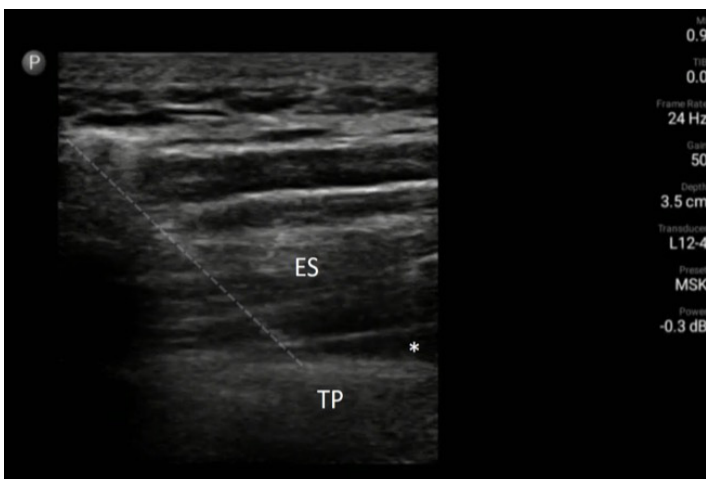
A 36-year-old male with no past medical history presented to the ED of a Peruvian hospital for right upper quadrant (RUQ) abdominal pain. He described seven days of intermittent pain that had become constant and more severe for the prior three days. On review of symptoms he also noted dark-colored urine. On physical exam, the patient had jaundice

and a positive Murphy's sign. Laboratory results were notable for elevated white blood cell (WBC) count, normal lipase, elevated bilirubin, and elevated alkaline phosphatase. Point-of-care ultrasound (POCUS) revealed gallstones and a dilated common bile duct, concerning for choledocholithiasis. Subsequent magnetic resonance cholangiopancreatography confirmed the diagnosis of choledocholithiasis.

The patient's ED course was complicated by severe abdominal pain, subjectively rated 10/10, despite treatment with 100 milligrams (mg) intravenous (IV) tramadol and 1 gram (g) of IV metamizol (a non-steroidal anti-inflammatory drug commonly used in Peru). Given the patient's refractory pain to opioid and non-opioid IV medications the decision was made to perform an ultrasound-guided ESPB. A high-frequency linear transducer was used to identify the transverse processes at the sixth thoracic (T6) level. Bilateral ultrasound-guided ESPBs were performed using 20-gauge Quincke spinal needles (Becton, Dickinson and Company, Franklin Lakes, NJ) to inject 10 milliliters (mL) of 0.25% bupivacaine and 10 mL of normal saline (NS) using an in-plane approach as shown in Images 1, 2, and 3. Thirty minutes after the procedure the patient's pain reduced from 10/10 to 0/10 on the self-reported pain scale.

## Case 2

A 25-year-old female, pregnant at 28 weeks estimated gestational age, with a past medical history significant for cholelithiasis, presented to the ED with RUQ abdominal pain. Her pain was described as intermittent and colicky in nature, having been present for one day, and associated with nausea and vomiting. On physical exam, she had tenderness to palpation in the RUQ without rebound or guarding. Lab exams including WBC count, liver enzymes, and lipase were all



**Image 1.** Erector spinae plane block. The dotted line highlights the needle traversing the erector spinae group muscles (labeled ES) in a diagonal trajectory and abutting the posterior side of the transverse process (labeled TP) with a hypoechoic wedge emanating from the tip (asterisk), which is anesthetic spreading along the erector spinae fascial plane.

## CPC-EM Capsule

What do we already know about this clinical entity?

*The erector spinae plane block (ESPB) is an ultrasound-guided regional anesthesia technique useful for treating pain in the emergency department.*

What makes this presentation of disease reportable?

*Here we report the successful use of the ESPB to treat abdominal pain related to biliary obstruction, which is a novel indication for this technique.*

What is the major learning point?

*The ESPB can be used to provide pain control for patients with pain from biliary obstruction in the emergency department.*

How might this improve emergency medicine practice?

*The ESPB is a promising technique that expands the tool kit for multimodal, opioid-sparing analgesia in the emergency department.*

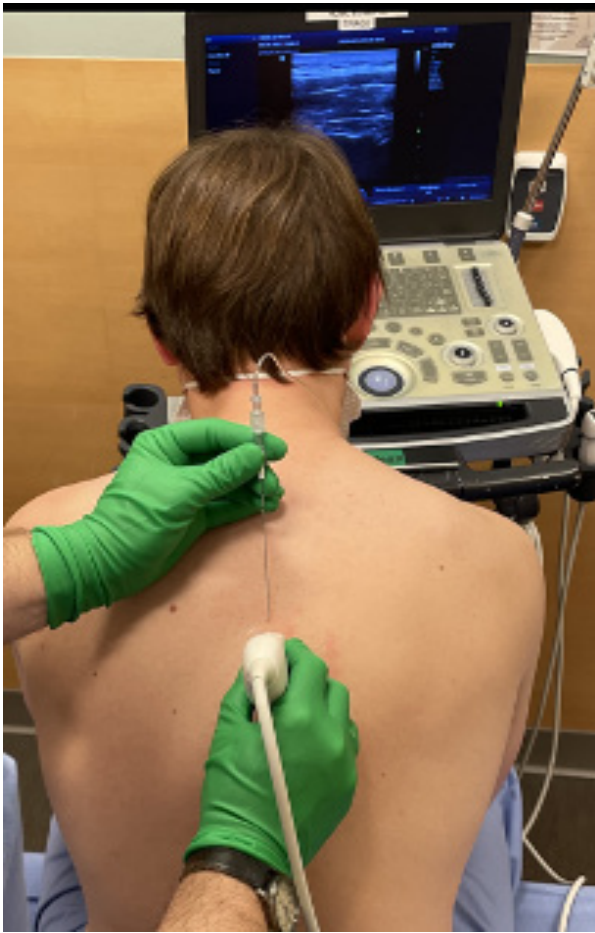within the normal reference range. Point-of-care ultrasound was notable for multiple gallstones without signs of cholecystitis or choledocholithiasis. The patient was diagnosed with symptomatic cholelithiasis.

She continued to endorse severe abdominal pain, subjectively rated as 10/10, despite receiving 2 g IV metamizol. An ultrasound-guided, right-sided ESPB was performed using 20 mL of 0.25% bupivacaine and 10 mL of NS. Thirty minutes after the block her pain reduced to 2/10 severity, and she was subsequently discharged home.

## Case 3

A 30-year-old female, with a past medical history pertinent for gallstones and a prior episode of gallstone pancreatitis (10 months prior to presentation), presented to the ED with RUQ abdominal pain and vomiting. Abdominal exam revealed tenderness to palpation in the RUQ and a positive Murphy's sign. Lab exams revealed elevated lipase and hepatic panel dysfunction with a classic cholestatic pattern. On POCUS, multiple gallstones were visualized without signs of cholecystitis; however, the common bile duct was not visualized. The patient was diagnosed with presumed gallstone pancreatitis.

The patient continued to endorse severe abdominal pain, rated 10/10 severity, despite receiving 100 mg of IV tramadol, and 2 gm of IV metamizol. An ultrasound-guided ESPB on the right side was performed at the T6 level using 20 mL of 0.25%



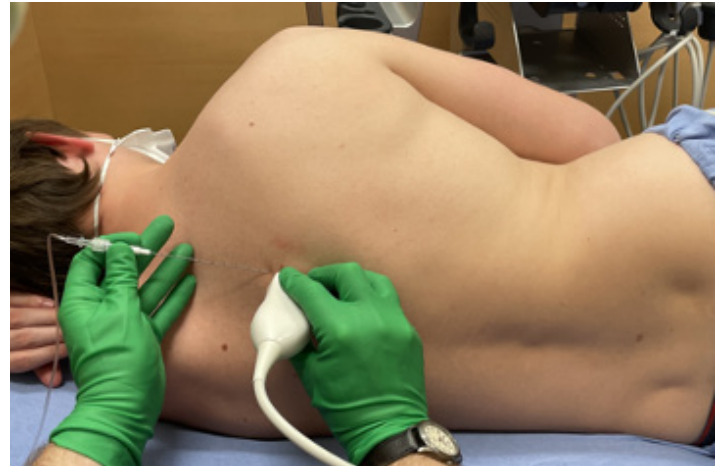**Image 2.** Demonstration of erector spinae plane block technique with the patient in a seated position. Notice the following: 1) ultrasound positioned in front of the operator within direct line of sight; 2) cranial to caudal orientation of the needle (This can be done cranial to caudal or caudal to cranial depending on operator's comfort and dexterity); and 3) direct in-line placement of the linear high-frequency transducer for good needle visualization.

bupivacaine diluted with 10 mL of NS using a similar in-plane approach as previously described. The patient's pain decreased to a 2/10 severity following the block. She was subsequently admitted for definitive management with endoscopic retrograde cholangiopancreatography followed by laparoscopic cholecystectomy.

#### Case 4

A 29-year-old female with no significant past medical history presented to the ED with a two-day history of RUQ pain, associated with nausea and vomiting that started after eating a meal of high fat content. She was noted to be jaundiced, with a positive Murphy's sign. Lab exams revealed elevated lipase and a cholestatic pattern of liver dysfunction. A POCUS exam demonstrated gallstones. The patient was diagnosed with presumed gallstone pancreatitis.

The patient continued to endorse severe abdominal pain, rated 9/10 severity, despite receiving tramadol 100 mg IV and



**Image 3.** Demonstration of erector spinae plane block technique with patient in a lateral decubitus position.

metamizol 2 g IV. A right-sided, ultrasound-guided ESPB was performed at the T6 level using 20 mL of bupivacaine 0.25% diluted in 10 mL of NS using a standard in-plane approach. Thirty minutes after the procedure the patient's pain reduced to a level of 2/10. She was subsequently admitted to the hospital for endoscopic retrograde cholangiopancreatography, followed by delayed laparoscopic cholecystectomy.

#### DISCUSSION

The ESPB was first described in 2016 by Forero et al. in the anesthesia literature as an effective technique for controlling thoracic pain.<sup>9</sup> It was first used for rib fractures and bone pain from metastatic breast cancer. Since its initial description, the technique has gained widespread use in postoperative regional anesthesia. Multiple randomized controlled trials have shown it to be effective at reducing postoperative opioid requirements in thoracic, spinal, abdominal (including cholecystectomy), and breast surgeries.<sup>10</sup> The ESPB technique has since firmly moved into the realm of acute pain management in the ED, where it is finding a growing list of reported indications. However, the literature supporting its use in the ED remains limited. We add this case series to support its use for control of visceral abdominal pain in the ED, which is a new frontier for the technique. When using ESPB for visceral pain there remain several open technical questions: What is the optimal spinal level for injection? What is the optimal volume of local anesthetic? Is bilateral injection superior to right-sided unilateral injection? Further study is needed to answer these questions with certainty.

Control of acute pain is of paramount importance in the practice of emergency medicine. The emergency physician is charged with balancing the goal of patient-centered and syndrome-specific pain control against the risks of pharmacological analgesics, particularly the adverse effects associated with opioid use. Ultrasound-guided nerve blocks



have emerged as an important tool for achieving this goal. Additionally, the American Academy of Emergency Medicine and the American College of Emergency Physicians recognize UGNBs as a core component of multimodal analgesia in the ED.<sup>11,12</sup>

Performing an UGNB requires a baseline knowledge of POCUS and procedural skills. The cases reported here were performed by emergency physicians during their POCUS fellowship training at a hospital in Peru that has a POCUS fellowship training program, thereby limiting the ability to generalize our findings to other settings with clinicians less experienced in the use of POCUS.

Regional anesthesia techniques such as the ESPB are particularly relevant in resource-limited settings. These patients presented to an urban ED in Lima, Peru, where there is often delay in definitive surgical management due to resource limitations (e.g., case 1), and patients experience extended ED boarding times. However, these conditions are certainly not limited to Peru, and we believe this technique to be very useful wherever it can be safely performed.

## CONCLUSION

In this case series we report successful pain control of visceral abdominal pain related to biliary obstruction with ultrasound-guided erector spinae plane block, a novel indication for this technique in the ED setting. This adds to the mounting body of evidence that ESPB is a useful opioid-sparing technique to control visceral pain in the ED. It is particularly well suited to resource-limited settings, where there may be a significant time delay prior to definitive surgical management of various intra-abdominal conditions. While use of this technique offers great promise to the emergency physician, further research is needed to compare it to other methods of pain control in terms of effectiveness and safety, and to define the optimum technique in terms of vertebral level, right sided vs bilateral, and the quantity of local anesthetic instilled.

The authors attest that their institution requires neither Institutional Review Board approval, nor patient consent for publication of this case report. Documentation on file.

## REFERENCES

1. Luftig J, Mantuani D, Herring AA, et al. Successful emergency pain control for posterior rib fractures with ultrasound-guided erector spinae plane block. *Am J Emerg Med.* 2018;36(8):1391-6.
2. Abdelhamid K, ElHawary H, Turner JP. The use of the erector spinae plane block to decrease pain and opioid consumption in the emergency department: a literature review. *Am J Emerg Med.*

**Address for Correspondence:** Daniel Parsons-Moss, MD, Hennepin County Medical Center, Department of Emergency Medicine, 701 Park Ave, Minneapolis, MN 55404. Email: daniel.parsons-moss@hcmcd.org.

**Conflicts of Interest:** By the CPC-EM article submission agreement, all authors are required to disclose all affiliations, funding sources and financial or management relationships that could be perceived as potential sources of bias. The authors disclosed none.

**Copyright:** © 2023 Parsons-Moss et al. This is an open access article distributed in accordance with the terms of the Creative Commons Attribution (CC BY 4.0) License. See: <http://creativecommons.org/licenses/by/4.0/>

- 2020;58(4):603-9.
3. Mantuani D, Luftig J, Herring A, et al. Successful emergency pain control for acute pancreatitis with ultrasound guided erector spinae plane blocks. *Am J Emerg Med.* 2020;38(6):1298.e5-7.
4. Gopinath B, Mathew R, Bhoi S, et al. Erector spinae plane block for pain control in patients with pancreatitis in the emergency department. *Turk J Emerg Med.* 2021;21(3):129-32.
5. Aydin ME, Tekin E, Ahiskalioglu EO, et al. Erector spinae plane block vs non-steroidal anti-inflammatory drugs for severe renal colic pain: a pilot clinical feasibility study. *Int J Clin Pract.* 2021;75(3):e13789.
6. Aydin ME, Ahiskalioglu A, Tekin E, et al. Relief of refractory renal colic in emergency department: a novel indication for ultrasound guided erector spinae plane block. *Am J Emerg Med.* 2019;37(4):794.e1-3.
7. Mantuani D, Luftig J, Herring A, et al. A novel technique to reduce reliance on opioids for analgesia from acute appendicitis: the ultrasound-guided erector spinae plane block. *Clin Pract Cases Emerg Med.* 2019;3(3):248-51.
8. Chin KJ and El-Boghdady K. Mechanisms of action of the erector spinae plane (ESP) block: a narrative review. *Can J Anaesth.* 2021;68(3):387-408.
9. Forero M, Adhikary SD, Lopez H, et al The erector spinae plane block: a novel analgesic technique in thoracic neuropathic pain regional anesthesia and pain medicine. *Reg Anesth Pain Med* 2016;41:621-7.
10. Fanelli A, Torrano V, Cozowicz C, et al. The opioid-sparing effect of erector spinae plane block for various surgeries: a meta-analysis of randomized-controlled trials. *Minerva Anesthesiol.* 2021;87(8):903-14.
11. ACEP Policy Statement 2017. Optimizing the treatment of acute pain in the emergency department. Available at: <https://www.acep.org/globalassets/new-pdfs/policy-statements/optimizing-the-treatment-of-acute-pain-in-the-ed.pdf>. Accessed January 28, 2022.
12. AAEM White Paper on Acute Pain Management in the Emergency department. Available at: <https://www.aaem.org/resources/statements/position/white-paper-on-acute-pain-management-in-the-emergency-department>. Accessed January 28, 2022.

# Extreme Paralysis Following Rocuronium Administration in a Myasthenia Gravis Patient: A Case Report

**Kelsey Billups, PharmD, BCPS\*** \*Medical University of South Carolina, Department of Pharmacy, Charleston, South Carolina  
**Charlotte Collins, MD†** †Medical University of South Carolina, Department of Emergency Medicine, Charleston, South Carolina  
**Aimee Weber, MD, MA‡** ‡Medical University of South Carolina, Department of Neurosurgery, Charleston, South Carolina

Section Editor: Steven Walsh, MD

Submission history: Submitted January 8, 2023; Revision received March 23, 2023; Accepted March 27, 2023

Electronically published July 19, 2023

Full text available through open access at [http://escholarship.org/uc/uciem\\_cpccm](http://escholarship.org/uc/uciem_cpccm)

DOI: 10.5811/cpccm.1548

**Introduction:** The use of paralytics during rapid sequence intubation (RSI) in patients with myasthenia gravis (MG) remains a controversial topic in emergency medicine. Due to fewer functional acetylcholine receptors, these patients can be both sensitive and resistant to different types of neuromuscular blocking agents (NMBA). Their atypical sensitivity to non-depolarizing NMBAs such as rocuronium can increase both the duration and depth of paralysis after its use at typical RSI doses. However, the extent of rocuronium's prolonged duration of effect in patients with MG has yet to be quantified in an emergency department setting.

**Case Report:** We describe a case wherein a full RSI dose of 1.2 milligrams per kilogram of rocuronium led to a prolonged 232-minute duration of paralysis in a patient with MG. This sustained paralysis was suspected but only confirmed after the patient received the reversal agent sugammadex. Once administered, an acute change in neurologic function was seen, and the patient was emergently taken to the operating room for neurosurgical intervention.

**Conclusion:** When intubating patients with MG, many emergency physicians are aware that using paralytics during RSI provides several challenges. If not properly dose-reduced, rocuronium may exert its paralytic effects for up to four hours in patients with MG. This unique case highlights the importance of personalizing care for this patient population before, during, and after RSI. [Clin Pract Cases Emerg Med. 2023;7(3):136–139.]

**Keywords:** case report; rapid sequence intubation; myasthenia gravis; rocuronium, paralytic.

## INTRODUCTION

In patients with myasthenia gravis (MG), the decision of which neuromuscular blocking agent (NMBA) to use during rapid sequence intubation (RSI), if any, is often controversial due to the atypical and unpredictable response to both succinylcholine and rocuronium.<sup>1,2</sup> Patients with MG have fewer functional acetylcholine receptors compared to other patients. Therefore, a decreased sensitivity to the depolarizing NMBA succinylcholine is seen.<sup>3</sup> Adult patients may require up to 2.6 times the normal induction dose for appropriate muscular relaxation. Contrastingly, patients with MG have an increased response to non-depolarizing NMBAs such as rocuronium.

Literature suggests that a dose reduction of 50-90% may still provide adequate neuromuscular blockade.<sup>1,4</sup> This increase in sensitivity can impact the depth and duration of paralysis. However, compared to other paralytics, the actual extent of these effects is not well known or reported with rocuronium use.<sup>5</sup> A one-time administration of 0.6-1.2 milligrams per kilogram (mg/kg) of rocuronium during RSI has a 37-72 minute duration of action in patients without MG.<sup>6,7</sup> In the MG population, the expected length of effect after RSI with a full or reduced dose in the emergency department (ED) is unknown.

The uncertainty of rocuronium's maximum duration of action is likely due to prompt, continuous sedation following

RSI and rare need for extubating patients with MG in the ED. Additionally, all previously reported literature reporting the duration of paralysis solely reflects the length of the associated surgery and subsequent extubation.<sup>1,4,8,9</sup> Due to this gap in knowledge, emergency physicians are likely unaware of how long their patients may be paralyzed following RSI with rocuronium and how critical it is to reduce the dose when using this NMBA for intubating patients with MG. We report a case in which an ED patient with MG required sugammadex administration for the reversal of rocuronium nearly four hours after administration. This case report highlights the special considerations that must be taken when caring for these patients before and after endotracheal intubation.

### CASE REPORT

A 66-year-old patient with a history of MG, chronic lymphocytic leukemia, diabetes, hypertension, and thyroid disease presented to the ED with altered mental status and fevers after falling. Upon arrival, vitals were taken, and the emergency physician performed the initial physical exam. The patient was noted to be obtunded but responsive to painful stimuli. Other than stating his name when asked, the patient was unable to follow commands. His pupils were equal and reactive bilaterally without ocular nystagmus. Given his continued decline in mental and respiratory status, the patient (estimated weight of 97.7 kg) was intubated in the ED with etomidate 0.3 mg/kg and a full RSI dose of rocuronium 1.2 mg/kg. A propofol infusion was initiated at 20 micrograms/kg/minute, and a computed tomography (CT) head was ordered. The patient's heart rate (HR) and blood pressure (BP) at that time were 117 beats per minute (BPM) and 140/79 millimeters of mercury (mm Hg), respectively. (See Table for summary of patient's ED course.)

Two hours after RSI, the emergency physician was made aware of the following CT head results: acute right subdural hematoma (SDH) measuring 1.5 centimeters with 12 mm shift, downward transtentorial herniation, subfalcine herniation, and uncal herniation. Shortly thereafter, neurosurgery was consulted for neurosurgical evaluation. Approximately three hours after RSI the patient's continuous sedation was stopped, and a bedside examination was performed by the neurosurgery team 20 minutes later. Prior to propofol discontinuation, the patient's HR was 100 BPM, and BP was 95/57 mm Hg. The patient had no cough and was not opening his eyes. His pupils were bilaterally reactive on examination.

The neurosurgeon then performed a bedside train of four (TOF) to assess the patient's level of paralysis. Train of four is a peripheral nerve stimulation used as a qualitative assessment of neuromuscular blockade. Electrical current is applied to the peripheral nerve, and the reactive muscular twitches are visually assessed. Train of four can be done at the ulnar or facial nerve. The test sends four impulses with an output between 10-70 milliamperes (mA). If a patient twitches 4/4 times, the patient is considered not paralyzed. If a patient

### CPC-EM Capsule

What do we already know about this clinical entity?

*Emergency medicine physicians are aware patients with myasthenia gravis have an atypical response to paralytics when used during rapid sequence intubation.*

What makes this presentation of disease reportable?

*This case quantifies the longest duration of paralysis ever reported when using rocuronium for rapid sequence intubation in a myasthenia gravis patient.*

What is the major learning point?

*Patients with myasthenia gravis must receive personalized care when intubated with paralytics, especially rocuronium, in the emergency department.*

How might this improve emergency medicine practice?

*Physicians in the Emergency Department are now better equipped in managing patients with myasthenia gravis during and after rapid sequence intubation.*

twitches 0/4 times, the patient is fully paralyzed. Two of four twitches at maximum output would indicate partial paralysis.

His TOF was 0/4 in each upper extremity. The patient did have one slight facial twitch with the stimulator maximized to an output of 70 mA, indicating near-complete neuromuscular blockade. At that time, sugammadex was ordered to determine whether the patient's examination was due to prolonged paralysis from rocuronium or his acute SDH.

Nearly four hours (232 minutes) after 1.2 mg/kg of rocuronium was given, sugammadex 4 mg/kg was administered. A final physical examination was immediately performed by the same neurosurgeon. The patient was found to have a motor exam positive for bilateral upper extremity flexion and bilateral lower extremity withdrawal and flexion. After these findings, the patient was then taken to the operating room (OR) for right-sided craniectomy and evacuation of their SDH. Thirty minutes following sugammadex administration, the patient's HR and BP were 90 BPM and 77/39 mm Hg, respectively.

### DISCUSSION

This case report describes the longest duration of paralysis following rocuronium administration in the ED for RSI in a

**Table.** Summary of Emergency Department Course.

	13:05-13:15	15:40-15:45	18:35-18:55	19:31-19:33	19:44-19:50
Event	Arrival to ED Physical exam #1	Rapid sequence intubation	Physical exam #2	Physical exam #3	Decision made to pursue OR
Medication administration		Etomidate 30 mg (0.3 mg/kg)  Rocuronium 120 mg (1.2 mg/kg)	Propofol stopped	Sugammadex 400 mg (4 mg/kg)	
Vitals	BP 168/80 mmHg HR 95 bpm RR 24 per min Temperature 39.4C (oral) Oxygen saturation 96%	BP 140/79 mmHg HR 117 bpm RR 14 per min			BP 77/39- 81/53 mmHg

ED, emergency department; OR, operating room; mg/kg, milligrams per kilogram; mcg, microgram; BP, blood pressure; mm Hg, millimeters of mercury; HR, heart rate; bpm, beats per minute; RR, respiration rate.

patient with MG. To assess neurologic function, our patient required sugammadex for reversal of rocuronium 232 minutes after administration. The change in physical examination after sugammadex administration, indicating excessive prolonged paralysis, highlights the challenges of using and dosing rocuronium appropriately in this patient population. Our patient’s clinical course and disposition drastically changed after sugammadex was given. Currently, literature describing rocuronium use followed by reversal with sugammadex in adult patients with MG is in the OR setting only.<sup>1,4,8-10</sup> We believe this case report gives emergency physicians unique guidance and reasoning into managing this patient population peri-endotracheal intubation. It may also help explain any unexpected neurologic changes, or lack thereof, seen when managing these patients post-intubation.

Patients with MG have autoimmune destruction of nicotinic acetylcholine receptors causing an unpredictable hyper-response to the non-depolarizing NMBA rocuronium. The effective dose varies between patients and has been reported to range between 0.15 and 1.2 mg/kg. Fujimoto and colleagues attempted to identify factors that would put MG patients at risk of an increased response to rocuronium. They found that patients with a lower baseline TOF and younger age of MG diagnosis achieved adequate paralysis in the OR with 0.15 mg/kg of rocuronium.<sup>8</sup> Unfortunately, as commonly seen in the ED, neither of these factors were known in our patient given the emergent need for intubation. While some patients with MG achieve paralysis with a reduced dose of rocuronium (0.15-0.3 mg/kg), others may require and safely respond to a dose of 1-1.2 mg/kg.<sup>4,8-10</sup>

Our patient was given 1.2 mg/kg of rocuronium to ensure immediate, adequate paralysis for emergent RSI. Prior to the current case report, the longest reported duration of paralysis after rocuronium intravenous (IV) push ranged upward to 120

and 180 minutes, using a full and reduced RSI dose, respectively.<sup>4,8</sup> However, these times reflect the duration of the elective procedure performed in the OR, not rocuronium’s full duration of effect. Unlike the current case report, those cases do not provide an accurate description of how long rocuronium’s paralysis may realistically last after RSI in the ED.

Despite rocuronium having an unpredictable effect in patients with MG, the ability of sugammadex to reverse this paralytic may offset this unwanted pharmacologic property. Sugammadex, first used for rocuronium reversal in a MG patient in 2010, binds to and reverses the effects of non-depolarizing NMBAs such as rocuronium and vecuronium.<sup>7,11</sup> This medication has a quick reversal time of less than five minutes and does not carry a risk of inducing a myasthenic crisis.<sup>12</sup> Sugammadex dosing seems to be consistent between patients with and without MG.

Dosing is determined by depth of neuromuscular blockade based on TOF, dose of rocuronium used, and elapsed time from non-depolarizing NMBA administration.<sup>7</sup> A typical dose of 1.25-4 mg/kg should obtain sufficient reversal of rocuronium in patients with MG after moderate to deep neuromuscular blockade.<sup>1,12,13</sup> A dose of 16 mg/kg should be reserved for rapid reversal immediately after rocuronium administration.<sup>13</sup> Adverse reactions include bradycardia, hypotension, anaphylactic reactions, and urticaria.<sup>14</sup> No bradycardia was seen in our patient. However, hypotension did occur as their BP declined from 95/57 mm Hg to 77/39 mm Hg after sugammadex administration. This reduction was self-limiting, and no interventions were required.

Succinylcholine is an alternative NMBA that may be used for RSI in patients with MG. However, the use of this depolarizing paralytic comes with its own challenges. Since myasthenic patients have fewer functioning acetylcholine receptors, succinylcholine resistance is commonly seen.



Rather than 1.5 mg/kg, a dose up to 2 mg/kg may be necessary for adequate intubation conditions.<sup>3</sup> Additionally, maintenance medications for MG such as pyridostigmine and rivastigmine may prolong the neuromuscular blocking effects of succinylcholine, as they inhibit an enzyme responsible for metabolizing this paralytic.<sup>5</sup> Due to the innate challenges of using either rocuronium or succinylcholine for RSI in patients with MG, some physicians may choose to withhold NMBAs entirely. It's reasonable to consider induction using IV sedation, analgesia, and/or topical anesthesia without a NMBA in these patients.<sup>2</sup> However, this approach has been most successfully reported in the perioperative setting.<sup>15</sup>

## CONCLUSION

This case describes the longest reported duration of paralysis after rocuronium administration in a patient with MG requiring emergent intubation in the ED. Nearly four hours after receiving a full induction dose of 1.2 mg/kg, our patient required sugammadex to reverse the effects of rocuronium. Many emergency physicians are aware that using paralytics during RSI in this patient population provides several challenges. This case report quantifies the extent of rocuronium sensitivity in patients with MG. Furthermore, it provides the emergency physician better insight into the duration of paralysis, the importance of rocuronium dose reduction, and the impact these clinical decisions can have on their patient's post-intubation medical care.

The authors attest that their institution does not require Institutional Review Board approval. Patient consent has been obtained for publication of this case report. Documentation on file.

---

*Address for Correspondence:* Kelsey Billups, PharmD, BCPS, Medical University of South Carolina Department of Pharmacy, 150 Ashley Ave Charleston, SC 29425. Email: billupsk@musc.edu.

*Conflicts of Interest:* By the CPC-EM article submission agreement, all authors are required to disclose all affiliations, funding sources and financial or management relationships that could be perceived as potential sources of bias. The authors disclosed none.

*Copyright:* © 2023 Billups et al. This is an open access article distributed in accordance with the terms of the Creative Commons Attribution (CC BY 4.0) License. See: <http://creativecommons.org/licenses/by/4.0/>

---

## REFERENCES

1. Ulke ZS, Yavru A, Camci E, et al. Rocuronium and sugammadex in patients with myasthenia gravis undergoing thymectomy. *Acta Anaesthesiol Scand.* 2013;57(6):745-8.
2. Roper J, Fleming ME, Long B, et al. Myasthenia gravis and crisis: evaluation and management in the emergency department. *J Emerg Med.* 2017;53(6):843-53.
3. Levitan R. Safety of succinylcholine in myasthenia gravis. *Ann of Emerg Med.* 2005;45(2):225-6.
4. Casarotti P, Mendola C, Cammarota G, et al. High-dose rocuronium for rapid-sequence induction and reversal with sugammadex in two myasthenic patients. *Acta Anaesthesiol Scand.* 2014;58(9):1154-8.
5. Abel M and Eisenkraft JB. Anesthetic implications of myasthenia gravis. *Mt Sinai J Med.* 2002;69:31-7.
6. Perry JJ, Lee JS, Sillberg VAH, et al. Rocuronium versus succinylcholine for rapid sequence induction intubation. *Cochrane Database of Systematic Reviews.* 2018;2:CD002788.
7. Lentz S, Morrissette KM, Porter BA, et al. What is the role of sugammadex in the emergency department? *J Emerg Med.* 2021;60(1):44-53.
8. Fujimoto M, Terasaki S, Nishi M, et al. Response to rocuronium and its determinants in patients with myasthenia gravis. *Eur J Anaesthesiol.* 2015;32(10):672-80.
9. Fernandes HDS, Ximenes JLS, Nunes DI, et al. Failure of reversion of neuromuscular block with sugammadex in patient with myasthenia gravis: case report and brief review of literature. *BMC Anesthesiol.* 2019;19(1):160.
10. Boer HD, Shields MO, Booij L. Reversal of neuromuscular blockade with sugammadex in patients with myasthenia gravis. *Eur J Anaesthesiol.* 2014;31(12):715-21.
11. Unterbuchner C, Fink H, Blobner M. The use of sugammadex in a patient with myasthenia gravis. *Anaesthesia.* 2010;65(3):302-5.
12. Carron M, De Cassai A, Linassi F. Sugammadex in the management of myasthenic patients undergoing surgery: beyond expectations. *Ann Transl Med.* 2019;7(suppl 8):S307.
13. Chambers D, Paulden M, Paton F, et al. Sugammadex for reversal of neuromuscular block after rapid sequence intubation: a systematic review and economic assessment. *Br J Anaesth.* 2010;105(5):568-75.
14. Hunter JM and Naguib M. Sugammadex-induced bradycardia and asystole: How great is the risk? *Br J Anaesth.* 2018;121(1):12-5.
15. Bouaggad A, Bouderkka MA, Abassi O. Total intravenous anaesthesia with propofol for myasthenic patients. *Eur Anaesthesiol.* 2005;22(5):393-4.

# Internal Carotid Artery Occlusion as a Rare Presentation of Infectious Endocarditis: A Case Report

Thijs Wolf, DO  
Kayla Dewey, MD  
David Adler, MD, MPH

University of Rochester Medical Center, Strong Memorial Hospital, Division of  
Emergency Medicine, Rochester, New York

Section Editor: Joel Moll, MD

Submission history: Submitted February 7, 2023; Revision received April 6, 2023; Accepted April 7, 2023

Electronically published July 3, 2023

Full text available through open access at [http://escholarship.org/uc/uciem\\_cpccem](http://escholarship.org/uc/uciem_cpccem)

DOI: 10.5811/cpcem.1489

**Introduction:** Internal carotid artery occlusion as a result of a septic embolism is a rare, commonly fatal, complication of mitral valve infectious endocarditis. Prompt recognition of this condition by the emergency physician may improve the chance of functional neurological survival.

**Case Report:** A 50-year-old male presented minimally responsive with a right gaze deviation, left hemiparesis, and a score of 26 on the National Institutes of Health Stroke Scale. A point-of-care echocardiogram showed a large mitral valve vegetation, and computed tomography angiography demonstrated an internal carotid artery occlusion.

**Conclusion:** The emergency physician should consider this potentially life-threatening condition and know the fundamental management recommendations once identified. [Clin Pract Cases Emerg Med. 2023;7(3):140–143.]

**Keywords:** *septic embolism; infectious endocarditis; stroke; case report.*

## INTRODUCTION

Septic emboli occur when a blood vessel is obstructed, typically as a result of a thrombus that travels from an infected source. Following an ischemic stroke, the initial ischemic insult often occurs from vascular occlusion; a second insult can occur later if the embolism results in a nidus of infection.<sup>1</sup> Over the last two decades there has been a steady rise in the incidence of infectious endocarditis (IE). One study showed a 30% increase in the incidence of IE from 2000 to 2011,<sup>2</sup> thought to be due to the increase in implantable cardiac devices, healthcare-associated infections, and the rise in intravenous (IV) drug use.<sup>3,4</sup> Infectious endocarditis is known to cause ischemic stroke, but complete occlusion of the internal carotid artery is extremely rare with only a few case reports in the literature. We present a case of a middle-aged male who presented with devastating neurological symptoms in the setting of mitral valve vegetation and complete internal carotid artery occlusion.

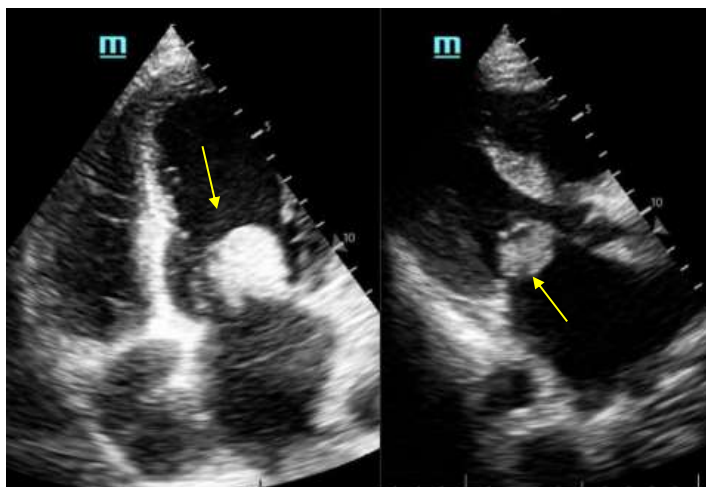
## CASE REPORT

A 50-year-old male presented to the emergency department (ED) via emergency medical services (EMS) after

being found minimally responsive in his bed at home by his roommate. He had a prior history of mitral valve endocarditis, IV heroin use, tobacco use, and atrial fibrillation on anticoagulation. The patient was last witnessed in his normal state of health the evening before his presentation to us. He had been recently hospitalized at another local hospital for methicillin-resistant *Staphylococcus aureus* bacteremia with documentation of known mitral valve vegetations, but he had left against medical advice 10 days prior. On arrival at our ED, he was ill-appearing and in acute distress with a Glasgow Coma Score of 8 (Eye 2, Verbal 2 Motor 4). The patient was afebrile, with a heart rate of 140 beats per minute with an irregular rhythm, blood pressure of 131/78 millimeters (mm) of mercury, respiratory rate of 30 breaths per minute, and pulse oximetry of 100% on a non-rebreather mask placed by EMS. The patient's blood sugar was reported as 167 milligrams per deciliter (mg/dL) on arrival.

The patient would occasionally groan but did not follow commands. Cardiac exam was notable for tachycardia with an irregular rhythm. Pupils were three mm, equal but sluggishly reactive with a right conjugate gaze deviation. The patient withdrew from pain in his right upper and lower extremities

but did not localize to pain and had left-sided hemiparesis. His score on the National Institute of Health Stroke Scale was 26. During his previous hospitalization 10 days earlier the patient was documented to have a normal neurological exam. Skin exam showed pallor with scattered track marks on his upper extremities. Point-of-care transthoracic echocardiogram (TTE) (Image 1) showed a large mitral valve vegetation. Laboratory data showed a leukocytosis of  $30,900/\text{mm}^3$  (reference range  $4,500\text{--}11,000/\text{mm}^3$ ) with neutrophilic predominance, plasma lactate of 7.3 millimoles per liter (mmol/L) ( $0.5\text{--}2.2$  mmol/L), and an acute kidney injury with a serum creatinine of 3.48 mg/dL ( $0.74\text{--}1.35$  mg/dL).



**Image 1** (Left) Point-of-care transthoracic echocardiogram in the apical four-chamber and (right) parasternal long-axis views demonstrating a large mitral valve vegetation (arrow).

A computed tomography (CT) without contrast and a CT angiography of the head (Image 2) and neck were performed demonstrating a right-sided internal carotid artery terminus occlusion with poor leptomeningeal collateral flow to the right cerebral hemisphere. Additionally, there were small areas of hemorrhagic transformation in his bilateral hemispheres, right greater than left.

The patient's neurological state worsened, and the decision was made to proceed with rapid sequence intubation. Broad-spectrum antibiotics were also started. The patient was deemed not to be a candidate for thrombolytics or embolectomy due to the extent of vascular insult seen on his imaging. Shortly after admission, two peripheral blood cultures grew *Staphylococcus aureus* (time to positivity 6.6 hours). The patient was admitted to the neuromedical intensive care unit and ultimately died from his condition several days later.

## DISCUSSION

Ischemic stroke can result from embolization of endocardial vegetations to several locations including the

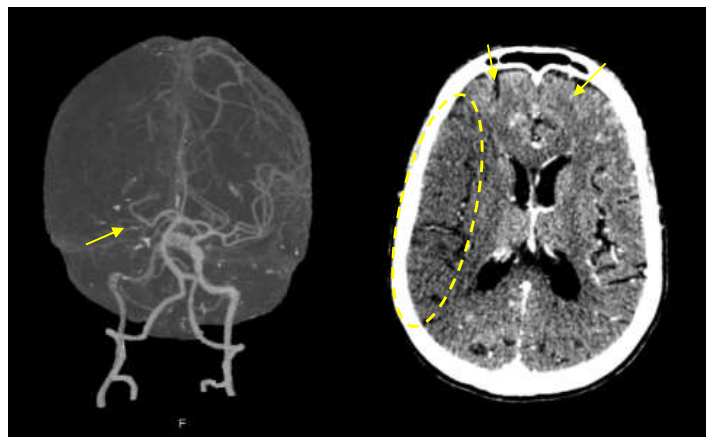
### *CPC-EM Capsule*

What do we already know about this clinical entity?  
*Common risk factors for septic embolisms are intravenous drug use, infectious endocarditis, and prosthetic cardiac valves.*

What makes this presentation of disease reportable?  
*Although septic emboli can occasionally cause large vessel occlusions, complete internal carotid artery occlusions rarely result from them.*

What is the major learning point?  
*Timely identification and appropriate management of septic embolism in high-risk populations is crucial to prevent severe neurological complications.*

How might this improve emergency medicine practice?  
*Consideration of this condition in patients with known risk factors and new neurological symptoms may lead to improved long-term neurological outcomes.*



**Image 2.** (Left) Computed tomography angiography of the head demonstrating a decrease in attenuation and caliber distal to the bifurcation (arrow) at the level of the internal carotid artery terminus with faint intermittent contrast distally that quickly dissipates. There is poor leptomeningeal collateral flow in the right hemisphere. (Right) Acute right middle cerebral artery infarction (circle) with slight effacement of the sulci and right to left shift with faint peripheral petechial hemorrhage (arrow).

cerebral vasculature, spleen, kidney, and mesentery. In addition to ischemic infarctions, disseminated disease can lead to the formation of meningitis or intracerebral infection when they propagate intracranially.<sup>5</sup> Typically, septic emboli are

small and affect more distal branches of the cerebral vasculature. Rarely, larger vegetations embolize and occlude more substantial blood vessels such as the internal carotid artery or middle cerebral artery, resulting in debilitating neurological symptoms. Strokes and transient ischemic attacks account for between 40-50% of neurological complications of IE.<sup>5</sup> Similar to strokes from a non-infectious source, the clinical presentation of a patient will depend upon the culprit vessel that is occluded.

It is important to note that despite the possibility of undiagnosed atrial fibrillation being the sole cause of this patient's thromboembolism, his medical history and risk factors made it far more likely that his presentation was related to a septic embolism. To the best of our knowledge this is only the sixth reported case of internal carotid artery occlusions as a result of septic embolism from IE.<sup>6,7</sup> Previous cases have been reported primarily in the context of mechanical thrombectomy retrieval.

In native cardiac valves, *S. aureus* accounts for between 30-35% of IE cases,<sup>8</sup> and carries an in-hospital mortality rate between 15-30%.<sup>9</sup> A multicenter prospective study conducted in 2011, which included 253 intensive care unit patients, revealed the severe prognosis of neurologic events caused by IE, with only one-third of patients surviving to discharge with functional independence.<sup>10</sup>

A traditional stroke evaluation including CT head without contrast and CT angiography of the head and neck should be pursued to establish the degree of ischemic insult. In the ED, TTE is recommended as the optimal modality for the initial evaluation of IE by both the American Heart Association and the European Society of Cardiology.<sup>11</sup> Thrombolysis for large vessel occlusions in the setting of IE is not frequently implemented due to the high risk of hemorrhagic transformation and lower rates of favorable outcomes,<sup>12</sup> and this increased risk is at least partly attributed to coexisting mycotic aneurysms.<sup>12</sup> The Society of Neurointerventional Radiology recommends that mechanical thrombectomy in patients with IE who suffer a large vessel occlusion may be safe as the risks and benefits are similar to those without IE.<sup>13,14</sup> If a patient's clinical presentation is concerning for septic embolism, broad-spectrum antibiotics and source control are the cornerstones of treatment and should be given as soon as possible.

## CONCLUSION

We present a rare case of an internal carotid occlusion resulting from a septic embolism in the setting of infectious endocarditis. This case is unique due to the extent of the ischemic insult it caused. Septic embolism should be considered in the differential diagnosis of patients with risk factors such as IV drug use who present with new neurological symptoms. The emergency physician should consider performing a point-of-care ultrasound to look for valvular vegetations, initiating early broad-spectrum antibiotics and source control as key early steps in the management of these patients. Thrombolysis should be

avoided due to the risk of hemorrhagic transformation. In certain patient populations, mechanical thrombectomy may be a possible management option.

The authors attest that their institution requires neither Institutional Review Board approval, nor patient consent for publication of this case report. Documentation on file.

---

**Address for Correspondence:** Thijs Wolf, DO, University of Rochester Medical Center, Division of Emergency Medicine, 601 Elmwood Ave, Box 655 Rochester, NY 14642. Email: Thijs\_Wolf@urmc.rochester.edu.

**Conflicts of Interest:** By the CPC-EM article submission agreement, all authors are required to disclose all affiliations, funding sources and financial or management relationships that could be perceived as potential sources of bias. The authors disclosed none.

**Copyright:** © 2023 Wolf et al. This is an open access article distributed in accordance with the terms of the Creative Commons Attribution (CC BY 4.0) License. See: <http://creativecommons.org/licenses/by/4.0/>

---

## REFERENCES

1. Stawicki SP, Firstenberg MS, Lyaker MR, et al. Septic embolism in the intensive care unit. *Int J Crit Illn Inj Sci.* 2013;3(1):58-63.
2. Pant S, Patel NJ, Deshmukh A, et al. Trends in infective endocarditis incidence, microbiology, and valve replacement in the United States from 2000 to 2011. *J Am Coll Cardiol.* 2015;65(19):2070-6.
3. Cahill TJ and Prendergast BD. Infective endocarditis. *Lancet (London, England).* 2016;387(10021):882-93.
4. Wurcel AG, Anderson JE, Chui KKH, et al. Increasing infectious endocarditis admissions among young people who inject drugs. *Open Forum Infect Dis.* 2016;3(3):ofw157.
5. Rauch RA and Jinkins JR. Infections of the central nervous system. *Curr Opin Radiol.* 1991;3(1):16-24.
6. Mowla A, Abdollahifard S, Sizardkhani S, et al. Endovascular treatment of large vessel occlusion strokes caused by infective endocarditis: a systematic review, meta-analysis, and case presentation. *Life (Basel, Switzerland).* 2022;12(12):2146.
7. Feil K, Küpper C, Tiedt S, et al. Safety and efficacy of mechanical thrombectomy in infective endocarditis: a matched case-control analysis from the German Stroke Registry-Endovascular Treatment. *Eur J Neurol.* 2021;28(3):861-7.
8. Mylonakis E and Calderwood SB. Infective endocarditis in adults. *N Engl J Med.* 2001;345(18):1318-30.
9. Leone S, Ravasio V, Durante-Mangoni E, et al. Epidemiology, characteristics, and outcome of infective endocarditis in Italy: the Italian Study on Endocarditis. *Infection.* 2012;40(5):527-35.
10. Sonneviller R, Mirabel M, Hajage D, et al. Neurologic complications and outcomes of infective endocarditis in critically ill patients: the ENDOcardite en REAnimation prospective multicenter study. *Crit*



- Care Med.* 2011;39(6):1474-81.
11. Grapsa J, Blauth C, Chandrashekar YS, et al. *Staphylococcus Aureus* infective endocarditis: JACC Patient Pathways. *J Am Coll Cardiol.* 2022;79(1):88-99.
  12. Asaithambi G, Adil MM, Qureshi AI. Thrombolysis for ischemic stroke associated with infective endocarditis: results from the nationwide inpatient sample. *Stroke.* 2013;44(10):2917-9.
  13. Matsukawa S, Go K, Yang T, et al. Low NIHSS score large vessel occlusion caused by infective endocarditis treated with thrombectomy. *J Stroke Cerebrovasc Dis.* 2023;32(2):106915.
  14. Al-Mufti F, Schirmer CM, Starke RM, et al. Thrombectomy in special populations: report of the Society of NeuroInterventional Surgery Standards and Guidelines Committee. *J Neurointerv Surg.* 2022;14(10):1033-41.

# Implanted Progestin Causing Pain and Psychiatric Disturbances in Porphyria Attack: A Case Report

Ryan K. Misek, DO\*  
Massimo F. Riitano, BS†

\*Midwestern University, Chicago College of Osteopathic Medicine, Department of  
Emergency Medicine, Downers Grove, Illinois

†Midwestern University, Chicago College of Osteopathic Medicine, Downers Grove, Illinois

Section Editor: Christopher San Miguel, MD

Submission history: Submitted October 31, 2022; Revision received April 20, 2023; Accepted April 20, 2023

Electronically published July 3, 2023

Full text available through open access at [http://escholarship.org/uc/uciem\\_cpccem](http://escholarship.org/uc/uciem_cpccem)

DOI: 10.5811/cpcem.1490

**Introduction:** Acute hepatic porphyrias (AHP) are a rare group of inherited disorders caused by abnormal functioning of the heme synthesis pathway. Patients often present with diffuse abdominal pain, neurologic dysfunction, and hyponatremia.

**Case Report:** We present a case of a 25-year-old female who presented with AHP after implantation of progestin birth control. The patient was confused, markedly tachycardic and hypertensive, and complained of severe abdominal pain. Spot urine ordered during the emergency department workup was later found positive for porphyrins and porphobilinogen (PBG).

**Conclusion:** Acute hepatic porphyrias typically present with nonspecific symptoms in young women and are often overlooked in the acute care setting. Spot urine testing for PBG and urine porphyrins should be initiated early in patients with clinical suspicion of AHP. [Clin Pract Cases Emerg Med. 2023;7(3):144–147.]

**Keywords:** *case report; porphyria; hemin; urine porphyrins.*

## INTRODUCTION

Acute hepatic porphyrias (AHP) comprise a rare group of inherited disorders caused by abnormal functioning of the heme synthesis pathway.<sup>1</sup> The dysfunction leads to the accumulation of metabolites and subsequent neurovisceral manifestations.<sup>1</sup> Heme is essential in the function of the cytochrome P450 (CYP450) pathway. Induction via medications such as sulfonamides, anesthetics, anticonvulsants, or sex hormones can precipitate acute attacks.<sup>1</sup> Patients often present with diffuse abdominal pain, neurologic dysfunction, and hyponatremia.<sup>2,3</sup> We present a case of a 25-year-old female who presented with AHP after implantation of progestin birth control.

## CASE REPORT

A 25-year-old female with a history of recent severe acute respiratory syndrome coronavirus 2 infection presented to the emergency department (ED) with altered mental status and lower abdominal pain of several days' duration. The patient was confused and agitated but was redirectable. The patient's mother at bedside reported that her daughter had an episode of

urinary incontinence and appeared to be delusional. She reported that the last time her daughter had acted similarly she had a supposed spider bite to her finger. The mother reported that the patient had fallen the previous day and struck her head. She also reported that the patient had a etonogestrel (a synthetic progesterone) birth control implant placed in her left arm 10 days prior. She endorsed inability to sleep. The patient denied any shortness of breath, constipation, back pain, fevers, or chills.

The physical examination was limited due to acute confusion, but vitals showed a blood pressure of 156/110 millimeters of mercury, a heart rate of 135 beats per minute, and respiration rate of 26 breaths per minute. The patient was noted to have a three-centimeter contusion to the right forehead. Abdominal examination revealed a soft and flat abdomen with intermittent voluntary guarding and no localizable tenderness, rebound, or rigidity.

Our review of the medical chart revealed that the patient had been seen at an outside hospital four days prior for similar complaints and discharged from the ED. Medical records showed she had a negative computed tomography (CT) of the

abdomen and pelvis with intravenous (IV) contrast, negative transvaginal ultrasound with Doppler, unremarkable speculum exam, negative *Chlamydia trachomatis* and *Neisseria gonorrhoeae* deoxyribonucleic acid probe, normal vaginal wet mount, and unremarkable lab work. Her pain had been treated and she was discharged with dicyclomine, ondansetron, ibuprofen, and docusate sodium. She reportedly had difficulty urinating despite having the urge and drinking plenty of water.

The patient was given droperidol 1.25 milligrams (mg) IV and morphine 2 mg IV without relief. A set of CTs of her head, neck, and abdomen were negative for acute pathology. A qualitative urine drug screen was positive for cannabinoids at a screening cutoff of 50 nanograms per milliliter (mL). A clean catch urine sample was collected and found to be red in color. The specimen tube was wrapped in Coban to protect against light, and spot urine porphyrin was sent to an outside facility for analysis. Her sodium was 118 milliequivalents per liter (mEq/L) (reference range, 135-145 mEq/L); 3% sodium chloride continuous IV infusion at a rate of 50 mL/hour (hr) was started after consultation with the nephrology service. She was admitted to the intensive care unit under the hospitalist service.

The patient remained acutely altered during her admission, and cardiology placed her on carvedilol 12.5 mg orally twice a day and clonidine 0.1mg/24hr transdermal patch to control her hypertension and tachycardia. She complained of weakness, and her creatine kinase was found to be over 5000 units/L (reference range, 30-145 U/L) on serial draws. Coronavirus disease 2019 antibody immunoglobulin (Ig) G was found to be positive, and the IgM was negative. An autoimmune panel was significant only for a slightly elevated anti-centromere antibody level. A work-up for pheochromocytoma via CT abdomen was negative. Magnetic resonance imaging with and without contrast did not reveal acute pathology. Cerebrospinal fluid was drawn via lumbar puncture, and testing for viral, bacterial, and fungal infections was negative.

The results of the spot urine porphyrin test, which were returned six days after admission, were significantly elevated as shown in Table 1. Concern was raised that the

**Table 1.** The patient’s lab test values collected on the day of admission show elevated porphyrins but were non-specific findings. When clinically correlated with her symptoms they increased the likelihood of an acute hepatic porphyria.

Spot Urine Porphyrins	Patient value	Reference range
Coproporphyrin-I urine-CRT ratio	39	0-6 µmol/mol
Coproporphyrin-III urine-CRT ratio	138	0-14 µmol/mol
Heptacarboxylate urine-CRT ratio	4	0-2 µmol/mol
Uroporphyrin urine-CRT ratio	435	0-4 µmol/mol

CRT, creatinine; µmol/mol, micromole per mole.

*CPC-EM Capsule*

What do we already know about this clinical entity?

*Acute Hepatic Porphyrin is a rare disorder caused by an inborn error of heme synthesis and presents with a unique constellation of non specific signs and symptoms.*

What makes this presentation of disease reportable?

*Acute Hepatic Porphyrin has rarely been reported after implantation of progesterone birth control.*

What is the major learning point?

*How to recognize acute porphyria attacks and how to initiate proper work-up and treatment from the emergency department.*

How might this improve emergency medicine practice?

*Early treatment of acute porphyria spares the patient significant morbidity and diagnosis leads to prevention of recurrent attacks.*

progesterone implant had triggered her attack, and it was removed the following day. The results of a 24-hr collection of urine porphyrin and porphobilinogen (PBG) (returned eight days after admission) were also elevated as shown in Table 2, which confirmed the diagnosis of AHP. The patient was started on dextrose 10% in water. Plasma porphyrins were also tested and demonstrate elevated plasma porphyrins of 34 nanomoles (nmol)/L (reference range, 0-15 nmol/L). The patient had returned to baseline mental status but was

**Table 2.** The patient’s lab test values collected over a 24-hour period show elevated porphyrins. Significantly elevated porphobilinogen is highly sensitive and specific for acute hepatic porphyrias.

24-hr Urine porphyrins and porphobilinogen	Patient value	Reference range
Coproporphyrin-I urine-CRT ratio	21	0-6 µmol/mol
Coproporphyrin-III urine-CRT ratio	66	0-14 µmol/mol
Heptacarboxylate urine-CRT ratio	10	0-2 µmol/mol
Porphobilinogen 24 hr	617.4	0-11 µmol/mol
Porphobilinogen per volume	233.0	0-8.8 µmol/mol
Uroporphyrin urine-CRT ratio	173	0-4 µmol/mol

CRT, creatinine; µmol/mol, micromole per mole; Hr, hour.

unable to ambulate. She was transferred to a tertiary care center where she received four hemin infusions at 4 mg per kilogram per day.

The patient had a prolonged hospital course after transfer for a total of 33 days inpatient. She had severe weakness and myopathy that prevented her from ambulating and required 14 days of inpatient physical therapy. She required 22 visits at outpatient physical therapy over the course of three months and subsequently suffered a second attack of porphyria five months after the initial presentation, which resolved with four days of hemin infusion. Genetic testing showed a positive heterozygous hydroxymethylbilane synthase pathologic mutation, which indicated a final diagnosis of acute intermittent porphyria (AIP).

## DISCUSSION

Acute hepatic porphyrias comprise a rare group of genetic diseases caused by altered heme biosynthesis. The four subtypes of AHP are AIP, variegate porphyria, hereditary coproporphyria, and delta-aminolevulinic acid dehydratase deficiency porphyria.<sup>1</sup> The most common is AIP, with one carrier per 2,000 people in the Western population; it is inherited as an autosomal dominant mutation with 10% penetrance with an 80-90% female predominance.<sup>4</sup> It typically presents in young women of reproductive age with abdominal pain, hyponatremia, fatigue, confusion, and stupor. Patients can experience hypertension and tachycardia that can be life-threatening.<sup>1-3</sup> Insomnia is often an early symptom of an AIP attack.<sup>5</sup> Metabolic stressors and cytochrome (CYP) P450 inducers, such as sulfonamides, alcohol, and sex hormones, can precipitate acute attacks.<sup>6</sup> Variegate porphyria and HCP can also present with cutaneous blistering on light-exposed skin.<sup>11</sup>

Acute hepatic porphyria can present after implantation of progesterone birth control.<sup>7</sup> Progesterone is thought to be responsible for cyclical attacks in women, but there is likely a multifactorial cause involving individual variation in progesterone metabolism and CYP450 activity. The risk for potential complications and benefits of hormonal therapy should be evaluated individually by a clinician, and hormone therapy should be stopped if patients begin to experience porphyria symptoms.<sup>3</sup>

Severe diffuse abdominal pain occurs in 90% of patients and in the presence of normal imaging and lab results, making diagnosis difficult.<sup>8</sup> Since patients often have a history of repeat visits to the ED for undifferentiated abdominal pain where they receive opioid analgesics, they may be suspected of drug-seeking behavior. Cannabinoid hyperemesis syndrome is becoming increasingly prevalent and may obscure the clinical picture in patients who smoke marijuana.<sup>9</sup> Accurate and timely diagnosis of porphyria prevents the development of long-term complications that include chronic kidney disease, chronic hypertension, hepatocellular carcinoma, polyneuropathy, depression, and anxiety.<sup>8,10</sup>

Current recommendations for diagnosis of patients suspected of AHP vary, but from the emergency physician's standpoint, a spot urine collection for both PBG and total porphyrins is specific and sensitive enough to make the diagnosis.<sup>11,12</sup> Twenty-four-hour collection of urine is no longer considered necessary for diagnosis and delays treatment. The sample container should be protected from light with a foil wrapping and frozen or refrigerated to protect against degradation of light-sensitive compounds. Urine porphyrin elevation occurs in many medical conditions and must be correlated clinically to rule in AHP. Urine discoloration is a common finding, but nonspecific. Second-line testing of plasma porphyrins with fluorescence or collection of fecal porphyrins can be conducted later to differentiate the AHP subtype.<sup>11</sup>

Symptom control of the acute attack consists of IV opioids, antiemetics, and anxiolytics. Beta-blockers are commonly used to prevent tachycardia, arrhythmia, and hypertensive crisis. Hemin therapy is the definitive treatment in moderate to severe attacks and should be started after the demonstration of typical symptoms of acute porphyria and elevation of urine PBG.<sup>1,3</sup> Carbohydrate loading via dietary intake or IV infusions at 300-500 grams per day can be used during mild attacks or if hemin is not available locally, and patients receiving infusions should be closely monitored for hyponatremia. Any patient with an acute porphyria episode with worsening symptoms or lack of improvement within one to two days should receive hemin therapy.<sup>1,3,8</sup> Prophylactic treatments for recurrent attacks include gonadotropin-releasing hormone agonists, IV hemin, and subcutaneous givosiran, which is a small interfering ribonucleic acid medication causing degradation of the delta-aminolevulinic acid synthase 1 enzyme.<sup>11</sup> Our patient was advised to begin prophylactic hemin or givosiran therapy should she experience more than 4-6 attacks per year.

## CONCLUSION

We present a case of a patient experiencing worsening symptoms of AHP following progesterone birth control implantation. Acute hepatic porphyria is one of a rare group of diseases that typically present with nonspecific symptoms in young women and are often overlooked in the acute care setting.<sup>2</sup> Spot urine testing for PBG and urine porphyrins should be initiated in patients with clinical suspicion of AHP.<sup>11,12</sup> Symptoms are managed with IV analgesia, antiemetics, and beta-blockers. Timely treatment via correction of electrolyte imbalances and initiation of hemin therapy prevents significant morbidity and mortality.<sup>1,3,8</sup>

The authors attest that their institution requires neither Institutional Review Board approval, nor patient consent for publication of this case report. Documentation on file.



**Address for Correspondence:** Ryan K. Misek, DO, FACOEP, FACEP, Midwestern University, 555 31<sup>st</sup> Street, Downers Grove, IL 60515. Email: rmisek@midwestern.edu.

**Conflicts of Interest:** By the CPC-EM article submission agreement, all authors are required to disclose all affiliations, funding sources and financial or management relationships that could be perceived as potential sources of bias. The authors disclosed none.

**Copyright:** © 2023 Misek et al. This is an open access article distributed in accordance with the terms of the Creative Commons Attribution (CC BY 4.0) License. See: <http://creativecommons.org/licenses/by/4.0/>

## REFERENCES

1. Anderson KE, Bloomer JR, Bonkovsky HL, et al. Recommendations for the diagnosis and treatment of the acute porphyrias. *Ann Intern Med.* 2005;142(6):439.
2. Puy H, Gouya L, Deybach J-C. Porphyrias. *Lancet.* 2010;375(9718):924-37.
3. Pischik E and Kauppinen R. An update of clinical management of acute intermittent porphyria. *Appl Clin Genet.* 2015;8:201-214.
4. Bissell DM, Anderson KE, Bonkovsky HL. Porphyria. *N Engl J Med.* 2017;377(9):862-72.
5. Stölzel U, Doss MO, Schuppan D. Clinical guide and update on porphyrias. *Gastroenterology.* 2019;157(2):365-81.
6. Tschudy DP, Magnussen CR, Valsamis M. Acute intermittent porphyria: clinical and selected research aspects. *Ann Intern Med.* 1975;83(6):851.
7. Strome A, Hawkins SD, Huang YY, et al. A case report on variegate porphyria after etonogestrel placement. *JAAD Case Rep.* 2022;22:104-6.
8. Stein PE, Badminton MN, Rees DC. Update review of the acute porphyrias. *Br J Haematol.* 2016;176(4):527-38.
9. Perisetti A, Gajendran M, Dasari CS, et al. Cannabis hyperemesis syndrome: an update on the pathophysiology and management. *Ann Gastroenterol.* 2020;33(6):571-8.
10. Gouya L, Ventura P, Balwani M, et al. Explore: a prospective, multinational, natural history study of patients with acute hepatic porphyria with recurrent attacks. *Hepatology.* 2019;71(5):1546-58.
11. Anderson KE, Lobo R, Salazar D, et al. Biochemical diagnosis of acute hepatic porphyria: updated expert recommendations for Primary Care Physicians. *Am J Med Sci.* 2021;362(2):113-21.
12. American Porphyria Foundation. Diagnosis and testing. Available at: <https://porphyriafoundation.org/for-healthcare-professionals/diagnosis-and-testing/>. Accessed September 11, 2022.

# A Previously Healthy Infant with Lemierre Syndrome in the Emergency Department: Case Report

Adeola Adekunbi Kosoko, MD  
Omoyeni O. Clement, MD

University of Texas Health Sciences Center at Houston, Department of Emergency Medicine, Houston, Texas

Section Editor: Anna McFarlin, MD

Submission history: Submitted November 21, 2022; Revision received May 2, 2023; Accepted May 5, 2023

Electronically published August 1, 2023

Full text available through open access at [http://escholarship.org/uc/uciem\\_cpem](http://escholarship.org/uc/uciem_cpem)

DOI: 10.5811/cpem.1580

**Introduction:** Lemierre syndrome (LS) is a rare condition with a high mortality risk. It is well described in older children and young adults involving bacteremia, thrombophlebitis, and metastatic abscess commonly due to *Fusobacterium* infections. Young, pre-verbal children are also susceptible to LS; thus, careful attention must be given to their pattern of symptoms and history to identify this condition in the emergency department (ED).

**Case Report:** A 12-month-old previously healthy boy with a recent diagnosis of acute otitis media and viral illness presented to the ED with a complaint of fever. Additional symptoms developed at the head and neck and were noted on subsequent ED visits. Advanced imaging revealed significant lymphadenopathy and deep space inflammation extending to the mediastinum. Subsequent imaging confirmed extensive sinus and deep vein thromboses, consistent with LS. Methicillin-resistant *Staphylococcus aureus* (MRSA) was the only organism identified. After surgical debridement, appropriate intravenous antibiotics, and heparin anticoagulation therapy, the patient experienced full recovery after prolonged hospitalization.

**Conclusion:** A febrile infant with multiple acute care visits and development of lymphadenopathy, decreased oral intake, decreased cervical range of motion, and sepsis should raise suspicion for Lemierre syndrome. The medical evaluation of deep neck spaces and deep veins should be similar to that of older children and adults with LS, including advanced imaging of the head and neck. However, medical management should particularly target MRSA due to its emerging prevalence among infantile LS cases. Further research is necessary to determine the optimal management strategies of LS for this age group. [Clin Pract Cases Emerg Med. 2023;7(3):148–152.]

**Keywords:** *infant; pediatric; Lemierre; thrombus; thrombophlebitis; MRSA; mediastinitis; case report.*

## INTRODUCTION

Lemierre syndrome (LS) is a well described condition characterized by the triad of internal jugular (IJ) thrombosis, pharyngitis, and metastatic abscess due to septic emboli. Patients classically present with fever and prolonged pharyngitis with a deteriorating clinical course. Historically, anaerobic pathogens, specifically *Fusobacterium necrophorum* or polymicrobial infections, cause LS.<sup>1</sup> The median age of patients with LS is 22 years old.<sup>2</sup> A minority of patients present within the first decade of life (8%).<sup>2</sup>

Although clinical diagnosis is typically made on signs and symptoms with computed tomography (CT) of the head

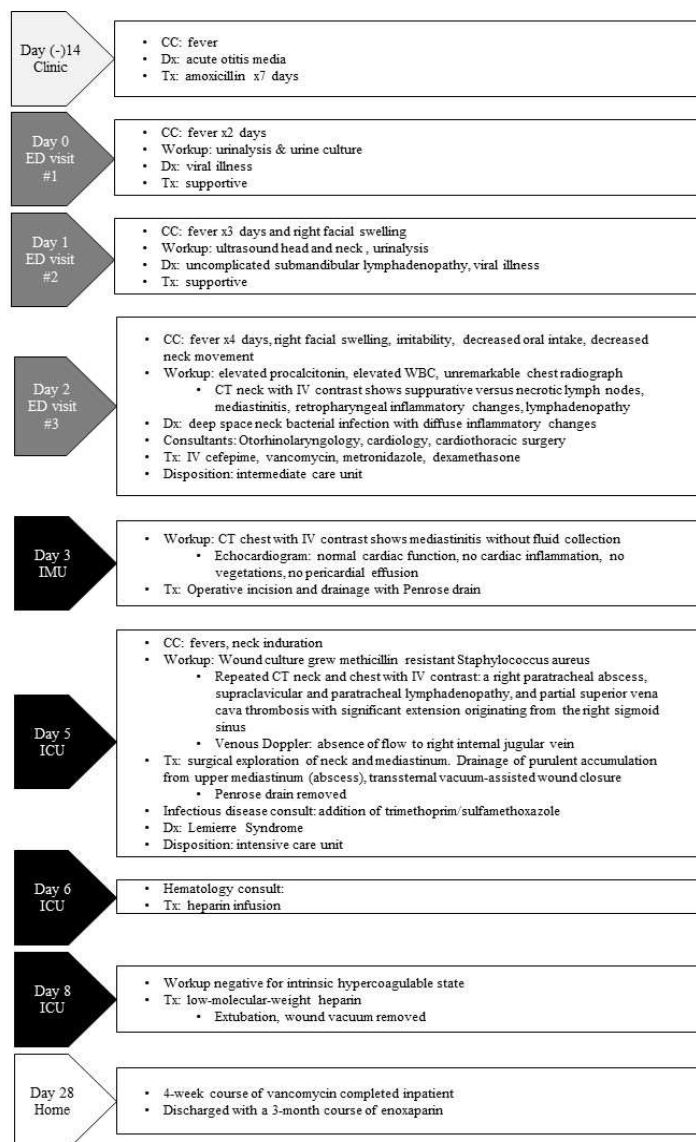
and neck with intravenous (IV) contrast, it is critical to ultimately obtain cultures of the affected sites. Depending on the respective symptoms, imaging of other body areas should also be evaluated for metastatic abscesses. For example, there is documentation of septic emboli being found in the brain, lungs, and, as in this case, the mediastinum. Doppler ultrasound may enhance the assessment of thromboembolic disease.

Emergency management strategies emphasize cardiovascular resuscitation with IV fluids and broad-spectrum antibiotics, particularly when considering bacterial causes unique to LS. Early blood culture samples should be collected

as they report positive in an estimated 86% of cases.<sup>3</sup> The role of anticoagulation therapy for LS remains controversial.

## CASE REPORT

A 12-month-old boy presented to the emergency department (ED) with three days of fever. The mother was concerned for the development of right-sided facial swelling approximately three hours prior to presentation, increased irritability, and decreased oral intake. There were no reported gastrointestinal losses. The boy had an uncomplicated term birth and was vaccinated as appropriate for his age. Two weeks prior, he had completed a seven-day course of amoxicillin for acute otitis media (Figure). One day prior, the



**Figure.** Timeline of events for an infant diagnosed with Lemierre syndrome. ED, emergency department; IMU, intermediate care unit; ICU, intensive care unit; CC, chief complaint; Dx, diagnosis; Tx, treatment; WBC, white blood cell; CT, computed tomography; IV, intravenous.

## CPC-EM Capsule

What do we already know about this clinical entity?

*Lemierre syndrome (LS) is a rare Fusobacterium bacteria oropharyngeal infection complicated by septic thrombophlebitis typically affecting adolescents and young adults.*

What makes this presentation of disease reportable?

*This case describes an infant with extensive LS with mediastinitis due to methicillin-resistant Staphylococcus aureus (MRSA).*

What is the major learning point?

*Young children are also at risk for LS, but the causative bacteria is more likely to be MRSA.*

How might this improve emergency medicine practice?

*Lemierre syndrome on the differential diagnosis for an infant with fever and lymphadenopathy will guide with antibiotic selection and understanding indication for neck computed tomography.*

boy had visited a different ED with a complaint of “fever.” He had a urinalysis not suggestive of a urinary tract infection. After receiving antipyretics, he was discharged with supportive care.

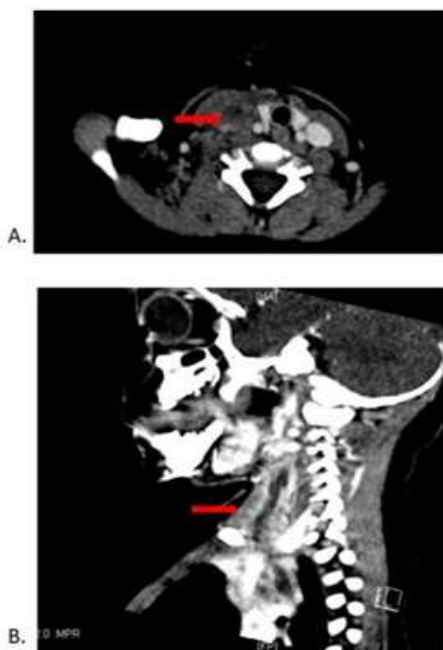
On evaluation, the patient’s core temperature was 101.2° Fahrenheit (F), the peripheral pulse rate was 182 beats per minute, the respiratory rate was 36 breaths per minute, and pulse oximetry was 97%. He was a well-appearing and playful child in no acute distress and with slight right-sided facial swelling along the parotid region involving the mandible without fluctuance, crepitus, or cutaneous findings. His bilateral tympanic membranes were normal. His cardiorespiratory evaluation was grossly normal except for tachycardia, which was concordant with his fever. A soft-tissue head and neck ultrasound demonstrated bilateral submandibular lymph nodes, the largest measuring 2.7 × 1.5 × 1.5 centimeters (cm) on the right and 2.4 × 0.9 × 0.9 cm on the left without organized fluid collection, cavitation, or abscess. Such findings were presumed to be viral in etiology, and the patient was diagnosed with uncomplicated viral lymphadenitis and discharged with supportive management instructions.

The patient returned to the ED on his fourth day of illness with parental concern about worsening irritability, new avoidance of right-sided neck movement, and persistent fever. In addition, he had decreased oral intake without choking,

vomiting, or respiratory distress, with resultant decreased urine output. His vital signs were as follows: temperature 102°F; blood pressure 118/75 millimeters of mercury, respirations between 28-35 breaths per minute, and pulse 140-156 beats per minute. His physical exam showed new and worsened right submandibular, submental, and cervical lymphadenopathy with decreased neck range of motion. However, he had a clear oropharyngeal exam and was protecting his airway. On otoscopy, he had a right-sided serous accumulation behind the tympanic membrane.

The basic metabolic panel was normal. His white blood cell count was  $14.9 \times 10^9/\mu\text{L}$  (reference range  $5.5 \times 10^9/\mu\text{L} - 18 \times 10^9/\mu\text{L}$ ), hemoglobin 10.2 grams per deciliter (g/dL) (10.5-13.5 g/dL), platelets  $315 \times 10^9/\mu\text{L}$  ( $133 \times 10^9/\mu\text{L} - 450 \times 10^9/\mu\text{L}$ ), with 72.2% neutrophils (15.0-40.0%). The whole blood lactic acid level was 1.5 millimoles per liter (mmol/L) (0.5-2.2 mmol/L), while procalcitonin was elevated at 0.78 nanograms ng/mL (normal high 0.10 ng/mL).

A chest radiograph was grossly unremarkable. Most notably, computed tomography (CT) of the neck and soft tissues with intravenous (IV) contrast revealed suppurative versus necrotic lymph nodes along the right upper neck, retropharyngeal phlegmonous/inflammatory changes, and fluid tracking inferiorly toward the mediastinum concerning for early mediastinitis (Image). Initial IV antibiotic management



**Image.** Computed tomography imaging of the neck with intravenous contrast shows multiple enlarged lymph nodes in the right upper neck with suppuration and/or necrosis; submandibular edema/phlegmonous change; mass effect of lymph nodes; fluid tracking inferiorly along the right neck extending to the superior mediastinum; and retropharyngeal phlegmonous/inflammatory changes (arrows). Right thrombophlebitis with occlusive clot beginning at the right sigmoid sinus to the superior vena cava. A) Axial view, B) sagittal view.

included vancomycin, cefepime, and metronidazole. The patient underwent a venous Doppler of the bilateral upper extremities in which the right IJ was not visualized. Complete echocardiography demonstrated a normal cardiac structure and no concerns for vegetations or pericardial effusion.

The patient was admitted to an inpatient step-down unit. Phlegmon and mediastinitis were managed operatively with incision and drainage by otorhinolaryngology (ENT). Wound cultures grew methicillin resistant *Staphylococcus aureus* (MRSA), and blood cultures demonstrated no growth.

Two days later, the patient acutely developed a worsening induration along the neck and a new fever, prompting another IV-contrast CT image of the neck and chest. Concerning findings included a right paratracheal abscess, supraclavicular and paratracheal lymphadenopathy, and an occlusive clot intracranially from the right sigmoid sinus that continued to the right IJ, right facial vein, and into the superior vena cava.

The patient went to the operating room emergently with ENT and cardiothoracic surgery for exploration. Trimethoprim/sulfamethoxazole was added to his care based on the recommendations of infectious diseases consultation. The team drained a purulent accumulation (5-7 mL) from the upper mediastinum and placed a transsternal, vacuum-assisted wound closure. Despite the extensive inflammation of surrounding structures, there was no cardiac or vascular involvement. The patient received multiple combinations of IV antibiotics during his hospitalization. Ultimately, the sensitivities of MRSA detection determined that vancomycin provided sufficient coverage.

A repeat venous Doppler ultrasound examination on the same day as his second surgery revealed a persistent lack of flow in the right IJ. The patient was started on heparin infusion and eventually transitioned to low-molecular-weight heparin with plans for a three-month anticoagulation therapy. Hypercoagulable workups did not identify other causes of thrombus.

Three months after discharge, a magnetic resonance venogram and Doppler ultrasound showed normal blood flow. Approximately eight months following his admission, he had a repeat CT chest with IV contrast and CT angiography of the head and neck that demonstrated full resolution of disease. Since then, the patient has not experienced any complications.

## DISCUSSION

Lemierre syndrome is a rare condition with high mortality. The condition is well described in older children and adults with classic presentation: sore throat or upper respiratory symptoms with prolonged fevers; lethargy; neck pain; lymphadenopathy; and sequelae of septic emboli. The presentation of this infant was consistent with LS: recent diagnosis of acute otitis media; lymphadenopathy; and persistently high fever. While pre-verbal children cannot describe pharyngeal pain, they commonly demonstrate it with decreased oral intake indicative of acute pharyngitis (e.g.,



herpangina or hand, foot, and mouth disease).<sup>4</sup> Although lymphadenopathy of the head and neck in young children is common and often benign, this patient developed restricted neck mobility, which was concerning for occult deep space infection of the head and neck and prompted further workup. With appropriate imaging we identified diffuse inflammation and extensive thrombosis.

Few cases of LS have been reported in young children/infants. Like older patients, there are no known predisposing risk factors. Based on the findings of a previous systematic review, the top three sources of infection related to LS were the tonsils (37%), upper respiratory tract (30%), and chest/lower respiratory tract infections (25%).<sup>1</sup> In this case, we believe that acute otitis media and an acute viral illness was the likely infectious source in accordance with what was described in previous medical evaluations. Head and neck infections, such as otitis media, are known to be associated with sigmoid sinus or other central venous thromboses, especially in preschool age children.<sup>5</sup>

*Fusobacterium necrophorum*, which is part of the normal anaerobic flora of the human oral cavity, is classically implicated as a cause of LS in older children and adults. However, a previous literature review reported that *Fusobacterium* infections in children <two years old are rare; only 12 cases in which *Fusobacterium* were the causative agents of mastoiditis have been documented during a 40-year period.<sup>6</sup> Another retrospective review from 2017 documented six cases of LS secondary to MRSA in the pediatric population, a third of which were in infants <one year old.<sup>7</sup> Hence, MRSA is an emerging source of LS, particularly in young children, and its preponderance coincides with the growing incidence of MRSA in the community since the early 2000s.<sup>7</sup> In our patient, MRSA was the only pathogen isolated from cultures of suppurative mediastinal collections. Our findings have direct implications on the recommendations regarding initial antibiotic selection for LS in young children.

As in older subgroups, this child underwent a CT with contrast, which is the preferred diagnostic measure in LS to visualize the extent or complications of local inflammation and detect potential deep vein thromboses. He also received multiple Doppler ultrasounds to evaluate the extent of the IJ thrombus. Internal jugular and other deep vein thrombophlebitis is diagnostic for LS.<sup>8</sup> However, the role of anticoagulation in preventing the extension of septic thrombi in LS remains controversial; some 64% of patient cases reported of LS received anticoagulation mostly as an adjunct therapy.<sup>8</sup>

The therapeutic emphasis for LS, however, is infection control over anticoagulation.<sup>8</sup> To date, there are no guidelines for using anticoagulation in children with LS. Despite the initial surgical intervention targeting the source control and extensive clot burden, our patient's clinical condition deteriorated. Therefore, a hematology consultant helped to guide the anticoagulation therapy recommendations for this

patient, initially with heparin and then with low-molecular weight heparin. However, both short-term and long-term implications of treating young children with LS with anticoagulants are unknown.

Pediatric patients (66%) frequently require surgical interventions for the management of LS, which involve debridement, incision and drainage, and even exploratory laparotomy.<sup>9</sup> This child was diagnosed with retropharyngeal phlegmon (14% of cases),<sup>1</sup> abscess, and mediastinitis, and surgical interventions using ENT and cardiothoracic surgery were required after the clinical condition worsened.

## CONCLUSION

Diagnosis and management of Lemierre syndrome in young children necessitates a deep understanding of the various presentations and management strategies. One must pay astute attention to a constellation of subtle symptoms in presentation, including prolonged fever, lymphadenopathy, decreased oral intake, restricted range of neck motion, and multiple acute/subacute preceding healthcare visits. Rather than the traditional emphasis on anaerobic and polymicrobial antibiotic targets, the pathogen profile of young children with LS may require more emphasis on MRSA coverage.

Lemierre syndrome is a complex condition that is better understood and described in young adults and older children. Further investigation is needed to understand the predisposing factors for young children with LS and to employ optimal management strategies for the youngest age group affected by this condition.

The authors attest that their institution requires neither Institutional Review Board approval, nor patient consent for publication of this case report. Documentation on file.

---

*Address for Correspondence:* Adeola A. Kosoko, MD, The University of Texas Health Science Center at Houston, Department of Emergency Medicine, 6431 Fannin, JLL 260G, Houston, TX 77030. Email: Adeola.A.Kosoko@uth.tmc.edu.

*Conflicts of Interest:* By the CPC-EM article submission agreement, all authors are required to disclose all affiliations, funding sources and financial or management relationships that could be perceived as potential sources of bias. The authors disclosed none.

*Copyright:* © 2023 Kosoko et al. This is an open access article distributed in accordance with the terms of the Creative Commons Attribution (CC BY 4.0) License. See: <http://creativecommons.org/licenses/by/4.0/>

---

## REFERENCES

1. Karkos PD, Asrani S, Karkos CD, et al. Lemierre's syndrome: a systematic review. *Laryngoscope*. 2009;119(8):1552-9.

2. Lee W-S, Jean S-S, Chen F-L, et al. Lemierre's syndrome: a forgotten and re-emerging infection. *J Microbiol Immunol Infect.* 2020;53(4):513-7.
3. Alves S, Stella L, Carvalho I, et al. Lemierre's syndrome: a disguised threat. *BMJ Case Rep.* 2019;12(4):e228397.
4. Amir J, Harel L, Smetana Z, et al. Treatment of herpes simplex gingivostomatitis with aciclovir in children: a randomised double blind placebo controlled study. *BMJ.* 1997;314(7097):1800.
5. deVeber G, Booth F, Bjornson B, et al. Cerebral sinovenous thrombosis. *New Engl J Med.* 2001;345(24):1777-8.
6. Stergiopoulou T and Walsh T.J. *Fusobacterium necrophorum* otitis and mastoiditis in infants and young toddlers. *Eur J Clin Microbiol Infect Dis.* 2016;35(5):735-40.
7. Jariwala RH, Srialluri S, Huang MZ, et al. Methicillin-resistant *Staphylococcus aureus* as a cause of Lemierre's syndrome. *Pediatr Infect Dis J.* 2017;36(4):429-31.
8. Johannesen K and Bodtger U. Lemierre's syndrome: current perspectives on diagnosis and management. *Infect Drug Resistance.* 2016;9:221-7.
9. Patel PN, Levi JR, Cohen MB. Lemierre's syndrome in the pediatric population: trends in disease presentation and management in literature. *Int J Pediatr Otorhinolaryngol.* 2020;136:110213.

# Posterior Reversible Encephalopathy Syndrome in a Patient with Septic Shock: A Case Report

Eric Boccio, MD\*  
Fiore Mastroianni, MD†  
Todd Slesinger, MD‡

\*UMass Chan Medical School – Baystate, Department of Emergency Medicine, Department of Healthcare Delivery & Population Sciences, Springfield, Massachusetts

†New York University Long Island School of Medicine, Department of Medicine, Mineola, New York

‡Herbert Wertheim College of Medicine, Florida International University, Department of Emergency Medicine, Miami, Florida

Section Editor: Joel Moll, MD

Submission history: Submitted December 13, 2022; Revision received May 10, 2023; Accepted May 11, 2023

Electronically published June 25, 2023

Full text available through open access at [http://escholarship.org/uc/uciem\\_cpccem](http://escholarship.org/uc/uciem_cpccem)

DOI: 10.5811/cpcem.1461

**Introduction:** Posterior reversible encephalopathy syndrome (PRES) is a reversible condition with nonspecific neurologic and characteristic radiologic findings. Clinical presentation may include headache, nausea, vomiting, altered mental status, seizures, and vision changes. Diagnosis is confirmed through T2-weighted brain magnetic resonance imaging (MRI) showing bilateral hyperintensities in the white matter of posterior circulatory regions.

**Case Report:** We report a case of PRES in a patient suffering from complicated diverticulitis. Following medical management in the emergency department, the patient deteriorated, becoming hypotensive and altered. Bowel resection under general anesthesia was performed. Postoperative brain MRI demonstrated bilateral and symmetric T2 signal hyperintensities suggestive of PRES. Following supportive treatment, the patient was discharged from the surgical intensive care unit on postoperative day 21 with no residual deficits.

**Conclusion:** It is important to recognize the nonspecific neurologic symptoms associated with PRES. Emergency physicians should suspect acute PRES when managing patients with prolonged or unexplained encephalopathy, while recognizing that hypertension need not be present. [Clin Pract Cases Emerg Med. 2023;7(3):153–157.]

**Keywords:** *posterior reversible encephalopathy syndrome; PRES; septic shock; case report.*

## INTRODUCTION

Posterior reversible encephalopathy syndrome (PRES) (known also as posterior reversible leukoencephalopathy and reversible posterior cerebral edema syndrome) is both a clinical and radiological entity, since it is defined by nonspecific neurologic symptoms and characteristic radiologic findings. Clinical presentation of PRES may include headache, nausea, vomiting, altered mental status, seizures, and visual loss or disturbance. Initial findings may not be specific enough to effectively raise clinical suspicion or confirm diagnosis. In contrast, neuroimaging demonstrates characteristic transient changes, and diagnosis is typically made based upon T2-

weighted magnetic resonance imaging (MRI) findings of hyperintensities predominantly in the posterior white matter, and less so in the surrounding cerebral cortex.

Although the cause of PRES is not clearly established, dysfunction in cerebral autoregulation and degradation of the blood-brain barrier has been posited.<sup>1</sup> Posterior reversible encephalopathy syndrome is a mostly reversible condition, and treatment should focus on alleviating the suspected underlying cause. In rare instances, symptoms of PRES are not reversible, and patients may suffer from cerebellar herniation and residual neurologic deficits. Many reports have described PRES in the setting of uncontrolled hypertension secondary to pre-eclampsia

and eclampsia, immunosuppressive therapies, renal insufficiency, post-transplantation, and lupus,<sup>2-5</sup> in contrast-related anaphylaxis and alcohol withdrawal,<sup>6</sup> as well as in the postoperative setting following spinal surgery<sup>7</sup> and thoracotomy.<sup>8</sup> Less frequently reported are cases of PRES in the setting of hypotension and various shock states. The etiology of this hypotensive subset of patients may still be due to dysfunction of cerebral blood flow; however, hypertension as a primary mechanism is nonexplanatory.

This case report illustrates a novel presentation of PRES diagnosed in a patient suffering from septic shock secondary to complicated diverticulitis who required vasopressors and surgical bowel resection under general anesthesia.

## CASE REPORT

A 68-year-old female with a known history of diverticulosis, hypercholesterolemia, and hypothyroidism presented to our emergency department (ED) complaining of three days of worsening abdominal pain. The pain was severe in the lower quadrants and more so in the left lower quadrant. Review of systems was notable for fever, chills, and diarrhea. She denied any associated nausea or vomiting. In a past exacerbation of her diverticulosis she had experienced lower gastrointestinal bleeding. Her last colonoscopy had been performed three years prior to date of presentation and showed diverticula. Current medications included aspirin, levothyroxine, atorvastatin, and ramipril. On physical exam, the abdomen was diffusely tender and distended with guarding. There were no other pertinent findings. Initial ED vital signs were within normal limits, with the exception of an elevated oral temperature that ranged between 99.0-102.9° Fahrenheit throughout the ED course.

Computed tomography (CT) of the abdomen and pelvis with iodinated intravenous contrast demonstrated a perforated diverticulum in the sigmoid colon and showed local extraluminal air. On admission, laboratory results revealed mild leukocytosis (11,500/microliters [uL]) (reference range 4,000-11,000/uL) with increased neutrophils (9,400/uL) (2,500-6,000/uL). There were also trace leukocyte esterase and 5-10 white blood cells per high-power field found in urinalysis. The patient was admitted to the surgical service for observation and initially treated with piperacillin/tazobactam.

While inpatient, the patient's clinical condition deteriorated resulting in fluid-refractory tachycardia and hypotension. She was intubated and taken to the operating room for surgical resection of the perforated bowel under general anesthesia, and a successful Hartman procedure was performed with minimal blood loss. Postoperatively, the patient was maintained on norepinephrine for hemodynamic support as well as fentanyl, midazolam, and propofol for post-intubation sedation. During her postoperative recovery, the patient failed to return to her baseline normal mental status, becoming increasingly agitated, delirious, and uncooperative. Soft physical restraints were maintained on both wrists.

### *CPC-EM Capsule*

What do we already know about this clinical entity?

*Posterior reversible encephalopathy syndrome (PRES) has nonspecific neurologic and characteristic radiologic findings typically described in the setting of hypertension.*

What makes this presentation of disease reportable?

*We present an unusual case of PRES in a patient suffering from septic shock secondary to complicated diverticulitis.*

What is the major learning point?

*Posterior reversible encephalopathy syndromeshould be considered in the differential of prolonged or otherwise unexplained encephalopathy, even in normo- and hypotensive patients.*

How might this improve emergency medicine practice?

*Awareness of PRES should facilitate ordering of appropriate neuroimaging, specifically brain magnetic resonance imaging, allowing for confirmation of characteristic radiologic findings.*

A CT head without contrast was performed on postoperative day 7 to investigate persistent mental status changes and visual deficits. Multiple hypodensities in the white matter of the posterior parietal and occipital lobes were identified (Image 1).

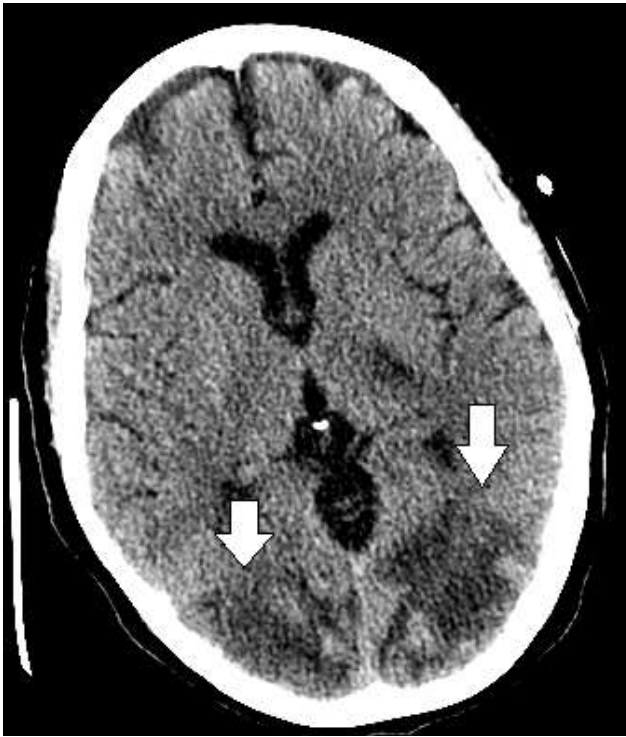
The next day, MRI brain without contrast demonstrated bilateral and symmetric T2-weighted signal hyperintensities confined to the white matter of the posterior cerebral cortex and cerebellum (Image 2).

The symmetrical nature of the abnormality and its confinement to the posterior cortex made it highly suspicious for PRES. Following the MRI, a 24-hour video electroencephalogram study was performed, which showed moderate diffuse cortical dysfunction and background slowing. The patient continued to receive supportive measures over several days and was discharged on postoperative day 21 with no residual neurologic deficits.

## DISCUSSION

Posterior reversible encephalopathy syndrome is referred to as a neurotoxic state characterized by variable clinical signs and symptoms, unique radiologic features, and a general



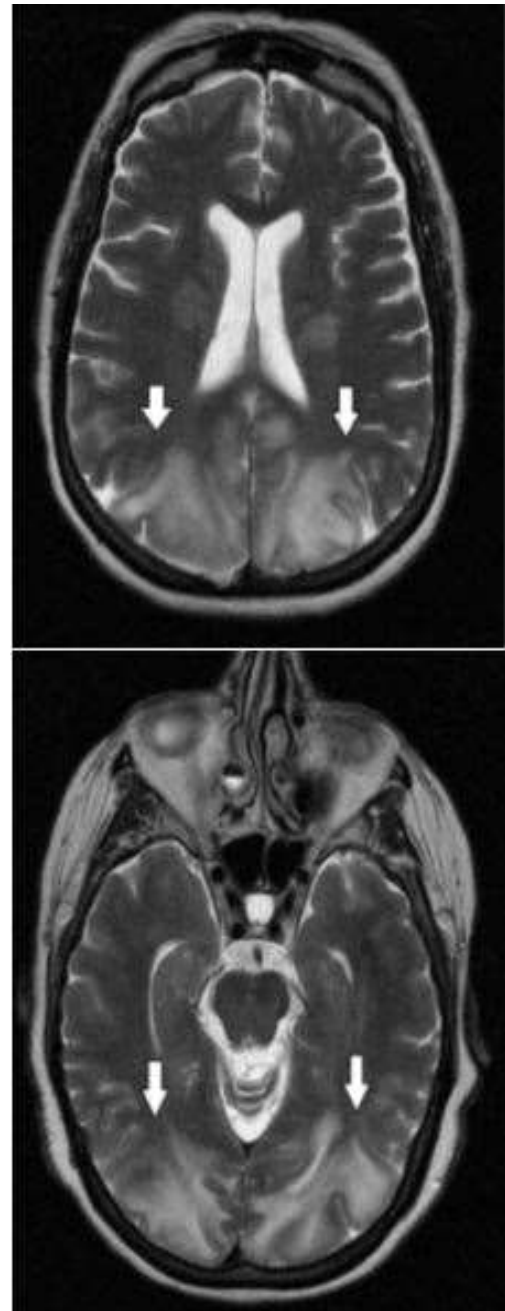


**Image 1.** Computed tomography head imaging performed on postoperative day seven demonstrating multiple hypodensities in white matter of posterior parietal and occipital lobes (arrows).

reversibility of condition. Acute PRES may present as severe headache, nausea, vomiting, altered mental status, seizures, stupor, and visual loss or disturbance.<sup>9</sup> The relative complexity and lack of specificity often make diagnosis difficult based on clinical symptoms alone.

Despite the widely diverse clinical presentation of PRES, its appearance on neuroimaging is better understood. On T2-weighted MRI brain, PRES can be seen as bilateral hyperintensities predominantly in the white matter of the posterior cerebral hemispheres although asymmetrical and partial image expressions are common. On diffusion-weighted imaging modalities, such as T1-weighted MRI brain, PRES is seen as hypointensities or isointensities localized in the same regions.<sup>10</sup> Affected regions are hypoattenuating on CT head. Because findings on CT are inconsistent, MRI has become the favored, if not essential, imaging modality for the diagnosis of PRES.<sup>11</sup>

Edema is predominantly present in focal regions of the posterior circulation territories, although anterior circulation structures of the brain are also involved: parietal or occipital regions (98%), frontal lobes (68%), inferior temporal lobes (40%), and cerebellar hemispheres (30%).<sup>12</sup> In the cerebellar hemispheres, three main patterns, and partial or asymmetric expression of these patterns, have been noted: holo-hemispheric watershed (23%); superior frontal sulcus (27%); and dominant parietal-occipital (22%). Presence of lesions in the basal ganglia, brain stem, and deep white matter



**Image 2.** Magnetic resonance imaging brain obtained on postoperative day eight demonstrating T2-weighted hyperintensities (arrows) localized to white matter of bilateral posterior cerebral cortex (bottom) and cerebellum (top).

of the brain, including the splenium, is also indicative of PRES.<sup>13</sup> Findings have suggested that there may be a higher incidence of atypical regions of involvement and uncommon imaging manifestations than previously perceived, making the radiologic presentation of PRES slightly more variable.<sup>6</sup>

The cause of acute PRES is not completely understood, and explanations of the mechanism leading to brain edema have been controversial. Controversy involves the role of hypertension and whether the edema is cytotoxic or vasogenic

in origin, resulting from hyperperfusion or hypoperfusion. While most cases (70%) have been associated with systemic hypertension, or, more accurately, a rapid rise in blood pressure, a significant portion of patients have documented normal or mildly elevated blood pressures.<sup>14</sup> Diffusion-weighted MRI of patients with hypertensive PRES suggests that the condition is attributable to hyperperfusion leading to disruption of the blood-brain barrier and resultant vasogenic edema, not ischemia nor infarction.<sup>11</sup> This theory suggests that the lesions seen in PRES are caused by abnormal autoregulatory functions, which control blood flow in the context of rapid increases in systemic blood pressure. Failure in this mechanism leads to a breakdown of endothelial cells in the cerebral vasculature, and the increased permeability leads to interstitial and vasogenic edema and increased intracranial pressure.<sup>2</sup>

Left untreated, vasogenic edema will progress to cytotoxic edema, ischemia, and infarction of brain tissues. Management strategies should be initiated early and focused on treating the underlying cause while eliminating exacerbating factors. Supportive care and symptom management are paramount. Hydration, electrolyte correction, airway monitoring and protection, and ventilatory support should be considered, especially if the patient is altered, obtunded, or suffering from status epilepticus.<sup>15</sup> If hypertension is believed to be the main cause, antihypertensives should be administered and blood pressure must be continually monitored.

When cytotoxicity is suspected, the dosage of the offending agent should be lowered, and medication may need to be withdrawn completely. In the case of pre-eclampsia and eclampsia, emergent delivery of the fetus is recommended. Pro-inflammatory states such as sepsis should be managed with antibiotics, hemodynamic management, and corticosteroids. There are currently no clinical trials assessing the efficacy and safety of hyperosmolar therapies in PRES.

## CONCLUSION

We have presented the case of an adult female suffering from septic shock secondary to complicated diverticulitis who developed posterior reversible encephalopathy syndrome. This case highlights the need to recognize the nonspecific neurologic symptoms associated with PRES and encourages emergency physicians to consider the diagnosis when approaching the differential of altered mental status. It is important to note that hypertension need not be present, as a subset of patients with PRES may be normotensive or hypotensive. Sepsis and septic shock are very common presentations in the ED setting, and encephalopathy must be considered a sign of end organ dysfunction.

It is plausible that acute PRES in septic shock patients exhibiting signs of encephalopathy is underdiagnosed due to a lack of clinical suspicion and unawareness of the disease process. For patients with prolonged or otherwise unexplained alteration in mental status, awareness and rapid ordering of appropriate neuroimaging will allow for confirmation of

characteristic radiologic findings and prevent misdiagnosis, unnecessary testing, and delays in treatment. Reversible with appropriate treatment, PRES requires early recognition; diagnosis is crucial to prevent the complicating factors associated with prolonged PRES, specifically cytotoxic edema, brain ischemia and infarction, and death.

The authors attest that their institution requires neither Institutional Review Board approval, nor patient consent for publication of this case report. Documentation on file.

*Address for Correspondence:* Eric Boccio, MD, UMass Chan Medical School – Baystate, Department of Emergency Medicine, 759 Chestnut Street, Springfield, MA 01199. Email: Eric.Boccio@baystatehealth.org.

*Conflicts of Interest:* By the CPC-EM article submission agreement, all authors are required to disclose all affiliations, funding sources and financial or management relationships that could be perceived as potential sources of bias. The authors disclosed none.

*Copyright:* © 2023 Boccio et al. This is an open access article distributed in accordance with the terms of the Creative Commons Attribution (CC BY 4.0) License. See: <http://creativecommons.org/licenses/by/4.0/>

## REFERENCES

- Hobson EV, Craven I, Blank SC. Posterior reversible encephalopathy syndrome: a truly treatable neurologic illness. *Perit Dial Int.* 2012;32(6):590-4.
- Bartynski WS, Boardman JF, Zeigler ZR, et al. Posterior reversible encephalopathy syndrome in infection, sepsis, and shock. *AJNR Am J Neuroradiol.* 2006;27(10):2179-90.
- Naqi R, Ahsan H, Azeemuddin M. Posterior reversible encephalopathy syndrome: a case series in patients with Eclampsia. *J Pak Med Assoc.* 2012;60(5):394-7.
- Hinchey J, Chaves C, Appignani B, et al. A reversible posterior leukoencephalopathy syndrome. *N Engl J Med.* 1996;334(8):494-500.
- Wright KL, Polito MH, French AE. Posterior reversible encephalopathy syndrome: a case study. *Am J Nurs.* 2012;112(5):36-40.
- McKinney AM, Short J, Truwit CL, et al. Posterior reversible encephalopathy syndrome: incidence of atypical regions of involvement and imaging findings. *AJR Am J Roentgenol.* 2007;189(4):904-12.
- Yi JH, Ha SH, Kim YK, et al. Posterior reversible encephalopathy syndrome in an untreated hypertensive patient after spinal surgery under general anesthesia: a case report. *Korean J Anesthesiol.* 201;60(5):369-72.
- Riaz N, Behnia MM, Catalano PW, et al. A patient with moderate post-operative hypertension presenting with posterior reversible encephalopathy syndrome: a case report. *Tanaffos.* 2013;12(3):58-61.

9. Rajasekhar A and George TJ. Gemcitabine-induced reversible posterior leukoencephalopathy syndrome: a case report and review of the literature. *Oncologist*. 2007;12(11):1332-5.
10. Lamy C, Oppenheim C, Meder JF, et al. Neuroimaging in posterior reversible encephalopathy syndrome. *J Neuroimaging*. 2004;14(2):89-96.
11. Pedraza R, Marik PE, Varon J. Posterior reversible encephalopathy syndrome: a review. *Crit Care & Shock*. 2009;12:135-43.
12. Covarrubias DJ, Luetmer PH, Campeau NG. Posterior reversible encephalopathy syndrome: prognostic utility of quantitative diffusion-weighted MR images. *AJNR Am J Neuroradiol*. 2002;23(6):1038-48.
13. Bartynski WS and Boardman JF. Distinct imaging patterns and lesion distribution in posterior reversible encephalopathy syndrome. *AJNR Am J Neuroradiol*. 2007;28(7):1320-7.
14. Fugate JE, Claassen DO, Cloft HJ, et al. Posterior reversible encephalopathy syndrome: associated clinical and radiologic findings. *Mayo Clin Proc*. 2010;85(5):427-32.
15. Choe S, Ganta N, Alnabwani D, et al. A case report of severe posterior reversible encephalopathy syndrome due to accelerated hypertension in a young patient. *Cureus*. 2022;14(7):e26918.

# Acute Epiglottitis Secondary to the Severe Acute Respiratory Syndrome Coronavirus 2: A Case Report

Melissa Gunchenko, MD\*  
 Mohammad Abboud, MD\*  
 Zachary W. Risler, MD†  
 Ryan C. Gibbons, MD\*

\*Lewis Katz School of Medicine at Temple University, Department of Emergency Medicine- Philadelphia, Pennsylvania  
 †Nazareth Hospital, Department of Emergency Medicine, Philadelphia, Pennsylvania

Section Editor: Anna McFarlin, MD

Submission history: Submitted December 31, 2022; Revision received May 10, 2023; Accepted May 19, 2023

Electronically published August 1, 2023

Full text available through open access at [http://escholarship.org/uc/uciem\\_cpccem](http://escholarship.org/uc/uciem_cpccem)

DOI: 10.5811/cpcem.1581

**Introduction:** Acute epiglottitis is a rapidly progressive, potentially life-threatening infection causing inflammation of the epiglottis and adjacent supraglottic structures.<sup>1-2</sup> Since the introduction of the *Haemophilus influenzae* vaccine, the incidence of pediatric cases has decreased dramatically while adult instances have increased.<sup>1-4</sup> Likewise, the etiology has changed considerably with the increasing prevalence of other causative bacterial and viral pathogens.<sup>1-4</sup>

**Case Report:** We present a novel case of acute epiglottitis secondary to infection with the severe acute respiratory syndrome coronavirus 2. This case report highlights the changing landscape of epiglottitis and the importance of airway assessment.

**Conclusion:** Present-day epiglottitis differs greatly from our traditional understanding. Numerous etiologies beyond *Haemophilus influenzae* now afflict adults predominately. As a clinically significant, novel complication of coronavirus disease 2019, acute epiglottitis is a life-threatening airway emergency. Emergency physicians must maintain a high index of suspicion, especially given the evolving clinical landscape. Early airway assessment with nasopharyngolaryngoscopic is critical. [Clin Pract Cases Emerg Med. 2023;7(3):158–160.]

**Keywords:** *airway emergencies; epiglottitis; coronavirus disease 2019; case report.*

## INTRODUCTION

Acute epiglottitis is a rapidly progressive, potentially life-threatening infection causing inflammation of the epiglottis and adjacent supraglottic structures.<sup>1-2</sup> Since the introduction of the *Haemophilus influenzae* type b (HiB) vaccine, the incidence of pediatric cases has decreased dramatically while adult instances have increased.<sup>1-4</sup> Likewise, the etiology has changed considerably with the increasing prevalence of other causative bacterial and viral pathogens.<sup>1-4</sup>

The novel viral illness coronavirus 2019 (COVID-19), caused by the severe acute respiratory syndrome coronavirus 2, has become a global pandemic infecting over 676 million people worldwide since December 2019.<sup>5</sup> While extensive pulmonary disease is a known sequela of COVID-19 infection, extrapulmonary manifestations have been observed as well, including coagulopathies and cardiovascular

complications.<sup>6-8</sup> This is only the second case report in the emergency medicine (EM) literature of COVID-19 epiglottitis, a novel complication with particular relevance to EM practice.<sup>9-12</sup> Furthermore, it highlights the importance of emergency physician airway assessment and management.

## CASE REPORT

A 25-year-old male presented to an outside emergency department (ED) with gradual onset flu-like symptoms, odynophagia, and shortness of breath over the preceding three to four days. Initial physical examination revealed no uvular swelling, oropharyngeal exudate, stridor, wheezing, or respiratory distress. Inflammatory markers were notable for a leukocytosis of 21.5 thousand per cubic millimeter (K/mm<sup>3</sup>) (reference range 4-11 K/mm<sup>3</sup>) and an elevated C-reactive protein of 11.8 milligrams per deciliter (mg/dL)



(0.0-0.4mg/dL). The initial treating clinician suspected a deep space neck infection and ordered computed topography (CT) imaging of the neck, which demonstrated edematous thickening of the epiglottis and mucosal hyperemia consistent with acute epiglottitis. Given a reported penicillin allergy, the patient received intravenous (IV) clindamycin (600 mg) and was transferred to our academic institution for otolaryngology evaluation.

On arrival, the patient was tachycardic but otherwise hemodynamically stable. Examination was notable only for a muffled voice. The emergency physician (EP) performed an immediate bedside nasopharyngolaryngoscopic (NPL) examination. Given the concern for imminent airway compromise, the EP preloaded a 6-0 endotracheal tube onto the scope. The NPL demonstrated severe swelling of the epiglottis and arytenoids with near complete upper airway obstruction (Video 1). The EP performed an immediate awake intubation using ketamine (2mg/kilogram [kg] IV). Following intubation, the patient received dexamethasone (10 mg IV), vancomycin (20 mg/kg IV), and ceftriaxone (2 grams IV) and was admitted to the intensive care unit. Prior to administering ceftriaxone, the EP confirmed a remote history of a questionable rash to penicillin. Therefore, the EP deemed the cephalosporin safe and appropriate.

The following lab tests were negative: HIV types 1 and 2 antibody and p24 antigen; hepatitis B viral surface antigen; hepatitis C viral antibody and ribonucleic acid; streptococcus rapid screen; monoscreen; blood, throat, and sputum cultures; and rapid influenza type A and B antigens. A respiratory pathogen panel was negative for other viruses. A nasopharyngeal reverse-transcription polymerase chain reaction swab (Luminex Corporation, Austin, TX) was positive for COVID-19.

The patient improved clinically and was extubated on hospital day five. The inpatient team discontinued the steroid and antibiotics and discharged the patient home on hospital day seven without complications.

## DISCUSSION

Prior to the advent of the HiB vaccination, traditional doctrine considered epiglottitis a predominately pediatric diagnosis. However, acute epiglottitis is now two to eight times more common in adults.<sup>2</sup> Currently *Streptococcus pneumoniae* and *Staphylococcus aureus* are the most frequent causative agents, typically secondary to direct inoculation or bacteremia.<sup>1-3,14,15</sup> Other less common etiologies include fungal and viral organisms, granulomatous and lymphoproliferative conditions, traumatic and thermal injuries, and toxic ingestions.<sup>1-3,14</sup>

Adult epiglottitis presents a diagnostic challenge. Given the anatomic airway dissimilarities, children typically present in respiratory distress with drooling and in a tripod position, whereas adults demonstrate less severe atypical signs and symptoms<sup>1-2</sup> with sore throat, odynophagia, and

### *CPC-EM Capsule*

What do we already know about this clinical entity?

*Airway compromise is a known complication of epiglottitis and is associated with a higher morbidity and mortality.*

What makes this presentation of disease reportable?

*Epiglottitis secondary to coronavirus disease 2019 is an emerging complication of which emergency physicians (EPs) need to be aware.*

What is the major learning point?

*Since the advent of the Haemophilus influenzae type b vaccine, the clinical presentation of epiglottitis has changed. Adults are more frequently affected and often have atypical presentations.*

How might this improve emergency medicine practice?

*Increased awareness of the changing clinical landscape of epiglottitis will facilitate EPs recognition of this clinical entity.*

dysphagia being the most common.<sup>1-4,13-15</sup> Stridor, drooling, and voice changes are present in fewer than 60% of cases.<sup>1-4,13-15</sup> Furthermore, adults have a more indolent course compared to the acute decompensation common among the pediatric population.<sup>2,14</sup> Our patient presented similarly. Physical examination and plain films lack adequate sensitivity.<sup>1-3,12</sup> In fact, lateral neck films have a false negative rate over 30%, and the classic “thumbprint sign” is present in less than 80% of cases.<sup>1,3,14,16</sup> While computed tomography with intravenous contrast of the neck has sensitivities between 88-100%, patients may be too unstable for transport.<sup>3,13,16,17</sup> Nasopharyngeal laryngoscopy has a sensitivity of 100% and facilitates assessment of disease severity as well.<sup>3,13,14,18</sup>

Using the National Emergency Departments Sample database, Hanna et al retrospectively reviewed over 33,000 cases of adult epiglottitis from 2007-2014 and found that less than 1% of patients had a laryngoscopic assessment or airway intervention in the ED, highlighting the lack of recognition of this condition.<sup>19</sup> Nonetheless, practice patterns vary. A more recent, single-center retrospective study determined that 55% of patients had an airway assessment in the ED.<sup>13</sup> However,

only three cases had an EP perform the evaluation.<sup>13</sup> Nasopharyngolaryngoscopy is often unavailable, or training is limited in the ED. In such instances, EPs must involve otolaryngology or anesthesiology early in the assessment of suspected epiglottitis. Study results have varied, with findings that indicate 8-50% of patients will require intubation with 10-33% requiring surgical intervention.<sup>3,4,14,15,18</sup> In the aforementioned single-center study, 17% of patients needed an advanced airway, 25% of which were surgical.<sup>13</sup>

Anticipating an advanced airway is challenging. Numerous studies have attempted to determine risk factors associated with airway interventions. Immunocompromised patients and those with diabetes, as well as patients presenting with hypoxia, stridor, voice changes, and airway edema, typically require emergent airway management.<sup>3,14,15,18,20</sup> Mortality ranges between 1-20%, but upper airway obstruction is associated with a five-fold increase in mortality.<sup>1,3,4,13-15,19-20</sup> Therefore, anticipating an airway emergency is critical in suspected cases of epiglottitis.

## CONCLUSION

Present-day epiglottitis differs greatly from our traditional understanding. Numerous etiologies beyond *H. influenzae* now afflict adults predominately. As a clinically significant, novel complication of COVID-19, acute epiglottitis is a life-threatening airway emergency. Emergency physicians must maintain a high index of suspicion, especially with the changing clinical landscape. Early airway assessment is critical in suspected cases.

**Video 1.** Nasopharyngolaryngoscopic video of edematous epiglottitis and arytenoids obscuring visualization of airway.

The authors attest that their institution requires neither Institutional Review Board approval, nor patient consent for publication of this case report. Documentation on file.

**Address for Correspondence:** Ryan C. Gibbons, MD, FAAEM, FACEP, FAIUM, Lewis Katz School of Medicine at Temple University, Department of Emergency Medicine, 1017 Jones Hall, 1316 West Ontario St, Philadelphia, PA 19140. Email: ryan.gibbons@tuhs.temple.edu.

**Conflicts of Interest:** By the CPC-EM article submission agreement, all authors are required to disclose all affiliations, funding sources and financial or management relationships that could be perceived as potential sources of bias. The authors disclosed none.

**Copyright:** © 2023 Gunchenko et al. This is an open access article distributed in accordance with the terms of the Creative Commons Attribution (CC BY 4.0) License. See: <http://creativecommons.org/licenses/by/4.0/>

## REFERENCES

1. Abdallah C. Acute epiglottitis: Trends, diagnosis and management. *Saudi J Anes.* 2012;6(3):279-81.
2. Bridwell RE, Koyfman A, Long B. High risk and low prevalence diseases: adult epiglottitis. *Am J Emerg Med.* 2022;57:14-20.
3. Baird SM, Marsh PA, Padiglione A, et al. Review of epiglottitis in the post Haemophilus influenzae type-b vaccine era. *ANZ J Surg.* 2018;88(11):1135-40.
4. Guldred LA, Lyhne D, Becker BC. Acute epiglottitis: epidemiology, clinical presentation, management and outcome. *J Laryngo & Otol.* 2008;122(8):818-23.
5. Johns Hopkins University of Medicine. Coronavirus Research Center. COVID-19 Dashboard by the Center for Systems Science and Engineering (CSSE) at Johns Hopkins University (JHU). Available at <https://coronavirus.jhu.edu/map.html>. Accessed April 26, 2023.
6. Gupta A, Madhavan MV, Sehgal, K. et al. Extrapulmonary manifestations of COVID-19. *Nat Med.* 2020;26:1017-32.
7. Iba T, Levy JH, Connors JM, et al. The unique characteristics of COVID-19 coagulopathy. *Crit Care.* 2020;24(1):1-8.
8. South AM, Diz DI, Chappell MC. COVID-19, ACE2, and the cardiovascular consequences. *Am J Physiol Heart Circ Physiol.* 2020;318:H1084-90.
9. Smith C, Mobarakai O, Sahra S, et al. Case report: epiglottitis in the setting of COVID-19. *IDCases.* 2021;24:e01116.
10. Fondaw A, Arshad M, Batool S, et al. COVID-19 infection presenting with acute epiglottitis. *J Surg Case Rep.* 2020;2020(9):rjaa280.
11. Emberey J, Velala SS, Marshall B, et al. Acute Epiglottitis Due to COVID-19 Infection. *Eur J Case Rep Intern Med.* 2021;8(3):002280.
12. Cordial P, Le T, Neuenschwander J. Acute epiglottitis in a COVID-19 positive patient. *Am J Emerg Med.* 2022;51:427.e1-427.e2.
13. Felton P, Lutfy-Clayton L, Smith LG, Visintainer P, Rathlev NK. A retrospective cohort study of acute epiglottitis in adults. *West J Emerg Med.* 2021;22(6):1326-34.
14. Cheung CS, Man SY, Graham CA, et al. Adult epiglottitis: a 6-year experience in a university teaching hospital in Hong Kong. *Eur J Emerg Med.* 2009;16(4):221-6.
15. Sideris A, Holmes T, Cumming B, et al. Systematic review and meta-analysis of predictors of airway intervention in adult epiglottitis. *Laryngoscope.* 2020;130:465-73.
16. Lee SH, Yun SJ, Kim DH, et al. Do we need a change in ED diagnostic strategy for adult acute epiglottitis? *Am J Emerg Med.* 2017;35(10):1519-24.
17. Ramalanjaona G and Shpak M. Challenges in diagnosing adult epiglottitis: limitations of CT scan. *Emerg Med - Open J.* 2015;1(1):1-4.
18. Katori H and Tsukuda M. Acute epiglottitis: analysis of factors associated with airway intervention. *J Laryngo & Otol.* 2005;119:967-72.
19. Hanna J, Brauer PR, Berson E, et al. Adult epiglottitis: trends and predictors of mortality in over 30 thousand cases from 2007 to 2014. *Laryngoscope.* 2019;129:1107-12.
20. Allen M, Meraj TS, Oska S, et al. Acute epiglottitis: analysis of US mortality trends from 1979 to 2017. *Am J Otolaryng.* 2021;42(2):102882.

# Acute Focal Bacterial Nephritis in a Patient with Solitary Kidney: Case Report

Adnane Guella, MD\*

Rabab Zaka Muhammad, MD\*

Mahdi Aljallabi, MD†

Abeer Mursi, MD†

Mohamed Elmahi, MD\*

\*University Hospital, Department of Internal Medicine, Sharjah, United Arab Emirates

†University Hospital, Department of Emergency Medicine, Sharjah, United Arab Emirates

Section Editor: Rachel Lindor, MD, JD

Submission history: Submitted January 23, 2023; Revision received May 10, 2023; Accepted May 11, 2023

Electronically published July 18, 2023

Full text available through open access at [http://escholarship.org/uc/uciem\\_cpccem](http://escholarship.org/uc/uciem_cpccem)

DOI: 10.5811/cpcem.1545

**Introduction:** Acute focal bacterial nephritis is an underdiagnosed condition. It clinically resembles acute pyelonephritis. If unrecognized and undertreated, it may progress into complications (kidney abscess and scars). Contrast-enhanced computed tomography (CT) reveals specific images of the disease and is considered the gold standard to make the diagnosis.

**Case Report:** A 63-year-old male patient with solitary kidney presented with symptoms compatible with acute pyelonephritis. Kidney ultrasound was not conclusive. Because of persisting high-grade fever not resolving after 48 hours of antibiotics, a contrast-enhanced CT was then performed, and the diagnosis of acute focal bacterial nephritis was made. A repeat CT after three weeks of intravenous (IV) antibiotics showed marked improvement of the intrarenal lesions, and a fourth week of IV antibiotics was dispensed.

**Conclusion:** Diagnosing acute focal bacterial nephritis is important (particularly in a patient with solitary kidney). This will dictate the therapy duration. Unlike acute pyelonephritis, acute focal bacterial nephritis requires at least three weeks duration of antibiotics to avoid progress into further complications. [Clin Pract Cases Emerg Med. 2023;7(3):161–164.]

**Keywords:** *acute focal bacterial nephritis; acute lobar nephronia; case report.*

## INTRODUCTION

Acute focal bacterial nephritis (AFBN) was first described by Rosenberg et al. in 1979.<sup>1</sup> It is defined as focal areas of non-liquefactive necrosis in the renal cortex that can involve one (focal) or more lobes (multifocal).<sup>2,3</sup> Acute focal bacterial nephritis is considered to be a complicated form of acute pyelonephritis (APN) and lies on the spectrum between APN and renal abscess. It remains underdiagnosed in both adults and children. The main reason for underdiagnosis is the clinical similarity between APN and AFBN, and failure to order imaging. Contrast-enhanced computed tomography (CT) provides the most sensitive and specific images of AFBN, i.e., poorly enhancing, wedge-shaped lesion in the kidney. Ultrasonography can be helpful if nephromegaly or a focal

mass are detected. Acute focal bacterial nephritis usually affects one kidney and, rarely, both kidneys. We report here a case in which AFBN is described in a patient with solitary kidney successfully managed by a long course of antibiotics.

## CASE REPORT

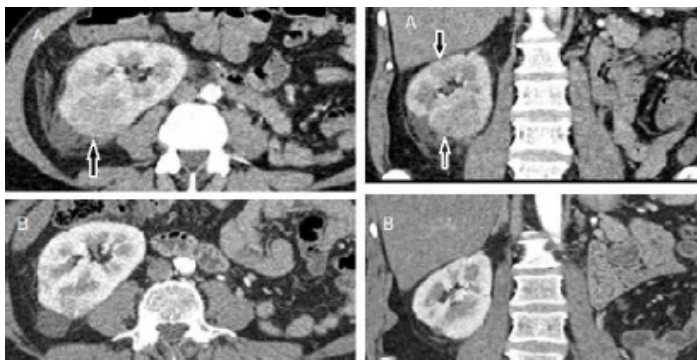
A 63-year-old male diabetic patient presented to the emergency department (ED) on two consecutive episodes. In the first presentation, he reported chills and dysuria for a few days but was not febrile. He reported slight right flank pain. He had been seen in a private clinic a few days before this presentation. At that time, he was febrile and received antibiotics. The most important element in his medical history was a left nephrectomy done in 2007 following a complicated

course of kidney stone and infection. Therefore, he was classified as a mild case of APN and was discharged home on oral antibiotics for seven days.

Three days later, he again presented to the ED. This time, he had high-grade fever (40.1° Celsius) and severe right flank pain. There was no frank hematuria, nausea, or vomiting. On examination he had severe tenderness of the right costovertebral angle. His laboratory results showed leukocytosis (20,000/microliter ( $\mu\text{L}$ ) (reference range: 4,000-10,000/ $\mu\text{L}$ ) with markedly elevated C-reactive protein (196 milligrams (mg)/L [ $<10$  mg/L]) and procalcitonin (6 nanograms (ng)/mL [ $\leq 0.15$  ng/mL]). Kidney ultrasound confirmed the left nephrectomy with compensatory hypertrophic right kidney and no gross abnormalities apart from a rim of perinephric fluid. The urinary bladder was well distended with normal wall thickness. There was no evidence of mass, sludge, or stone. The prostate was of normal volume.

Blood and urine cultures were taken in the ED, and the patient was admitted as a case of APN and started empirically on meropenem at a dose of 1 gram three times daily as his kidney function was normal (creatinine was 105 micromoles [ $\mu\text{mol}$ ]/L; reference range: 62-115  $\mu\text{mol}/\text{L}$ ). After 48 hours of antibiotics, the patient remained febrile with no improvement of the costovertebral tenderness. At this time, we received the results of the urine and blood cultures, which revealed an extended spectrum beta-lactamase (ESBL) *Escherichia coli* sensitive to meropenem. All these elements prompted a request for contrast-enhanced CT, which showed right renal ill-defined cortical hypodense areas with poor enhancement compatible with the diagnosis of multifocal bacterial nephritis (Image).

The patient's condition improved after another 48 hours of meropenem. We then discharged him on ertapenem since its once daily administration is more convenient for outpatient treatment than the three daily doses of meropenem. A repeat contrast-enhanced CT after a three-week course of antibiotics revealed a remarkable improvement of the kidney lesions



**Image.** Contrast-enhanced computed tomography showing in “A” a wedge-shaped lesion with decreased enhancement (arrows), and in “B” marked improvement after three weeks of antibiotics.

### CPC-EM Capsule

What do we already know about this clinical entity?

*Acute focal bacterial nephritis (AFBN) is underdiagnosed in adults as it resembles clinically acute pyelonephritis (APN).*

What makes this presentation of disease reportable?

We report a case of AFBN in a solitary kidney that if not diagnosed would have exposed the patient to serious complications

What is the major learning point?

*Diagnosing AFBN is easily made by contrast-enhanced computed tomography. A minimum three-week course of antibiotics is needed to clear the renal lesions.*

How might this improve emergency medicine practice?

*This case may help raise awareness and lower the threshold of suspicion for AFBN, particularly since APN is a common presentation in the emergency department.*

(Image). We decided to prescribe an additional week of ertapenem considering his severe condition and solitary kidney. After that, the patient was followed up monthly in the outpatient clinic and remained completely asymptomatic after six months of follow-up with normal kidney function.

### DISCUSSION

Most cases of acute pyelonephritis are first seen in the ED. As AFBN shares with APN similar clinical presentation, it is seldom considered. Therefore, the patients do not proceed for imaging and are typically treated as outpatients for a short duration. Imaging is ordered only when nonspecific symptoms dominate the presentation, including nausea, severe vomiting, and abdominal guarding, mimicking other clinical conditions.<sup>4,5</sup> Therefore, the diagnosis of AFBN may be delayed or even not considered. This is clearly shown in the study of Campos-Franco et al. The same expert radiologist retrospectively reviewed the images of 377 patients admitted at one hospital with APN over a five-year period. The diagnosis of AFBN was missed in 57 cases (prevalence of 15.1%) based on the ultrasound findings of renal focal mass(es) of decreased or, less frequently, increased echogenicity and decreased vascularity on Doppler or when contrast-enhanced CT revealed one or multiple wedge-shaped areas of decreased kidney density.<sup>6</sup>



Kidney ultrasound is the imaging of choice in children for its non-invasive nature, lack of radiation, and ability to detect congenital urological abnormalities. However, nephromegaly or the presence of an ill-defined focal mass may be missing. Saito et al reviewed AFBN cases in children seen in their facility from 2008-2011. They found that seven of 11 children had false negative renal ultrasound. The diagnosis of AFBN was made after contrast-enhanced CT, and the authors deemed CT to be indispensable for the diagnosis.<sup>7</sup> In adults as well, ultrasonic anomalies may be lacking while contrast-enhanced CT findings are characteristic.<sup>8</sup>

In a recent systematic review reporting data from 138 cases, kidney ultrasound was performed in addition to CT and/or magnetic resonance imaging (MRI) in 41% and had a sensitivity of 91%. The diagnosis was confirmed solely by ultrasound in 20% of the cases, and 52% had their diagnosis confirmed by contrast-enhanced CT and/or MRI.<sup>5</sup> Jiao et al. in their retrospective analysis of the data of 238 adult patients diagnosed with AFBN by contrast-enhanced CT, ultrasound identified nephromegaly in only 52 patients (21.85%) and a hypoechoic focal mass in two patients (0.84%), indicating that the sensitivity of ultrasound for AFBN diagnosis was probably not satisfactory.<sup>9</sup> In our case, which to our knowledge is the first report of AFBN in a patient with solitary kidney, ultrasound did not show any focal mass, and the diagnosis was made by contrast-enhanced CT.

Our case highlights some aspects that should trigger the ordering of a contrast-enhanced CT, which is the gold standard for diagnosing AFBN. Many authors have tried to find potential markers or symptoms that would orient toward AFBN. Among these symptoms, fever present in 98% of the cases was found to be of higher grade (above 39° Celsius) and to persist for a longer period in AFBN than in APN.<sup>6,9</sup> In our patient, fever was not present during the first presentation, which made AFBN an unlikely diagnosis. However, the patient had fever prior to this presentation when he visited a private clinic, and he received antibiotics for a few days. This may explain the absence of fever and the confusion in reaching a proper diagnosis. Symptoms during the second presentation were more serious and prompted further investigations.

In the management of AFBN, the duration of antibiotics therapy is important to consider. A treatment period for two weeks or less, as in APN, would be insufficient and may lead to further complications, particularly abscess formation and fibrosis.<sup>10,11</sup> In pediatrics, it was clearly shown that a minimum of three weeks is mandatory for successful treatment of AFBN.<sup>12,13</sup> Cheng et al observed 17% treatment failure with two weeks therapy duration vs 0% treatment failure with three weeks of antibiotic therapy.<sup>13</sup> In adults, the optimal treatment period is not known, but in general the three- to four-week duration as in pediatrics is followed.<sup>9</sup> We documented by CT the clearance of the focal lesions in the kidney after at least a three-week period of therapy.<sup>14</sup> In our current case with

solitary kidney, important multifocal lesions, and positive culture of ESBL *E. coli*, we opted for a longer treatment period with intravenous ertapenem for four weeks. We believe that this case should alert emergency physicians to have a lower threshold for AFBN suspicion, as the diagnosis of AFBN indicates the need for a longer duration of antibiotics.

## CONCLUSION

This case illustrates the usefulness of contrast-enhanced CT in diagnosing acute focal bacterial nephritis, particularly in patients with solitary kidney. Indeed, a longer treatment duration than in acute pyelonephritis should be considered to avoid further complications. Our observation confirms the recommendation that at least three weeks of antibiotics are required to clear the intrarenal infection process.

The authors attest that their institution requires neither Institutional Review Board approval, nor patient consent for publication of this case report. Documentation on file.

---

*Address for Correspondence:* Adnane Guella, MD, University Hospital, Sharjah, United Arab Emirates. Department of Nephrology, University City, PO Box 72772. Email: guella@gmail.com.

*Conflicts of Interest:* By the CPC-EM article submission agreement, all authors are required to disclose all affiliations, funding sources and financial or management relationships that could be perceived as potential sources of bias. The authors disclosed none.

*Copyright:* © 2023 Guella et al. This is an open access article distributed in accordance with the terms of the Creative Commons Attribution (CC BY 4.0) License. See: <http://creativecommons.org/licenses/by/4.0/>

---

## REFERENCES

1. Rosenfield AT, Glickman MG, Taylor KJW, et al. Acute focal bacterial nephritis (acute lobar nephronia). *Radiology*. 1979;132(3):553-61.
2. Cheng CH, Tsau YK, Lin TY. Is Acute lobar nephronia the midpoint in the spectrum of upper urinary tract infections between acute pyelonephritis and renal abscess? *J Pediatr*. 2010;156(1):82-6.
3. Zaontz MR, Pahira JJ, Wolfman M, et al. Acute focal bacterial nephritis: a systematic approach to diagnosis and treatment. *J Urol*. 1985;133(5):752-7.
4. Conley SP and Frumkin K. Acute lobar nephronia: a case report and literature review. *J Emerg Med*. 2014;46(5):624-6.
5. Sieger N, Kyriazis I, Schaudinn A, et al. Acute focal bacterial nephritis is associated with invasive diagnostic procedures - a cohort of 138 cases extracted through a systematic review. *BMC Infect Dis*. 2017;17(1):240.
6. Campos-Franco J, Macia C, Huelga E, et al. Acute focal bacterial nephritis in a cohort of hospitalized adult patients with acute pyelonephritis. Assessment of risk factors and a predictive model.

- Eur J Intern Med.* 2017;39:69-74.
7. Saito K, Fuchigami T, Hasegawa M, et al. Clinical features of acute focal bacterial nephritis in children. *Int J Clin Pediatr.* 2013;2(2):68-73.
  9. Jiao S, Yan Z, Zhang C, et al. Clinical features of acute focal bacterial nephritis in adults. *Sci Rep.* 2022;12(1):7292.
  10. Shimizu M, Katayama K, Kato E, et al. Evolution of acute focal bacterial nephritis into a renal abscess. *Pediatr Nephrol.* 2004;20(1):93-5.
  11. Cheng CH, Tsau YK, Chang CJ, et al. Acute lobar nephronia is associated with a high incidence of renal scarring in childhood urinary tract infections. *Pediatr Infect Dis J.* 2010;29(7):624-8.
  12. Cheng CH, Tsau YK, Chen SY, et al. Clinical courses of children with acute lobar nephronia correlated with computed tomographic patterns. *Pediatr Infect Dis J.* 2009;28(4):300-303.
  13. Cheng CH, Tsau YK, Lin TY. Effective duration of antimicrobial therapy for the treatment of acute lobar nephronia. *Pediatrics.* 2006;117(1):e84-9.
  14. Guella A, Khan A, Jarrah D. Acute focal bacterial nephritis: two cases and review of the literature. *Can J Kidney Health Dis.* 2019;6:205435811988431.

# A Case Report of Nitrous Oxide-induced Myelopathy: An Unusual Cause of Weakness in an Emergency Department

Madeleine S. Birch, MD  
Emmelyn J. Samones, BS  
Tammy Phan, BS  
Mindi Guptill, MD

Loma Linda University Medical Center, Department of Emergency Medicine, Loma Linda, California

Section Editor: Steven Walsh, MD

Submission history: Submitted February 8, 2023; Revision received May 10, 2023; Accepted May 11, 2023

Electronically published July 19, 2023

Full text available through open access at [http://escholarship.org/uc/uciem\\_cpce](http://escholarship.org/uc/uciem_cpce)

DOI: 10.5811/cpcem.1549

**Introduction:** Weakness is a common symptom that within itself does not indicate a specific diagnosis. Recreational inhalant use such as nitrous oxide (NO) may not often be disclosed. Additionally, professional or occupational history, such as being a dentist or dental assistant, should be determined because of higher reported rates of NO misuse.<sup>1</sup> Nitrous oxide can cause vitamin B<sub>12</sub> deficiency and resulting neuropathy. Nitrous oxide toxicity can have a wide variation of presentations with or without laboratory abnormalities or remarkable imaging findings, which can further complicate a diagnosis of weakness secondary to NO use.

**Case Report:** A 33-year-old female presented to the emergency department with progressive bilateral leg numbness and objective weakness after repeated recreational NO use. After an extensive workup, she was found to have vitamin B<sub>12</sub> deficiency and an electromyography study consistent with myeloneuropathy, despite normal imaging. She was prescribed high-dose vitamin B<sub>12</sub> therapy and stopped using NO. One year after diagnosis, our patient maintained NO sobriety and had near-complete resolution of prior neurologic deficits.

**Conclusion:** The use of recreational inhalant and the patient's occupation should be considered when a patient presents with weakness. Obtaining vitamin B<sub>12</sub> and methylmalonic acid levels should be considered for diagnosis. However, NO-induced neuropathy can be seen in patients with normal vitamin B<sub>12</sub> and methylmalonic levels and patients do not always have abnormal imaging findings. The healthcare team should consider the varied presentations and findings of substance-induced conditions such as NO toxicity. [Clin Pract Cases Emerg Med. 2023;7(3):165–167.]

**Keywords:** *Vitamin B<sub>12</sub> neuropathy; nitrous oxide; weakness; case report.*

## INTRODUCTION

Weakness is a common presenting chief complaint of patients seeking care in the emergency department (ED), making up an estimated 10% of annual visits.<sup>2</sup> One under-recognized cause of weakness is recreational use of inhalants. Nitrous oxide (NO) use is increasing, particularly among music festival and club attendees with a prevalence of 38% in 2014.<sup>3</sup> While weakness is a vague complaint with a broad differential, careful history-taking and consideration of substance use and occupational history can assist in the

diagnosis and treatment of underlying neurological pathology. Neurotoxicity from NO is a potentially reversible condition that can be treated with appropriate vitamin B<sub>12</sub> supplementation and abstinence from NO use.

## CASE REPORT

A 33-year-old woman employed as a warehouse associate without significant past medical history presented to the ED with bilateral lower extremity weakness that had been progressive for one month. The patient reported that symptoms

initially began as a “pins and needles” sensation in her feet that slowly progressed to a “heavy” sensation and difficulty walking. She denied recent trauma, illness, or pain and disclosed she regularly huffed 20-30 “balloons” of NO two to three times a month. On physical exam, she had normal vital signs, cranial nerve function, and rectal tone. She had decreased bilateral lower extremity strength with decreased sensation to pinprick, vibration, and pain to the mid-abdomen with full sensation and strength preserved in her upper extremities. In addition, she had a positive Lhermitte’s sign and Romberg test with diminished, 1+ patellar and Achilles reflexes with 2+ brachioradialis, and biceps and triceps reflexes bilaterally. The patient was admitted to the neurology ward.

Laboratory results obtained after admissions were notable for a decreased vitamin B<sub>12</sub> level with an elevated methylmalonic acid level without macrocytosis, normal levels of intrinsic factor without antibodies, and unremarkable cerebrospinal fluid studies with normal inflammatory and infectious markers. Folate and copper levels were also found to be normal. Radiographic findings including contrasted magnetic resonance imaging brain and spine were normal. Electromyography studies did not suggest demyelination; however, they were abnormal and suggestive of myeloneuropathy in the setting of vitamin B<sub>12</sub> deficiency from NO use.

The patient was administered high-dose vitamin B<sub>12</sub> injections (1,000 micrograms daily) with significant clinical improvement. The patient was discharged home on day three of hospitalization with a walker and outpatient physical therapy. At eight-week neurology follow-up, the patient was able to ambulate independently with 5/5 strength in bilateral hip flexors with negative Romberg. The patient had full resolution of symptoms one year after initial onset. She maintained sobriety from NO, and her vitamin B<sub>12</sub> and methylmalonic acid levels have remained normal.

## DISCUSSION

Vitamin B<sub>12</sub> is a fat-soluble enzyme found in animal products. Once absorbed, vitamin B<sub>12</sub> becomes an essential cofactor for enzymes involved in deoxyribonucleic acid, fatty acids, and myelin synthesis; thus, B<sub>12</sub> deficiencies can present with hematological or neurological deficits. Vitamin B<sub>12</sub> is an important cofactor in the conversion of methylmalonyl-CoA to succinyl-CoA (Figure). In patients with vitamin B<sub>12</sub> deficiencies, levels of methylmalonic acid and homocysteine levels accumulate and are thought to damage myelin, resulting in neurologic deficit.<sup>4</sup> Nitrous oxide, also known as “laughing gas,” is an odorless gas that is used recreationally for euphoric effect. Nitrous oxide causes permanent oxidation of vitamin B<sub>12</sub>, rendering it useless as a cofactor for essential enzymatic processes resulting in deficiency, which can present as a myeloneuropathy or subacute combined degeneration of the spinal cord.<sup>5</sup> In a systematic review conducted by Garakani

### CPC-EM Capsule

What do we already know about this clinical entity?  
*Nitrous oxide can cause vitamin B<sub>12</sub> deficiency. vitamin B<sub>12</sub> is an essential enzyme for neuronal health and deficiencies can present with neurological deficits.*

What makes this presentation of disease reportable?  
*The patient presented had vitamin B<sub>12</sub> deficiency and an electromyography study consistent with myeloneuropathy, despite normal imaging.*

What is the major learning point?  
*Neurotoxicity from nitrous oxide use can vary in clinical presentations, laboratory findings and imaging findings. High dose Vitamin B therapy is the treatment.*

How might this improve emergency medicine practice?  
*Recreational inhalant use and occupational exposure should be considered in patients presenting with weakness regardless of normal imaging.*

et al., 72 of 91 patients presented with neurological sequelae, with radiographic findings in 39 of those 72 patients. Vitamin B<sub>12</sub> deficiency was reported in 52 of the 72 patients, and elevated methylmalonic acid and homocysteine levels were reported in several patients.<sup>6</sup>

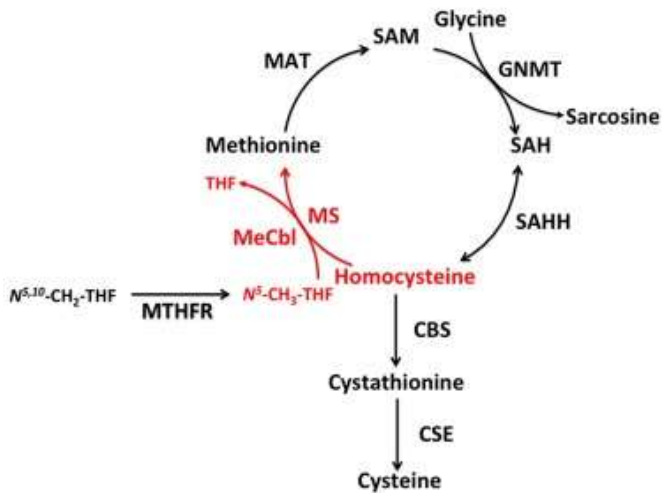
Recent studies report recreational NO use has been increasing, and NO toxicity can have varied presentations and recovery of neurological symptoms.<sup>4,8</sup> When symptomatic, vitamin B<sub>12</sub> levels can be low as in this case; however, neurological symptoms can still occur in patients with normal vitamin B<sub>12</sub> levels.<sup>6</sup> Neurological manifestations can include ataxia, paresthesias, polyneuropathy, subacute combined degeneration, or myelopathy. Patients can also present with psychiatric manifestations such as hallucinations and delirium.<sup>9</sup>

## CONCLUSION

Neurotoxicity from nitrous oxide use can present with a wide variety of clinical presentations, laboratory findings, and imaging findings. While neurological deficits can vary in severity and in recovery, supplemental vitamin B<sub>12</sub> and complete cessation of NO use is the recommended treatment. As previously noted, symptomatic weakness does not lend itself to a specific diagnosis and requires the clinician to maintain a broad differential including atypical causes such as

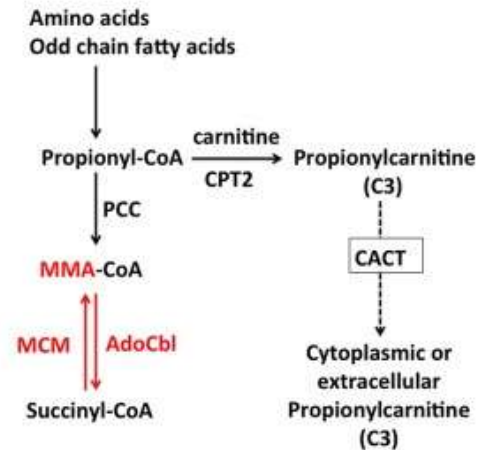


### A Homocysteine metabolism



MAT = methionine adenosyltransferase  
 GNMT = glycine N-methyltransferase  
 SAHH = S-adenosylhomocysteine hydrolase  
 CBS = cystathionine  $\beta$ -synthase  
 MTHFR = methylenetetrahydrofolate reductase  
 PCC = propionyl-CoA carboxylase  
 CPT2 = carnitine palmitoyl transferase II

### B Methylmalonic acid metabolism



MS = methionine synthase  
 MCM = methylmalonyl-CoA mutase  
 MeCbl = methylcobalamin  
 AdoCbl = adenosylcobalamin

**Figure.** Methylmalonic acid and homocysteine metabolism, from Hannibal et al. Biomarkers and algorithms for the diagnosis of Vitamin B12 deficiency. Reproduced with author permission.

nutritional deficiencies, nutritional toxicities, occupational exposure, or inhalational drug use.

The authors attest that their institution requires neither Institutional Review Board approval, nor patient consent for publication of this case report. Documentation on file.

**Address for Correspondence:** Emmelyn J. Samones, BS, Loma Linda, Department of Emergency Medicine, 11234 Anderson St., Room A890A, Loma Linda, CA 92354. Email: esamones@llu.edu.

**Conflicts of Interest:** By the CPC-EM article submission agreement, all authors are required to disclose all affiliations, funding sources and financial or management relationships that could be perceived as potential sources of bias. The authors disclosed none.

**Copyright:** © 2023 Birch et al. This is an open access article distributed in accordance with the terms of the Creative Commons Attribution (CC BY 4.0) License. See: <http://creativecommons.org/licenses/by/4.0/>

## REFERENCES

1. Aston R. Drug abuse. Its relationship to dental practice. *Dent Clin North Am.* 1984;28(3):595-610.
2. Nickel CH, Nemeč M, Bingisser R. Weakness as presenting symptom in the emergency department. *Swiss Med Wkly.* 2009;139(17-18):271-2.
3. Kaar SJ, Ferris J, Waldron J, et al. Up: The rise of nitrous oxide abuse. An international survey of contemporary nitrous oxide use. *J Psychopharmacol.* 2016;30(4):395-401.
4. Ankar A and Kumar A. Vitamin B12 deficiency. 2022. Available from: [https://www.ncbi.nlm.nih.gov/books/NBK441923/?utm\\_medium=email&utm\\_source=transaction](https://www.ncbi.nlm.nih.gov/books/NBK441923/?utm_medium=email&utm_source=transaction). Accessed 25 January 2023.
5. Lin RJ, Chen HF, Chang YC, et al. Subacute combined degeneration caused by nitrous oxide intoxication: case reports. *Acta Neurol Taiwan.* 2011;20(2):129-37.
6. Garakani A, Jaffe RJ, Savla D, et al. Neurologic, psychiatric, and other medical manifestations of nitrous oxide abuse: a systematic review of the case literature. *Am J Addict.* 2016;25(5):358-69.
7. Hannibal L, Lysne V, Bjørke-Monsen AL, et al. Biomarkers and algorithms for the diagnosis of Vitamin B12 deficiency. *Front Mol Biosci.* 2016;3:27. Erratum in: *Front Mol Biosci.* 2017;4:53.
8. Mancke F, Kaklauskaitė G, Kollmer J, et al. Psychiatric comorbidities in a young man with subacute myelopathy induced by abusive nitrous oxide consumption: a case report. *Subst Abuse Rehabil.* 2016;7:155-9.
9. Trowbridge P and Poland C. Missing a case of nitrous oxide toxicity. *Ther Adv Infect Dis.* 2022;9:20499361221104377.

# Retropharyngeal Hematoma Causing Airway Compromise After Tissue Plasminogen Activator Administration: A Case Report

**Christian Provenza, MD\***  
**Arun Christian Habermann†**  
**Theron Williams, MD\***  
**Jeffrey Metter, MD‡**  
**James Richard Walker III, MD\***

\*University of Tennessee Health Science Center - Department of Emergency Medicine, Memphis, Tennessee

†University of Tennessee Health Science Center College of Medicine, Memphis, Tennessee

‡University of Tennessee Health Science Center – Department of Neurology, Memphis, Tennessee

Section Editor: Rachel Lindor, MD, JD

Submission history: Submitted November 14, 2022; Revisions received June 8, 2023; Accepted June 9, 2023

Electronically published August 9, 2023

Full text available through open access at [http://escholarship.org/uc/uciem\\_cpem](http://escholarship.org/uc/uciem_cpem)

DOI: 10.5811/cpcem.1602

**Introduction:** Tissue plasminogen activator (tPA), commonly used for treatment of acute ischemic stroke, is associated with life-threatening bleeding intracranially as well as surrounding the airway.

**Case Report:** A 78-year-old year old male who presented with stroke symptoms and after tPA administration developed a retropharyngeal hematoma requiring intubation and surgical intervention.

**Conclusion:** Numerous threats to the patient's airway can develop after tPA administration. While angioedema is the most common cause, it is important to be prepared for other causes related to hemorrhage. [Clin Pract Cases Emerg Med. 2023;7(3):168–171.]

**Keywords:** *Retropharyngeal hematoma, tissue plasminogen activator, stroke, airway, hemorrhage.*

---

## INTRODUCTION

The risk of hemorrhage after tissue plasminogen activator (tPA) administration in the treatment of acute ischemic stroke is well known, with intracranial hemorrhage the primary concern.<sup>1</sup> Tissue plasminogen activator has also been known to cause airway compromise due to angioedema, occurring in 1.3-5.1% of patients.<sup>2,3</sup> While rare, there have also been reported cases of tPA administration leading to hemorrhage causing airway compromise through lingual hematoma and thyroid hemorrhage.<sup>4,6</sup>

Head trauma within the prior three months and other major trauma within 14 days as contraindications to tPA administration are Class III, level of evidence C and class IIb, level of evidence C recommendations, respectively.<sup>1</sup> This is because tPA administration comes with the possibility of worsening or recurrence of traumatic bleeding leading to exsanguination, hemorrhagic shock, or significant hematoma formation due to uncontrolled bleeding. Neck trauma is often

associated with clinically insignificant retropharyngeal hematomas, but in rare instances it may be severe enough to cause airway obstruction.<sup>7,8</sup> Retropharyngeal hematomas may also be confused for angioedema in certain clinical settings after tPA administration, given that angioedema is a well-documented phenomenon and thus is high on the differential. We present the case of a hemorrhagic airway obstruction resulting from tPA administration in the setting of minor trauma.

## CASE REPORT

A 78-year-old male with a history of hypertension and hyperlipidemia came to the emergency department (ED) due to right-sided arm weakness. He was initially found on the floor by family after falling out of bed. He could not recall specifically whether he had been weak prior to the fall or if he had fallen and then become weak. Upon arrival to the ED, he was last known normal approximately 94 minutes prior. On exam, the patient had right-sided facial weakness, right upper

extremity drift, and right lower extremity drift for a National Institutes of Health Stroke Scale (NIHSS) score of five.

Computed tomography (CT) of the head showed no acute finding and no intracranial hemorrhage. The CT of the cervical spine, given his fall, showed multilevel degenerative but no acute findings (Images 1 and 2). A CT angiogram showed severe stenosis of the proximal right vertebral artery with occlusion at the V2 segment with retrograde filling at V4 level. His labs on arrival were unremarkable. He was administered tPA approximately three hours after his last known normal.

The patient improved significantly after tPA administration, with resolution of his facial asymmetry and right lower extremity drift, and improvement in his right upper extremity drift for an NIHSS of 1. However, three hours later while holding in the ED, he complained of difficulty breathing. He was tripodding with labored respirations, stridor, and tachycardia, saturating 70% on room air and then 80% on nonrebreather mask. The circumference of his neck was also visibly expanding alarmingly. The initial concern was tPA-induced angioedema, and he was given methylprednisolone, diphenhydramine, and famotidine empirically. However, on examination of the patient's upper oropharynx, there was no visible evidence of mucosal swelling. He was unable to protect

*CPC-EM Capsule*

What do we already know about this clinical entity?

*Fibrinolytics can cause hemorrhage. Tissue plasminogen activator (tPA) can cause angioedema and airway compromise.*

What makes this presentation of disease reportable?

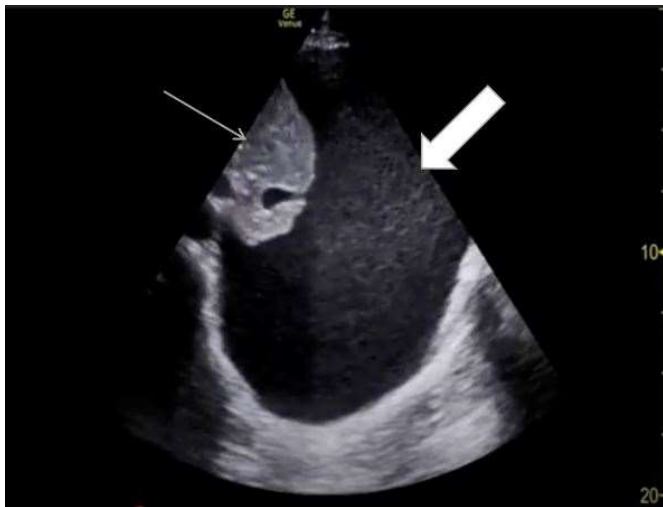*This relatively rare cause of airway compromise after tPA administration has not been previously reported in the literature.*

What is the major learning point?

*Be aware of sources of bleeding other than the brain, other threats to the airway than anioedema, and the risks after fibrinolytics in all trauma, even minor cases.*

How might this improve emergency medicine practice?

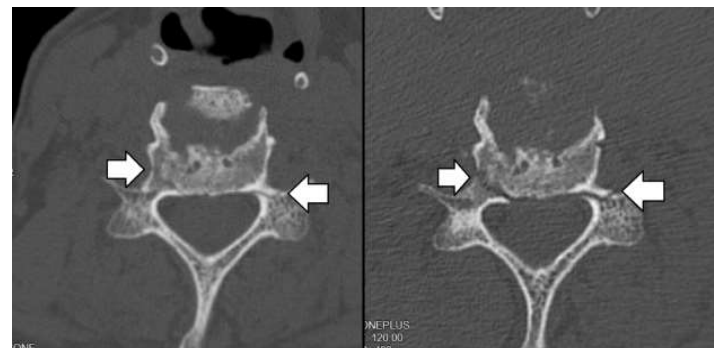
*This case report highlights the potential for post-fibrinolytic complication even after minor trauma.*



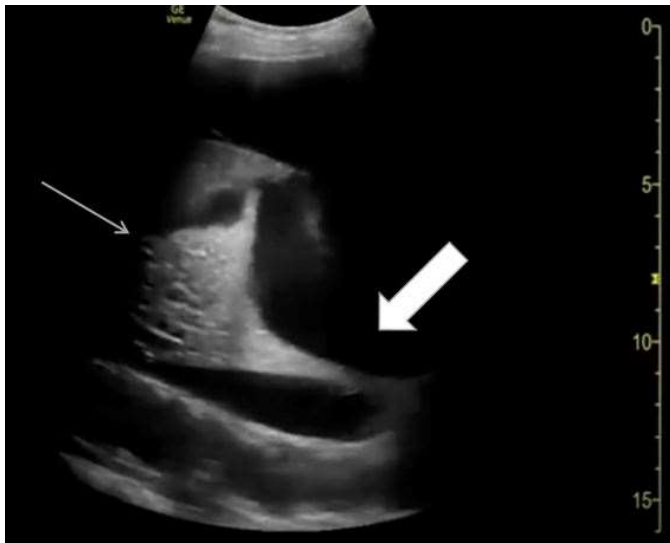
**Image 1.** Sagittal slice of the computed tomography of the patient's cervical spine prior to administration of tissue plasminogen activator. The arrow identifies the level of the patient's anterior longitudinal ligament rupture and source of his future bleeding.

his airway, and given his worsening respiratory status he was emergently intubated by the emergency physician without waiting for a response to medical intervention. During intubation, there was significant narrowing of the patient's posterior oropharynx and larynx.

Repeat head CT did not show any bleeding, but given his stiff, swollen neck and deep oropharyngeal swelling, a CT soft tissue of the neck was obtained, which showed a large retropharyngeal hematoma. Image 3 depicts magnetic



**Image 2.** Bilateral sixth cervical vertebra pedicle fractures (arrows) on arrival (left) and post-intubation (right). This image shows the initial subtle fractures that appear similar to vascular channels compared to the clear fractures after intubation.



**Image 3.** Sagittal slice of magnetic resonance imaging of the patient's retropharyngeal hematoma, demonstrating total occlusion of the airway at the midline. The endotracheal tube can be visualized above and below the hematoma at this slice. The arrow identifies the ruptured anterior longitudinal ligament and source of the patient's hematoma. The cervical 5-6 disc space is noticeably wider when compared to computed tomography imaging obtained before administration of tissue plasminogen activator (Image 1).

resonance imaging of the hematoma. Otolaryngology was consulted, and tPA reversal was initiated with cryoprecipitate.

While planning incision and drainage and tracheostomy, the otolaryngologist noticed a cervical spine fracture that was missed on the initial non-contrast CT cervical spine imaging at arrival due to its subtle appearance (Image 2) and the CT soft tissue neck after intubation, as the radiologist had focused on the soft tissue and prevertebral hematoma. The patient was placed in a cervical collar, and radiology reviewed the imaging obtained after intubation, finding a C4 spinous process fracture, widening of the C5-6 anterior disc space suggesting disruption of the anterior longitudinal ligament, C6 right transverse process fracture, and bilateral C6 pedicle fractures. Magnetic resonance imaging (MRI) of the cervical spine confirmed the C5-6 anterior longitudinal ligament rupture, which appeared to be the source of the retropharyngeal hematoma. Neurosurgery was consulted.

The patient then underwent incision and drainage of the retropharyngeal hematoma and tracheostomy, followed immediately by C5-6 open reduction, anterior discectomy, arthrodesis, and anterior instrumentation. The patient did well postoperatively. There was no further bleeding. An MRI

of the brain obtained postoperatively showed new, right-sided cerebellar infarctions.

## DISCUSSION

Major trauma is a relative contraindication to tPA administration.<sup>1</sup> In this patient who had suffered a minor fall from a height of several feet, cervical fractures and signs of a ligamentous injury were subtle and missed on initial presentation. However, given his significant right-sided weakness and an initially benign interpretation of the CT of the cervical spine, the benefits of tPA administration were determined to outweigh the risks.

Retropharyngeal hematomas are common in trauma patients, especially in the setting of cervical injuries. It has been reported that up to 60% of patients with cervical injury had widening of the prevertebral space, suggestive of retropharyngeal hematoma.<sup>7</sup> However, airway obstruction due to retropharyngeal hematoma occurs in only 1.2% of patients.<sup>8</sup> Hyperextension injuries of the cervical vertebrae can cause tearing of the longus colli muscle or anterior longitudinal ligament, which was identified as the likely source of bleeding in this patient.<sup>9,10</sup> Fractures of cervical vertebrae may also damage surrounding soft tissue and tear small branches of vertebral arteries; however, no contrast extravasation was noted on this patient's CT angiograms for his stroke evaluation.<sup>11</sup>

Tsao et al. performed a systematic review of traumatic retropharyngeal hematoma cases, discovering that 68% of patients with retropharyngeal hematomas had an associated cervical spinal injury, including cervical spinal fracture or dislocation and ligament injury. Their review found that the median age of reported cases was 72 years, that geriatric patients constituted the largest proportion of all patients, and that most (67.6%) were associated with ground-level or low-energy falls. A high index of suspicion for retropharyngeal hematoma should be applied to geriatric patients with trauma, even for those who have sustained only minor trauma.<sup>12</sup> The elderly patient we describe here with a low-energy fall mechanism and associated cervical spine injury fits all these categories.

The primary threat to life in retropharyngeal hematoma is airway obstruction. Therefore, securing a patent airway is the critical action. In the setting of an acutely obstructed airway, oral intubation, even with video laryngoscope, may be difficult. It is important to have backup equipment including bronchoscope and cricothyrotomy or tracheostomy equipment on hand. This also applies to airway-threatening angioedema.

As soon as the airway is secure, bleeding should be addressed. The American Heart Association/ American Stroke Association (AHA/ASA) recommend tranexamic acid (TXA) or aminocaproic acid, as well as cryoprecipitate, for treatment of intracranial bleeding after tPA administration.<sup>13</sup> The AHA/ASA guidelines do not make specific recommendations for other sources of bleeding; however,



given that the recommendations are specific to the mechanism of tPA, they should be followed for any severe or symptomatic bleeding. Tissue plasminogen activator converts plasminogen to plasmin, which lyses fibrin and fibrinogen, breaking up blood clots. Tranexamic acid and aminocaproic acid directly oppose this mechanism by binding to plasminogen and preventing its conversion to plasmin. The guidelines also recommend cryoprecipitate to replenish fibrinogen levels until its level is greater than 150 milligrams per deciliter to facilitate clotting and hemostasis, as tPA depletes fibrinogen specifically.<sup>13</sup>

## CONCLUSION

It is important to recognize that although angioedema is likely the most common threat to a patient's airway after tPA administration, clinicians should maintain suspicion for other bleeding threats as well. Careful consideration should be given to the risks of bleeding after tPA administration in the setting of trauma, even when the degree of trauma appears to be minor. Bleeding is a well-known potential complication of tPA and requires emergent reversal by TXA or aminocaproic acid and fibrinogen replacement with cryoprecipitate administration if severe, and swift airway protection is crucial to prevent morbidity and mortality.

## ACKNOWLEDGMENTS

Another case report was previously published about this patient from the pharmacist's perspective, without shared images, words or ideas, in the following article: Jolley A, McKnight M, Clark K. Retropharyngeal hematoma mimicking angioedema after intravenous thrombolysis for acute ischemic stroke. *Am J Emerg Med.* 2023 May;67:196.e1-196.e2. doi: 10.1016/j.ajem.2023.03.016. Epub 2023 Mar 12. PMID: 36948989.

IRB approval and patient consent have been obtained for publication of this case report. Documentation on file.

*Address for Correspondence:* Christian Provenza, MD, University of Tennessee Health Science Center, Department of Emergency Medicine, Memphis Hall, Suite A-207, 251 South Claybrook, Memphis, TN 38104. E-mail: cproven2@uthsc.edu.

*Conflicts of Interest:* By the CPC-EM article submission agreement, all authors are required to disclose all affiliations, funding sources and financial or management relationships that could be perceived as potential sources of bias. The authors disclosed none.

*Copyright:* © 2023 Provenza et al. This is an open access article distributed in accordance with the terms of the Creative Commons Attribution (CC BY 4.0) License. See: <http://creativecommons.org/licenses/by/4.0/>

## REFERENCES

1. Demaerschalk BM, Kleindorfer DO, Adeoye OM, et al. American Heart Association Stroke Council and Council on Epidemiology and Prevention. Scientific Rationale for the Inclusion and Exclusion Criteria for Intravenous Alteplase in Acute Ischemic Stroke: A Statement for Healthcare Professionals from the American Heart Association/American Stroke Association. *Stroke.* 2016;47(2):581-641. Erratum in: *Stroke.* 2016;47(11):e262.
2. Hill MD and Buchan AM, Canadian Alteplase for Stroke Effectiveness Study (CASES) investigators. Thrombolysis for acute ischemic stroke: results of the Canadian Alteplase for Stroke Effectiveness Study. *CMAJ.* 2005;172(10):1307-12.
3. Hill MD, Lye T, Moss H, et al. Hemi-oro-lingual angioedema and ACE inhibition after alteplase treatment of stroke. *Neurology.* 2003;60(9):1525-7.
4. Gallant SC, Fritz MA, Paul BC, et al. Management of airway compromise following thyroid cyst hemorrhage after thrombolytic therapy. *Laryngoscope.* 2015;125(3):604-7.
5. Shaps HJ, Snyder GE, Sama AE, et al. Airway compromise secondary to lingual hematoma complicating administration of tissue plasminogen activator for acute ischemic stroke. *Ann Emerg Med.* 2001;38(4):447-9.
6. Sutter R, Bruder E, Weissenburg M, et al. Thyroid hemorrhage causing airway obstruction after intravenous thrombolysis for acute ischemic stroke. *Neurocrit Care.* 2013;19(3):381-4.
7. Penning L. Prevertebral hematoma in cervical spine injury: incidence and etiologic significance. *AJNR Am J Neuroradiol.* 1980;1(6):557-65.
8. Kuhn JE and Graziano GP. Airway compromise as a result of retropharyngeal hematoma following cervical spine injury. *J Spinal Disord.* 1991;4(3):264-9.
9. Park JH, Jeong EK, Kang DH, et al. Surgical treatment of a life-threatening, large retropharyngeal hematoma after minor trauma: two case reports and a literature review. *J Korean Neurosurg Soc.* 2015;58(3):304-7.
10. Paul D, Sen S, Palai A, et al. Retropharyngeal hematoma secondary to minor blunt trauma neck: a rare case report. *Bengal J Otolaryng Head Neck Surg.* 2015;23:35-8.
11. Kudo S, Fukushima K, Hashimoto M, et al. Airway and circulatory collapse due to retropharyngeal hematoma after blunt vertebral artery injury. *Am J Emerg Med.* 2017;35:806-7.
12. Tsao YL, Hsu CC, Chen KT. Blunt traumatic retropharyngeal hematoma with respiratory symptoms: a systematic review of reported cases. *Emerg Med Int.* 2021;2021:5158403.
13. Powers WJ, Rabinstein AA, Ackerson T, et al. Guidelines for the Early Management of Patients with Acute Ischemic Stroke: 2019 Update to the 2018 Guidelines for the Early Management of Acute Ischemic Stroke: A Guideline for Healthcare Professionals from the American Heart Association/American Stroke Association. *Stroke.* 2019;50(12):e344-e418. Erratum in: *Stroke.* 2019;50(12):e440-1.

# Emergency Department Point-of-care Ultrasound Identification of Suspected Lemierre's Syndrome: A Case Report

Paul Craven, MD  
Bradley End, MD  
Peter Griffin, MD

West Virginia University, Department of Emergency Medicine, Morgantown, West Virginia

Section Editor: Shadi Lahham, MD

Submission history: Submitted March 26, 2023; Revision received June 5, 2023; Accepted June 5, 2023

Electronically published August 9, 2023

Full text available through open access at [http://escholarship.org/uc/uciem\\_cpccm](http://escholarship.org/uc/uciem_cpccm)

DOI: 10.5811/cpcem.1245

**Introduction:** Lemierre's syndrome is septic thrombophlebitis of the internal jugular vein, most commonly associated with head and neck infections. While central catheters are associated with venous thromboembolism and catheter-associated bacterial infections, cases of Lemierre's syndrome caused by central catheters are extraordinarily rare.

**Case Report:** We detail a case of Lemierre's syndrome resulting from a peripherally inserted central catheter in a pregnant female patient. Diagnosis of this rare and potentially life-threatening disease process was expedited using point-of-care ultrasound.

**Conclusion:** Diagnosis of rare but potentially life- or limb-threatening pathologies is paramount to the successful practice of emergency medicine. Identifying these rare disease processes requires a high index of suspicion and a work-up strategy that includes consideration of medical history in combination with lab and imaging findings to determine appropriate interventions. [Clin Pract Cases Emerg Med. 2023;7(3):172–174.]

**Keywords:** *Case report; septic thrombophlebitis; Lemierre's syndrome; point-of-care ultrasound.*

---

## INTRODUCTION

Lemierre's syndrome is septic thrombophlebitis of the internal jugular (IJ) vein. It is most commonly caused by oropharyngeal flora, usually fusobacterium species, although streptococcal species such as *Eikenella corrodens* are also common. Pathogenesis is through extension of pharyngitis, tonsillitis, odontogenic, and other oropharyngeal and head and neck infections.<sup>1</sup> Septic thrombophlebitis is a known but rare complication of central catheters, with peripherally inserted central catheters (PICC) lines having reduced risk of infection.<sup>2</sup> We report a case of septic thrombophlebitis related to a PICC line extending into the jugular veins and throughout the central vasculature of the chest in a pregnant patient, initially diagnosed on point-of-care ultrasound (POCUS).

## CASE REPORT

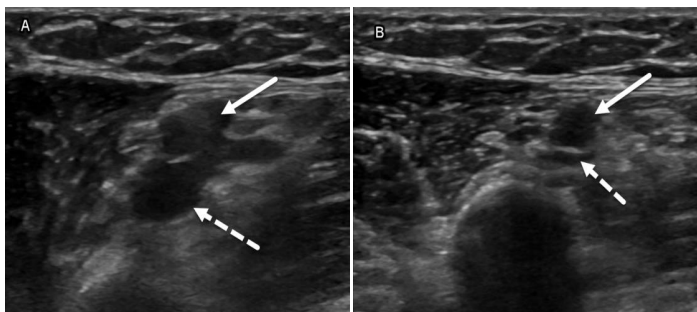
A 29-year-old female, gravida 3 para 2 at 29 weeks gestation presented to the emergency department (ED) with left arm and neck swelling. Her pregnancy had been complicated by hyperemesis gravidarum requiring a left-sided PICC. Her medical history was significant for prior pregnancies complicated by hyperemesis and a reported history of opioid use disorder on buprenorphine. The PICC had been removed at another ED approximately three days prior to presentation at our ED after the site had become erythematous and painful. She was placed on oral antibiotics and recommended to follow up with her obstetrician. Despite removal of the the PICC, the site had become severely swollen and erythematous extending over her left neck. In addition, she had begun to experience chest pain, worsening shortness

of breath, fever, chills, and left arm paresthesias, which prompted her to seek evaluation.

On arrival her heart rate (HR) was in the 160s beats per minute (bpm) and blood pressure (BP) 95/67 millimeters of mercury (mm Hg); otherwise, her vital signs were within normal limits. On physical exam, the PICC site was erythematous, swollen, and tender. She had marked swelling involving her left upper extremity, chest, and left side of the neck. Given the patient's vitals and physical exam, there was significant clinical suspicion for deep venous thrombosis (DVT). We used point-of-care-ultrasound to perform a bedside DVT assessment with noted extensive clot burden extending through the basilic vein into the axillary vein (Image 1), as well as in the IJ vein (Image 2). Serum labs were notable for a white blood count of  $20.7 \times 10^3$  cells per microliter (uL) with 80% neutrophils (reference range:  $3.7\text{--}11 \times 10^3$  cells/uL).

The findings prompted a recommendation that she undergo a computed tomography (CT) pulmonary embolism protocol, which she consented to. Cross-sectional imaging demonstrated extensive clot burden encompassing the left brachiocephalic, left subclavian, and left internal and external jugular veins (Image 2). The CT was also concerning for septic pulmonary emboli. Given the combination of extensive clot burden encompassing the IJ, in addition to septic emboli, we were able to confirm the diagnosis of Lemierre's syndrome. The patient was immediately initiated on heparin and broad-spectrum antibiotics.

Obstetrics was consulted at the time of the patient's arrival and was bedside shortly thereafter. She received dexamethasone six milligrams intramuscular in the event of an emergent cesarean section. Fortunately, neonatal stress testing demonstrated no evidence of fetal distress, and the patient continued to improve. She was subsequently admitted to the intensive care unit (ICU) by which time her HR had improved to 116 bpm and BP to 105/52 mm Hg. Interventional radiology was also consulted for possible thrombectomy vs thrombolysis at time of arrival; however, given the patient's improvement by time of admission to the ICU the recommendation was for conservative therapy.



**Image 1.** Point-of-care ultrasound of the left axilla in short axis using a 15–6 MHz linear probe: A) without compression; and B) with compression. The axillary vein (solid white arrow) demonstrates non-compressible venous structures with near-complete collapse of the concomitant artery (dotted white arrow).

### CPC-EM Capsule

What do we already know about this clinical entity?

*Lemierre's syndrome is a bacterial infection that extends to the lateral pharyngeal space, precipitating septic thrombophlebitis of the internal jugular veins.*

What makes this presentation of disease reportable?

*Lemierre's syndrome is rare; any opportunity to identify and learn from the disease process is beneficial, particularly expediting diagnosis.*

What is the major learning point?

*Ultrasound can be an effective modality to aid in the diagnosis of Lemierre's syndrome.*

How might this improve emergency medicine practice?

*Ultrasound is often more readily available in the evaluation of unstable patients and can be performed in resource-limited settings.*

While inpatient, blood cultures resulted positive for methicillin-sensitive *Staphylococcus aureus* (MSSA).

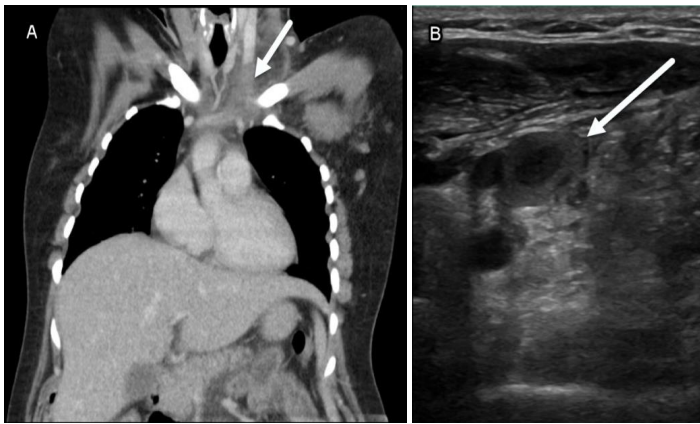
Ultimately the patient did very well without requiring procedural intervention or cesarean section. She was continued on enoxaparin and discharged on six weeks of cefazolin.

### DISCUSSION

Lemierre's syndrome is a rare form of septic thrombophlebitis, usually arising from an infection of the head or neck. Our literature review revealed only two case reports of Lemierre's syndrome resulting from catheter use. The first described a dialysis catheter in the patient's IJ, and the second a PICC line that had migrated into the jugular vein.<sup>3,4</sup> Our case represents a unique example of a patient with no catheter in the jugular vein developing Lemierre's syndrome. Furthermore, while MSSA is a common isolate associated with central line-associated bacteremia, it rarely causes Lemierre's syndrome. Using POCUS for DVT evaluation allows for rapid diagnosis of venous thromboembolism at bedside. We found two cases in the literature of Lemierre's syndrome being diagnosed with POCUS.<sup>4,5</sup>

### CONCLUSION

Patients with central catheters, whether peripherally or centrally inserted, are at increased risk for both thromboembolism and septic thrombophlebitis. A high index



**Image 2.** A) Contrast-enhanced computed tomography of the chest in coronal view demonstrating lack of contrast in the left internal jugular vein (arrow). B) Point-of-care ultrasound of the left neck using a 15-6 MHz linear probe demonstrating lack of compressibility of the left internal jugular vein with noted thrombus within the lumen (arrow).

of suspicion is required to make the proper diagnosis. Patients presenting to the ED with signs and symptoms of venous thromboembolism and infectious symptoms should undergo point-of-care ultrasound and sepsis evaluation to identify this rare but life-threatening pathology.

The authors attest that their institution requires neither Institutional Review Board approval, nor patient consent for publication of this case report. Documentation on file.

*Address for Correspondence:* Bradley End, MD, Robert C. Byrd Health Sciences Center, Department of Emergency Medicine, Department of Medical Education, RCBHSC PO BOX 9149, West Virginia University, Morgantown, WV 26506. Email: Bradley.end@hsc.wvu.edu.

*Conflicts of Interest:* By the *CPC-EM* article submission agreement, all authors are required to disclose all affiliations, funding sources and financial or management relationships that could be perceived as potential sources of bias. The authors disclosed none.

*Copyright:* © 2023 Craven et al. This is an open access article distributed in accordance with the terms of the Creative Commons Attribution ([CC BY 4.0](http://creativecommons.org/licenses/by/4.0/)) License. See: <http://creativecommons.org/licenses/by/4.0/>

## REFERENCES

1. Golpe R, Marín B, Alonso M. Lemierre's syndrome (necrobacillosis). *Postgrad Med J.* 1999;75(881):141-4.
2. Andes DR, Urban AW, Archer CW, et al. Septic thrombosis of the basilic, axillary, and subclavian veins caused by a peripherally inserted central venous catheter. *Am J Med.* 1998;105(5):446-50.
3. Hennigan A, Collinge N, Halker R, et al. Cuffed-catheter-related Lemierre syndrome. *Hemodial Int.* 2004;8(4):400-3.
4. Davies O and Than M. Lemierre's syndrome: diagnosis in the emergency department. *Emerg Med Australas.* 2012;24(6):673-6
5. Castro-Marín F and Kendall JL. Diagnosis of Lemierre syndrome by bedside emergency department ultrasound. *J Emerg Med.* 2010;39(4):436-9.



# The Diagnostic Dilemma in Delayed Subarachnoid Hemorrhage: A Case Report

Danielle A. Bazer, DO<sup>†</sup>  
Nicholas Koroneos, DO\*  
Matthew Orwitz, MD\*  
Jordan Amar, MD<sup>‡</sup>  
Ryan Corn, DO\*  
Elizabeth Wirkowski, MD\*

\*Stony Brook University Hospital, Department of Neurology, Stony Brook, New York  
†Johns Hopkins Medicine, Department of Neurology, Baltimore, Maryland  
‡Washington University in St. Louis, Department of Neurology, St. Louis, Missouri

Section Editor: Austin Smith, MD

Submission history: Submitted December 7, 2022; Revision received June 2, 2023; Accepted June 9, 2023

Electronically published August 2, 2023

Full text available through open access at [http://escholarship.org/uc/uciem\\_cpem](http://escholarship.org/uc/uciem_cpem)

DOI: 10.5811/cpem.1586

**Introduction:** Radiologically negative subarachnoid hemorrhage (SAH) has a low incidence and is associated with good clinical outcomes.

**Case Report:** We present the case of a 44-year-old male with new-onset headaches, which began one week prior while bike riding. At an outside hospital, he had normal computed tomography head and angiogram. He declined a lumbar puncture. Over the following week, the headache was persistent. He lacked meningeal signs. Repeat studies were normal. Lumbar puncture was positive for xanthochromia.

**Conclusion:** Radiologically negative SAH should be included in the differential diagnosis of patients presenting with unremitting headache in the setting of recent exercise, despite negative imaging, and meningeal signs. [Clin Pract Cases Emerg Med. 2023;7(3):175–177.]

**Keywords:** *subarachnoid hemorrhage; lumbar puncture; radiologically negative.*

## INTRODUCTION

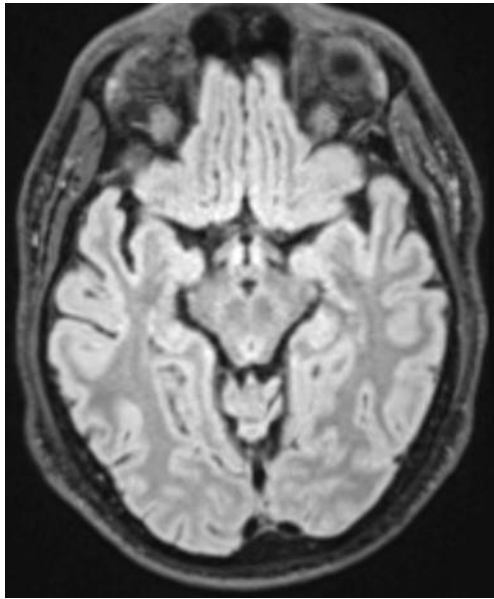
The unifying features of all types of subarachnoid hemorrhage (SAH) are an average age of onset at 55 years old with a male predominance (despite aneurysmal SAH having a female predominance).<sup>1,2</sup> Patients with an idiopathic etiology tend to have a less severe disease course with fewer complications.<sup>1</sup> However, 85% of SAH are secondary to aneurysmal rupture.<sup>3</sup> Vascular imaging is suggested after the diagnosis of SAH is made.<sup>3</sup> Although at a low incidence, less than 1% of cases are diagnosed by spectrophotometric detection of a bilirubin peak in the cerebrospinal fluid (CSF) obtained from a lumbar puncture (LP), as reflected in this case.<sup>4,6</sup>

## CASE REPORT

This is a case of a 44-year-old male, without past medical history, who initially presented due to new-onset headaches. The patient reported no personal or family history of

headaches. His symptoms began one week prior to presentation while exercising vigorously on his exercise bike. During the last few minutes of his workout, he developed an acute onset, band-like headache with radiation to his cervical spine. He first went to a local emergency department where he underwent CT head and CT angiogram, which were reportedly normal. He was offered an LP, but he declined.

Over the following week, the headache was persistent, with new-onset tinnitus, intermittent phonophobia, and continued pain radiation down his spine to his central lower back. He denied pain with eye movements, photophobia, nausea, vomiting, and positional changes. His neurological exam was unremarkable, with absent meningeal signs. Head CT, magnetic resonance imaging (MRI) of the brain (Image), cervical, thoracic, and lumbar spine were normal. Magnetic resonance angiogram of the head and neck was also normal. Complete blood count, chemistry, coagulation studies,



**Image.** This is a normal magnetic resonance image of the brain. There is no blood in the perimesencephalic area.

erythrocyte sedimentation rate, and C-reactive protein were within normal limits.

An LP revealed yellow-colored CSF positive for xanthochromia, 223 white blood cells (97% mononuclear cells), and 6,000 red blood cells. Protein and glucose levels were normal. He subsequently underwent diagnostic cerebral angiogram, which was normal. The patient was diagnosed with a radiographic-negative SAH and was treated with a trial of steroids upon discharge home. He was followed up outpatient at two weeks and six weeks from discharge. By six-week follow-up, he reported 99% improvement of his symptoms.

## DISCUSSION

In 85% of SAH cases, aneurysms are the cause. Non-aneurysmal SAH is defined as SAH without vascular lesions on angiography and can be further divided into perimesencephalic and non-perimesencephalic non-aneurysmal SAH. Aneurysmal SAH has a vascular lesion.<sup>7</sup> Although non-contrast CT of the brain is the preferred initial imaging modality, CT angiogram, diagnostic angiogram, and MRI can aid in the diagnosis to further understand cerebrovascular anatomy and aneurysms.<sup>8</sup> The sensitivity of MRI in SAH ranges from 50-94% with an acute SAH and 33-100% in subacute SAH. The most sensitive sequence is T2 with a sensitivity of 94%. The specificity is 98.5%.<sup>9</sup> Lu et al found that digital subtraction angiogram had a sensitivity of 91.3% of detecting aneurysms less than 3 millimeters (mm); 94.0% for aneurysms between 3 mm but <5 mm; 98.4% for aneurysms between 5 mm and <10 mm; and 100% for aneurysms  $\geq 10$  mm.<sup>10</sup>

This case highlights the importance of the above evaluation with regard to sentinel headaches. Sentinel

### *CPC-EM Capsule*

What do we already know about this clinical entity?

*Although rare, we know that subarachnoid hemorrhages can be radiologically negative.*

What makes this presentation of disease reportable?

*Although the patient lacked meningeal signs and had negative neuro-imaging on two occasions, the lumbar puncture confirmed the diagnosis of radiologically negative subarachnoid hemorrhage.*

What is the major learning point?

*It is imperative to obtain a lumbar puncture when radiographic studies are negative to rule out subarachnoid hemorrhage as the etiology of a headache.*

How might this improve emergency medicine practice?

*This case will likely urge emergency medicine providers to obtain lumbar punctures on patients who have an unremitting headache and negative neuro-imaging.*

headaches signify a particularly severe headache that precedes a second episode of a profound headache secondary to intracranial aneurysm rupture.<sup>11</sup> Typically, sentinel bleeds are believed to be a warning as an aneurysm starts to bleed and will subsequently rebleed a few days later, necessitating medical attention and evaluation.<sup>11</sup> Gambhir et al in 2009 cited that 38% of patients with aneurysmal SAH had sentinel headaches, with misdiagnosis being a key problem.<sup>12</sup>

As a sentinel headache typically does not share the cardinal features of spontaneous SAH, such as focal neurological deficits or nuchal rigidity, it is common for sentinel headaches to be misdiagnosed as a different headache type.<sup>13,14</sup> Therefore, in individuals who are not prone to having headaches a complete evaluation, including imaging and LP, should be obtained.<sup>13</sup> For our patient, it was key to have a LP performed, as he had both CT- and MRI-negative brain and vessel imaging on two separate occasions, as well as an unrevealing diagnostic angiogram. Given the persistence of bilirubin and xanthochromia in the spinal fluid up to 15 days after hemorrhage, it is imperative to obtain a LP when the radiographic studies are negative to elucidate whether SAH is the etiology of the headache.<sup>15</sup>

## CONCLUSION

This case highlights the importance of including radiologically negative SAH in the differential diagnosis of patients presenting with unremitting headache in the setting of recent exercise, despite negative imaging and the absence of meningeal signs on physical exam.

Patient consent was obtained for the publication of this case report. Documentation on file.

---

*Address for Correspondence:* Danielle A. Bazer, DO, Johns Hopkins Medicine, Department of Neurology, Skip Viragh Building, 201 North Broadway, 9<sup>th</sup> Floor Mailbox #3, Baltimore, MD 21287. Email: dbazer1@jhu.edu.

*Conflicts of Interest:* By the CPC-EM article submission agreement, all authors are required to disclose all affiliations, funding sources and financial or management relationships that could be perceived as potential sources of bias. The authors disclosed none.

*Copyright:* © 2023 Bazer et al. This is an open access article distributed in accordance with the terms of the Creative Commons Attribution (CC BY 4.0) License. See: <http://creativecommons.org/licenses/by/4.0/>

---

## REFERENCES

1. Lagares A, Gómez PA, Lobato RD, et al. Hemorragia subaracnoidea no filiada: comparación de diferentes patrones de sangrado y evolución a largo plazo [Idiopathic subarachnoid hemorrhage; comparison of different bleeding patterns and long-term outcome]. *Neurocirugia (Astur)*. 2002;13(2):110-9. Spanish.
2. Wáng YX, He J, Zhang L, et al. A higher aneurysmal subarachnoid hemorrhage incidence in women prior to menopause: a retrospective analysis of 4,895 cases from eight hospitals in China. *Quant Imaging Med Surg*. 2016;6(2):151-6.
3. Macdonald RL and Schweizer TA. Spontaneous subarachnoid haemorrhage. *Lancet*. 2017;389(10069):655-66.
4. McCormack RF and Hutson A. Can computed tomography angiography of the brain replace lumbar puncture in the evaluation of acute-onset headache after a negative noncontrast cranial computed tomography scan? *Acad Emerg Med*. 2010;17(4):444-51.
5. Beetham R, Fahie-Wilson MN, Park D. What is the role of CSF spectrophotometry in the diagnosis of subarachnoid haemorrhage? *Ann Clin Biochem*. 1998;35( Pt 1):1-4.
6. Mohan M, Islim AI, Rasul FT, et al. British Neurosurgical Trainee Research Collaborative. Subarachnoid haemorrhage with negative initial neurovascular imaging: a systematic review and meta-analysis. *Acta Neurochir (Wien)*. 2019;161(10):2013-26.
7. van Gijn J, Kerr RS, Rinkel GJ. Subarachnoid hemorrhage. *Lancet*. 2007;369(9558):306-18.
8. Hoh BL, Ko NU, Amin-Hanjani S, et al. 2023 Guideline for the Management of Patients with Aneurysmal Subarachnoid Hemorrhage: A guideline from the American Heart Association/ American Stroke Association. *Stroke*. 2023;54(7):e314-70.
9. Mitchell P, Wilkinson ID, Hoggard N, et al. Detection of subarachnoid haemorrhage with magnetic resonance imaging. *J Neurol Neurosurg Psychiatry*. 2001;70(2):205-11.
10. Lu L, Zhang LJ, Poon CS, et al. Digital subtraction CT angiography for detection of intracranial aneurysms: comparison with three-dimensional digital subtraction angiography. *Radiology*. 2012;262(2):605-12.
11. Viarasilpa T, Ghosh P, Gidwani S, et al. Prognostic significance of sentinel headache preceding aneurysmal subarachnoid hemorrhage. *World Neurosurg*. 2020;139:e672-6.
12. Gambhir S, O'Grady G, Koelmeyer T. Clinical lessons and risk factors from 403 fatal cases of subarachnoid haemorrhage. *J Clin Neurosci*. 2009;16(7):921-4.
13. Ziu E, Kahn Suheb MZ, Mesfin FB. (2021). *Subarachnoid Hemorrhage*. Treasure Island, FL: StatPearls Publishing. Available at: <https://www.ncbi.nlm.nih.gov/books/NBK441958/> Accessed June 1, 2023.
14. Pereira JL, de Albuquerque LA, Dellaretti M, et al. Importance of recognizing sentinel headache. *Surg Neurol Int*. 2012;3:162.
15. Edjlali M, Rodriguez-Régent C, Hodel J, et al. Subarachnoid hemorrhage in ten questions. *Diagn Interv Imaging*. 2015;96(7-8):657-66.

# Delayed-onset Angioedema Following a Snakebite in a Patient on ACE Inhibitors: A Case Report

Christopher Scott Sampson, MD\*  
Evan Schwarz, MD†

\*University of Missouri School of Medicine, Department of Emergency Medicine, Columbia, Missouri

†Washington University School of Medicine in Saint Louis, Department of Emergency Medicine, Saint Louis, Missouri

Section Editor: Steven Walsh, MD

Submission History: Submitted January 24, 2022; Revision received March 17, 2022; Accepted March 17, 2022

Electronically published June 26, 2023

Full text available through open access at [http://escholarship.org/uc/uciem\\_cpem](http://escholarship.org/uc/uciem_cpem)

DOI: 10.5811/cpcem.1463

**Introduction:** Angiotensin converting enzyme inhibitors (ACEI) are a common class of medications prescribed to patients for hypertension. Anti-hypertensive use is not normally considered an important factor when treating patients with crotalid envenomations; however, in combination with the venom in this patient, it may have resulted in angioedema.

**Case Report:** A 65-year-old male on ACEI presented to his community emergency department following a snake envenomation to his thumb. Six vials of Crotalidae polyvalent immune fab were administered, and he was transferred to a referral center. Approximately 18 hours after the envenomation, the patient complained of tongue swelling and difficulty speaking. There was evidence of angioedema, with the right side of the tongue significantly enlarged compared to the left. He was intubated for airway protection and remained on a ventilator for three days.

**Conclusion:** Angiotensin converting enzyme inhibitors may potentiate the effects of exogenous bradykinin as some snake venom has naturally occurring bradykinin, which may further amplify its effects. Extra vigilance may be warranted for the development of angioedema in patients receiving ACEI. [Clin Pract Cases Emerg Med. 2023;7(3):178–181.]

**Keywords:** case report; angioedema; Crotalidae polyvalent immune fab; snakebite.

## INTRODUCTION

Angiotensin converting enzyme inhibitors (ACEI) are a common class of medications prescribed to patients for hypertension. Their use in patients envenomated by North American crotalids is generally not considered to be clinically significant. We report a case of delayed angioedema potentially from an interaction of the venom and ACEI in a patient envenomated by a copperhead (*Agkistrodon contortrix*).

## CASE REPORT

A 65-year-old male presented to a community emergency department (ED) following a snake envenomation to his thumb. Approximately four hours prior to arrival, he had attempted to pick up a copperhead in the field by his home and “it turned around and bit me on the thumb.” He complained

of pain and swelling to thumb, hand, and wrist, along with shortness of breath. His past medical history included chronic obstructive pulmonary disease, atrial fibrillation, hypertension, mitral and tricuspid regurgitation, coronary artery disease, and diabetes. His daily oral medications included amiodarone 400 milligrams (mg), apixaban 5 mg, atorvastatin 40 mg, clopidogrel 75 mg, furosemide 20 mg, lisinopril 5 mg, and metoprolol succinate extended release 25 mg. He had been taking the lisinopril as prescribed for almost two years.

Initial vital signs were temperature of 36.5° Celsius, heart rate 74 beats per minute, blood pressure 128/82 millimeters of mercury (mm Hg), and respiratory rate 26 breaths per minute with saturations of 96% on room air. Initial examination was notable for wheezing bilaterally, an irregularly irregular heartbeat, and edema of the thumb, hand, and wrist without



ecchymosis or necrosis. His white blood cell count was  $10 \times 10^9$  per liter (L) (reference range  $3.50\text{-}10.50 \times 10^9/\text{L}$ ), hemoglobin 13.7 grams per deciliter (g/dL) (reference range  $12\text{-}15.5 \text{ g/dL}$ ), hematocrit 41.5% (reference range:  $34.9\text{-}44.5\%$ ), and platelets  $163 \times 10^9/\text{L}$  (reference range  $150\text{-}450 \times 10^9/\text{L}$ ). Prothrombin time was 12.8 seconds (s) (reference range  $12.5\text{-}15.1 \text{ s}$ ) with an international normalized ratio 1.09 (reference range  $0.9\text{-}1.2$ ), and partial thromboplastin time 27.9 s (reference range  $25.8\text{-}35.6 \text{ s}$ ). Electrolytes were within normal limits.

An electrocardiogram demonstrated atrial fibrillation at a normal rate with no ischemic changes. His wheezing resolved with a nebulized albuterol breathing treatment. Shortly into his ED stay, the patient complained of increasing pain and swelling along with nausea. On re-examination, edema was noted up to the level of his elbow. Six vials of crotalidae polyvalent immune fab (FabAV) were administered intravenously (IV), and he was transferred to a referral center.

Upon arrival at the referral ED, the patient only had mild edema of his hand and wrist. Ink markings placed at the community ED and transport team were noted on his forearm and upper arm, with the edema not extending past the highest levels of the markings. Vital signs were normal. He was admitted overnight for serial examinations and analgesia with ketorolac and oxycodone.

Approximately 18 hours after the envenomation, the patient complained of tongue swelling and difficulty speaking. He did not develop new wheezing or a rash. There was evidence of angioedema with the right side of the tongue significantly enlarged when compared to the left side. The patient had difficulty controlling his secretions but could swallow his saliva without problem. However, his voice was muffled compared to when he arrived. He received famotidine 20 mg IV, methylprednisolone 125 mg IV, and 50 mg of IV diphenhydramine without improvement; 0.2 mg epinephrine was administered intramuscularly.

Otolaryngology performed a bedside rhinoscopy. Nasal mucosa was examined and was within normal limits. The nasopharynx, soft palate, and oropharynx were unremarkable. Fullness of the base of his tongue was noted. His epiglottis was normal with questionably minimal thickening; the remainder of the glottis and supraglottis were normal. True vocal cords were mobile bilaterally.

Given increasing symptoms, the patient was intubated without difficulty. He remained intubated for three days and was extubated without difficulty. The day after extubation, the patient complained of seeing bugs on the ventilator of his room overnight, as well as spiders and birds outside his window. He received benzodiazepines for either delirium vs alcohol withdrawal with improvement over the next 24 hours. Symptoms improved in less than 24 hours. He was discharged the next day.

## DISCUSSION

Copperheads are responsible for most native venomous snake envenomations in Missouri. While there are two species of

### *CPC-EM Capsule*

What do we already know about this clinical entity?

*Patients prescribed angiotensin converting enzyme inhibitors (ACEI) have a small risk of angioedema; ACEI mimic the action of viper venom, which prevents breakdown of bradykinin.*

What makes this presentation of disease reportable?

*A patient taking ACEI presented following a copperhead bite, received antivenom, and developed a delayed, severe case of angioedema.*

What is the major learning point?

*Angiotensin converting enzyme inhibitors may potentiate the effects of exogenous bradykinin, amplifying its effects.*

How might this improve emergency medicine practice?

*Extra vigilance may be warranted for the development of angioedema in patients with snakebites who are receiving ACEI.*

rattlesnakes in this state, there are far fewer envenomations from rattlesnakes than copperheads here. Furthermore, given that the patient only experienced pain and swelling without necrosis or hematologic abnormalities, the envenomation is most consistent with that of a copperhead, particularly in this area.

The signs and symptoms of crotalinae (pit viper) envenomation can vary from local to systemic. Localized complaints include pain, edema, erythema, and ecchymosis. These symptoms generally appear within eight hours of the envenomation; dry bites occur in approximately 25% of cases. Nausea, vomiting, diaphoresis and, very rarely, coagulopathy have been reported. Systemic complaints include nausea, vomiting, diaphoresis, coagulopathy, neurologic abnormalities, nephrotoxicity, angioedema, and increased vascular permeability.<sup>1-2</sup> We could not find any reports in the literature of angioedema associated with a copperhead bite.

Crotalidae polyvalent immune fab is a sheep-derived antivenom created for management of crotalid envenomation. The medication is administered intravenously. Indications for administration include significant or progressive local tissue damage and evidence of hematological toxicity.<sup>3</sup> A recent randomized controlled trial demonstrated the benefit of treating patients envenomated by copperheads

with antivenom.<sup>4</sup> Hypersensitivity including anaphylaxis is a known, although rare, complication following the administration of FabAV. The most common complications are urticaria, rash, nausea, pruritis, and back pain.<sup>5</sup> Immediate serious adverse events related to FabAV include two cases of tongue swelling.

A review of the North American Snakebite Registry demonstrated that only 1.1% of patients developed a combination of hypotension, bronchospasm, and angioedema following administration of FabAV.<sup>6</sup> Additionally, a 68-year-old male developed urticaria and hypotension during the initial 20 minutes of an infusion of six vials of FabAV, which temporarily resolved after he received diphenhydramine, famotidine, and methylprednisolone. The infusion was restarted and completed. However, shortly afterward, hypotension and urticaria recurred, and angioedema developed requiring epinephrine.<sup>7</sup> A 36-year-old also developed angioedema while receiving FabAV. All reports of angioedema secondary to FabAV use have been immediate and occurred during the infusion period.<sup>8</sup>

Captopril, the original ACEI, was developed after peptides in the Brazilian viper *Bothrops jararaca*'s venom were discovered to inhibit angiotensin converting enzyme.<sup>9</sup> Angiotensin converting enzyme inhibitors prevent the breakdown of bradykinin, which may lead to the development of angioedema. Components in the venom of a pit viper include histamine and bradykinin-like factors that can cause systemic effects.<sup>10</sup> Given that the mechanism of angioedema from ACEI is thought to be through bradykinin release and that our patient had a pit viper envenomation, the delayed angioedema may have been a result of both synergistically interacting. While FabAV may cause angioedema, this is rare, and all reports of angioedema secondary to FabAV use has been immediate and occurred during the infusion period. Given the lack of unpublished reports and the time frame of onset, the angioedema was not likely associated with the antivenin infusion. Delayed-onset venom effects may also result in angioedema. However, this seems unlikely as it has not been previously reported.

A case report from Sweden described severe and prolonged hypertension in a 60-year-old male caused by an adder bite. The case report suggests that given ACEI potentiating the effects of exogenous bradykinin and that some snake's venom has naturally occurring bradykinin which may amplify its effects.<sup>11</sup> ACEI angioedema appears to occur through decreased bradykinin metabolism by the ACE enzyme.<sup>12</sup> Components in the venom of a pit viper include histamine and bradykinin-like factors which can cause systemic effects.<sup>10</sup> Given the mechanism of angioedema from ace inhibitors, the bradykinin accumulation from his medication and associated pit viper envenomation, the delayed angioedema may be a result of both synergistically interacting.

Thus, we believe that this patient most likely developed angioedema due to an amplification of bradykinin from his

prescribed ACEI combined with bradykinin in the snake venom. Despite copperhead bites not being associated with angioedema, the levels of bradykinin were possibly increased, and angioedema developed. The patient had no reported previous episodes of angioedema and had been taking his ACEI for many years. While ACEI-associated angioedema can occur at any time, most cases occur within weeks of its initiation.

## CONCLUSION

In the setting of a crotalid envenomation in a patient on an ACE inhibitor, a delayed reaction may occur and should be included in patient education. In a patient on ACEI, extra vigilance may be warranted for the development of angioedema.

The Institutional Review Board approval has been documented and filed for publication of this case report.

---

*Address for Correspondence:* Christopher Scott Sampson, MD, University of Missouri School of Medicine, Department of Emergency Medicine, 1 Hospital Drive, Columbia, MO 65212. Email: sampsoncs@health.missouri.edu.

*Conflicts of Interest:* By the CPC-EM article submission agreement, all authors are required to disclose all affiliations, funding sources and financial or management relationships that could be perceived as potential sources of bias. The authors disclosed none.

*Copyright:* © 2023 Sampson et al. This is an open access article distributed in accordance with the terms of the Creative Commons Attribution (CC BY 4.0) License. See: <http://creativecommons.org/licenses/by/4.0/>

---

## REFERENCES

1. Jacobson AA, Raukar NP. Bites, Snake. Ferri's Clinical Advisor 2022. Elsevier 2022.
2. Lavonas EJ, Ruha AM, Banner W, et al. Unified treatment algorithm for the management of crotaline snakebite in the United States: results of an evidence-informed consensus workshop. *BMC Emerg Med.* 2011;11:2.
3. U.S. Food & Drug Administration. Package Insert-CroFab. Available at: <https://www.fda.gov/media/74683/download>. Accessed October 19, 2021.
4. Gerardo CJ, Quackenbush E, Lewis B, et al. The efficacy of Crotalidae polyvalent immune Fab (ovine) antivenom versus placebo plus optional rescue therapy on recovery from copperhead snake envenomation: a randomized, double-blind, placebo-controlled, Clinical Trial. *Ann Emerg Med.* 2017;70(2):233-44.e3.
5. Greene S, Cheng D, Vilke GM, et al. How should native Crotalid envenomation be managed in the emergency department? *J Emerg Med.* 2021;61(1):41-8.
6. Kleinschmidt K, Ruha AM, Campleman S, et al. Acute adverse events associated with the administration of Crotalidae polyvalent

- immune Fab antivenom within the North American Snakebite Registry. *Clin Toxicol (Phila)*. 2018;56(11):1115-20.
7. Lepak MR, Bochenek SH, Bush SP. Severe adverse drug reaction following Crotalidae Polyvalent Immune Fab (Ovine) administration for copperhead snakebite. *Ann Pharmacother*. 2015;49(1):145-9.
  8. Clark RF, McKinney PE, Chase PB, et al. Immediate and delayed allergic reactions to Crotalidae polyvalent immune Fab (ovine) antivenom. *Ann Emerg Med*. 2002;39(6):671-6.
  9. Bryan J. From snake venom to ACE inhibitor-the discovery and rise of captopril. 2009. Available at: <https://pharmaceutical-journal.com/article/news/from-snake-venom-to-ace-inhibitor-the-discovery-and-rise-of-captopril>. Accessed January 22, 2022.
  10. Svensson P, Rosenberg J, Ostergren J, et al. Potentieras ormgift av ACE-hämmare? Huggormsbett gav kraftig och långvarig hypotoni [Do ACE inhibitors potentiate snake venom? Severe and prolonged hypotension caused by adder bite]. *Lakartidningen*. 1993;90(32-33):2653-54.
  11. Kaufman MB. ACE inhibitor-related angioedema: are your patients at risk? *P T*. 2013;38(3):170-2.
  12. Wilkerson RG, Winters ME. Angiotensin-Converting Enzyme Inhibitor-Induced Angioedema. *Emerg Med Clin North Am*. 2022 Feb;40(1):79-98.

# Low-dose Fosphenytoin for Aborting Acute Trigeminal Neuralgia Pain: A Case Report

Jamie Baydoun, MD<sup>\*†</sup>  
Alexander Lin, MD<sup>\*†</sup>  
Jared Miya, MD<sup>\*†</sup>

\*University of Nevada Las Vegas School of Medicine, Department of Emergency Medicine, Las Vegas, Nevada

†University Medical Center of Southern Nevada, Department of Psychiatry and Behavioral Health, Las Vegas, Nevada

‡Sound Emergency Physicians, Department of Emergency Medicine, Las Vegas, Nevada

Section Editor: Christopher San Miguel, MD

Submission history: Submitted July 18, 2022; Revision received June 28, 2023; Accepted June 23, 2023

Electronically published August 9, 2023

Full text available through open access at [http://escholarship.org/uc/uciem\\_cpem](http://escholarship.org/uc/uciem_cpem)

DOI: 10.5811/cpcem.1603

**Introduction:** While the typical treatment for trigeminal neuralgia is carbamazepine, the dose must be gradually titrated over time to achieve pain control, which makes the drug a less than ideal candidate for treatment for acute exacerbation of pain due to trigeminal neuralgia in the emergency department (ED) setting. The literature for other effective treatments for acute exacerbations of trigeminal neuralgia is currently lacking. We discuss a case where intravenous (IV) fosphenytoin was used for treatment of acute pain due to trigeminal neuralgia in the ED.

**Case Report:** This is a case of a 35-year-old male diagnosed with trigeminal neuralgia who presented with acute facial pain. His history and physical exam were consistent with an acute exacerbation of his trigeminal neuralgia. The patient was refractory to multiple doses of standard pain medication in the ED, and the decision was made to attempt IV fosphenytoin to relieve his pain. He was given 250 milligrams of fosphenytoin that was infused via IV over 10 minutes. By the end of the infusion, the patient had reported complete resolution of his pain.

**Conclusion:** Fosphenytoin is a viable treatment option for pain relief in patients with acute exacerbation of trigeminal neuralgia. It may be a more favorable drug to use in the ED for acute pain given that carbamazepine must be titrated to effect. It is also possible that lower doses of fosphenytoin may provide equally beneficial analgesic effect than what is described in the literature, as pain relief was achieved in our case with approximately 3 milligrams/kilogram of fosphenytoin. [Clin Pract Cases Emerg Med. 2023;7(3):182–184.]

**Keywords:** *fosphenytoin; trigeminal neuralgia; emergency department management; case report.*

## INTRODUCTION

Trigeminal neuralgia (TN) is a rare condition with severe, debilitating symptoms that is best controlled quickly. Trigeminal neuralgia is divided into three classifications: primary, also referred to as classic, secondary, and idiopathic. Primary TN is thought to be caused by vascular compression of the nerve root at the pons, and secondary TN is caused by demyelinating diseases or mass effect and compression. The most effective medication described in the literature for maintenance of primary TN is carbamazepine.<sup>1-2</sup> Other

potential treatments include surgical decompression or local peripheral nerve block. Unfortunately, carbamazepine often needs to be titrated to alleviation of clinical symptoms over days to weeks, and this makes it a poor emergency department (ED) choice for abortion of acute TN flares.

## CASE REPORT

We report a case of a 35-year-old male diagnosed with trigeminal neuralgia eight months prior who presented with two days of intractable 10/10 left facial pain with radiation



from his jaw to his temple. This pain was exacerbated by clenching of his jaw and chewing. He described his pain as sharp and shooting, lasting only seconds, and consistently self-resolving. Over the two days prior to his ED visit, he had more frequent episodes of pain, and endorsed up to 30 episodes a day. His pain was refractory to multiple over-the-counter pain medications. The day of presentation he had six hours of near-constant clusters of severe shooting pain. His physical exam revealed normal vital signs, normal head, eyes, ears, nose, and throat exam except for hyperalgesia of his left face. Cranial nerves 2-12 were intact. He had normal speech, symmetric motor and sensation to all four extremities, and a normal gait. He had no meningismus upon examination of his neck.

In our ED, he was initially treated with a cocktail of ibuprofen, diphenhydramine, prochlorperazine, and one liter of normal saline. The patient had no resolution of symptoms 45 minutes after administration of this “migraine cocktail.” The history and physical exam were consistent with a trigeminal neuralgia crisis. To treat the patient’s neuropathic pain, he was given 250 milligrams (mg) of fosphenytoin that was infused intravenously (IV) over 10 minutes. At the end of the infusion, his pain had completely resolved. He was discharged with a neurology follow-up and a prescription for carbamazepine. Chart review six months after the patient was discharged did not show any other ED visits listed after discharge.

## DISCUSSION

Typical treatment for trigeminal neuralgia includes carbamazepine; however, the dose must be gradually increased to achieve pain control. There is currently a paucity of evidence regarding effective alternative treatments for acute exacerbations of TN. The American Academy of Neurology does not recommend, or refute, the use of any medication for acute TN.<sup>1</sup> The European Academy of Neurology suggests that opioids are ineffective for management of acute TN.<sup>2</sup>

The European Academy of Neurology guidelines do state that in acute exacerbations of TN IV infusions of fosphenytoin or lidocaine may be used as treatment methods. Furthermore, a systematic review by Moore et al. showed limited data suggesting that lidocaine, sumatriptan, phenytoin, or fosphenytoin could be effective rescue analgesic strategies in acute exacerbations of primary TN.<sup>3</sup> In a placebo-controlled crossover trial of 20 patients the administration of IV infusion of lidocaine at 5 mg/kilogram (kg) over one hour showed some relief in pain for up to 24 hours after infusion.<sup>4</sup> However, IV lidocaine administration requires continuous cardiac monitoring with electrocardiogram and frequent blood pressure checks. Another small, placebo-controlled crossover trial demonstrated that 3 mg subcutaneous injection of sumatriptan could provide improvement in pain relief. However, the mean duration of pain relief was only about eight hours in that study.<sup>5</sup>

### *CPC-EM Capsule*

What do we already know about this clinical entity?  
*The most effective medication for maintenance of trigeminal neuralgia is carbamazepine however, it often needs to be titrated over many days, making it a poor choice for aborting acute flares.*

What makes this presentation of disease reportable?  
*Literature for other effective treatments for acute trigeminal neuralgia flare is lacking. We discuss a case where fosphenytoin was used successfully for acute trigeminal neuralgia flares.*

What is the major learning point?  
*Fosphenytoin is a viable treatment option for pain relief in patients presenting to the emergency department (ED) with acute exacerbation of trigeminal neuralgia.*

How might this improve emergency medicine practice?  
*Fosphenytoin can be an effective option for aborting pain in acute trigeminal neuralgia pain due to its rapid onset of relief, low cost and wide availability in the ED.*

Fosphenytoin is a phosphate ester prodrug that is directly metabolized by plasma esterases to the active moiety phenytoin. Phenytoin is approved by the US Food and Drug Administration for seizures; however, off-label phenytoin use for neuropathic pain has been described in the literature.<sup>6</sup> Phenytoin is known to stabilize neuronal membranes by decreasing the influx of sodium ions, which in turn decreases the generation of nerve impulses.<sup>7</sup> Sodium channel blockade is the most likely mechanism of action by which phenytoin exerts its analgesic effect in trigeminal neuralgia.<sup>8</sup>

There are case reports and retrospective reviews demonstrating that fosphenytoin achieved significant pain control in patients with acute neuropathic and TN pain. McCleane was one of the first investigators to report the effectiveness of IV phenytoin as a treatment for neuropathic pain. In this double-blinded, placebo crossover study, patients with neuropathic pain were given either a placebo or 15 mg/kg of phenytoin. There was a significant reduction in burning pain ( $P<0.05$ ), shooting pain ( $P<0.001$ ), sensitivity ( $P<0.001$ ), and overall pain ( $P<0.005$ ).<sup>9</sup> While there were no cases of TN crisis in McCleane’s study, there have since been reports showing the effectiveness of IV fosphenytoin in acute TN pain crisis. Cheshire reported using IV fosphenytoin in three cases of acute TN with complete resolution of pain for two days, which allows for titration

of oral medications.<sup>10</sup> Another case report by Vargas and Thomas demonstrated an improvement of pain down to 2/10 after a 15 mg/kg dose of IV fosphenytoin.<sup>11</sup> A retrospective study performed by Schnell et al. in Argentina reviewed 73 IV fosphenytoin infusions for TN crisis. In this review 85% of cases had immediate relief, with 26% of patients experiencing adverse effects, with dizziness and nausea as the most common.<sup>12</sup>

Our patient received a much lower dose of fosphenytoin, roughly 3 mg/kg (250 mg total), than what has been described in the literature. We based this dose off recommendations in the tertiary drug reference Lexicomp, which lists fosphenytoin as an off-label use for rescue therapy for trigeminal neuralgia. The dose range listed was IV 250 mg-1 gram as a one-time dose or 15 mg/kg. We decided to opt for the lower end of dosing to potentially minimize adverse effects. In the Cheshire case series, interval dosing of fosphenytoin was used, starting at 100 mg with reassessment every 10 minutes for additional dosing.<sup>10</sup> Our plan was to use the lowest dose (250 mg) based on our drug reference in Lexicomp and then increase by 100 mg to a total of 1 gram as needed based on reassessment of symptoms every 10 minutes. Since our patient had resolution of symptoms and continued to be pain-free on multiple reassessments, we did not need to give additional doses. Our patient had complete resolution with just one 3 mg/kg dose of fosphenytoin, which suggests the analgesic effect of fosphenytoin in trigeminal neuralgia may be achieved with more conservative dosing. This is important to note given that hydantoins are known to have dose-dependent, life-threatening toxicities such as coma, seizures, hypotension, and bradyarrhythmias.

## CONCLUSION

In our case, the patient had complete alleviation of symptoms immediately after infusion of fosphenytoin. We believe fosphenytoin is an excellent treatment option for acute trigeminal neuralgia because it is available in most EDs, is reasonably priced, and has been shown in case studies and retrospective reviews to have rapid onset of relief for acute TN. We were able to use a lower dose of fosphenytoin to achieve pain relief in our patient's acute TN crisis. Randomized controlled trials should be performed to determine if and at what dose fosphenytoin is efficacious for treatment of acute trigeminal neuralgia pain crisis.

The authors attest that their institution requires neither Institutional Review Board approval, nor patient consent for publication of this case report. Documentation on file.

*Address for Correspondence:* Jamie Baydou, MD, UNLV School of Medicine, Department of Emergency Medicine, 901 Rancho Lane, Suite #135, Las Vegas, NV 89106. Email: meadejamie@gmail.com.

*Conflicts of Interest:* By the CPC-EM article submission agreement, all authors are required to disclose all affiliations, funding sources and financial or management relationships that could be perceived as potential sources of bias. The authors disclosed none.

*Copyright:* © 2023 Baydou et al. This is an open access article distributed in accordance with the terms of the Creative Commons Attribution (CC BY 4.0) License. See: <http://creativecommons.org/licenses/by/4.0/>

## REFERENCES

1. Cruccu G, Gronseth G, Alksne J, et al. AAN-EFNS guidelines on trigeminal neuralgia management. *Eur J Neurol.* 2008;15(10):1013-28.
2. Bendtsen L, Zakrzewska JM, Abbott J, et al. European Academy of Neurology guideline on trigeminal neuralgia. *Eur J Neurol.* 2019;26(6):831-49.
3. Moore D, Chong MS, Shetty A, et al. A systematic review of rescue analgesic strategies in acute exacerbations of primary trigeminal neuralgia. *Br J Anaesth.* 2019;123(2):385-96.
4. Stravropoulou E, Argyra E, Zis P, et al. The effect of intravenous lidocaine on trigeminal neuralgia: a randomized double blind placebo controlled trial. *ISRN Pain.* 2014;2014:853826:1-5.
5. Kanai A, Saito M, Hoka S. Subcutaneous sumatriptan for refractory trigeminal neuralgia. *Headache.* 2006;46:583-4.
6. McCleane GJ. Intravenous infusion of phenytoin relieves neuropathic pain: a randomized, double-blinded, placebo-controlled, crossover study. *Anesth Analg.* 1999;89(4):985-8.
7. Fischer JH, Patel TV, Fischer PA. Fosphenytoin: clinical pharmacokinetics and comparative advantages in the acute treatment of seizures. *Clin Pharmacokinet.* 2003;42(1):33-58.
8. Tate R, Rubin LM, Krajewski KC. Treatment of refractory trigeminal neuralgia with intravenous phenytoin. *Am J Health Syst Pharm.* 2011;68(21):2059-61.
9. McCleane GJ. Intravenous infusion of phenytoin relieves neuropathic pain: a randomized, double-blinded, placebo-controlled, crossover study. *Anesth Analg.* 1999;89(4):985-8.
10. Cheshire WP. Fosphenytoin: an intravenous option for the management of acute trigeminal neuralgia crisis. *J Pain Symptom Manage.* 2001;21(6):506-10.
11. Vargas A and Thomas K. Intravenous fosphenytoin for acute exacerbation of trigeminal neuralgia: case report and literature review. *Ther Adv Neurol Disord.* 2015;8(4):187-8.
12. Schnell S, Marrodan M, Acosta JN, et al. Trigeminal neuralgia crisis - intravenous phenytoin as acute rescue treatment. *Headache.* 2020;60(10):2247-53.

# Intracranial Hemorrhage and Facial Fractures After Nose Blowing and Sternutation: A Case Report

Cameron G. Hanson, DO  
Christopher Stewart, DO  
Keith Cronovich, DO

Henry Ford Health-Macomb, Department of Emergency Medicine, Clinton Township, Michigan

Section Editor: Christopher San Miguel, MD

Submission history: Submitted January 13, 2023; Revision received June 29, 2023; Accepted June 30, 2023

Electronically published August 4, 2023

Full text available through open access at [http://escholarship.org/uc/uciem\\_cpccem](http://escholarship.org/uc/uciem_cpccem)

DOI: 10.5811/cpcem.1588

**Introduction:** Blowing the nose and sneezing are ubiquitous physiologic processes. While exceedingly rare, traumatic injuries have been described. We detail a case of spontaneous intracranial hemorrhage and orbital fractures sustained as a result of these two phenomena in an otherwise healthy adult without known risk factors for bleeding or intracranial hemorrhage.

**Case Report:** A 79-year-old female presented to the emergency department after blowing her nose with an episode of sneezing following mild epistaxis. She denied any history of trauma, anticoagulation use, bleeding disorders, or pain associated with her symptoms. On examination, she had notable right periorbital swelling. Computed tomography revealed multiple areas of intracranial hemorrhage along with right-sided orbital and zygomatic fractures. After consulting trauma surgery and neurosurgery, we elected to pursue conservative management with repeat imaging. The patient had an uneventful course and was discharged with outpatient follow-up two days later.

**Conclusion:** To our knowledge, this is the first case described of this constellation of injuries after a relatively benign process. Despite not having increased risk factors for intracranial hemorrhage (anticoagulation use, history of trauma, history of coagulopathy), this patient had severe injuries that presented with few external symptoms. This case serves as a reminder that while physiologic processes are almost always benign, serious traumatic injuries can result. Clinicians should have a low threshold for advanced imaging when there is a high clinical suspicion of facial fractures or more ominous processes. [Clin Pract Cases Emerg Med. 2023;7(3):185–188.]

**Keywords:** *case report; intracranial hemorrhage; sneezing; blowing nose; orbital fracture.*

## INTRODUCTION

Sternutation, or sneezing, is the involuntary, forceful act of expelling irritants from the nasal passages, typically due to noxious stimuli. A universal phenomenon, sternutation is the result of an autonomically triggered event leading to a large pressure build-up in the intrathoracic cavity, followed by release of this pressure into the nasopharyngeal passages at up to 6 kilopascal, or one pound-force per square inch, of pressure with speeds up to 30–40 meters per second ( $\approx$ 70–90 miles per hour).<sup>1</sup> While this is a common reflex, associated injuries—although rare—have been documented. Injuries are often partially due to the large, pressure build-up effect on upper airway adjacent structures. Traumatic injuries, including orbital blowout fractures, have been reported after sneezing and nose blowing.<sup>2–5</sup>

Isolated neurologic cases have been rarely described. We detail a unique case of spontaneous subarachnoid hemorrhage (SAH), subdural hemorrhage, and unilateral orbital blow-out fracture after sternutation in an adult with no prior history of anticoagulation or coagulopathy. To our knowledge, this constellation is the first case of these multiple traumatic injuries after blowing the nose and sternutation.

## CASE REPORT

A 79-year-old female presented to the emergency department (ED) with chief complaint of periorbital edema. The patient stated she had been at a restaurant when she developed spontaneous right-sided epistaxis. Approximately five minutes after bleeding had started, she blew her nose, which led to one

episode of sternutation. Following this, her epistaxis had resolved, and she went to the bathroom where she noticed right-sided periorbital edema which prompted her to go to the ED. The patient denied any recent trauma, falls, prior injuries to the head or face, headache, or orbital pain. She had no history of oral anticoagulation use, including aspirin. She denied any history of known osteoporosis, coagulopathy, or bleeding disorders.

Review of systems was remarkable for right eye swelling; however, she denied any sinus pain, periorbital pain, or headaches. On physical examination, there was significant right-sided periorbital swelling without proptosis. There were no signs of periorbital ecchymosis. The patient’s head was atraumatic without abrasions, lacerations, or ecchymosis. Her neurologic exam, including cranial nerve exam testing, was unremarkable. She had notable pain with palpation to the superior orbital rim. There was dried blood from the nares bilaterally, with evidence of a small area of excoriation on the anterior septum on the right, but no active epistaxis. Lab testing, including basic metabolic panel, complete blood count, and coagulation studies, was unremarkable apart from an ethanol level of 100 milligrams/deciliter (mg/dL) (reference range: less than 80 mg/dL). [While we do not believe the patient’s alcohol intoxication played a significant role in her injury, it is a limitation to our report.]

Due to suspicion of orbital injury (including findings of periorbital swelling and bony orbit pain with palpation), the patient underwent computed tomography (CT) of the orbits without contrast. Imaging demonstrated multiple findings including a preseptal hematoma, along with an incomplete right zygomaticomaxillary complex fracture with preservation of the zygomatic arch. A buckle fracture of the lateral wall of the right orbit was also seen, with fractures of the right orbital floor and medial orbital wall without evidence of medial or inferior rectus entrapment [Image 1]. This fracture had propagation through the anterior lateral right maxillary sinus.

*CPC-EM Capsule*

What do we already know about this clinical entity?

*Traumatic injuries very rarely occur after a benign physiologic process such as sneezing.*

What makes this presentation of disease reportable?

*We describe a unique constellation of traumatic injuries, including orbital fractures and intracranial hemorrhage, after the patient blew her nose and sneezed.*

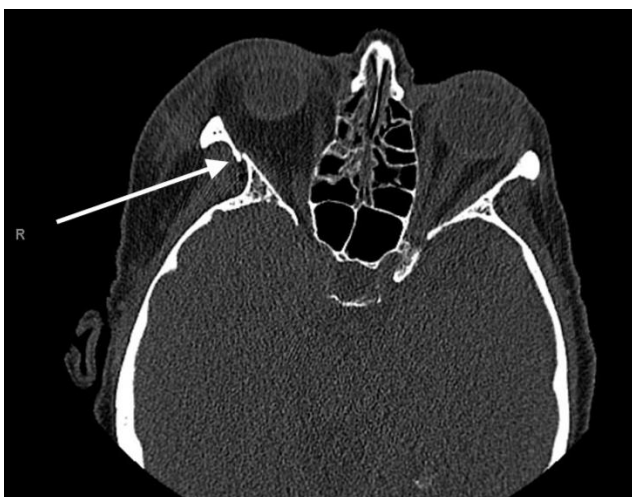What is the major learning point?

*Advanced imaging should be obtained when there are physical exam findings or symptoms concerning for traumatic injuries*

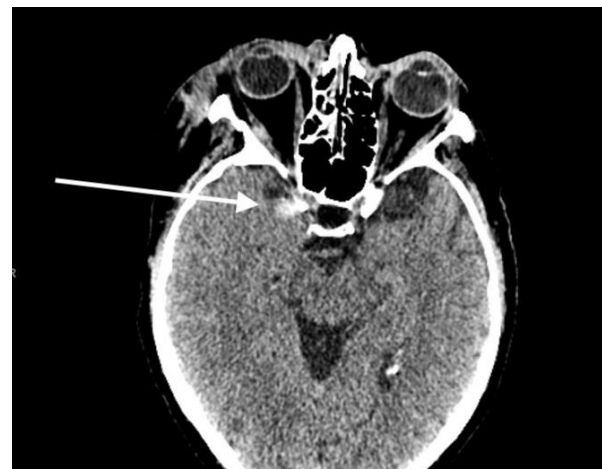How might this improve emergency medicine practice?

*By physical exam and clinical suspicion, emergency physicians may identify serious injuries despite a seemingly benign and ubiquitous process.*

A CT of the head without contrast was also performed, which was remarkable for small foci of SAH over the medial left frontal sulci. There was an additional area of SAH in the sulci of the right temporal parietal junction [Image 2]. Trauma surgery and neurosurgery were consulted and recommended admission with repeat CT in



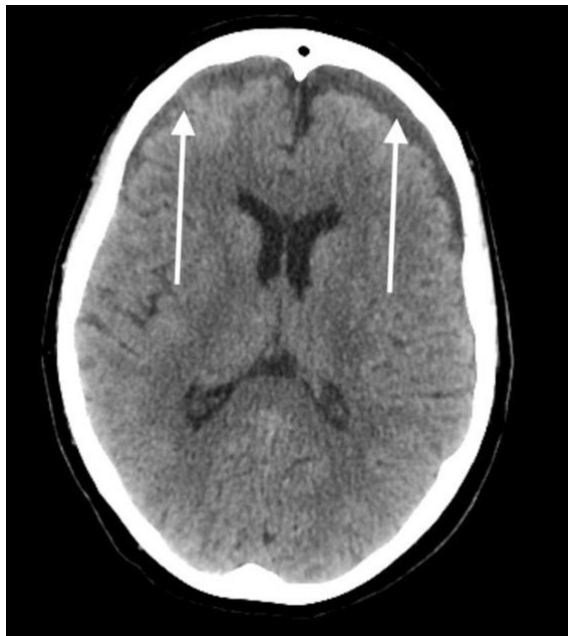**Image 1.** Computed tomography demonstrating right-sided, mildly displaced orbital wall fracture (arrow).



**Image 2.** Computer tomography of the head demonstrating foci of subarachnoid hemorrhage (arrow).



six hours. The following day, the patient's repeat CT head without contrast showed new bilateral subdural hematomas measuring eight millimeters (mm) on the frontal aspect on the right and seven mm on the left, and SAH in the left parietal lobe [Image 3].



**Image 3.** Computed tomography of the head demonstrating right and left subdural hematomas (arrows).

The patient remained stable without any neurologic complaints. Hematology work-up during her hospitalization was unremarkable. Two days following her initial presentation, repeat CT head showed stable findings with no increase in intracranial hemorrhage. Per neurosurgery recommendations, the patient was started on levetiracetam 500 mg twice daily for seven days, and she was subsequently discharged with instructions to follow up with plastic surgery regarding her orbital and facial fractures.

## DISCUSSION

Nose blowing and sternutation is a nearly universal physiologic function that can happen almost daily for a large portion of the population. While rare, traumatic injuries can be associated with this relatively benign process. In 2019 Setzen et al. reviewed 52 case reports of traumatic injuries associated with the act of sneezing.<sup>6</sup> The authors reported that of these case reports, 65% of patients did not have a prior risk factor for injury (i.e., prior trauma or infection). Of the injuries noted, 25% involved the orbit, including orbital fractures, and 17% involved the nervous system, although SAH and subdural hematoma were not noted in their review.

Our own review of the literature revealed one prior article documenting SAH after sneezing,<sup>7</sup> and one article describing a spontaneous subdural hematoma after sneezing.<sup>8</sup> In line with the review by Setzen et al., our review demonstrated that orbital injuries, including orbital fractures and orbital emphysema, were the most common traumatic injuries associated with blowing the nose and sneezing, with the latter being the most described. Neurologic complications were among the rarest injuries and pneumocephalus the most common,<sup>6,8,9</sup> but very few articles describe intracranial hemorrhage.

## CONCLUSION

Although the patient had evidence of potential orbital abnormalities prompting further imaging, had this not been present, along with her negative review of systems for associated symptoms (including headache) and lack of increased bleeding risk factors, clinical suspicion for subarachnoid hemorrhage or subdural hematoma may have been low. In this case, physical examination increased the suspicion for possible orbital wall fracture with focal tenderness on palpation around the right orbit, thus prompting a CT of the orbits, which confirmed the diagnosis of complex orbital wall fractures and intracranial blood. Our case demonstrates the extreme end of the spectrum with a constellation of traumatic injuries due to a natural and nearly universal phenomenon. This case report should serve as a reminder that while these physiological processes are ubiquitous and almost always benign, they can cause significant traumatic injuries. Advanced imaging should be obtained when there are physical exam findings or symptoms concerning for traumatic injuries.

The authors attest that their institution requires neither Institutional Review Board approval, nor patient consent for publication of this case report. Documentation on file.

*Address for Correspondence:* Cameron G. Hanson, DO, Henry Ford Health-Macomb, Department of Emergency Medicine, 15855 19 Mile Rd, Clinton Township, MI 48038. Email: chanson5@hfhs.org.

*Conflicts of Interest:* By the CPC-EM article submission agreement, all authors are required to disclose all affiliations, funding sources and financial or management relationships that could be perceived as potential sources of bias. The authors disclosed none.

*Copyright:* © 2023 Hanson et al. This is an open access article distributed in accordance with the terms of the Creative Commons Attribution (CC BY 4.0) License. See: <http://creativecommons.org/licenses/by/4.0/>

## REFERENCES

1. Rahiminejad M, Haghghi A, Dastan A, et al. Computer simulations of pressure and velocity fields in a human upper airway during

- sneezing. *Comput Biol Med.* 2016;71:115-27.
2. García de Marcos JA, del Castillo-Pardo de Vera JL, Calderón-Polanco J. Orbital floor fracture and emphysema after nose blowing. *Oral Maxillofac Surg.* 2008;12:163–5.
  3. Akyol PY, Erol Ünlüer EE, Oyar O, et al. An unexpected complication of sneezing: blow-out orbital fracture. *J. Emerg Trauma Shock.* 2015;8(3):172.
  4. Roselle HA and Herman M. A hearty sneeze. *Lancet.* 2010;376(9755):1872.
  5. Chiu TW, Chung CK, Chan SH, et al. Sneezing and orbital fracture. *Plast Reconst Surg.* 2006;117(3):1049-50.
  6. Setzen S and Platt M. The dangers of sneezing: a review of injuries. *Am J Rhinol Allergy.* 2019;33(3):331-7.
  7. Ali Zohair Nomani, Haris Majid Rajput, Mansoor Iqbal, et al. Subarachnoid hemorrhage secondary to forceful sneeze. *Case Rep Neurol Med.* 2015;(2015):5.
  8. Wu Y-H, Yeh I-J, Liu K-T. Spontaneous pneumocephalus and subdural hemorrhage after sneezing. *Am J Emerg Med.* 2018;36(10).
  9. Cancelliere A. Nothing to sneeze at: tension pneumocephalus causing an acute stroke following endoscopic sinus surgery. *JECCM.* 2019;3:16.

# Shone Complex: A Case Report of Congenital Heart Disease Detected Using Point-of-care Ultrasound

Jordan C. Seaback, MD  
David A. Masner, DO  
Jacob H. Schoeneck, MD

Atrium Health Wake Forest Baptist, Department of Emergency Medicine, Winston Salem, North Carolina

Section Editor: Christopher San Miguel, MD

Submission history: Submitted April 13, 2023; Revision received July 6, 2023; Accepted June 30, 2023

Electronically published August 9, 2023

Full text available through open access at [http://escholarship.org/uc/uciem\\_cpem](http://escholarship.org/uc/uciem_cpem)

DOI: 10.5811/cpcem.1319

**Introduction:** Undiagnosed congenital heart disease and management of pediatric cardiogenic shock presents a diagnostic challenge for the emergency clinician. These diagnoses are rare and require a high index of suspicion given the overlap with more common pediatric pathology. Point-of-care ultrasound can assist in differentiating these presentations. We present a case of neonatal cardiogenic shock secondary to a previously undiagnosed congenital heart disease, specifically Shone complex, detected using point-of-care ultrasound.

**Case Report:** A six-week-old female presented with severe respiratory distress and was found to be in cardiogenic shock secondary to a previously undiagnosed congenital heart defect.

**Conclusion:** Initial diagnosis of congenital heart disease is uncommon in the emergency department, but it should be recognized by clinicians given the high associated morbidity and mortality. Point-of-care ultrasound is a powerful tool to assist in evaluating for cardiac abnormalities as an etiology for undifferentiated shock in the pediatric population. [Clin Pract Cases Emerg Med. 2023;7(3):189–192.]

**Keywords:** *case report; Shone complex; point-of-care ultrasound; cardiogenic shock; congenital heart disease.*

## INTRODUCTION

Congenital anomalies are the leading cause of infant mortality in the United States with congenital heart disease accounting for 30-50% of these deaths.<sup>1</sup> Despite advances in prenatal ultrasound screening, detection of congenital heart disease is missed in approximately half of cases. National screening programs in several developed countries have reported detection rates of only 30-60%.<sup>2</sup> While ED presentation of an undiagnosed congenital heart disease is rare, this diagnosis must be considered. Patient presentations can vary substantially and include nonspecific complaints such as respiratory distress, lethargy, failure to thrive and, rarely, cardiogenic shock.<sup>3</sup>

Early use of point-of-care ultrasound in this patient population can provide invaluable information for the emergency clinician. Our case highlights the utility of

point-of-care ultrasound to identify a previously undiagnosed congenital heart defect in a neonate presenting in cardiogenic shock. Specifically, our case highlights Shone complex, a rare congenital heart disease comprised of four left-sided heart defects including a parachute mitral valve, subaortic stenosis, a supra-annular mitral ring, and coarctation of the aorta.<sup>4</sup>

## CASE REPORT

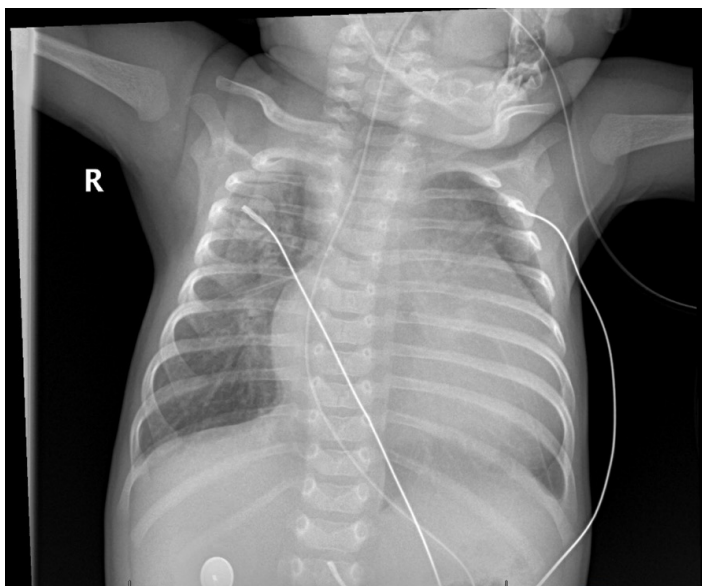
A six-week-old female presented to our ED via ambulance from her pediatrician's office for respiratory distress. She had no known past medical history and was born at 38 weeks via induced vaginal delivery with routine prenatal care. Her mother described a history of increased work of breathing, wheezing, and grunting respirations since birth, which had noticeably worsened in the prior week. The

patient had mild associated congestion and rhinorrhea, but her mother denied other infectious symptoms. At the pediatrician's office, the patient was found to have an oxygen saturation of 70% and was placed on a non-rebreather with minimal improvement.

Her initial vital signs on arrival to the ED showed hypothermia with a temperature of 35.2° Celsius, a tachycardic heart rate of 169 beats per minute, tachypnea with a respiratory rate of 50 breaths per minute, and persistent hypoxia at 68% despite oxygenation by non-rebreather. Obtaining an accurate blood pressure was challenging, but the highest measurement was 38/23 millimeters of mercury. Physical examination was notable for an ill-appearing, mottled, neonatal female. Her heart and lung sounds were diminished on auscultation, with diffuse rales that were more prominent in the right lung. She was noted to have absent femoral pulses.

Given the patient's poor oxygen saturation and increased work of breathing, she was transitioned to high-flow nasal cannula. A chest radiograph was obtained and demonstrated cardiomegaly with pulmonary interstitial edema (Image 1).

Focused point-of-care echocardiography was performed, which showed poor left ventricular contractility with an ejection fraction visually estimated to be less than 15%, restricted motion of the mitral valve leaflets with abnormal valve morphology, and a mitral regurgitation jet (Image 2 and Video). These findings raised the concern for cardiogenic shock secondary to a previously undiagnosed congenital heart defect. An epinephrine infusion was started to provide inotropic support with improvement in the patient's blood pressure.



**Image 1.** Chest radiograph demonstrating cardiomegaly and interstitial prominence suggestive of pulmonary edema.

### *CPC-EM Capsule*

What do we already know about this clinical entity?

*Undiagnosed congenital heart disease can be a diagnostic challenge given the overlap with more common pediatric pathology.*

What makes this presentation of disease reportable?

*Cardiogenic shock from an undiagnosed congenital heart disease such as Shone complex is a rare but important consideration in the undifferentiated sick neonate.*

What is the major learning point?

*Point-of-care ultrasound is a powerful tool to assist in evaluating for cardiac abnormalities as an etiology for undifferentiated shock in the pediatric population.*

How might this improve emergency medicine practice?

*Point-of-care ultrasound in the sick pediatric patient can provide real-time diagnostic information and facilitate early collaboration with consultants.*

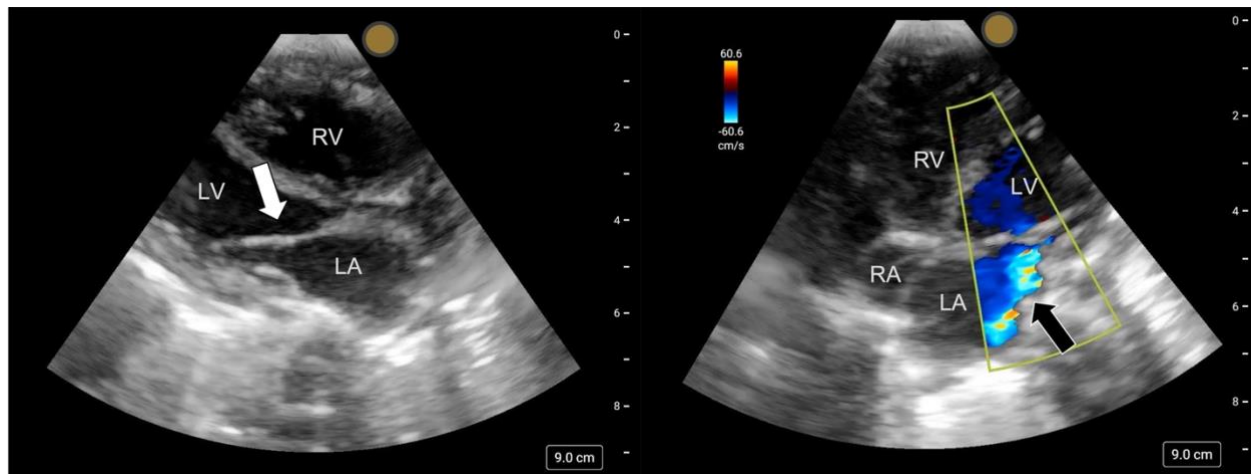
Ultimately her oxygenation and work of breathing failed to improve on high-flow nasal cannula, and she was intubated. Fentanyl was given for induction and sedation, but paralytics were avoided to ensure preservation of her respiratory drive.

Cardiology was consulted and a complete echocardiogram was performed, which confirmed the diagnosis of congenital heart disease, more specifically an incomplete Shone complex. We considered initiation of alprostadil in case of a ductal-dependent lesion, and this was eventually administered after transfer to the pediatric intensive care unit. Her clinical course was complicated by significant end-organ damage including acute renal failure requiring continuous renal replacement therapy and seizures. She underwent coarctation repair several days later, which she tolerated well. Her ejection fraction, renal failure, and seizures improved, and she was discharged home one month after admission.

### **DISCUSSION**

Shone complex is a rare congenital heart disease comprising four left-sided heart defects including a parachute mitral valve, subaortic stenosis, a supravulvar





**Image 2.** Parasternal long axis (left) depicting restricted movement and abnormal morphology of the anterior mitral valve leaflet (white arrow). Apical four chamber (right) with visualization of the left atrium (LA), left ventricle (LV), right atrium (RA), and right ventricle (RV) with a mitral regurgitation jet on color flow Doppler (black arrow).

mitral ring, and coarctation of the aorta. It is estimated that Shone complex comprises 0.6-0.7% of all congenital heart disease.<sup>5-7</sup> If all four defects are present, the complex is termed “complete,” although the majority of cases have three or fewer defects present and are considered “incomplete.”<sup>4,5</sup> Several other congenital heart defects are frequently associated with Shone complex including bicuspid aortic valve, atrial and ventricular septal defects, patent ductus arteriosus, and interrupted aortic arch.<sup>7</sup> The degree of mitral valve obstruction in Shone complex correlates with a poor prognosis and earlier onset of symptoms. Symptoms can be non-specific including dyspnea, cough, failure to thrive, poor feeding, lethargy, wheezing, and recurrent respiratory tract infections. Long-term prognosis is generally poor with many patients requiring multiple surgeries and ultimately heart transplantation.<sup>8</sup>

While the definitive diagnosis of Shone complex is well outside the scope of point-of-care ultrasound, some defining sonographic abnormalities can be striking and readily appreciated. Our point-of-care echocardiography was performed using the phased array probe placed in the standard positioning. There are no differences in probe placement between the adult and pediatric populations. The “parachute” shape of the mitral valve has a distinct sonographic appearance and may markedly restrict the movement of the valve leaflets, which is easily appreciated on dynamic imaging (Image 2 and Video). Mitral insufficiency and regurgitation can be visualized with color Doppler in the apical four-chamber view. The diagnosis of subaortic stenosis is more complicated requiring measurement of post-stenotic flow velocities. Views of the aortic arch and descending aorta can be obtained with the probe placed in the suprasternal notch, although the diagnosis of aortic coarctation is challenging and requires

excellent visualization for accurate measurements and Doppler evaluation.<sup>7</sup>

In our case, a previously healthy six-week-old with reported routine prenatal care presented in decompensated cardiogenic shock. She was ultimately found to have an incomplete form of Shone complex with a bicuspid aortic valve, a parachute mitral valve, and critical postductal coarctation of the aorta. She did not have subaortic stenosis or a supravalvular mitral ring. Her case proved to be a diagnostic challenge as we began with a working diagnosis of bronchiolitis, prompting the initiation of high-flow nasal cannula. We additionally considered sepsis, toxin-mediated, congenital metabolic disorders, and non-accidental trauma as other etiologies for her decompensation.

The cardiomegaly and interstitial prominence on her chest radiograph initially raised our concern for underlying heart failure. However, the chest radiograph alone did not provide enough diagnostic information for proper management. In the acute setting, the anatomic, physiological, and hemodynamic information that functional echocardiography provides can be used in targeting specific interventions and evaluating response to treatment.<sup>9</sup> Point-of-care ultrasound enabled us to assess for additional causes of cardiomegaly, including pericardial effusions and cardiac tamponade, which would have substantially changed our management. Ultimately, POCUS revealed severe cardiac anomalies that facilitated early consultation and collaboration with our pediatric cardiologists.

In general, pediatric cardiogenic shock with left ventricular systolic failure, such as in Shone complex, is managed with inotropes to increase contractility and reduce afterload. Diuretics may also be used to decrease both pulmonary vascular congestion and preload.<sup>10</sup> Diuretics were not indicated in the acute management of our patient in

extremis and were not recommended by our cardiology colleagues. Clinicians may also consider prostaglandins such as alprostadil in the case of a ductal-dependent lesion. However, this should only be given in conjunction with cardiology consultation, as side effects of this medication can be profound and include worsening hypotension and apnea.<sup>11</sup>

The decision to intubate congenital heart patients is debated given the risk of decreasing preload and worsening cardiac output. In severe cases, intubation and positive-pressure ventilation may assist in decreasing left ventricular transmural pressure and afterload as well as the metabolic demands of respiratory muscles. Our decision to proceed with intubation was made in conjunction with our pediatric intensivists and cardiology colleagues as sedation and intubation can cause rapid deterioration in which mechanical cardiac support may be needed.<sup>10</sup> Prior to intubation we started an epinephrine infusion for inotropic support and used fentanyl only for sedation without paralytics to ensure preservation of the patient's respiratory drive.

## CONCLUSION

Delayed diagnosis of congenital heart disease is rare but carries a high risk of morbidity and mortality. These cases can be diagnostic challenges given that heart failure and cardiogenic shock is rare in the pediatric and neonatal population. Symptoms can also overlap with more common conditions including bronchiolitis or pneumonia. Emergency physicians should be aware of these lesions and the role of point-of-care ultrasound to assist with diagnosis.

**Video.** Narrated video describing the chest radiograph with cardiomegaly and pulmonary interstitial edema. Video clip of the point-of-care parasternal long-axis view demonstrates abnormal mitral valve morphology with tethering and restricted motion of the mitral valve leaflet (white arrow). Point-of-care apical four-chamber view demonstrates color flow Doppler with a mitral regurgitant jet (white arrow). In the final clips, a cardiology-performed echocardiogram in the parasternal long-axis and short-axis views reveal a "parachute" mitral valve (white arrow) and bicuspid aortic valve (white arrow), respectively. The suprasternal aortic view reveals coarctation of the aorta (white arrow).

Patient consent was obtained for the publication of this case report. Documentation on file.

*Address for Correspondence:* Jordan C. Seaback, MD, Atrium Health Wake Forest Baptist, Department of Emergency Medicine, Medical Center Boulevard, Winston Salem, NC 27157. Email: [jcausey@wakehealth.edu](mailto:jcausey@wakehealth.edu).

*Conflicts of Interest:* By the *CPC-EM* article submission agreement, all authors are required to disclose all affiliations, funding sources and financial or management relationships that could be perceived as potential sources of bias. The authors disclosed none.

*Copyright:* © 2023 Seaback et al. This is an open access article distributed in accordance with the terms of the Creative Commons Attribution ([CC BY 4.0](https://creativecommons.org/licenses/by/4.0/)) License. See: <http://creativecommons.org/licenses/by/4.0/>

## REFERENCES

1. Copel J. *Congenital Heart Disease: Prenatal Screening, Diagnosis, and Management*. UpToDate, Post TW (Ed) Available at: <https://www.uptodate.com/contents/congenital-heart-disease-prenatal-screening-diagnosis-and-management>. Accessed August 17, 2022.
2. van Nesselrooij AEL, Teunissen AKK, Clur SA, et al. Why are congenital heart defects being missed? *Ultrasound Obstet Gynecol*. 2020;55(6):747-7.
3. Fisher JD, Bechtel RJ, Siddiqui KN, et al. Clinical spectrum of previously undiagnosed pediatric cardiac disease. *Am J Emerg Med*. 2019;37(5):933-6.
4. Zhang X, Ma G, Zheng L, et al. Echocardiographic diagnosis of Shone's syndrome. *Echocardiography*. 2020;37(12):2139-43.
5. True A, Baidya M, Lui C, et al. Computed tomography imaging characteristics of shone syndrome. *Radiol Case Rep*. 2019;14(2):164-7.
6. Aslam S, Khairy P, Shohoudi A, et al. Shone complex: an under-recognized congenital heart disease with substantial morbidity in adulthood. *Can J Cardiol*. 2017;33(2):253-9.
7. Li YD, Meng H, Pang KJ, et al. Echocardiography in the diagnosis of Shone's complex and analysis of the causes for missed diagnosis and misdiagnosis. *World J Clin Cases*. 2022;10(11):3369-78.
8. Brauner RA, Laks H, Drinkwater DC, et al. Multiple left heart obstructions (Shone's anomaly) with mitral valve involvement: long-term surgical outcome. *Ann Thorac Surg*. 1997;64(3):721-9.
9. Tissot C and Singh Y. Neonatal functional echocardiography. *Curr Opin Pediatr*. 2020;32(2):235-44.
10. Migally K and McBride ME. Cardiogenic shock beyond the neonatal period. *Clin Pediatr Emerg Med*. 2018;19(4):345-52.
11. Strobel AM and Lu LN. The critically ill infant with congenital heart disease. *Emerg Med Clin North Am*. 2015;33(3):501-18.

# Spontaneous Coronary Sinus Thrombosis Detected by Point-of-care Transthoracic Echo: A Case Report

Lily Leitner Berrin, MD\*

Kaitlen Howell, MD\*

Amanda Foote, MD<sup>†</sup>

Jordan Mullings, MD, MBA\*

Akash Desai, MD\*

Martha Montgomery, MD, MS\*

Sophie Barbant, MD<sup>‡</sup>

Arun Nagdev, MD\*

\*Highland Hospital, Alameda Health System, Department of Emergency Medicine, Oakland, California

<sup>†</sup>University of California San Francisco, Department of Emergency Medicine, San Francisco, California

<sup>‡</sup>Highland Hospital, Alameda Health System, Department of Cardiology, Oakland, California

Section Editor: Jacqueline Le, MD

Submission history: Submitted February 4, 2023; Revision received June 22, 2023; Accepted June 23, 2023

Electronically published August 4, 2023

Full text available through open access at [http://escholarship.org/uc/uciem\\_cpccm](http://escholarship.org/uc/uciem_cpccm)

DOI: 10.5811/cpcem.1590

**Introduction:** Coronary sinus thrombosis (CST) is a rare condition, primarily occurring after instrumentation of the heart, with no prior reported cases diagnosed via point-of-care ultrasound or of spontaneous occurrence without predisposing medical or surgical history. Patients typically present with critical illness, and CST has a reported mortality of 80%.

**Case Report:** We present a case of a healthy 38-year-old male with chest pain one hour after cocaine use, with an electrocardiogram pattern consistent with Wellens syndrome, whose point-of-care cardiac ultrasound revealed CST.

**Conclusion:** This uncommon ultrasonographic finding has never been reported in the emergency medicine literature to our knowledge. It can be recognized by the clinician sonographer during standard point-of-care transthoracic echocardiogram. [Clin Pract Cases Emerg Med. 2023;7(3):193–196.]

**Keywords:** *Case report; POCUS; TTE; coronary sinus thrombosis; ECG.*

## INTRODUCTION

Coronary sinus thrombosis (CST) refers to clot formation within the blood vessel that drains most of the coronary arteries' deoxygenated blood. This vessel travels posterior to the junction of the left atrium and left ventricle before emptying directly into the right atrium. Coronary sinus thrombosis occurs as a rare complication of intracardiac instrumentation and very rarely due to infective endocarditis, congenital structural abnormalities, myocardial infarction, or prothrombotic states, with no previously reported cases occurring without predisposing medical or surgical history or in the setting of substance use.<sup>1</sup> Patients typically present with critical illness and have a poor prognosis, with a reported mortality of 80%.<sup>2</sup> Here we describe a case of CST detected by point-of-care ultrasound (POCUS) in a previously healthy, 38-year-old male presenting with chest pain within hours of cocaine and heroin use, associated with a Wellens pattern on electrocardiogram (ECG).<sup>3</sup>

## CASE REPORT

A 38-year-old male with a past medical history only of substance use disorder presented to the emergency department (ED) 20 minutes following intranasal stimulant use. The patient complained of severe chest pain that was sudden in onset, non-exertional, and non-radiating. He also reported mild shortness of breath and anxiety. Prehospital responders noted initial relief of his chest pain and shortness of breath following administration of 325 milligrams (mg) of aspirin and 0.4 mg of sublingual nitroglycerin, but the pain returned upon arrival to the ED. The patient's initial vital signs at time of presentation included a blood pressure of 156/108 millimeters of mercury (mmHg), heart rate of 79 beats per minute, respiratory rate of 18 breaths per minute, and oxygen saturation of 100% on room air. Upon arrival, the patient reported chest pain and fatigue and denied any other symptoms. He also denied any family history of cardiac disease.

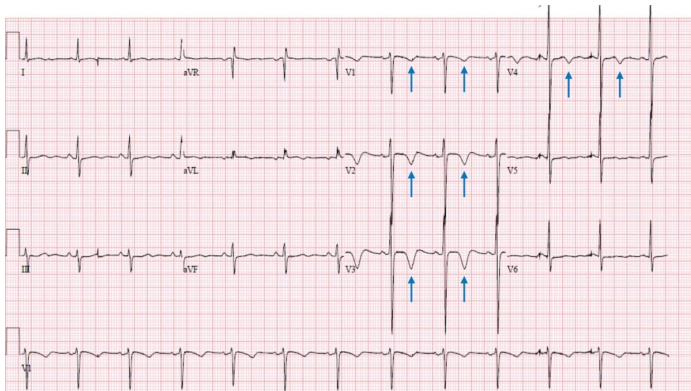On physical examination, the patient appeared drowsy and had symmetrically small but not pinpoint, equally round and reactive pupils. Cardiopulmonary exam and complete physical examination were unremarkable. The emergency clinician obtained an ECG, chest radiograph, troponin level, complete blood count, comprehensive metabolic panel, and a bedside transthoracic echocardiogram (TTE) to guide medical management. The initial electrocardiogram ECG (Image 1) revealed deep and symmetric T-wave inversions in leads V1-V4, with no Q-waves, normal R-wave progression, and no ST-segment elevations, concerning for Wellens syndrome.

A cardiology consultation was initiated, and point-of-care TTE was then performed by emergency clinicians at point of care. On parasternal long view, a circular, hyperechoic focus was noted posterior to the left atrium, at the location of the coronary sinus (Image 2A). This can be compared to a parasternal long TTE view with a normal coronary sinus (Image 2B). There were no signs of systolic or diastolic dysfunction, no noted pericardial effusion, and the size of the atria and ventricles were within normal limits. At the time the echo was completed, the patient was resting comfortably in the gurney without chest pain.

Results from the patient's blood tests came back unremarkable, including a normal troponin. Urine toxicology screen was positive for cocaine and opioids and negative for amphetamines. A chest radiograph was within normal limits. A comprehensive echocardiogram was subsequently performed and confirmed the diagnosis of CST. Because the patient was pain free, hemodynamically stable, and with negative serial troponins, cardiology recommended inpatient monitoring and anticoagulation, and did not recommend clot retrieval.

## DISCUSSION

The occurrence of CST is exceedingly rare. Most instances occur as a complication of right heart instrumentation, infective endocarditis, hypercoagulable



**Image 1.** Initial echocardiogram with deep and symmetric T-wave inversions in leads V1-V4 (blue arrows), with no Q-waves, normal R-wave progression, and no ST-segment elevations, concerning for Wellens syndrome.

## CPC-EM Capsule

What do we already know about this clinical entity?

*Coronary sinus thrombosis (CST) is a rare condition primarily occurring after instrumentation of the heart, with an 80% mortality rate.*

What makes this presentation of disease reportable?

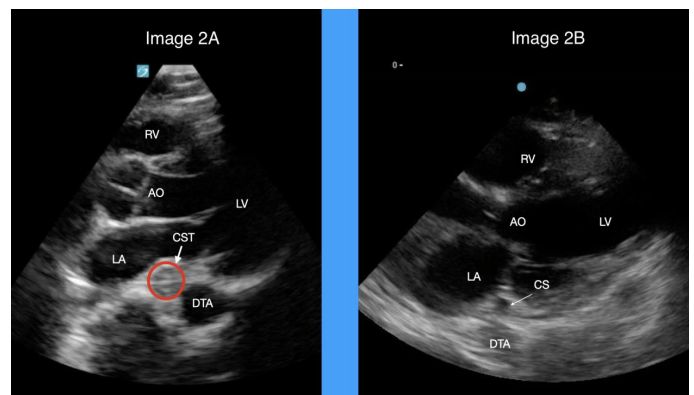
*This is the first report of CST detected via point-of-care-ultrasound (POCUS) in a patient with no predisposing history but with recent cocaine use.*

What is the major learning point?

*Point-of-care-ultrasound is a valuable bedside tool that can detect rare conditions and track a dynamic pathologic process such as CST.*

How might this improve emergency medicine practice?

*Subtle abnormalities on POCUS can suggest possible uncommon pathological conditions. Combined with consultative echocardiography it can be useful in difficult cases.*



**Image 2.** (A) Initial parasternal long-axis view of patient with coronary sinus thrombosis (CST); (B) normal coronary sinus (CS) with anatomic labels. LA, left atrium, LV, left ventricle, AO, aortic outflow; RV, right ventricle; DTA, descending thoracic aorta.

states, or congenital malformation.<sup>4</sup> This is the first reported case of CST detected by POCUS in an ED setting.

While cocaine is classically associated with coronary artery vasospasm and arrhythmia, its thrombogenic effects can be just



as lethal.<sup>5,6</sup> Cocaine induces a prothrombotic state by promoting platelet activity and aggregation, increasing clotting factor concentrations, and inhibiting thrombolysis.<sup>7</sup> Previous reports discuss various cocaine-induced thromboses including deep vein thrombosis and pulmonary embolism, myocardial infarction from intracoronary thrombus despite normal coronary arteries, and floating aortic arch thrombus.<sup>8-10</sup> Our case suggests CST may similarly be triggered by cocaine use.

Coronary sinus thrombosis may be acute or chronic and typically presents as a severe condition, with signs and symptoms including chest pain, shortness of breath, and hypotension.<sup>4</sup> Secondary complications of CST may include pericardial effusion, cardiogenic shock, or even sudden cardiac death.<sup>4,11</sup> More insidious presentations, including entirely asymptomatic cases, have been reported in partial or incomplete thrombus formation. Most often, CST is reported to be a fatal condition, with most cases identified via autopsy.<sup>4</sup> Remarkably, the patient we present was well-appearing and hemodynamically stable, with resolved chest pain at the time POCUS echocardiography demonstrated CST. It is possible that CST is underdiagnosed in stable patients presenting with chest pain who are discharged from the ED and do not receive comprehensive echocardiography during their evaluation, highlighting the importance of POCUS and awareness of this sonographic diagnosis.

To date, POCUS has not been a common diagnostic tool for CST; in fact, we were unable to identify any prior published reports of point-of-care imaging used to diagnose CST. Previously, CST has been diagnosed using comprehensive echocardiography from either a transthoracic or transesophageal approach, with transesophageal views being more sensitive. Unlike comprehensive echocardiography performed by ultrasound technologists, POCUS allows for easy serial sonographic evaluation. Our consulting cardiologist reviewed and found dynamic changes between the initial POCUS study, a comprehensive echocardiogram obtained two hours later, and a repeat POCUS performed approximately four hours after the initial one. While the first images showed complete occlusion of the coronary sinus, the comprehensive study showed a slightly smaller thrombus with some flow present around the thrombus on color Doppler. The images obtained at four hours showed an even smaller thrombus within the coronary sinus. These progressive findings over hours may have increased the likelihood of this patient's CST being related to his reported substance use that same day.

Dynamic ECG changes such as ST-segment elevations and left axis deviation can be found in acute CST, most likely due to increased myocardial perfusion pressure and decreased coronary artery blood flow leading to acute ischemia of the myocardium.<sup>4,12</sup> To our knowledge, this is the first reported case of Wellens pattern associated with acute CST. However, it should be noted that the Wellens pattern on ECG may have been due to the patient's recent cocaine use, independent of the CST.

There are no current guidelines for the management of CST, and treatment has varied by case given the rarity of the

condition.<sup>4,13</sup> Treatment options include interventional management with thrombectomy and medical management with anticoagulation. Thrombectomy followed by heparin as a bridge to warfarin therapy has been previously documented when a patient is critically ill or unstable.<sup>14</sup> Other case reports include the use of low-molecular-weight heparin as a bridge to warfarin therapy or the use of novel anticoagulants, without clot retrieval, in clinically stable patients.<sup>2</sup>

In a case report detailing CST as a complication of ventricular free-wall rupture following a myocardial infarction, the risk of hemorrhage into the pericardium was deemed too great, and the patient was managed without anticoagulation, ultimately doing well with conservative management.<sup>15</sup> The morbidity and mortality benefits of these varied approaches have not yet been established in the literature, and further clinical studies are needed. Ultimately, our patient was discharged on rivaroxaban after a short and uncomplicated hospital stay, with recommended repeat TTE in two months.

## CONCLUSION

Coronary sinus thrombosis is a rare condition that has never before been reported as detected by POCUS. Classically, point-of-care TTE is used for the assessment of gross left ventricular systolic function, detection of a pericardial effusion, and evaluation for right heart strain. As clinicians become more comfortable with performing these evaluations, other subtle and less common findings will be detected. Point-of-care ultrasound is a valuable bedside assessment tool for patients with chest pain and ECG changes and can be used to track a dynamic pathologic process such as CST. As in our case, the ECG pattern, along with the detection of a hyperechoic lesion in the location of the coronary sinus, triggered specialist consultation, comprehensive TTE, and therapeutic intervention.

The author attests that neither IRB Approval, nor patient consent is required for the publication of this case report. Documentation on file.

---

*Address for Correspondence:* Lily Berrin, MD, Highland Hospital, Department of Emergency Medicine, 1411 East 31<sup>st</sup> St, Oakland, CA 94602. Email: lilyberrin@gmail.com.

*Conflicts of Interest:* By the CPC-EM article submission agreement, all authors are required to disclose all affiliations, funding sources and financial or management relationships that could be perceived as potential sources of bias. Dr. Arun Nagdev is a salaried employee of Exo Inc. The authors disclosed no conflicts of interest.

*Copyright:* © 2023 Berrin et al. This is an open access article distributed in accordance with the terms of the Creative Commons Attribution (CC BY 4.0) License. See: <http://creativecommons.org/licenses/by/4.0/>

---

## REFERENCES

1. Bapat VN, Hardikar AA, Porwal MM, et al. Coronary sinus thrombosis after cannulation during cardiopulmonary bypass. *Ann Thorac Surg.* 1996;62(5):1506-7.
2. Milligan G and Moscona JC. Coronary sinus thrombosis: echocardiographic visualization in a patient with known risk factors. *J Clin Ultrasound JCU.* 2018;46(8):555-7.
3. de Zwaan C, Bär FW, Wellens HJ. Characteristic electrocardiographic pattern indicating a critical stenosis high in left anterior descending coronary artery in patients admitted because of impending myocardial infarction. *Am Heart J.* 1982;103(4 Pt 2):730-6.
4. Masood W and Sitammagari KK. Coronary sinus thrombosis. Available at: <http://www.ncbi.nlm.nih.gov/books/NBK507806/>. Accessed January 24, 2023.
5. Wilson RE, Kado HS, Samson R, et al. A case of caffeine-induced coronary artery vasospasm of a 17-year-old male. *Cardiovasc Toxicol.* 2012;12(2):175-9.
6. Matta A, Bouisset F, Lhermusier T, et al. Coronary artery spasm: new insights. *J Intervent Cardiol.* 2020;2020:5894586.
7. Havakuk O, Rezkalla SH, Kloner RA. The cardiovascular effects of cocaine. *J Am Coll Cardiol.* 2017;70(1):101-13.
8. Minor RL, Scott BD, Brown DD, et al. Cocaine-induced myocardial infarction in patients with normal coronary arteries. *Ann Intern Med.* 1991;115(10):797-806.
9. Toudou-Daouda M, Ouanounou G, Aghasaryan M, et al. Floating aortic arch thrombus involving the left common carotid artery complicated with ischemic stroke associated with cocaine use. *Neurol Sci Off J Ital Neurol Soc Ital Soc Clin Neurophysiol.* 2022;43(9):5629-32.
10. Sharma T, Kumar M, Rizkallah A, et al. Cocaine-induced thrombosis: review of predisposing factors, potential mechanisms, and clinical consequences with a striking case report. *Cureus.* 2019;11(5):e4700.
11. Kachalia A, Sideras P, Javaid M, et al. Extreme clinical presentations of venous stasis: coronary sinus thrombosis. *J Assoc Physicians India.* 2013;61(11):841-3.
12. Yeo KK, Davenport J, Raff G, et al. Life-threatening coronary sinus thrombosis following catheter ablation: case report and review of literature. *Cardiovasc Revascularization Med Mol Interv.* 2010;11(4):262.e1-5.
13. Mararenko A, Alshami A, Ajam F, et al. Coronary sinus thrombosis in a patient without history of endothelial cardiac injury. *J Med Cases.* 2021;12(9):355-8.
14. Neri E, Tripodi A, Tucci E, et al. Dramatic improvement of LV function after coronary sinus thromboembolectomy. *Ann Thorac Surg.* 2000;70(3):961-3.
15. Salehi M, Ochieng L, Gosling R, et al. Coronary sinus thrombosis as a complication of myocardial infarction-associated ventricular wall rupture: an unusual cause of collapse. *BMJ Case Rep.* 2022;15(3):e248815.

## A Man with Severe, Left Lower Quadrant Abdominal Pain

Ta-Jen Wen, MD\*  
 Yu-Te Su, MD\*  
 Hung-Yen Ke, MD†  
 Kuan-Cheng Lai, MD‡

\*Tri-Service General Hospital, National Defense Medical Center, Department of Emergency Medicine, Taipei, Taiwan  
 †Tri-Service General Hospital, National Defense Medical Center, Division of Cardiovascular Surgery, Department of Surgery, Taipei, Taiwan  
 ‡Chiayi Branch, Taichung Veterans General Hospital, Department of Emergency Medicine, Chiayi, Taiwan

Section Editor: Lev Libet, MD

Submission history: Submitted November 28, 2022; Revision received June 2, 2023; Accepted May 31, 2023

Electronically published August 8, 2023

Full text available through open access at [http://escholarship.org/uc/uciem\\_cpccm](http://escholarship.org/uc/uciem_cpccm)

DOI: 10.5811/cpcem.1601

**Case presentation:** An 84-year-old man presented to the emergency department with sudden, left lower quadrant cramping pain. Because critical hypotension was noted, point-of-care ultrasonography (POCUS) was performed immediately. The study revealed a pulsatile flow extravasating from the left common iliac artery into the left psoas muscle with hypoechoic para-aortic fluid collection.

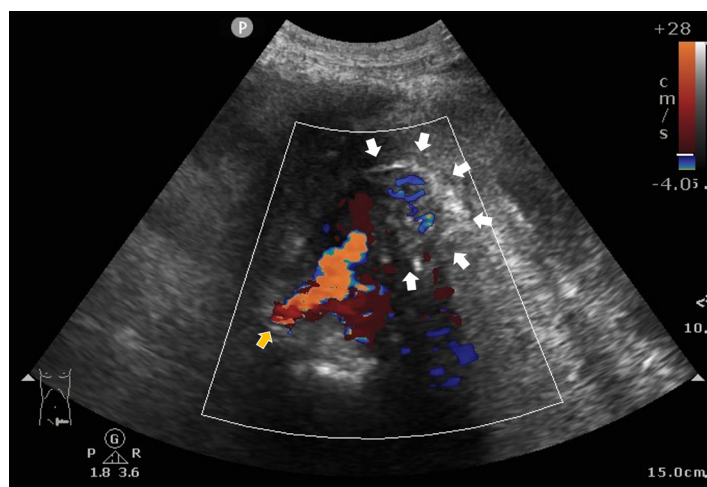
**Discussion:** Common iliac artery rupture is rare and has nonspecific clinical presentations. A quick disposition can be made with a combination of clinical manifestations and POCUS results. [Clin Pract Cases Emerg Med. 2023;7(3):197–199.]

**Keywords:** *Common iliac artery rupture, diagnostic ultrasound, POCUS.*

### CASE PRESENTATION

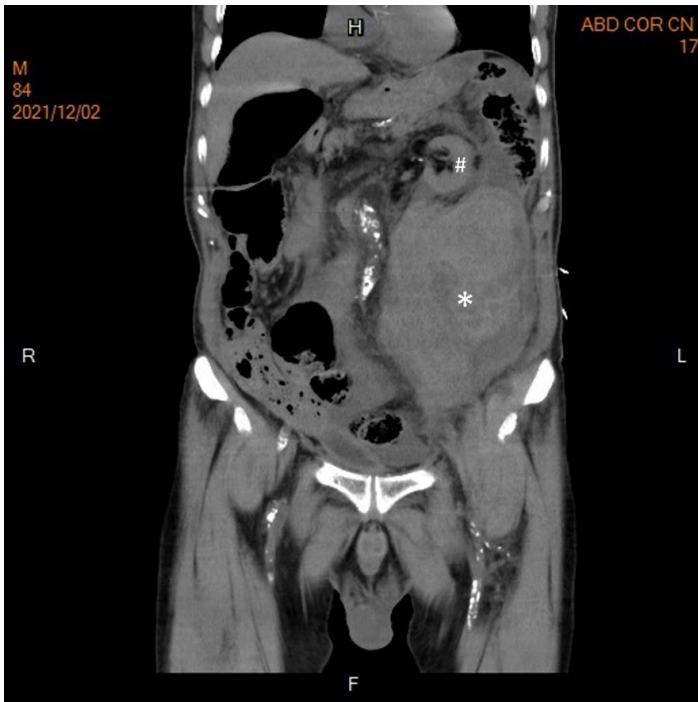An 84-year-old man with a history of hypertension and peripheral arterial occlusive disease presented to the emergency department (ED) with sudden onset of left lower quadrant (LLQ) cramping abdominal pain. The patient was in stable condition with blood pressure 129/61 millimeters of mercury (mm Hg), heart rate 78 beats per minute, and 99% oxygen saturation on room air without respiratory distress on arrival to the ED. Physical examination disclosed mild tenderness over LLQ of abdomen. There was a sudden drop in blood pressure to 66/41 mm Hg with altered consciousness with a Glasgow Coma Score of three (eyes 1, verbal 1, motor 1), while waiting for lab results.

Point-of-care ultrasound (POCUS) over the LLQ of the abdomen showed a left common iliac artery with a demarcated arterial mural defect (Video 1). Pulsatile flow extravasating from the left common iliac artery into the left psoas muscle with a hypoechoic para-arterial fluid collection was noted under color Doppler display (Image 1 and Video 2). Emergent endotracheal intubation and adequate fluid resuscitation with crystalloids was performed immediately. Non-contrast computed tomography was performed subsequently, which revealed a large retroperitoneal hematoma with anterior displacement of the left kidney and



**Image 1.** Point-of-care ultrasound in transverse view over left lower quadrant of abdomen demonstrating an extravasating flow from left common iliac artery (yellow arrow) into left psoas muscle (white arrows) under color Doppler display with hypoechoic para-arterial fluid collection.

descending colon (Image 2). Emergent percutaneous angioplasty was performed based on the suspicion of the rupture of common iliac artery.



**Image 2.** Computed tomography of the abdomen and pelvis, in coronal view, demonstrating a large retroperitoneal hematoma formation (\*) with anterior displacement of left kidney (#).

## DISCUSSION

Common iliac artery rupture is rare and often results from iliac artery aneurysms, dissection, connective tissue disorders (e.g., Marfan, Ehlers-Danlos, and Loeys-Dietz syndromes), atherosclerosis, or even iatrogenesis.<sup>1</sup> Iliac artery aneurysms generally have nonspecific clinical presentations, including relatively nonspecific severe lower abdomen pain, pulsatile abdominal mass, and bruit.<sup>2</sup> Due to the rapid progression and hemodynamic instability of arterial rupture a high index of suspicion by the emergency physician is necessary, and POCUS should be considered to make a timely diagnosis.<sup>3</sup> Sonography may reveal a sharply demarcated aortic mural defect, hypoechoic para-aortic fluid collection, or a heterogeneous collection within a retroperitoneal space. With a combination of clinical manifestations and POCUS results a quick disposition could be made. Percutaneous angioplasty with covered stent (Image 3) in a timely fashion is the main treatment for this emergent condition.<sup>4</sup>

**Video 1.** Point-of-care ultrasound over the left lower quadrant of the abdomen showed a left common iliac artery with demarcated arterial mural defect.

**Video 2.** Point-of-care ultrasound in transverse view over left lower quadrant of abdomen demonstrating a pulsatile extravasating flow from the left common iliac artery with hypoechoic para-arterial fluid collection.

### *CPC-EM Capsule*

What do we already know about this clinical entity?

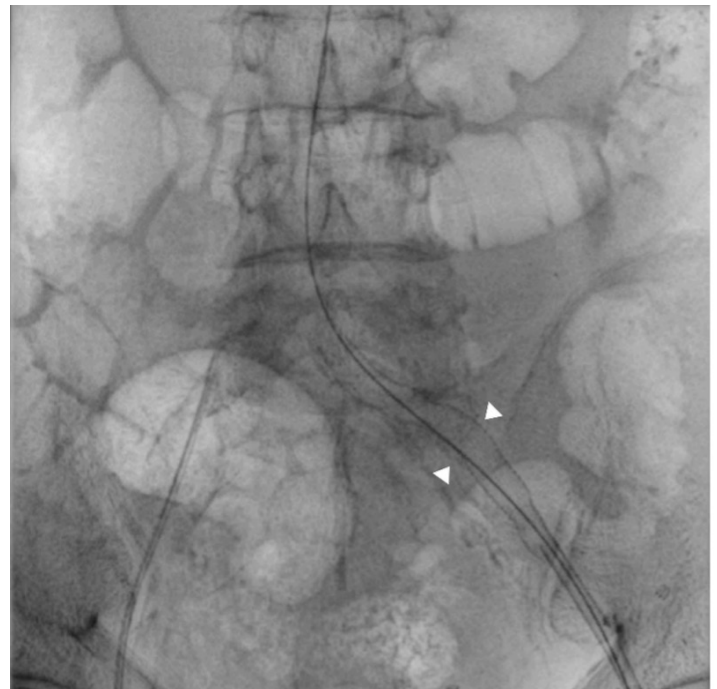
*Common iliac artery rupture is a rare but serious condition often associated with aneurysms, dissection, or connective tissue disorders.*

What is the major impact of the image(s)?

*The images obtained through point-of-care ultrasonography (POCUS) help in timely diagnosis and guide emergent percutaneous angioplasty, potentially preventing fatal outcomes.*

How might this improve emergency medicine practice?

*Increased awareness of this condition and liberal use of POCUS can lead to quicker diagnosis and prompt intervention, improving patient outcomes in cases of common iliac artery rupture.*



**Image 3.** A covered stent (arrowheads) placed in the left common iliac artery by percutaneous transluminal angioplasty.



The Institutional Review Board approval has been documented and filed for publication of this image in emergency medicine.

---

*Address for Correspondence:* Kuan-Cheng Lai, MD, Chiayi Branch, Taichung Veterans General Hospital, Chiayi, Taiwan, Department of Emergency Medicine, 60090, No. 600, Sec. 2, Shixian Rd., West Dist., Chiayi City, Taiwan (R.O.C). Email: DOC50061@mail.ndmctsgh.edu.tw / Laikc926@gmail.com.

*Conflicts of Interest:* By the CPC-EM article submission agreement, all authors are required to disclose all affiliations, funding sources and financial or management relationships that could be perceived as potential sources of bias. The authors disclosed none.

*Copyright:* © 2023 Wen et al. This is an open access article distributed in accordance with the terms of the Creative Commons Attribution (CC BY 4.0) License. See: <http://creativecommons.org/licenses/by/4.0/>

---

## REFERENCES

1. Altobelli E, Rapacchietta L, Profeta VF, et al. Risk factors for abdominal aortic aneurysm in population-based studies: a systematic review and meta-analysis. *Int J Environ Res Public Health*. 2018;15(12):2805.
2. Azhar B, Patel SR, Holt PJ, et al. Misdiagnosis of ruptured abdominal aortic aneurysm: systematic review and meta-analysis. *J Endovasc Ther*. 2014;21(4):568-75.
3. Rubano E, Mehta N, Caputo W, et al. Systematic review: emergency department bedside ultrasonography for diagnosing suspected abdominal aortic aneurysm. *Acad Emerg Med*. 2013;20(2):128-38.
4. Wanhainen A, Verzini F, Van Herzelee I, et al. Editor's Choice - European Society for Vascular Surgery (ESVS) 2019 Clinical Practice Guidelines on the Management of Abdominal Aorto-iliac Artery Aneurysms. *Eur J Vasc Endovasc Surg*. 2019;57(1):8-93.

## Female with Atraumatic Abdominal Bruising

Zachary S. Pacheco, MD  
Grace Johnson, MD  
Erin F. Shufflebarger, MD

University of Alabama Birmingham Heersink School of Medicine, Department of  
Emergency Medicine, Birmingham, Alabama

Section Editor: Joel Moll, MD

Submission history: Submitted March 26, 2023; Revision received June 6, 2023; Accepted June 5, 2023

Electronically published August 4, 2023

Full text available through open access at [http://escholarship.org/uc/uciem\\_cpem](http://escholarship.org/uc/uciem_cpem)

DOI: 10.5811/cpcem.1247

**Case presentation:** We describe the case of a 38-year-old female patient with a history of lupus presenting with atraumatic abdominal pain and ecchymosis. The ultimate diagnosis of abdominal lupus erythematosus panniculitis was determined based on physical exam and imaging findings.

**Discussion:** Lupus erythematosus panniculitis is a rare diagnosis, but consideration is important as early recognition and treatment is important to reduce pain and lessen the possibility of irreversible disfigurement and unnecessary costs to affected patients. [Clin Pract Cases Emerg Med. 2023;7(3):200–201.]

**Keywords:** *Lupus erythematosus panniculitis; dermatology.*

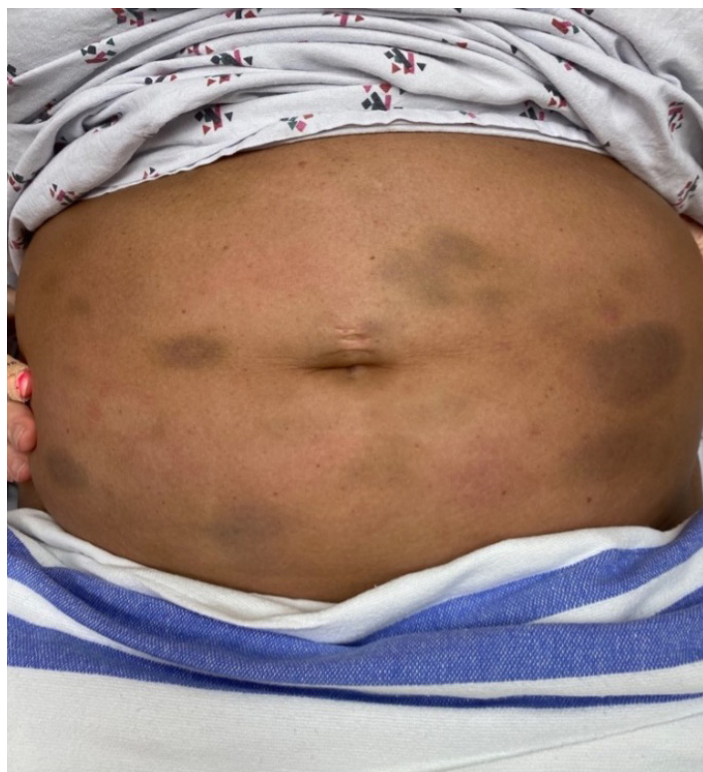### CASE PRESENTATION

A 38-year-old female with a history of cutaneous lupus erythematosus on hydroxychloroquine presented to the emergency department (ED) with months of abdominal pain and two weeks of abdominal ecchymosis with underlying palpable nodules. She endorsed nausea without emesis, small-volume bowel movements, and shortness of breath secondary to pain. She denied similar previous episodes of this bruising or pain. However, the patient reported that her mother also had lupus with similar symptoms. Her abdominal exam was notable for generalized tenderness, diffusely scattered ecchymosis with palpable subcutaneous nodules (Image 1). Laboratory findings were unremarkable. Abdominal computed tomography was performed (Image 2).

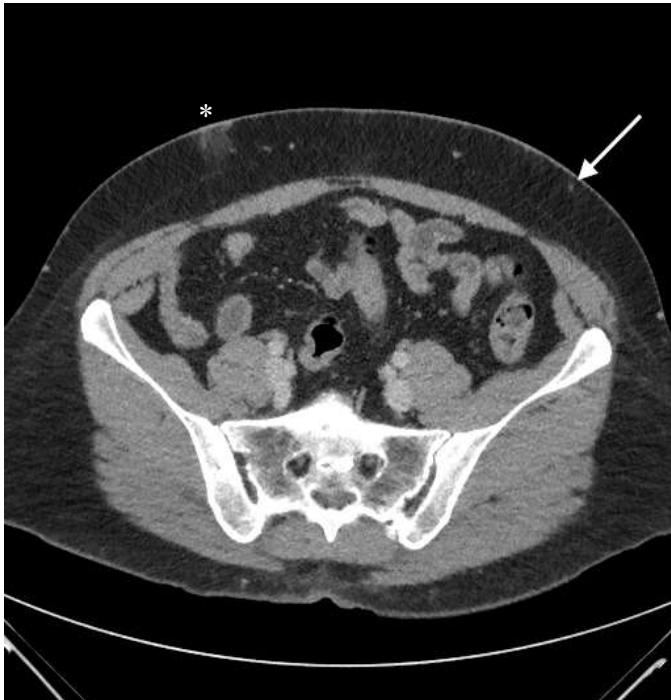The patient's exam and imaging findings led to the diagnosis of lupus erythematosus panniculitis (LEP) of the abdomen. After this diagnosis, she was discharged with a short course of steroids. At follow-up with her primary care physician weeks later, abdominal nodules were noted to be smaller in size and no longer tender.

### DISCUSSION

This case describes a rare ED diagnosis of abdominal LEP. This condition is a rare variant of systemic lupus erythematosus, occurring in approximately 2% of patients



**Image 1.** Scattered ecchymosis and nodularity seen on the patient's abdominal physical exam.



**Image 2.** Computed tomography of the abdomen demonstrating areas of subcutaneous stranding and edema (\*), as well as scattered areas of nodularity (arrow) in the soft tissues of the abdominal wall.

with this condition; however, it can also be seen in association with discoid lupus erythematosus or in isolation.<sup>2</sup> Most lesions have been described as affecting the proximal extremities, face, and back of middle-aged females with a prior diagnosis of lupus.<sup>2</sup> In patients with history and clinical exam suggestive of LEP, imaging including ultrasound, computed tomography, or magnetic resonance imaging can be used to evaluate for underlying abscess and for further characterization of the lesions.<sup>3</sup> However, biopsy and histopathology are recommended for definitive diagnosis.<sup>3</sup>

The diagnosis of LEP is often delayed for greater than one year, which can lead to preventable complications such as calcification or atrophy. Treatment often requires two or more systemic therapies including first-line hydroxychloroquine; recurrence is common.<sup>4</sup> It is important that emergency physicians be aware of this rare diagnosis and consider it when evaluating patients with relevant medical history, as timely diagnosis and treatment is important for pain reduction, irreversible disfigurement, and costs for affected patients.<sup>4</sup>

The authors attest that their institution requires neither Institutional Review Board approval for publication of this case report. Patient consent was obtained. Documentation on file.

### *CPC-EM Capsule*

What do we already know about this clinical entity?

*Lupus erythematosus panniculitis (LEP) is rare, with lesions typically affecting the proximal extremities, face, and back of middle-aged females with a prior lupus diagnosis.*

What is the major impact of the image(s)?

*In patients with history and clinical exam suggestive of LEP, imaging aids evaluation for underlying abscess and further characterization of the lesions.*

How might this improve emergency medicine practice?

*Timely diagnosis and treatment is important for reducing pain and avoiding irreversible disfigurement and costs for affected patients.*

*Address for Correspondence:* Erin F. Shufflebarger, MD, University of Alabama Birmingham Heersink School of Medicine, Department of Emergency Medicine, GSB Suite 203, 521 19<sup>th</sup> Street South, Birmingham, AL 35233. Email: erinshufflebarger@uabmc.edu.

*Conflicts of Interest:* By the CPC-EM article submission agreement, all authors are required to disclose all affiliations, funding sources and financial or management relationships that could be perceived as potential sources of bias. The authors disclosed none.

*Copyright:* © 2023 Pacheco et al. This is an open access article distributed in accordance with the terms of the Creative Commons Attribution (CC BY 4.0) License. See: <http://creativecommons.org/licenses/by/4.0/>

### REFERENCES

1. Diaz-Jouanen E, DeHoratius RJ, Alarcon-Segovia D, et al. Systemic lupus erythematosus presenting as panniculitis (lupus profundus). *Ann Intern Med.* 1975;82(3):376-9.
2. Fraga J and García-Díez A. Lupus erythematosus panniculitis. *Dermatol Clin.* 2008;26(4):453-63.
3. Kimball H, Kimball D, Siroy A, et al. Novel diagnostic imaging features of facial lupus panniculitis: ultrasound, CT, and MR imaging with histopathology correlate. *Clin Imaging.* 2019;58:177-81.
4. Rangel LK, Villa-Ruiz C, Lo K, et al. Clinical characteristics of lupus erythematosus panniculitis/profundus: a retrospective review of 61 patients. *JAMA Dermatol.* 2020;156(11):1264-6.

# Leser-Trélat Sign as a Marker for Underlying Pancreatic Cancer

Kalpiti Modi, MD  
Richard Chen, MD  
Layla Abubshait, MD

Einstein Healthcare Network, Einstein Medical Center Montgomery Emergency  
Department, East Norriton, Pennsylvania

Section Editor: Lev Livet, MD

Submission history: Submitted March 26, 2023; Revision received June 13, 2023; Accepted June 23, 2023

Electronically published August 9, 2023

Full text available through open access at [http://escholarship.org/uc/uciem\\_cpem](http://escholarship.org/uc/uciem_cpem)

DOI: 10.5811/cpcem.1248

**Case Presentation:** Early diagnosis and rapid treatment of cancer is essential for good clinical outcomes for patients. In this case, an 85-year-old man presented with failure to thrive and was noted to have rapid-onset, multiple seborrheic keratoses (Leser-Trélat sign) on his chest and back. He was ultimately diagnosed with pancreatic cancer using computed tomography.

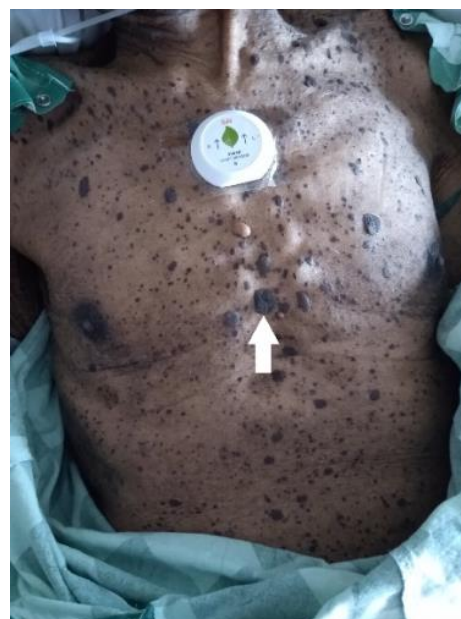**Discussion:** Leser-Trélat sign is a rare cutaneous marker for underlying malignancy. Identification of this sign can help guide diagnostic imaging and lab work to identify an occult internal malignancy, resulting in more rapid diagnosis, earlier treatment, and potentially better clinical outcomes. [Clin Pract Cases Emerg Med. 2023;7(3):202–204.]

**Keywords:** Leser-Trélat, cancer, malignancy, seborrheic keratosis.

## CASE PRESENTATION

An 85-year-old man with a history of chronic obstructive pulmonary disease, chronic kidney disease, congestive heart failure, and atrial fibrillation presented to the emergency department (ED) via ambulance for failure to thrive. The patient's home-care nurse was concerned due to his worsening weakness, development of peripheral edema, decreasing appetite, and general deterioration over the prior week. The patient had no complaints, aside from diarrhea, and was not sure why his home-care nurse had called for an ambulance. On arrival to the ED, the patient was hemodynamically stable and oxygenating well on a baseline of two liters of oxygen via nasal cannula. He appeared thin and frail and had significant generalized weakness when moving his extremities. Cutaneous exam showed numerous seborrheic keratoses on his chest, abdomen, and back (Image 1).

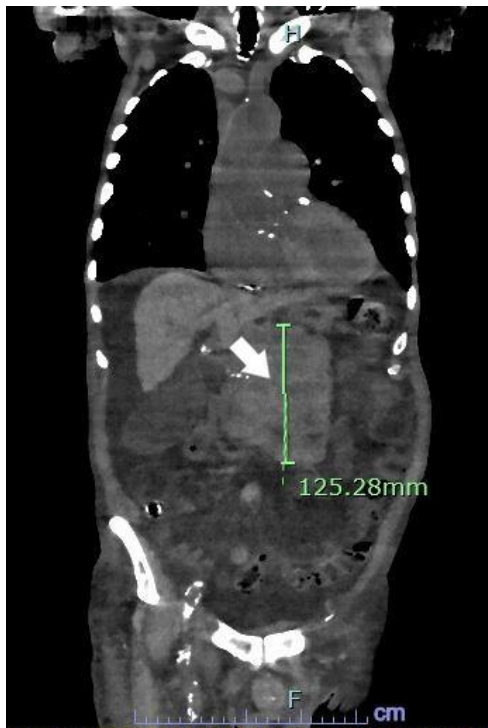
The patient had no abdominal tenderness to palpation. However, he did have significant lower extremity edema. His constellation of symptoms in combination with the cutaneous finding (absent on skin exams from his admission two months prior) raised suspicion that his eruptive skin lesions were a manifestation of the Leser-Trélat sign (LTS). He underwent computed tomography (CT) of the abdomen and pelvis, which revealed a lobular mass in the pancreatic body measuring 10 centimeters (cm) x 11 cm x 12 cm, concerning for likely malignancy (Images 2, 3). After admission to the hospital, the



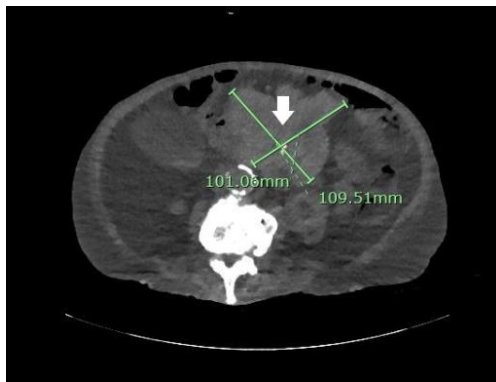
**Image 1.** Multiple seborrheic keratoses (arrow) on the chest and abdomen.

patient and family made the joint decision to transition him to hospice care, opting to forego further medical management of the underlying cancer.





**Image 2.** Pancreatic mass (arrow) diagnosed via computed tomography of the abdomen and pelvis in coronal view.



**Image 3.** Pancreatic mass (arrow) diagnosed via computed tomography of the abdomen and pelvis in axial view.

## DISCUSSION

Leser-Trélat sign is a rare cutaneous marker for underlying malignancy.<sup>1,2</sup> It manifests with a sudden appearance or rapid accumulation of multiple seborrheic keratoses on the chest, abdomen, or back.<sup>2</sup> Seborrheic keratoses are waxy-textured papules that are black or brown in color and characterized by their appearance of being stuck onto the skin.<sup>3</sup> Seborrheic keratoses are themselves benign skin growths that grow slowly over a number of years, but their accumulation or sudden appearance (often within one year) can be a sign of an underlying malignancy.<sup>1,4</sup> The most common malignancies associated with LTS are those of the gastrointestinal tract, in

### *CPC-EM Capsule*

What do we already know about this clinical entity?

*The Leser-Trélat sign, the rapid appearance or accumulation of seborrheic keratoses, is a rare cutaneous marker that can point to an underlying malignancy.*

What is the major impact of the image(s)?

*The images show a manifestation of the Leser-Trélat sign in a patient ultimately diagnosed with pancreatic cancer.*

How might this improve emergency medicine practice?

*Identification of the Leser-Trélat sign in the emergency department can lead to earlier diagnosis and treatment of the underlying cancer.*

particular, gastric adenocarcinoma.<sup>1</sup> The pathogenesis of LTS is still unknown but hypothesized to be paraneoplastic in nature.<sup>1,2,4</sup>

In the ED, incidental cutaneous findings are often disregarded in favor of more pressing pathologies; however, identification of LTS can direct imaging that could lead to earlier diagnosis and treatment of the underlying cancer.<sup>5</sup> Prognosis of patients with LTS is often poor since the cancer is usually in a more advanced stage.<sup>2,5</sup> To clarify, it is not always necessary to search for an underlying malignancy in the ED for patients with LTS. Instead, identification of LTS is important because it spurs physicians to arrange close follow-up with an outpatient dermatologist for further testing.

The authors attest that their institution requires neither Institutional Review Board approval or patient consent for publication of this article. Documentation on file.

*Address for Correspondence:* Author Kalpit Modi, MD, Einstein Healthcare Network, Einstein Medical Center Montgomery Emergency Department, 559 W. Germantown Pike, East Norriton, PA 19403. Email: kalpit.modi@jefferson.edu.

*Conflicts of Interest:* By the CPC-EM article submission agreement, all authors are required to disclose all affiliations, funding sources and financial or management relationships that could be perceived as potential sources of bias. The authors disclosed none.

*Copyright:* © 2023 Modi et al. This is an open access article distributed in accordance with the terms of the Creative Commons Attribution (CC BY 4.0) License. See: <http://creativecommons.org/licenses/by/4.0/>

**REFERENCES**

1. Ellis DL and Yates RA. Sign of Leser-Trélat. *Clin Dermatol*. 1993;11(1):141-8.
2. Schwartz RA. Sign of Leser-Trélat. *J Am Acad Dermatol*. 1996;35(1):88-95.
3. Gorai S, Ahmad S, Raza SSM, et al. Update of pathophysiology and treatment options of seborrheic keratosis. *Dermatol Ther*. 2022;35(12):e15934.
4. Khemakhem R, Kallel N, Jarraya R, et al. Leser-Trélat syndrome secondary to non-small-cell lung carcinoma. *Clin Case Reports*. 2022;10(8):e6069.
5. Wagner Jr RF and Wagner KD. Malignant neoplasms and the Leser-Trélat sign. *Arch Dermatol*. 1981;117(9):598-99.

JOIN  
CAL/AAEM!



**CALAAEM**

CALIFORNIA CHAPTER MEMBERSHIP OF THE  
AMERICAN COLLEGE OF EMERGENCY PHYSICIANS

*Championing  
individual physician rights  
and workplace fairness*

## **BENEFITS**

- Western Journal of Emergency Medicine Subscription
- CAL/AAEM News Service email updates
- Discounted AAEM pre-conference fees
- And more!

## **CAL/AAEM NEWS SERVICE**

- Healthcare industry news
- Public policy
- Government issues
- Legal cases and court decisions

In collaboration with our official journal

**WestJEM** Integrating Emergency Care  
with Population Health

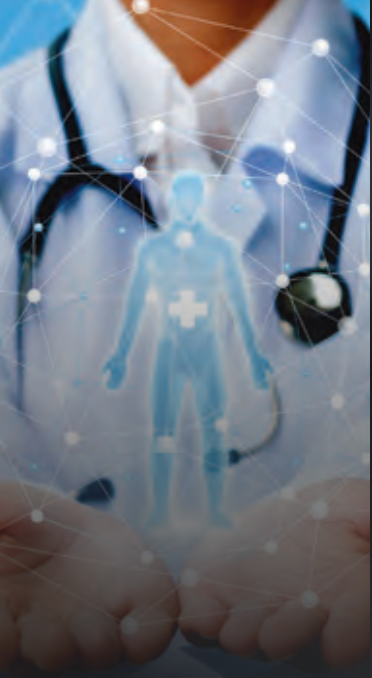


FACEBOOK.COM/CALAAEM



FOLLOW US @CALAAEM

[HTTP://WWW.CALAAEM.ORG](http://www.calaaem.org)



# ADVANCED **ED** >

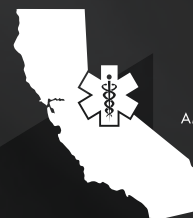## **EvolvED: Redefining EM**

> **CALIFORNIA ACEP'S ANNUAL CONFERENCE 2023**

Education is targeted to Medical Students and Residents, but all are welcome to attend.

**Friday, September 8, 2023**

The Sheraton Pasadena



**CALIFORNIA ACEP**  
AMERICAN COLLEGE OF EMERGENCY PHYSICIANS